

New record of parasitic isopod (Isopoda: Bopyridae) infecting the branchial chamber of blue swimming crab *Portunus pelagicus* (Linnaeus, 1758) (Decapoda: Portunidae) in the Philippines


Marwin B. Dela Cruz¹ • Karl Marx A. Quiazon² • Emmanuel M. Vera Cruz²

¹ Fisheries and Marine Sciences Department, Cavite State University – Naic Campus, Naic, Cavite 4110, Philippines

² Department of Aquaculture, College of Fisheries, Central Luzon State University, Science City of Muñoz, Nueva Ecija 3120, Philippines

Correspondence

Marwin B. Dela Cruz; Fisheries and Marine Sciences Department, Cavite State University – Naic Campus, Naic, Cavite 4110, Philippines

 Awenbuenacruz@gmail.com

Manuscript history

Received 9 August 2019 | Revised 28 March 2020 | Accepted 31 March 2020 | Published online 3 April 2020

Citation

Dela Cruz MB, Quiazon KMA, Vera Cruz EM (2020) New record of parasitic isopod (Isopoda: Bopyridae) infecting the branchial chamber of blue swimming crab *Portunus pelagicus* (Linnaeus, 1758) (Decapoda: Portunidae) in the Philippines. *Journal of Fisheries* 8(1): 746–751.

Abstract

A parasitic disease causing swollen carapace in commercially important blue swimming crab (*Portunus pelagicus* L.) has not received considerable attention; neither its causative agent is identified nor its seasonality is recorded. This study aimed to identify the parasite in *P. pelagicus* inhabiting the Manila Bay. Parasite found in the branchial chamber were isolated, preserved in ethanol and examined. A total of 292 crab specimens were examined and ten were found to be infected (3.42% prevalence with 0–2 parasites per host). Infections were only observed in November 2014 and between January and June 2015. The highest prevalence of infection (10.34%) was recorded in January 2015 whereas the greatest intensity of infection (up to two parasites per infected crab individual) was recorded from February to April 2015. The parasite, based on morphology, was identified as *Allokepon monodi*. This study presents the third record of female and second record of male *A. monodi* infecting a crab species. It also represents the first record of male *A. monodi* in *P. pelagicus* and in the Philippines. We recommend further studies on the impacts and economic implications of the disease.

pelagicus

1 | INTRODUCTION

Crabs are commercially important species of high demand around the globe (Hungria *et al.* 2017; Rahman *et al.* 2020). Blue swimming crab, *Portunus Pelagicus* Linnaeus represents a valuable component of small-scale coastal fisheries in many countries in the tropical and temperate altitudes (Enany *et al.* 2012) including the Philippines (DA-

BFAR 2013). The Philippines (34,076 t) followed the top crab producer, China (52,577 t), in terms of catches (FAO-UN 2014). However, resource reduction on raw crab supply has become more of a problem in the country since 2009. The major problem is the difficulty to catch considerable amount of crab compared to previous years (DA-BFAR 2013).

Currently, a parasitic disease has been observed in *P. pelagicus* along Manila Bay in the Philippines. This parasitic organism is often found attached to the gill chambers and results in deformity of the crab carapace. In both wild and captive crabs mortalities and reduced market demand may be expected when affected by diseases (Messick and Sindermann 1992). However, the role played by infectious disease in limiting the sustainability of the production of crustaceans has largely been neglected (Rowley *et al.* 2014).

Parasites are common in ecosystems and are also known from the fossil record (Klomp-maker *et al.* 2014). Isopod-induced swellings in the branchial chamber of marine decapod crustaceans were reported in the fossil from the Jurassic period and this has been generally associated to be of bopyrid origin (Williams and Boyko 2012; Klomp-maker *et al.* 2014). In this study parasitic infestation of blue swimming crab is reported with special reference to its prevalence and intensity in relation to sampling months and host sex for the first time.

2 | METHODOLOGY

A total of 292 blue swimming crab *Portunus Pelagicus* specimens were collected between October 2014 and September 2015 from the Manila Bay (N14.762027°, E120.768985°), Philippines. Monthly random collections of 1 kg of blue swimming crab were carried out. After collection, crab specimens were sexed following DA-BFAR (2013). Infected crabs were identified through the presence of carapace bulge and preserved in 70% ethanol. Later parasites from the swollen portion of carapace were separated and preserved in 70% ethanol solution. Gross morphological examination under a dissecting microscope (Zeiss Stemi SV II Apo) was carried out for the identification, sexing and life stage determination (after Duan *et al.* 2008). However, differences in body parts between male and female parasites were examined under a light microscope (Olympus CKX4, Japan), based on a total of 11 female including four mature and seven immature and two male parasites.

All illustrations presented in this paper were drawn using a stereo microscope (Amscope Forward Stereo Microscope, USA). All descriptions were carried out following the terminologies and definitions from previous studies (e.g. Kensley and Schotte 1989; Markham 1998).

3 | RESULTS

3.1 Intensity and prevalence of infection

The length (as carapace size, CL) of crab specimens examined varied from 45 to 110 mm whereas infected individuals were 63 – 85 mm CL. With respect to seasons, infection was only recorded in November 2014 and from January to June 2015 (Table 1). The highest prevalence of infection was in January 2015 (10.34%) whereas the highest

intensity of infection was recorded from February to April 2015 (up to 2 parasites per crab). The overall prevalence of infection during the whole survey period was 3.42% with an intensity of infection ranged from 0 – 2 parasites per individual crab.

TABLE 1 Intensity and prevalence of infection of parasitic isopod in blue swimming crab in various sampling months.

Month	No. of crab kg ⁻¹ (♂ – ♀)	No. of infected crab	No. of isolated parasite	Prevalence of infection (%)	Intensity of infection
2014					
Oct	28 (4–24)	0	0	0	0
Nov	25 (18–7)	1	1	4	0–1
Dec	22 (21–1)	0	0	0	0
2015					
Jan	29 (23–6)	3	3	10.34	0–1
Feb	25 (14–11)	1	2	4	0–2
Mar	24 (12–12)	2	3	8.33	0–2
Apr	18 (16–2)	1	2	5.55	0–2
May	26 (16–10)	1	1	3.85	0–1
Jun	24 (16–8)	1	1	4.17	0–1
Jul	21 (14–7)	0	0	0	0
Aug	21 (11–10)	0	0	0	0
Sep	29 (14–15)	0	0	0	0
Total	292 (179–113)	10	13	3.42	0–2

Among the collected crab specimens 179 were male and 113 were female. Eight male crabs were infected (3.35% infection prevalence) with up to 2 parasites per host. In case of female crab, five were infected (3.54% infection prevalence) with up to 0–2 parasites per individual (Table 2).

TABLE 2 Intensity and prevalence of parasitic infection in male and female blue swimming crab.

Sex	No. of specimen	No. of infected crab	No. of isolated parasite	Intensity	Prevalence (%)
Male	179	6	8	0–2	3.35
Female	113	4	5	0–2	3.54
Total	292	10	13	0–2	3.42

Gross morphological examination revealed that all isolated parasites were *Allokepon monodi* Bourdon 1967 isopod. Two crab specimens were infected with both male and female parasites. In majority (80%) of the cases crabs were infected by female parasite only whereas, none found to be infected by male parasite only. Parasites were found on either single or both sides of carapace and bran-

chial chambers. Morphological descriptions of the species isolated are as follows:

Bopyridae Rafinesque-Schmaltz, 1815
Allokepon monodi (Bourdon, 1967)

3.2 Description of mature female (4 specimens)

Maximal length (excluding uropod) 11.41 – 14.68 mm (mean: 13.56 mm), pereonal length 6.39 – 7.62 mm (mean: 6.99 mm), pereon maximal width 8.56 – 10.02 mm (mean: 9.26 mm), pleonal length 3.65 – 5.15 mm (mean: 4.59 mm), pleon maximal width 1.62 – 1.93 mm (mean: 1.61 mm). Body outline was oval and almost circular in form (Figures 1).

Head with well-defined bilobate feature, sub-heart shaped, wider than length and slightly extended beyond the first pereomere. Head length 2.04 mm, head width 3.12 mm. Frontal lamina extended beyond sides of the head, medial part slightly visible in dorsal view. No visible eyes, antennae and barbula. Maxilliped (Figure 1F) broad towards anterior part of the body and narrowing posteriorly; with prominent non-articulating, falcate and setose palp, anteriomedially located and extending beyond front of maxilliped.

Pereon of seven pereomeres is broader than length. Pereon is the broadest across 3rd pereomere and tapering smoothly before and behind. First five pereomeres

indistinguishably separated via margin, only the 6th and 7th pereomeres have prominent, spicate and triangularly falcate mid-dorsal projections making it distinguishable among pereomeres. Dorsolateral bosses present at pereomeres 1st – 4th while tergal projections at pereomeres 1st to 5th. Each pereomere has pair of pereopods, 7 pairs of pereopods in total. All pereopods of six segments are similar in structure (Figure 1E) except differences in sizes as it markedly increases posteriorly. Length of pereopod (attached to 1st pereomere) is 3.30 mm. Oostegites completely enclosed brood pouch. Oostegite (Figure 1G–H) with sub-circular anterior segment, produced into falcate extended point posterolaterally, with internal ridges on anterior segments.

Pleon of six pleomeres is longer than width, pleon is broadest at 1st pleomere, and first five pleomeres have lateral plates longer than biramous pleopods of similar structures (Figure 1D). Pleopod and lateral plate length (attached to 5th pleomere) varied from 2.36 to 4.45 mm. First five pleomeres and lateral plates have tuberculiform projections visible in the ventral view. Last pleomere is small, bilobed, with no lateral plates and has uniramous uropod with similar structure with lateral plates (Figure 1C). Uropod length is 4.60 mm (right) and 4.35 mm (left). In total, the parasite has 12 pleonal appendages that are 32 in total rami.

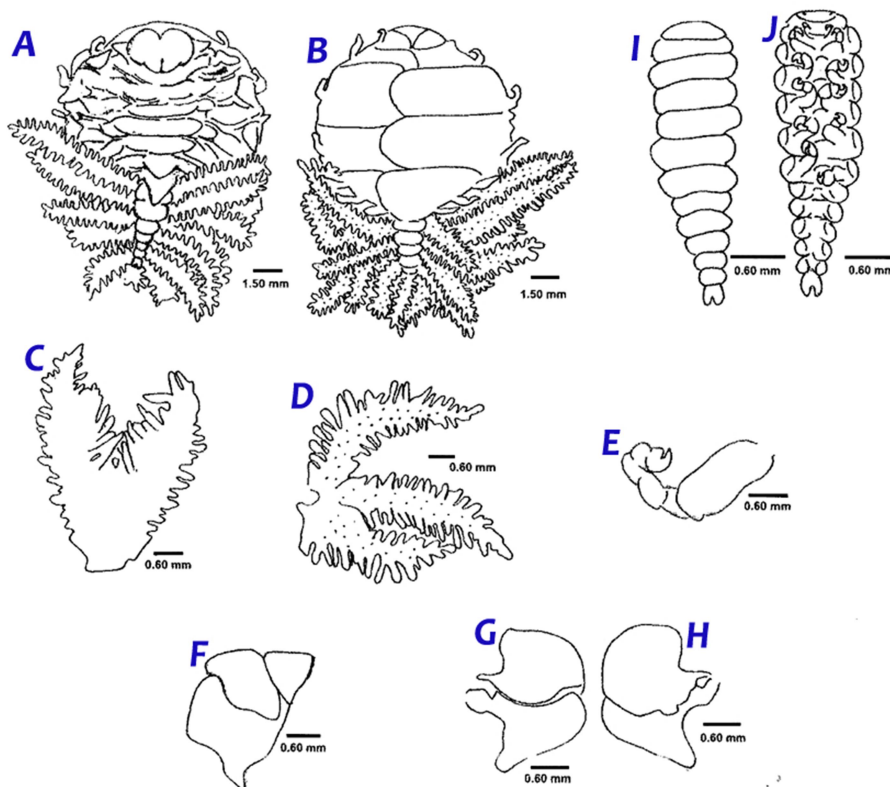


FIGURE 1 Whole and body parts of representative mature female (A – H) and male (I – J) *Allokepon monodi*. A, dorsal view; B, ventral view; C, uropod; D, 5th left pleopod; E, 1st left pereopod; F, left maxilliped; G, right oostegite 1 external view; H, same internal view; I, dorsal view; J, ventral view. Scale: 1.50 mm for A and B; 0.60 mm for C to I.

3.3 Description of male (2 specimens)

Mean maximal length 2.92 mm (2.74 – 3.09 mm), pereon length 1.54 – 1.71 (mean: 1.63) mm, pereon maximal width 0.82 – 0.97 mm (mean: 0.9 mm), pleonal length 1.05 – 1.25 mm (mean: 1.15 mm), pleon maximal width 0.77 – 0.84 mm (mean: 0.81 mm). Body outline is fusiform (Figure 1I–J). No spots on the dorsal surface.

Head obscurely sub-oval and extending to the first pereomere. No eyes. Antennae obscurely present from ventral side. Pereon of 7 pereomeres is longer than width, widest at 3rd pereomere and is smoothly tapering anteriorly and posteriorly. Mid-ventral tubercle projection present on each pereomere. Pereon with 7 pairs of pereopods. Well defined pereomere margins from dorsal view (Figure 1I).

Pleon of 6 pleomeres is longer than width, widest at 1st pleomere and is smoothly tapering posteriorly. No mid-ventral projections on pleomeres. Obscure oval pleopod-like projections from the posterior corners of 1st to 5th pleomeres. Sixth pleomere has bilobate digitate projection which also has an appearance of double emarginated fish tail.

3.4 Description of immature female (7 specimens)

Maximal length excluding uropod 7.31 – 11.31 mm (mean: 9.33 mm), pereon length 4.53 – 6.83 mm (mean: 5.70 mm), pereon maximal width 3.64 – 7.02 mm (mean: 5.61 mm), pleonal length 2.32 – 4.05 mm (mean: 3.17 mm), pleonal maximal width 1.16 – 2.16 mm (mean: 1.66 mm). Body outline sub-oval.

Head bilobed, sub-heart shaped, wider than length and slightly extended beyond the first pereomere. Frontal lamina slightly extending beyond both sides of the head and medial part visible in the dorsal view. No visible eyes, antennae and barbula.

Pereon of seven pereomeres is slightly broader than length (generally narrower than mature female). Pereon is broadest across 4th pereomere, tapering smoothly before and behind. All pereomeres distinguishably separated via margin, only the 6th and 7th pereomeres have prominent, spicate and triangularly falcate mid-dorsal projections making it distinguishable among pereomeres, mid-dorsal projection of the last or 7th pereomere has a more falcating appearance and more defined than the other. Dorsolateral bosses present at pereomeres 1st – 4th while tergal projections obscurely present. Each pereomere has pair of pereopods, 7 pairs of pereopods in total. All pereopods similar in structure (Figure 2E) except differences in size, increases posteriorly.

Pleon of six pleomeres is longer than width, pleon is broadest at 1st pleomere (Figure 2A), and first five pleomeres have lateral plates and biramous slender pleopods of similar structures with tuberculiform projections on ventral surface (Figure 2C). Smaller immature female parasites (Figure 2G) have pleopods with slightly digitate tuberculiform projections. Last pleomere is small, bilobed, no lateral plates and has uniramous uropod with similar structure with lateral plates (Figure 2D). In total, the parasite has 12 pleonal appendages that are 32 in total rami.

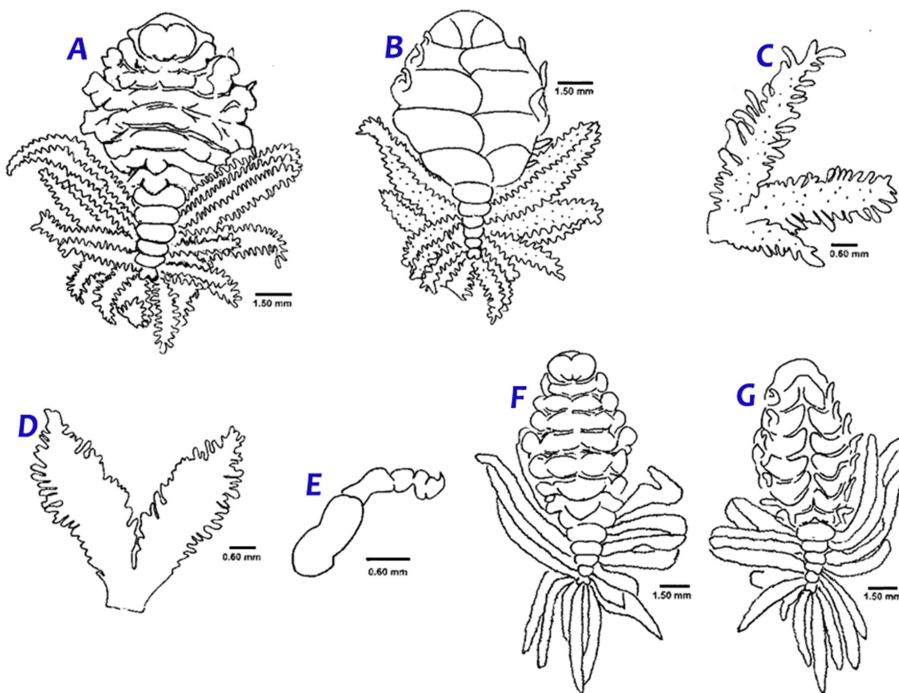


FIGURE 2 Whole and body parts of representative immature females *Allokepon monodi* (specimen 1, A–E; specimen 2, F–G). A, dorsal view; B, ventral view; C, 5th left pleopod (ventral view); D, uropod; E, 2nd left pereopod; F, dorsal view; G, ventral view. Scale: 1.50 mm for A, B, F and G; 0.60 mm for C to E.

In Hainan, China, female *A. monodi* has been found to infect *Thalamita* spp., *P. pelagicus* and *P. trituberculatus*. Moreover, *Thalamita* spp. has also been parasitized by male *A. monodi* (Duan *et al.* 2008). The first record of female *A. monodi* infecting *Stenorhynchus seticornis* in Senegal was reported by Bourdon (1967) and was first named *Portunicepon monodi*, but was later transferred to the genus *Allokepon* (Duan *et al.* 2008). In this study *A. monodi* were retrieved from the branchial chambers of crabs but study in China by Duan *et al.* (2008) did not mention its site of infection. Slightly bigger parasitic specimens were obtained in this study. However, major morphological features of both male and female parasites conformed very well with those recorded in China (Duan *et al.* 2008).




FIGURE 3 Digital photographs of *Portunus pelagicus* (A – B) infected with *Allokepon monodi* (C – J). A, whole specimen of infected crab showing the swollen portion of the carapace (with arrow); B, infected crab with carapace removed, showing the parasitic isopod in the branchial chamber; C, dorsal view of parasite female; D, ventral view of mature female; E, ventral view of male; F, dorsal view of male; G, dorsal view of immature female (larger specimen); H, ventral view of immature female (larger specimen); I, dorsal view of immature female (smaller specimen); and J, ventral view of immature female (smaller specimen).

4 | DISCUSSION

An *et al.* (2015) has reviewed four species of the genus *Allokepon* including *A. hendersoni*, *A. longicauda*, *A. monodi* and *A. sinensis*. The present materials from the

Philippines (Figure 3) have morphologically conformed to *A. monodi* based on the descriptions and illustrations of Duan *et al.* (2008). This study reports the third record of female *A. monodi* infecting crab species and second record of the male parasite. Moreover, this is the first record of *P. pelagicus* hosting male *A. monodi* and the Philippines as a new locality of the parasite. Hosts exhibited carapace bulging on either left or right side. Swellings of both left and right sides were also manifested. Hosts were either parasitized by female *A. monodi* only or by both male and female but none with solely by male.

The number of parasite infected the crab (up to two parasites per crab) and the percentage of infected *P. pelagicus* is relatively low (prevalence of 3.42%). Low prevalence of bopyrid infestation was also reported in other crustacean group (e.g. shrimp, <5%; Bower 2006). A further example may include infestation of *Epipenaeon ingens* in *Penaeus semisulcatus* with 0.2 – 0.7% prevalence which has been reported in the Philippines (Palisoc 1987). Slightly higher prevalence of infection (8.6%) by *E. latifrons* in *Fenneropenaeus indicus* was also reported in the Philippines (Eduardo 2017). These data fit with that of the prevalence of infection in January and March 2015 of this study with 10.34% and 8.33% prevalence respectively. Nonetheless, higher percentages of infection were also reported; *E. japonicus* (up to 70%) in Japanese red prawn (*Penaeopsis akayebi*; Sinderman 1990), *E. ingens* (25%) in tiger prawn (*P. semisulcatus*) of Australia (Somers and Kirkwood 1991). Moreover, the slightly higher prevalence of infection of female host (3.54%; c.f. 3.35% for males) was not surprising as the female hosts are common than male (Danforth 1963; Jay 1989). This has led to considerable speculation on the effect of bopyrid parasite on its hosts because some bopyrid parasitic infestation affect reproductive capability of hosts that it may be reduced or may cause complete parasitic castration of their hosts, either gonad of female hosts do not mature or parasitized males are feminized (Van Wyk 1982; O'Brien and Van Wyk 1985; William and Boyko 2012). Therefore, it could lead to misidentification of the true sex of host and may favour higher prevalence to female hosts. It is recommended that further studies should employ molecular tools to identify the parasite. In addition, the infection distribution in the whole Philippines should also be explored.

ACKNOWLEDGEMENTS

The authors would like to thank College of Fisheries and the Freshwater Aquaculture Center of the Central Luzon State University in the Philippines. Much appreciation is also given to the reviewers of this research paper.

CONFLICT OF INTEREST

The authors declare no conflict of interest.

REFERENCES

- An J, Boyko CB, Li X (2015) A review of bopyrids (Crustacea: Isopoda: Bopyridae) parasitic on caridean shrimps (Crustacea: Decapoda: Caridea) from China. *Bulletin of the American Museum of Natural History* 399: 1–85.
- Bower MS (2006) Parasitic diseases of shellfish. In: Woo PTW (Ed) *Fish diseases and disorders 1: protozoan and metazoan infections*, 2nd ed. CABI, Oxfordshire, UK.
- DA-BFAR (2013) The Philippine blue swimming crab management plan. Bureau of Fisheries and Aquatic Resources, Philippines.
- Danforth CG (1963) Bopyridian (Crustacea, Isopoda) parasites found in the eastern pacific of the United States. PhD thesis, Oregon State University, Oregon, USA.
- Duan J, An J, Yu H (2008) A new species and two new record species of genus *Allokepon* Markham, 1982 (Isopoda: Epicaridea: Bopyridae) from China. *Zootaxa* 1682: 62–68.
- Eduardo SL (2017) *Epipenaeon latifrons* (Isopoda: Bopyridae) and *Pandarus rhincodoniscus* (Copepoda: Pandaridae), new records of parasitic crustaceans for the Philippines. *Philippine Journal of Veterinary Medicine* 54(2): 91–100.
- Enany ME, El-Atta ME, El Tantawy MM (2012) Incidence of some bacterial pathogens in summer season from shell diseased crab in the Suez Canal region. www.braesd.com.
- FAO-UN (2014) Species fact sheets (*Portunus pelagicus*). Retrieved from <http://www.fao.org> on November 13, 2014.
- Hungria DB, Tavares CPDS, Pereira LÂ, Silva UDATD, Ostrensky A (2017) Global status of production and commercialization of soft-shell crabs. *Aquaculture International* 25: 2213–2226.
- Jay CV (1989) Prevalence, size and fecundity of the parasitic isopod *Argenia pugettensis* on its host shrimp *Crangon francisorum*. *American Midland Naturalist* 121: 68–77.
- Kensley B, Schotte M (1989) *Guides to the marine isopod crustaceans of the Carribean*. Smithsonian Press, Washington DC and London.
- Klompmaaker AA, Artal P, van Bakel BWM, Fraaije RHB, Jagt JWM (2014) Parasites in the fossil record: a cretaceous fauna with isopod-infested decapod crustaceans, infestation patterns through time, and a new Ichnotaxon. *Plos One* 9(3): 1–17.
- Markham JC (1998) Descriptions and revisions of some species of isopoda bopyridae of the Northwestern Atlantic Ocean. *Zoologische Verhandlungen* (246): 1–61.
- Messick GA, Sandermann GJ (1992) Synopsis of principal diseases of the blue crab, *Callinectes sapidus*. Woods Hole, Massachusetts.
- O'Brien J, Van Wyk PM (1985) Effects of crustacean parasitic castrators (epicaridean isopods and rizocephalan barnacles) on growth of crustacean hosts. In: Wenner AM (Ed) *Crustacean issues 3: factors in adult growth*. AA Balkema, Rotterdam, Netherland.
- Palisoc F (1987) Observations on the host-parasite relationship of *Epipenaeon ingens* Nobili (Epicaridea: Bopyridae) and *Penaeus semisulcatus* de Mann. *Philippine Journal of Science* 116: 282–293.
- Rahman MM, Haque SM, Galib SM, Islam MA, Parvez MT, Hoque MN, Wahab MA, Eгна H, Brown C (2020) Mud crab fishery in climate vulnerable coastal Bangladesh: an analysis towards sustainable development. *Aquaculture International*. DOI: 10.1007/s10499-020-00523-2
- Rowley AF, Cross ME, Culloty SC, Lynch SA, Mackenzie CL, Morgan E, O'Riordan R, Robins PE, Smith AL, Thrupp TJ, Vogan CJ, Wootton EC, Malham SK (2014) The potential impact of climate change on the infectious diseases of commercially important shellfish populations in the Irish Sea—a review. *ICES Journal of Marine Science* 71(4): 741–759.
- Sindermann CJ (1990) *Principal diseases of marine fish and shellfish*, Vol. 2. Academic Press, San Diego, California, USA.
- Somers IF, Kirkwood GP (1991) Population ecology of the grooved tiger prawn, *Penaeus semisulcatus*, in north-western Gulf of Carpentaria, Australia: growth, movement, age structure and infestation by the bopyrid parasite *Epipenaeon ingens*. *Australian Journal of Marine and Freshwater Research* 42: 349–367.
- Van Wyk PM (1982) Inhibition of the growth and reproduction of the porcellanid crab *Pachycheles rudis* by the bopyrid isopod, *Aporobopyrus muguensis*. *Parasitology* 85: 459–473.
- Williams JD, CB Boyko (2012) The global diversity of parasitic isopods associated with crustacean hosts (Isopoda: Bopyroidea and Cryptoniscoidea). *Plos One* 7(4): 1–9.

CONTRIBUTION OF THE AUTHORS

MBDC research design; MBDC & KMAQ sampling and morphological study; KMAQ & EMVC manuscript preparation



MB Dela Cruz  <https://orcid.org/0000-0001-5867-8285>

KMA Quiazon  <https://orcid.org/0000-0002-7902-0885>

EM Vera Cruz  <https://orcid.org/0000-0002-3704-8601>