



# Oculocardiac Reflex During Intravitreal Injection

Miguel Paciuc-Beja <sup>1</sup>, Daniela Meizner-Grezemkovsky <sup>2</sup>, Mario Paciuc <sup>3</sup>, Idaira Sanchez-Santos <sup>2</sup>, Anabeli Ruiz-Roman <sup>2</sup>, Ashlee Fack <sup>2</sup>, Andres Lisker-Cervantes <sup>2</sup>, Gerardo Mendieta <sup>1</sup>, Virgilio Morales-Canton <sup>2</sup>, Hugo Quiroz-Mercado <sup>2</sup>

<sup>1</sup> Ophthalmology Department, Centro Medico ABC, Av Carlos Fernandez Graef, Mexico City, Mexico.

<sup>2</sup> Retina Department. Asociacion para Evitar la Ceguera en Mexico, Vicente Garcia Torres, Mexico City, Mexico.

<sup>3</sup> Department of Statistics, Rice University, Houston TX, USA.

Epub: March 22, 2020

## ABSTRACT

Oculocardiac reflex (OCR) has been described to occur with mechanical manipulation of the eye, eyelids or orbit. There are no reports in the literature of OCR during intravitreal injection (IVI). This may be due to the fact that heart rate is not monitored during the procedure. We aimed to evaluate OCR during IVI. A total of 532 patients were enrolled in the study at Asociacion para Evitar la Ceguera en Mexico, Mexico City, Mexico. IVI was performed on one eye in every patient with diabetic retinopathy (DR), age related macular degeneration (AMD) or choroidal neovascularization (CNV) secondary to pathological myopia. Heart rate was monitored with a pulse oximeter before, during and after injection. OCR was defined as a 20% decrease or more of basal heart rate. The population enrolled included 270 females and 262 males with mean age of 63.8 years. A decrease in heart rate of 20% or more occurred in 18 patients during IVI (3.3%; 95% confidence interval 1.85% and 4.92%). OCR was asymptomatic in these patients. OCR occurred in 3.3% of our patients during IVI. Hence, OCR must be considered when performing IVI.

## KEY WORDS

Oculocardiac Reflex; Intravitreal Injection; Basal Heart Rate.

Copyright © 2020, Author(s). This is an open-access article distributed under the terms of the Creative Commons Attribution-Non Commercial 4.0 International License (<http://creativecommons.org/licenses/by-nc/4.0/>) which permits copy and redistribute the material just in noncommercial usages, provided the original work is properly cited.

**Correspondence to:** Dr Miguel Paciuc-Beja MD; Paseo de las Palmas 735-1102 Mexico City, Mexico 11000 Tel: 5255-5202-8804. E-mail: [visualkids@aol.com](mailto:visualkids@aol.com)

**How to cite this article:** Paciuc-Beja M, Meizner-Grezemkovsky D, Paciuc M, Sanchez-Santos I, Ruiz-Roman A, Fack A, Lisker-Cervantes A, Mendieta G, Morales-Canton V, Quiroz-Mercado H, Oculocardiac Reflex During Intravitreal Injection. Med Hypothesis Discov Innov Ophthalmol. 2020 Summer; 9(2): 111-117.

## INTRODUCTION

The oculocardiac reflex (OCR) is a sudden onset bradycardia that occurs sometimes during mechanical manipulation of the eye, eyelids or orbit. The afferent pathway comes from the ophthalmic branch of the trigeminal nerve. The efferent pathway is carried by the vagus nerve, which is accountable for the vagally mediated response of bradycardia [1-3]. Although sinus bradycardia is the most frequent effect of OCR, arrhythmia and asystole have been reported as well [4-7]. OCR occurs more frequently in children, especially during strabismus surgery [8-11], it can also occur in

adults [12, 13] and it has been described in a large variety of ophthalmic procedures [14-24].

The intensity of OCR decreases after repeated stimuli [25]. It is a fatigable reflex. Retrobulbar block [26], the use of anticholinergics [27-29] and deeper general anesthesia [10, 30, 31] can help reduce the occurrence of OCR. On the other hand, when fast-acting opioids [32, 33] or dexmedetomidine [34, 35] are used, they can increase OCR.

Intravitreal injection (IVI) of anti-vascular endothelial growth factor (VEGF) [36-40] and other drugs [41-44] is



now the most frequent procedure performed in ophthalmology [45]. IVI of anti-VEGF is commonly used to treat a variety of retinal conditions, such as age related macular degeneration and diabetic retinopathy [39, 46-51]. It is estimated that 5.9 million IVI were performed in the United States in 2016 [45].

The purpose of this study was to evaluate OCR during IVI.

#### MATERIALS and METHODS

During a 30-day period (June 2019), 532 patients scheduled for IVI were included for this study at the Asociacion para Evitar la Ceguera en Mexico (APEC) in Mexico City. The study complied with the Declaration of Helsinki. A written informed consent was obtained from all patients. This study received an ethical approval from our academic center. Only one eye of each patient was considered for the study. Patients taking medication for arrhythmia or having a pacemaker were excluded, all other patients were included. All injections were performed in the supero-temporal quadrant location. Injections were done following the 2018 consensus protocol recommendations [43]. The IVI was achieved in a sterile fashion (Figure 1). Heart rate was measured with a pulse oximeter (Zacurate, The USA) before and after placing the eyelid speculum, during the injection and after removing the speculum.

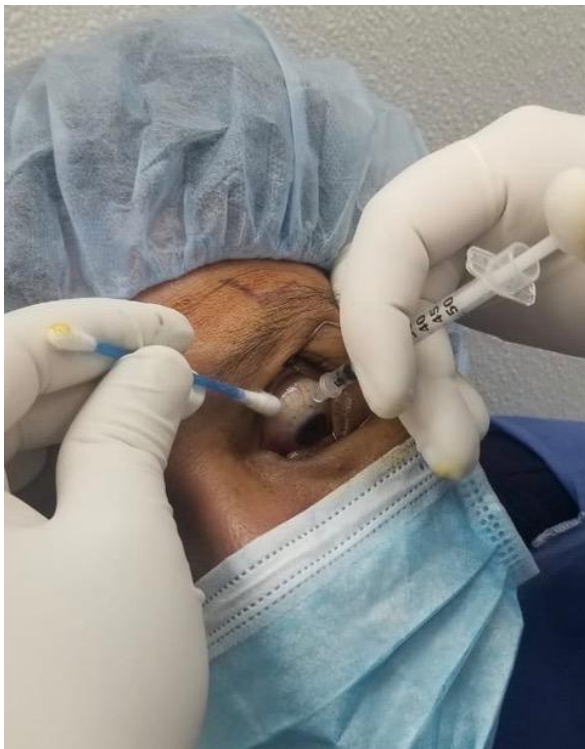

Figure 1. Superotemporal Intravitreal Injection in a Sterile Fashion in the Left Eye.

#### Statistical analysis

The percentage of patients with a decrease of 20% or more in basal heart rate was calculated using programming language R [52-54].

#### RESULTS

As shown in Table 1, of 532 eyes studied, 262 were males and 270 females, with a mean (range) age of 63.8 (29 – 89) years and 247 IVI in the right eye (OD) and 285 in the left eye (OS). Indications for IVI were respectively diabetic retinopathy (DR) in 352 eyes, age related macular degeneration (AMD) in 177 and choroidal neovascularization (CNV) secondary to pathological myopia in 3. In terms of the type of drug injected, 340 eyes received Ranibizumab (Lucentis; Genentech, The USA), 186 eyes Aflibercept (Wetlia; Bayer, Germany) and 3 eyes Ozurdex implant by IVI (Allergan, The USA; Dexamethasone intravitreal implant), respectively. Regarding OCR, of 532 patients enrolled, 18 presented a decrease in basal heart rate of 20% or more (Table 2 and Figure 2). As shown in Table 2, of 18 eyes, 12 were males and 6 females with a mean (range) age of 63.2 (41-84) years and 8 IVI in the OD and 10 IVI in the OS. Indications for IVI in these 18 patients were DR in 10 eyes, AMD in 6 eyes and CNV secondary to pathological myopia in 2 eyes. Ranibizumab was injected in 10 eyes and Aflibercept in 8 eyes. Statistical analysis showed a 3.3% incidence for OCR during IVI. A 95% confidence interval (CI) was found to be (1.85% and 4.92%). However, all patients with OCR were asymptomatic.



**Table 1. Demographic Characteristics of the Study Subjects**

Age; range (years)	29 – 89 (mean 63.8)	
Gender; n	Male	262
	Female	270
Laterality; n	OD	247
	OS	285
Indication for IVI; n	DR	352
	AMD	177
	CNV	3
Injected Medication; n	Ranibizumab	340
	Aflibercept	186
	Ozurdex	3

Abbreviations: n: number of eyes; OD: right eye; OS: left eye; IVI: intravitreal injection; DR: Diabetic Retinopathy; AMD: age related macular degeneration; CNV: choroidal neovascularization secondary to secondary to pathological myopia; Ranibizumab: Lucentis (Genentech, The USA); Aflibercept: Wetlia (Bayer, Germany); Ozurdex: (Allergan, The USA) Dexamethasone intravitreal implant.

**Table 2. A Summary of Characteristics of Patients With OCR During IVI**

No.	Sex; F/M	Age; Y	Basal HR	IVI HR	Name of Medication	Side	Diagnosis
1	F	55	86	63	Aflibercept	OD	DR
2	F	84	91	69	Ranibizumab	OS	DR
3	F	63	89	65	Aflibercept	OD	DR
4	F	60	75	57	Aflibercept	OD	AMD
5	F	50	92	73	Aflibercept	OS	DR
6	F	59	85	65	Ranibizumab	OS	DR
7	M	76	92	64	Aflibercept	OS	AMD
8	M	41	95	75	Ranibizumab	OD	CNV
9	M	56	105	82	Ranibizumab	OD	DR
10	M	62	89	69	Ranibizumab	OD	DR
11	M	64	86	66	Aflibercept	OS	DR
12	M	54	89	68	Ranibizumab	OS	DR
13	M	60	99	66	Ranibizumab	OS	CNV
14	M	77	81	62	Aflibercept	OD	AMD
15	M	74	63	49	Ranibizumab	OS	AMD
16	M	65	84	58	Aflibercept	OS	DR
17	M	71	73	57	Ranibizumab	OD	AMD
18	M	67	82	61	Ranibizumab	OS	AMD

Abbreviations: F: female; M: male; Y: years; HR: heart rate; IVI: intravitreal injection; OD: right eye; OS: left eye; DR: Diabetic Retinopathy; AMD: age related macular degeneration; CNV: choroidal neovascularization secondary to pathological myopia; Ranibizumab: Lucentis (Genentech, USA); Aflibercept: Wetlia (Bayer, Germany).

**DISCUSSION**

In this study, OCR occurred in 3.3% of patients during IVI. All patients who had OCR were asymptomatic. OCR occurred in patients of both genders and all were over 40 years. OCR occurred with both Aflibercept and Ranibizumab, both were the most frequent medications used in this study.

OCR is more common in children, particularly during strabismus surgery, although other studies have shown that OCR can occur in adults [13]. Using electrocardiogram, in 1998 we published a series of adult patients with OCR during Laser-Assisted In Situ Keratomileusis (LASIK) [13]. In patients with OCR,

decrease in heart rate appeared when the suction ring (pressure) was applied; all patients who underwent LASIK and presented a decrease in heart rate during the procedure were asymptomatic.

For the purpose of this study, we measured how many seconds it took to perform the IVI. For the experienced ophthalmologist, IVI took 10 seconds or less, in contrast with rectus muscle traction during strabismus surgery (minutes) [55, 56].

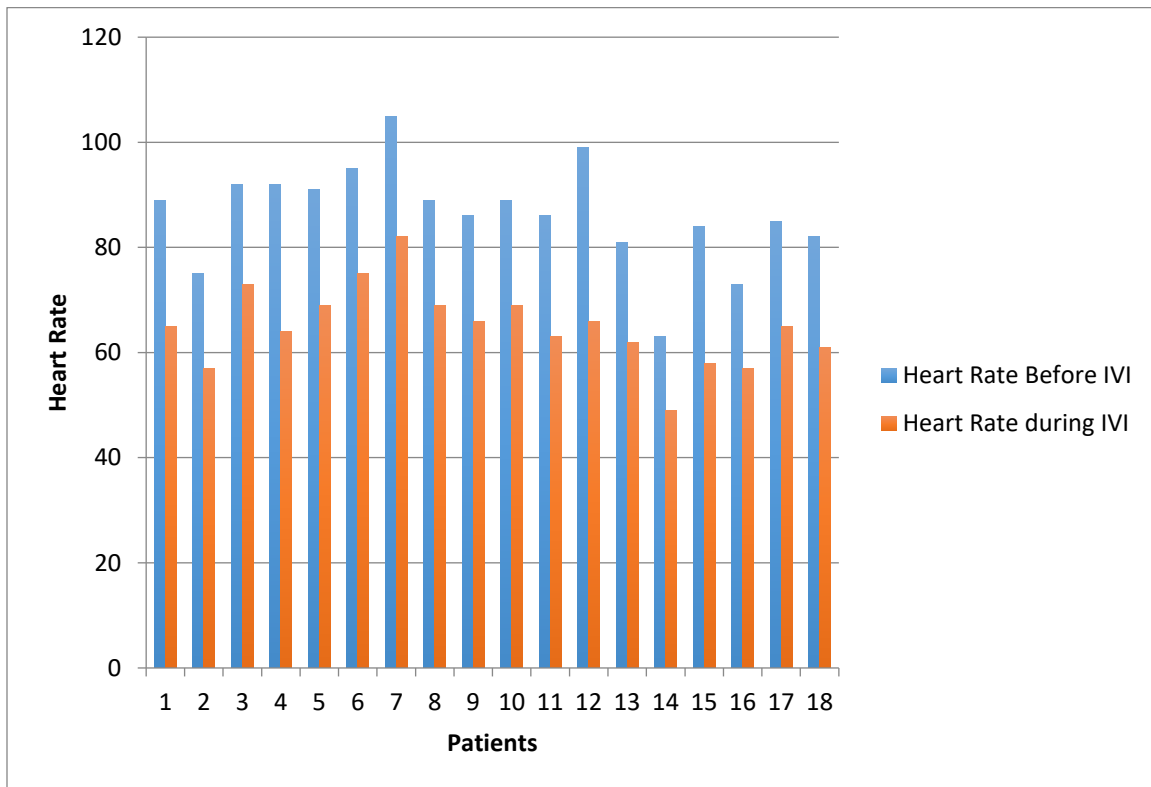


Figure 2. Basal Heart Rate (Heart Rate Before) and Heart Rate of Patients With Oculocardiac Reflex During Intravitreal Injection (IVI)

OCR has been reported in 14% to 90% of patients during strabismus surgery [57]. Although OCR has been described in adult patients during different ophthalmological procedures [13, 20, 58], it is more common in children. Muscle traction during strabismus surgery and muscle entrapment in blowout fractures [59-62] of the orbit are the two most common circumstances associated with OCR. Individual cases of OCR during different procedures in adults under local anesthesia could be seen as anecdotal, but the ophthalmologist must be aware of its possible occurrence.

We assume that in this study OCR was asymptomatic because of the short duration of the procedure [63-65]. The “2018 Update on Intravitreal Injections: Euretina Consensus Recommendations” addresses important issues related to pre-injection, peri-injection and post-injection management [45]. The authors stated that “the ophthalmologist should be aware of the potential cardiovascular and cerebrovascular risks of these agents”. Unusual systemic events after anti-VEGF IVIs have been reported, such as visual hallucinations, erectile dysfunction and acute decrease in kidney function [45] The role of anti-VEGF in these instances remains to be established.

After a comprehensive PubMed search, we could not find any report in the literature concerning OCR and IVI. This is because heart rate is not monitored during IVI and therefore not detected. A similar situation occurred during LASIK, OCR was not considered until heart rate was monitored during the procedure [13, 31]. This is the first report of OCR during IVI. Although our study included over 500 patients, it was single center, and compromised three types IVI and three medications. Therefore, further multicentric studies with more sample size, and wide range of injected medications and indications, must be done to confirm our findings.

#### CONCLUSION

In conclusion, OCR occurred in 3.3% of patients during IVI. Hence, OCR must be considered when performing IVIs.

#### DISCLOSURE

Ethical issues have been completely observed by the authors. All named authors meet the International Committee of Medical Journal Editors (ICMJE) criteria for authorship of this manuscript, take responsibility for the integrity of the work as a whole, and have given final



approval for the version to be published. No conflict of interest has been presented. Funding/Support: None. The datasets analyzed during this study are available from the corresponding author on reasonable request.

#### ACKNOWLEDGMENT

This study has been presented in part as a poster at the Fifty-second Annual Scientific Meeting of the Retina Society, London, the UK, September 11-15, 2019

#### REFERENCES

1. Mirakhur RK, Jones CJ. Oculocardiac Reflex. *British Journal of Anaesthesia*. 1983;55(9). doi: [10.1093/bja/55.9.921](https://doi.org/10.1093/bja/55.9.921)
2. Bharati SJ, Chowdhury T. The Oculocardiac Reflex. *Trigemino-cardiac Reflex* 2015. p. 89-99.
3. Arnold RW. The human heart rate response profiles to five vagal maneuvers. *Yale J Biol Med*. 1999;72(4):237-44. pmid: [10907774](https://pubmed.ncbi.nlm.nih.gov/10907774/)
4. Cheung MY, Viney M. A unique case of recurrent asystole secondary to paroxysmal pain of acute herpetic ophthalmicus. *Anesth Analg*. 2007;105(4):1127-9, table of contents. doi: [10.1213/01.ane.0000280536.96489.95](https://doi.org/10.1213/01.ane.0000280536.96489.95) pmid: [17898398](https://pubmed.ncbi.nlm.nih.gov/17898398/)
5. Gold RS, Pollard Z, Buchwald IP. Asystole due to the oculocardiac reflex during strabismus surgery: a report of two cases. *Ann Ophthalmol*. 1988;20(12):473-5, 7. pmid: [3064667](https://pubmed.ncbi.nlm.nih.gov/3064667/)
6. Osborn TM, Ueek BA, Ham LB, Assael LA. A case of asystole from periorbital laceration manipulation and oculocardiac reflex in an acute trauma setting. *J Trauma*. 2008;65(1):228-30. doi: [10.1097/01.ta.0000195450.92536.7f](https://doi.org/10.1097/01.ta.0000195450.92536.7f) pmid: [17429330](https://pubmed.ncbi.nlm.nih.gov/17429330/)
7. A Van Noord B. Asystole during Vitrectomy Secondary to Increasing Intraocular Infusion Pressure Transmitted via Sclerotomy Infusion Cannula. *Journal of Anesthesia & Clinical Research*. 2012;03(03). doi: [10.4172/2155-6148.1000198](https://doi.org/10.4172/2155-6148.1000198)
8. Min SW, Hwang JM. Adjustment in patients with asystole during strabismus surgery. *Graefes Arch Clin Exp Ophthalmol*. 2011;249(12):1889-92. doi: [10.1007/s00417-011-1628-6](https://doi.org/10.1007/s00417-011-1628-6) pmid: [21301860](https://pubmed.ncbi.nlm.nih.gov/21301860/)
9. Milot JA, Jacob JL, Blanc VF, Hardy JF. The oculocardiac reflex in strabismus surgery. *Can J Ophthalmol*. 1983. doi:[10.1201/b16817-84](https://doi.org/10.1201/b16817-84).
10. Karaman T, Demir S, Dogru S, Sahin A, Tapar H, Karaman S, et al. The effect of anesthesia depth on the oculocardiac reflex in strabismus surgery. *J Clin Monit Comput*. 2016;30(6):889-93. doi: [10.1007/s10877-015-9789-1](https://doi.org/10.1007/s10877-015-9789-1) pmid: [26438656](https://pubmed.ncbi.nlm.nih.gov/26438656/)
11. Tuzcu K, Coskun M, Tuzcu EA, Karcioğlu M, Davarci I, Hakimoglu S, et al. Effectiveness of sub-Tenon's block in pediatric strabismus surgery. *Braz J Anesthesiol*. 2015;65(5):349-52. doi: [10.1016/j.bjane.2014.02.003](https://doi.org/10.1016/j.bjane.2014.02.003) pmid: [26323732](https://pubmed.ncbi.nlm.nih.gov/26323732/)
12. Baykara M, Dogru M, Ozmen AT, Ozcetin H. Oculocardiac reflex in a nonsedated laser in situ keratomileusis patient. *J Cataract Refract Surg*. 2002;28(9):1698-9. doi: [10.1016/s0886-3350\(01\)01113-0](https://doi.org/10.1016/s0886-3350(01)01113-0) pmid: [12231334](https://pubmed.ncbi.nlm.nih.gov/12231334/)
13. Paciuć M, Mendieta G, Naranjo R. Oculocardiac reflex during laser in situ keratomileusis. *J Cataract Refract Surg*. 1998;24(10):1317-9. doi: [10.1016/s0886-3350\(98\)80221-6](https://doi.org/10.1016/s0886-3350(98)80221-6) pmid: [9795844](https://pubmed.ncbi.nlm.nih.gov/9795844/)
14. Cui W. [Blepharoplasty and oculocardiac reflex]. *Zhonghua Zheng Xing Shao Shang Wai Ke Za Zhi*. 1993;9(5):355-6, 97. pmid: [8143207](https://pubmed.ncbi.nlm.nih.gov/8143207/)
15. Matarasso A. The oculocardiac reflex in blepharoplasty surgery. *Plast Reconstr Surg*. 1989;83(2):243-50. doi: [10.1097/00006534-198902000-00006](https://doi.org/10.1097/00006534-198902000-00006) pmid: [2911623](https://pubmed.ncbi.nlm.nih.gov/2911623/)
16. Katowitz WR, O'Brien M, Kiskis E, Elliott EM. An asystolic event after eyelid skin bupivacaine injection during chalazion surgery. *J AAPOS*. 2016;20(1):75-7. doi: [10.1016/j.jaapos.2015.09.010](https://doi.org/10.1016/j.jaapos.2015.09.010) pmid: [26917079](https://pubmed.ncbi.nlm.nih.gov/26917079/)
17. Hampl KF, Marsch SC, Schneider M, Flammer J. Vasovagal heart block following cataract surgery under local anesthesia. *Ophthalmic Surg*. 1993;24(6):422-4. pmid: [8336897](https://pubmed.ncbi.nlm.nih.gov/8336897/)
18. Gao L, Tao Z, Wang Q. [Oculocardiac reflex in senile cataract operation]. *Zhonghua Yan Ke Za Zhi*. 1997;33(5):334-6. pmid: [10451974](https://pubmed.ncbi.nlm.nih.gov/10451974/)
19. Gao L, Wang Q, Xu H, Tao Z, Wu F. The oculocardiac reflex in cataract surgery in the elderly. *Br J Ophthalmol*. 1997;81(7):614. doi: [10.1136/bjo.81.7.614](https://doi.org/10.1136/bjo.81.7.614) pmid: [9290386](https://pubmed.ncbi.nlm.nih.gov/9290386/)
20. Kosaka M, Asamura S, Kamiishi H. Oculocardiac reflex induced by zygomatic fracture; a case report. *J Craniomaxillofac Surg*. 2000;28(2):106-9. doi: [10.1054/jcms.2000.0107](https://doi.org/10.1054/jcms.2000.0107) pmid: [10958423](https://pubmed.ncbi.nlm.nih.gov/10958423/)
21. Woernley TC, Wright TL, Lam DN, Jundt JS. Oculocardiac Reflex in an Orbital Fracture Without Entrapment. *J Oral Maxillofac Surg*. 2017;75(8):1716-21. doi: [10.1016/j.joms.2017.03.014](https://doi.org/10.1016/j.joms.2017.03.014) pmid: [28412263](https://pubmed.ncbi.nlm.nih.gov/28412263/)
22. Joseph JM, Rosenberg C, Zoumalan CI, Zoumalan RA, White WM, Lisman RD. Oculocardiac reflex associated with a large orbital floor fracture. *Ophthalmic Plast Reconstr Surg*. 2009;25(6):496-8. doi: [10.1097/IOP.0b013e3181b80ea7](https://doi.org/10.1097/IOP.0b013e3181b80ea7) pmid: [19935262](https://pubmed.ncbi.nlm.nih.gov/19935262/)
23. Young TE. Pharmacology Review: Topical Mydriatics: The Adverse Effects of Screening Examinations for Retinopathy of Prematurity. *NeoReviews*. 2003;4(6):163e-6. doi: [10.1542/neo.4-6-e163](https://doi.org/10.1542/neo.4-6-e163)
24. Mimura T, Amano S, Funatsu H, Araie M, Kagaya F, Kaji Y, et al. Oculocardiac reflex caused by contact lenses. *Ophthalmic Physiol Opt*. 2003;23(3):263-4. doi: [10.1046/j.1475-1313.2003.00114.x](https://doi.org/10.1046/j.1475-1313.2003.00114.x) pmid: [12753482](https://pubmed.ncbi.nlm.nih.gov/12753482/)
25. Ha SG, Huh J, Lee BR, Kim SH. Surgical factors affecting oculocardiac reflex during strabismus surgery. *BMC Ophthalmol*. 2018;18(1):103. doi: [10.1186/s12886-018-0771-9](https://doi.org/10.1186/s12886-018-0771-9) pmid: [29673326](https://pubmed.ncbi.nlm.nih.gov/29673326/)
26. Defalque RJ. Retrobulbar block for oculocardiac reflex: duration of protection by common local anesthetics. *Acta Ophthalmol (Copenh)*. 1969;47(4):998-1003. doi: [10.1111/j.1755-3768.1969.tb03723.x](https://doi.org/10.1111/j.1755-3768.1969.tb03723.x) pmid: [5394852](https://pubmed.ncbi.nlm.nih.gov/5394852/)
27. Gilani SM, Jamil M, Akbar F, Jehangir R. Anticholinergic premedication for prevention of oculocardiac reflex during





- squint surgery. *J Ayub Med Coll Abbottabad*. 2005;17(4):57-9. [pmid: 16599038](#)
28. Meyers EF, Tomeldan SA. Glycopyrrolate compared with atropine in prevention of the oculocardiac reflex during eye-muscle surgery. *Anesthesiology*. 1979;51(4):350-2. [doi: 10.1097/00000542-197910000-00017](#) [pmid: 484900](#)
29. Hunsley JE, Bush GH, Jones CJ. A study of glycopyrrolate and atropine in the suppression of the oculocardiac reflex during strabismus surgery in children. *Br J Anaesth*. 1982;54(4):459-64. [doi: 10.1093/bja/54.4.459](#) [pmid: 7066144](#)
30. Safavi M, Honarmand A. Comparison of effects of thiopental, propofol or ketamine on the cardiovascular responses of the oculocardiac reflex during strabismus surgery. *J Res Med Sci*. 2007.
31. Arnold RW, Bond AN, McCall M, Lunoe L. The oculocardiac reflex and depth of anesthesia measured by brain wave. *BMC Anesthesiol*. 2019;19(1):36. [doi: 10.1186/s12871-019-0712-z](#) [pmid: 30871507](#)
32. Paciuc M, Mendieta G, Naranjo R, Angel E, Reyes E. Oculocardiac reflex in sedated patients having laser in situ keratomileusis. *Journal of Cataract & Refractive Surgery*. 1999;25(10):1341-3. [doi: 10.1016/s0886-3350\(99\)00209-6](#)
33. Arnold RW, Jensen PA, Kovtoun TA, Maurer SA, Schultz JA. The profound augmentation of the oculocardiac reflex by fast acting opioids. *Binocul Vis Strabismus Q*. 2004;19(4):215-22. [pmid: 15530138](#)
34. Arnold RW, Biggs R, Beerle B. Dexmedetomidine (Precedex) increases oculocardiac reflex. *Journal of American Association for Pediatric Ophthalmology and Strabismus*. 2017;21(4). [doi: 10.1016/j.jaapos.2017.07.133](#)
35. Arnold RW, Biggs RE, Beerle BJ. Intravenous dexmedetomidine augments the oculocardiac reflex. *J AAPOS*. 2018;22(3):211-3 e1. [doi: 10.1016/j.jaapos.2018.01.016](#) [pmid: 29733898](#)
36. Tah V, Orlans HO, Hyer J, Casswell E, Din N, Sri Shanmuganathan V, et al. Anti-VEGF Therapy and the Retina: An Update. *J Ophthalmol*. 2015;2015:627674. [doi: 10.1155/2015/627674](#) [pmid: 26417453](#)
37. Ferrara N, Damico L, Shams N, Lowman H, Kim R. Development of ranibizumab, an anti-vascular endothelial growth factor antigen binding fragment, as therapy for neovascular age-related macular degeneration. *Retina*. 2006;26(8):859-70. [doi: 10.1097/01.iae.0000242842.14624.e7](#) [pmid: 17031284](#)
38. Amadio M, Govoni S, Pascale A. Targeting VEGF in eye neovascularization: What's new?: A comprehensive review on current therapies and oligonucleotide-based interventions under development. *Pharmacol Res*. 2016;103:253-69. [doi: 10.1016/j.phrs.2015.11.027](#) [pmid: 26678602](#)
39. Osaadon P, Fagan XJ, Lifshitz T, Levy J. A review of anti-VEGF agents for proliferative diabetic retinopathy. *Eye (Lond)*. 2014;28(5):510-20. [doi: 10.1038/eye.2014.13](#) [pmid: 24525867](#)
40. Das A, McGuire PG, Rangesamy S. Diabetic Macular Edema: Pathophysiology and Novel Therapeutic Targets. *Ophthalmology*. 2015;122(7):1375-94. [doi: 10.1016/j.ophtha.2015.03.024](#) [pmid: 25935789](#)
41. Scaramuzzi M, Querques G, Spina CL, Lattanzio R, Bandello F. Repeated intravitreal dexamethasone implant (Ozurdex) for diabetic macular edema. *Retina*. 2015;35(6):1216-22. [doi: 10.1097/IAE.0000000000000443](#) [pmid: 25574787](#)
42. Khan Z, Kuriakose RK, Khan M, Chin EK, Almeida DR. Efficacy of the Intravitreal Sustained-Release Dexamethasone Implant for Diabetic Macular Edema Refractory to Anti-Vascular Endothelial Growth Factor Therapy: Meta-Analysis and Clinical Implications. *Ophthalmic Surg Lasers Imaging Retina*. 2017;48(2):160-6. [doi: 10.3928/23258160-20170130-10](#) [pmid: 28195619](#)
43. Matonti F, Pommier S, Meyer F, Hajjar C, Merite PY, Parrat E, et al. Long-term efficacy and safety of intravitreal dexamethasone implant for the treatment of diabetic macular edema. *Eur J Ophthalmol*. 2016;26(5):454-9. [doi: 10.5301/ejo.5000787](#) [pmid: 27079207](#)
44. Gonzalez-Salinas R, Hernandez-Zimbron LF, Gullias-Canizo R, Sanchez-Vela MA, Ochoa-De La Paz L, Zamora R, et al. Current Anti-Integrin Therapy for Ocular Disease. *Semin Ophthalmol*. 2018;33(5):634-42. [doi: 10.1080/08820538.2017.1388411](#) [pmid: 29087767](#)
45. Grzybowski A, Told R, Sacu S, Bandello F, Moisseiev E, Loewenstein A, et al. 2018 Update on Intravitreal Injections: Euretina Expert Consensus Recommendations. *Ophthalmologica*. 2018;239(4):181-93. [doi: 10.1159/000486145](#) [pmid: 29393226](#)
46. Cheung CMG, Arnold JJ, Holz FG, Park KH, Lai TYY, Larsen M, et al. Myopic Choroidal Neovascularization: Review, Guidance, and Consensus Statement on Management. *Ophthalmology*. 2017;124(11):1690-711. [doi: 10.1016/j.ophtha.2017.04.028](#) [pmid: 28655539](#)
47. Gupta N, Mansoor S, Sharma A, Sapkal A, Sheth J, Falatoonzadeh P, et al. Diabetic retinopathy and VEGF. *Open Ophthalmol J*. 2013;7:4-10. [doi: 10.2174/1874364101307010004](#) [pmid: 23459241](#)
48. Das A, Stroud S, Mehta A, Rangesamy S. New treatments for diabetic retinopathy. *Diabetes Obes Metab*. 2015;17(3):219-30. [doi: 10.1111/dom.12384](#) [pmid: 25160598](#)
49. Solomon SD, Lindsley K, Vedula SS, Krzystolik MG, Hawkins BS. Anti-vascular endothelial growth factor for neovascular age-related macular degeneration. *Cochrane Database Syst Rev*. 2014(8):CD005139. [doi: 10.1002/14651858.CD005139.pub3](#) [pmid: 25170575](#)
50. Kovach JL, Schwartz SG, Flynn HW, Jr., Scott IU. Anti-VEGF Treatment Strategies for Wet AMD. *J Ophthalmol*. 2012;2012:786870. [doi: 10.1155/2012/786870](#) [pmid: 22523653](#)
51. Browning DJ, Kaiser PK, Rosenfeld PJ, Stewart MW. Aflibercept for age-related macular degeneration: a game-changer or quiet addition? *Am J Ophthalmol*. 2012;154(2):222-6. [doi: 10.1016/j.ajo.2012.04.020](#) [pmid: 22813448](#)
52. Dessau R, Pipper C. ["R"--project for statistical computing]. *Ugeskr Laeger*. 2008.



53. Eloyan A, Li S, Muschelli J, Pekar JJ, Mostofsky SH, Caffo BS. Analytic programming with fMRI data: a quick-start guide for statisticians using R. *PLoS One*. 2014;9(2):e89470. doi: [10.1371/journal.pone.0089470](https://doi.org/10.1371/journal.pone.0089470) pmid: 24586801
54. Jalal H, Pechlivanoglou P, Krijkamp E, Alarid-Escudero F, Enns E, Hunink MGM. An Overview of R in Health Decision Sciences. *Med Decis Making*. 2017;37(7):735-46. doi: [10.1177/0272989X16686559](https://doi.org/10.1177/0272989X16686559) pmid: 28061043
55. Machida CJ, Arnold RW. The effect of induced muscle tension and fatigue on the oculocardiac reflex. *Binocul Vis Strabismus Q*. 2003;18(2):81-6. pmid: 12785319
56. Arnold RW, Ellis FD, Wolfe TM. Prolonged oculocardiac reflex during strabismus surgery under topical anesthesia. *J Pediatr Ophthalmol Strabismus*. 1997;34(4):252-4. pmid: 9253742
57. Chung CJ, Lee JM, Choi SR, Lee SC, Lee JH. Effect of remifentanyl on oculocardiac reflex in paediatric strabismus surgery. *Acta Anaesthesiol Scand*. 2008;52(9):1273-7. doi: [10.1111/j.1399-6576.2008.01745.x](https://doi.org/10.1111/j.1399-6576.2008.01745.x) pmid: 18823468
58. Ghali AM, El Btarny AM. The effect on outcome of peribulbar anaesthesia in conjunction with general anaesthesia for vitreoretinal surgery. *Anaesthesia*. 2010;65(3):249-53. doi: [10.1111/j.1365-2044.2009.06191.x](https://doi.org/10.1111/j.1365-2044.2009.06191.x) pmid: 20039868
59. Jackson BF. Orbital trauma, bradycardia, and vomiting: trapdoor fracture and the oculocardiac reflex: a case report. *Pediatr Emerg Care*. 2010;26(2):143-5. doi: [10.1097/PEC.0b013e3181ce30d8](https://doi.org/10.1097/PEC.0b013e3181ce30d8) pmid: 20145507
60. Chung SY, Langer PD. Pediatric orbital blowout fractures. *Curr Opin Ophthalmol*. 2017;28(5):470-6. doi: [10.1097/ICU.0000000000000407](https://doi.org/10.1097/ICU.0000000000000407) pmid: 28797015
61. Jurdy L, Malhotra R. White-eyed medial wall blowout fracture mimicking head injury due to persistent oculocardiac reflex. *J Craniofac Surg*. 2011;22(5):1977-9. doi: [10.1097/SCS.0b013e31822eaa25](https://doi.org/10.1097/SCS.0b013e31822eaa25) pmid: 21959489
62. Basagaoglu B, Steinberg A, Tung IT, Olorunnipa S, Maricevich RS. Oculocardiac Reflex as a Late Presentation of Orbital Floor Fracture. *J Craniofac Surg*. 2018;29(7):e720-e2. doi: [10.1097/SCS.0000000000004966](https://doi.org/10.1097/SCS.0000000000004966) pmid: 30192295
63. Fauser S, Schwabecker V, Muether PS. Suppression of intraocular vascular endothelial growth factor during aflibercept treatment of age-related macular degeneration. *Am J Ophthalmol*. 2014;158(3):532-6. doi: [10.1016/j.ajo.2014.05.025](https://doi.org/10.1016/j.ajo.2014.05.025) pmid: 24879948
64. Chhablani J, Bansal P, Veritti D, Sambhana S, Sarao V, Pichi F, et al. Dexamethasone implant in diabetic macular edema in real-life situations. *Eye (Lond)*. 2016;30(3):426-30. doi: [10.1038/eye.2015.246](https://doi.org/10.1038/eye.2015.246) pmid: 26611849
65. Green-Simms AE, Ekdawi NS, Bakri SJ. Survey of intravitreal injection techniques among retinal specialists in the United States. *Am J Ophthalmol*. 2011;151(2):329-32. doi: [10.1016/j.ajo.2010.08.039](https://doi.org/10.1016/j.ajo.2010.08.039) pmid: 21168821