

Diagnosis of major heart defects by routine first-trimester ultrasound examination: association with high nuchal translucency, tricuspid regurgitation and abnormal flow in the ductus venosus

Gian Piero MINNELLA,¹ Francesco CRUPANO,¹ Argyro SYNGELAKI,¹ Vita ZIDERE,¹
Ranjit AKOLEKAR,^{2,3} Kypros H. NICOLAIDES¹

1. Fetal Medicine Research Institute, King's College Hospital, London, UK
2. Fetal Medicine Unit, Medway Maritime Hospital, Gillingham, UK
3. Institute of Medical Sciences, Canterbury Christ Church University, Chatham, UK

Correspondence:

Professor KH Nicolaides,
Harris Birthright Research Centre for Fetal Medicine,
Fetal Medicine Research Institute,
King's College Hospital,
16-20 Windsor Walk, Denmark Hill, London SE5 8BB
email: kypros@fetalmedicine.com

Keywords: Congenital heart defects, First trimester screening, Nuchal translucency, Tricuspid regurgitation, Ductus venosus Doppler, Fetal abnormalities, Prenatal diagnosis, Ultrasound examination.

Short title: First-trimester detection of heart defects

This article has been accepted for publication and undergone full peer review but has not been through the copyediting, typesetting, pagination and proofreading process which may lead to differences between this version and the Version of Record. Please cite this article as doi: 10.1002/uog.21956

CONTRIBUTION

What are the novel findings of this work?

The study demonstrates that more than half of major heart defects can be detected by routine ultrasound examination at 11-13 weeks' gestation and confirms that high nuchal translucency, tricuspid regurgitation and abnormal flow in the ductus venosus are useful markers for such defects.

What are the clinical implications of this work?

At 11-13 weeks' gestation measurement of nuchal translucency and assessment of flow across the tricuspid valve and in the ductus venosus can lead to the early diagnosis of major heart defects.

ABSTRACT

Objective: To examine the association between fetal major heart defects and high nuchal translucency thickness (NT), tricuspid regurgitation and abnormal flow in the ductus venosus in a large population of singleton pregnancies undergoing a routine ultrasound examination at 11-13 weeks' gestation.

Methods: This was a retrospective study of prospectively collected data from singleton pregnancies attending for a routine ultrasound scan at 11-13 weeks' gestation which included examination of fetal anatomy, measurement of NT, and assessment of blood flow across the tricuspid valve and in the ductus venosus according to a standardized protocol. The incidence of fetal NT $\geq 95^{\text{th}}$ and NT $\geq 99^{\text{th}}$ percentile, tricuspid regurgitation and reversed a-wave in the ductus venosus in fetuses with and without major heart defects was determined and the performance of each marker and their combination in the detection of major heart defects was calculated.

Results: The study population of 93,209 pregnancies with no apparent chromosomal abnormality included 211 (0.23%) with major heart defects and 92,998 morphologically normal neonates. In 113 (53.6%) of the major heart defects the diagnosis was made at the 11-13 weeks scan, in 82 (38.9%) at the 18-24 weeks scan, in 10 (4.7%) at the third-trimester scan and in 6 (2.8%) postnatally. At the 11-13 weeks scan we diagnosed all cases of tricuspid or pulmonary atresia and polyvalvular dysplasia, >90% of cases of hypoplastic left heart syndrome or atrioventricular septal defect, about 60% of complex heart defects and left atrial isomerism (interrupted inferior vena cava with normal intracardiac anatomy), 30-40% of tetralogy of Fallot and arch abnormalities, 25% of tricuspid valve abnormalities, about 15% of transposition of great arteries, but none of aortic or pulmonary stenosis and common arterial trunk. Fetal NT $\geq 95^{\text{th}}$ percentile, NT $\geq 99^{\text{th}}$ percentile, tricuspid regurgitation, or abnormal ductus venosus flow was observed in 77 (36.5%), 45 (21.3%), 61 (28.9%), and 58 (27.5%) of the fetuses with major heart defects, respectively, and in 5,678 (6.1%), 857 (0.9%), 1,136 (1.2%), and 1,644 (1.8%) of those without heart defects. Any one of NT $\geq 95^{\text{th}}$, tricuspid regurgitation or abnormal flow in the ductus venosus was found in 117 (55.5%, 95% CI 48.5–62.3%) of the fetuses with heart defects and in

8,166 (8.8%, 95% CI 8.6-9.0%) of those without heart defects. Any one of NT $\geq 99^{\text{th}}$ percentile and the other two markers was found in 99 of the fetuses with heart defects (46.9%, 95% CI 40.0-53.9%) and in 3,517 of those without heart defects (3.8%, 95% CI 3.7-3.9%).

Conclusion: At 11-13 weeks' gestation measurement of fetal NT and assessment of flow across the tricuspid valve and in the ductus venosus can lead to the early diagnosis of major heart defects.

INTRODUCTION

Ultrasound examination at 11-13 weeks' gestation can lead to the diagnosis of a wide range of fetal non-chromosomal abnormalities.¹⁻³ In relation to the first trimester scan fetal non-chromosomal abnormalities can be subdivided into three groups:^{2,3} first, those that are easily detectable by direct visualization, such as acrania and exomphalos; second, those that are potentially detectable depending on the objectives set for such a scan based on a standardized protocol and the presence of easily detectable markers for an underlying abnormality, such as high nuchal translucency thickness (NT), tricuspid regurgitation and abnormal flow in the ductus venosus for heart defects,⁴⁻¹² and third, abnormalities that are undetectable in the first trimester because they develop later in pregnancy, such as ovarian cysts, their phenotypic expression becomes apparent in later pregnancy as a result of physiological changes in the fetus, such as increased fetal swallowing unmasking bowel obstruction, or the defects evolve with advancing gestational age, such as short limbs in achondroplasia.

In a previous study of first-trimester screening for aneuploidies in 40,990 singleton pregnancies, examined between 2006 and 2009, we reported that fetal NT >95th percentile, tricuspid regurgitation, or ductus venosus reversed a-wave was observed in (58%, 95% confidence interval 47–68%) of 85 fetuses with major heart defects, and in 8% of those without heart defects and suggested that these biomarkers are useful in the early diagnosis of heart defects.^{10,11}

The objectives of this study of 93,209 singleton pregnancies undergoing a routine examination of the fetal anatomy is to investigate further the association between fetal major heart defects and high NT, tricuspid regurgitation and abnormal flow in the ductus venosus at the 11-13 weeks scan.

METHODS

Study population

This was a retrospective study of prospectively collected data from women with singleton pregnancies attending for a routine hospital visit at 11⁺⁰ - 13⁺⁶ weeks' gestation at King's College Hospital, London or Medway Maritime Hospital, Gillingham, UK between October 2009 and July 2018. In this visit we recorded maternal characteristics and medical history, performed an ultrasound scan to first, measure fetal NT thickness;¹³⁻¹⁵ second, diagnose any fetal abnormalities;^{2,3} and third, assess blood flow across the tricuspid valve and in the ductus venosus.^{8,10,11} Assessment of risk for aneuploidies included measurement of maternal serum free β -human chorionic gonadotropin and pregnancy-associated plasma protein-A.^{16,17} Women were given their estimated individual risk for trisomies and those with a high risk were offered invasive testing for fetal karyotyping or cell free DNA testing for trisomies 21, 18 and 13.^{18,19}

In all cases with a continuing pregnancy a fetal anomaly scan was undertaken at 18-24 weeks' gestation and in many cases a scan was also carried out at 30-34 or 35-37 weeks' gestation. We excluded pregnancies with known aneuploidies. Data on pregnancy outcome were collected from computerized records of the delivery ward and neonatal unit or the patient general practitioners and all prenatal and postnatal findings were recorded in a Fetal Database. This study constitutes a retrospective analysis of data derived from a routine clinical examination and did not require ethics committee approval.

Ultrasound scans

All ultrasound examinations were carried out according to standardized protocols by sonographers that had obtained the Fetal Medicine Foundation Certificate of Competence in ultrasound examination for fetal abnormalities or by trainees under the supervision of certified sonographers. The ultrasound examinations were performed transabdominally, using 3-7.5 MHz curvilinear transducers, but in 2-3% of cases when there were technical difficulties to obtain

adequate views a transvaginal scan (3-9 MHz) was also carried out. The time allocated for the ultrasound examination of the fetus was 30 minutes. All cases of suspected fetal abnormalities in the first, second or third trimester scans were examined on the same day by a fetal medicine specialist. Likewise, all cases of suspected fetal heart defects were examined by a fetal cardiologist.

At the 11-13 weeks scan the protocol included transverse section of the thorax and use of color Doppler to assess the four-chamber view of the heart and outflow tracts, assessment of blood flow across the tricuspid valve and in the ductus venosus. At the routine second and third trimester scans the protocol included a sweep through the heart in transverse plane to assess the four-chamber view, outflow tracts and three-vessel view of the heart.

Presence or absence of tricuspid regurgitation was determined by pulsed-wave Doppler during fetal quiescence.²⁰ A sample volume of 3.0 mm was positioned across the tricuspid valve in an apical four chamber view of the fetal heart such that the angle to the direction of flow was less than 30°. The tricuspid valve could be insufficient in one or more of its three cusps and therefore the sample volume was placed across the valve at least three times in an attempt to interrogate the complete valve. The diagnosis of tricuspid regurgitation was made if it was found during at least half of the systole and with a velocity of >60 cm/s, because aortic or pulmonary arterial blood flow at this gestation can produce a maximum velocity of 50 cm/s. In the assessment of flow in the ductus venosus,²¹ examinations were undertaken during fetal quiescence, the magnification of the image was such that the fetal thorax and abdomen occupied the whole screen, a right ventral mid-sagittal view of the fetal trunk was obtained and color flow mapping was used to demonstrate the umbilical vein, ductus venosus and fetal heart, the pulsed Doppler sample was small (0.5–1.0 mm) to avoid contamination from the adjacent veins and it was placed in the yellowish aliasing area which is the portion immediately above the umbilical sinus, the insonation angle was less than 30°, the filter was set at a low frequency (50–70 Hz) to allow visualization of the whole waveform, and the sweep speed was high (2–3 cm/s) so that the waveforms were widely spread allowing better assessment of the a-wave. Waveforms were assessed qualitatively and considered to be abnormal if the a-wave was reversed.

Fetal echocardiography by a cardiologist was carried out at 11-13 weeks²² in all cases of fetal NT $\geq 99^{\text{th}}$ percentile for CRL and at 20 weeks in those with NT between the 95th and 99th percentiles or tricuspid regurgitation or reversed a-wave in the ductus venosus at 11-13 weeks.

Outcome measures

In this study, we compared the measurements of fetal NT and blood flow across the tricuspid valve and ductus venosus at 11–13 weeks in pregnancies with major fetal heart defects and those resulting in live birth of morphologically normal babies. Heart defects were considered to be major if they required surgery or interventional cardiac catheterization within the first year of life. We included all cases with major heart defects diagnosed by pediatric cardiologists either antenatally and/or in the neonatal period. Abnormalities suspected antenatally but not confirmed in the neonates were not included. In contrast, the prenatal diagnosis in cases of terminations and miscarriages at <24 weeks or stillbirths at ≥ 24 weeks were assumed to be correct because in these cases postmortem examination was not performed systematically. All babies in our hospitals are examined in the neonatal period by a pediatrician, but certain asymptomatic internal abnormalities are inevitably missed. For example, ventricular septal defects or coarctation of the aorta with patent arterial duct may be missed by early neonatal examination, which does not include echocardiography. However, all children with heart defects diagnosed prenatally or postnatally from our area are examined in a regional pediatric cardiac centre which notifies us of any such abnormalities.

We excluded: first, all aneuploidies and non-cardiac defects diagnosed prenatally or in the neonatal period, second, pregnancies with no abnormal fetal findings at the first, second or third trimester scans which resulted in termination, miscarriage or stillbirth and third, those lost to follow-up. We also excluded the following heart defects: first, ventricular septal defects because they are generally not considered to be major defects, second, right aortic arch, persistent left superior vena cava and aberrant right subclavian artery because these are variants of normal rather than true defects, and third, cardiac tumors, ventricular aneurism, arrhythmias and

cardiomyopathy, developing during the second and third trimesters of pregnancy because these defects would not be expected to have any manifestations during the 11–13 weeks' scan.

Cases with coarctation of the aorta, aortic arch hypoplasia and interrupted aortic arch were classified as arch abnormalities. Similarly, cases with Epstein's anomaly or tricuspid dysplasia were classified as tricuspid valve abnormalities. Cases with at least two different major heart defects were classified as complex.

Association of major heart defects with high NT, tricuspid regurgitation and abnormal flow in the ductus venosus

The incidence of fetal NT $\geq 95^{\text{th}}$ and NT $\geq 99^{\text{th}}$ percentile, tricuspid regurgitation and reversed a-wave in the ductus venosus in fetuses with and without major heart defects was determined and the performance of each marker and their combination in the detection of major heart defects was calculated.

Literature Search

We searched MEDLINE, Embase and the Cochrane Library from inception to October 2019 to identify first-trimester screening studies for major heart defects by high NT, tricuspid regurgitation or abnormal flow in the ductus venosus. We selected studies involving a minimum of 1,000 pregnancies which reported data allowing calculation of detection rate (DR) and false positive rate (FPR). The results of these studies were tabulated for comparison with our findings.

RESULTS

Study population

During the study period we carried out an ultrasound examination at 11-13 weeks in 101,793 singleton pregnancies with a live fetus and CRL of 45-84 mm. We excluded 4,802 that were lost to follow up, 796 with prenatal or postnatal diagnosis of aneuploidy, 1,328 with prenatal or postnatal diagnosis of non-cardiac defects, 181 with heart defects that did not meet the inclusion criteria, and 1,477 with no detectable abnormalities but subsequent termination, miscarriage or stillbirth (Figure 1). The study population of 93,209 pregnancies included 211 (0.23%) with major heart defects and 92,998 morphologically normal neonates.

At the time of the first-trimester scan the median maternal age of the study population was 31.0 (IQR 26.7-34.8) years, the median weight was 67.3 (IQR 59.5-78.5) Kg, the median fetal CRL was 63.8 (IQR 58.5-69.6) mm and median gestational age was 12.7 (IQR 12.3-13.2) weeks; the scan was carried out during the 11th week in only 7,853 (8.4%) of cases. The racial origin of the women was White in 69,529 (74.6%), Black in 15,021 (16.1%), South Asian in 4,220 (4.5%), East Asian in 1,948 (2.1%) and mixed in 2,491 (2.7%). The 11-13 weeks scan was carried out by one of 476 sonographers.

Major heart defects

In 113 (53.6%) of the major heart defects the diagnosis was made or suspected at the 11-13 weeks scan, in 82 (38.9%) at the 18-24 weeks scan, in 10 (4.7%) at the third-trimester scan and in 6 (2.8%) postnatally. At the 11-13 weeks scan we diagnosed all cases of tricuspid or pulmonary atresia and polyvalvular dysplasia, >90% of cases of hypoplastic left heart syndrome or atrioventricular septal defect, about 60% of complex heart defects and left atrial isomerism (interrupted inferior vena cava with normal intracardiac anatomy), 30-40% of tetralogy of Fallot and arch abnormalities, 25% of tricuspid valve abnormalities, about 15% of transposition of great arteries, but none of aortic or pulmonary stenosis and common arterial trunk. If a cardiac defect

was suspected at the 11-13 weeks scan but the cardiologists were uncertain of the diagnosis the patients were reviewed at 15-16 weeks' gestation.

Association of major heart defects with high NT, tricuspid regurgitation and abnormal ductus venosus flow

The incidence of high NT, tricuspid regurgitation and abnormal flow in the ductus venosus was significantly higher in fetuses with than without major heart abnormalities (Table 1). The performance of high NT, tricuspid regurgitation, abnormal flow in the ductus venosus and their combination in the detection of major heart defects is shown in Table 2. Fetal NT $\geq 95^{\text{th}}$ percentile, NT $\geq 99^{\text{th}}$ percentile, tricuspid regurgitation, or abnormal ductus venosus flow was observed in 77 (36.5%), 45 (21.3%), 61 (28.9%), and 58 (27.5%) of the fetuses with major heart defects, respectively, and in 5,678 (6.1%), 857 (0.9%), 1,136 (1.2%), and 1,644 (1.8%) of those without heart defects. Any one of NT $\geq 95^{\text{th}}$, tricuspid regurgitation or abnormal flow in the ductus venosus was found in 117 (55.5%, 95% CI 48.5-62.3%) of the fetuses with heart defects and in 8,166 (8.8%, 95% CI 8.6-9.0%) of those without heart defects. Any one of NT $\geq 99^{\text{th}}$ percentile and the other two markers was found in 99 of the fetuses with heart defects (46.9%, 95% CI 40.0-53.9%) and in 3,517 of those without heart defects (3.8%, 95% CI 3.7-3.9%).

Literature search

The findings of the screening studies with a minimum of 1,000 patients providing data on the association between major heart defects and high NT, abnormal flow in the ductus venosus and tricuspid regurgitation identified by the literature search are summarized in Table 3.

DISCUSSION

Main findings of the study

This study of 93,209 pregnancies, including 211 (0.23%) with major heart defects has demonstrated that: first, >90% of the defects were detected at the first or second trimester scans and in more than half the diagnosis was made at the 11-13 weeks scan; second, at the first-trimester scan we diagnosed all cases of tricuspid or pulmonary atresia and polyvalvular dysplasia, >90% of cases of hypoplastic left heart syndrome or atrioventricular septal defect, about 60% of complex heart defects and left atrial isomerism (interrupted inferior vena cava with normal intracardiac anatomy), 30-40% of tetralogy of Fallot and arch abnormalities, 25% of tricuspid valve abnormalities, about 15% of transposition of great arteries, but none of aortic or pulmonary stenosis and common arterial trunk; and third, any one of NT $\geq 95^{\text{th}}$, tricuspid regurgitation or reversed a-wave in the ductus venosus was found in 55.5% of the fetuses with heart defects and in 8.8% of those without heart defects and any one of NT $\geq 99^{\text{th}}$ percentile and the other two markers was found in 46.9% of the fetuses with heart defects and in 3.8% of those without heart defects.

Comparison with findings from previous studies

Our findings in this series of 93,209 pregnancies, examined between 2009 and 2018, are consistent with those in our previous study of 40,990 pregnancies examined between 2006 and 2009. Previous studies reporting on the association between high NT and major heart defects varied in the definition of high NT, which included NT $>95^{\text{th}}$ percentile, $\geq 95^{\text{th}}$ percentile, >2.5 mm or ≥ 2.5 mm and of very high NT, which included NT $>99^{\text{th}}$ percentile, $\geq 99^{\text{th}}$ percentile, >3.5 mm, ≥ 3.5 mm or ≥ 2.5 MoM.^{4,9,11,12,23-34} Our findings, that with NT $\geq 95^{\text{th}}$ percentile the DR and FPR were about 37% and 6%, respectively and that with NT $\geq 99^{\text{th}}$ percentile the DR and FPR were 21% and 1%, respectively, are consistent with the results of most previous studies.

Six studies reported on the association between abnormal flow in the ductus venosus, defined as reversed or absent/reversed a-wave, and major heart defects.^{9,11,12,32-34} The number of pregnancies examined varied from 1,066 to 40,990 cases, the incidence of heart defects varied from 0.21 to 0.73%, the DR varied from 20 to 39% and FPR varied from 1.8 to 5.6%. Our findings of DR of about 28% at FPR of 1.8% are consistent with the results of most of the above studies.

Two studies reported on the association between tricuspid regurgitation and major heart defects. Pereira *et al.*, examined 40,990 pregnancies including 85 (0.21%) with major heart defects and reported that the DR and FPR of tricuspid regurgitation was 32.9% and 1.3%, respectively; with a combination of NT >95th percentile, tricuspid regurgitation or abnormal ductus venosus flow the DR was 57.6% and FPR was 8.0%.¹¹ Very similar results were obtained by Volpe *et al.*, who examined 4,445 pregnancies including 18 (0.40%) with major heart defects and reported that the DR and FPR of tricuspid regurgitation was 33.3% and 1.7%, respectively; with a combination of NT >95th percentile, tricuspid regurgitation or abnormal ductus venosus flow the DR was 55.6% and FPR was 10.1%.³⁴

Implications for clinical practice

Assessment of blood flow across the tricuspid valve and in the ductus venosus was initially incorporated into the 11-13 weeks scan with the aim of improving the performance of screening for fetal trisomies, especially in women with an intermediate risk from the combined test.³⁵⁻³⁸ A secondary benefit arose from the finding of an association between these markers and major heart defects. Recently, the importance of these Doppler studies in screening for trisomies was diminished after the widespread uptake of cfDNA testing of maternal blood, especially in women with an intermediate risk from the combined test. However, our findings highlight the continuing importance of these markers in screening for heart defects; high NT was observed in about 37% of fetuses with major heart defects and any one of the three markers was present in 56% of the affected fetuses.

In our study three factors contributed to the high first and / or second trimester prenatal detection rate of major heart defects; first, specific training of all sonographers and expectation that they would follow a protocol which includes examination of the transverse section of the thorax and use of color Doppler to assess the four-chamber view of the heart and outflow tracts, second, assessment of blood flow across the tricuspid valve and in the ductus venosus, and third, ready availability of fetal cardiologists to examine all cases of suspected heart defects and those with high NT, tricuspid regurgitation or abnormal flow in the ductus venosus. Within such a framework it is not possible to define the differential contribution of each marker or component of the service in the detection of major heart defects. In cases with optimal examination of the four-chamber view of the heart and outflow tracts it is unlikely that there would be additional benefit from assessment of tricuspid or ductus venosus flow, however it is often not possible to achieve such optimal examination and in such cases the finding of tricuspid regurgitation or reversed a-wave in the ductus venosus would alert the sonographer of the necessity for referral to a specialist echocardiographer. This is analogous to the second-trimester assessment of the fetal skull and cerebellum for the lemon and banana signs, respectively, or first-trimester intracerebral translucency, which provide clues to the sonographer for the possible need for more careful examination of the spine for diagnosis of open spina bifida.³⁹⁻⁴³

Strengths and limitations of the study

The main strength of our study is the examination of a large number of pregnancies attending for routine assessment in the first, second and third trimesters of pregnancy using standardized protocols and appropriately trained sonographers in units with expertise in fetal medicine and fetal cardiology.

There are three main limitations of the study. First, the study was retrospective and recruitment span over a 10-year period during which there have been considerable improvements in the quality and resolution of ultrasound images. Second, a limitation of this and most previous studies investigating the effectiveness of routine ultrasound examination in the prenatal diagnosis of major heart defects relates to ascertainment of such abnormalities. Although in our

Accepted Article

centres all neonates are examined by pediatricians it is possible that asymptomatic abnormalities, such as coarctation of the aorta with patent arterial duct may be missed by early neonatal examination. Third, another limitation of this study is the method of diagnosing or excluding a cardiac defect in cases of pregnancy termination or fetal death. We selected the pragmatic end-point of sonographically detectable defect by a pediatric cardiologist specialist in fetal echocardiography. Ideally, in these cases the antenatal findings should have been validated by postmortem examination.

Conclusions

At 11-13 weeks' gestation measurement of nuchal translucency and assessment of flow across the tricuspid valve and in the ductus venosus can lead to the early diagnosis of major heart defects.

Sources of Funding: The study was supported by a grant from the Fetal Medicine Foundation (Charity No: 1037116).

Conflict of interest: No

REFERENCES

1. Souka AP, Snijders RJ, Novakov A, Soares W, Nicolaides KH. Defects and syndromes in chromosomally normal fetuses with increased nuchal translucency thickness at 10–14 weeks of gestation. *Ultrasound Obstet Gynecol* 1998; **11**: 391–400.
2. Syngelaki A, Chelemen T, Dagklis T, Allan L, Nicolaides KH. Challenges in the diagnosis of fetal non-chromosomal abnormalities at 11–13 weeks. *Prenat Diagn* 2011; **31**: 90–102.
3. Syngelaki A, Hammami A, Bower S, Zidere V, Akolekar R, Nicolaides KH. Diagnosis of fetal non-chromosomal abnormalities on routine ultrasound examination at 11–13 weeks' gestation. *Ultrasound Obstet Gynecol* 2019; **54**: 468–476.
4. Hyett J, Perdu M, Sharland G, Snijders R, Nicolaides KH. Using fetal nuchal translucency to screen for major congenital cardiac defects at 10–14 weeks of gestation: population based cohort study. *BMJ* 1999; **318**: 81–85.
5. Ghi T, Huggon IC, Zosmer N, Nicolaides KH. Incidence of major structural cardiac defects associated with increased nuchal translucency but normal karyotype. *Ultrasound Obstet Gynecol* 2001; **18**: 610–614.
6. Atzei A, Gajewska K, Huggon IC, Allan L, Nicolaides KH. Relationship between nuchal translucency thickness and prevalence of major cardiac defects in fetuses with normal karyotype. *Ultrasound Obstet Gynecol* 2005; **26**: 154–157.
7. Matias A, Huggon I, Areias JC, Montenegro N, Nicolaides KH. Cardiac defects in chromosomally normal fetuses with abnormal ductus venosus blood flow at 10–14 weeks. *Ultrasound Obstet Gynecol* 1999; **14**: 307–310.
8. Maiz N, Plasencia W, Dagklis T, Faros E, Nicolaides K. Ductus venosus Doppler in fetuses with cardiac defects and increased nuchal translucency thickness. *Ultrasound Obstet Gynecol* 2008; **31**: 256–260.
9. Martínez JM, Comas M, Borrell A, Bennasar M, Gómez O, Puerto B, Gratacós E. Abnormal first-trimester ductus venosus blood flow: a marker of cardiac defects in fetuses with normal karyotype and nuchal translucency. *Ultrasound Obstet Gynecol* 2010; **35**: 267–272.
10. Chelemen T, Syngelaki A, Maiz N, Allan L, Nicolaides KH. Contribution of ductus venosus Doppler in first trimester screening for major cardiac defects. *Fetal Diagn Ther* 2011; **29**: 127–134.

11. Pereira S, Ganapathy R, Syngelaki A, Maiz N, Nicolaides KH. Contribution of fetal tricuspid regurgitation in first-trimester screening for major cardiac defects. *Obstet Gynecol* 2011; **117**: 1384-1391.
12. Borrell A, Grande M, Bennasar M, Borobio V, Jimenez JM, Stergiotou I, Martinez JM, Cuckle H. First-trimester detection of major cardiac defects with the use of ductus venosus blood flow. *Ultrasound Obstet Gynecol* 2013; **42**: 51-57.
13. Nicolaides KH, Azar GB, Byrne D, Mansur CA, Marks K. Nuchal translucency: ultrasound screening for chromosomal defects in the first trimester of pregnancy. *BMJ* 1992; **304**: 867-869.
14. Snijders RJ, Noble P, Sebire N, Souka A, Nicolaides KH. UK multicentre project on assessment of risk of trisomy 21 by maternal age and fetal nuchal-translucency thickness at 10-14 weeks of gestation. Fetal Medicine Foundation First Trimester Screening Group. *Lancet* 1998; **352**: 343-346.
15. Wright D, Kagan KO, Molina FS, Gazzoni A, Nicolaides KH. A mixture model of nuchal translucency thickness in screening for chromosomal defects. *Ultrasound Obstet Gynecol* 2008; **31**: 376-383.
16. Spencer K, Souter V, Tul N, Snijders R, Nicolaides KH. A screening program for trisomy 21 at 10–14 weeks using fetal nuchal translucency, maternal serum free beta-human chorionic gonadotropin and pregnancy-associated plasma protein-A. *Ultrasound Obstet Gynecol* 1999; **13**: 231–237.
17. Kagan KO, Wright D, Baker A, Sahota D, Nicolaides KH. Screening for trisomy 21 by maternal age, fetal nuchal translucency thickness, free beta-human chorionic gonadotropin and pregnancy-associated plasma protein-A. *Ultrasound Obstet Gynecol* 2008; **31**: 618–624.
18. Gil MM, Accurti V, Santacruz B, Plana MN, Nicolaides KH. Analysis of cell-free DNA in maternal blood in screening for aneuploidies: updated meta-analysis. *Ultrasound Obstet Gynecol* 2017; **50**: 302-314.
19. Gil MM, Revello R, Poon LC, Akolekar R, Nicolaides KH. Clinical implementation of routine screening for fetal trisomies in the UK NHS: cell-free DNA test contingent on results from first-trimester combined test. *Ultrasound Obstet Gynecol* 2016; **47**: 45-52.
20. Falcon O, Faiola S, Huggon I, Allan L, Nicolaides KH. Fetal tricuspid regurgitation at the 11+0 to 13+6-week scan: association with chromosomal defects and reproducibility of the method. *Ultrasound Obstet Gynecol* 2006; **27**: 609–612.

21. Maiz N, Kagan KO, Milovanovic Z, Celik E, Nicolaides KH: Learning curve for Doppler assessment of ductus venosus flow at 11 +0 to 13 +6 weeks' gestation. *Ultrasound Obstet Gynecol* 2008; **31**: 503-506.
22. Huggon IC, Ghi T, Cook AC, Zosmer N, Allan LD, Nicolaides KH. Fetal cardiac abnormalities identified prior to 14 weeks' gestation. *Ultrasound Obstet Gynecol* 2002; **20**: 22-29.
23. Michailidis GD, Economides DL. Nuchal translucency measurement and pregnancy outcome in karyotypically normal fetuses. *Ultrasound Obstet Gynecol* 2001; **17**: 102-105.
24. Mavrides E, Cobian-Sanchez F, Tekay A, Moscoso G, Campbell S, Thilaganathan B, Carvalho JS. Limitations of using first-trimester nuchal translucency measurement in routine screening for major congenital heart defects. *Ultrasound Obstet Gynecol* 2001; **17**: 106-110.
25. Hafner E, Schuller T, Metzenbauer M, Schuchter K, Philipp K. Increased nuchal translucency and congenital heart defects in a low-risk population. *Prenat Diagn* 2003; **23**: 985-989.
26. Bruns RF, Moron AF, Murta CG, Gonçalves LF, Zamith MM. The role of nuchal translucency in the screening for congenital heart defects. *Arq Bras Cardiol* 2006; **87**: 307-314.
27. Westin M, Saltvedt S, Bergman G, Almström H, Grunewald C, Valentin L. Is measurement of nuchal translucency thickness a useful screening tool for heart defects? A study of 16,383 fetuses. *Ultrasound Obstet Gynecol* 2006; **27**: 632-639.
28. Müller MA, Clur SA, Timmerman E, Bilardo CM. Nuchal translucency measurement and congenital heart defects: modest association in low-risk pregnancies. *Prenat Diagn* 2007; **27**: 164-169.
29. Simpson LL, Malone FD, Bianchi DW, Ball RH, Nyberg DA, Comstock CH, Saade G, Eddleman K, Gross SJ, Dugoff L, Craigo SD, Timor-Tritsch IE, Carr SR, Wolfe HM, Tripp T, D'Alton ME. Nuchal translucency and the risk of congenital heart disease. *Obstet Gynecol* 2007; **109**: 376-383.
30. Sananes N, Guigue V, Kohler M, Bouffet N, Cancellier M, Hornecker F, Hunsinger MC, Kohler A, Mager C, Neumann M, Schmerber E, Tanghe M, Nisand I, Favre R. Nuchal translucency and cystic hygroma colli in screening for fetal major congenital heart defects in a series of 12,910 euploid pregnancies. *Ultrasound Obstet Gynecol* 2010; **35**: 273-279.

31. Alanen J, Leskinen M, Sairanen M, Korpimaki T, Kouru H, Gissler M, Ryyanen M, Nevalainen J. Fetal nuchal translucency in severe congenital heart defects: experiences in Northern Finland. *J Matern Fetal Neonatal Med* 2019; **32**: 1454-1460.
32. Toyama JM, Brizot ML, Liao AW, Lopes LM, Nomura RM, Saldanha FA, Zugaib M. Ductus venosus blood flow assessment at 11 to 14 weeks of gestation and fetal outcome. *Ultrasound Obstet Gynecol* 2004; **23**: 341-345.
33. Wiechec M, Nocun A, Matyszkiewicz A, Wiercinska E, Latała E. First trimester severe ductus venosus flow abnormalities in isolation or combination with other markers of aneuploidy and fetal anomalies. *J Perinat Med* 2016; **44**: 201-209.
34. Volpe P, Ubaldo P, Volpe N, Campobasso G, De Robertis V, Tempesta A, Volpe G, Rembouskos G. Fetal cardiac evaluation at 11-14 weeks by experienced obstetricians in a low-risk population. *Prenat Diagn* 2011; **31**: 1054-1061.
35. Maiz N, Valencia C, Kagan KO, Wright D, Nicolaides KH. Ductus venosus Doppler in screening for trisomies 21, 18 and 13 and Turner syndrome at 11–13 weeks of gestation. *Ultrasound Obstet Gynecol* 2009; **33**: 512–517. 3.
36. Kagan KO, Valencia C, Livanos P, Wright D, Nicolaides KH. Tricuspid regurgitation in screening for trisomies 21, 18 and 13 and Turner syndrome at 11 + 0 to 13 + 6 weeks of gestation. *Ultrasound Obstet Gynecol* 2009; **33**: 18–22.
37. Nicolaides KH, Spencer K, Avgidou K, Faiola S, Falcon O. Multicenter study of first-trimester screening for trisomy 21 in 75 821 pregnancies: results and estimation of the potential impact of individual risk-orientated two-stage first-trimester screening. *Ultrasound Obstet Gynecol* 2005; **25**: 221–226. 8.
38. Kagan KO, Staboulidou I, Cruz J, Wright D, Nicolaides KH. Two-stage first-trimester screening for trisomy 21 by ultrasound assessment and biochemical testing. *Ultrasound Obstet Gynecol* 2010; **36**: 542–547.
39. Nicolaides KH, Campbell S, Gabbe SG, Guidetti R. Ultrasound screening for spina bifida: cranial and cerebellar signs. *Lancet* 1986; **2**: 72-74.
40. Van den Hof MC, Nicolaides KH, Campbell J, Campbell S. Evaluation of the lemon and banana signs in one hundred and thirty fetuses with open spina bifida. *Am J Obstet Gynecol* 1990; **162**: 322-327.
41. Chaoui R, Benoit B, Mitkowska-Wozniak H, Heling KS, Nicolaides KH. Assessment of intracranial translucency (IT) in the detection of spina bifida at the 11-13-week scan. *Ultrasound Obstet Gynecol* 2009; **34**: 249-252.

42. Chaoui R, Nicolaides KH. From nuchal translucency to intracranial translucency: towards the early detection of spina bifida. *Ultrasound Obstet Gynecol* 2010; **35**: 133-138.
43. Lachmann R, Chaoui R, Moratalla J, Picciarelli G, Nicolaides KH. Posterior brain in fetuses with open spina bifida at 11 to 13 weeks. *Prenat Diagn* 2011; **31**: 103-106.

Figure legend

Figure 1. Description of the study population.

Table 1. Timing of diagnosis of major heart defects and their relation to high nuchal translucency thickness, tricuspid regurgitation and abnormal flow in the ductus venosus at the 11-13 weeks scan.

Group	n	Diagnosis				Nuchal translucency		Tricuspid regurgitation	Abnormal ductus venosus flow	Any of the three markers
		First trimester	Second trimester	Third trimester	Postnatal	≥ 95 th percentile	≥ 99 th percentile			
Major heart defects	211	113 (53.6)	82 (38.9)	10 (4.7)	6 (2.8)	77 (36.5)	45 (21.3)	61 (28.9)	58 (27.5)	117 (55.5)
Tricuspid atresia	7	7 (100)				3 (42.9)	1 (14.3)		4 (57.1)	4 (57.1)
Pulmonary atresia	11	11 (100)				4 (36.4)	4 (36.4)	6 (54.5)	3 (27.3)	7 (63.6)
Polyvalvular dysplasia	1	1 (100)				1 (100)	1 (100)	1 (100)	1 (100)	1 (100)
Hypoplastic left heart syndrome	40	37 (92.5)	3 (7.5)			17 (42.5)	9 (22.5)	16 (40.0)	15 (37.5)	25 (62.5)
Septoventricular septal defect	11	10 (90.9)	1 (9.1)			8 (72.7)	7 (63.6)	9 (81.8)	5 (45.5)	10 (90.9)
Complex heart defects	26	16 (61.5)	10 (38.5)			11 (42.3)	6 (23.1)	10 (38.5)	13 (50.0)	18 (69.2)
Left atrial isomerism	7	4 (57.1)	3 (42.9)			3 (42.9)	2 (28.6)	1 (14.3)	2 (28.6)	4 (57.1)
Tetralogy of Fallot	29	11 (37.9)	16 (55.2)	1 (3.6)	1 (3.4)	5 (17.2)	4 (13.8)	7 (24.1)	4 (13.8)	12 (41.4)
Other abnormalities	38	12 (31.6)	21 (55.3)	4 (10.5)	1 (2.6)	18 (47.4)	9 (23.7)	5 (13.2)	8 (21.1)	22 (57.9)
Tricuspid valve abnormalities	8	2 (25.0)	3 (37.5)	2 (25.0)	1 (12.5)	2 (25.0)	1 (12.5)	4 (50.0)	1 (12.5)	5 (62.5)
Transposition of great arteries	15	2 (13.3)	12 (80.0)		1 (6.7)	2 (13.3)		1 (6.7)		3 (20.0)
Aortic stenosis	6		4 (66.7)	1 (16.7)	1 (16.7)	1 (16.7)	1 (16.7)	1 (16.7)	2 (33.3)	4 (66.7)
Pulmonary stenosis	11		8 (72.7)	2 (18.2)	1 (9.1)	2 (18.2)				2 (18.2)
Common arterial trunk	1		1 (100)							
Normal live births	92,998					5,678 (6.1)	857 (0.9)	1,136 (1.2)	1,644 (1.8)	8,166 (8.8)

Data are presented as n (%).

Table 2. Performance of high nuchal translucency thickness, tricuspid regurgitation, abnormal flow in the ductus venosus and their combination in the detection of major heart defects.

Screening	DR	FPR	+ve LR	-ve LR	PPV	NPV
NT $\geq 95^{\text{th}}$ percentile	77; 36.5 (30.0-43.4)	5,678; 6.1 (6.0-6.3)	5.98 (4.99-7.15)	0.68 (0.61-0.75)	1.34 (1.12-1.60)	99.85 (99.83-99.86)
NT $\geq 99^{\text{th}}$ percentile	45; 21.3 (16.0-27.5)	857; 0.92 (0.86-0.98)	23.14 (17.71-30.24)	0.79 (0.74-0.85)	4.99 (3.86-6.42)	99.82 (99.81-99.83)
Tricuspid regurgitation	61; 28.9 (22.9-35.5)	1,136; 1.2 (1.2-1.3)	23.67 (19.01-29.47)	0.72 (0.66-0.78)	5.10 (4.13-6.27)	99.84 (99.82-99.85)
Abnormal DV flow	58; 27.5 (21.6-34.0)	1,644; 1.8 (1.7-1.9)	15.55 (12.42-19.46)	0.74 (0.68-0.80)	3.41 (2.74-4.23)	99.83 (99.82-99.85)
NT $\geq 95^{\text{th}}$ percentile and / or tricuspid regurgitation	104; 49.3 (42.4-56.2)	6,665; 7.2 (7.0-7.3)	6.88 (5.99-7.90)	0.55 (0.48-0.62)	1.54 (1.34-1.76)	99.88 (99.86-99.89)
NT $\geq 95^{\text{th}}$ percentile and / or abnormal DV flow	97; 46.0 (39.1-53.0)	7,208; 7.8 (7.6-7.9)	5.93 (5.12-6.88)	0.59 (0.52-0.66)	1.33 (1.15-1.54)	99.87 (99.85-99.88)
any of the three	117; 55.5 (48.5-62.3)	8,166; 8.8 (8.6-9.0)	6.31 (5.59-7.14)	0.49 (0.42-0.57)	1.41 (1.25-1.59)	99.89 (99.87-99.90)
NT $\geq 99^{\text{th}}$ percentile						
Tricuspid regurgitation	80; 37.9 (31.3-44.8)	1,949; 2.1 (2.0-2.2)	18.1 (15.1-21.6)	0.63 (0.57-0.70)	3.94 (3.32-4.68)	99.86 (99.84-99.87)
Abnormal DV flow	73; 34.6 (28.2-41.4)	2,460; 2.7 (2.6-2.8)	13.1 (10.8-15.8)	0.67 (0.61-0.74)	2.88 (2.40-3.46)	99.85 (99.83-99.86)
any of the three	99; 46.9 (40.0-53.9)	3,517; 3.8 (3.7-3.9)	12.4 (10.7-14.4)	0.55 (0.49-0.63)	2.74 (2.37-3.16)	99.87 (99.86-99.89)

Data are presented as n; % (95% confidence interval)

DR = detection rate, FPR = false positive rate, LR = likelihood ratio, PPV = positive predictive value, NPV = negative predictive value

Table 3. Summary of results from screening studies for major heart defects by high nuchal translucency thickness, abnormal ductus venosus flow and tricuspid regurgitation.

Author	N	Heart defects	High nuchal translucency			Very high nuchal translucency			Abnormal ductus venosus flow			Tricuspid regurgitation	
			Definition	DR	FPR	Definition	DR	FPR	Definition	DR	FPR	DR	FPR
Hyatt 2000 ⁴	29,154	50 (0.17)	>95 th percentile	28 (56.0)	1,794 (6.2)	>99 th percentile	20 (40.0)	295 (1.0)					
Michailidis 2001 ²³	6,606	9 (0.14)	>95 th percentile	4 (44.4)	219 (3.3)	>99 th percentile	3 (33.3)	60 (0.9)					
Mavroudes 2001 ²⁴	7,339	25 (0.34)	≥ 2.5 mm	4 (16.0)	254 (3.5)	≥3.5 mm	3 (12.0)	57 (0.8)					
Hanner 2003 ²⁵	12,978	25 (0.19)	≥95 th percentile	5 (20.0)	642 (5.0)								
Bruno 2005 ²⁶	3,664	9 (0.25)	>2.5 mm	2 (22.2)	154 (4.2)	>3.5 mm	2 (22.2)	31 (0.74)					
Westin 2006 ²⁷	16,383	55 (0.34)	≥95 th percentile	8 (14.5)	426 (2.6)	≥3.5 mm	3 (5.4)	49 (0.3)					
Murphy 2007 ²⁸	4,144	13 (0.31)	>95 th percentile	2 (15.4)	98 (2.4)	>99 th percentile	2 (15.4)	19 (0.5)					
Simpson 2007 ²⁹	34,266	52 (0.15)				≥2.5 MoM	7 (13.5)	202 (0.6)					
Sananes 2010 ³⁰	12,910	44 (0.34)	≥95 th percentile	24 (54.5)	1,106 (8.6)	≥3.5 mm	(27.3)	(1.7)					
Alanen 2019 ³¹	31144	62 (0.2)	>95 th percentile	26 (32.9)	1531 (4.9)	>99 th percentile	12 (15.2)	299 (0.96)					
Toyama 2004 ³²	1,066	5 (0.50)	>95 th percentile	2 (40.0)	134 (12.6)				A/R a-wave	1 (20.0)	59 (5.6)		
Martinez 2010 ⁹	6,120	45 (0.73)				>99 th percentile	13 (28.9)	63 (1.0)	A/R a-wave	11 (24.4)	134 (2.2)		
Bonnet 2013 ¹²	12,835	36 (0.28)	>95 th percentile	15 (41.7)	(5.0)	>99 th percentile	10 (28.6)	(1.0)	A/R a-wave	14 (38.9)	222 (1.8)		
Wieder 2016 ³³	5,673	28 (0.50)							R a-wave	6 (21.4)	135 (2.4)		
Pereira 2011 ¹¹	40,990	85 (0.21)	>95 th percentile	30 (35.3)	1,956 (4.8)	>99 th percentile	18 (21.2)	290 (0.7)	R a-wave	24 (28.2)	856 (2.1)	28 (32.9)	516 (1.3)
Volpe 2011 ³⁴	4,445	18 (0.40)	>95 th percentile	7 (38.9)	248 (5.6)	>99 th percentile	4 (22.2)	49 (1.1)	R a-wave	4 (22.2)	137 (3.1)	6 (33.3)	606 (1.7)
This study	93,209	211 (0.23)	≥95 th percentile	77 (36.5)	5,678 (6.1)	≥99 th percentile	45 (21.3)	857 (0.9)	R a-wave	58 (27.5)	1,644 (1.8)	61 (28.9)	1,136 (1.2)

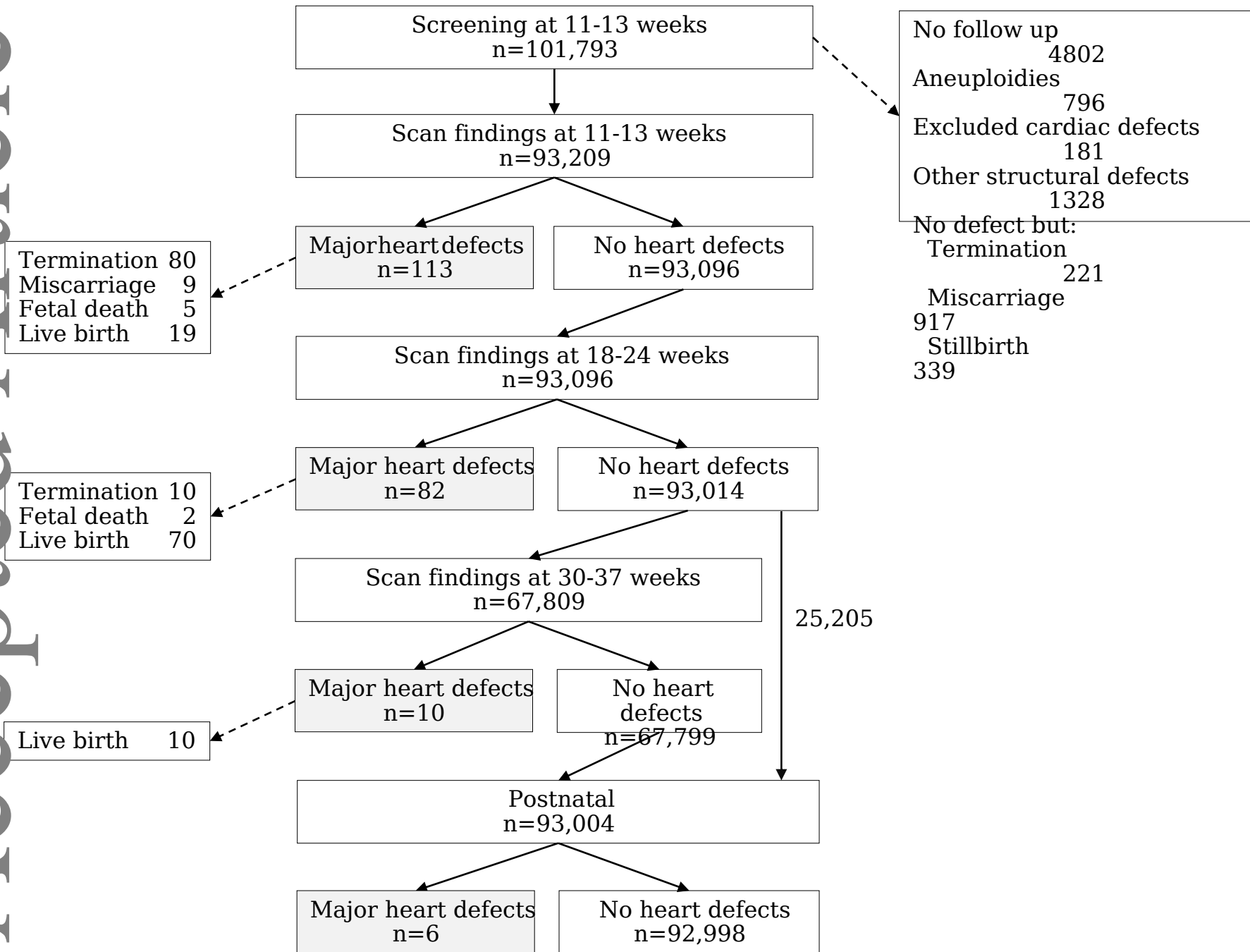


Figure 1