



# THE UNIVERSITY *of* EDINBURGH

## Edinburgh Research Explorer

### Unique Case of Haemophilus Influenzae Purulent Pericarditis Secondary to Infected Mirena Coil

**Citation for published version:**

Tzolos, E, Anwar, M & Scott, AE 2018, 'Unique Case of Haemophilus Influenzae Purulent Pericarditis Secondary to Infected Mirena Coil', *Clinical Case Reports International*.  
<[http://www.clinicalcasereportsint.com/pdfs\\_folder/ccri-v2-id1056.pdf](http://www.clinicalcasereportsint.com/pdfs_folder/ccri-v2-id1056.pdf)>

**Link:**

[Link to publication record in Edinburgh Research Explorer](#)

**Document Version:**

Publisher's PDF, also known as Version of record

**Published In:**

Clinical Case Reports International

**General rights**

Copyright for the publications made accessible via the Edinburgh Research Explorer is retained by the author(s) and / or other copyright owners and it is a condition of accessing these publications that users recognise and abide by the legal requirements associated with these rights.

**Take down policy**

The University of Edinburgh has made every reasonable effort to ensure that Edinburgh Research Explorer content complies with UK legislation. If you believe that the public display of this file breaches copyright please contact [openaccess@ed.ac.uk](mailto:openaccess@ed.ac.uk) providing details, and we will remove access to the work immediately and investigate your claim.





## Unique Case of Haemophilus Influenzae Purulent Pericarditis Secondary to Infected Mirena Coil

Evangelos Tzolos\*, Mohammed Anwar and Anne Scott

Department of Cardiology, Royal Infirmary Edinburgh, UK

### Abstract

A 50 year old previously fit and well lady presented with septic shock. The chest x-ray suggested cardiomegaly and bilateral pleural effusions both of which were new compared to 2 years ago. Inflammatory markers were raised. Sepsis 6 protocols were followed including treatment with broad spectrum antibiotics. A CTPA was performed and showed bilateral pleural effusions and a moderate global pericardial effusion. Bedside echocardiography the next morning confirmed a moderate global pericardial effusion. No clear echocardiographic features of tamponade were present and no pulsus paradoxus elicited but in view of her resistant hypotension requiring inotropes despite adequate filling a decision was made to perform urgent pericardiocentesis. An urgent pericardiocentesis was performed and an immediate improvement in blood pressure was observed. The pericardial fluid had an unusual creamy color and slightly viscous consistency. Pericardial fluid cultures later confirmed the presence of *Haemophilus Influenzae*. A Mirena coil was inserted one month prior to admission. A high vaginal swab from the intrauterine mirena coil revealed *H. Influenzae* infection and prompted removal of the device and full recovery of the patient. We have reviewed PubMed and found 10 cases of *H. Influenzae* pericardial effusion and tamponade in adults. This appears to be the first reported case where the primary focus of *Haemophilus Influenzae* appears to have been related to an intrauterine device. It also illustrates the importance of considering tamponade where classical physical and echocardiographic signs are not present.

**Keywords:** Haemophilus influenzae; Pericarditis

### Patient Presentation

An otherwise healthy 47 year old lady was admitted to the medical admissions unit of our District General Hospital with a one week history of pericarditis chest pain, followed by collapse. She normally kept fit, with regular horse riding. Two weeks prior to admission she started experiencing periodical chills, rigors and night sweating. She then developed pericarditis chest pain and a non-productive cough with associated pleuritic chest pain. She was treated for a lower respiratory tract infection by her GP but she did not improve and on the day of the admission she collapsed, prompting her to visit the emergency department (Table 1).

The only past medical history was of hypertension and uterine fibroids with associated heavy periods. A Mirena Coil device had been implanted one month prior to presentation. There had been no recent foreign travel or known contact with infectious illness. She had no known drug allergies and took no regular medication.

On initial assessment the patient was found to be profoundly hypotensive (BP 80/60) and pyrexial (37.6). She was tachycardia (116/min), oliguric, tachypnoeic (26/min) and hypoxic with saturation by pulse oximetry of 94% on 28% oxygen. Sepsis six protocols were followed in accordance with local guidelines. A full set of bloods was sent including lactate and she was established on fluid resuscitation (3 L over the first hour). She was catheterised to monitor urine output. Broad spectrum antibiotics were administered.

Physical examination revealed her to be peripherally cool with no peripheral signs of endocarditis. Heart sounds were normal with no murmur or rub evident. Kussmaul's sign was negative and pulsus paradoxus was not evident either. Respiratory and abdominal examinations were unremarkable.

Laboratory studies were notable for a white blood cell count of 17,000 with 85% neutrophils, hematocrit of 40.1%, platelet count of 435,000, blood urea nitrogen of 16.5 mmol/L, acute kidney injury with creatinine of 166 µmol/L and an eGFR of 29, (ALT: 122 i.u/L; ALP: 144 i.u/L, bilirubin:

### OPEN ACCESS

#### \*Correspondence:

Evangelos Tzolos, Department of Cardiology, Royal Infirmary Edinburgh, 51 Little France Cres, Edinburgh, Scotland, EH16 4SA, UK, E-mail: [evan.tzolos@gmail.com](mailto:evan.tzolos@gmail.com)

Received Date: 17 May 2018

Accepted Date: 28 Jun 2018

Published Date: 06 Jul 2018

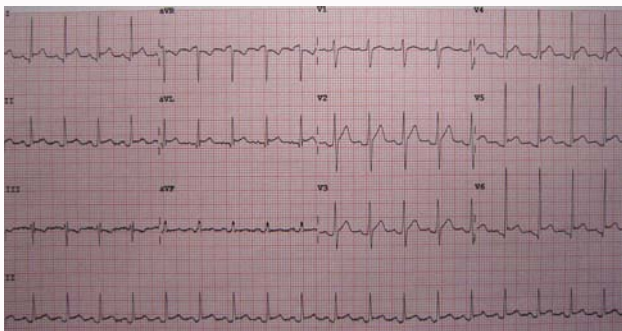
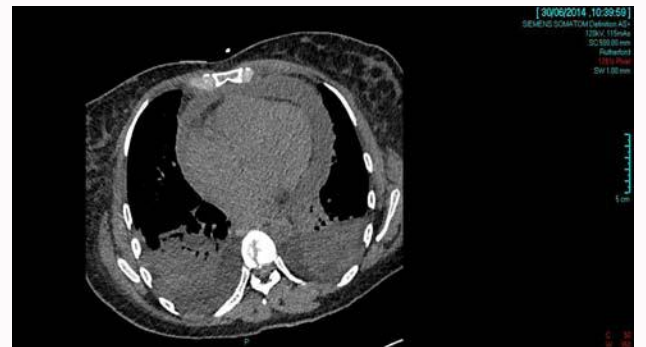
#### Citation:

Tzolos E, Anwar M, Scott A. Unique Case of Haemophilus Influenzae Purulent Pericarditis Secondary to Infected Mirena Coil. *Clin Case Rep Int.* 2018; 2: 1056.

**Copyright** © 2018 Evangelos Tzolos. This is an open access article distributed under the Creative Commons Attribution License, which permits unrestricted use, distribution, and reproduction in any medium, provided the original work is properly cited.

**Table 1:** Timeline.

Day	Events
1	Patient presents acutely with one week history of pericarditis chest pain, followed by collapse.
	Initial assessment suggested septic shock and she was transferred to ICU.
	Hypotensive: adrenaline infusion commenced and broad spectrum antibiotics.
2	Worsening hypotension-increasing adrenaline requirements. Bedside ECHO suggested cardiac tamponade. Pericardial drain inserted.
3	Purulent fluid suggested infective cause.
	Patient improving. Decision made to stop adrenaline.
	Mirena coil removed by Gynaecology team and swabs sent for cultures.
5	Mirena coil swabs returned positive for <i>H. Influenzae</i> and patient switched to appropriate antibiotics.
19	Patient completed 2 weeks of antibiotics. Repeat ECHO suggested no pericardial effusion.
120	3 months follow up ECHO suggested no evidence of restriction.

**Figure 1:** 12 lead ECG on admission suggesting global ST concave elevation with PR segment depression.**Figure 2:** Large pericardial effusion and bilateral pleural effusions.

22 mmol/L, albumin: 21 g/L, lactate of 2.8 mmol/L and a CRP of 244 mg/L. Cardiac biomarkers were negative for myocardial injury.

ECG showed sinus rhythm with a heart rate of 116 bpm and widespread, concave, ST elevation with PR segment depression, consistent with pericarditis (Figure 1).

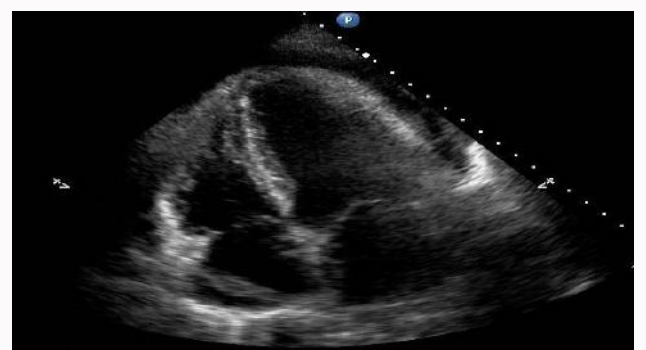A chest x-ray showed a globular heart and bilateral pleural effusions.

Despite the initial aggressive fluid resuscitation she remained hypotensive and was commenced on inotropes to maintain an adequate blood pressure. She was treated as sepsis of unknown origin with IV ceftriaxone and metronidazole.

As the initial investigations revealed acute kidney injury and the ECG were felt to be in keeping with pericarditis, an urgent CT-Thorax was ordered to assess the patient as an echocardiogram was not available out of hours. The CT-thorax demonstrated small bilateral effusions and a global pericardial effusion with estimated volume 250 ml to 500 ml (Figure 2).

The patient was admitted to the intensive care unit for continued inotropic support and the following day despite use of inotropes she remained hypotensive, therefore an urgent echocardiogram and Cardiology review were sought in order to exclude tamponade in view of the CT result. This showed 1.3 cm circumferential pericardial effusion (Figure 3).

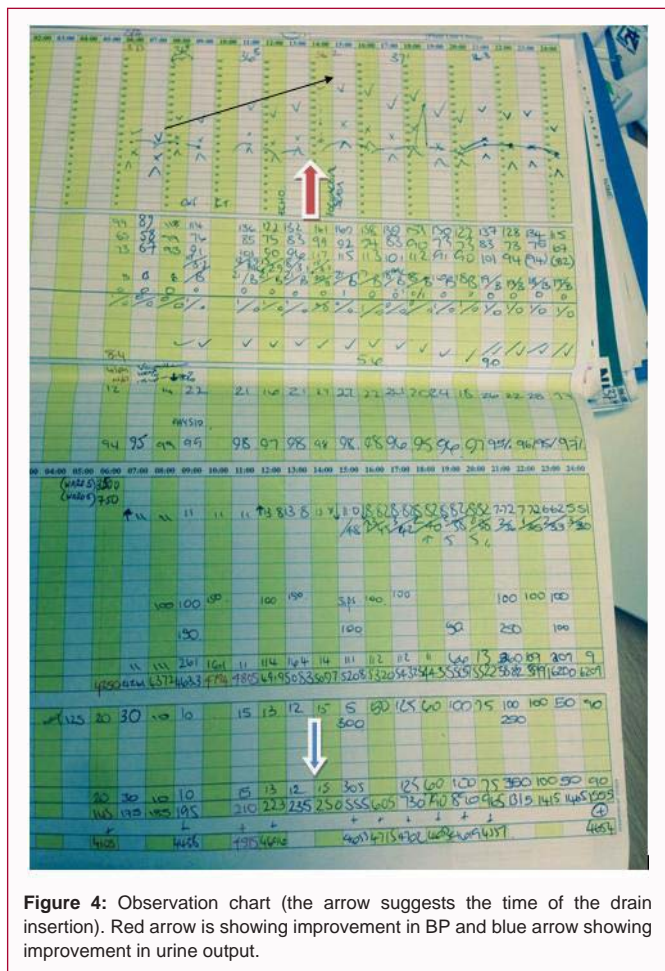
No clear echocardiographic features of tamponade were present and no pulsus paradoxus elicited but in view of her resistant hypotension requiring inotropes despite adequate filling the cardiologist elected to perform urgent pericardiocentesis.

**Figure 3:** 4 Chamber view with marked circumferential pericardial effusion.

670 ml of an unusual creamy color and slightly viscous consistency pericardial fluid was drained. A sample was sent off for culture. Notably her Mean Blood Pressure (MAP) and urine output immediately improved post procedure and she was fully weaned off inotropes by 2 hours after the drain insertion (Figure 4).

A CT of thorax, abdomen and pelvis after the effusion was drained showed that the pericardial effusion had resolved, moderate bilateral pleural effusions remained and a high density uterine mass (7.5 cm) was noted and thought to be consistent with a large fibroid. An intrauterine device *in situ* was also seen. No abscess or other source of infection identified. Cultures of the pleural effusions and high vaginal swabs were also performed.

In the next 24 hours all cultures sent (pericardial fluid, pleural effusion and high vaginal swab) came back positive for *H. Influenzae*. The Mirena Coil was identified as the cause of the infection and it was



**Figure 4:** Observation chart (the arrow suggests the time of the drain insertion). Red arrow is showing improvement in BP and blue arrow showing improvement in urine output.

removed by the Gynaecology team. She was started on the appropriate antibiotics and thereafter patient made a speedy recovery. At 3, 6 and 12 month follow up there has been no evidence of pericardial effusion or constriction.

The following tests were also normal or negative: abdominal ultrasound, blood cultures, HIV test, PCR for RSV, parainfluenza virus type 1-4, Adenovirus, Mycoplasma pneumonia, Metapneumovirus, Rhinovirus, Chlamydia, gonorrhoea, Leptospira and serology for EBV and Lyme.

**Discussion**

In the era of antibiotics *Haemophilus Influenzae* related bacterial pericarditis is rare with only 10-15 cases report to date, with majority of these relating to the pre-antibiotic era [1,2].

We have searched PubMed for similar cases of purulent pericarditis and tamponade secondary to *Haemophilus*. We found 8 pediatric cases and 8 cases in adults. We believe his is the first case report of *Haemophilus Influenzae* pericarditis with associated pericardial tamponade secondary to an infected intrauterine device in an immunologically competent adult.

There are two previous cases of associated pericardial tamponade [2,3]. Drainage of the effusion hastens recovery and normalization

of the haemodynamics. Although previously pericardiectomy or formation of pericardial window was common practice in such cases [1,4], in this case pericardial drainage with antibiotics had a completely successful outcome with no constrictive pericarditis on follow up so far.

Although *Haemophilus Influenzae* most commonly affects the respiratory tract in adults, other source of infection should be actively sought as evidenced by the mirena coil device being the culprit in this case [5].

This case demonstrates *Haemophilus Influenzae* pericarditis with pericardial tamponade although rare can present with severe sepsis which is poorly responsive to inotropes [6]. It also illustrates the importance of considering tamponade where classical physical and echocardiographic signs are not present.

**Conclusion**

Bacterial pericarditis due to *Haemophilus Influenzae* can lead to pericardial effusion with haemodynamic compromise even when the classical clinical or echocardiography signs are not present.

Prompt treatment with antibiotics along with drainage of the pericardial effusion and identification of the source bacteraemia is vital to complete resolution. Cultures of all effusions and *in situ* devices (when possible) are essential.

In this case the outcome was excellent with early antibiotic treatment. Constrictive pericarditis post *Haemophilus Influenzae* pericarditis did not occur but focussed follow-up echo is important. Compared to previous reports our case suggests that a pericardial window is not always necessary.

**Consent**

Informed consent was obtained from this patient for publication of this case history and associated images in line with COPE recommendations.

**References**

- Hirschmann JV, Everett ED. *Haemophilus influenzae* infections in adults: Report of nine cases and a review of the literature. *Medicine (Baltimore)*. 1979;58(1):80-94.
- Garg P, Gupta R, Szalados JE. Bacterial pericarditis and tamponade due to nonencapsulated *Haemophilus influenzae* complicating a case of adult community-acquired pneumonia. *MedGenMed*. 2006;8(4):48.
- Varghese V, George JC. Purulent pericarditis caused by *Haemophilus influenzae* type B. *J Invasive Cardiol*. 2011;23(5):E110-2.
- Sink JD, Spray TL, Rankin JS. *Haemophilus influenzae* pericarditis. *Clin Cardiol*. 1982;5:547-9.
- Graham BS, Reiss TF, Gregory DW. Pericarditis associated with *Haemophilus influenzae* type B pneumonia and bacteremia in two adults. *Chest*. 1983;84(1):48-50.
- Imazio M, Brucato A, Barbieri A, Ferroni F, Maestroni S, Ligabue G, et al. Good prognosis for pericarditis with and without myocardial involvement: results from a multicenter, prospective cohort study. *Circulation*. 2013;128(1):42-9.