THE UNIVERSITY of EDINBURGH

Edinburgh Research Explorer

Emerging concepts in the management of pancreatic adenocarcinoma

Citation for published version:
Parks, R & Srinivasa, S 2019, 'Emerging concepts in the management of pancreatic adenocarcinoma', *Laparoscopic, Endoscopic and Robotic Surgery*. https://doi.org/10.1016/j.lers.2019.07.002

Digital Object Identifier (DOI):
10.1016/j.lers.2019.07.002

Link:
Link to publication record in Edinburgh Research Explorer

Document Version:
Version created as part of publication process; publisher's layout; not normally made publicly available

Published In:
Laparoscopic, Endoscopic and Robotic Surgery

General rights
Copyright for the publications made accessible via the Edinburgh Research Explorer is retained by the author(s) and / or other copyright owners and it is a condition of accessing these publications that users recognise and abide by the legal requirements associated with these rights.

Take down policy
The University of Edinburgh has made every reasonable effort to ensure that Edinburgh Research Explorer content complies with UK legislation. If you believe that the public display of this file breaches copyright please contact openaccess@ed.ac.uk providing details, and we will remove access to the work immediately and investigate your claim.

OPEN ACCESS

Download date: 23. Jul. 2021

Laparoscopic, Endoscopic and Robotic Surgery xxx (xxxx) xxx

Contents lists available at ScienceDirect

Laparoscopic, Endoscopic and Robotic Surgery

journal homepage: www.keaipublishing.com/en/journals/laparoscopic-endoscopic-and-robotic-surgery

Emerging concepts in the management of pancreatic ductal adenocarcinoma

Sanket Srinivasa [a], Rowan Parks [a, b, *]

[a] HPB Surgery, Royal Infirmary of Edinburgh, Edinburgh, UK
[b] Department of Clinical Surgery, University of Edinburgh, Edinburgh, UK

ARTICLE INFO

Article history:
Received 4 June 2019
Received in revised form
11 July 2019
Accepted 12 July 2019
Available online xxx

Keywords:
Pancreatic ductal adenocarcinoma
Pancreatic resection
Laparoscopic surgery
Robotic surgery

ABSTRACT

Pancreatic ductal adenocarcinoma is characterised by poor oncological outcomes with curative treatment only possible for a minority. Symptoms are dependent on the stage of the disease and location within the pancreas with constitutional decline often prominent. Patients require biochemical investigations and accurate imaging with CT to determine stage of disease and local resectability. CT-PET and endoscopic ultrasound are increasingly used preoperatively. Surgery remains the cornerstone of curative management and can be performed using minimally invasive approaches. Vascular resection and combination treatment with chemoradiotherapy are also utilised for suitable patients. Perioperative outcomes may be optimised using enhanced recovery pathways. Quality standards have been defined for individual clinicians and units to benchmark their clinical outcomes. The developments described hold promise in improving outcomes from pancreatic ductal adenocarcinoma.

© 2019 Sir Run Run Shaw Hospital affiliated to Zhejiang University School of Medicine. Published by Elsevier B.V. This is an open access article under the CC BY-NC-ND license (http://creativecommons.org/licenses/by-nc-nd/4.0/).

1. Introduction

Pancreatic ductal adenocarcinoma (PDAC) remains a lethal disease with annual mortality approaching the incidence.[1] Potentially curative treatment is possible only for a minority of patients, is resource-intensive and requires multidisciplinary management but provides the best option for improved outcomes. Although appreciable gains in survival are yet to be seen, there have been a number of recent advances in the management of PDAC. The aim of this review is to provide an overview of contemporary management of PDAC and expand upon newer trends and contentious areas pertaining to investigation and treatment.

2. Diagnosis & staging

2.1. Clinical presentation

Symptoms from PDAC are dependent on the stage of disease and location of the malignancy within the pancreas. Early stage disease is often asymptomatic or characterised by non-specific constitutional symptoms such as weight loss and anorexia. Symptoms can include abdominal or back pain - the latter often being a sign of coeliac plexus involvement and potential unresectability - and jaundice if malignancy in the head of pancreas causes biliary obstruction.[2] Painless jaundice remains a common mode of presentation. The lack of overt symptoms from malignancy in the body and tail often results in advanced malignancy by the time of diagnosis. Clinical signs of pancreatic malignancy may include jaundice, nutritional sequalae or abdominal findings such as a palpable gallbladder, ascites or presence of a Sister Mary Joseph nodule.

With the increasing recognition of pre-cancerous conditions such as intraductal papillary mucinous neoplasms (IPMN) and the widespread use of imaging, incidental diagnosis is becoming a commoner mode of presentation with the diagnosis made on the basis of imaging rather than clinical presentation.[3]

2.2. Laboratory investigations

Any patient suspected of having a pancreatic malignancy should have basic blood tests including full blood count, electrolytes, liver function tests and clotting function. These provide valuable information regarding the patient's current state and any acute issues that may need to be addressed, such as jaundice or anaemia. They also provide some indication of the patient's

* Corresponding author: HPB Surgery, Royal Infirmary of Edinburgh; Department of Clinical Surgery, University of Edinburgh, Edinburgh, UK.
E-mail address: r.w.parks@ed.ac.uk (R. Parks).

https://doi.org/10.1016/j.lers.2019.07.002
2468-9009/© 2019 Sir Run Run Shaw Hospital affiliated to Zhejiang University School of Medicine. Published by Elsevier B.V. This is an open access article under the CC BY-NC-ND license (http://creativecommons.org/licenses/by-nc-nd/4.0/).

Please cite this article as: Srinivasa S, Parks R, Emerging concepts in the management of pancreatic ductal adenocarcinoma, Laparoscopic, Endoscopic and Robotic Surgery, https://doi.org/10.1016/j.lers.2019.07.002

fitness for intervention. Tumour markers (CEA, CA 19-9, CgA) can also provide useful baseline information and help clarify diagnostic uncertainty, such as between adenocarcinoma and neuroendocrine tumours. There is increasing information that the CA 19-9 trend may be indicative of response to chemotherapy (see below) but it is important to note that since CA 19-9 is a blood group antigen, a percentage of any population (e.g. up to 35% of the black population) may not secrete it.[4,5]

2.3. Imaging

Although some patients will have an abdominal ultrasound as part of an initial evaluation of abdominal pain and jaundice, or due to clinical suspicion of gallstones, the diagnosis of probable PDAC is usually made by dedicated abdominal CT.[6,7] CT serves multiple purposes and remains the cornerstone of diagnosis, staging and pre-operative planning.[6] Multiphase, multidetector helical CT with three-dimensional reconstruction is the current gold-standard.[6] PDAC has abundant fibrous stroma and hypovascularity and thus enhances poorly compared to normal pancreatic parenchyma.[8] CT can evaluate the interface between a head of pancreas mass and its relationship to the superior mesenteric vein/portal vein (SMV/PV), superior mesenteric artery (SMA) and other vasculature (e.g. hepatic artery) as seen in Figs. 1 and 2.[1] Similarly, body/tail masses can be evaluated for their relationship to the coeliac trunk and left adrenal gland. Involvement of local structures represents relative/absolute contraindications to resection and can also provide valuable information for planning an extended resection when appropriate. Moreover, CT can identify clinically important anatomical variants such as a replaced right hepatic artery or coeliac artery stenosis which can impact on subsequent surgical intervention.

CT can also help determine if distant metastases (e.g. liver/lung) or lymph nodes outside the field of resection are present, and thus stage the patient accurately. A meta-analysis by Bipat et al reported sensitivity and specificity rates for helical CT in tumour detection of 91% and 85% respectively, with slightly lower values of 81% and 82% for determining resectability.[7] However, CT is not ideal for detecting small peritoneal nodules or lymph node metastases in normal-sized nodes.[8] In addition, its diagnostic accuracy in the preoperative assessment of extraregional lymph node metastases is low due to poor sensitivity.[9]

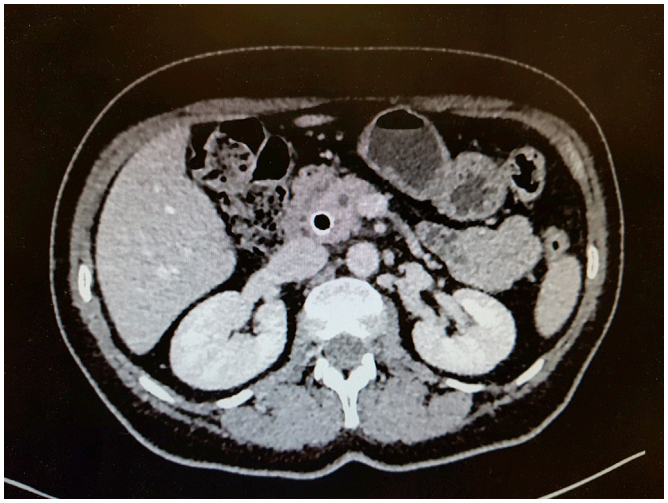

Fig. 2 Mass in head of pancreas involving SMV/PV.
CT showing an uncinate mass with abutment of PV (Borderline resectable). The patient underwent pancreaticoduodenectomy with *en bloc* PV resection and reconstruction.

MRI is not routinely undertaken in patients with PDAC but may be used to assess the pancreatic parenchyma and pancreatic duct when evaluating patients with IPMN.[8,10] Dedicated liver MRI can be used to evaluate indeterminate liver lesions to exclude metastases.[11] Some institutions also employ either selective or routine staging laparoscopy to diagnose occult peritoneal disease or metastases not visible on imaging.[12,13] The diagnostic yield of this is increasingly small due to constant improvements in imaging technology and the cumulative accuracy of multiple investigations of varying modalities in an individual patient.[12,14] However, diagnostic laparoscopy has been shown to decrease the rate of futile laparotomies and is still employed in some institutions.[13,15]

In a recent study, fluorodeoxyglucose-positron emission tomography CT (FDG-PET CT) (see Fig. 3) was shown to provide more accurate staging information preoperatively and changed decision making in 45% of patients.[16] It has been shown to be cost effective by reducing the number of patients undergoing potentially unnecessary surgery and was shown to detect CT-occult metastases in an extra 20% of patients who had otherwise been fully

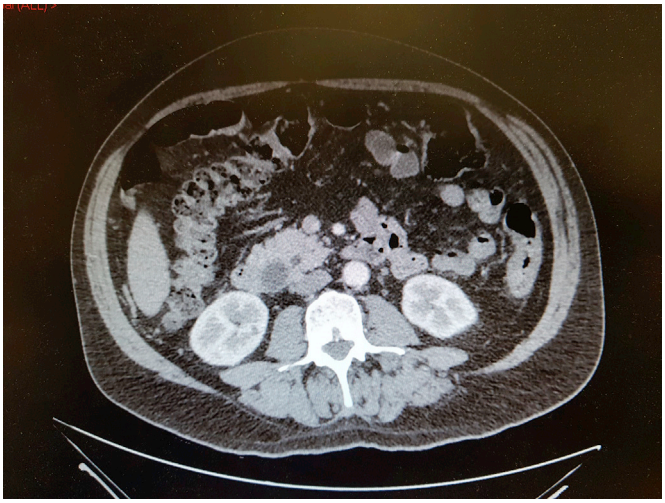

Fig. 1 Mass in head of pancreas with preserved PV/SMV fat-plane.
CT showing an ampullary mass with a clear fat plane around the SMV. This patient underwent routine pancreaticoduodenectomy.

Fig. 3 PET-avid mass in head of pancreas.
FDG-PET CT showing avid head of pancreas mass.

Please cite this article as: Srinivasa S, Parks R, Emerging concepts in the management of pancreatic ductal adenocarcinoma, Laparoscopic, Endoscopic and Robotic Surgery, https://doi.org/10.1016/j.lers.2019.07.002

investigated.[16] Thus FDG-PET CT can allow for more prudent patient selection and may decrease the number of patients who may have early distant recurrence due to undiagnosed occult metastases. In the United Kingdom, the routine use of FDG-PET CT has now been recommended for all patients with PDAC being considered for treatment with curative intent in recently published guidelines.[17] FDG-PET CT has also been described as providing a dynamic indicator of response to chemotherapy in patients undergoing neoadjuvant treatment and can be a proxy of complete pathological response if previously metabolically active disease is not visible on repeat imaging after treatment.[4] It is important to note, however, that the diagnostic accuracy of FDG-PET CT suffers in patients with diabetes, and obtaining an extra investigation may possibly cause delays in providing definitive treatment.[18,19]

2.4. Endoscopic ultrasound

Historically, the diagnosis of PDAC was made radiologically and suitable patients were recommended for surgery without a tissue diagnosis.[20] A false-positive rate due to benign mass-forming chronic pancreatitis was previously accepted despite the relatively high morbidity and mortality associated with surgery.[20] This was due to the difficulties in obtaining tissue with the retroperitoneal location of the pancreas and concerns of inadvertent organ/vascular injury and seeding malignancy. However, endoscopic ultrasound (EUS) has overcome these problems and is now commonly employed to visualise pancreatic masses. It is particularly useful for head of pancreas lesions as it can provide complementary information to CT by assessing the relationship of the mass to the SMV/PV or SMA.[21] Moreover, EUS can be used to get either cytological or histological information using fine needle aspirate or core biopsies to obtain a definitive diagnosis before proceeding to surgery.[22] It can also be used to sample suspicious lymph nodes which may be out of the resection field and therefore help determine resectability.[22] As the use of neoadjuvant chemotherapy becomes increasingly common, preoperative diagnosis of cancer using EUS is crucial and an attempt at obtaining a tissue diagnosis prior to considering major pancreatic resection in all patients would seem prudent.[17]

3. Treatment options

Depending on the mode of diagnosis and patient symptoms, the initial management of patients with PDAC can involve treatment of sepsis, amelioration of jaundice and/or appropriate palliation. Palliative management includes optimisation of nutrition and the use of pancreatic enzyme supplements, treatment of symptoms (e.g. pain, jaundice) as well as consideration of systemic chemotherapy.[23] Since jaundice is usually caused by distal biliary obstruction, endoscopic retrograde cholangiopancreatography (ERCP) is the preferred modality to relieve jaundice whilst also attempting tissue diagnosis with brushings.[17] Since preoperative biliary drainage (either with ERCP or with percutaneous biliary dilatation) has been associated with an increased incidence of postoperative complications, patients with jaundice without sepsis, major electrolyte derangement or renal impairment, who are otherwise good operative candidates and have resectable disease, are excellent candidates for unstented pancreaticoduodenectomy (PD).[17,24] This requires considerable logistical capabilities within an institution and can mean that obtaining all investigations (e.g. FDG-PET CT and EUS-guided biopsy) in a short time-frame may be challenging.[17] Moreover, it may only allow minimal time for the patient to comprehend the magnitude of the treatment proposed but has been shown to provide superior postoperative outcomes.[24,25]

3.1. Pancreatic resection

A minority of patients are suitable for treatment with curative intent.[1] The majority of patients are not suitable due to advanced age and significant comorbidity which may be a contra-indication for major pancreatic resection, or because the disease has either metastasised or is locally unresectable.[1] For suitable patients, the surgical options are generally PD or distal/subtotal pancreatectomy. A small number of patients require total pancreatectomy or central pancreatectomy. Most patients are offered post-operative chemotherapy depending on final histology and post-operative progress.[1] Surgery is associated with a morbidity rate of up to 50%, a 20% risk of major complications and 5% risk of 90-day mortality.[26] For true head of pancreas adenocarcinoma - as compared to distal cholangiocarcinoma or duodenal carcinoma - the risk of a microscopically positive margin in patients deemed to be resectable remains high.[27]

There have been a number of exciting developments in surgical management. Minimally invasive pancreatic resections - either laparoscopic or robotic - have begun to be implemented worldwide. Laparoscopic distal pancreatectomy has been shown to be associated with improved short term outcomes, decreased blood loss and decreased complications.[28–30] It has also been shown to be cost effective and provides non-inferior oncological outcomes.[28–30] Laparoscopic PD has been reported by multiple centres worldwide.[31–34] There is a steep learning curve but in expert centres, has been reported to be associated with improved short term outcomes with comparable long term results.[31–34] Advocates of laparoscopic PD recommend careful case selection and acknowledge the potential difficulties of completing the operation laparoscopically with one intermediate option being to consider hybrid (laparoscopic dissection; open reconstruction) or hand-assisted approaches.[32,35–37] The only multi-centre trial comparing laparoscopic to open PD was terminated early due to a higher number of deaths in the laparoscopic arm.[38] Another alternative has been to employ a robotic approach which can provide multiple hands and greater degrees of freedom compared to the relatively restricted laparoscopic working angles.[39,40] Published evidence on robotic pancreatic surgery suggests that equivalent outcomes to laparoscopic surgery can be obtained but with a less difficult learning curve, which is manifest in a decreased rate of conversion to an open procedure.[41] At present, minimally invasive PD should be considered to be in the evaluation stage and should be performed within a closely monitored system to avoid undue harm, whilst laparoscopic distal pancreatectomy can be considered to be best practice depending on surgeon and patient factors.

Open pancreatic resections have also seen some changes proposed. The “artery-first” approach - early control and dissection of the SMA to prove resectability - has been shown to improve the likelihood of obtaining a negative resection margin.[42] Although it is unlikely to improve outcomes in all patients requiring PD, it is a prudent approach for cancers affecting the uncinate process. Distal/subtotal pancreatectomy has also seen the evolution of anterior and posterior radical anterograde modular pancreaticosplenectomy (RAMPS).[42,43] This operation fundamentally assesses whether pancreatic lesions are exophytic and compromise the pancreatic capsule. The procedure involves early vascular control with medial to lateral dissection and a wider margin. Posterior RAMPS encompasses the left adrenal gland and skeletonises Gerota's fascia *en bloc* whereas anterior RAMPS goes behind the anterior renal fascia. The technique is considered analogous to a total mesorectal excision for rectal cancer and aims to increase the likelihood of a negative tangential margin and an increased lymph node count.[44] Initial results from the pioneering centre and a subsequent systematic

Please cite this article as: Srinivasa S, Parks R, Emerging concepts in the management of pancreatic ductal adenocarcinoma, Laparoscopic, Endoscopic and Robotic Surgery, https://doi.org/10.1016/j.lers.2019.07.002

review have shown improved lymph node count, a higher rate of negative margins and decreased local recurrence.[44–46]

3.2. Vascular resection

Poor oncological outcomes from PDAC following surgery relate to both local and distant recurrence. To overcome the problem of local recurrence, some centres have advocated the use of vascular resection to minimise the risk of a positive margin.[47] Whilst the role of venous resection is well-established and thought to be a useful strategy, albeit with a higher rate of perioperative morbidity, some centres practice arterial resection and reconstruction.[4,47,48] Results published from high-volume centres have reported a not insignificant mortality rate but with impressive margin-negative resection rates and overall survival.[4,48] Although this has mainly been reported in the context of PD, some centres have reported coeliac trunk resection for body of pancreas malignancy.[49] The hepatic arterial inflow is then dependent on retrograde flow from the gastroduodenal artery or is supplemented with formal reconstruction or a jump graft. Others have advocated skeletonising major vessels to obtain negative margins though in the case of the SMA, this has been shown to cause debilitating diarrhoea.[50]

3.3. Neoadjuvant chemoradiotherapy

The use of neoadjuvant chemoradiotherapy represents a major paradigm shift in the management of PDAC. Traditional management has consisted of surgery for resectable patients followed by adjuvant chemotherapy if appropriate.[51] However, the definition of resectability is increasingly viewed as a spectrum which includes borderline resectable and locally advanced disease, as determined by preoperative imaging.[52,53] A number of studies have reported trialling combination chemotherapy and radiotherapy for patients with borderline resectable or locally advanced disease in an attempt to downstage the disease before attempting trial dissection.[4,54–56] The rationale for this strategy is akin to management of other solid organ neoplasms such as stomach and rectal cancer. It allows patients to receive chemotherapy upfront, rather than being unable to receive it postoperatively due to complications or a protracted recovery.[56,57] Moreover, it may prevent futile surgery in patients who progress whilst receiving chemotherapy thus manifesting more aggressive tumour biology.[56,57] Chemotherapy may also decrease occult systemic tumour burden and decrease the rate of metastatic recurrence.[57] The role of radiotherapy is thought to sterilise the difficult operative margins (SMA, retroperitoneum) and decrease the risk of local recurrence.[54] Conversely, since PDAC is inherently chemoresistant, there is a risk that a period of ultimately ineffectual chemotherapy may lead to patients missing a vital therapeutic window and radiotherapy may increase the perioperative morbidity due to deleterious effects on anastomotic healing.[58,59] Nonetheless, a number of centres have reported very impressive survival with a high margin-negative resection rate and acceptable perioperative morbidity when evaluating neoadjuvant chemoradiotherapy followed by trial dissection.[4,54,55] Intriguingly, these studies suggest that radiological assessment of pancreatic lesions may not be valid after neoadjuvant treatment as imaging is unable to differentiate between persistent cancer and treatment-induced fibrosis.[4,54] Trial dissection in all patients without metastatic disease is advocated. A potential role for FDG-PET CT and monitoring with CA 19-9 measurements has been suggested in this context.[4]

With the encouraging results reported by some centres for borderline resectable and locally advanced disease, the next question to be addressed is whether patients with resectable cancer at presentation should also be treated with neoadjuvant chemoradiotherapy.[60] Despite the concerns of missing therapeutic windows, the drop-off in patients proceeding to surgery due to adverse effects and the physical toll of neoadjuvant treatment regimens, recent evidence suggests that neoadjuvant chemoradiotherapy followed by surgery may offer superior survival compared to surgery followed by chemotherapy.[60,61] These results are affected by case-mix, perioperative outcomes as well as the choice of treatment regimens, but this remains an area in flux and likely to see major changes in treatment pathways.

4. Perioperative care

Modern advances in perioperative care have challenged long-standing surgical dogma such as enforced starvation and bed rest. Enhanced recovery protocols are an important component of providing benchmarked surgical care. This has been evaluated in detail for patients undergoing pancreatic resection with recommendations made for many aspects of perioperative care.[62] These include an emphasis on preoperative counselling and nutritional optimisation as well as avoidance of prolonged fasting. The authors recommend regional anaesthesia wherever possible and maintenance of neutral fluid balance perioperatively. Routine use of nasogastric tubes is discouraged with early feeding and mobilisation recommended.

Two areas of ongoing discussion in perioperative management include the use of perianastomotic drains and somatostatin analogues. Whilst some surgeons advocate complete avoidance of drains, the published literature is confounded by multiple differences such as the characteristics of the pancreas gland (e.g soft versus firm) and whether the pancreatic duct is dilated.[63,64] Moreover, whilst some studies have shown equivalent outcomes in patients who have not had a drain placed, one multicentre trial was terminated prematurely due to a higher rate of mortality in the no-drain group.[65] As such, most centres appear to favour the default use of drains with exclusion in selected cases. The timing of drain removal has also been studied with recommendations towards early removal (24–72 hours) based on drain amylase levels.[66,67]

Somatostatin analogues reduce pancreatic secretions and have thus been investigated for their ability to decrease post-operative pancreatic fistula (POPF). The evidence is, however, conflicting. One single-centre randomised trial showed that pasireotide decreased the rate of POPF but these results have not been replicated in other settings.[68–70] In a retrospective review of factors predicting POPF, the use of somatostatin analogues was shown to be associated with a higher risk of POPF.[69] However, this may be a reflection of surgeons using somatostatin analogues prophylactically in higher risk cases. At present, the role of somatostatin analogues remains undefined and requires further study in the context of high risk cases such as those with a soft pancreas and non-dilated pancreatic duct.

5. Quality standards

PDAC remains an uncommon disease. As mentioned above, the number of patients who are suitable for treatment with curative intent is even smaller. As such, most centres and individual surgeons do not have extensive experience in this area. Centralisation has been proposed to overcome some of these challenges as correlation between volume and outcome has been demonstrated for major pancreatic resections.[71,72] However, the relationship between surgeon and institutional volume and outcome is complex. Cumulative institutional experience is thought to be most important to foster collective knowledge and decrease the likelihood of failure to rescue.[73] However, without formal legislation and due to

Please cite this article as: Srinivasa S, Parks R, Emerging concepts in the management of pancreatic ductal adenocarcinoma, Laparoscopic, Endoscopic and Robotic Surgery, https://doi.org/10.1016/j.lers.2019.07.002

local geographical factors, population density and organisation of health services, centralisation may be impractical or unnecessary in some settings.[74] Moreover, since the volume of patients with PDAC is ultimately dependent on the size of the population served, some settings are unlikely to ever have high volume units.[74] Thus, it may be more important to focus on improving the quality of care provided by improving available infrastructure and committing to upholding quality standards in PDAC care.[75] In a recent study of this topic, a number of standards have been proposed relating to timely diagnosis and provision of multidisciplinary care with clearly defined key performance indicators.[75]

6. Conclusion

PDAC remains difficult to treat. Over the last generation, perioperative outcomes from surgery have improved substantially but without significant gains in long term survival. The advances in imaging technology and emergence of EUS have allowed for more accurate diagnosis and staging. The changes in surgical approach and a potential paradigm shift in treatment sequencing with greater use of chemoradiotherapy represent important avenues to pursue further improvement in oncological outcomes.

Conflicts of interest

None.

References

1. Hidalgo M. Pancreatic cancer. *N Engl J Med*. 2010;362(17):1605–1617.
2. Kelsen DP, Portenoy R, Thaler H, Tao Y, Brennan M. Pain as a predictor of outcome in patients with operable pancreatic carcinoma. *Surgery*. 1997;122(1):53–59.
3. Takeda Y, Saiura A, Takahashi Y, et al. Asymptomatic pancreatic cancer: does incidental detection impact long-term outcomes? *J Gastrointest Surg*. 2017;21(8):1287–1295.
4. Truty MJ, Kendrick ML, Nagorney DM, et al. Factors predicting response, perioperative outcomes, and survival following total neoadjuvant therapy for borderline/locally advanced pancreatic cancer. *Ann Surg*. 2019 [Publish Ahead of Print]. https://doi.org/10.1097/SLA.0000000000003284. PMID: 30946090.
5. Orntoft TF, Holmes EH, Johnson P, Hakomori S, Clausen H. Differential tissue expression of the Lewis blood group antigens: enzymatic, immunohistologic, and immunochemical evidence for Lewis a and b antigen expression in Le(a-b-) individuals. *Blood*. 1991;77(6):1389–1396.
6. Callery MP, Chang KJ, Fishman EK, Talamonti MS, Traverso LW, Linehan DC. Pretreatment assessment of resectable and borderline resectable pancreatic cancer: expert consensus statement. *Ann Surg Oncol*. 2009;16(7):1727–1733.
7. Bipat S, Phoa SS, van Delden OM, et al. Ultrasonography, computed tomography and magnetic resonance imaging for diagnosis and determining resectability of pancreatic adenocarcinoma: a meta-analysis. *J Comput Assist Tomogr*. 2005;29(4):438–445.
8. Hanbidge AE. Cancer of the pancreas: the best image for early detection–CT, MRI, PET or US? *Can J Gastroenterol*. 2002;16(2):101–105.
9. Tseng DS, van Santvoort HC, Fegrachi S, et al. Diagnostic accuracy of CT in assessing extra-regional lymphadenopathy in pancreatic and peri-ampullary cancer: a systematic review and meta-analysis. *Surg Oncol*. 2014;23(4):229–235.
10. The European Study Group on Cystic Tumours of the Pancreas. European evidence-based guidelines on pancreatic cystic neoplasms. *Gut*. 2018;67(5):789–804.
11. Elsayes KM, Leyendecker JR, Menias CO, et al. MRI characterization of 124 CT-indeterminate focal hepatic lesions: evaluation of clinical utility. *HPB (Oxford)*. 2007;9(3):208–215.
12. De Rosa A, Cameron IC, Gomez D. Indications for staging laparoscopy in pancreatic cancer. *HPB (Oxford)*. 2016;18(1):13–20.
13. Allen VB, Gurusamy KS, Takwoingi Y, Kalia A, Davidson BR. Diagnostic accuracy of laparoscopy following computed tomography (CT) scanning for assessing the resectability with curative intent in pancreatic and periampullary cancer. *Cochrane Database Syst Rev*. 2016;7:Cd009323.
14. Mayo SC, Austin DF, Sheppard BC, Mori M, Shipley DK, Billingsley KG. Evolving preoperative evaluation of patients with pancreatic cancer: does laparoscopy have a role in the current era? *J Am Coll Surg*. 2009;208(1):87–95.
15. Schnelldorfer T, Gagnon AI, Birkett RT, Reynolds G, Murphy KM, Jenkins RL. Staging laparoscopy in pancreatic cancer: a potential role for advanced laparoscopic techniques. *J Am Coll Surg*. 2014;218(6):1201–1206.
16. Ghaneh P, Hanson R, Titman A, et al. PET-PANC: multicentre prospective diagnostic accuracy and health economic analysis study of the impact of combined modality 18fluorine-2-fluoro-2-deoxy-d-glucose positron emission tomography with computed tomography scanning in the diagnosis and management of pancreatic cancer. *Health Technol Assess*. 2018;22(7):1–114.
17. O'Reilly D, Fou L, Hasler E, et al. Diagnosis and management of pancreatic cancer in adults: a summary of guidelines from the UK National Institute for Health and Care Excellence. *Pancreatology*. 2018;18(8):962–970.
18. Jahromi AH, Fallahzadeh MK, Takalkar A, Sheng J, Zibari G, Amiri HS. Impact of plasma glucose level at the time of fluorodeoxyglucose administration on the accuracy of FDG-PET/CT in the diagnosis of pancreatic lesions. *Int J Endocrinol Metab*. 2014;12(4), e16429.
19. Surasi DS, Bhambhvani P, Baldwin JA, Almodovar SE, O'Malley JP. 18F-FDG PET and PET/CT patient preparation: a review of the literature. *J Nucl Med Technol*. 2014;42(1):5–13.
20. Fitzgerald PJ, Fortner JG, Watson RC, et al. The value of diagnostic aids in detecting pancreas cancer. *Cancer*. 1978;41(3):868–879.
21. DeWitt J, Devereaux B, Chriswell M, et al. Comparison of endoscopic ultrasonography and multidetector computed tomography for detecting and staging pancreatic cancer. *Ann Intern Med*. 2004;141(10):753–763.
22. Yoshinaga S, Suzuki H, Oda I, Saito Y. Role of endoscopic ultrasound-guided fine needle aspiration (EUS-FNA) for diagnosis of solid pancreatic masses. *Dig Endosc*. 2011;23(Suppl. 1):29–33.
23. Fazal S, Saif MW. Supportive and palliative care of pancreatic cancer. *JOP*. 2007;8(2):240–253.
24. van der Gaag NA, Rauws EA, van Eijck CH, et al. Preoperative biliary drainage for cancer of the head of the pancreas. *N Engl J Med*. 2010;362(2):129–137.
25. Otutaha B, Srinivasa S, Koea J. Patient information needs in upper gastrointestinal cancer: what patients and their families want to know. *ANZ J Surg*. 2019;89(1–2):20–24.
26. Ho CK, Kleeff J, Friess H, Büchler MW. Complications of pancreatic surgery. *HPB (Oxford)*. 2005;7(2):99–108.
27. Verbeke CS, Leitch D, Menon KV, McMahon MJ, Guillou PJ, Anthoney A. Redefining the R1 resection in pancreatic cancer. *Br J Surg*. 2006;93(10):1232–1237.
28. de Rooij T, van Hilst J, van Santvoort H, et al. Minimally invasive versus open distal pancreatectomy (LEOPARD): a multicenter patient-blinded randomized controlled trial. *Ann Surg*. 2019;269(1):2–9.
29. van Hilst J, de Rooij T, Klompmaker S, et al. Minimally invasive versus open distal pancreatectomy for ductal adenocarcinoma (DIPLOMA): a pan-European propensity score matched study. *Ann Surg*. 2019;269(1):10–17.
30. Søreide K, Olsen F, Nymo LS, Kleive D, Lassen K. A nationwide cohort study of resection rates and short-term outcomes in open and laparoscopic distal pancreatectomy. *HPB (Oxford)*. 2018;21(6):669–678.
31. Poves I, Burdio F, Morato O, et al. Comparison of perioperative outcomes between laparoscopic and open approach for pancreatoduodenectomy: the PADULAP randomized controlled trial. *Ann Surg*. 2018;268(5):731–739.
32. Palanivelu C, Rajan PS, Rangarajan M, et al. Evolution in techniques of laparoscopic pancreaticoduodenectomy: a decade long experience from a tertiary center. *J Hepatobiliary Pancreat Surg*. 2009;16(6):731–740.
33. Palanivelu C, Senthilnathan P, Sabnis SC, et al. Randomized clinical trial of laparoscopic versus open pancreatoduodenectomy for periampullary tumours. *Br J Surg*. 2017;104(11):1443–1450.
34. Croome KP, Farnell MB, Que FG, et al. Total laparoscopic pancreaticoduodenectomy for pancreatic ductal adenocarcinoma: oncologic advantages over open approaches? *Ann Surg*. 2014;260(4):633–648.
35. Kendrick ML, Cusati D. Total laparoscopic pancreaticoduodenectomy: feasibility and outcome in an early experience. *Arch Surg*. 2010;145(1):19–23.
36. Speicher PJ, Nussbaum DP, White RR, et al. Defining the learning curve for team-based laparoscopic pancreaticoduodenectomy. *Ann Surg Oncol*. 2014;21(12):4014–4019.
37. Wang YF, Bergman S, Piedimonte S, Vanounou T. Bridging the gap between open and minimally invasive pancreaticoduodenectomy: the hybrid approach. *Can J Surg*. 2014;57(4):263–270.
38. van Hilst J, de Rooij T, Bosscha K, et al. Laparoscopic versus open pancreatoduodenectomy for pancreatic or periampullary tumours (LEOPARD-2): a multicentre, patient-blinded, randomised controlled phase 2/3 trial. *Lancet Gastroenterol Hepatol*. 2019;4(3):199–207.
39. Caba Molina D, Lambreton F, Arrangoiz Majul R. Trends in robotic pancreaticoduodenectomy and distal pancreatectomy. *J Laparoendosc Adv Surg Tech A*. 2019;29(2):147–151.
40. Zureikat AH, Moser AJ, Boone BA, Bartlett DL, Zenati M, Zeh H. 250 robotic pancreatic resections: safety and feasibility. *Ann Surg*. 2013;258(4):554–562.
41. Ielpo B. Laparoscopic versus robotic distal pancreatectomy. *Laparoscopic Surg*. 2018;2(4).
42. Ironside N, Barreto SG, Loveday B, Shrikhande SV, Windsor JA, Pandanaboyana S. Meta-analysis of an artery-first approach versus standard pancreatoduodenectomy on perioperative outcomes and survival. *Br J Surg*. 2018;105(6):628–636.
43. Strasberg SM, Drebin JA, Linehan D. Radical antegrade modular pancreatosplenectomy. *Surgery*. 2003;133(5):521–527.
44. Cao F, Li J, Li A, Li F. Radical antegrade modular pancreatosplenectomy versus standard procedure in the treatment of left-sided pancreatic cancer: a systemic review and meta-analysis. *BMC Surg*. 2017;17(1):67.
45. Strasberg SM, Linehan DC, Hawkins WG. Radical antegrade modular pancreatosplenectomy procedure for adenocarcinoma of the body and tail of the

Please cite this article as: Srinivasa S, Parks R, Emerging concepts in the management of pancreatic ductal adenocarcinoma, Laparoscopic, Endoscopic and Robotic Surgery, https://doi.org/10.1016/j.lers.2019.07.002

ARTICLE IN PRESS

pancreas: ability to obtain negative tangential margins. *J Am Coll Surg*. 2007;204(2):244–249.
46. Mitchem JB, Hamilton N, Gao F, Hawkins WG, Linehan DC, Strasberg SM. Long-term results of resection of adenocarcinoma of the body and tail of the pancreas using radical antegrade modular pancreatosplenectomy procedure. *J Am Coll Surg*. 2012;214(1):46–52.
47. Chua TC, Saxena A. Extended pancreaticoduodenectomy with vascular resection for pancreatic cancer: a systematic review. *J Gastrointest Surg*. 2010;14(9):1442–1452.
48. Mollberg N, Rahbari NN, Koch M, et al. Arterial resection during pancreatectomy for pancreatic cancer: a systematic review and meta-analysis. *Ann Surg*. 2011;254(6):882–893.
49. Klompmaker S, van Hilst J, Gerritsen SL, et al. Outcomes after distal pancreatectomy with celiac Axis resection for pancreatic cancer: a pan-European retrospective cohort study. *Ann Surg Oncol*. 2018;25(5):1440–1447.
50. Hackert T, Strobel O, Michalski CW, et al. The TRIANGLE operation - radical surgery after neoadjuvant treatment for advanced pancreatic cancer: a single arm observational study. *HPB (Oxford)*. 2017;19(11):1001–1007.
51. Neoptolemos JP, Stocken DD, Friess H, et al. A randomized trial of chemoradiotherapy and chemotherapy after resection of pancreatic cancer. *N Engl J Med*. 2004;350(12):1200–1210.
52. Bockhorn M, Uzunoglu FG, Adham M, et al. Borderline resectable pancreatic cancer: a consensus statement by the international study group of pancreatic surgery (ISGPS). *Surgery*. 2014;155(6):977–988.
53. Evans DB, George B, Tsai S. Non-metastatic pancreatic cancer: resectable, borderline resectable, and locally advanced-definitions of increasing importance for the optimal delivery of multimodality therapy. *Ann Surg Oncol*. 2015;22(11):3409–3413.
54. Ferrone CR, Marchegiani G, Hong TS, et al. Radiological and surgical implications of neoadjuvant treatment with FOLFIRINOX for locally advanced and borderline resectable pancreatic cancer. *Ann Surg*. 2015;261(1):12–17.
55. Sadot E, Duossot A, O'Reilly EM, et al. FOLFIRINOX induction therapy for stage III pancreatic adenocarcinoma. *Ann Surg Oncol*. 2015;22(11):3512–3521.
56. Jang JY, Han Y, Lee H, et al. Oncological benefits of neoadjuvant chemoradiation with gemcitabine versus upfront surgery in patients with borderline resectable pancreatic cancer: a prospective, randomized, open-label, multicenter phase 2/3 trial. *Ann Surg*. 2018;268(2):215–222.
57. Abrams RA, Lowy AM, O'Reilly EM, Wolff RA, Picozzi VJ, Pisters PW. Combined modality treatment of resectable and borderline resectable pancreas cancer: expert consensus statement. *Ann Surg Oncol*. 2009;16(7):1751–1756.
58. Stathis A, Moore MJ. Advanced pancreatic carcinoma: current treatment and future challenges. *Nat Rev Clin Oncol*. 2010;7(3):163–172.
59. Noyes RD, Weiss SM, Krall JM, et al. Surgical complications of intraoperative radiation therapy: the radiation therapy oncology group experience. *J Surg Oncol*. 1992;50(4):209–215.
60. Bradley A, Van Der Meer R. Upfront surgery versus neoadjuvant therapy for resectable pancreatic cancer: systematic review and bayesian network meta-analysis. *Sci Rep*. 2019;9:4354.
61. Unno M, Motoi F, Matsuyama Y, et al. Randomized phase II/III trial of neoadjuvant chemotherapy with gemcitabine and S-1 versus upfront surgery for resectable pancreatic cancer (Prep-02/JSAP-05). *J Clin Oncol*. 2019;49:190–194.
62. Lassen K, Coolsen MM, Slim K, et al. Guidelines for perioperative care for pancreaticoduodenectomy: enhanced recovery after surgery (ERAS®) society recommendations. *World J Surg*. 2013;37(2):240–258.
63. Pratt WB, Callery MP, Vollmer Jr CM. Risk prediction for development of pancreatic fistula using the ISGPF classification scheme. *World J Surg*. 2008;32(3):419–428.
64. Correa-Gallego C, Brennan MF, D'Angelica M, et al. Operative drainage following pancreatic resection: analysis of 1122 patients resected over 5 years at a single institution. *Ann Surg*. 2013;258(6):1051–1058.
65. Van Buren 2nd G, Bloomston M, Hughes SJ, et al. A randomized prospective multicenter trial of pancreaticoduodenectomy with and without routine intraperitoneal drainage. *Ann Surg*. 2014;259(4):605–612.
66. Bassi C, Molinari E, Malleo G, et al. Early versus late drain removal after standard pancreatic resections: results of a prospective randomized trial. *Ann Surg*. 2010;252(2):207–214.
67. Ven Fong Z, Correa-Gallego C, Ferrone CR, et al. Early drain removal–the middle ground between the drain versus No drain debate in patients undergoing pancreaticoduodenectomy: a prospective validation study. *Ann Surg*. 2015;262(2):378–383.
68. Allen PJ, Gonen M, Brennan MF, et al. Pasireotide for postoperative pancreatic fistula. *N Engl J Med*. 2014;370(21):2014–2022.
69. Ecker BL, McMillan MT, Asbun HJ, et al. Characterization and optimal management of high-risk pancreatic anastomoses during pancreatoduodenectomy. *Ann Surg*. 2018;267(4):608–616.
70. Adiamah A, Arif Z, Berti F, Singh S, Laskar N, Gomez D. The use of prophylactic somatostatin therapy following pancreaticoduodenectomy: a meta-analysis of randomised controlled trials. *World J Surg*. 2019;43(7):1788–1801.
71. Eppsteiner RW, Csikesz NG, McPhee JT, Tseng JF, Shah SA. Surgeon volume impacts hospital mortality for pancreatic resection. *Ann Surg*. 2009;249(4):635–640.
72. Gooiker GA, van Gijn W, Wouters MW, et al. Systematic review and meta-analysis of the volume–outcome relationship in pancreatic surgery. *Br J Surg*. 2011;98(4):485–494.
73. Amini N, Spolverato G, Kim Y, Pawlik TM. Trends in hospital volume and failure to rescue for pancreatic surgery. *J Gastrointest Surg*. 2015;19(9):1581–1592.
74. Wylie N, Hider P, Armstrong D, et al. The volume, cost and outcomes of pancreatic resection in a regional centre in New Zealand. *ANZ J Surg*. 2018;88(12):1258–1262.
75. Maharaj AD, Ioannou L, Croagh D, et al. Monitoring quality of care for patients with pancreatic cancer: a modified Delphi consensus. *HPB (Oxford)*. 2019;21(4):444–455.

Please cite this article as: Srinivasa S, Parks R, Emerging concepts in the management of pancreatic ductal adenocarcinoma, Laparoscopic, Endoscopic and Robotic Surgery, https://doi.org/10.1016/j.lers.2019.07.002