



THE UNIVERSITY *of* EDINBURGH

Edinburgh Research Explorer

Cerebellar amyloid-beta plaques: How frequent are they, and do they influence 18F-Florbetaben SUVR?

Citation for published version:

Catafau, AM, Bullich, S, Seibyl, JP, Barthel, H, Ghetti, B, Leverenz, J, Ironside, J, Schulz-Schaefer, WJ, Hoffmann, A & Sabri, O 2016, 'Cerebellar amyloid-beta plaques: How frequent are they, and do they influence 18F-Florbetaben SUVR?', *Journal of Nuclear Medicine*.
<https://doi.org/10.2967/jnumed.115.171652>

Digital Object Identifier (DOI):

[10.2967/jnumed.115.171652](https://doi.org/10.2967/jnumed.115.171652)

Link:

[Link to publication record in Edinburgh Research Explorer](#)

Document Version:

Peer reviewed version

Published In:

Journal of Nuclear Medicine

Publisher Rights Statement:

This research was originally published in JNM. Cerebellar amyloid-beta plaques: How frequent are they, and do they influence 18F-Florbetaben SUVR?
JNM. 2016;vol:pp–pp. © by the Society of Nuclear Medicine and Molecular Imaging, Inc.

General rights

Copyright for the publications made accessible via the Edinburgh Research Explorer is retained by the author(s) and / or other copyright owners and it is a condition of accessing these publications that users recognise and abide by the legal requirements associated with these rights.

Take down policy

The University of Edinburgh has made every reasonable effort to ensure that Edinburgh Research Explorer content complies with UK legislation. If you believe that the public display of this file breaches copyright please contact openaccess@ed.ac.uk providing details, and we will remove access to the work immediately and investigate your claim.



Cerebellar amyloid-beta plaques: How frequent are they, and do they influence ^{18}F -Florbetaben SUVR?

Ana M. Catafau¹, Santiago Bullich¹, John P. Seibyl², Henryk Barthel³, Bernardino Ghetti⁴, James Leverenz⁵, James W. Ironside⁶, Walter J. Schulz-Schaefer⁷, Anja Hoffmann^{8*}, Osama Sabri^{3*}

1. Piramal Imaging GmbH, Berlin, Germany.

2. Molecular Neuroimaging, New Haven, CT, United States.

3. University of Leipzig, Leipzig, Germany.

4. Indiana University School of Medicine, Indianapolis, IN, United States.

5. VA-Puget Sound Health Care System and University of Washington, Seattle, WA, United States.

6. University of Edinburgh, Edinburgh, United Kingdom.

7. Georg-August University Göttingen, Göttingen, Germany.

8. Bayer Pharma AG, Berlin, Germany.

**Contributed equally*

Word Count: 5116

Short running title: Cerebellar amyloid and Florbetaben SUVR

Corresponding author

Dr. Ana M Catafau

Funding

The trial was funded by Bayer Pharma AG, Berlin (Germany), and Piramal Imaging S.A., Matran (Switzerland).

ABSTRACT

Standardized uptake value ratios (SUVR) are used for relative quantification of ^{18}F -Florbetaben (FBB) scans. Cerebellar cortex can be used as reference region for quantification. However, cerebellar amyloid-beta ($\text{A}\beta$) plaques may be present in Alzheimer disease (AD). The aim of this study was to assess the influence of $\text{A}\beta$ pathology, including neuritic, diffuse plaques, and vascular deposits, in FBB SUVR, when using cerebellum as the reference.

Methods: Neuropathological assessment of frontal, occipital, anterior and posterior cingulate cortices and cerebellar cortex from 87 end of life patients (64 AD, 14 other dementia, 9 non-demented aged volunteers; 80.4 ± 10.2 yrs.) who underwent a FBB positron emission tomography (PET) before death was performed using immunohistochemistry for $\text{A}\beta$ plaques and vascular deposits and the Bielschowsky method to demonstrate neuritic plaques. The lesions were rated as absent (none, sparse) or present (moderate, frequent). Mean cortical SUVRs were compared among cases with different cerebellar $\text{A}\beta$ loads.

Results: None of the 83 evaluable cerebellar samples showed frequent diffuse $\text{A}\beta$ or neuritic plaques, 8 samples showed frequent vascular $\text{A}\beta$ deposits. Diffuse $\text{A}\beta$ plaques were rated as absent in $n=78$ samples (94%) and as present in $n=5$ samples (6%). Vascular $\text{A}\beta$ was rated as absent in 62 samples (74.7%) and as present in 21 samples (25.3%). No significant differences in the cerebellum SUVs were found among cases with different amounts or types of $\text{A}\beta$ deposits in the cerebral cortex. Both diffuse and neuritic plaques were found in the cerebral cortex of 26-44 cases. No significant SUVR differences were found in these brains, which showed different cerebellar $\text{A}\beta$ loads.

Conclusions: The effect of cerebellar plaques in cortical FBB SUVRs appears to be negligible even in advanced stages of AD with a higher cerebellar $\text{A}\beta$ load.

Key words: Alzheimer disease, florbetaben, positron-emission tomography

INTRODUCTION

Histopathological confirmation of the in-vivo detection of amyloid-beta ($A\beta$) plaques by means of ^{18}F -Florbetaben PET imaging supports the use of this tracer as a biomarker for identifying brain $A\beta$ burden in clinical practice (1). Visual assessment, using a systematic methodology developed for this amyloid PET tracer, has shown high accuracy in the identification of positive and negative scans (2,3). However, potential subtle changes in $A\beta$ burden over time may not be apparent by visual inspection of the images. Thus, quantitative analysis has been found necessary for longitudinal observational studies and interventional trials when change in amyloid burden measured by PET serves as a treatment end point (4,5).

The main quantification used in brain $A\beta$ PET imaging is the standardized uptake value ratio (SUVR), a relative measurement defined as the ratio of SUV (% injected dose/body weight) in the target region over the SUV in the reference region. There are theoretical requirements for a reference region to be chosen, such as to have similar cellular and blood flow characteristics as the target region and to be devoid of specific binding sites (i.e. to be amyloid-free), thus having the same non-displaceable activity (free+nonspecific binding) as the target region (4). The cerebellar cortex is commonly used as a reference region for FBB quantification (4,6). This region fulfills all the requirements, except that it may contain $A\beta$ plaques in patients with the most advanced stage of AD (7) and in some types of familial AD (8). In these patients, the increase of specific $A\beta$ binding in the cerebellum might lead to an underestimation of the cortical SUVR measurements of $A\beta$ plaque load. This possibility has raised some concern about relying on this area as a reference region (4,8). Correlations of *in vivo* FBB PET scan SUVR quantification with post-mortem neuropathological assessments of cerebral cortical and cerebellar $A\beta$ plaques would allow this concern to be investigated. Therefore, a post hoc analysis of a FBB PET assessment correlation with pathology from a phase 3 clinical trial was performed in order to assess the influence of cerebellar amyloid pathology, including neuritic plaques and diffuse $A\beta$ plaques as well as vascular $A\beta$ deposits, in FBB SUVR when using the cerebellar cortex as reference region.

METHODS

Subjects

FBB PET scans and brain tissue samples from a total of 87 end of life patients included in a Phase 3 study, who underwent a PET scan during life and subsequent neuropathological assessment at autopsy, were included in the analysis. In brief, n=64 patients were diagnosed with AD (79.6 ± 9.9 yrs), n=14 of other forms of dementia (88.2 ± 9.3 yrs), and n=9 were non-demented aged volunteers (77.1 ± 11.4 yrs) This study was conducted in accordance with the Declaration of Helsinki. Approvals by regulatory authorities and ethics committees were obtained (1).

FBB PET

FBB PET images were acquired 90–110 minutes after intravenous injection of 300 MBq \pm 20% florbetaben according to a standardized acquisition and image-processing protocol (*1*). Three-dimensional volumetric T1-weighted brain magnetic resonance imaging data were also collected.

Quantification was performed using the method described in Barthel et al. (2011) (*6*). A standardized volume of interest (VOI) template was applied to the spatially normalized gray matter PET image based on a gray/white/cerebrospinal fluid segmentation of the participant's T1-weighted volumetric magnetic resonance imaging.

SUVs were obtained from both cerebellar cortex and cerebral cortical regions using the corresponding segmented gray portion of the template VOI. The cerebral cortical regions included two regions likely to contain high numbers of A β plaques, such as the frontal cortex and the posterior cingulate cortex, and two regions likely to contain lower numbers of A β plaques, such as the occipital cortex and the anterior cingulate cortex. Cerebral cortical SUVRs were then calculated using the cerebellar cortex as the reference region.

Neuropathology

Sections for histological analysis were cut from formalin-fixed paraffin-embedded tissue blocks from 5 predefined brain regions of interest including 4 cortical regions (frontal cortex, occipital cortex, anterior cingulate gyrus and posterior cingulate gyrus/precuneus) and one cerebellar cortical region (for details see (*1*)). Analysis for the presence or absence of neuritic plaques and diffuse A β plaques as well as vascular A β deposits, was performed by three experienced neuropathologists as previously described (*1*).

Diffuse A β plaques and vascular A β deposits were assessed by A β immunohistochemistry (monoclonal 6E10 A β antibody, Zytomed Systems, Berlin, Germany) and neuritic plaques were assessed by Bielschowsky silver stains (BSS) in sections from each tissue block.

Both types of plaques and vascular A β deposits were quantified according to a semi-quantitative score, which was originally developed for neuritic plaques (*9*) using the categories none, sparse, moderate or frequent. In the absence of any other semi-quantitative scoring system for diffuse A β plaques and vascular A β deposits, the same scoring system was applied for these types of pathology, which in addition allowed for semi-quantitative comparison across pathology subtypes. Pathology was rated as absent when the scoring for each category (neuritic plaques, diffuse A β plaques and vascular A β deposits) was none or sparse, and rated as present when scoring was moderate or frequent.

Statistical analysis

FBB mean cerebellar cortex SUVs and cerebral cortical SUVRs were compared among different cerebellar A β scores by means of a two-way analysis of variance (ANOVA) using the cerebellar diffuse A β plaques and the vascular A β deposits as factors potentially influencing SUV and SUVRs. Because of the negligible amount of neuritic cerebellar plaques found, these were not taken into account in the ANOVA analysis.

RESULTS

Cerebellar cortex pathology

Results related to A β pathology in the cerebellar cortex are summarized in Table 1. A total n=83 cases with a sample of cerebellar cortex were evaluable. Neuritic plaques were scored as none in all but one cerebellar sample, which was scored as sparse. Therefore, neuritic plaques were rated as absent in all samples. According to the semi-quantitative scoring system described above, diffuse A β plaques were rated as absent in n=78 samples (94%) and as present in n=5 samples (6%), all with a moderate amount of pathology. No samples contained frequent diffuse A β plaques in the cerebellum. Vascular A β was the most frequently detected type of A β deposit. It was rated as absent in 62 samples (74.7%), and as present in 21 samples (25.3%) (Table 1).

From the total of 21 samples showing vascular A β deposits, vascular A β was the only type of A β pathology present in n=18 samples (86%), while n=3 (14%) samples also contained moderate diffuse A β plaques in the cerebellar cortex (molecular layer). On the other hand, 3 out of 5 (60%) of the samples with moderate diffuse A β plaques also contained vascular A β deposits (Fig. 1, Table 1). The only sample with sparse neuritic plaques also contained both sparse diffuse A β plaques and moderate vascular A β deposits.

FBB quantification and pathology

Cerebellar SUVs ranged between 0.26 and 1.79 (0.90 \pm 0.32 (0.83, 0.97); mean \pm sd and 95% confidence intervals). No significant SUV differences were found in the cerebellar cortex among brains with none, sparse or moderate cerebellar A β pathology ($p_{\text{diffuse}}=0.49$, $p_{\text{vascular}}=0.43$) (Fig. 1). In subjects rated for presence of cerebral cortical plaques (i.e. moderate or frequent A β diffuse and/or neuritic plaques, in 26-44 cases), who are the most likely to have A β deposits in the cerebellum, cortical SUVRs ranged between 0.91-2.37 (frontal cortex), 1.10-2.13 (occipital cortex), 0.83-2.49 (anterior cingulate cortex) and 0.95-2.84 (posterior cingulate cortex). No significant SUVR differences among brains with different amounts of cerebellar A β pathology (i.e. scores of none, sparse or moderate) were found (Table 2, Figs. 2 and 3). Neither the nature nor the amount of A β deposits in the cerebellum had any effect on cortical SUVRs. When analyzing the full cohort of patients, including those with either the absence or presence of cortical A β plaques, cortical SUVRs

ranged between 0.66-2.37 (frontal cortex), 1.07-2.13 (occipital cortex), 0.47-2.49 (anterior cingulate cortex) and 0.95-2.84 (posterior cingulate cortex). In the full cohort, the amount of cerebellar A β pathology positively correlated with the amount of amyloid plaques in the cerebral cortex as measured using SUVRs (Table 2, Fig. 4).

DISCUSSION

To the best of our knowledge, this is the first study comparing post-mortem pathologically confirmed cerebellar A β pathology with ante-mortem FBB PET scan quantification within the same subjects to investigate the appropriateness of the use of the cerebellum as a reference region. Neuropathological studies have shown that A β is present in the cerebellum only in the most advanced stage of AD, when other cerebral regions including the cortex are already severely affected (7). Therefore, the potential influence of cerebellar A β in cortical SUVR quantification was investigated in patients with cerebral cortical A β plaques. This study showed that the potential binding of FBB to cerebellar amyloid does not influence the SUVR in cerebral cortical regions. Most of the cerebellar amyloid deposits were in form of either diffuse A β plaques and/or vascular A β , which have been reported to influence the cerebral cortical SUVR measurements using FBB (10). However, in this study the cerebellar SUV was not influenced by either the amount or the type of A β deposition, probably because of the relatively low levels of A β deposits detected in the cerebellum. This finding indicates that the signal from any potential FBB binding in the cerebellum will be small and is likely to fall within the margins of error in PET signal measurement, and will therefore not be detectable. Another possible explanation may be the morphological and immunocytochemical differences between the neuropathological lesions of AD in the cerebral cortex and cerebellum (11). As expected, the amount of cerebellar A β deposition assessed pathologically correlated positively with the cortical SUVRs in the full sample of patients; subjects without A β deposition in the cerebral cortex did not show A β deposition in the cerebellum, and the higher the amount of cerebellar A β deposition, the higher the cerebral cortical SUVR.

Cerebellar pathology in AD

It is well established in the literature that A β deposits can be found in the cerebellum in the patients with AD and Down syndrome. Cerebellar amyloid plaques were detected in “familial organic psychosis (Alzheimer’s type)” as early as 1934 (12) and the existence of diffuse A β plaques in the cerebellum has been noted with introduction and the increasingly widespread use of A β immunohistochemistry (13-15). The presence of cerebellar A β deposits has been reported especially – but not exclusively - in familial forms of AD, e.g. in patients with *APP* and *PSEN1* mutations (16,17), in severe early-onset cases of AD (15) and in the late stages of sporadic AD. In Braak and Braak’s neuropathological staging of AD, the presence of cerebellar pathology is only mentioned in stage C (18) and in the more recent analysis of the sequence of A β deposition in the brain in AD by Thal et

al., the presence of cerebellar A β deposits is described in the final stage of the disease (Phase 5) (7).

The amount of diffuse A β plaques and neuritic plaques detected in the cerebellum in our study is fully in keeping with earlier descriptions (13,15,19): While sparse neuritic plaques as determined by BSS were identified only in one case, diffuse A β plaques in varying amounts were identified in 39 (= 47%) cases. Since the number of A β deposits in most of these cases did not meet the criteria to be scored as moderate the pathology was overall rated as absent, while only 6% (n=5) of cases had moderate quantities of A β pathology, which was rated as present according to the agreed criteria for this study. A larger sample of cases with presence of cerebellar A β pathology would have been desirable to investigate whether a subtle FBB uptake in the cerebellum may have any effects on cortical SUVR.

Vascular A β deposition was detected in 25.3% of the 83 evaluable cerebellar samples in this study. In the cerebellar samples from AD patients (n=60), vascular A β deposition was found in n=17 cases (28.3%). Thus, the overall frequency of cerebellar vascular A β deposits in this sample is somewhat less than reported for some earlier series of AD patients (13,14,20), but still occurred in a significant portion of samples. This finding is not surprising, since the phase 3 clinical trial that provided the patients for this study included end-of-life patients only, often in advanced clinical stages of the AD (1). Therefore, this series of patients is considered representative of the late neuropathological stages of AD in the majority of cases. However, in the target clinical population for amyloid PET imaging for diagnostic purposes the cerebellum is likely to be devoid of A β pathology, as the clinical population expected to undergo diagnostic PET imaging is considered likely to be in the early stages of AD and may include atypical cases of cognitive impairment with difficult diagnoses (21), in which the AD pathology may not be advanced.

The nature and distribution of the A β deposited in the cerebellar samples in this study is fully in keeping with earlier descriptions (11,13). Most of the diffuse A β plaques in the cerebellum were present in the molecular layer, although in some AD cases diffuse A β plaques have been observed in the Purkinje cell and granular cell layers (13-17). It has been suggested that the pathology of cerebellar A β plaques is similar, but not identical to the respective A β deposits in the cerebral cortex, as some of the accompanying elements of AD pathology including neurofibrillary tangles and microglial activation appear either absent or much less common in the cerebellum (11,22). Thus, cerebellar A β plaques have been considered to possibly represent an earlier form of plaque evolution or even an attenuated stage in the process of plaque maturation when compared to the A β plaques in the cerebral cortex in AD. These suggestions may reflect the observation that cerebellar pathology in AD is not as readily demonstrable by either classical neuropathological staining techniques or classical neuroimaging methods.

Cerebellum as the reference region in FBB amyloid PET

Selection of the reference region in the brain has been emphasized as one of the most critical factors affecting A β PET measurements (4). One of the reasons to select the cerebellar cortex for the first A β PET studies with ^{11}C -PIB was the finding that clearance of this tracer from the cerebellar gray matter is more similar to its clearance from the cerebral gray matter target regions than from cerebral white matter (23). Moreover, in the clinical population in whom the use of brain A β imaging is intended, the cerebellum is likely to be devoid of A β in most patients, as described above. ^{11}C -PIB retention in the cerebellum in familial AD has been reported (8), leading to the suggestion that the cerebellum may not be an appropriate reference region for ^{11}C -PIB in subjects with likelihood of cerebellar A β plaques (24). However, to the best of our knowledge, no correlations between the in-vivo ^{11}C -PIB scans and cerebellar pathology post-mortem in the same individuals were performed in previous studies. No familial AD cases were included in this study, thus the potential effect of FBB binding to cerebellar A β in the SUVR in these cases remains unknown. However, A β PET imaging has been considered to be inappropriate when the diagnosis is based solely “on a positive family history of dementia or presence of *Apolipoprotein E (APOE) ϵ 4*” (21). The results from our study show that FBB retention in the cerebellum (SUV) is not affected by the presence of cerebellar A β pathology in end-of-life patients (including advanced AD cases), and that when using FBB as A β PET tracer the potential influence of cerebellar A β deposits on cortical SUVRs when the cerebellar cortical gray matter is the reference region is negligible. From a biological perspective, the cerebellar cortex is the most appropriate reference region for A β PET quantification, and this study supports its use in FBB A β PET scans.

In the absence of direct PET and pathology correlation studies to address the influence of cerebellar A β pathology in the cortical SUVR when using other A β PET tracers, the search for alternative reference regions to the cerebellum for each amyloid PET tracer has been the subject of recent active research. The pons and the subcortical white matter are the two main brain regions studied as an alternative reference region to the cerebellum. (25)(7,26). Whereas the pons has similar blood flow characteristics to the cerebral cortex (27), supporting its use as a reference region in brain ^{18}F -Fluorodeoxyglucose and ^{18}F -Flutemetamol PET scans, this is not the case for the subcortical white matter (23,28). The pharmacokinetics of ^{11}C -PIB differs in the pons (and subcortical white matter) when compared with cerebral cortical areas in subjects without brain A β deposition (23). Therefore, ^{11}C -PIB pharmacokinetics in the pons may not adequately represent the cerebral cortical tissue kinetics of nonspecifically bound and free ^{11}C -PIB. Nevertheless, SUVRs using the pons as the reference region have been used for ^{11}C -PIB when there is retention in the cerebellum (24). The presence of subcortical white matter abnormalities with different flow and cellular characteristics across aged subjects such as white matter vascular pathology is frequent in the elderly population (29-31), and therefore the SUV in this region is not stable, making the rationale for exploring the subcortical white matter as a reference region for A β PET quantification questionable.

Potential issues arising from the use of the cerebellar cortex as the reference region include technical factors. In PET centers with little experience in brain PET scans and head positioning, the proximity of the cerebellum to the edge of the scanner field of view may lead to signal noise and truncation (4). The small VOI sizes, which contain low counts, may lead to statistical noise and high variability of measurements. This may explain in part the rationale for attempting to use the subcortical white matter as the reference region in patients followed longitudinally with ^{18}F -Florbetapir (32). However, the use of the whole cerebellum (including gray and white matter) in the VOI would increase the statistical counts in the reference region. In a recent study comparing different reference regions across different amyloid tracers (^{18}F -Flutemetamol, $n=258$; ^{18}F -Florbetapir $n=184$; and ^{18}F -Florbetaben $n=211$), in different clinical conditions, in patients with different cerebral $\text{A}\beta$ status, and across time, found the cerebellar gray matter as the most stable reference region across the examined conditions for FBB, but not for ^{18}F -Flutemetamol or ^{18}F -Florbetapir, where a composite of the subcortical white matter+pons and the subcortical white matter were reported as the most stable reference regions respectively (33). Comparison of different reference regions using FBB in longitudinal studies is not the objective of the current study. However, our results with FBB are consistent with the findings of this study (33), reinforcing the use of the cerebellar cortex as an appropriate reference region for this tracer. In a cross-sectional study comparing FBB SUVR results across the cerebellar cortex, whole cerebellum, pons, and white matter as reference regions showed no significant differences in effect sizes, correlation coefficients, test-retest variability or intra-class correlation coefficients across the different reference regions (34). Altogether, these results show that FBB quantification is very robust, and that the cerebellar cortex is the most appropriate reference region for FBB from both theoretical and biological perspectives, and can be used in any clinical setting in which this amyloid tracer is employed.

CONCLUSIONS

This study addresses for the first time the potential influence of the presence of $\text{A}\beta$ pathology in the cerebellum in FBB quantification, by means of a within-subject PET and pathology correlation design in an end-of-life patient population, which included cases with advanced stages AD. The results show that the effect of cerebellar $\text{A}\beta$ pathology in FBB SUVR quantification is negligible, even in subjects with a high $\text{A}\beta$ load in the cerebral cortex, thus supporting the use of cerebellar cortical gray matter as the reference region for FBB SUVR quantification.

ACKNOWLEDGEMENTS

Authors wish to thank Aleksandar Jovalekic for his editorial and coordination contributions, and the whole Florbetaben study group.

REFERENCES

1. Sabri O, Sabbagh M, Seibyl J, et al. Florbetaben PET imaging to detect amyloid beta plaques in Alzheimer disease: phase 3 study. *Alzheimers Dement*. 2015;11:964-974.
2. Seibyl J, Catafau AM, Barthel H, et al. Impact of training method on the robustness of the visual assessment of 18F-florbetaben PET scans - results from a phase 3 study. *J Nucl Med*. 2016.
3. Piramal Imaging. Neuraceq - Prescribing Information (US). 2014.
4. Schmidt ME, Chiao P, Klein G, et al. The influence of biological and technical factors on quantitative analysis of amyloid PET: Points to consider and recommendations for controlling variability in longitudinal data. *Alzheimers Dement*. 2015;11:1050-1068.
5. Ong KT, Villemagne VL, Bahar-Fuchs A, et al. Abeta imaging with 18F-florbetaben in prodromal Alzheimer's disease: a prospective outcome study. *J Neurol Neurosurg Psychiatry*. 2015;86:431-436.
6. Barthel H, Gertz HJ, Dresel S, et al. Cerebral amyloid-beta PET with florbetaben (18F) in patients with Alzheimer's disease and healthy controls: a multicentre phase 2 diagnostic study. *Lancet Neurol*. 2011;10:424-435.
7. Thal DR, Rub U, Orantes M, Braak H. Phases of A beta-deposition in the human brain and its relevance for the development of AD. *Neurology*. 2002;58:1791-1800.
8. Knight WD, Okello AA, Ryan NS, et al. Carbon-11-Pittsburgh compound B positron emission tomography imaging of amyloid deposition in presenilin 1 mutation carriers. *Brain*. 2011;134:293-300.
9. Mirra SS, Heyman A, McKeel D, et al. The Consortium to Establish a Registry for Alzheimer's Disease (CERAD). Part II. Standardization of the neuropathologic assessment of Alzheimer's disease. *Neurology*. 1991;41:479-486.
10. Sabri, Catafau, Barthel, et al. Impact of Morphologically Distinct Amyloid b (Ab) Deposits on 18F-Florbetaben (FBB) PET Scans. *J Nucl Med*. 2015;56:195.
11. Lerner AJ. The Cerebellum in Alzheimer's Disease. *Dement Geriatr Cogn Disord*. 1997;8:203-209.
12. Lowenberg KK, Waggoner RW. Familial organic psychosis (Alzheimer's type). *Arch Neuropsych*. 1934;31:737-754.
13. Yamaguchi H, Hirai S, Morimatsu M, Shoji M, Nakazato Y. Diffuse type of senile plaques in the cerebellum of Alzheimer-type dementia demonstrated by beta protein immunostain. *Acta Neuropathol*. 1989;77:314-319.

14. Joachim CL, Morris JH, Selkoe DJ. Diffuse senile plaques occur commonly in the cerebellum in Alzheimer's disease. *Am J Pathol.* 1989;135:309-319.
15. Cole G, Neal JW, Singhrao SK, Jasani B, Newman GR. The distribution of amyloid plaques in the cerebellum and brain stem in Down's syndrome and Alzheimer's disease: a light microscopical analysis. *Acta Neuropathol.* 1993;85:542-552.
16. Ghetti B, Murrell J, Benson MD, Farlow MR. Spectrum of amyloid beta-protein immunoreactivity in hereditary Alzheimer disease with a guanine to thymine missense change at position 1924 of the APP gene. *Brain Res.* 1992;571:133-139.
17. Lemere CA, Lopera F, Kosik KS, et al. The E280A presenilin 1 Alzheimer mutation produces increased A beta 42 deposition and severe cerebellar pathology. *Nat Med.* 1996;2:1146-1150.
18. Braak H, Braak E. Neuropathological staging of Alzheimer-related changes. *Acta Neuropathol.* 1991;82:239-259.
19. Wolf DS, Gearing M, Snowdon DA, Mori H, Markesbery WR, Mirra SS. Progression of regional neuropathology in Alzheimer disease and normal elderly: findings from the Nun study. *Alzheimer Dis Assoc Disord.* 1999;13:226-231.
20. Braak H, Braak E, Ohm T, Bohl J. Alzheimer's disease: mismatch between amyloid plaques and neuritic plaques. *Neurosci Lett.* 1989;103:24-28.
21. Johnson KA, Minoshima S, Bohnen NI, et al. Appropriate Use Criteria for Amyloid PET: A Report of the Amyloid Imaging Task Force (AIT), the Society of Nuclear Medicine and Molecular Imaging (SNMMI) and the Alzheimer Association (AA). *Alzheimers Dement.* 2013;9:e1-e16.
22. Wood P. The Cerebellum in AD. In: Wood P, ed. *Neuroinflammation*: Humana Press; 2003:295-300.
23. Price JC, Klunk WE, Lopresti BJ, et al. Kinetic modeling of amyloid binding in humans using PET imaging and Pittsburgh Compound-B. *J Cereb Blood Flow Metab.* 2005;25:1528-1547.
24. Klunk WE, Price JC, Mathis CA, et al. Amyloid deposition begins in the striatum of presenilin-1 mutation carriers from two unrelated pedigrees. *Journal of Neuroscience.* 2007;27:6174-6184.
25. Thurfjell L, Lilja J, Lundqvist R, et al. Automated quantification of 18F-flutemetamol PET activity for categorizing scans as negative or positive for brain amyloid: concordance with visual image reads. *J Nucl Med.* 2014;55:1623-1628.
26. Kyriakides T, Silbert PL, Kakulas BA. Cerebral amyloid angiopathy and intracerebral hemorrhage with special reference to the pons. *Clin Neuropathol.* 1994;13:71-76.
27. Minoshima S, Frey KA, Foster NL, Kuhl DE. Preserved pontine glucose metabolism in Alzheimer disease: a reference region for functional brain image (PET) analysis. *J Comput Assist Tomogr.* 1995;19:541-547.

28. Zhang K, Herzog H, Mauler J, et al. Comparison of cerebral blood flow acquired by simultaneous [¹⁵O]water positron emission tomography and arterial spin labeling magnetic resonance imaging. *J Cereb Blood Flow Metab.* 2014;34:1373-1380.
29. Anderson VC, Obayashi JT, Kaye JA, et al. Longitudinal relaxographic imaging of white matter hyperintensities in the elderly. *Fluids Barriers CNS.* 2014;11:1-10.
30. Abraham HM, Wolfson L, Moscufo N, Guttmann CR, Kaplan RF, White WB. Cardiovascular risk factors and small vessel disease of the brain: blood pressure, white matter lesions, and functional decline in older persons. *J Cereb Blood Flow Metab.* 2015;36:132-142.
31. Murray ME, Senjem ML, Petersen RC, et al. Functional impact of white matter hyperintensities in cognitively normal elderly subjects. *Arch Neurol.* 2010;67:1379-1385.
32. Landau SM, Fero A, Baker SL, et al. Measurement of longitudinal A β change with 18F florbetapir PET and standard uptake value ratios. *J Nucl Med.* 2015;56:567-574.
33. Villemagne V, Bourgeat P, Dore V, et al. Amyloid Imaging in Therapeutic Trials: The Quest for the Optimal Reference Region. *Alzheimers Dement.* 2015;11:21-22.
34. Barthel H, Bullich S, Sabri O, et al. 18F-Florbetaben (FBB) PET SUVR quantification: Which reference region? *J Nucl Med.* 2015;56:1563.

TABLES

Table 1. Cerebellar cortex pathology results.

| | | | Vascular A β deposits | | | | Total | |
|---------------------------------|---------|----|-----------------------------|--------|----------|----------|-------|----|
| | | | Absent | | Present | | | |
| | | | 62 | | 21 | | | |
| | | | none | sparse | moderate | frequent | | |
| Diffuse A β plaques | Absent | 78 | none | 25 | 14 | 3 | 2 | 44 |
| | | | sparse | 8 | 13 | 8* | 5 | 34 |
| | Present | 5 | moderate | 1 | 1 | 2 | 1 | 5 |
| | | | frequent | 0 | 0 | 0 | 0 | 0 |
| | | | Total | 34 | 28 | 13 | 8 | 83 |

Numbers refer to number of samples with the corresponding pathology finding. *One subject in this group showed also sparse neuritic plaques.

Table 2. FBB SUVRs for each cerebral cortical region among different cerebellar A β deposits and scores (mean \pm sd and 95% confidence interval), and statistical comparison results.

| | Cerebral region (n) | Cerebellar A β deposits | Cerebellar A β scores | | | | ANOVA | | |
|-------------------------|-------------------------|-------------------------------|--------------------------------|--------------------------------|--------------------------------|--------------------------------|--------------------------------|-----------------------|------|
| | | | Absent | Sparse | Moderate | Frequent | P _{diffuse} | P _{vascular} | |
| SUVR (full sample) | Frontal cortex (83) | Diffuse plaques | 1.36 \pm 0.35 (1.29,1.43) | 1.70 \pm 0.33 (1.62,1.77) | 1.82 \pm 0.29 (1.76,1.89) | - | <10 ⁻⁴ | 0.003 | |
| | | Vascular | 1.31 \pm 0.35 (1.23,1.38) | 1.66 \pm 0.34 (1.56,1.74) | 1.66 \pm 0.33 (1.59,1.73) | 1.77 \pm 0.24 (1.72,1.82) | | | |
| | Occipital cortex (82) | Diffuse plaques | 1.44 \pm 0.21 (1.40,1.49) | 1.66 \pm 0.24 (1.61,1.71) | 1.69 \pm 0.26 (1.64,1.75) | - | <10 ⁻⁴ | 0.001 | |
| | | Vascular | 1.41 \pm 0.21 (1.36,1.46) | 1.63 \pm 0.21 (1.59,1.68) | 1.65 \pm 0.30 (1.58,1.71) | 1.66 \pm 0.19 (1.62,1.70) | | | |
| | Ant. Cing. cortex (82) | Diffuse plaques | 1.37 \pm 0.40 (1.29,1.46) | 1.74 \pm 0.38 (1.66,1.82) | 1.86 \pm 0.31 (1.80,1.93) | - | <10 ⁻⁴ | 0.03 | |
| | | Vascular | 1.35 \pm 0.37 (1.27,1.43) | 1.65 \pm 0.45 (1.56,1.75) | 1.67 \pm 0.43 (1.58,1.77) | 1.91 \pm 0.18 (1.87,1.95) | | | |
| | Post. Cing. cortex (82) | Diffuse plaques | 1.59 \pm 0.39 (1.51,1.67) | 1.87 \pm 0.37 (1.79,1.95) | 1.86 \pm 0.24 (1.81,1.92) | - | 0.004 | 0.13 | |
| | | Vascular | 1.56 \pm 0.37 (1.48,1.64) | 1.80 \pm 0.39 (1.72,1.89) | 1.81 \pm 0.43 (1.72,1.90) | 1.96 \pm 0.22 (1.91,2.01) | | | |
| | SUVR (subsample) | Frontal cortex (44) | Diffuse plaques | 1.64 \pm 0.34 (1.54,1.74) | 1.77 \pm 0.29 (1.69,1.85) | 1.73 \pm 0.24 (1.66,1.80) | - | 0.47 | 0.83 |
| | | | Vascular | 1.64 \pm 0.33 (1.54,1.74) | 1.74 \pm 0.32 (1.65,1.84) | 1.75 \pm 0.26 (1.67,1.83) | 1.79 \pm 0.28 (1.71,1.87) | | |
| | | Occipital cortex (41) | Diffuse plaques | 1.67 \pm 0.21 (1.60,1.73) | 1.68 \pm 0.23 (1.61,1.75) | 1.60 \pm 0.16 (1.55,1.65) | - | 0.77 | 0.08 |
| | | | Vascular | 1.50 \pm 0.22 (1.43,1.56) | 1.68 \pm 0.19 (1.62,1.74) | 1.74 \pm 0.23 (1.67,1.81) | 1.74 \pm 0.17 (1.68,1.79) | | |
| Ant. Cing. cortex (26) | | Diffuse plaques | 1.73 \pm 0.39 (1.58,1.88) | 1.77 \pm 0.36 (1.63,1.90) | 1.74 \pm 0.18 (1.67,1.81) | - | 0.97 | 0.57 | |
| | | Vascular | 1.77 \pm 0.16 (1.70,1.83) | 1.72 \pm 0.48 (1.54,1.91) | 1.63 \pm 0.18 (1.56,1.70) | 1.92 \pm 0.21 (1.84,2.00) | | | |
| Post. Cing. cortex (32) | | Diffuse plaques | 1.91 \pm 0.44 (1.77,2.06) | 1.94 \pm 0.34 (1.82,2.06) | 1.79 \pm 0.20 (1.72,1.86) | - | 0.78 | 0.96 | |
| | | Vascular | 1.90 \pm 0.42 (1.76,2.05) | 1.90 \pm 0.43 (1.75,2.05) | 1.89 \pm 0.29 (1.79,1.99) | 1.98 \pm 0.26 (1.89,2.07) | | | |

SUVR=standardized uptake value ratio taking the cerebellar cortex as reference region; ANOVA= analysis of variance; Ant. Cing.= Anterior cingulate; Post. Cing.=Posterior cingulate

Figure 1. FBB cerebellar SUV distribution according to the different cerebellar diffuse A β plaque loads. None and sparse scores were rated as absence of A β plaques. White dots: subjects with no vascular A β in the cerebellum; black dots: subjects with vascular A β in the cerebellum.

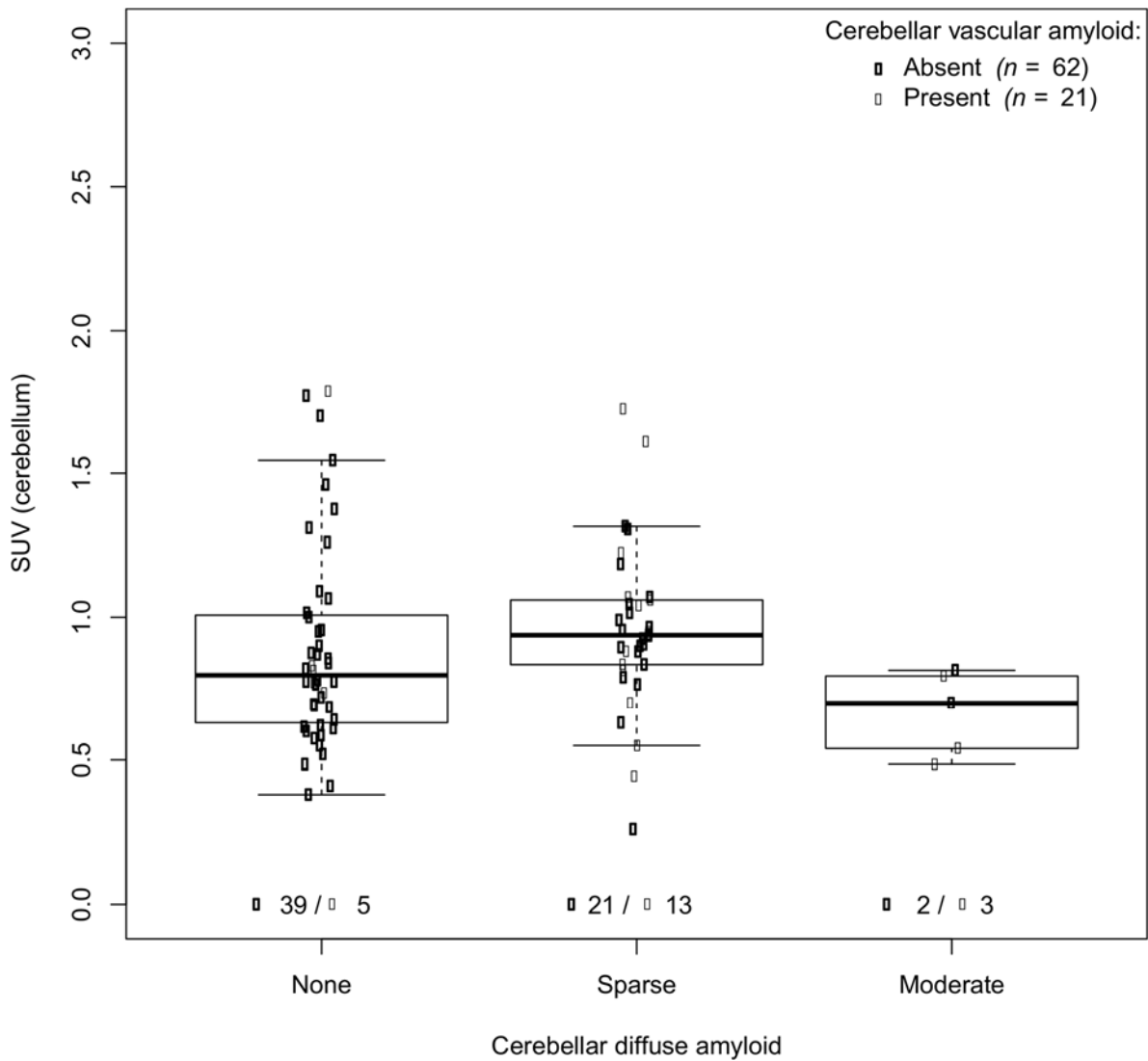


Figure 2. FBB SUVR distribution in the four cortical regions studied according to the different cerebellar diffuse A β plaque loads in subjects with presence of cerebral cortical A β plaques. None and sparse scores were rated as absence of A β plaques. White dots: subjects with no vascular A β in the cerebellum; black dots: subjects with vascular A β in the cerebellum.

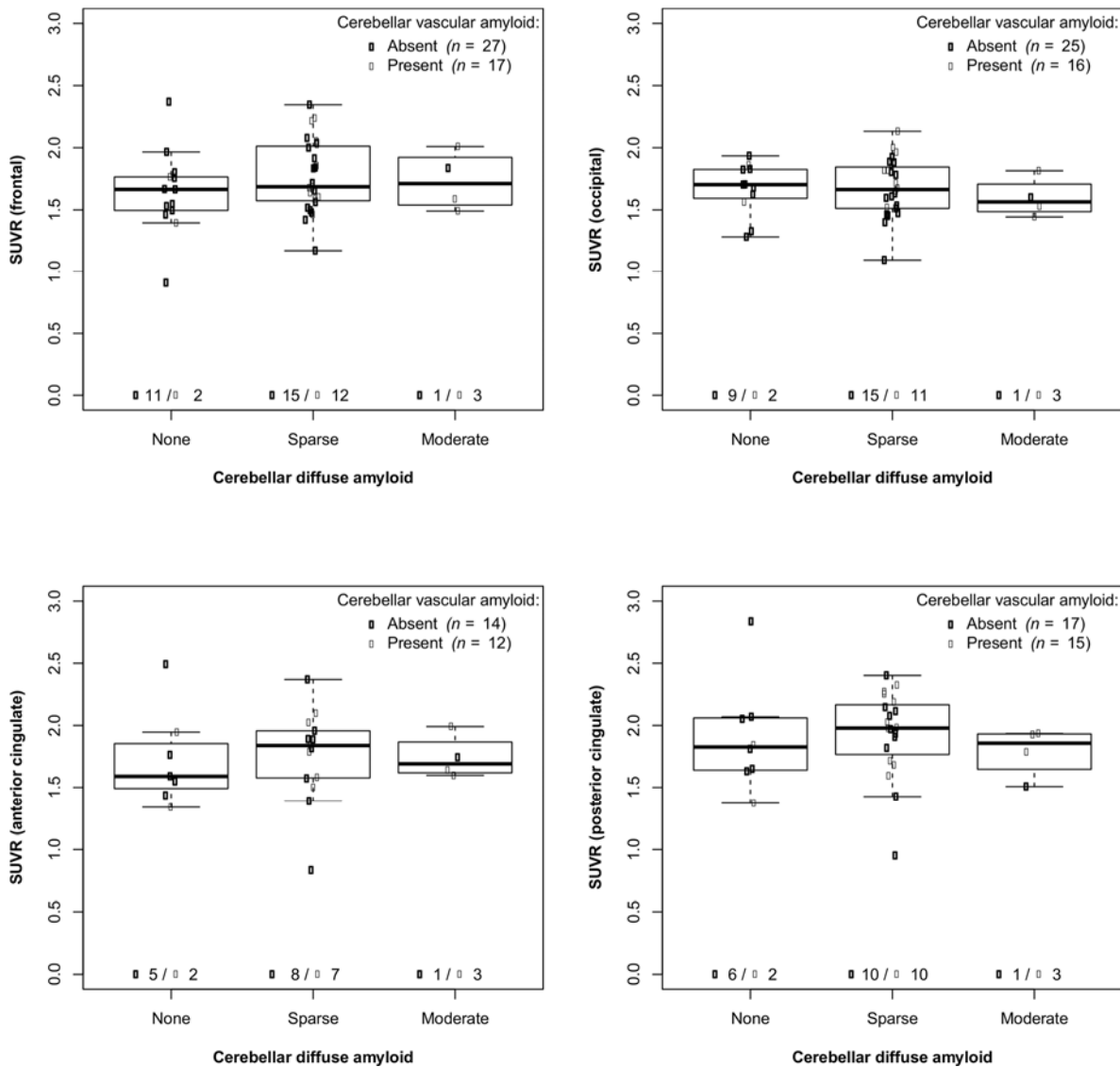


Figure 3. Representative FBB PET images in a subject with sparse diffuse A β plaques in the cerebellum and frequent diffuse A β plaques in all cortical regions, with moderate neuritic plaques in the frontal cortex and moderate vascular A β in the occipital cortex. SUVR(frontal cortex)=2.08; SUVR(occipital cortex) = 1.50; SUVR(anterior cingulate cortex)=2.26; SUVR(posterior cingulate cortex)=2.22.

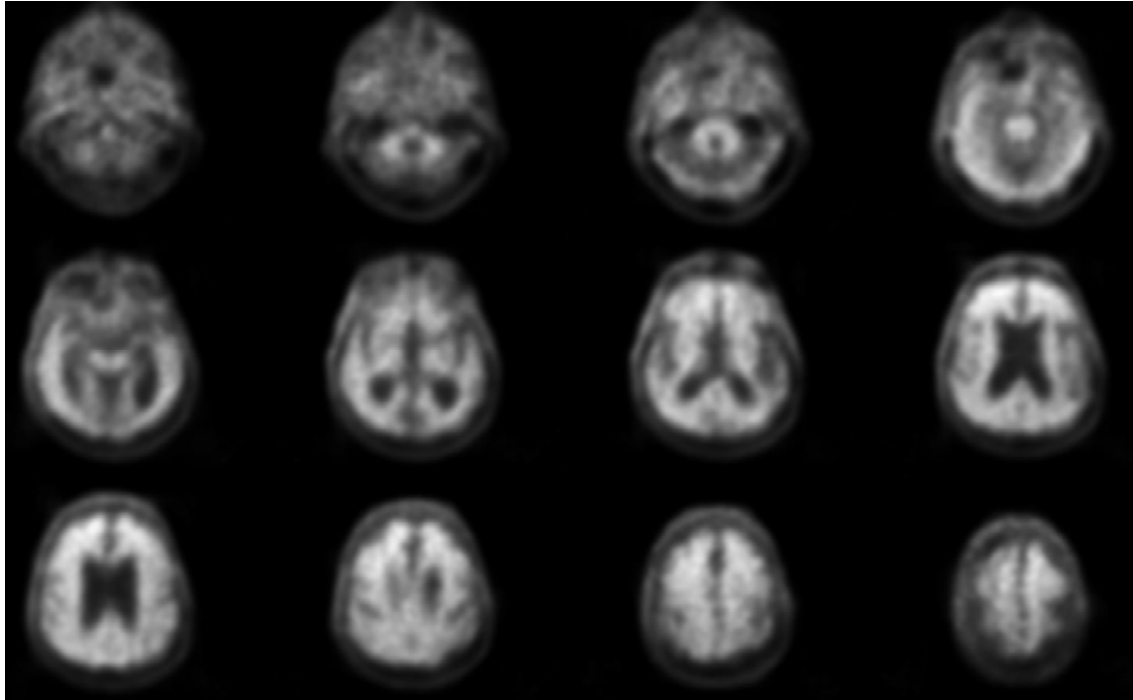
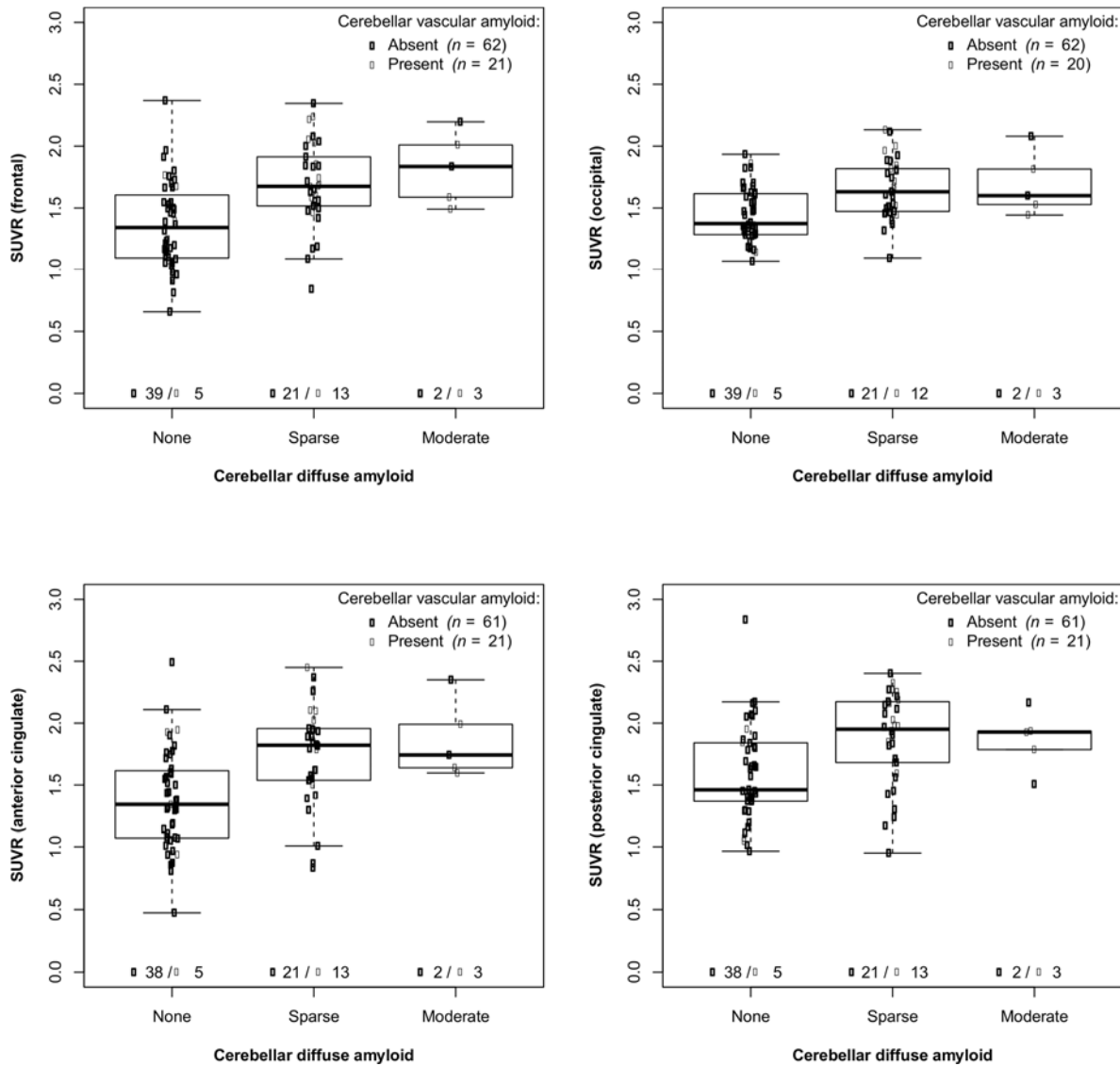


Figure 4. FBB SUVR distribution in the four cortical regions studied according to the different cerebellar diffuse A β plaque loads in the full sample of subjects rated with either absence or presence of cerebral cortical A β plaques. None and sparse scores were rated as absence of A β plaques. White dots: subjects with no vascular A β in the cerebellum; black dots: subjects with vascular A β in the cerebellum.





The Journal of
NUCLEAR MEDICINE

Cerebellar amyloid-beta plaques: How frequent are they, and do they influence F-Florbetaben SUVR? ¹⁸

Ana M Catafau, Santiago Bullich, John P Seibyl, Henryk Barthel, Bernardino Ghetti, James Leverenz, James W Ironside, Walter J Schulz-Schaefer, Anja Hoffmann and Osama Sabri

J Nucl Med.

Published online: June 30, 2016.

Doi: 10.2967/jnumed.115.171652

This article and updated information are available at:

<http://jnm.snmjournals.org/content/early/2016/06/29/jnumed.115.171652>

Information about reproducing figures, tables, or other portions of this article can be found online at:

<http://jnm.snmjournals.org/site/misc/permission.xhtml>

Information about subscriptions to JNM can be found at:

<http://jnm.snmjournals.org/site/subscriptions/online.xhtml>

JNM ahead of print articles have been peer reviewed and accepted for publication in *JNM*. They have not been copyedited, nor have they appeared in a print or online issue of the journal. Once the accepted manuscripts appear in the *JNM* ahead of print area, they will be prepared for print and online publication, which includes copyediting, typesetting, proofreading, and author review. This process may lead to differences between the accepted version of the manuscript and the final, published version.

The Journal of Nuclear Medicine is published monthly.
SNMMI | Society of Nuclear Medicine and Molecular Imaging
1850 Samuel Morse Drive, Reston, VA 20190.
(Print ISSN: 0161-5505, Online ISSN: 2159-662X)

© Copyright 2016 SNMMI; all rights reserved.