



THE UNIVERSITY *of* EDINBURGH

Edinburgh Research Explorer

The use of hemostatic spray as an adjunct to the conventional hemostatic measures in high-risk nonvariceal upper GI bleeding (with video)

Citation for published version:

Sinha, R, Lockman, KA, Church, NI, Plevris, JN & Hayes, PC 2016, 'The use of hemostatic spray as an adjunct to the conventional hemostatic measures in high-risk nonvariceal upper GI bleeding (with video)', *Gastrointestinal Endoscopy*. <https://doi.org/10.1016/j.gie.2016.04.016>

Digital Object Identifier (DOI):

[10.1016/j.gie.2016.04.016](https://doi.org/10.1016/j.gie.2016.04.016)

Link:

[Link to publication record in Edinburgh Research Explorer](#)

Document Version:

Peer reviewed version

Published In:

Gastrointestinal Endoscopy

Publisher Rights Statement:

Author's final peer-reviewed manuscript as accepted for publication

General rights


Copyright for the publications made accessible via the Edinburgh Research Explorer is retained by the author(s) and / or other copyright owners and it is a condition of accessing these publications that users recognise and abide by the legal requirements associated with these rights.

Take down policy

The University of Edinburgh has made every reasonable effort to ensure that Edinburgh Research Explorer content complies with UK legislation. If you believe that the public display of this file breaches copyright please contact openaccess@ed.ac.uk providing details, and we will remove access to the work immediately and investigate your claim.



Accepted Manuscript



The use of hemostatic spray as an adjunct to the conventional hemostatic measures in high-risk nonvariceal upper GI bleeding (with video)

Rohit Sinha, MBBS, MRCP, PgDip, Khalida A. Lockman, MBChB, MRCP, MD, Nicholas I. Church, MBChB, MD, FRCP, John N. Plevris, MD, PhD, FRCPE, FEBGH, Peter C. Hayes, BSc, MBChB, MD, PhD, FRCPE

PII: S0016-5107(16)30062-1

DOI: [10.1016/j.gie.2016.04.016](https://doi.org/10.1016/j.gie.2016.04.016)

Reference: YMGE 9975

To appear in: *Gastrointestinal Endoscopy*

Received Date: 10 January 2016

Accepted Date: 7 April 2016

Please cite this article as: Sinha R, Lockman KA, Church NI, Plevris JN, Hayes PC, The use of hemostatic spray as an adjunct to the conventional hemostatic measures in high-risk nonvariceal upper GI bleeding (with video), *Gastrointestinal Endoscopy* (2016), doi: 10.1016/j.gie.2016.04.016.

This is a PDF file of an unedited manuscript that has been accepted for publication. As a service to our customers we are providing this early version of the manuscript. The manuscript will undergo copyediting, typesetting, and review of the resulting proof before it is published in its final form. Please note that during the production process errors may be discovered which could affect the content, and all legal disclaimers that apply to the journal pertain.

Title:

The use of hemostatic spray as an adjunct to the conventional hemostatic measures in high-risk nonvariceal upper GI bleeding (with video)

Authors:

Rohit Sinha¹, Khalida A. Lockman², Nicholas I. Church¹, John N. Plevris¹, Peter C. Hayes¹

Affiliations:

¹Centre of Liver and Digestive Disorder, ²Acute Medicine Unit,
The Royal Infirmary and The University of Edinburgh,
51 Little France Crescent, Edinburgh EH16 4SA, United Kingdom

Degrees:

R Sinha – MBBS, MRCP, PgDip

KA Lockman – MBChB, MRCP, MD

NI Church – MBChB, MD, FRCP

JN Plevris – MD, PhD, FRCPE, FEBGH

PC Hayes – BSc, MBChB, MD, PhD, FRCPE

Corresponding Author:

Dr Rohit Sinha

Centre of Liver and Digestive Disorder

The Royal Infirmary and The University of Edinburgh,

51 Little France Crescent,

Edinburgh EH16 4SA,

United Kingdom.

Email: rohit.sinha@nhs.net

Telephone: 0044 131 2421625

Fax: 0044 131 2421633

The use of hemostatic spray as an adjunct to the conventional hemostatic measures in high-risk nonvariceal upper GI bleeding (with video)

R Sinha¹, KA Lockman², NI Church¹, JN Plevris¹, PC Hayes¹

¹Centre of Liver and Digestive Disorder, ²Acute Medicine Unit,
The Royal Infirmary and The University of Edinburgh,
51 Little France Crescent, Edinburgh EH16 4SA, UK

Corresponding author:

Dr Rohit Sinha

Centre of Liver and Digestive Disorder

The Royal Infirmary and The University of Edinburgh,

51 Little France Crescent,

Edinburgh EH16 4SA,

United Kingdom.

Email: rohit.sinha@nhs.net

Telephone: 0044 131 2421625

Fax: 0044 131 2421633

Abstract

Background: Endoscopic management of nonvariceal upper gastrointestinal bleed (NVUGIB) can be challenging. Hemospray (Cook Medical, Winston-Salem, NC, USA) is a novel endoscopic hemostatic agent for NVUGIB. Its efficacy in attaining hemostasis in NVUGIB is promising, particularly with respect to technically difficult lesions. However, most of the currently available data are focused on its application as monotherapy. The aim of this study was to evaluate its efficacy as a second agent to adrenaline, or as an addition to the combination of adrenaline with either clips or a thermal device in NVUGIB.

Methods: Consecutive patients with Forrest 1a and 1b ulcer treated with hemostatic spray as an adjunct to conventional endoscopic hemostatic measures between July 2013 and June 2015 were included in this retrospective analysis. The endpoints were initial hemostasis, 7-day rebleeding, 30-day rebleeding, all cause, and GI-related 30-day mortality.

Results: A total of 20 (median age 75 years, 50% men, 60% Forrest 1a ulcer) were treated with hemostatic spray as a second agent to adrenaline, or as an adjunct to the combination of adrenaline with either clips or a thermal device. Hemostatic spray was used as a second agent to adrenaline in 40% and as a third agent to combined dual therapy in 60%. Initial hemostasis was attained in 95% with an overall rebleeding rate at 7-day of 16%. There was no difference between 7-day and 30-day rebleeding rate. The combination of hemostatic spray and adrenaline resulted in 100% initial hemostasis and 25% 7-day rebleeding. Similarly, initial hemostasis was achieved in 92% with 9% rebleeding rate when hemostatic spray was used as the third agent to 2 of the conventional measures. All-cause mortality was 15% with one GI-related death (3%).

Conclusion: In our single-center retrospective analysis, hemostatic spray appears promising as an adjunct to conventional methods for NVUGIB, although prospective controlled trials are needed to confirm.

Keywords:

Hemospray, nonvariceal gastrointestinal bleeding, hemostatic powder

Introduction

Mortality associated with acute upper gastrointestinal bleeding remains high at 10%^{1, 2}. This figure has not changed appreciably since the 1950s in part due to an aging population. In a recent United Kingdom-wide audit, 1 in 4 patients with acute upper GI bleeding were aged over 80 years². Because mortality from upper GI bleeding increases steeply with age, peptic ulcer bleeding will continue to pose a significant therapeutic challenge³. Recent advances in endoscopic techniques have enabled effective hemostatic interventions to be deployed. The combination of adrenaline with a mechanical method (clips) or with a thermal device is the preferred strategy to achieve hemostasis^{4, 6}. Indeed, monotherapy with adrenaline has largely been superseded by this approach due to an unacceptably high rate of rebleeding⁷. However, in 10% to 20% of patients, rebleeding occurs despite initial hemostasis with combined therapy¹.

Hemostatic sprays are relatively new addition to the established hemostatic agents. Hemospray (Cook Medical, Winston-Salem, NC, USA is the first to be licensed in Europe, but it is not as yet FDA approved. It is a proprietary inorganic hemostatic powder approved for use in nonvariceal upper gastrointestinal bleed (NVUGIB). The powder is propelled through a carbon dioxide pressurized catheter fed through the working channel of an endoscope and sprayed at a distance of 1 to 2 cm from the bleeding site until a complete coating of the lesion and an obliteration of fresh blood is achieved. When put in contact with moisture (eg, blood or tissue) in the GI tract, the powder becomes cohesive and adhesive⁸. Its hemostatic mechanisms are 2-fold. First, it exerts a tamponade effect by forming a confluent mechanical barrier at the bleeding site. Second, it promotes thrombus formation by enhancing platelet aggregation and increasing the concentration of clotting factors⁹. Additionally, it has been shown to shorten coagulation time in vitro¹⁰.

The effect of hemostatic spray on hemostasis in NVUGIB cases so far has been encouraging. Initial hemostasis was achieved in 81% to 100% with rebleeding rate of 5-39%¹¹⁻¹⁵. However, most of these data were focused on the use of Hemospray as monotherapy. Moreover, the study populations are heterogeneous with respect to the underlying etiology. Data on the use of hemostatic spray as a second-line hemostatic agent to adrenaline or as an adjunct to combined therapy are limited. Intuitively, these strategies could offer a significant advantage; hemostatic spray may augment hemostasis achieved by standard therapy. This approach is attractive in cases in which the application of dual therapy is challenging. Adrenaline injection occasionally masks the bleeding lesion. More frequently, position of the ulcer renders the effective application of clips or heater probe impossible. Finally, the fibrous nature of the ulcer base or large size of a visible vessel may mean that attempting to apply clips or heater probe would be unlikely to succeed or potentially dangerous.

In this study, we evaluated the effect of this hemostatic spray on initial hemostasis, rebleeding rate, and mortality when used in high-risk patients with peptic ulcer bleed. Here, hemostatic spray was used as a second agent to adrenaline, or as an adjunct to the combination of adrenaline with either clips or a thermal contact device.

Methods

Study population

This retrospective analysis reviewed 30 consecutive patients who had been treated with hemostatic spray for GI bleeding between July 1, 2013 and June 30, 2015 in a large tertiary unit. One case of hemostatic spray application to lower GI bleeding, one case with incomplete clinical information and 4 cases with the following underlying causes: gastroesophageal carcinoma, Mallory Weiss tear without visible vessel, angiodysplasia, and pangastritis, were excluded. Four patients with Forrest 2a and 2b ulcers were excluded due to the small sample size.

The final analysis included the remaining 20 cases of Forrest 1a and 1b ulcers. Of these, one patient had post-ampullectomy GI bleeding, but a spurting arterial vessel was identified on the index gastroscopy. Similarly, another patient who had a Mallory Weiss tear was included in this group because a visible vessel was treated. The nature of the lesions in these 2 cases was akin to that of a peptic ulcer and therefore were considered as Forrest 1a and 1b, respectively. In these cases, hemostatic spray was used either as a second agent to adrenaline or as an adjunct to the combination of adrenaline with either clips or a thermal contact device.

The outcomes were as follows: initial hemostasis (defined as adequate hemostasis confirmed on observation and to the satisfaction of endoscopist), 7-day and 30-day rebleeding (defined as (1) clinical presentation of hematemesis or melaena; (2) hemodynamic instability; (3) drop in hemoglobin ≥ 2 g/L, blood transfusion of ≥ 4 units; necessitating further investigation such as repeat endoscopy or radiological intervention); all cause and GI bleed-related 30-day mortality; adverse event; and equipment failure relating to the use of hemostatic spray¹².

For comparison, we reviewed the outcomes of 20 consecutive patients with Forrest 1a and 1b ulcer who received conventional treatment before the introduction of hemostatic spray in our department between August 2010 and June 2013.

Patients were identified using the endoscopy logbook entries. Endoscopy report and clinical information were obtained from Unisoft (Unisoft Medical Systems, Enfield, UK) and Trakcare (Intersystem Corporation, Cambridge, Mass) respectively. Demographics, Rockall, and Blatchford scores, antiplatelet use, findings at endoscopy, endoscopic therapeutic interventions, use of proton pump inhibitor infusions, *Helicobacter pylori* status, and the study end points were recorded. All identifiable data were replaced with study identification numbers to preserve confidentiality. The use of these data was approved by the Confidentiality (Caldicott) Guardian for NHS Lothian.

This study was considered as a retrospective review by the local committee in our institution; hence, no formal ethical approval from the NHS Research Ethics Committee was necessary.

Clinical procedure

The choice of treatment was at the discretion of the attending endoscopist. All patients were adequately resuscitated before the endoscopic procedure. Hemostatic spray was used to achieve complete hemostasis if there was evidence of continued oozing after conventional therapy (adrenaline with either hemostatic clips or thermal devices). Similarly, hemostatic spray was used after adrenaline injection if the lesion was inaccessible for application of hemostatic clips or thermal devices. Hemostatic spray was delivered through a 10F catheter (Cook Medical, Winston-Salem, NC, USA) fed through the working channel of an endoscope (Olympus, Japan or FujiFilm, Japan). Adequacy of hemostasis was confirmed on observation of the treated lesion and to the satisfaction of the endoscopist. All patients received intravenous proton pump inhibitor infusion for 72 hours (Hong Kong regimen) after endoscopy.

Statistical analysis

Statistical analysis was performed using IBM SPSS for Macintosh version 22.0 (IBM Corporation, Armonk, NY, USA). Mann-Whitney *U* test was used to compare continuous variables between two populations. The Fisher exact test was used to compare categorical variables between 2 groups. Data are presented in median interquartile range (IQR) or frequency (percentage of the total study population). A 2-sided *P* value of less than .05 was considered to be statistically significant.

Results

Hemostatic spray group

A total 20 patients (median age 75 (IQR=11) years, men 50%) were included in the final analysis. Of these, 60% (12/20) had Forrest 1a and 40% (8/20) had Forrest 1b. The median Rockall score and Blatchford score were 8 (IQR = 2) and 14 (IQR = 6) respectively. Ten (50%) patients were on anti-platelet agents at the time of presentation.

Hemostatic spray was used as a second agent to adrenaline (AH) in 8 (40%) and as an addition to combined therapy (DH) in 12 (60%) patients (Table 1). The reasons for hemostatic spray application in the AH group were as follows: lesions in difficult site, suboptimal views, and concerns regarding perforation or torrential hemorrhage, all of which had precluded effective deployment of hemostatic clips or a thermal contact device. Hemostatic spray was used as a third agent with persistent oozing or in cases where the risk of rebleeding remained significant despite the conventional dual therapy. Descriptions of individual cases are provided in Supplementary Table 1.

Initial hemostasis and rebleeding

Initial hemostasis was achieved in 19 out of 20 (95%) cases. One patient (5%) who did not achieve initial hemostasis despite the use of hemostatic spray in the DH group subsequently had gastroduodenal artery embolization to achieve hemostasis. Seven-day rebleeding occurred in 16% (3/19; median day 0, IQR = 3). Rebleeding events in the AH and DH group were 25% (2/8) and 9% (1/11), respectively (Table 3). Two of the rebleeding cases were treated with gastroduodenal artery embolization. One patient was too frail for further intervention and subsequently died. There was no rebleeding recorded beyond day 7. Thus, the 30-day rebleeding remained at 15%.

Mortality

All-cause mortality at 30 days in the hemostatic spray group was 15% (3/20) (Table 3). GI bleed-related mortality at 30-day was 5% (1/20). Other causes of death were septicemia and aspiration pneumonia.

Rebleeding event and mortality according to the severity of bleed

Forrest 1a

Forty-two percent (5/12) of those with Forrest 1a lesions received hemostatic spray as a second line to adrenaline therapy (AH) (Table 3). In this group, initial hemostasis was achieved in 100%. However, rebleeding was noted in 40% (2/5). The 30-day mortality in this group was 20% (1/5). The remaining 58% (7/12) had hemostatic spray in conjunction with the combined therapy (DH). Of these, the initial hemostasis rate was 86% (6/7). Rebleeding occurred in 17% (1/6). There was no mortality in this group.

Forrest 1b

Thirty-eight percent (3/8) of patients with Forrest 1b lesions had AH therapy, with initial hemostasis of 100%, 0% rebleeding, and 0% 30-day mortality (Table 3). The remaining 62% (5/8) received DH therapy. Initial hemostasis was 100%, and there were no rebleeding episodes. However, 30-day mortality was 40% (2/5). One death was due to septicemia and another was due to aspiration pneumonia.

Other adverse events and technical failure with hemostatic spray

There was no significant hemostatic spray-related equipment failure. On occasion, it was necessary to use the second supplied catheter to achieve adequate therapy. This was due to blockage within the first catheter induced by moisture within the endoscope channel or the gut

lumen. The former can be minimized by vigorous flushing of the endoscope channel with air before catheter insertion. No other adverse event was observed.

Conventional therapy group outcomes (August 2010 to June 2013)

Baseline characteristics (age, gender, etiology, preceding anti-thrombotic use, Rockall and Blatchford scores) were similar in both groups (Table 2). Descriptions of individual cases are provided in Supplementary Table 2.

Initial hemostasis and rebleeding

Initial hemostasis with conventional strategies was achieved in 16 out of 20 (80%) and rebleeding occurred in 4 out of 16 (25%) and 5 out of 16 (31%) at 7 days and 30 days, respectively. Three out of 4 patients with failed initial hemostasis required emergency laparotomy. One died of ongoing bleeding. Three patients were treated with adrenaline monotherapy due to technical difficulties in deploying clips or thermal device. Rebleeding occurred in 2 out of 3 (67%) of these cases. Among those who received the standard dual therapy (adrenaline and hemostatic clips (AC) or adrenaline and a thermal device (AT)), initial hemostasis was achieved in 14 out of 17 (82%). The 30-day rebleeding rate of 21% (3/14) was comparatively higher than that seen with the combination of hemostatic spray and standard dual therapy (9%).

Mortality

The overall 30-day mortality with conventional therapy was 6 out of 20 (30%), and GI bleed-related death occurred in 3 out of 20 (15%).

Discussion

Our study examined the efficacy of Hemospray as a second agent to adrenaline and as a third agent to the combined therapy in high-risk patients with nonvariceal upper GI bleed. These patients were truly high risk with median Rockall and Blatchford scores of 8 and 14, respectively. In this context, our rationale was to use hemostatic spray to maximize the hemostatic effect. Our data highlight 2 important points. First, using this approach, hemostatic spray was effective in attaining initial hemostasis as evident by the favorable rate of 95%. Second, hemostatic spray offers a good protection against rebleeding. Indeed, the overall rebleeding rate in our cohort was 16%, and when used in combination dual conventional treatment modalities, the rebleeding rate was a mere 9%.

In this study, hemostatic spray was used as a second agent to adrenaline in 40% of cases in which the deployment of clips or thermal contact devices was not technically feasible. Initial hemostasis achieved in combination with adrenaline was 100%, even in high-risk lesions. Importantly, the rebleeding rate of 25% in Forrest 1a and Forrest 1b ulcers with this combination was better than that seen with adrenaline monotherapy for similar lesions^{16, 17}. When compared with our previous experience in a group of patients with Forrest 1a and 1b lesions before introduction of hemostatic spray in our unit, rebleeding occurred in 67% when the therapeutic option was technically limited to adrenaline monotherapy. Therefore, hemostatic spray may be a viable alternative for lesions inaccessible to hemostatic methods which require precise targeting. To this end, hemostatic spray can be applied without direct mucosal contact or en face view of a lesion. Prior injection of adrenaline can provide an immediate clear visualization for a targeted application of hemostatic spray and complement its hemostatic effect. Thus, hemostatic spray

offers ease of application, particularly in technically challenging cases. It obviates the need for more advanced techniques such as the use of a duodenoscope or a cap-assisted approach, for which the required skills may not be widely available.

Sustained hemostasis with a combination of hemostatic spray and adrenaline in our cohort was comparatively lower than that reported with conventional measures, particularly for Forrest 1a ulcers¹⁸⁻²². It is of interest that although Hemospray has been licensed as monotherapy for NVUGIB, its efficacy in Forrest 1a lesions has not been adequately studied. Our center experience of hemostatic spray as monotherapy was limited to a single case where it was successfully used to control a significant bleeding episode from pancreatitis. In a porcine model, hemostatic spray induces 100% hemostasis with 20% rebleeding within 24 hours¹⁹. These findings were corroborated by subsequent clinical studies. For example, Sung et al¹² achieved 95% initial hemostasis with 85% sustained hemostasis at 72 hours in patients with Forrest 1a and 1b ulcers. Likewise, Smith et al¹¹ reported initial hemostasis in 85% and a rebleeding rate of 15% using hemostatic spray as monotherapy. However, in a subsequent case series, the rate of rebleeding with hemostatic spray monotherapy was considerable prompting authors to recommend either a second re-look or prolonged hospital observation²³. This raises the question as to whether hemostatic spray as monotherapy is a cost-effective approach. This was addressed in a recent study, which showed that the combination of hemostatic spray with conventional hemostatic measures was more cost-effective than hemostatic spray as monotherapy²⁴. In a recent case series, the use of hemostatic spray as monotherapy in Forrest 1a lesions was associated with 100% rebleeding necessitating further endotherapy or interventional radiology²⁵. Therefore, the available evidence currently suggests that hemostatic spray monotherapy is unlikely to replace conventional hemostatic therapy.

In our series, hemostatic spray was used as an adjunct to the standard dual therapy in cases where the risk of rebleeding was deemed to be significant. This triple therapy approach resulted in the overall initial hemostasis of 92% with the rebleeding rate of 9%. Even among those with Forrest 1a, the initial hemostasis and the rebleeding rate were encouraging. Furthermore, in Forrest 1a and 1b lesions, the rebleeding rate of 9% was comparatively less than the rebleeding rate reported with the conventional approaches for similar lesions^{13, 17, 26}. Indeed, the hemostatic effect with the triple therapy surpassed the initial hemostasis of 82% and the rebleeding rate of 21% previously observed with the conventional dual therapy in our institution. This effect might be explained by the ability of hemostatic spray to cover large areas and address multiple bleeding points from feeding vessels simultaneously. It could be surmised that the spray provides a sealant barrier that complements tamponade, vasoconstriction, and mechanical or thermal coagulation resulting from conventional combination therapy.

Similar to the findings of a recent United Kingdom-wide audit, our cohort was elderly with median age of 75 years and the mortality observed was largely related to decompensation of comorbid conditions². One GI bleed-related death was attributable to a duodenal ulcer that had rebled. In this case, no further intervention was deemed appropriate due to significant frailty. In our study, there was no difference in mortality when hemostatic spray was used as an adjunct to adrenaline or incorporated into the standard combination therapy. Even though there have been reports of perforated viscus, biliary orifice obstruction, and splenic infarct associated with the use of hemostatic spray, we did not observe any adverse events in our cohort^{14, 27}.

This study has several limitations. The retrospective nature precludes a comparison of the efficacy of hemostatic spray as monotherapy compared with its adjuvant use to dual therapy.

Cases were highly selected and treatment was at the discretion of the endoscopist rather than directed by a specific protocol. Data regarding the exact amount of hemostatic spray applied are unavailable. Our case series, albeit small, is the largest to date that reports the complementary role of hemostatic spray, either as a second agent after adrenaline injection or as a third agent after conventional dual therapy in high-risk nonvariceal upper GI bleeding.

In conclusion, our data support the use of hemostatic spray in high-risk peptic ulcer bleeding, particularly when the application of additional hemostatic agents after adrenaline injection may not be technically feasible. Its use as an adjunct can be considered when primary hemostasis is not achieved with standard combination therapy. Whether it can replace conventional measures remains to be seen and its role in additionally securing hemostasis in high-risk patients remains unclear. Future prospective randomized controlled trials comparing hemostatic spray alone and in various combinations with conventional therapies in high-risk bleeding lesions are required to establish its optimal place in the hemostatic armamentarium.

REFERENCES

1. Rollhauser C, Fleischer DE. Current status of endoscopic therapy for ulcer bleeding. *Baillieres Best Pract Res Clin Gastroenterol* 2000;14:391-410.
2. Hearnshaw SA, Logan RF, Lowe D, et al. Acute upper gastrointestinal bleeding in the UK: patient characteristics, diagnoses and outcomes in the 2007 UK audit. *Gut* 2011;60:1327-35.
3. Rockall TA, Logan RF, Devlin HB, et al. Incidence of and mortality from acute upper gastrointestinal haemorrhage in the United Kingdom. Steering Committee and members of the National Audit of Acute Upper Gastrointestinal Haemorrhage. *BMJ* 1995;311:222-6.
4. Marmo R, Rotondano G, Piscopo R, et al. Dual therapy versus monotherapy in the endoscopic treatment of high-risk bleeding ulcers: a meta-analysis of controlled trials. *Am J Gastroenterol* 2007;102:279-89; quiz 469.
5. Sung JJ, Tsoi KK, Lai LH, et al. Endoscopic clipping versus injection and thermo-coagulation in the treatment of non-variceal upper gastrointestinal bleeding: a meta-analysis. *Gut* 2007;56:1364-73.
6. Gralnek IM, Dumonceau JM, Kuipers EJ, et al. Diagnosis and management of nonvariceal upper gastrointestinal hemorrhage: European Society of Gastrointestinal Endoscopy (ESGE) Guideline. *Endoscopy* 2015;47:a1-46.
7. Vergara M, Bennett C, Calvet X, et al. Epinephrine injection versus epinephrine injection and a second endoscopic method in high-risk bleeding ulcers. *Cochrane Database Syst Rev* 2014;10:CD005584.

8. Barkun AN, Moosavi S, Martel M. Topical hemostatic agents: a systematic review with particular emphasis on endoscopic application in GI bleeding. *Gastrointest Endosc* 2013;77:692-700.
9. Giday SA. Preliminary Data on the nanopowder Hemostatic Agent TC-325 to control gastrointestinal bleeding. *Gastroenterol Hepatol (N Y)* 2011;7:620-2.
10. Holster IL, van Beusekom HM, Kuipers EJ, et al. Effects of a hemostatic powder Hemospray on coagulation and clot formation. *Endoscopy* 2015;47:638-45.
11. Smith LA, Stanley AJ, Bergman JJ, et al. Hemospray application in nonvariceal upper gastrointestinal bleeding: results of the survey to evaluate the application of Hemospray in the luminal tract. *J Clin Gastroenterol* 2014;48:e89-92.
12. Sung JJ, Luo D, Wu JC, et al. Early clinical experience of the safety and effectiveness of Hemospray in achieving hemostasis in patients with acute peptic ulcer bleeding. *Endoscopy* 2011;43:291-5.
13. Masci E, Arena M, Morandi E, et al. Upper gastrointestinal active bleeding ulcers: review of literature on the results of endoscopic techniques and our experience with Hemospray. *Scand J Gastroenterol* 2014;49:1290-5.
14. Yau AH, Ou G, Galorport C, et al. Safety and efficacy of Hemospray(R) in upper gastrointestinal bleeding. *Can J Gastroenterol Hepatol* 2014;28:72-6.
15. Holster IL, Kuipers EJ, Tjwa ET. Hemospray in the treatment of upper gastrointestinal hemorrhage in patients on antithrombotic therapy. *Endoscopy* 2013;45:63-6.
16. Lin HJ, Hsieh YH, Tseng GY, et al. Endoscopic injection with fibrin sealant versus epinephrine for arrest of peptic ulcer bleeding: a randomized, comparative trial. *J Clin Gastroenterol* 2002;35:218-21.
17. Pescatore P, Jornod P, Borovicka J, et al. Epinephrine versus epinephrine plus fibrin glue injection in peptic ulcer bleeding: a prospective randomized trial. *Gastrointest Endosc* 2002;55:348-53.
18. Chung I-K, Ham J-S, Kim H-S, et al. Comparison of the hemostatic efficacy of the endoscopic hemoclip method with hypertonic saline and epinephrine injection and a combination of the two for the management of bleeding peptic ulcers. *Gastrointestinal Endoscopy*;49:13-18.

19. Giday SA, Kim Y, Krishnamurty DM, et al. Long-term randomized controlled trial of a novel nanopowder hemostatic agent (TC-325) for control of severe arterial upper gastrointestinal bleeding in a porcine model. *Endoscopy* 2011;43:296-9.
20. Chung SS, Lau JY, Sung JJ, et al. Randomised comparison between adrenaline injection alone and adrenaline injection plus heat probe treatment for actively bleeding ulcers. *BMJ* 1997;314:1307-11.
21. Lin HJ, Tseng GY, Perng CL, et al. Comparison of adrenaline injection and bipolar electrocoagulation for the arrest of peptic ulcer bleeding. *Gut* 1999;44:715-9.
22. Park CH, Joo YE, Kim HS, et al. A prospective, randomized trial comparing mechanical methods of hemostasis plus epinephrine injection to epinephrine injection alone for bleeding peptic ulcer. *Gastrointest Endosc* 2004;60:173-9.
23. Dixon S, Tate D, Przemioslo R, et al. PTH-034 Hemospray may not reliably achieve hemostasis beyond 48 hours in acute upper gastrointestinal bleeding. *Gut* 2015;64:A420-A421.
24. Barkun AN, Adam V, Chen Y-I, et al. Tu1736 The cost-effectiveness of hemospraytm in patients with non variceal upper gastrointestinal bleeding [abstract]. *Gastrointestinal Endoscopy* 2015;81:AB576-AB577.
25. Nasr I, De Martino S, Borrow D-M, et al. PWE-007 When to use hemospray? a single centre experience. *Gut* 2015;64:A212-A213.
26. Chau CH, Siu WT, Law BK, et al. Randomized controlled trial comparing epinephrine injection plus heat probe coagulation versus epinephrine injection plus argon plasma coagulation for bleeding peptic ulcers. *Gastrointest Endosc* 2003;57:455-61.
27. Smith LA, Morris J, Stanley AJ. PWE-054 Preliminary Experience of Hemospray in the Management of Diffuse Portal Hypertensive Bleeding. *Gut* 2013;62:A152-A153.
28. Forrest JA, Finlayson ND, Shearman DJ. Endoscopy in gastrointestinal bleeding. *Lancet* 1974;2:394-7.
29. Peter S, Wilcox CM. Modern endoscopic therapy of peptic ulcer bleeding. *Dig Dis* 2008;26:291-9.
30. Laine L, Peterson WL. Bleeding peptic ulcer. *N Engl J Med* 1994;331:717-27.

Legends

Figure 1: Forrest 1a duodenal ulcer

Figure 2: Forrest 1a duodenal ulcer after a triple therapy (a combination of adrenaline, thermal device and hemostatic spray)

Video Legend

A 76-year-old woman with cardio-respiratory comorbidity had presented with major peptic ulcer bleeding 2 weeks previously. She remained in intensive care after a laparotomy and under-running of a duodenal ulcer after failure of endoscopic hemostasis. After further bleeding and cardiovascular instability developed, gastroscopy under general anesthetic was performed. The surgical team felt she would not survive a second laparotomy.

The site of bleeding was a visible vessel in a high lesser curve gastric ulcer previously obscured by fundal clot. Circumferential adrenaline injection was performed to a total of 28 mL. The needle can be seen to puncture the feeding vessel during circumferential injection. The heater probe was used at 30J power setting to cavitate around the visible vessel. It was decided not to treat the vessel directly due to the high risk of precipitating torrential hemorrhage. The vessel began to actively ooze during therapy. Clips would not have been an option due to the chronic fibrous ulcer base. Therefore, hemostatic spray was used to effect hemostasis. The patient underwent a semi-urgent left gastric artery embolization the following day and was successfully discharged home 2 months later.

Clinical characteristics	Adrenaline + hemostatic spray (AH) <i>n</i> =8	Dual therapy + hemostatic spray (DH) <i>n</i> =12	<i>P</i> value
Age (years)	75	71	0.73
Women	3	7	0.65
Rockall score	8	8	0.75
Blatchford score	14	15	0.51
Use of antithrombotic therapy	5	5	0.64
Pathology			0.65
Duodenal ulcer	4	8	
Esophageal ulcer	3	1	
Dual pathology	0	1	
Gastric ulcer	0	1	
Others*	1	1	

*Others: Mallory Weiss with visible vessel, ampullectomy with arterial spurt.

Data presented as median (IQR) or *n*.

Table 1: Demographics and clinical characteristics of patients treated with hemostatic spray.

Clinical characteristics	Hemostatic spray group (July 2013- August 2015) <i>n</i> =20	Conventional therapy (August 2010 – June 2013) <i>n</i> =20	<i>P</i> value
Age (years)	75 (11)	73 (21)	0.72
Women	10	9	1.00
Rockall score	8 (2)	7 (3)	0.30
Blatchford score	14 (6)	14 (4)	0.82
Use of antithrombotic therapy	10	12	0.75

Data presented as median (IQR) or *n*.

Table 2: Clinical characteristics of patients with Forrest 1a and 1b ulcers in hemostatic spray and conventional therapy

Forrest classification	Hemostatic spray treatment (July 2013 – August 2015)						Conventional treatment (August 2010 – June 2013)				Risk of rebleeding after endoscopic treatment ²⁸ in literature	
	Study population <i>n</i> (%)		Initial hemostasis <i>n</i> (%)	7-day rebleeding <i>n</i> (%)	Mortality 30-day <i>n</i> (%)	Study population <i>n</i> (%)	Initial hemostasis <i>n</i> (%)	7-day rebleeding <i>n</i> (%)	Mortality 30-day <i>n</i> (%)			
1a	12 (60)	AH	5 (42)	5 (100)	2 (40)	1 (20)	A	0 (0)	0 (0)	-	0 (0)	0-69% ^{13, 29, 30}
		DH	7 (58)	6 (86)	1 (17)	0 (0)	D	12 (100)	9 (75)	1 (11) 2* (22)	2 (22)	
1b	8 (40)	AH	3 (38)	3 (100)	0 (0)	0 (0)	A	3 (38)	2 (66)	2 (100)	3 (100)	0-25% ^{13, 29}
		DH	5 (62)	5 (100)	0 (0)	2 (40)	D	5 (62)	5 (100)	1 (20)	1 (20)	

AH, adrenaline plus hemostatic spray; DH, conventional dual therapy plus hemostatic spray; A, adrenaline alone; D, conventional dual therapy (a combination of adrenaline with hemostatic clips or a thermal device); * 30-day rebleeding.

Table 3: Initial hemostasis, rebleeding events, and 30-day mortality stratified according to the Forrest classification in hemostatic spray and conventional treatment groups

No	Age (years)	Sex	Rockall score	Blatchford score	ATT	Etiology	Forrest classification	Endoscopic treatment	Initial hemostasis	Rebleeding	Outcome
1	81	M	10	7	Yes	Duodenal ulcer	1b	DH	Yes	no	survived 30 days
2	70	F	9	16	No	Duodenal ulcer	1a	DH	No; embolized	no	survived 30 days
3	84	M	10	16	Yes	Duodenal ulcer	1a	DH	Yes	no	survived 30 days
4	87	F	9	8	Yes	Dual pathology	1b	DH	Yes	no	Non-GI bleed related death
5	55	M	5	10	No	Duodenal ulcer	1a	DH	Yes	no	survived 30 days
6	86	F	9	19	No	Duodenal ulcer	1a	AH	Yes	Day 0; too frail for treatment	GI bleed death
7	71	F	8	15	Yes	Duodenal ulcer	1a	DH	Yes	no	survived 30 days
8	75	F	6	9	No	Esophageal ulcer	1a	AH	Yes	no	survived 30 days
9	52	F	8	15	No	Esophageal ulcer	1b	DH	Yes	no	Non-GI bleed related death
10	68	F	6	17	No	Duodenal ulcer	1a	DH	Yes	Yes; Day 6 - embolization	survived 30 days
11	64	M	8	9	Yes	Esophageal ulcer	1b	AH	Yes	no	survived 30 days
12	74	M	8	14	Yes	Duodenal	1b	AH	Yes	no	survived 30

						ulcer					days
13	56	M	5	13	Yes	Duodenal ulcer	1a	AH	Yes	no	survived 30 days
14	76	F	6	15	Yes	Duodenal ulcer	1a	AH	Yes	Yes; Day 0 - embolization	survived 30 days
15	76	F	6	17	No	Gastric ulcer	1b	DH	Yes	no	survived 30 days
16	27	M	4	10	No	Duodenal ulcer	1a	DH	Yes	no	survived 30 days
17	76	M	8	12	Yes	Esophageal ulcer	1b	AH	Yes	no	survived 30 days
18	75	M	8	14	No	Ampullectomy	1a	AH	Yes	no	survived 30 days
19	79	M	6	17	No	Mallory-Weiss	1b	DH	Yes	no	survived 30 days
20	66	F	8	14	Yes	Duodenal ulcer	1a	DH	Yes	no	survived 30 days

F, Female; M, Male; ATT, Antithrombotic therapy; AH, adrenaline plus hemostatic spray; DH, conventional dual therapy plus hemostatic spray; GI, gastrointestinal

Supplementary Table 1: Endoscopic treatment and outcomes of 20 consecutive patients with Forrest 1a and 1b ulcers treated with hemostatic spray from July 2013 to August 2015.

No	Age (years)	Sex	Rockall score	Blatchford score	ATT	Etiology	Forrest classification	Endoscopic treatment	Initial hemostasis	Rebleeding	Outcome
1	73	F	9	16	yes	Duodenal ulcer	1b	A	Yes	Day 1; treated endoscopically	GI bleed death
2	68	M	6	14	yes	Duodenal ulcer	1b	AT	Yes	Day 6; treated endoscopically	survived 30 days
3	84	M	7	12	yes	Duodenal ulcer	1b	AC	Yes	no	Non-GI bleed death
4	55	M	5	12	no	Duodenal ulcer	1a	AC	No – proceeded to laparotomy	no	survived 30 days
5	86	F	9	20	yes	Duodenal ulcer	1b	AT	Yes	no	survived 30 days
6	71	M	6	12	yes	Duodenal ulcer	1b	A	Yes	Day 1; treated endoscopically	Non-GI bleed death
7	91	F	7	17	no	Duodenal ulcer	1b	A	No	no	GI bleed death
8	52	M	4	13	yes	Duodenal ulcer	1b	AT	Yes	no	survived 30 days
9	86	F	9	15	yes	Gastric ulcer	1b	AT	Yes	no	survived 30 days
10	58	F	5	9	no	Duodenal ulcer	1a	AT	No – proceeded to laparotomy	no	survived 30 days
11	74	M	6	10	yes	Duodenal ulcer	1a	AT	Yes	no	survived 30 days
12	64	F	8	12	no	Sphincterotomy	1a	AC	Yes	no	survived 30 days
13	72	F	4	14	no	Duodenal ulcer	1a	AC	Yes	no	survived 30 days
14	50	M	3	11	no	Duodenal ulcer	1a	AT	Yes	no	survived 30 days
15	79	F	9	17	no	Duodenal ulcer	1a	AC	Yes	Day 8; too frail for treatment	GI bleed death
16	71	F	6	13	no	Duodenal ulcer	1a	AT	No – proceeded to	no	Non-GI bleed

									laparotomy		death
17	89	M	9	16	yes	Duodenal ulcer	1a	AT	Yes	no	survived 30 days
18	62	M	8	16	yes	Duodenal ulcer	1a	AT	Yes	no	survived 30 days
19	91	M	7	14	yes	Duodenal ulcer	1a	AT	Yes	no	survived 30 days
20	77	M	6	15	yes	Duodenal ulcer	1a	AT	Yes	Day 2; treated endoscopically	survived 30 days

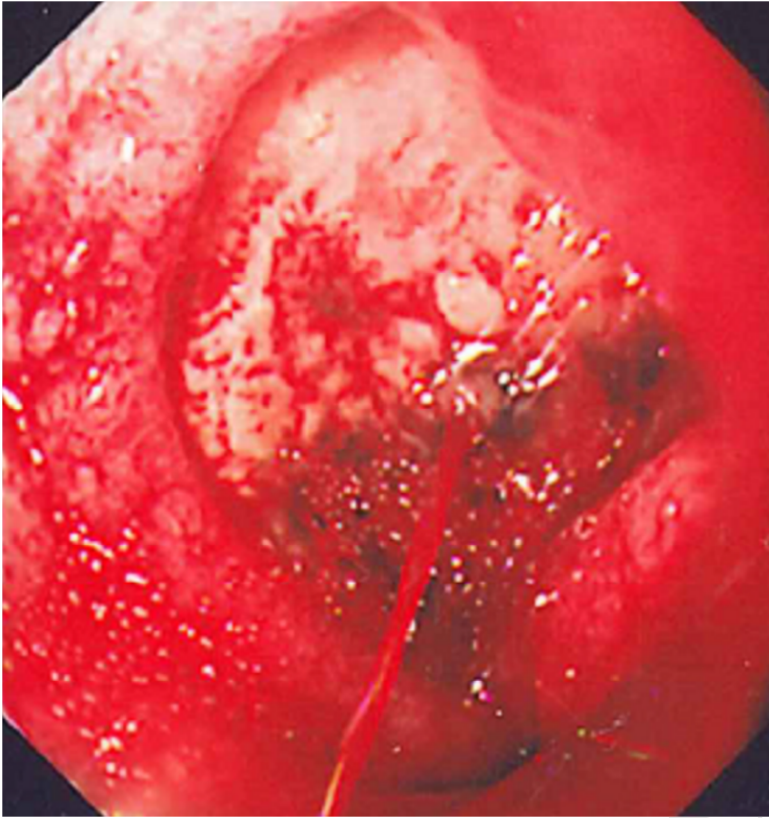
F, Female; M, Male; ATT, Antithrombotic therapy; A, adrenaline only; AT, adrenaline plus a thermal device; AC, adrenaline plus hemostatic clip; GI, gastrointestinal

Supplementary Table 2: Endoscopic treatment and outcomes of 20 consecutive patients with Forrest 1a and 1b ulcers from August 2010 to June 2013 before the introduction of hemostatic spray.

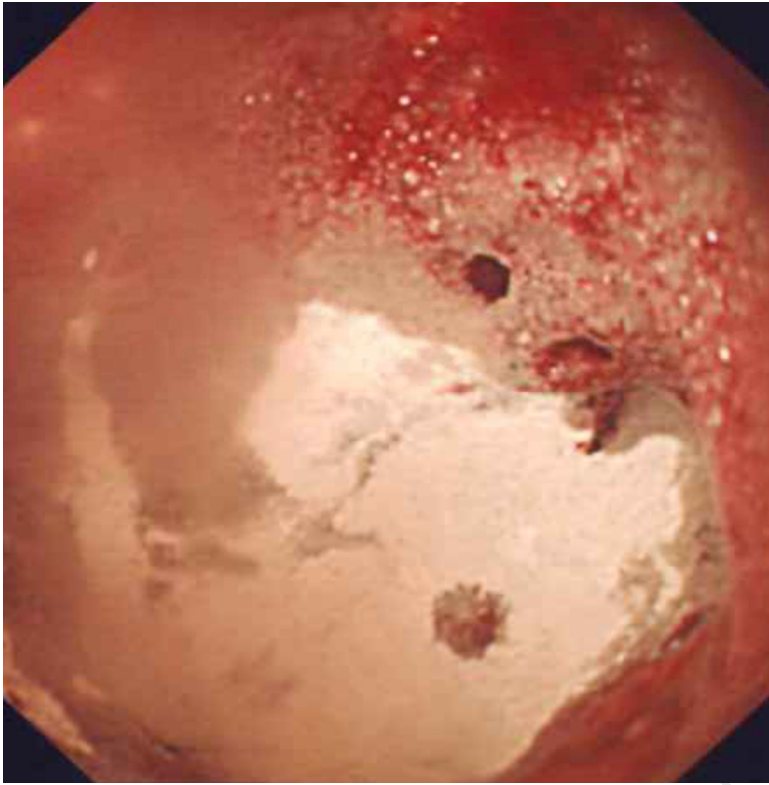
No. of subjects	Lesion	Initial hemostasis (%)	7-day re-bleeding (%)	30-day mortality (%)	Reference
10	Spurting vessel*	100	0	NA	19
20	Forrest 1a and 1b	95	11	0	12
7	Forrest 1a and 1b	100	14	NA	13
16	Forrest 1a and 1b	-	19	NA	11
12	Forrest 1a and 1b	58	29 [±]	NA	25

*In animal (pig) model; NVUGIB, nonvariceal upper gastrointestinal bleed; [±]Unsustained primary hemostasis; NA, not available

Supplementary Table 3: Previous studies on hemostatic spray as a monotherapy in high-risk NVUGIB.



ACCEPTED MANUSCRIPT



ACCEPTED MANUSCRIPT

Authors' contribution

Contribution: RS collected, analysed the data and wrote manuscript. KAL and NIC advised on manuscript, presentation and DICOM file contribution. JNP and PCH conceptualized the idea and edited the manuscript.

Conflict of interest: The authors do not have any conflict of interest to declare.

Acknowledgement: Authors acknowledge and thank Mrs Anita Talbot for identification of cases through endoscopy log-book record.

List of Acronyms

AH	Adrenaline plus Hemospray [®]
DH	Dual therapy plus Hemospray [®]
Fr	French
GI	Gastrointestinal
IQR	Interquartile Range
NHS	National Health Service
NVUGIB	Non Variceal Upper Gastrointestinal Bleed