

We are IntechOpen, the world's leading publisher of Open Access books Built by scientists, for scientists

4,800

Open access books available

122,000

International authors and editors

135M

Downloads

Our authors are among the

154

Countries delivered to

TOP 1%

most cited scientists

12.2%

Contributors from top 500 universities



WEB OF SCIENCE™

Selection of our books indexed in the Book Citation Index
in Web of Science™ Core Collection (BKCI)

Interested in publishing with us?
Contact book.department@intechopen.com

Numbers displayed above are based on latest data collected.
For more information visit www.intechopen.com



Hypothenar Muscles and Guyon's Canal

Georgi P. Georgiev

Abstract

The increased number of articles in the last years about hypothenar variations and some misdescriptions and the role of the additional structures to ulnar nerve and artery compression, as well as my unostentatious contribution in the field, provoked me to write this chapter. The aim of it is to present in detail the usual hypothenar muscular anatomy, including the origins and insertions of the hypothenar muscles, their relations to each other, the vascular supply and innervation, the function of the muscles, the reported variations and their possible clinical implications. Herein, I also presented briefly the Guyon's canal anatomy and some interesting comments about it. Presenting the compendium about hypothenar muscles and the canal to my opinion will help the anatomists and the clinicians to better understand the clinically oriented anatomy. They also will be more qualified in the anatomical dissection course as well as during the surgical interventions. The detailed knowledge of the anatomy in the region would be also useful to medical students in better understanding the hypothenar region.

Keywords: hypothenar muscles, anatomy, variations, Guyon's canal, clinical significance

1. Introduction

Muscular variations of the hypothenar have been well described in the medical literature [1–3]. In most cases, these muscles are asymptomatic and are found during anatomical dissections, surgical interventions or imaging modalities. In some cases, variant hypothenar muscles may cause ulnar nerve and artery compression, as presented in some surgical case reports [4–10]. Shea and McClain [11] reported that around 3% of compression neuropathies are due to variant muscle.

At the region of the wrist, the ulnar nerve passes through a fibro-osseous tunnel known as “Guyon's canal” or “distal ulnar tunnel”, in which the ulnar nerve could be compressed [4, 6, 8, 12–14]. Different causes as trauma, lipoma, false aneurysm of the ulnar artery, ganglion cyst and rarely aberrant muscular slips have been reported [3, 15]. In some surgical reports, different variant muscles, usually abductor digiti minimi, followed by flexor digiti minimi brevis have been reported, as a cause of ulnar nerve compression [4, 6, 8, 12–14]. In all cases the excision of the additional muscle was curative. However, it should be pointed out that the clinical appearance of the variant muscles should be related to two factors: the anatomical site and the muscle hypertrophy [4]. According to Turner and Caird [16],

a provoking factor, such as acute injury or repetitive minor trauma, as well as the type of the work, could predispose to hypertrophy of the variant muscles. There are reports of ulnar nerve compression syndromes provoked by anomalous muscles in which additional factors exist [1, 4, 17]. In addition to nerve compression, a hypothenar muscle variation could be also associated with thrombosis of the ulnar artery in Guyon's canal [7, 18].

In recent years the increased interest and numerous articles about hypothenar variants and Guyon's canal provoke me to make a brief review and make a compendium of normal anatomy of the muscles in the hypothenar region as well to present the reported variations and their possible clinical significance. I hope that this chapter will make future studies on this theme easier and help anatomist, hand surgeons and medical students for better knowledge of anatomy and for better clinical practice.

2. Anatomy, variations and clinical significance

2.1 Palmaris brevis muscle (Pbm)

Pbm is a small cutaneous hand muscle, located superficially to the hypothenar eminence and considered to be atavistic remnant of the panniculus carnosus. The Pbm is usually presented by a thin, quadrilateral in form muscle body, lying beneath the skin of the ulnar aspect of the palm. It has been reported to start from the flexor retinaculum and palmar aponeurosis and insert in the skin and fascia of the medial palm (**Figure 1**) [19–24].

2.1.1 Variations

The variations of the Pbm are rarely reported in the literature. This muscle could vary in size and may be absent or duplicated; it could also insert to flexor digiti minimi brevis muscle or the pisiform bone [25, 26].

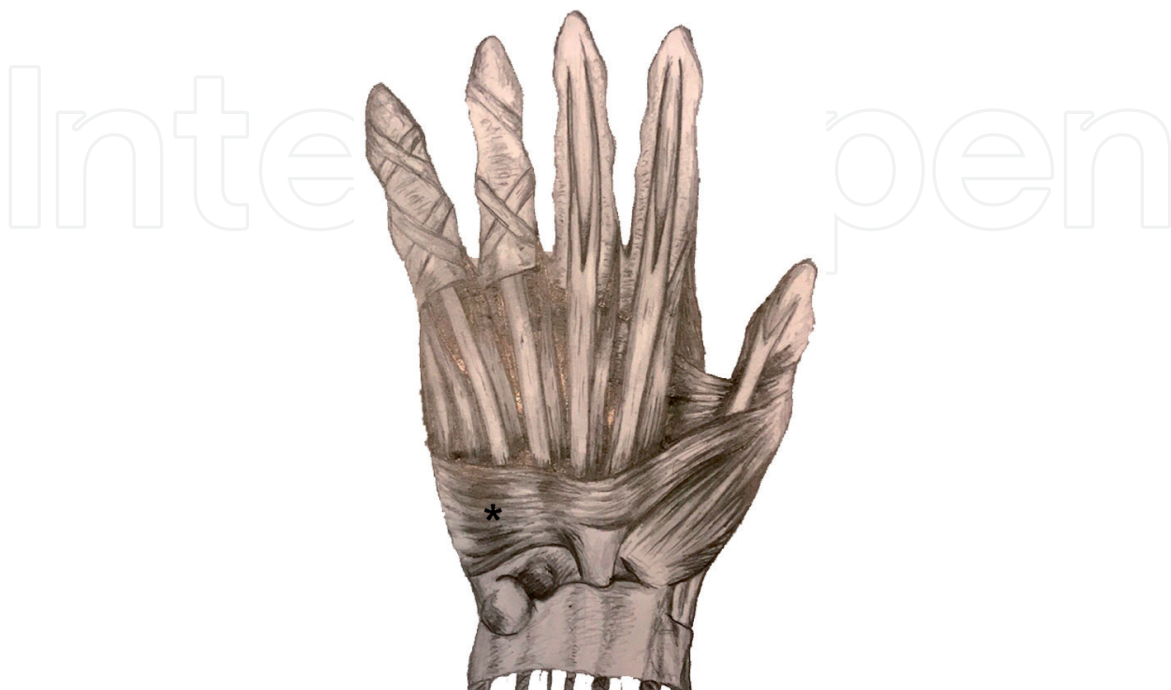

Figure 1.
Schematic anterior view of the wrist and hand presenting the Pbm (asterisk).

2.1.2 Clinical application

This muscle and its variants could simulate soft tissue tumor [27] or provoke ulnar nerve compression at the wrist [17, 28]; Pbm flap could be used in the treatment of recurrent carpal tunnel syndrome [29] and Pbm spasm syndrome [30].

2.1.3 Actions

Pbm deepens the hollow of the palm and presents muscular barrier of the ulnar neurovascular bundle at the wrist [21].

2.1.4 Innervation

The Pbm is innervated by the motor component of the superficial branch of the ulnar nerve [24].

2.2 Abductor digiti minimi muscle (ADMm)

The ADMm is situated more ulnarly of the hypothenar muscles and arises from the pisiform bone and from the tendon of the flexor carpi ulnaris muscle; it attaches as a flat tendon that finally divides into two parts: one that inserts to the ulnar side of the base of the proximal phalanx of the little finger and the other to the ulnar border of the aponeurosis of the extensor digiti quinti proprius (**Figure 2**) [20, 21].

2.2.1 Variations

Different variations of ADMm have been reported in the anatomical and surgical literature. They include the absence and presence of a second head, variant origin (from the pisiform bone, fascia of the forearm, palmaris longus tendon,

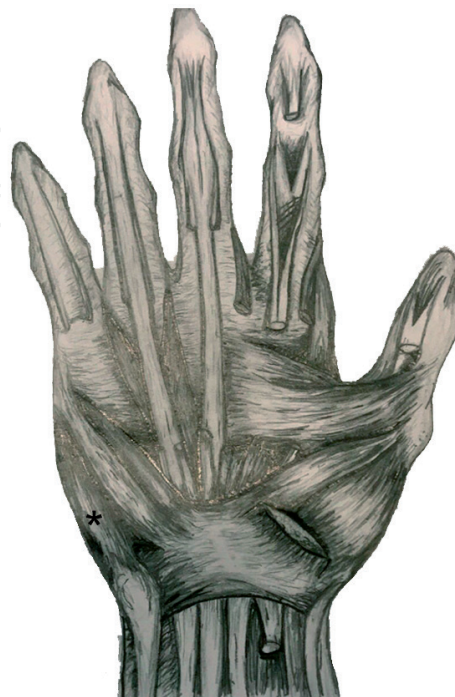


Figure 2.
Schematic anterior view of the wrist and hand presenting the ADMm (asterisk).

fascia of the flexor carpi radialis, intermuscular fascia, flexor carpi ulnaris, flexor retinaculum, both from the flexor retinaculum and antebrachial fascia), fusion with the flexor digiti minimi brevis, presence of a “deep abductor-flexor” (m. abductor-flexor digiti minimi profundus), triple origin and also coexistence with reversed palmaris longus muscle [4, 5, 9, 15, 25–27, 31–38].

2.2.2 Clinical application

Hypertrophied ADMm could simulate soft tissue tumor [5] or ulnar nerve compression at the wrist [13, 14] and may be associated with ulnar artery thrombosis in Guyon’s canal [7]; ADMm myocutaneous flap can be used for opponensplasty [39].

2.2.3 Actions

The ADMm abducts the little finger from the ring finger and contributes to the fifth metacarpophalangeal joint flexion and interphalangeal extension [20, 21].

2.2.4 Innervation

ADMm is innervated by the deep branch of the ulnar nerve (C8, Th1) [20, 21].

2.3 Flexor digiti minimi brevis muscle (FDMBm)

The FDMBm is situated more radially than the ADMm. It starts from the hamulus of the hamate bone, and the anterior surface of the flexor retinaculum, and inserts into the ulnar side of the base of the phalanx of the little finger (**Figure 3**) [20, 21].

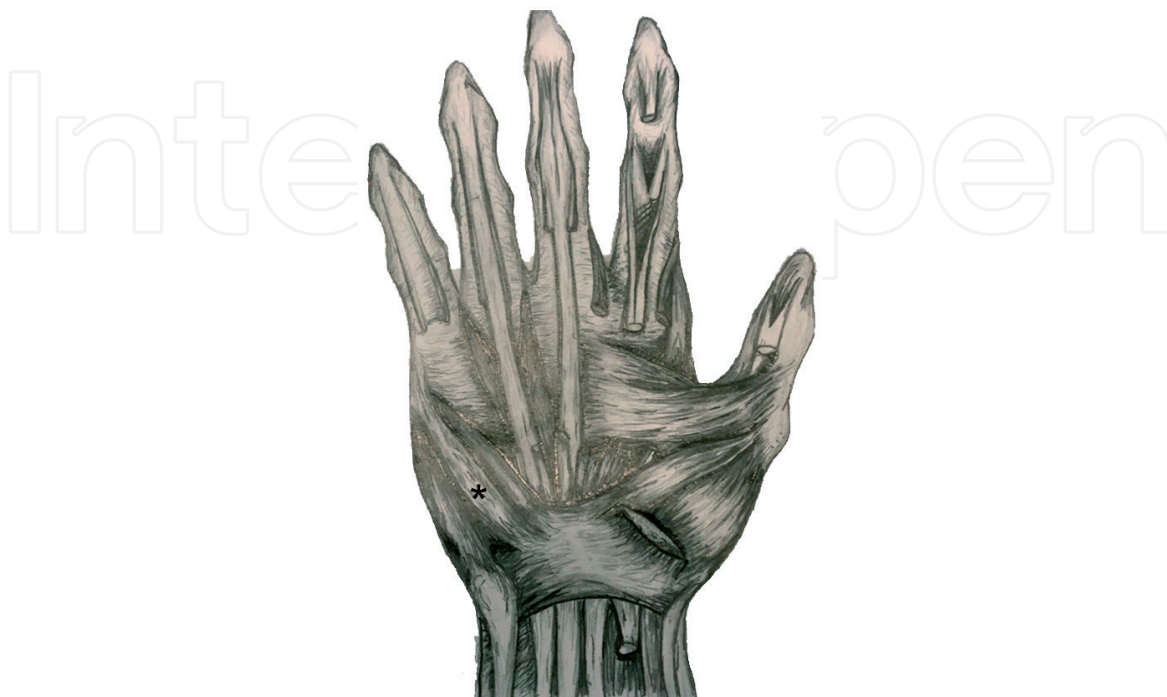

Figure 3.
Schematic anterior view of the wrist and hand presenting the FDMBm (asterisk).

2.3.1 Variations

The reported variations of the FDMBm in the available literature are absence and presence of an accessory slip from the palmaris longus tendon, presence of a slip to the metacarpal, replacement by a tendinous band arising from the flexor carpi ulnaris muscle and inserting into the fifth proximal phalanx and the hamate bone, presence of accessory FDMBm, fusion with ADMm or opponens digiti minimi muscles, origin from the antebrachial fascia, deep abductor-flexor of little finger, FDMBm with triple origin and origin from flexor carpi radialis muscle [25, 26, 33, 40–43].

2.3.2 Clinical application

Hypertrophied FDBMm could simulate soft tissue tumor [44] or ulnar nerve compression at the wrist [8, 12].

2.3.3 Actions

The FDBMm flexion of the proximal phalanx, also with some lateral rotation [20, 21].

2.3.4 Innervation

FDBMm is innervated by the deep branch of the ulnar nerve (C8, Th1) [20, 21].

2.4 Opponens digiti minimi muscle (ODMm)

The ODMm has a triangular form, lying beneath the ADMm and FDMBm. It starts from the hamulus of the hamate bone and near part of the flexor retinaculum and attaches to the ulnar margin and palmar surface of the fifth metacarpal bone (**Figure 4**) [20, 21].

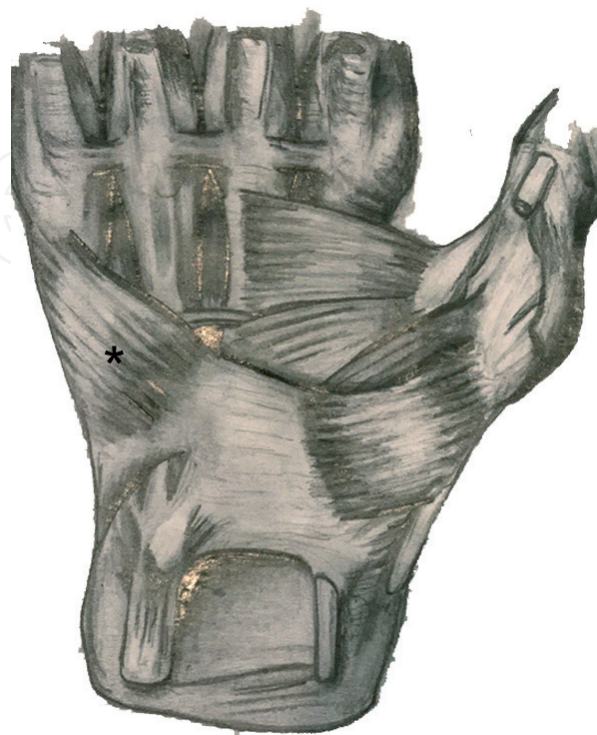

Figure 4.
Schematic anterior view of the wrist and hand presenting the ODMm (asterisk).

2.4.1 Variations

The reported variations of the ODMm are rarely described in the literature and include absence, splitting into two parts and merging with ADMm [25, 26].

2.4.2 Clinical application

There is no clinical application reported.

2.4.3 Innervation

The ODMm is innervated by the deep branch of the ulnar nerve (C8, Th1) [20, 21].

2.4.4 Actions

The ODMm flexes and laterally rotates the fifth metacarpal bone at the carpo-metacarpal joint, brings the fifth finger into opposition with the thumb and together with the ADMm and FDMBm absorbs forces on the ulnar border of the hand [20, 21].

3. Anatomy of Guyon's canal

The Guyon's canal or ulnar canal is a fibro-osseous tunnel situated between the pisiform and the hook of the hamate and measured around 40–45 mm in length [45, 46]. In 1861, it is first described by the French surgeon Jean Casimir Félix Guyon. He presented it as an intra-aponeurotic compartment which the anterior wall is constituted by a fibrous layer and its posterior wall by the anterior carpal ligament [47]. Guyon's canal is situated between the proximal edge of the palmar carpal ligament to the fibrous arch of the hypothenar muscles at the level of the hook of the hamate (**Figure 5**). Through this canal the ulnar nerve and artery pass from the forearm to the palm, as the nerve is lying deep and ulnar to the artery. Of course, the vena comitans and connective fatty tissue fill up this space [48, 49].

Guyon's canal has been described as a space with complex and variable anatomy [48]. It should be pointed out that the canal is not a rigid structure and varying in its dimensions [50]. According to Ombaba et al. [49], it has dynamic space, and its relationships are changed during wrist movement.

Precise knowledge of the anatomy of Guyon's canal is essential in understanding the diagnosis and treatment of ulnar tunnel syndrome [51]. This tunnel is a potential entrapment site that could provoke compression of the ulnar nerve, presented by paresthesia or numbness, or both, to the ulnar two digits, as well as hand weakness, atrophy and ungainliness [51]. The compression could be localized in three zones [11, 52]:

Zone I: compression occurs proximal to or within Guyon's canal, before the nerve bifurcation, and presents with combined motor and sensory deficits.

Zone II: compression involves only the deep motor branch and occurs as the ulnar nerve exits Guyon's canal or at the hook of the hamate level.

Zone III: compression, with isolated superficial sensory branch involvement, may also occur as the nerve exits Guyon's canal or at the hook of the hamate distal to the bifurcation.

Importantly during surgical interventions, all three compartments should be decompressed, including the pisohamate hiatus, by releasing the pisohamate arcade [49].

Different muscular variations have been reported as the most common anatomical predispositions that might contribute to the ulnar nerve compression

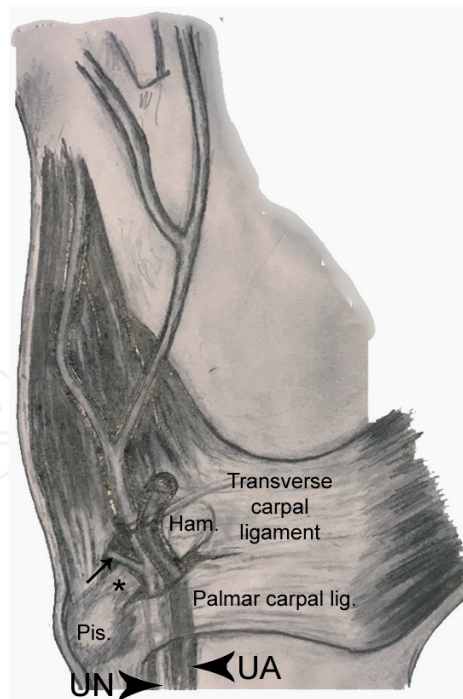


Figure 5. *Anatomy of Guyon's canal. Pisohamate ligament (asterisk); deep motor branch of the ulnar nerve (arrow); pisiform bone (Pis.); hamate bone (ham.); ulnar nerve (UN); ulnar artery (UA).*

in Guyon's canal [51]. Different muscular variations related to the ADMm, followed by FDMBm, are reported [8, 12–14]. In these cases, ultrasonography or MRI could help clinicians to clearly identify the muscular variants in Guyon's canal [38, 53].

4. Conclusion

This chapter summarizes the existing data in the literature concerning the anatomy of the hypothenar muscles, as well as its variants and the anatomy of Guyon's canal. I hope that the presented literature data will help students in learning anatomy, help the anatomists and hand surgeons during their works, as well as for better scientific production and to better understand, describe and classify the muscular variations and Guyon's canal. Using the chapter, they will avoid mistakes in classifying different variations of the hypothenar muscles. I think that the knowledge of reported variants will ensure self-confidence and avoid confusions during wrist and palm procedures, especially during releasing Guyon's canal, extended carpal tunnel release, or palmar fasciectomy. Precise knowledge of the anatomy and its variant also would help radiologist in their routine work on ultrasonography and MRI, where different variations could be evaluated in cases of soft tissue tumor or in diagnosis of primary or recurrent ulnar nerve compression.

Acknowledgements

The author would like to thank Mr. Ahmed Hashim Mohamed Ali (Student at Medical University of Sofia, Bulgaria) for the kind help through his excellent drawings illustrated in the chapter.

Conflict of interest

The author declares no conflict of interest.

Abbreviations

Pbm	palmaris brevis muscle
ADMm	abductor digiti minimi muscle
FDMBm	flexor digiti minimi brevis muscle
ODMm	opponens digiti minimi muscle

Author details

Georgi P. Georgiev
Department of Orthopedics and Traumatology, University Hospital Queen
Giovanna-ISUL, Medical University of Sofia, Sofia, Bulgaria

*Address all correspondence to: georgievgp@yahoo.com

IntechOpen

© 2020 The Author(s). Licensee IntechOpen. This chapter is distributed under the terms of the Creative Commons Attribution License (<http://creativecommons.org/licenses/by/3.0>), which permits unrestricted use, distribution, and reproduction in any medium, provided the original work is properly cited. 

References

- [1] Al-Qattan MM. Ulnar nerve compression at the wrist by the accessory abductor digiti minimi muscle: Wrist trauma as a precipitating factor. *Hand Surgery*. 2004;**9**:79-82. DOI: 10.1142/s0218810404001899
- [2] Murata K, Tamai M, Gupta A. Anatomic study of variations of hypothenar muscles and arborization patterns of the ulnar nerve in the hand. *The Journal of Hand Surgery*. 2004;**29**:500-509. DOI: 10.1016/j.jhsa.2004.01.006
- [3] Claassen H, Schmitt O, Schulze M, Wree A. Variation in the hypothenar muscles and its impact on ulnar tunnel syndrome. *Surgical and Radiologic Anatomy*. 2013;**35**:893-899. DOI: 10.1007/s00276-013-1113-5
- [4] Jeffery AK. Compression of the deep palmar branch of the ulnar nerve by an anomalous muscle. Case report and review. *Journal of Bone and Joint Surgery*. British Volume (London). 1971;**53**:718-723
- [5] Simodynes EE, Cochran RM 2nd. Anomalous muscles in the hand and wrist--report of three cases. *The Journal of Hand Surgery*. 1981;**6**(6):553-554. DOI: 10.1016/s0363-5023(81)80129-3
- [6] James MR, Rowley DI, Norris SH. Ulnar nerve compression by an accessory abductor digiti minimi muscle presenting following injury. *Injury*. 1987;**18**:66-67. DOI: 10.1016/0020-1383(87)90393-7
- [7] Pribyl CR, Moneim MS. Anomalous hand muscle found in the Guyon's canal at exploration for ulnar artery thrombosis. A case report. *Clinical Orthopaedics and Related Research*. 1994;**306**:120-123
- [8] Spinner RJ, Lins RE, Spinner M. Compression of the medial half of the deep branch of the ulnar nerve by an anomalous origin of the flexor digiti minimi. A case report. *The Journal of Bone and Joint Surgery*. American Volume. 1996;**78**:427-430
- [9] Slavchev SA, Georgiev GP. Aberrant abductor digiti minimi muscle found during open surgical decompression of the carpal tunnel: Case report. *Revista Argentina de Anatomía Clínica*. 2013;**5**:88-91
- [10] Georgiev GP. Anatomical variations of muscles in the human body and their relevance for clinical practice. *International Journal of Anatomical Variations*. 2018;**11**:48-49
- [11] Shea JD, McClain EJ. Ulnar-nerve compression syndromes at and below the wrist. *The Journal of Bone and Joint Surgery*. American Volume. 1969;**51**:1095-1103
- [12] Sälgeback S. Ulnar tunnel syndrome caused by anomalous muscles. Case report. *Scandinavian Journal of Plastic and Reconstructive Surgery*. 1977;**11**:255-258
- [13] Coraci D, Luchetti R, Paolasso I, Santilli V, Padua L. Intermittent ulnar nerve compression due to accessory abductor digiti minimi muscle: Crucial diagnostic role of nerve ultrasound. *Muscle & Nerve*. 2015;**52**:463-464. DOI: 10.1002/mus.24660
- [14] Mohan J, Ramesh BA. Ulnar nerve compression by accessory abductor digiti minimi muscle. *Nigerian Journal of Plastic Surgery*. 2016;**12**:69-71. DOI: 10.4103/0794-9316.202440
- [15] Georgiev GP, Jeleu L. Unusual coexistence of a variant abductor digiti minimi and reversed palmaris longus and their possible relation to median and ulnar nerves entrapment at the wrist. *Romanian Journal of Morphology and Embryology*. 2009;**50**(4):725-727

- [16] Turner MS, Caird DM. Anomalous muscles and ulnar nerve compression at the wrist. *The Hand*. 1977;**9**:140-142. DOI: 10.1016/s0072-968x(77)80007-7
- [17] Tonkin MA, Lister GD. The palmaris brevis profundus. An anomalous muscle associated with ulnar nerve compression at the wrist. *The Journal of Hand Surgery*. 1985;**10**:862-864
- [18] Moss DP, Forthman CL. Ulnar artery thrombosis associated with anomalous hypothenar muscle. *Journal of Surgical Orthopaedic Advances*. 2008 Summer;**17**(2):85-88
- [19] von Lanz T, Wachsmuth W. Arm. In: *Praktische Anatomie*. 1. Bd, 3. Teil. Berlin: Verlag von Julius Springer; 1935. p. 193
- [20] Clemente CD. *Anatomy of the Human Body*. 30th ed. Philadelphia: Lea and Febiger; 1985. pp. 553-554
- [21] Standring S, Borley NR, Gray H. *Gray's Anatomy: The Anatomical Basis of Clinical Practice*. 40th ed. Edinburgh: Churchill Livingstone/Elsevier; 2008. pp. 857-898
- [22] Nayak SR, Krishnamurthy A. An unusually large palmaris brevis muscle and its clinical significance. *Clinical Anatomy*. 2007;**20**:978-979. DOI: 10.1002/ca.20542
- [23] Moore CW, Beveridge TS, Rice CL. Fiber type composition of the palmaris brevis muscle: Implications for palmar function. *Journal of Anatomy*. 2017;**231**:626-633. DOI: 10.1111/joa.12652
- [24] Moore CW, Rice CL. Structural and functional anatomy of the palmaris brevis: Grasping for answers. *Journal of Anatomy*. 2017;**231**:939-946. DOI: 10.1111/joa.12675
- [25] Macalister A. Additional observations on muscular anomalies in human anatomy (third series), with a catalogue of the principal muscular variations hitherto published. *Transactions of the Royal Irish Academy*. 1875;**25**:1-130
- [26] Bergman RA, Afifi AK, Miyauchi R. Part I: Muscular system. In: *Illustrated Encyclopedia Of Human Anatomic Variations*. 2019. Available from: <http://www.anatomyatlases.org/AnatomicVariants/AnatomyHP.shtml> [Accessed: 26 November 2019]
- [27] Lipscomb PR. Duplication of hypothenar muscles simulating soft-tissue tumor of the hand. Report of a case. *The Journal of Bone and Joint Surgery. American Volume*. 1960;**42**:1058-1061
- [28] Robinson D, Aghasi MK, Halperin N. Ulnar tunnel syndrome caused by an accessory palmaris muscle. *Orthopaedic Review*. 1989;**18**:345-347
- [29] Rose EH. The use of the palmaris brevis flap in recurrent carpal tunnel syndrome. *Hand Clinics*. 1996;**12**:389-395
- [30] Eswaradass PV, Kalidoss R, Ramasamy B, Gnanashanmugham G. Familial palmaris brevis spasm syndrome. *Annals of Indian Academy of Neurology*. 2014;**17**:141-142. DOI: 10.4103/0972-2327.128597
- [31] Wood J. Variations in human myology observed during the winter session of 1866-1867 at King's college, London. In *Variations in Human Myology*. Vol IV. *Proceedings of the Royal Society of London*. 1867;**15**:518-546
- [32] Wood J. Variations in human myology observed during the winter season of 1867-1868 at King's college, London. In *Variations in Human Myology*. Vol XVII. *Proceedings of the Royal Society of London*. 1868;**16**:483-525
- [33] Le Double A. *Muscles de la main*. In: *Traité des variations du système musculaire de l'homme*. Tome II. Paris: Schleicher Frères; 1897. pp. 153-218

- [34] Gloobe H, Pecket P. An anomalous muscle in the canal of Guyon (a possible ulnar nerve compression). *Anatomischer Anzeiger*. 1973;**133**:477-479
- [35] Sañudo JR, Mirapeix RM, Ferreira B. A rare anomaly of abductor digiti minimi. *Journal of Anatomy*. 1993;**182**(3):439-442
- [36] Georgiev GP, Jeleu L, Surchev L. Undescribed variant muscle - "deep abductor-flexor" of the little finger, in relation to ulnar nerve compression at the wrist. *Annals of Anatomy*. 2007;**189**:276-282. DOI: 10.1016/j.aanat.2006.11.003
- [37] Georgiev GP, Jeleu L, Surchev L. Variations of the hypothenar muscles. *Acta Morphologica et Anthropologica*. 2008;**13**:313-315
- [38] Georgiev GP, Jeleu L, Kinov P. Aberrant muscles at the Guyon's canal. *International Journal of Anatomical Variations*. 2010;**4**:67-69
- [39] Upton J, Taghinia AH. Abductor digiti minimi myocutaneous flap for opponensplasty in congenital hypoplastic thumbs. *Plastic and Reconstructive Surgery*. 2008;**122**:1807-1811. DOI: 10.1097/PRS.0b013e31818cc260
- [40] Saadeh FA, Bergman RA. An unusual accessory flexor (opponens) digiti minimi muscle. *Anatomischer Anzeiger*. 1988;**165**:327-329
- [41] Wingerter S, Gupta S, Le S, Shamasunder S, Bernstein R, Rabitaille W, et al. Unusual origin of the flexor digiti minimi brevis muscle. *Clinical Anatomy*. 2003;**16**:531-533. DOI: 10.1002/ca.10122
- [42] Georgiev GP, Jeleu L. Variant triple origin of the flexor digiti minimi brevis (Manus) muscle in relation to ulnar nerve and artery compression at the wrist. *Clinical Anatomy*. 2007;**20**:976-977. DOI: 10.1002/ca.20529
- [43] Georgiev GP, Jeleu L. An aberrant flexor digiti minimi brevis Manus muscle. *The Journal of Hand Surgery*. 2011;**36**:1965-1967. DOI: 10.1016/j.jhsa.2011.09.002
- [44] Harvie P, Patel N, Ostlere SJ. Prevalence and epidemiological variation of anomalous muscles at Guyon's canal. *Journal of Hand Surgery (British)*. 2004;**29**:26-29. DOI: 10.1016/j.jhsb.2003.08.004
- [45] Depukat P, Mizia E, Kuniewicz M, Bonczar T, Mazur M, Pelka P, et al. Syndrome of canal of Guyon - definition, diagnosis, treatment and complication. *Folia Medica Cracoviensia*. 2015;**55**:17-23
- [46] Depukat P, Henry BM, Popieluszko P, Roy J, Mizia E, Konopka T, et al. Anatomical variability and histological structure of the ulnar nerve in the Guyon's canal. *Archives of Orthopaedic and Trauma Surgery*. 2017;**137**:277-283. DOI: 10.1007/s00402-016-2616-4
- [47] Guyon F. Note sur une disposition anatomique propre a la face anterieure de la region du poignet et non encore decrite. *Bulletins de la Société Anatomique de Paris*. 1861;**6**:184-186
- [48] Bachoura A, Jacoby SM. Ulnar tunnel syndrome. *The Orthopedic Clinics of North America*. 2012;**43**:467-474. DOI: 10.1016/j.jocl.2012.07.016
- [49] Ombaba J, Kuo M, Rayan G. Anatomy of the ulnar tunnel and the influence of wrist motion on its morphology. *The Journal of Hand Surgery*. 2010;**35**:760-768. DOI: 10.1016/j.jhsa.2010.02.028
- [50] Fadel ZT, Samargandi OA, Tang DT. Variations in the anatomical structures of the Guyon canal. *Plastic Surgery*. 2017;**25**:84-92. DOI: 10.1177/2292550317694851

[51] Bozkurt MC, Tağil SM, Ozçakar L, Ersoy M, Tekdemir I. Anatomical variations as potential risk factors for ulnar tunnel syndrome: A cadaveric study. *Clinical Anatomy*. 2005;**18**:274-280. DOI: 10.1002/ca.20107

[52] Gross MS, Gelberman RH. The anatomy of the distal ulnar tunnel. *Clinical Orthopaedics and Related Research*. 1985;**196**:238-247

[53] Zeiss J, Guillian-Haidet L. MR demonstration of anomalous muscles about the volar aspect of the wrist and forearm. *Clinical Imaging*. 1996;**20**:219-221. DOI: 10.1016/0899-7071(95)00013-5

IntechOpen