

We are IntechOpen, the world's leading publisher of Open Access books Built by scientists, for scientists

4,800

Open access books available

122,000

International authors and editors

135M

Downloads

Our authors are among the

154

Countries delivered to

TOP 1%

most cited scientists

12.2%

Contributors from top 500 universities



WEB OF SCIENCE™

Selection of our books indexed in the Book Citation Index
in Web of Science™ Core Collection (BKCI)

Interested in publishing with us?
Contact book.department@intechopen.com

Numbers displayed above are based on latest data collected.

For more information visit www.intechopen.com



Oral Cancer: The State of the Art of Modern-Day Diagnosis and Treatment

*Quang Van Le, Duy Quoc Ngo, Toan Duc Tran
and Quy Xuan Ngo*

Abstract

Diagnosing and treating lesions of the mouth and gums is challenging for most clinicians because of the wide variety of disease processes that can present with similar appearing lesions and the fact that most clinicians receive inadequate training in mouth diseases. Oral cancer, a common lesion in oral cavity, is not correctly diagnosing a clinical picture of an early squamous cell carcinoma. The prevalence of oral cancer continues to rise worldwide, related to the increase in consumption of tobacco, alcohol and other carcinogenic products. However, there has also been a significant reduction in mortality due to increasing awareness, early diagnosis and advances in treatments. This chapter is an attempt to provide a comprehensive update encompassing the spectrum of etiologic/risk factors, current clinical diagnostic tools, management philosophies, and molecular biomarkers and progression indicators of oral cancer.

Keywords: oral cancer, oral cavity cancer, head and neck cancer, squamous cell carcinoma, oral lesions

1. Introduction

Oral cancer is one of the most prevalent diseases worldwide, accounting for 30–40% of the head and neck cancer. There are an estimated 200,000 cases of oral cancer worldwide each year, which cause an estimated 100,000 deaths [1]. Particularly, these are malignant lesions of the oral structure including anterior two thirds of tongue, lips (upper lip, lower lip and edge), the upper and lower gingiva, retromolar trigone, buccal mucosa and floor of the mouth. The most common histopathology of oral cancer is squamous cell carcinoma, contributing to approximately 90% of cases. Multidisciplinary oncologic treatment, such as surgery, radiation therapy and chemotherapy, plays important roles in treatment for oral cavity cancer [2].

2. Oral cavity anatomy

The oral cavity is composed of the mucosa of the lips (not outer, dry lips), the buccal mucosa, the anterior tongue, the floor of the mouth, the hard palate and the

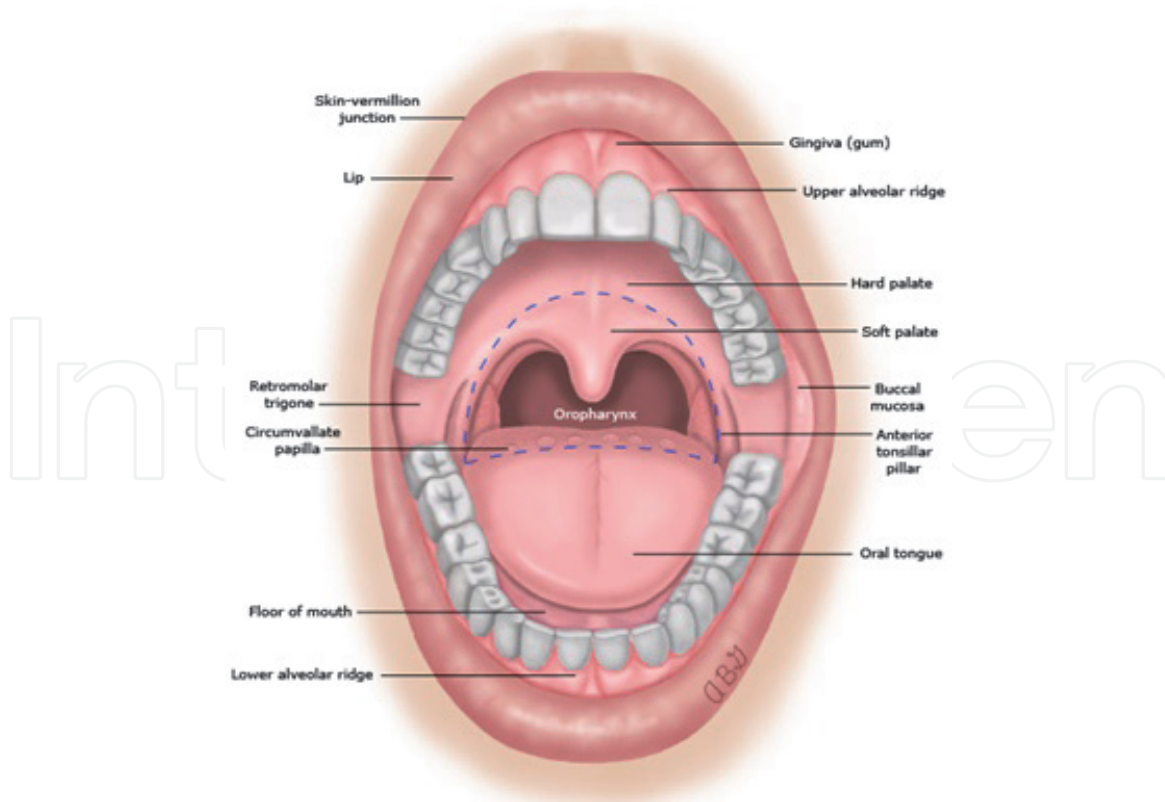


Figure 1.
Oral cavity anatomy.

upper and lower gingiva. The anterior boundary is determined by the portion of the upper lip connected to the lower lip (wet mucosa). While, the posterior side is bound by the V-groove of the tongue, the anterior tonsillar pillars (palatoglossus muscles) and the posterior margin of the hard palate. Inferiorly, the oral cavity is formed by mylohyoid muscles. Additionally, the lateral border of the oral cavity spans between the buccomasseteric area (buccal mucosa) and retromolar trigone (**Figure 1**).

3. Epidemiology and etiology of pathogenesis

An estimated 200,000 cases of oral cancer every year worldwide resulted in around 100,000 lethal cases [1]. Oral cavity tumors frequently occur with the local invasions, destructions of the surrounding tissue and lymph node metastases, but there is not often have distant metastasis at the time of diagnosis. Smoking and alcohol assumption are two major risks of the oral squamous cell carcinoma [3]. Likewise, in Asia, especially in India, chewing nut quid is also an important key factor [4]. Furthermore, oral tobacco use, periodontal disease, radiation and immunodeficiency have been considered as risks linked to oral cancer. By the same token, sun exposure (ultraviolet radiation) is also a causal factor. Both of tobacco assumption and chewing nut quid are predominant risks of buccal mucosa cancers [3, 4]. **Figure 2** illustrates Region-Specific Incidence Age-Standardized Rates by Sex for Cancers of the Lip and Oral Cavity in 2018 [1].

Interestingly, human papillomavirus (HPV) infection, especially HPV 16, is associated with the incidence rates of tonsilloma and tongue cancer. Yet, the ratio of HPV infection related to oral cancer is significantly lower and there was an unclear

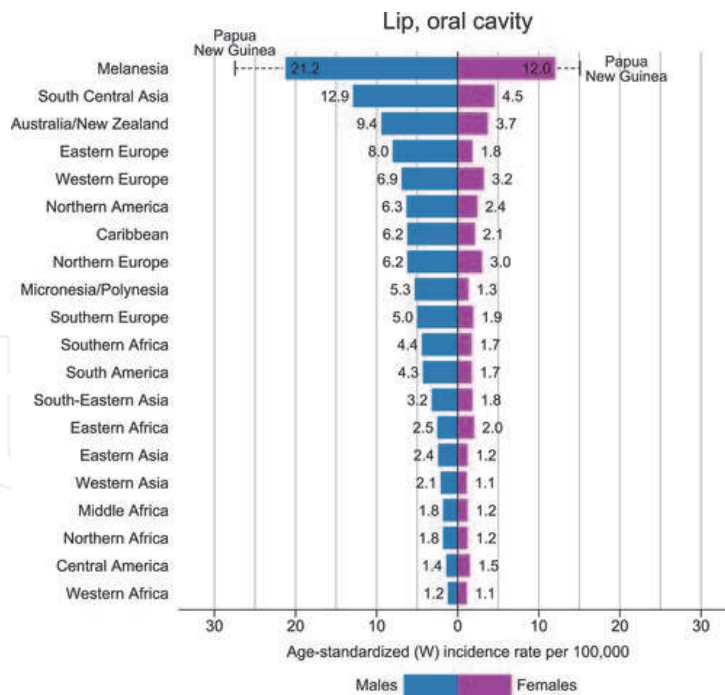


Figure 2.
 Bar chart of region-specific incidence age-standardized rates by sex for cancers of the lip and Oral cavity in 2018. Source: GLOBOCAN 2018 [1].

relationship between clinical pathology and prognosis. Therefore, the HPV test has not been recommended for oral cancer [5].

4. Pathology

A total of 90 to 95% of all malignant lesions in the oral cavity are the squamous cell carcinoma. Moreover, it can be classified into three main groups: good differentiation (above 75% keratinization), moderate differentiation (25–75% keratinization) and poorly differentiated tumors (below 25% keratinization). Besides, less common types of histopathology could be mentioned such as verrucous carcinoma (a variant of squamous cell carcinoma), adenocarcinoma, adenoid cystic carcinoma and mucoepidermoid carcinomas.

On the other hand, the squamous cell carcinoma of the head and neck ordinarily undergo several developments of precancerous lesions due to exposure to carcinogenic factors.

- Oral leukoplakia is a precancerous lesion that presents as white patches in the oral mucosa. Notably, this damage is relatively common at a rate of 4% in the population [6]. Leukoplakia is divided into two types: homogenous lesions and heterogeneous lesions, in which cancer is highly induced by heterogeneous lesions. The diagnosis of leukoplakia usually relies on a biopsy to diagnose histopathology. Aside from that, biopsy is a standard criterion of the histopathological diagnosis in the clinical leukoplakia [7]. Surgery was indicated to any cases with small heterogeneous leukoplakia or lesions with severe dysplasia. Likewise, conservative treatments are regularly indicated for widespread leukoplakia or lesions with moderate or mild dysplasia [8]. Not to mention is oral proliferative verrucous leukoplakia (OPVL), a rare case found in patients. This is a malignant lesion of heterozygous leukoplakia with multifocal-type surface characteristics, slow progression and immense rate of malignant transformation. Some of the treatments such as surgery, laser,

radiation or bleomycin-contained-chemotherapy facilitate to temporarily control the damage. Nonetheless, the relapse rate or malignant transformation is up to 70% of patients and the lethal rate contributes to higher than 30% for around a decade [9].

- Erythroplakia, a type of relatively uncommon lesions, has a relatively high rate of malignant transformation (above 80%) [10]. This lesion can be recognized with a red strip, relatively smooth, no symptoms in the floor of the mouth, the surface of the tongue and the soft palate in elder patients routinely using tobacco and alcohol. Thus, a complete removing surgery is a major recommendation in this case [11].

5. Clinical features and staging

5.1 Clinical presentation

The clinical manifestations of the oral cavity cancer are greatly contingent on the location of the primary tumor. Particularly, some of the symptoms could be found such as mouth sores or mouth ulcers, loose teeth, dysphagia, weight loss and bleeding. What's more, tumors of the mucosal surface, at the initial stage, recurrently appear as an unhealed ulcer with varying degrees of pain and occasionally bleed. These lesions regularly appear in the range of prior weeks to months that patients realized and go to the examination.

Above 66% of patients with tongue cancer have local lymph node metastases, depending on stage T and invasive depth, whereas the rate of lymph node metastasis is significantly lower than that of the hard palate cancer patients [12]. Similarly, the location and extent of the primary tumor attribute to the variants of clinical symptoms:

- Tongue cancer may develop as an ulcerative and/or infective lesion (**Figure 3**). Clinical signs are regular pain, with or without swallowing dysfunction. Markedly, the occurrence of those symptoms indicates that the tumor has deeper invaded into underlying other muscle layers of the tongue. In another way, it is seen that the disease is not at the early stage but reveals the history of leukoplakia or erythema in patients as well.
- Buccal mucosa cancer (**Figure 4**) can be presented with parotitis resulted from the pinched tumor-pinched-Stensen's duct sign.
- Oral cancer can induce one or both sides of the gland inflammation due to tumor compression and/or blockage of the Wharton duct leading to a palpable mass in the submandibular area, which may be the symptom.
- Upper gingival cancer at the early stage is easily bewildered with perianal infections which are inefficiency when being antibiotics-treated. Furthermore, sores, wounds and tooth loss could happen at the advanced stage.
- Lip cancer is generally presented with an exophytic or an ulcerative lesion, occasionally associated with bleeding or pain. Some cases indicate the nerve-associated-chin numbness because of invasion of the mental nerve [12].

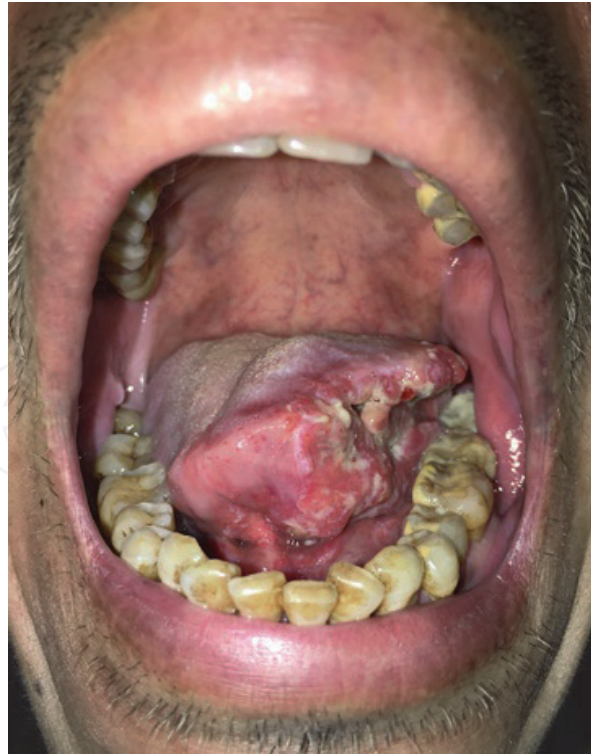

Figure 3.
Cancer of anterior two thirds of tongue.

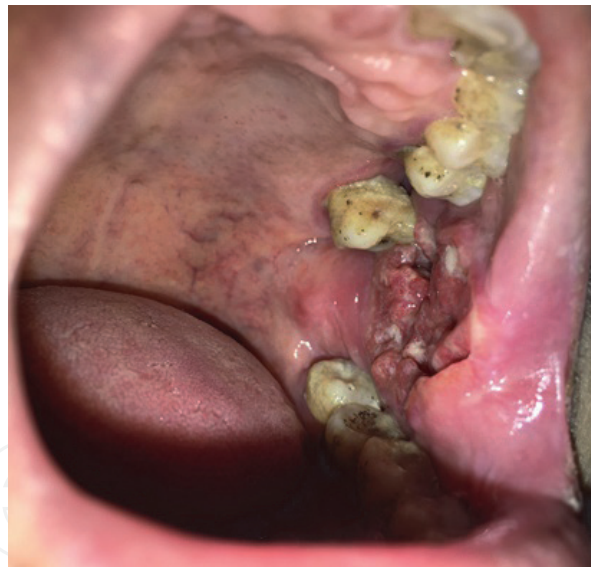

Figure 4.
Buccal mucosa cancer.

5.2 Physical examination

All patients with the oral tumor should have a completely general examination for both head and neck areas which includes finding and evaluating secondary tumors in the upper gastrointestinal tract as well as regional lymph nodes.

5.2.1 Intraoral examination

The process of the oral examination requires to systematically observe and touch the buccal mucosa, the anterior tongue, the floor of the mouth, the hard palate, and

the upper, lower gingiva and the retromolar trigone. It is advisable to use a tongue depressor with good light (headlight) to fully observe all positions of the oral cavity. Then again, the size and characteristics of the lesion are evaluated, including the extent of invasion (endophytic or exophytic) and the relationship of lesion with surrounding structures.

5.2.2 Extraoral examination

With patients suffering from oral tumors, it is strongly advised that the facial skin and scalp are strongly advised to carefully observe and palpate. Besides, the major salivary glands and metastatic lymph nodes of the neck are evaluated. For instance, the sensation of the forehead, cheeks, upper lip, chin and lower lip should be assessed to find the clinical evidence of tumor-invaded-nerve.

The lymph nodes of the head and neck should be thoroughly and systematically such as preauricular, periparotid, submental, prevascular facial, submandibular, deep jugular and posterior triangle lymph nodes. Having said that, neck lymph nodes I, II and III are concerned as the most metastatic lymph-node groups of oral cancer. Whenever abnormal lymph nodes are detected, a conscientious assessment of the location, size, amount and clinical signs of the invasive lymph nodes is conducted.

5.3 Tissue diagnosis

In the oral tumor case, the histopathological diagnosis is preferentially carried out by a “bite” or excisional biopsy with few pieces from the boundary of benign and malignant lesions. This procedure should be performed in a specialized clinic with anesthetics. Similarly important is that the biopsy piece must be resected at the margin of positive and negative lesions. Additionally, the biopsy piece is necessary to take a sufficient depth to ensure the quality and necrotic area should be averted. If the anatomy is negative but clinically suspected to be cancerous, a biopsy is advisory performed until the procedure is positive. Notably, the fine needle aspiration biopsy applied into the metastasis-suspected lymph nodes in the neck also facilitates to identify and diagnose the disease stage. Nevertheless, this technique should be conducted under ultrasound guidance to enhance accuracy.

5.4 TNM staging system

The tumor, node, metastases (TNM) staging system of the American Joint Committee on Cancer (AJCC) and the Union for International Cancer Control (UICC) is used to classify cancers of the head and neck (**Table 1**) [13]. The T classifications indicate the extent of the primary tumor and are site specific; there is considerable overlap in the cervical N classifications.

5.5 Staging evaluation

Diagnostic imaging tools coupled with clinical examination help to accurately assess the stage of the disease, especially the extent of tumor invasion, lymph node metastasis, distant metastasis and the occurrence of second primary cancer. The most common metastatic areas are the lungs, liver and bone. Meanwhile, the second primary cancer is often found in the head and neck area, following the lung and esophagus.

Primary tumor (T)			
T category	T criteria		
TX	Primary tumor cannot be assessed		
Tis	Carcinoma <i>in situ</i>		
T1	Tumor ≤2 cm with depth of invasion (DOI)* ≤5 mm		
T2	Tumor ≤2 cm, with DOI* >5 mm and ≤10 mm; or Tumor >2 cm and ≤4 cm, with DOI* ≤10 mm		
T3	Tumor >2 cm and ≤4 cm with DOI* >10 mm; or Tumor >4 cm with DOI* ≤10 mm		
T4	Moderately advanced or very advanced local disease		
T4a	Moderately advanced local disease. Tumor >4 cm with DOI* >10 mm; or Tumor invades adjacent structures only (eg, through cortical bone of the mandible or maxilla, or involves the maxillary sinus or skin of the face). NOTE: Superficial erosion of bone/tooth socket (alone) by a gingival primary is not sufficient to classify a tumor as T4.		
T4b	Very advanced local disease. Tumor invades masticator space, pterygoid plates, or skull base and/or encases the internal carotid artery.		
* DOI is depth of invasion and not tumor thickness.			
Regional lymph nodes (N)			
Clinical N (cN)			
N category	N criteria		
NX	Regional lymph nodes cannot be assessed		
N0	No regional lymph node metastasis		
N1	Metastasis in a single ipsilateral lymph node, 3 cm or smaller in greatest dimension ENE(-)		
N2	Metastasis in a single ipsilateral node larger than 3 cm but not larger than 6 cm in greatest dimension and ENE(-); or Metastases in multiple ipsilateral lymph nodes, none larger than 6 cm in greatest dimension and ENE(-); or In bilateral or contralateral lymph nodes, none larger than 6 cm in greatest dimension, and ENE(-)		
N2a	Metastasis in a single ipsilateral node larger than 3 cm but not larger than 6 cm in greatest dimension, and ENE(-)		
N2b	Metastases in multiple ipsilateral nodes, none larger than 6 cm in greatest dimension, and ENE(-)		
N2c	Metastases in bilateral or contralateral lymph nodes, none larger than 6 cm in greatest dimension, and ENE(-)		
N3	Metastasis in a lymph node larger than 6 cm in greatest dimension and ENE(-); or Metastasis in any node(s) and clinically overt ENE(+)		
N3a	Metastasis in a lymph node larger than 6 cm in greatest dimension and ENE(-)		
N3b	Metastasis in any node(s) and clinically overt ENE(+)		
NOTE: A designation of "U" or "L" may be used for any N category to indicate metastasis above the lower border of the cricoid (U) or below the lower border of the cricoid (L). Similarly, clinical and pathological ENE should be recorded as ENE(-) or ENE(+).			
Pathological N (pN)			
N category	N criteria		
NX	Regional lymph nodes cannot be assessed		
N0	No regional lymph node metastasis		
N1	Metastasis in a single ipsilateral lymph node, 3 cm or smaller in greatest dimension and ENE(-)		
N2	Metastasis in a single ipsilateral lymph node, 3 cm or smaller in greatest dimension and ENE(+); or Larger than 3 cm but not larger than 6 cm in greatest dimension and ENE(-); or Metastases in multiple ipsilateral lymph nodes, none larger than 6 cm in greatest dimension and ENE(-); or In bilateral or contralateral lymph node(s), none larger than 6 cm in greatest dimension, ENE(-)		
N2a	Metastasis in single ipsilateral node 3 cm or smaller in greatest dimension and ENE(+); or A single ipsilateral node larger than 3 cm but not larger than 6 cm in greatest dimension and ENE(-)		
N2b	Metastases in multiple ipsilateral nodes, none larger than 6 cm in greatest dimension and ENE(-)		
N2c	Metastases in bilateral or contralateral lymph node(s), none larger than 6 cm in greatest dimension and ENE(-)		
N3	Metastasis in a lymph node larger than 6 cm in greatest dimension and ENE(-); or Metastasis in a single ipsilateral node larger than 3 cm in greatest dimension and ENE(+); or Multiple ipsilateral, contralateral, or bilateral nodes any with ENE(+); or A single contralateral node of any size and ENE(+)		
N3a	Metastasis in a lymph node larger than 6 cm in greatest dimension and ENE(-)		
N3b	Metastasis in a single ipsilateral node larger than 3 cm in greatest dimension and ENE(+); or Multiple ipsilateral, contralateral, or bilateral nodes any with ENE(+); or A single contralateral node of any size and ENE(+)		
NOTE: A designation of "U" or "L" may be used for any N category to indicate metastasis above the lower border of the cricoid (U) or below the lower border of the cricoid (L). Similarly, clinical and pathological ENE should be recorded as ENE(-) or ENE(+).			
Distant metastasis (M)			
M category	M criteria		
M0	No distant metastasis		
M1	Distant metastasis		
Prognostic stage groups			
When T is...	And N is...	And M is...	Then the stage group is...
Tis	N0	M0	0
T1	N0	M0	I
T2	N0	M0	II
T3	N0	M0	III
T1, T2, T3	N1	M0	III
T4a	N0, N1	M0	IVA
T1, T2, T3, T4a	N2	M0	IVA
Any T	N3	M0	IVB
T4b	Any N	M0	IVB
Any T	Any N	M1	IVC

Table 1.
 The tumor, node, metastases (TNM) staging system of the American Joint Committee on Cancer (AJCC) and the Union for International Cancer Control (UICC) is used to classify cancers of the head and neck [13].

5.5.1 Fine needle aspiration (FNA) biopsy

Fine needle aspiration biopsy was used in the case with a patient with metastatic cervical lymph nodes. This technique has high sensitivity and specificity, markedly, diagnostic accuracy is in the range of 89–98% [14, 15]. Yet, if a metastatic neck lymph node was suspected contrary to the negative FNA result, FNA needed to be re-conducted before an open biopsy being performed.

5.5.2 Diagnostic methods

5.5.2.1 Primary tumor

Both of CTs with intravenous contrast and magnetic resonance imaging can diagnose the tumor's invasion to surrounding organs. Indeed, axial and sagittal MRI scan can accurately assess tumor depth. However, CT scan with contrast allows an accurate approach to measure how deep bone could be invasive such as tumors in the hard palate, gums or floor of the mouth [16]. While, magnetic resonance is superior to CT that could evaluate the degree of soft tissue invasion, nerve invasion [17].

5.5.2.2 Nodal metastases

CT with intravenous contrast and MRI can facilitate the diagnosis of metastatic lymph node and extranodal spread circumstances. In other words, the lymph nodes with an increase in size enhancement, round, rim enhancement and central necrosis are suspected as malignant ones [18, 19].

5.5.2.3 Distant metastasis

Diagnosis of the presence of distant metastasis is highly important to determine the treatment and prognosis of the patients. Chest X-rays may be indicated to the early-staged cases or patients with low-risk lesions and non-smokers. However, in the advance-staged patients, the risk of lymph nodes N2,3 and bilateral lymph nodes are under a higher possibility of a distant invasion. Hence, chest CT or PET/CT are recommended to this group [20]. No differences have been found in the diagnosis of metastatic lung lesions between chest CT and PET/CT [21].

6. Treatment

The comprehensive management of oral cancer requires a disciplinary specialty including head and neck surgery, radiotherapy, medical oncology, imaging, pathology, microsurgery, nutrition, social workers and nurses. Generally, surgery is the primary treatment for oral squamous cell carcinoma. Surgery allows an accurate assessment of the anatomical stage, margins, invasive status and histopathological characteristics, based on the pros and cons that can determine the strategy. Adjuvant radiotherapy ± chemotherapy is used on locoregionally advanced tumors if being indicated. Multidisciplinary coordination is also extraordinarily important to ensure treatment outcomes. To individualize treatment, several factors need to be carefully considered, in which the risk of treatment-related complications should be assessed based on age, comorbidities (e.g., cardiovascular condition, respiration ...), lifestyle (smoking, alcohol assumption ...), surgical resectability and expectation of patients.

6.1 Surgery

Generally, surgery is the primary treatment for oral cancer. Remarkably, the general principles of surgical treatment will be discussed in this article such as the surgical approach to oral cancer, management of the mandible, management of neck lymph nodes and reconstruction of defects after oral surgery.

6.1.1 Management of primary tumor

The surgical purpose is to completely remove the primary tumor with negative margins as well as evaluate the stage and treatment of regional lymph nodes [22]. Every attempt should be made to ensure negative resection margins since positive margins are associated with a worse prognosis. The rate of local control significantly increased when the resection distance to the tumor was greater than 0.5 cm compared to less than 0.5 cm (36 and 18%, respectively) [23]. Moreover, the surgical approach is determined by the location and size of the tumor (**Figure 5**). The possibility of complete resection with a negative margin in the three dimensions is the most important factor in determining the approach. Lesions located in the anterior or lateral oral tongue, superficial tumors of the anterior floor of mouth are resected transorally. However, in the case, the invasion intensively toward posterior and/or on patients with trismus and/or obstructive dentition may require a more invasive approach such as the lip-splitting paramedian mandibulotomy approach [24]. The upper cheek flap and midfacial degloving approaches are indicated for gaining access to the maxilla.

6.1.2 Management of the mandible

Management of the mandible is an important consideration in oral cancer surgery since the proximity of the primary tumor to the mandible or invasion of the mandible by primary tumor requires resection of some part of the mandible. The mandibular invasion can occur at an early stage of tumors of the floor of the mouth, lower gingiva. Thus, assessment of the mandible is essential for appropriate surgical planning and treatment. In some circumstances, the floor of the mouth tumors can be removed via transoral approach, regularly combined with marginal or segmental mandibulectomy. The local control rate is declined to own to the mandibular invasion. That said, this resection is based on an assessment of the invasive cortex and bone marrow before surgery. The current indications for marginal mandibulectomy are: (1) for obtaining satisfactory three-dimensional margins around the primary tumor, (2) when the primary tumor approximates the mandible and (3) for minimal erosion of the alveolar process of the mandible (**Figure 6**).

The current indications for segmental mandibulectomy include: (1) gross invasion by oral cancer; (2) proximity of oral cancer to the mandible in a previously irradiated patient; (3) invasion of the inferior alveolar nerve or canal by tumor [12, 25, 26].

6.1.3 Management of neck lymph nodes

Management of the neck is a key component of oral cavity cancer treatment. Sixty percentage of patients with metastatic cervical lymph nodes (cN0) in the early stage of oral cancer cannot be clinically detected. Additionally, approximately 20–30% has evidence of microscopic lymph node metastasis on pathology after the selective neck dissection (SND). The risk of neck lymph node metastasis is associated with several factors such as tumor size, histologic grade, depth of invasion,

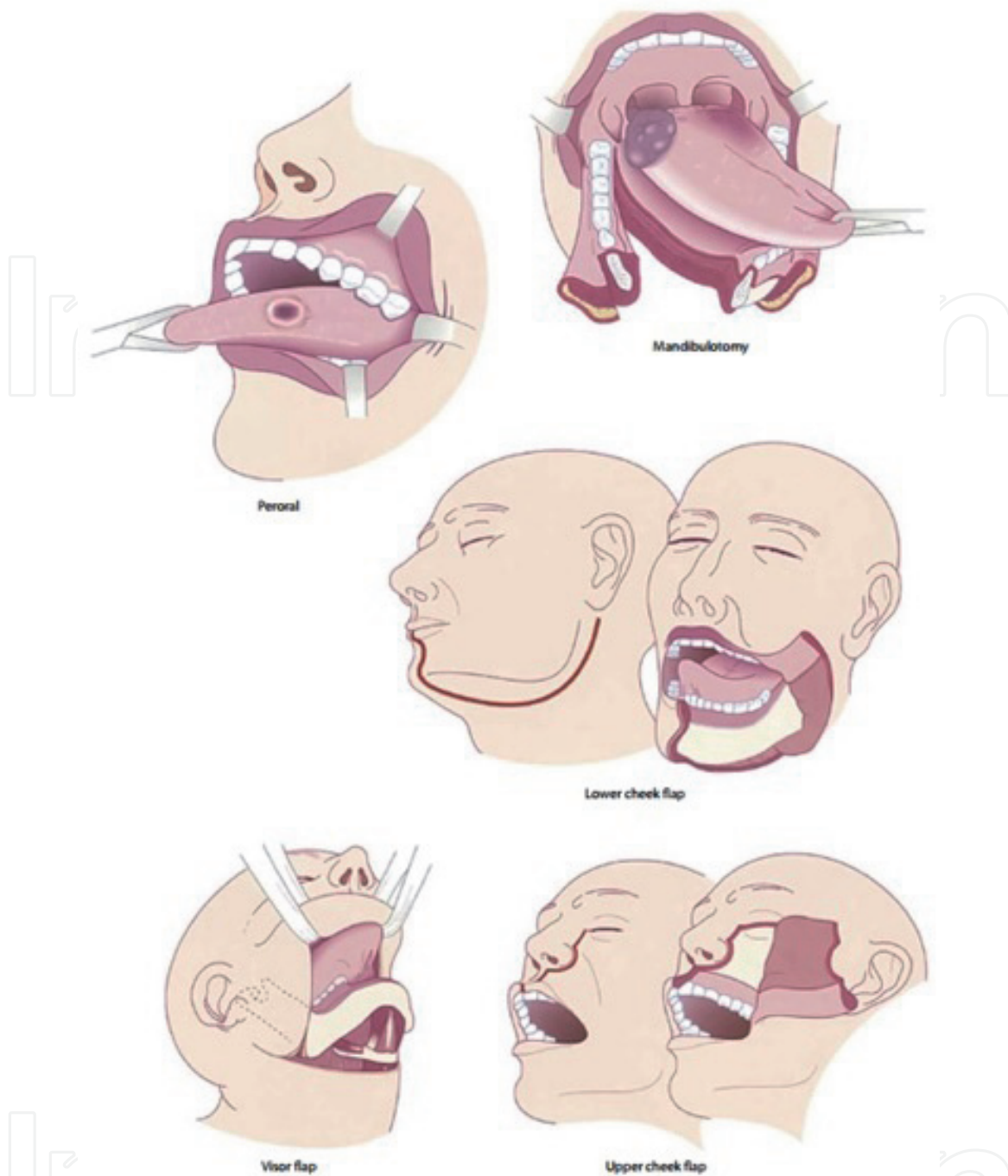


Figure 5.
Surgical approaches to oral cavity [12].

perineural invasion and vascular invasion [27, 28]. Cervical lymph node metastasis is the most essentially prognostic aspect of oral cancer. To give an illustration, comparing to a similar primary tumor without lymph node metastases, the chance of survival is declined by 50% [29]. Squamous cell carcinoma of the mobile tongue and the floor of the mouth are likely to metastases of the cervical lymph nodes, so these patients should have a selective neck removal surgery even with early-stage tumors, especially, the tumor thickness > 4 mm [30]. The SND is not indicated in the circumstances of the hard palate and maxillary gland tumors owing to their less possibility to have lymph node metastasis. Sentinel node biopsy may be an alternative to SND in patients with early stage (cT1,2 N0) squamous cell carcinoma. Notably, this technique was initially published in 2001 by Shoaib and colleagues, then analyzed in several single-center studies and two multi-center clinical trial

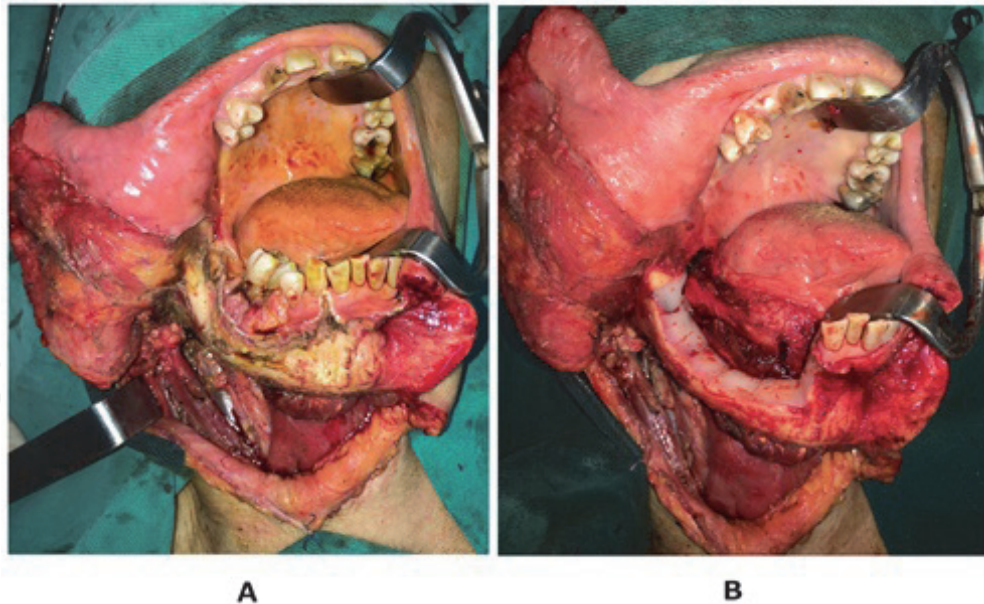


Figure 6.
(A) Cancer of lower gingiva. (B) Marginal mandibulectomy for cancer of lower gingiva.

studies, one in the US and one in Europe [31]. On the other hand, the procedure is still a big technical challenge and unsustainable success in identifying lymph nodes and metastases which highly dependent on the experience and competence of surgeons. That is to say, this technique could only be performed in some of the intensive centers with proficient skills. In some patients with lymph node metastasis on clinical examination or diagnostic imaging, therapeutic comprehensive neck dissection is indicated, including cervical lymph node group I to V group. The conservation or destruction of other structures such as the spinal accessory nerve, sternocleidomastoid muscle, or internal jugular vein is reliant on the location as well as the metastatic characteristics. The most common type of comprehensive neck dissection is the modified radical neck dissection, MRND Type 1. Radical neck dissection is rarely performed unless there is a direct extranodal spread of the lymph nodes to evade into the corresponding organs. Likewise, in patients without clinical lymph node metastases, the underlying risk of lymph node metastasis is mainly in the group I-III, rarely in the groups IV and V. Thus, supraomohyoid neck resection (SOHND) is commonly sufficient for stage cN0. Similarly, the rate of neck recurrence is 10–24% was found in patients who have positive lymph nodes under SND treatment [32]. Then again, patients are appropriately chosen to optimize postoperative radiation therapy. Particularly, the failure control rate is reported less than 10% in patients with cN0 demonstrated no lymph node metastasis on pathology [33].

6.1.4 Reconstructive surgery

Reconstructive surgery plays an important role in treatment for oral cavity cancer. The defects after surgery can cause significant issues in airway management, mastication, speech and cosmesis. The aim of reconstructive surgery is to restore presurgical function and cosmesis. Primary reconstruction, rather than a secondary surgery, has become the first choice of treatment for most cases with oral cancer. Primary closure or the use of skin graft can indicate for defects after oral surgery of early stage tumors. Contrarily, with large and complex defects after the oral tumor resection, plastic surgery needs the participation of an expert reconstructive surgeon. Microvascular free flap surgery is the prevalingly preferential

technique. For instance, application of the free radial forearm flap into patients with soft tissue defects of tongue, the floor of mouth or retromolar trigone apparently performs an excellent result. In addition to the purpose of covering the soft tissue, the free flap is also a reliable method for recovering the bone defects, such as the fibula free flap used as post-surgical reconstruction after segmental mandibulectomy. Other combined microvascular flanges could be considered as radial forearm osteocutaneous flap, iliac crest and scapula free flaps. What's more, a few studies have demonstrated the effectiveness and safety of microsurgery [34]. The potency to recover major defects after surgery has contributed to improving the oncologic outcomes in patients with locally advanced stage due to increased ability to complete resection [35]. Pedicled myocutaneous flaps such as the pectoralis major, latissimus dorsi or trapezius flaps may also be a promising alternative when there is no reconstructive surgeon or the patient's condition is inappropriate for microvascular surgery.

6.2 Adjuvant treatment

Postoperative adjuvant therapy is indicated to patients with high risks of the local, regional recurrence, including pT3,4 primary tumors, pN2,3 lymph node metastases, level IV or V lymph node metastases, positive margins, lymphovascular invasion, perineural invasion and extracapsular spread. Indeed, external beam radiation is the traditional adjuvant treatment, with doses of 60–70 Gy often providing positive control. Two clinical trials have shown that adjuvant radiotherapy with cisplatin significantly improves the control rates along with survival time compared to the single adjuvant radiation therapy in those who have invasive head and neck cancer with extracapsular spread [36, 37]. But for all that concomitant radiotherapy has more severe side effects, so it should be carried out in the large centers with an expert team and appropriate infrastructure.

7. Prognosis

The clinical stage is the key predictor of survival. The Surveillance, Epidemiology and End Results (SEER) Cancer Statistics reveal that a 5-year survival for locally advanced oral cavity cancer of 54.7%, in contrast to 82.5% for early-stage cancer patients treated from 1975 to 2007 [38]. Lymph node metastasis is the single most important prognostic factor for oncologic outcome in oral cancer [39]. Besides, the number and size of positive lymph nodes, the presence of extranodal extension higher histologic grade, the presence of perineural invasion and increasing size have been correlated with worse outcomes [40–42].

8. Following

Oral cancer has a high risk of local, regional recurrence and development of a secondary primary cancer, but the recurrent rate due to distant metastases is relatively low. The contingency of the second cancer is about 4–7% annually [43]. A comprehensive clinical examination and high vigilance are the cornerstones of the early diagnosis. That's said, lifestyle modifications, such as smoking and drinking management should be a priority since these factors increase the risk of treatment failure and the appearance of second cancer. Unfortunately, preventive chemicals are ineffective and follow-up is the second crucial step. Basic imaging is usually indicated every 3–6 months after the end of treatment or clinical signs are

suspected. Chest radiographs are not routinely used but may be useful in some patients with a history of tobacco addiction. Additional assessments could be included oral and swallowing rehabilitation if being indicated, thyroid hormone test if neck-area radiation and periodic dental examinations are performed.

9. Conclusions

The treatment outcome of oral cancer in recent decades has compellingly improved with the advancement in reconstructive surgery and adjuvant treatment. Further improvement in prolonging survival is hampered by an increase in the second-cancer incidence in long-term patients. With this in mind, oral cancer prevention is the first step, following that a requirement of enhancing awareness, promoting education, improving lifestyle and developing early diagnosis tools should have high consideration.

Conflict of interest

The authors declare no conflict of interest.

Author details


Quang Van Le^{1,2}, Duy Quoc Ngo^{1*}, Toan Duc Tran¹ and Quy Xuan Ngo¹

1 Department of Head and Neck Surgery, Vietnam National Cancer Hospital, Hanoi, Vietnam

2 Hanoi Medical University, Hanoi, Vietnam

*Address all correspondence to: duyyhn@gmail.com

IntechOpen

© 2020 The Author(s). Licensee IntechOpen. This chapter is distributed under the terms of the Creative Commons Attribution License (<http://creativecommons.org/licenses/by/3.0>), which permits unrestricted use, distribution, and reproduction in any medium, provided the original work is properly cited. 

References

- [1] http://globocan.iarc.fr/Pages/factsheets_population.aspx [Accessed: 20 February 2018]
- [2] Harrison LB, Sessions RB, Hong WK. Head and Neck Cancer: A Multidisciplinary Approach. 3rd ed. Philadelphia, PA: Lippincott, William & Wilkins; 2009
- [3] Warnakulasuriya S. Global epidemiology of oral and oropharyngeal cancer. *Oral Oncology*. 2009;**45**:309
- [4] Guha N, Warnakulasuriya S, Vlaanderen J, Straif K. Betel quid chewing and the risk of oral and oropharyngeal cancers: A meta-analysis with implications for cancer control. *International Journal of Cancer*. 2014;**135**:1433
- [5] Castellsagué X, Alemany L, Quer M, et al. HPV involvement in head and neck cancers: Comprehensive assessment of biomarkers in 3680 patients. *Journal of the National Cancer Institute*. 2016;**108**:djv403
- [6] Mello FW, Miguel AFP, Dutra KL, et al. Prevalence of oral potentially malignant disorders: A systematic review and meta-analysis. *Journal of Oral Pathology & Medicine*. 2018;**47**:633
- [7] van der Waal I. Oral leukoplakia, the ongoing discussion on definition and terminology. *Medicina Oral, Patología Oral y Cirugía Bucal*. 2015;**20**:e685
- [8] Holmstrup P, Dabelsteen E. Oral leukoplakia-to treat or not to treat. *Oral Diseases*. 2016;**22**:494
- [9] Pentenero M, Meleti M, Vescovi P, Gandolfo S. Oral proliferative verrucous leucoplakia: Are there particular features for such an ambiguous entity? A systematic review. *British Journal of Dermatology*. 2014;**170**:1039
- [10] Kalavrezos N, Scully C. Mouth cancer for clinicians part 6: Potentially malignant disorders. *Dental Update*. 2015;**42**:866
- [11] Yang SW, Lee YS, Chang LC, et al. Outcome of excision of oral erythroplakia. *The British Journal of Oral & Maxillofacial Surgery*. 2015;**53**:142
- [12] Shah JP, Patel SG, Singh B. Jatin Shah's Head and Neck Surgery and Oncology. 5th ed. Philadelphia, PA: Elsevier Mosby; 2019
- [13] Part II Head and Neck. In: Amid MB, editor. *AJCC Cancer Staging Manual*. 8th ed. New York: Springer; 2017, 2018. p. 53. Corrected at 4th printing
- [14] Tandon S, Shahab R, Benton JI, et al. Fine-needle aspiration cytology in a regional head and neck cancer center: Comparison with a systematic review and meta-analysis. *Head & Neck*. 2008;**30**:1246
- [15] Pisharodi LR. False-negative diagnosis in fine-needle aspirations of squamous-cell carcinoma of head and neck. *Diagnostic Cytopathology*. 1997;**17**:70
- [16] Arya S, Rane P, Deshmukh A. Oral cavity squamous cell carcinoma: Role of pretreatment imaging and its influence on management. *Clinical Radiology*. 2014;**69**:916-930
- [17] Ong C, Chong V. Imaging of perineural spread in head and neck tumours. *Cancer Imaging*. 2010;**10**(1A): S92-S98
- [18] King A, Tse G, Ahuja A, et al. Necrosis in metastatic neck nodes: Diagnostic accuracy of CT, MR imaging, and US. *Radiology*. 2004;**230**(3): 720-726

- [19] King A, Tse G, Yuen E, et al. Comparison of CT and MR imaging for the detection of extranodal neoplastic spread in metastatic neck nodes. *European Journal of Radiology*. 2004; **52**(3):264-270
- [20] Coca-Pelaz A, Rodrigo JP, Suarez C. Clinicopathologic analysis and predictive factors for distant metastases in patients with head and neck squamous cell carcinomas. *Head & Neck*. 2012;**34**:771-775
- [21] Krabbe CA, Pruim J, van der Laan BF, et al. FDG-PET and detection of distant metastases and simultaneous tumors in head and neck squamous cell carcinoma: A comparison with chest radiography and chest CT. *Oral Oncology*. 2009;**45**:234-240
- [22] National Comprehensive Cancer Network: NCCN Practice Guidelines in Oncology: Head and Neck Cancers. 2019. Available from: http://www.nccn.org/professionals/physician_gls/f_guidelines.asp
- [23] Loree TR, Strong EW. Significance of positive margins in oral cavity squamous carcinoma. *American Journal of Surgery*. 1990;**160**:410-414
- [24] Cilento BW, Izzard M, Weymuller EA, et al. Comparison of approaches for oral cavity cancer resection: Lip-split versus visor flap. *Otolaryngology and Head and Neck Surgery*. 2007;**137**:428-432
- [25] Wax MK, Bascom DA, Myers LL. Marginal mandibulectomy vs segmental mandibulectomy: Indications and controversies. *Archives of Otolaryngology – Head & Neck Surgery*. 2002;**128**:600-603
- [26] Wang CC, Cheng MH, Hao SP, et al. Osteoradionecrosis with combined mandibulotomy and marginal mandibulectomy. *Laryngoscope*. 2005; **115**:1963-1967
- [27] Woolgar JA, Scott J. Prediction of cervical lymph node metastasis in squamous cell carcinoma of the tongue/floor of mouth. *Head & Neck*. 1995; **17**(6):463-472
- [28] Spiro RH, Huvos AG, Wong GY, et al. Predictive value of tumor thickness in squamous carcinoma confined to the tongue and floor of the mouth. *American Journal of Surgery*. 1986;**152**(4):345-350
- [29] Robbins KT, Ferlito A, Shah JP, et al. The evolving role of selective neck dissection for head and neck squamous cell carcinoma. *The European Archives of Oto-Rhino-Laryngology*. 2013; **270**(4):1195-1202
- [30] Huang SH, Hwang D, Lockwood G, et al. Predictive value of tumor thickness for cervical lymph node involvement in squamous cell carcinoma of the oral cavity: A meta-analysis of reported studies. *Cancer*. 2009;**115**(7):1489-1497
- [31] Shoaib T, Soutar DS, MacDonald DG, et al. The accuracy of head and neck carcinoma sentinel lymph node biopsy in the clinically N0 neck. *Cancer*. 2001;**91**(11): 2077-2083
- [32] Tupchong L, Scott CB, Blitzer PH, et al. Randomized study of preoperative versus postoperative radiation therapy in advanced head and neck carcinoma: Long-term follow-up of RTOG study 73-03. *International Journal of Radiation Oncology, Biology, Physics*. 1991;**20**(1): 21-28
- [33] Andersen PE, Shah JP, Cambronero E, et al. The role of comprehensive neck dissection with preservation of the spinal accessory nerve in the clinically positive neck. *American Journal of Surgery*. 1994; **168**(5):499-502

- [34] Hanasono MM, Friel MT, Klem C, et al. Impact of reconstructive microsurgery in patients with advanced oral cavity cancers. *Head & Neck*. 2009; **31**:1289-1296
- [35] Hanasono MM, Friel MT, Klem C, et al. Impact of reconstructive microsurgery in patients with advanced oral cavity cancers. *Head & Neck*. 2009; **31**(10):1289-1296
- [36] Cooper JS, Pajak TF, Forastiere AA, et al. Postoperative concurrent radiotherapy and chemotherapy for high-risk squamous-cell carcinoma of the head and neck. *The New England Journal of Medicine*. 2004;**350**(19): 1937-1944
- [37] Bernier J, Dommenege C, Ozsahin M, et al. Postoperative irradiation with or without concomitant chemotherapy for locally advanced head and neck cancer. *The New England Journal of Medicine*. 2004;**350**(19):1945-1952
- [38] Available from: http://seer.cancer.gov/csr/1975_2007/ [Accessed: 14 March 2011]
- [39] Shah JP, Cendon RA, Farr HW, Strong EW. Carcinoma of the oral cavity. Factors affecting treatment failure at the primary site and neck. *American Journal of Surgery*. 1976;**132**: 504
- [40] Gil Z, Carlson DL, Boyle JO, et al. Lymph node density is a significant predictor of outcome in patients with oral cancer. *Cancer*. 2009;**115**:5700
- [41] Myers JN, Greenberg JS, Mo V, Roberts D. Extracapsular spread. A significant predictor of treatment failure in patients with squamous cell carcinoma of the tongue. *Cancer*. 2001; **92**:3030
- [42] Arduino PG, Carrozzo M, Chiecchio A, et al. Clinical and histopathologic independent prognostic factors in oral squamous cell carcinoma: A retrospective study of 334 cases. *Journal of Oral and Maxillofacial Surgery*. 2008;**66**:1570
- [43] Leon X, Martinez V, Lopez M, et al. Second, third, and fourth head and neck tumors. A progressive decrease in survival. *Head & Neck*. 2012;**34**(12): 1716-1719