

# We are IntechOpen, the world's leading publisher of Open Access books Built by scientists, for scientists

**4,800**

Open access books available

**122,000**

International authors and editors

**135M**

Downloads

Our authors are among the

**154**

Countries delivered to

**TOP 1%**

most cited scientists

**12.2%**

Contributors from top 500 universities



**WEB OF SCIENCE™**

Selection of our books indexed in the Book Citation Index  
in Web of Science™ Core Collection (BKCI)

Interested in publishing with us?  
Contact [book.department@intechopen.com](mailto:book.department@intechopen.com)

Numbers displayed above are based on latest data collected.

For more information visit [www.intechopen.com](http://www.intechopen.com)



# Bullet and Shrapnel Embolism: When “Uncommon” Meets “Dangerous”

*Stephen D. Dingley, Zachary E. Darby, Jennifer C.B. Irick,  
Gregory Domer and Stanislaw P. Stawicki*

## Abstract

Bullet and shrapnel embolism (BSE) is well described in the literature. Despite that, its rare occurrence creates a diagnostic challenge for providers tending to penetrating trauma victims. As with other forms of embolic phenomena, cases of BSE require a blend of superb clinical expertise and experience, as well as a high diagnostic index of suspicion. Management is highly individualized and spans a broad spectrum of options from “watchful waiting” to open heart surgery. Due to the risk of retained projectile migration through tissues, including erosion into surrounding anatomic structures, non-operative approaches warrant long-term clinical surveillance. When promptly recognized and treated appropriately, patients with BSE can be expected to have excellent clinical outcomes.

**Keywords:** bullet embolism, clinical management, diagnosis, shrapnel embolism, treatment

## 1. Introduction

With approximately only 300 published cases to date, bullet and shrapnel emboli (BSE) constitute a rare, but well-established, phenomenon in trauma [1–3]. The incidence of BSE has been reported to range between 0.3 and 1.1% of penetrating injuries, depending on the type of projectile, the setting of injury, and various patient characteristics [4].

The literature on the topic is heavily case-based, limiting both the generalizability and applicability of the findings [1–3, 5]. Consequently, clinical progress appears to follow the publication of major case series and definitive reviews on the topic. A 1950 review by Barrett presented a collected series of foreign bodies which have embolized into the cardiovascular system [2]. In the early 1960s, Kinmonth et al. published a case and a commentary titled, “Gunshot wounds of the heart with embolism” [5]. In that report, the authors describe open heart surgery using extracorporeal circulatory support to extract loose shotgun pellets from cardiac cavities [5]. In the late 1970s, Mattox et al. [6] published an important series describing clinical management of nearly 30 cases of intravascular migratory bullets. Over the past three decades, controversies persisted regarding the preferred stance on BSE, ranging from “watchful waiting” to “mandatory removal” [1, 7]. Today, approaches to BSE involve state-of-the-art diagnostic and therapeutic developments, from

high-resolution computed tomography (CT) imaging to endovascular retrieval techniques [8]. In this chapter, we provide an overview of BSE, starting with case-based historical perspective and ending with a summary of modern developments in this rarely encountered but important area of penetrating trauma management.

## **2. Case-based historical perspective**

Surgical case history is rich with fascinating stories demonstrating both the natural history and the evolution of clinical management of BSE. In an 1834 report, Davis describes what may well be the first formal case report of BSE. The patient was a 10-year-old boy who, while making a gun, accidentally set off the gunpowder and was shot with a 3-inch piece of wood. This pierced his chest to the right of the sternum between the 3rd and 4th ribs. The patient lived for 37 days and Davis reported that the autopsy showed no injury to the heart. Instead, it appeared that the object had pierced through the lung and into vena cava, from where it traveled to the right ventricle (RV) [9].

Another early report originated during the First Anglo-Burmese War in 1824, whereby a soldier suffered a rifle shot into the left axilla [2]. He was subsequently noted to have drainage of blood, air, and later purulent material from his wound. Unfortunately, he went on to succumb to this injury 3 days later. An autopsy showed the tract of the round bullet into the left lung, with the projectile eventually migrating into the left ventricle (LV). Of note, there was no direct injury to the heart. The bullet appeared to have penetrated a pulmonary vein and traveled back to the heart [2].

Despite his skeptical stance toward the original report by Davis [9], Bland-Sutton in 1919 stated that “in regard to the embolic theory that (Davis) advanced to explain the presence of the stick in the ventricle” it was important to emphasize that “at the date of the accident surgeons knew nothing of the transport of blood-clot either to or from the heart” [10]. It was only around that time that Virchow’s theory regarding deep venous thrombosis (DVT) and pulmonary embolism (PE) was coming into formation [11, 12].

Even during the time of Barrett’s review in 1950 with comparatively limited access to information and drastically fewer publications than today, he stated that “any writer who believes his case to be singular or unique is probably not well-informed” [2]. The same point continues to be true despite tremendous progress in trauma surgery since the 1950s. Therefore, it is the authors’ duty to inform the reader that although cases of BSE are rare, they have indeed been well-documented in the literature and tend to follow a number of fairly typical patterns [7, 13–16]. The modern surgeon or interventionalist must be aware not only of the presence of BSE but also key aspects of diagnosis, clinical management approaches, and possible short- and long-term outcomes [1, 7].

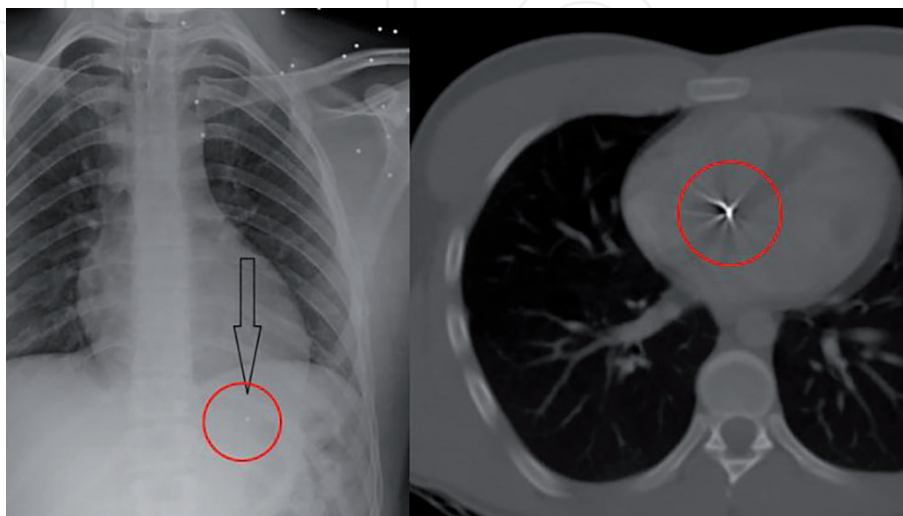
## **3. Anatomic, pathophysiological, and diagnostic considerations**

A bullet or shrapnel may undergo embolization when it only penetrates a single vessel wall and subsequently enters the circulation [4, 8]. To cross only one vessel wall and come to rest within the vessel, the bullet or projectile must be of a smaller diameter than the vessel and must possess kinetic energy that allows the initial penetration but is insufficient to allow subsequent extravascular re-emergence. In general, a bullet or projectile without such narrowly defined characteristics will be highly unlikely to embolize. It is not surprising, therefore, that shotgun pellets and

22-caliber bullets are the two most common projectiles associated with BSE [3, 17, 18]. In fact, the vast majority of the cases in literature feature bullets that are 0.38 caliber and smaller, with only one recorded case of a 0.40 caliber bullet embolism [18]. An example of distal embolization of a shotgun pellet from the left brachiocephalic vein to the right ventricle is shown in **Figure 1** [19]. The incidence of shrapnel-related BSE may be even lower [4]. Projectiles from non-powdered guns, often regulated as recreational toys rather than weapons, can pose significant risk of embolization, with a recent systematic review calling attention to this public health risk in the pediatric population [20].

While it is often difficult to determine the presence of a BSE, there are several diagnostic findings that should raise suspicion. To start, an inconsistent number of entry and exit wounds may suggest a retained bullet. Secondly, when there is no evidence, either radiographically or clinically, of the bullet along the extrapolated course or if the bullet is found at a distant location, the possibility of BSE should be entertained. Lastly, when the piece of shrapnel (or a bullet) is seen in different locations on serial radiograph images, the phenomenon of a “migrating projectile” should increase the suspicion for BSE [21]. In one case, the application of whole body CT scan was instrumental in effectively localizing an embolized shrapnel fragment within the right mid-lobar pulmonary artery [4]. This particular example demonstrates that if small enough, grenade/bomb fragments can find their way to intravascular locations that are far removed from the area of original injury [4].

Projectiles can enter the cardiovascular system in a myriad of ways, including by direct entrance into an artery or vein, direct entrance into the chambers of the heart, or erosion from the lungs into the pulmonary vasculature [22]. According to a systematic review by Kuo et al. [20], reporting on 261 cases of BSE, embolization via venous route is most common (56%), with arterial (27%) and cardiac injuries (15%) seen less frequently. It is imperative that physicians are able to recognize the signs and symptoms of BSE so that timely and appropriate care can be instituted, with the goal of minimizing both associated complications and mortality. Because bullet embolism to the peripheral arterial system is an extremely rare phenomenon, early symptoms/manifestations are often misdiagnosed. Thus, in any patient presenting with history of exposure to bullet or shrapnel, as well as the appropriate clinical context and symptomatology, one must be vigilant in assessing for the



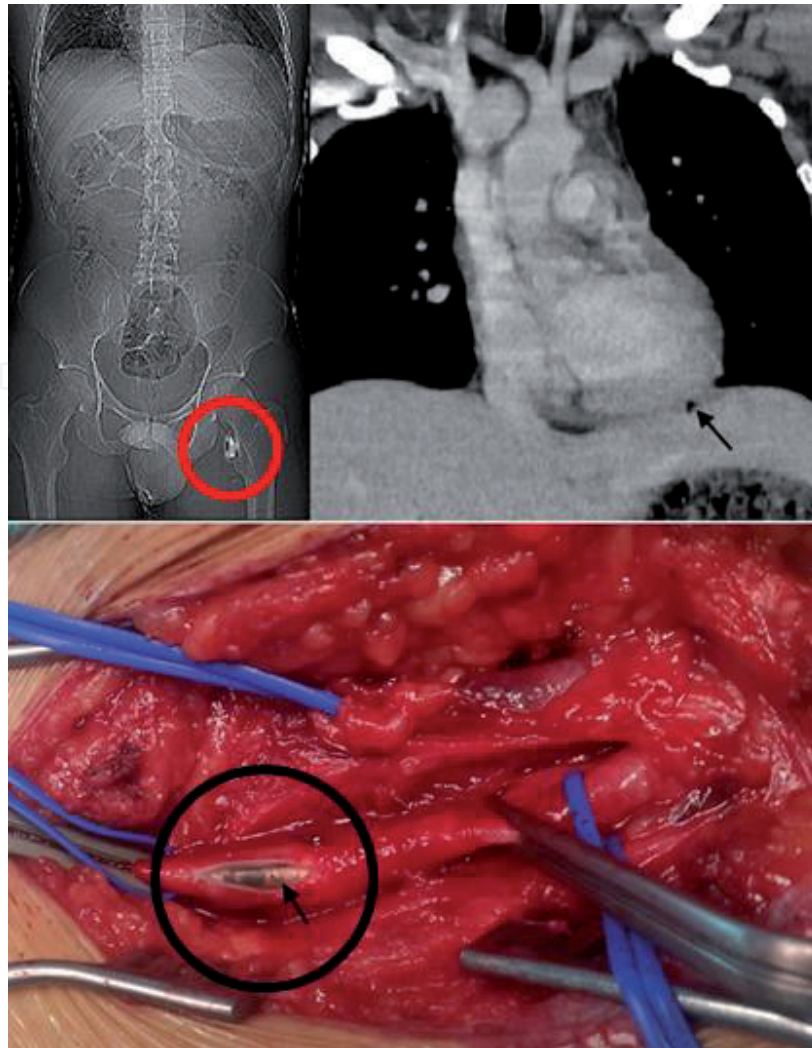
**Figure 1.** An example of a pellet from a shotgun blast to the left upper chest/proximal left arm area (left), with pellet embolization to the right ventricle (CT image, right). Source: Greaves [19]. Images reproduced and modified under the terms of the creative commons attribution license (<http://creativecommons.org/licenses/by/2.0>) which permits sharing and adapting of published work, as long as original work is properly cited/attributed.

signs of acute arterial occlusion. These manifestations include the presence of pain, pallor, paresthesias, pulselessness, poikilothermia, and paralysis. The sequential appearance of these signs and symptoms is important when determining the duration of ischemia and prognosis through the Rutherford classification for acute limb ischemia. One must also consider the possibility of BSE when the wound–projectile locations are discordant on imaging. In most cases, an arterial projectile should be removed as soon as possible, even if the patient is initially asymptomatic as the embolus may become symptomatic, resulting in profound clinical sequelae and potential morbidity [23].

The reported distribution of BSE between venous, arterial, and cardiac portals of entry varies across published studies [4, 20, 21]. Nonetheless, clinical manifestations and management principles tend to be fairly consistent across the literature. The principal complication from arterial emboli is extremity or end-organ ischemia and thrombosis, which may occur due to the fact that intra-arterial projectiles travel with the flow of blood until they become wedged in smaller, more distal vessels. Given that significant proportion of BSE are sufficiently large to occlude a medium diameter vessel, the clinical relevance of bullet or shrapnel embolism becomes readily apparent. Not surprisingly, approximately 80% of arterial emboli are symptomatic and thus tend to present earlier and prompt more immediate treatment [3]. The foremost intervention utilized for arterial emboli is embolectomy, which is currently considered as the gold standard, with both open and endovascular techniques described [4, 24]. An example of a bullet causing left chest injury and subsequently embolizing to the left common femoral artery is provided in **Figure 2** [25]. The more commonly used military or civilian weapons fire bullets of 9 mm or greater diameter. This, in turn, means that such projectiles are unlikely to embolize beyond the iliac arteries distally or the common carotid and subclavian arteries proximally. At the same time, shotgun projectiles can be found virtually anywhere in peripheral arterial or venous circulation, with each pellet measuring approximately 2 mm in diameter [26, 27].

While venous BSE also typically follow the flow of blood, there are certain subtypes where venous emboli travel in a nonconforming fashion. For example, bullets may travel retrograde, due to the effects of gravity, within the venous system and thus manifest as “retrograde emboli”; however, this occurs only in an estimated 15% of instances [28]. Additionally, the projectile may cross over from venous to arterial circulation, becoming a “paradoxical” BSE. This usually requires the presence of a traumatic arteriovenous fistula (AVF) or an intracardiac defect, such as a patent foramen ovale or ventricular septal defect [3]. The incidence of such paradoxical emboli appears to be low, or approximately 2.4% [29]. In most (>80%) cases, therefore, venous BSE tend to migrate with the flow of blood and most commonly come to rest in the right heart or the pulmonary arterial (PA) system [1]. In a 2011 review, Schroeder et al. [30] pointed out that among 120 cases over a 90-year period, 83% of venous BSE terminate their intravascular journey in the PA or the right heart, while 4% remain in the peripheral venous system.

Embolized venous projectiles may be associated with a multitude of potential complications including, but not limited to, pulmonary artery embolism, cardiac valve dysfunction, dysrhythmias, intraventricular communications, cardiac conduction defects, endocarditis, abscess formation, sepsis, thrombosis, tissue erosion, hemorrhage, pseudoaneurysm, cardiac ischemia from erosion into coronary vessels, and thrombophlebitis [7, 21, 31]. However, it is important to keep in mind that venous emboli are only symptomatic in approximately one-third of cases, with clinically detectable complications related to the initial injury often noted months or even years later. Therefore, the preferred treatment approach, as well as the overall interventional aggressiveness, toward venous emboli has remained controversial [21, 32].



**Figure 2.**

*An example showing images of a thoracic stray bullet that lodged within the left femoral artery. Intraoperative picture (bottom) shows the bullet immediately prior to its removal. Source: Aoun et al. [25]. Images reproduced under the terms of the CC BY-NC-ND license (<http://creativecommons.org/licenses/by-nc-nd/4.0/>) which permits sharing of published work, as long as original work is properly credited.*

While a conservative approach in asymptomatic patients with retained projectiles may be warranted, there are case reports of patients presenting up to 6 years post-injury with sequelae of BSE [33]. Given the possibility for delayed morbidity, it is vital that medical specialties maintain a high index of suspicion for the risk of BSE in patients with even a remote history of penetrating trauma complicated by retained foreign objects, as these patients may present with relatively innocuous symptoms that are not obviously related to the initial insult.

#### **4. Evolution of modern management approaches**

As early as 1939, Decker published an important review of a large collected series of cases, seeking to determine the optimal management of intracardiac BSE [34]. Across the sources reviewed, 47 patients underwent BSE removal with a mortality rate of 17%, while 53 underwent observation with a mortality rate of 30%. These preliminary findings suggested a benefit to BSE removal [34]. In 1946, Harken and Zoll laid out the principles for removing BSE, which were subsequently used as the authoritative guidance for the next few decades [35]. To summarize, Harken and Zoll's guiding principles and goals of therapy included:

- The prevention of embolus of the foreign body or associated thrombus
- The reduction of the risk of bacterial endocarditis
- The prevention of recurrent pericardial effusion(s)
- The reduction of BSE-related myocardial damage, including any associated pain or other morbidity [35]

With advancements in surgical techniques, up to and including cardiopulmonary bypass, open BSE removal options became increasingly sophisticated and safer [36, 37]. The next advancement in management was made possible by further innovations in surgical technology that facilitated endovascular approaches, such as the removal of cardiac bullet “via a wire basket” [6].

In the late 1970s, Mattox et al. reported their experience involving 28 patients with intravascular bullet emboli [6]. In terms of projectile origin–destination pairings, this important article described BSE events as follows:

- Seven patients with peripheral vein to PA embolization
- Six patients with abdominal aorta to peripheral artery migration
- Five cases involving peripheral vein to heart embolization
- Four patients with thoracic aorta to peripheral artery migration
- Three cases of heart to peripheral artery embolization
- Two instances of heart to inferior vena cava (IVC) migration
- And finally one case of paradoxical embolism from IVC to abdominal aorta via penetration of the atrial septa [6]

In terms of management approaches, a total of 20 (71.4%) of projectiles were removed (12 peripheral artery, 5 heart, 2 PA, and 1 aortic bifurcation), removal of 1 projectile (3.6%) involving the carotid was unsuccessful, and 7 projectiles were left in place (5 in PA, 1 in hepatic vein, and 1 in renal vein) [6]. Morbidity in their series was limited to the bullet being left in place rather than efforts at retrieval. Two patients died, one from the propagation of carotid thrombosis and subsequent distal ischemia and the other from unrecognized cardiac trauma related to the bullet. Synthesizing their experience and prior literature reports, the authors recommended that most BSE should be removed [6].

Subsequent reports describe a wide range of therapeutic approaches, from clinical observation to intravascular BSE removal [7, 38–41]. With the entire spectrum of considerations within this evolving area being beyond the scope of the current chapter, the reader is encouraged to consult literature sources referenced below. More specifically, Kortbeek et al. provide an overview of conservative management approaches to pulmonary artery BSE [39]. Although potentially biased, their collected series suggests a favorable morbidity and mortality profile [39]. On the other hand, Shannon et al. [40] and Adegboyega et al. [7] advocate for mandatory BSE extraction, citing substantial morbidity and mortality of projectiles left in place [7, 40]. Furthermore, Norton et al. highlight the relative safety of modern cardiac procedures as part of their rationale for recommending the surgical approach [42].

The potential for delayed presentation has also been suggested as a rationale for surgical intervention [41]. More recently, percutaneous radiographic interventions have been increasingly common, as demonstrated by case reports of endovascular extraction of an intracardiac BSE [38, 43]. Yang et al. present a 12-case experience with nonsurgical management of intravascular foreign bodies [44].

In a recent review of 261 cases of BSE by Kuo et al. [20], authors propose a management strategy algorithm for intravascular projectiles, based on the evidence that foreign objects within the “left-sided” (e.g., left cardiac chambers, systemic arteries, pulmonary veins) circulation pose a greater risk of complications than those within the “right-sided” (e.g., right cardiac chambers, systemic veins, pulmonary arteries) circulation. Their algorithm considers the circulatory site (left vs. right), the presence or absence of symptoms, as well as presence of a cross-circulation shunt. They propose that all missiles to the “left-sided” circulation be removed either by operative or endovascular routes, while objects within the “right-sided” circulation may be safely managed conservatively if the patient is asymptomatic and does not have a right-to-left shunt [20].

Symptomatic BSEs can be defined as those leading to any of the potential complications mentioned throughout this article. Whenever possible, symptomatic BSE should be removed using endovascular approaches as the primary management option. Specific indications for removal include objects >5 mm in diameter, irregularly shaped objects, and projectiles that are freely mobile or only partially embedded within the myocardium [45, 46]. Advanced endovascular techniques can help facilitate safe removal of BSE, as exemplified by a 1980s report describing the first use of endovascular snare to retrieve a bullet embolus from the RV [47]. Since then multiple additional reports described various endovascular techniques and approaches for removing BSE across a broad range of anatomic locations [30, 44, 48, 49].

The management of asymptomatic venous emboli is not clearly defined and continues to be somewhat controversial. Nagy et al. [45] proposed criteria for non-operative management of such BSEs, recommending observation for right-sided cardiac and pulmonary artery BSE if there was no arrhythmia and no valvular dysfunction, the BSE was smooth and <5 mm, it was firmly in place, and there was no gastrointestinal contamination. In asymptomatic cases, the risk of surgical intervention involving the PA or RV must be weighed against the risk of delayed embolic or infective complications. When comparing available evidence, surgical intervention versus observation for venous BSE appears to produce no difference in outcome [39, 40]. Some authors have advocated for observation if an endovascular approach cannot be utilized given the arguably higher morbidity and mortality of open retrieval options, such as sternotomy and cardiopulmonary bypass [21]. The clinical heterogeneity of venous BSEs and limited clinical evidence have made it impractical to have a strict definition and a rigid approach toward conducting non-operative management. Instead, a set of loose recommendations evolved for outpatient follow-up featuring serial imaging, consideration of therapeutic anticoagulation, and potentially antibiotic prophylaxis when appropriate [24, 50].

## **5. Summary of specific clinical presentations**

Due to the heterogeneity of anatomic locations and differing projectile-specific propensity to migrate and cause complications, a broad range of clinical presentations have been described. For example, cardiac-related findings may include valvular insufficiency [21, 31], broadly defined “cardiac irritability” such as the appearance of arrhythmias [41], and even sudden death [51]. Common pulmonary manifestations of BSE include chest pain, cough, dyspnea, and hemoptysis [22, 52]. Reported central



nervous system manifestations include both direct and paradoxical embolization leading to a stroke or other thromboembolic sequelae [21]. Peripheral vascular BSE may present with thrombophlebitis, venous thrombosis, vascular insufficiency, as well as limb ischemia [7, 21]. Finally, as outlined earlier in this chapter, one must keep in mind that arterial emboli will tend to present much earlier than venous emboli and that any major end-organ is potentially at risk of being affected [21].

## 6. Conclusions

Given the heterogeneity of presentations, projectile or shrapnel types, and variability of anatomic locations, management of BSE depends heavily on the clinical judgment of the treating physician. Specific considerations should take into account the anatomic location of the BSE, any associated symptoms, patient comorbidity profile, hospital endovascular capabilities, and the risk–benefit determination regarding more invasive interventions. Perhaps more important than the nuance in management is the necessity of recognition that BPE exists and is well-documented. Prompt workup to diagnose this phenomenon can be lifesaving and should guide the subsequent treatment. As our general understanding of the problem increases, the management of BSE will likely continue to move toward endovascular approaches, especially given the ongoing technological and procedural advances.

## Author details

Stephen D. Dingley<sup>1</sup>, Zachary E. Darby<sup>2,3</sup>, Jennifer C.B. Irick<sup>4</sup>, Gregory Domer<sup>1</sup> and Stanislaw P. Stawicki<sup>1,5\*</sup>

<sup>1</sup> Department of Surgery, St. Luke's University Health Network, Bethlehem, Pennsylvania, USA

<sup>2</sup> Medical School of St. Luke's University Health Network, Bethlehem, Pennsylvania, USA

<sup>3</sup> Lewis Katz School of Medicine at Temple University, Bethlehem, Pennsylvania, USA

<sup>4</sup> Department of Emergency Medicine, St. Luke's University Health Network, Easton, Pennsylvania, USA

<sup>5</sup> Department of Research and Innovation, St. Luke's University Health Network, Bethlehem, Pennsylvania, USA

\*Address all correspondence to: [stawicki.ace@gmail.com](mailto:stawicki.ace@gmail.com)

## IntechOpen

© 2020 The Author(s). Licensee IntechOpen. This chapter is distributed under the terms of the Creative Commons Attribution License (<http://creativecommons.org/licenses/by/3.0>), which permits unrestricted use, distribution, and reproduction in any medium, provided the original work is properly cited. 

## References

- [1] Wojda TR et al. Foreign intravascular object embolization and migration: Bullets, catheters, wires, stents, filters, and more. In: *Embolic Diseases-Unusual Therapies and Challenges*. London, UK: IntechOpen; 2017
- [2] Barrett NR. Foreign bodies in the cardiovascular system. *The British Journal of Surgery*. 1950;**37**:416
- [3] Lu K et al. Approach to management of intravascular missile emboli: Review of the literature and case report. *The Western Journal of Emergency Medicine*. 2015;**16**(4):489-496
- [4] Khomenko I et al. Pulmonary artery embolism by a metal fragment after a booby trap explosion in a combat patient injured in the armed conflict in East Ukraine: A case report and review of the literature. *Journal of Medical Case Reports*. 2018;**12**(1):330
- [5] Kinmonth J et al. Gunshot wounds of the heart with embolism. *British Medical Journal*. 1961;**2**(5268):1666
- [6] Mattox KL et al. Intravascular migratory bullets. *American Journal of Surgery*. 1979;**137**(2):192-195
- [7] Adegboyega PA, Sustento-Reodica N, Adesokan A. Arterial bullet embolism resulting in delayed vascular insufficiency: A rationale for mandatory extraction. *Journal of Trauma and Acute Care Surgery*. 1996;**41**(3):539-541
- [8] Carter CO et al. Venous bullet embolism and subsequent endovascular retrieval—A case report and review of the literature. *International Journal of Surgery Case Reports*. 2012;**3**(12):581-583
- [9] Davis T. Singular case of a foreign body found in the heart of a boy. *Transactions of the Provincial Medical and Surgical Association*. 1834;**2**:357-360
- [10] Bland-Sutton J. Introductory. *British Journal of Surgery*. 1919;**7**(25):1-6
- [11] Bagot CN, Arya R. Virchow and his triad: A question of attribution. *British Journal of Haematology*. 2008;**143**(2):180-190
- [12] Szczepański M. Elements of Virchow's triad in the prevention and treatment of venous thrombosis. *Polish Journal of Surgery*. 2009;**81**(8):364-371
- [13] Patel K et al. Bullet embolism. *The Journal of Cardiovascular Surgery*. 1989;**30**(4):584-590
- [14] Trimble C. Arterial bullet embolism following thoracic gunshot wounds. *Annals of Surgery*. 1968;**168**(5):911
- [15] Schurr M, McCord S, Croce M. Paradoxical bullet embolism: Case report and literature review. *Journal of Trauma and Acute Care Surgery*. 1996;**40**(6):1034-1036
- [16] Bertoldo U et al. Retrograde venous bullet embolism: A rare occurrence—Case report and literature review. *Journal of Trauma and Acute Care Surgery*. 2004;**57**(1):187-192
- [17] Hollerman JJ et al. Gunshot wounds: 2. Radiology. *American Journal of Roentgenology*. 1990;**155**(4):691-702
- [18] Stallings LA et al. Right ventricular bullet embolism: Diagnostic and therapeutic decisions. *Injury Extra*. 2013;**44**(7):64-66
- [19] Greaves N. Gunshot bullet embolus with pellet migration from the left brachiocephalic vein to the right ventricle: A case report. *Scandinavian Journal of Trauma, Resuscitation and Emergency Medicine*. 2010;**18**(1):36
- [20] Kuo AH et al. Systematic review of civilian intravascular ballistic embolism

- reports during the last 30 years. *Journal of Vascular Surgery*. 2019;**70**(1):298-306
- [21] Miller KR et al. The evolving management of venous bullet emboli: A case series and literature review. *Injury*. 2011;**42**(5):441-446
- [22] Hassan AM et al. Pulmonary bullet embolism—A safe treatment strategy of a potentially fatal injury: A case report. *Patient Safety in Surgery*. 2009;**3**(1):12
- [23] Schwoerer AP, Omshoro-Jones JA, Zellweger R. A bullet embolism to the right popliteal artery following an abdominal gunshot wound. *European Journal of Trauma*. 2004;**30**(5):319-322
- [24] Fernandez-Ranvier GG et al. Pulmonary artery bullet embolism—Case report and review. *International Journal of Surgery Case Reports*. 2013;**4**(5):521-523
- [25] Aoun T, Amine F, Ziad K. Femoral artery embolization of a thoracic stray bullet. *Journal of Vascular Surgery Cases and Innovative Techniques*. 2017;**3**(3):123-125
- [26] Barnes FC, Woodard WT. *Cartridges of the World*. 15th ed. Stevens Point, Wisconsin, USA: Krause Publishing; 2016
- [27] Huang J et al. Popliteal artery embolism of bullet after abdominal gunshot wound. *Radiology Case Reports*. 2016;**11**(4):282-286
- [28] Pan GZ et al. Bullet embolization from an aorto-caval fistula to the heart. *Interactive Cardiovascular and Thoracic Surgery*. 2013;**16**(5):710-711
- [29] Springer J, Newman W, McGoey R. Intravascular bullet embolism to the right atrium. *Journal of Forensic Sciences*. 2011;**56**:S259-S262
- [30] Schroeder ME et al. Retrograde migration and endovascular retrieval of a venous bullet embolus. *Journal of Vascular Surgery*. 2011;**53**(4):1113-1115
- [31] Ettinger J et al. Cardiac bullet embolus after thoracic vena cava penetrating injury causing tricuspid valve insufficiency. *International Journal of Surgery*. 2007;**5**(1):66-68
- [32] Manganas C et al. Traumatic pulmonary arteriovenous malformation presenting with massive hemoptysis 30 years after penetrating chest injury. *The Annals of Thoracic Surgery*. 2003;**76**(3):942-944
- [33] Elison RMA et al. Surgical management of late bullet embolization from the abdomen to the right ventricle: Case report. *International Journal of Surgery Case Reports*. 2017;**39**:317-320
- [34] Decker HR. Foreign bodies in the heart and pericardium: Should they be removed? *Journal of Thoracic Surgery*. 1939;**9**:62-79
- [35] Harken DE, Zoll PM. Foreign bodies in and in relation to the thoracic blood vessels and heart; indications for the removal of intracardiac foreign bodies and the behavior of the heart during manipulation. *American Heart Journal*. 1946;**32**:1-19
- [36] Swan H, Forsee JH, Goyette EM. Foreign bodies in the heart; indications for and technic of removal with temporary interruption of cardiac blood flow. *Annals of Surgery*. 1952;**135**(3):314-323
- [37] Cysne E et al. Bullet embolism into the cardiovascular system. *Texas Heart Institute Journal*. 1982;**9**(1):75-80
- [38] Best IM. Transfemoral extraction of an intracardiac bullet embolus. *The American Surgeon*. 2001;**67**(4):361
- [39] Kortbeek JB, Clark JA, Carraway RC. Conservative

management of a pulmonary artery bullet embolism: Case report and review of the literature. *The Journal of Trauma*. 1992;**33**(6):906-908

[40] Shannon FL et al. Venous bullet embolism: Rationale for mandatory extraction. *The Journal of Trauma*. 1987;**27**(10):1118-1122

[41] Wales L, Jenkins DP, Smith PL. Delayed presentation of right ventricular bullet embolus. *The Annals of Thoracic Surgery*. 2001;**72**(2):619-620

[42] Norton JR et al. Bullet embolus to the right ventricle: Report of three cases. *The American Journal of Surgery*. 1971;**122**(5):584-590

[43] Ghanaat M et al. Endovascular management of an intracardiac bullet. *Injury*. 2015;**46**(1):166-168

[44] Yang F-S et al. Non-surgical retrieval of intravascular foreign body: Experience of 12 cases. *European Journal of Radiology*. 1994;**18**(1):1-5

[45] Nagy KK et al. Missile embolization revisited: A rationale for selective management. *The American Surgeon*. 1994;**60**(12):975-979

[46] Khanna A, Drugas GT. Air gun pellet embolization to the right heart: Case report and review of the literature. *The Journal of Trauma*. 2003;**54**(6):1239-1241

[47] Hartzler GO. Percutaneous transvenous removal of a bullet embolus to the right ventricle. *The Journal of Thoracic and Cardiovascular Surgery*. 1980;**80**(1):153-155

[48] Nolan T et al. Bullet embolization: Multidisciplinary approach by interventional radiology and surgery. *Seminars in Interventional Radiology*. 2012;**29**(3):192-196

[49] Kaushik VS, Mandal AK. Non-surgical retrieval of a bullet embolus from the right heart. *Catheterization and Cardiovascular Interventions*. 1999;**47**(1):55-57

[50] Dato GMA et al. Posttraumatic and iatrogenic foreign bodies in the heart: Report of fourteen cases and review of the literature. *The Journal of Thoracic and Cardiovascular Surgery*. 2003;**126**(2):408-414

[51] Padula RT, Sandler SC, Camishion R. Delayed bullet embolization to the heart following abdominal gunshot wound. *Annals of Surgery*. 1969;**169**(4):599

[52] Symbas PN, Harlaftis N. Bullet emboli in the pulmonary and systemic arteries. *Annals of Surgery*. 1977;**185**(3):318