

# We are IntechOpen, the world's leading publisher of Open Access books Built by scientists, for scientists

**4,800**

Open access books available

**122,000**

International authors and editors

**135M**

Downloads

Our authors are among the

**154**

Countries delivered to

**TOP 1%**

most cited scientists

**12.2%**

Contributors from top 500 universities



**WEB OF SCIENCE™**

Selection of our books indexed in the Book Citation Index  
in Web of Science™ Core Collection (BKCI)

Interested in publishing with us?  
Contact [book.department@intechopen.com](mailto:book.department@intechopen.com)

Numbers displayed above are based on latest data collected.

For more information visit [www.intechopen.com](http://www.intechopen.com)



# The Surgical Management of Hydatid Cyst of the Liver: What is New?

Mehmet Mihmanli, Mert Tanal, Emre Bozkurt  
and Onur Guven

## Abstract

Liver hydatid cyst is a disease of zoonosis caused by *Echinococcus granulosus* or less frequently by *Echinococcus multilocularis* and *Echinococcus oligarthrus*. The primary carriers are canines, while human beings are secondary hosts. Early diagnosis is important for cysts not to become complicated and for the treatment not to get difficult. The most effective treatment of uncomplicated hydatid cyst is to reduce the dead space of the cavity and to discharge the fluid as much as possible. However, if the cysts get complex, there is no standard treatment management defined other than offered management options by authors. In complex conditions, the treatment is determined according to the stage of the cyst and the relation of the cyst with biliary ducts or surrounding organs. In this chapter, the treatment regimens of liver hydatid disease mainly based on interventions and surgical operations are going to take a part.

**Keywords:** conservative surgery, *Echinococcus*, hydatid cyst, PAIR, radical surgery, zoonosis

## 1. Introduction

There are mainly three types of *Echinococcus* causing diseases in humans: *E. granulosus*, *E. alveolaris* (*E. multilocularis*), and *E. oligarthrus*. This chapter will be based on the surgical approaches to hydatid cysts caused by *E. granulosus*.

## 2. Pathophysiology

The agent of hydatid cysts is *Echinococcus granulosus* which belongs to the tapeworm family of cestodes. The tapeworm consists of four segments. The most important segment is the first segment, which consists of four hooked structures that help the pathogen attach to the tissues. The life cycle of the pathogen is unique and explains the pathology.

The hydatid cyst lesion has a round cystic structure and consists of three main layers: an external fibrous pericyst 2–4 mm thick, mainly composed of the host's tissues to protect itself from the cyst; 2-mm-thick middle, nucleus-free hyaline layer, also known as ectocyst, or the laminar membrane in other words; and parasitic inner germinal membrane, known as endocyst. The annual growth rate of the cysts is 1–3 cm per year.

The germinative layer on the wall of the cyst is the site of asexual proliferation and secretes the cystic fluid. The larvae also emerge from this layer. If the connections between the laminar layer and the pericyst layer break down, the oxygenation of the cyst deteriorates and cannot produce liquid. The inevitable consequence of this is that the growth of the cyst stops.

### 2.1 Life cycle of *E. granulosus*

The disease lives in canines that are infected by eating the internal organs of sheep which contain hydatid cysts. The eggs in the cysts adhere to the small intestines of the dogs and become adult tapeworms attached to the intestinal wall. Each worm holds about 500 ovaries in the intestine. Dog feces containing infected eggs contaminate grasses and farmland, and the ovaries are swallowed by intermediate hosts such as sheep, cattle, pigs, and humans. The egg has chitinous envelopes that are dissolved with gastric juice. The released ovary then passes through the intestinal mucosa and is transported by the portal vein to the liver, where it develops in an adult cyst. Most cysts are caught in hepatic sinusoids, and therefore 70% of hydatid cysts occur in the liver, often in the right inferior segments. The placed embryo is immediately transformed into larvae. The larvae turn to the vesicle (scolex) and to the cyst at the end. The larvae can multiply asexually. Thus, there may be more than one living larva in a single cyst. Several pathogens pass through the liver, and the lung keeps them in its capillary bed, or they enter to the systemic circulation to form cysts in the lungs, spleen, brain, or bones.

## 3. Diagnosis

Uncomplicated cysts may be silent and incidental. Rarely, the affected patient has symptoms such as right upper quadrant pain or abdominal distension. The cysts may be secondary infected (usually by *E. coli*), invade other organs, or even cause ruptures leading to an allergic or anaphylactic reaction.

There are four medical tests used in diagnosis: Casoni skin test, the complement fixation test, *Echinococcus* IHA (indirect hemagglutination) test, and enzyme-linked immunosorbent assay (ELISA). The Casoni skin test is no longer used. The complement fixation test (Weinberg) is not widely used in diagnosis (the sensitivity is about 80%), but it is useful in follow-up because it becomes negative after the first year of the treatment. Its sensitivity is about 90% by then.

The *Echinococcus* IHA (indirect hemagglutination) is the most commonly used diagnostic test in practice. Its sensitivity is 90%. The *Echinococcus* IHA test is done by the patient's serum taken and diluted on microplates in times of 2, 4, 8, 16, 32, 64, 128, 256 ... 2048. A kit recognizing echinococcal antibodies is added to each microplate medium. If erythrocytes form agglutination in the presence of a kit, this indicates that the test is positive at that density. It is significant that IHA is positive at dilutions exceeding 1/128. However, many authors accept a 1/256 dilution as the presence of the disease. Positivity at lower dilutions means that the patient got cured or the disease is currently inactive.

It should be kept in mind that once IHA is positive, it may remain positive for more than 20 years. In a comprehensive epidemiological study published in Turkey, the positive prevalence of the *Echinococcus* IHA is 291/100,000 in the general population.

The diagnosis of hydatid cyst disease is based on the findings of ELISA for echinococcal antigens, and results are positive in approximately 85% of infected

patients. The test may be negative if it is not leaking or the parasite is no longer alive.

In conclusion, the serological screening tests based on antigens (e.g., indirect hemagglutination, latex agglutination, ELISA) are highly associated with false-positive and false-negative results. However, while ELISA detection of specific antigens and immune complexes of the cyst has a much higher sensitivity, ELISA and radioallergosorbent test (RAST) can also detect specific IgE antibodies. Antigen 5 (arc-5) and antigen B8 are the major parasitic antigens having diagnostic value.

Eosinophilia occurs in approximately 30% of infected patients. Ultrasonography and CT scan of the abdomen are very sensitive in hydatid cyst detection, and the appearance of cysts on images depends on the stage of cyst development. Ultrasound images may show peripheral calcifications of cysts or curved bands of delaminated endocysts, called lotus. In CT scans, hydatid cysts are usually seen as hypodense lesions.

Calcification of female cysts occurs in approximately 75% of cases and 50% of the surrounding cyst wall [1]. As healing occurs, the entire cyst densely calcifies, and a lesion with this appearance is usually dead or ineffective. Daughter cysts usually occur at a peripheral location within the mother cyst and are typically more hypodense than the mother cyst. Abdominal MRI may be useful in assessing pericyst, cyst matrix, and daughter cyst characteristics. MRI is the technique that best shows pericyst or “cyst hydatid sand” (free floating membranes) and daughter cysts. Fibrous and rigid pericysts appear as a hypodense ring on both T1- and T2-weighted images. The hydatid matrix is hyperdense in T2-weighted images and hypodense in T1-weighted images. Daughter cysts may be seen in both T1- and T2-weighted images.

The treatment and the follow-up procedures are based on the cyst and the symptoms of the patients. Below, you may find the clinical and radiological staging as well as WHO classification for hydatid cysts.

### **3.1 Clinical staging**

Stage 1: Asymptomatic.

Stage 2: Symptomatic (right upper quadrant pain).

Stage 3: Symptomatic + presence of liver dysfunction (e.g., AST, ALT elevation).

### **3.2 Gharbi classification in USG**

Type 1: Pure liquid collection.

Type 2: The decomposition of the germinative membrane and the pericyst.

Type 3: Multivesicular type.

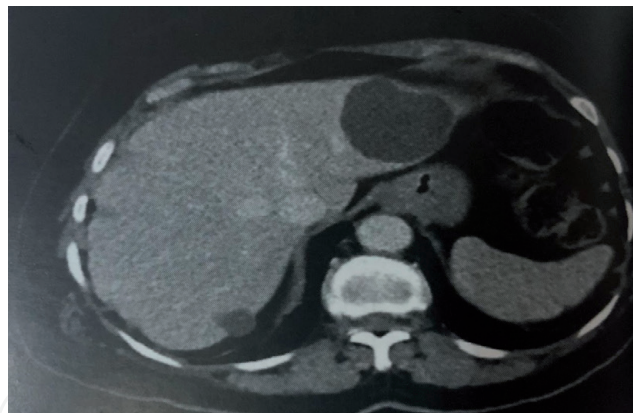
Type 4: Heterogeneous echo pattern.

Type 5: The calcified wall.

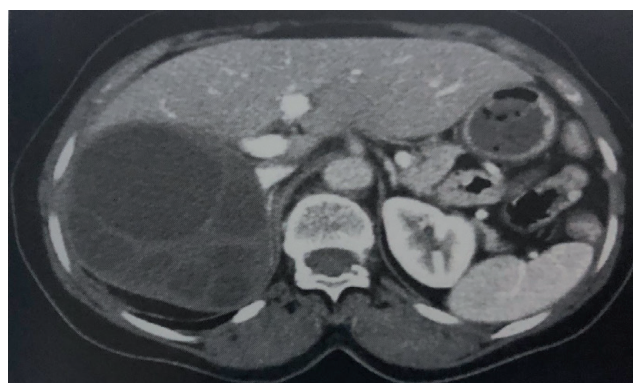
### **3.3 2001 WHO classification**

- CL
  - Unilocular anechoic cystic lesion [2]
  - No any internal echoes or septations

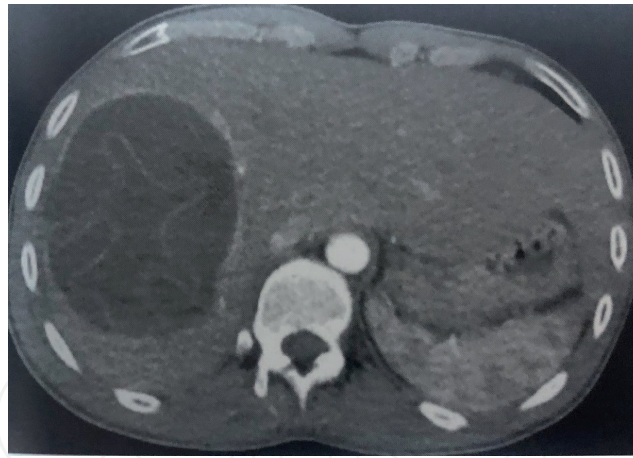
- **CE 1** (active stage)
  - Uniformly anechoic cyst with fine internal echoes, may only be visible after patient repositioning (**Figure 1**).
  - Internal echoes represent “hydatid sand” (fluid and protoscolices originating from a ruptured vesicle).
- **CE 2** (active stage)
  - Cyst with internal septation (**Figure 2**)
  - Septa represent walls of daughter cyst(s)
  - Described as multivesicular, rosette, or honeycomb appearance
- **CE 3** (transitional stage)
  - Evolving appearance of daughter cyst(s) within the encompassing parent cyst
  - **3A**—daughter cysts have detached laminated membranes (water lily sign) (**Figure 3**)
  - **3B**—daughter cysts within a solid matrix



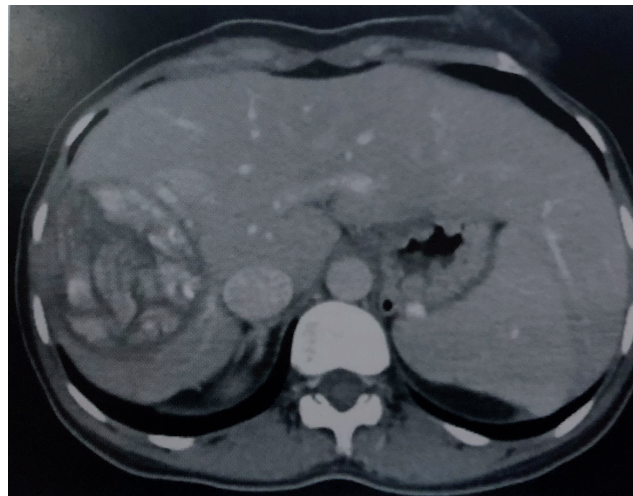
**Figure 1.**  
*CE1 hydatid cyst in both liver lobes shown in abdominal CT scan [3].*



**Figure 2.**  
*CE2 hydatid cyst in right liver lobe shown in abdominal CT scan [3].*



**Figure 3.**  
*CE3a hydatid cyst in right liver lobe shown in abdominal CT scan [3].*



**Figure 4.**  
*CE4 hydatid cyst in right liver lobe shown in abdominal CT scan [3].*

- **CE 4 (inactive/degenerative)**
  - Absence of daughter cysts (**Figure 4**)
  - Mixed hypoechoic and hyperechoic matrix, resembling a ball of wool (ball of wool sign)
- **CE 5 (inactive/degenerative)**
  - Arch-like, thick partially or completely calcified wall

#### **4. The medical treatment**

The goal of the treatment is mainly to stop the growth of the cyst and to eliminate the risk of infection or rupture. Unless the cysts are small, cyst hydatid disease is treated surgically because of high risk of secondary infection and rupture. Benzimidazole-derived antibiotics such as mebendazole and its new analogue albendazole are used. Medical treatment with albendazole relies on drug diffusion along the cyst membrane. The concentration of drug obtained in the cyst is

uncertain but is better than that of mebendazole, and albendazole can be used as an initial treatment for small, asymptomatic cysts.

The standard dose of mebendazole is 35–50 mg/kg/day, and the standard administration period is 6 months, whereas albendazole's standard dose is 10 mg/kg/day. Albendazole is more effective than mebendazole, because it has better absorption from the gastrointestinal tract, reaching much higher concentrations in both serum and cyst fluids. Therefore, the daily dose of albendazole is lower. However, it has toxic effects on the liver and bone marrow. For this reason, liver function tests and hemogram should be performed periodically in the patients under treatment.

Even if the management of the patient is decided as operation, the administration of albendazole for 1 month preoperatively reduces the number of viable vesicles within the cyst and reduces the risk of surgical scattering/recurrence.

## 5. Interventional treatment algorithm

In the majority of the patients, the medical treatment of the hydatid cyst is applied first, both for the treatment of the disease and for reducing the rate of the complications even if the cure is going to be reached by the surgical procedures.

The effectivity of the medical treatment can be assessed in two ways. By radiological assessment, USG can be performed, and if the cyst diameter does not increase and/or calcification is developed, the medical treatment is successful. By the serological assessment, the IHA test is repeated after 6 months of treatment.

Regardless of the stage, special attention should be paid to the content of each cyst. Cysts, in which the content is biliary or purulent, deserve additional interventions (finding and suturing the biliary tract (s) opened to the cyst, making drainage more diligently, increasing the number of drains, etc.).

Even if the risk is first defined as 25% in literature [4], 5% of the cases with indication for surgery are associated with bile ducts. This risk is greater in multivesicular cysts. Biliary entrances may result from communication between the pericyst and the biliary tract or from rupture of the cyst into the biliary tract. Strong communication of the cysts and bile ducts can lead to secondary bacterial infection of the cyst, cholangitis, or biliary obstruction. Bacterial contamination occurs in 10–35% of cases, and almost all of the infected cysts are associated with bile ducts.

Occasionally, the cysts spontaneously tear into the peritoneal cavity and cause anaphylaxis, which starts with abdominal pain. Many intra-abdominal cysts may develop as a result of intraperitoneal leakage. Liver hydatid cysts can penetrate the diaphragm and cause empyema, pulmonary cysts, biliary bronchial fistulas, or pericardial collections.

Some hydatid cyst disintegrates into bile ducts and may simulate choledocholithiasis. If the calcified cyst is unclear, cholangiography may show significant irregularities in the caliber of biliary ducts and large displacement of intrahepatic branches secondary to the mass effect of a large hydatid cyst [5, 6]. Before the interventions, if the patient has signs of jaundice and/or cholangitis, preoperative MRCP and ERCP, if necessary, should be definitely evaluated for the presence of the cyst opening to the biliary tract or the presence of cysts in the biliary tract. This procedure is very important in determining the surgical strategy.

The general rule is that surgical treatment is indicated for cysts larger than 5 cm. However, there are controversial issues such as attempting medical treatment first or applying medical treatment if there already occurred calcification on the wall. The discussion remains under the knowledge of the physiology of the cyst.

## 6. Percutaneous techniques

Traditionally, surgery has been the recommended treatment for hepatic cysts since the 1996 World Health Organization Consortium [7], but the combination of percutaneous drainage with drug therapy is always an alternative. Although percutaneous aspiration is contraindicated due to the risk of anaphylaxis, this complication has been shown to be rare for many years [8, 9]. Initially, a catheter was inserted for percutaneous drainage, and a cystolytic agent was injected into the cyst cavity after cystography. No complications or recurrences were reported 6 months to 1 year after treatment.

If percutaneous drainage is planned for the patient, it is important to remember that hydatid cysts do not resolve by aspiration just like any cyst. Recurrence is almost inevitable when only aspiration is performed. Therefore, a percutaneous technique called PAIR (perforation, aspiration, injection, reaspiration) can be used concurrently with albendazole treatment, which is found to have several advantages over surgical resection. In this method, after ultrasound-guided percutaneous perforation and aspiration of the hydatid cyst, 20% sodium chloride solution or 95% ethanol is injected into the cavity and then reaspired [10]. This intervention can be done twice or more in the same session to reduce the cavity of the cyst.

According to the Gharbi classification, PAIR can be applied for stage 1 and 2 diseases, whereas care should be taken for stage 3 diseases not to remain any vesicles inside. For stages 4 and 5, it is not expected for the cyst to collapse and close itself, because of the calcification and the irregularity of the wall [11]. In such cases, if surgical intervention has been performed, at least one of the cavity-minimizing and secretion-reducing procedures such as omentoplasty, capitonnage, and intraflexion must be added to the procedure after the removal of the germinative and laminar membranes.

First, Khuroo et al. [12] compared percutaneous drainage of hepatic hydatid cysts with surgery and reported that percutaneous drainage with albendazole was an effective alternative to cystectomy. They found that percutaneous drainage showed similar efficacy in the regression and loss of cysts with the advantages of shorter hospital stay and low complication rate.

Zerem and Jusufovic treated 72 patients with univesicular and multivesicular hepatic hydatid cysts with percutaneous drainage by imaging with albendazole, and 81% of the cysts in the univesicular group and 63% of the multivesicular group were cured.

As a derived technique, Schipper et al. reported in 2002 that percutaneous evacuation of cyst content (PEVAC) is a safe and effective treatment for multivesicular echinococcal cysts with or without cystobiliary fistula, even though it is not used nowadays.

Hydatid cysts usually communicate with the biliary tree, which is a contraindication to the injection of sclerosing agents, as this may cause widespread injuries to the biliary epithelium [3].

## 7. Surgical procedures

The main purpose of surgical treatment in liver hydatid cyst is to eliminate the parasite, to prevent recurrence of the disease, and to minimize the complication and mortality by removing the germinative and laminar membranes. If the germinative membrane stays, asexual reproduction occurs, which is currently the actual recurrence reason of the cysts. Even if there are no vesicles left, sterile cysts may occur in the main location [13].



The main question here is: Is it necessary to remove the entire cyst, or is it sufficient to remove only the cyst? Two treatment modalities have therefore been proposed: radical and conservative surgery. The choice of surgical treatment depends on the number, localization, diameter, and complexity of the hydatid cysts, as well as the age and comorbidities of the patient, and the experience of the surgeon.

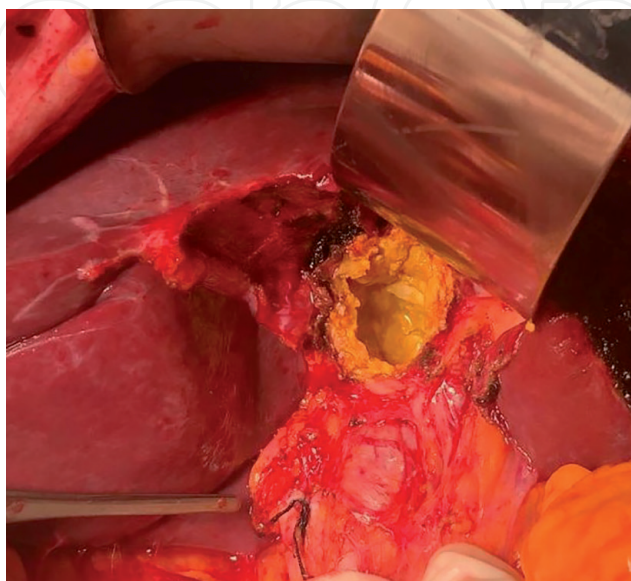
### 7.1 Surgical treatment indications

1. In large-scale uncomplicated CE2 and CE3b cysts with a large number of female vesicles [14].
2. In uncomplicated large cysts compressing adjacent vital organs.
3. In cases where percutaneous treatment is not possible.
  - a. In spite of the possibility of spontaneous or traumatic rupture in superficially located and large single cysts.
  - b. Infected cysts.
4. An alternative to percutaneous treatment in cysts with cystobiliary relationship.

### 7.2 Conservative surgical procedures

The basic principles of conservative surgical treatment are to clean all the contents inside the cyst and sterilize the cavity and to excise the pericyst as much as possible. Conservative surgical procedures are more simple and easier to perform than radical procedures. It is possible to perform these procedures in daily general surgical practice (**Figure 5**).

In conservative surgery, the basic principle is to open the cyst and sterilize the interior and then to manage the cavity. Various scolicedal agents are preferred for emptying the cyst content and for sterilizing the cavity interior. NaCl,



**Figure 5.**  
*An example of biliary duct connection of the cyst shown during the operation. A photo from our collection.*

chlorhexidine, povidone iodine, ethyl alcohol, and hydrogen peroxide are used as scolicidal agents. The administration time of these agents is 5–15 min. Hypertonic NaCl and cetrimide are the most commonly used agents [15]. Different concentrations have been reported for hypertonic NaCl. Both clinical and experimental studies suggest that the scolicidal efficacy of a concentration below 10% is not sufficient. The ideal concentration is 20%. Each scolicidal agent must be prevented from contact with the bile duct, because they all have the potential to cause caustic sclerosing cholangitis. After emptying of the cavity, bile control should be performed. Bile leakage can be seen directly with the eye, or some researchers recommend to wash the cystic duct or choledochus with isotonic NaCl for detection of the bile duct invasion. It is recommended that all detectable bile ducts be carefully closed without damaging the common bile ducts. In cysts with large bile duct openings, caution is needed when using scolicidal agents and closing the fistula openings.

The second main part of cavity management is how to reduce or close the cavity. The cyst wall outside the liver parenchyma should be excised as much as possible, which is defined as partial cystectomy. After the cyst cavity has been minimized, the methods for the remaining cavity are unroofing, marsupialization, tube drainage, Posadas surgery and modifications (Llobet-Varsi modification), Roux-En-Y cystojejunostomy, and omentoplasty [16]. In the marsupialization technique, the edges of the cyst are sutured to the abdominal wall, and the cyst contents are drained out, which is now a historical approach. The technique that has been adapted to current surgical approaches is tube drainage, in which the cyst cavity is drained out of the tube, but postoperative complications are high. Posadas surgery and its modifications are used in small peripheral cysts with no biliary involvement and closure of the cyst after opening and emptying.

The current techniques used in the treatment of liver hydatid cysts are changing from simply unroofing the cyst to hepatic resections; the important part is to define the techniques. The cystectomy is basically opening the dome of the cyst and removing the germinative membranes and vesicles, whereas in pericystectomy, radical surgery is done by resection of the cyst with some liver tissue surrounding. Unroofing stands for the excision of the part of the cyst located outside the liver. Apart from the germinative membrane, parts of the cyst within the liver parenchyma are not touched when unroofing is done. The placement of a visceral organ, usually the omentum, into the cavity after unroofing is done is defined as quilting technique, whereas marsupialization is a historical technique in which building a tract from the cyst to the skin like an ostomy is done.

Although the most common indications for transduodenal sphincteroplasty are related to bile duct stones and cholangitis, this technique can also be used in hydatid cyst residues and membranes extracted from the common bile duct. The procedure may extend to the left and right hepatic channels, and angled Randall forceps are useful for this purpose. Sphincteroplasty involves suturing both sides or edges of the surgical sphincterotomy to prevent future stenosis of the incision. The sutures provide hemostasis in the incision margins and lead to the risk of retroduodenal perforation but also help prevent leakage of the duodenal content if it extends beyond the common portion of the incision line and sphincter.

Recent studies have reported postoperative morbidity and mortality rates of conservative techniques as 3–24% and 0–4% [17]. Although conservative surgical treatments are safer than radical procedures, they have become controversial due to the complications occurring in the postoperative period and the length of hospitalization. The most common complications are biliary fistula and cavity infection. Apart from these complications, bile peritonitis, cholangitis, and rarely sepsis and anaphylaxis can be observed in the preoperative period. Although anaphylaxis is

extremely rare, it can be fatal. Hypernatremia is another complication that should be kept in mind in patients using hypertonic NaCl for cavity sterilization.

Although bile fistula is affected by various factors, it is observed in approximately 30–50% of cases. It is the most disturbing complication of conservative surgical treatment for the surgeon. The most predictive factor for postoperative bile fistula was found out to be the diameter of the cyst. Postoperative bile fistula rate increases in patients with a cyst diameter greater than 10 cm. Studies on the number, localization, and stage of the cysts on postoperative complications have yielded variable results, but localized cysts in the dome were definitely reported as a predictive factor. Postoperative bile fistula is defined as permanent bile fistula if it lasts more than 10 days. Endoscopic procedures are recommended primarily for the treatment of biliary fistulas. The cystobiliary fistula can be seen by ERCP, and endoscopic sphincterotomy, stenting, or nasobiliary drainage can be performed for therapeutic purposes.

An important problem during conservative surgery is the cavity infection. The rate of cavity infection in different series has been reported to be between 5.5 and 37%. Omentoplasty is thought to be useful in preventing cavity infection.

Mortality after conservative surgery can be seen up to 1.5%. Although higher mortality can be seen in patients with biliary involvement of the cyst, local recurrence rate is relatively higher in conservative methods than radical methods. Recurrences are reported to be caused by cysts growing from the pericyst to the liver parenchyma (exogenous vesiculation).

### 7.3 Radical surgical procedures

There are two radical procedures: pericystectomy and hepatectomy. In radical surgery, all the cysts can be performed with either excising the pericyst (pericystectomy—total cystectomy) or excising the parenchyma with the pericyst (hepatectomy) without opening the cyst. The rate of pericystectomy in radical surgery procedures is close to 90%. Unlike conservative procedures, radical procedures are more complex and difficult.

The pericystectomy is the preferred radical procedure because it is aimed to protect the healthy parenchyma as much as possible. There is a good dissection plan between liver tissue and cyst. Determining and progressing this plan will provide a comfortable dissection plan. When pericystectomy is performed laparoscopically, the operation is completed without emptying the cyst contents, and when the open method is performed, the pericyst is excised after the cyst is opened and the contents are emptied. Open method should be preferred especially in deeply located cysts adjacent to the hepatic artery or portal vein.

Indications for hepatectomy include the presence of large cysts that fill a lobe, multiple cysts, complicated cysts, and, according to some authors, being proximal to hilar vascular structures. This is an indication for hepatectomy if the large biliary tract is eroded. Particularly, lesions close to the inferior vena cava have been reported to be a partial contraindication. Caution is specifically needed for lesions adjacent to the right atrium and hepatic veins, especially the lesions in segments 1, 4, and 8. The radical resection is recommended for patients under age 75 only if the lesion is located with less than three segments of liver; if the residual liver function is sufficient to allow the surgery; if the vena cava, portal vein, hepatic artery, or biliary tract are suitable for repair; and if distant metastases are suitable for resection or do not cause life-threatening complications at least.

Complications vary according to the surgical method used in radical surgery. In general, complications related to liver surgery are observed and vary between 3 and 30% postoperatively. This rate is lower than conservative surgery. The advantage

of radical surgery is that there is no cavity infection and the risk of biliary fistula is less (0.7–7%). The rate of infection in the surgical site is less than 3% in patients who underwent radical surgery. The low postoperative morbidity reduces the length of hospital stay in patients who underwent radical surgery. In addition, the possibility of local recurrence is less in radical surgery. The rate of local recurrence in conservative methods has been reported to be 20–25% in the literature, while the recurrence rate after radical surgery is 0.6–4%.

#### **7.4 Surgical treatment of complicated cysts**

It should be done according to complication. Biliary tract problems should be solved primarily in cysts that are involved with bile ducts. For this, ERCP and endoscopic sphincterotomy can be performed. Conservative methods should be used rather than radical surgery in free ruptured cysts to the peritoneum.

#### **7.5 Minimal invasive surgery**

The role of laparoscopy in the surgical treatment of liver hydatid cysts has always been discussed. The first studies were reported in the 1990s. The general advantages of laparoscopy, such as less hospital stay, less wound problems, and less pain, apply here. However, it is difficult to reach cysts in some localizations, and there are difficulties in aspiration of cyst contents and concerns about spreading of content and question marks about laparoscopy.

Reaching the cysts in the posterior and superior segments of the liver poses some technical difficulties. However, access to cysts in segments II, III, IVB, V, and VI is more convenient [16]. This situation also provides patient selection in liver hydatid cyst. In other words, laparoscopic or minimally invasive surgical treatment seems more reasonable for patients with cysts in the anterior segments. It can even be interpreted that laparoscopy is a relative contraindication for cysts in segments I and VII.

In addition, the cyst content is completely evacuated, and the possibility of spreading around while being evacuated is another problem. After the cavity is emptied and sterilized, it is aimed to perform cavity management with the same methods as in open cases [14]. After the cyst has been evacuated, laparoscopy can be used to magnify the bile leakage and suture the sources of leakage.

In laparoscopic surgery, exposure is usually caused by inaccessibility of the cyst, calcifications, and other complications (bleeding, etc.). The conversion rate to open radical techniques was reported as 1.7% [16]. At present, there is no obstacle to the treatment of liver hydatid cysts with minimally invasive surgery. In the published series, the recurrence rate in patients undergoing minimally invasive surgery is not higher than in open-operated patients. However, the indications of laparoscopy should not be forced, and patients should be selected well. As minimal invasive hepatectomies become widespread, minimally invasive radical surgery for liver hydatid cyst will increase.

### **8. Postop follow-up**

Albendazole starting at 10 mg/kg/day should start to be used immediately for 6 months postoperatively. Hemogram and blood biochemistry should be performed every month (due to the risk of the toxicity of liver and bone marrow). Serological tests are not used in the early stages of follow-up (first few months), because none of them becomes negative in the early period. A control serological test (usually *Echinococcus* IHA) should be performed at the end of the 6-month postoperative period.

In this first 6 months postoperatively, USG is the main follow-up method. It shows both early recurrences and complications related to surgery. In the first few months, USG may show fluid accumulation in the cyst, which is usually seroma and will disappear afterwards. In recurrences, the fluid seen in the cavity in the previous USG will gradually increase.

Recurrence rates after surgery or invasive procedures range from 0 to 15%. The most common cause of recurrence is the scattering of living scolexes into the peritoneal cavity. Even if the patients is going to get operated, albendazole treatment is started 4–6 weeks preoperatively, which significantly reduces the risk of recurrence. The treatment of recurrent cysts is designed as in newly diagnosed cysts.

### 9. Alveolar cysts (*E. alveolaris* = *E. multilocularis*)

It forms 2–3% of liver cysts. In radiological imaging techniques, it is seen as the cyst wall makes papillary extensions into the liver parenchyma, which may resemble a hepatic tumor that leaks clinically and radiographically with irregular edges and heterogeneous density [18]. This formation is very important because if a part of the liver parenchyma is not resected in the surgery, there may remain a part of the germinative membrane which will cause recurrences (**Figure 6**).

There is also a PNM staging for alveolar echinococcal disease. P in the PNM shows the state of the parasite in the liver, N shows adjacent organ involvement, and M is for metastasis. Accordingly, PNM staging is as follows:

P: Shows the localization of the metacestode in the liver.

PX: Parasitic lesion cannot be evaluated.

P0: No parasitic lesion in the liver.

P1: Peripherally located and without biliary or proximal vascular involvement.

P2: Central lesion involving the biliary or proximal vascular structures in a single lobe.

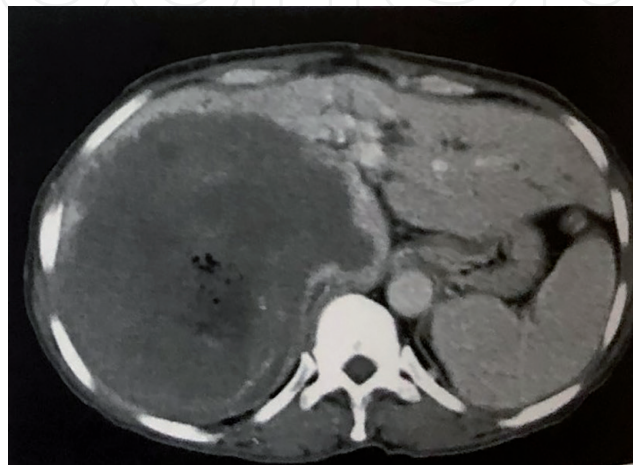
P3: Central lesion involving the biliary or proximal vascular structures of two lobes, or involving two hepatic veins, or both.

P4: Any lesion extending along the portal vein, inferior vena cava, or hepatic artery.

N: Shows extrahepatic involvement to neighboring organs.

Nx: Unable to evaluate.

N0: No regional involvement.



**Figure 6.** Alveolar Echinococcus lesion in right liver lobe shown in abdominal CT scan. Partial calcifications are seen around the lesion and left lobe is hypertrophied. Differential diagnosis with hemangioma is done with biopsy [3].

N1: Involvement of neighboring organs or tissues.

M: The situation of metastasis.

M0: No metastasis.

M1: Metastasis.

The only treatment of alveolar hydatid cyst is surgery. Interventional radiological methods are not recommended. The surgical treatment should be pericystectomy, in which intact liver tissue of at least 1 cm should be excised with cyst. Within all operated hydatid cyst cases in Turkey, the ratio of alveolar echinococcus is about 15-25%.

MR and MRCP, and ERCP if necessary, are used preoperatively in each case considered for surgical treatment. Since pericystectomy will be performed, it should be known whether there is an invasion to the bile ducts, portal vein, or inferior vena cava.

Albendazole is used in cases where surgical treatment cannot be applied and in the postoperative period as well (as in case of all hydatid cysts). However, their daily dose should be higher, and the duration of use has to be much longer (at least 1 year).

In conclusion, alveolar hydatid cyst is a more resistant type and requires more aggressive surgery and medical treatment.

## Conflict of interest

The authors declare no conflict of interest.

IntechOpen

## Author details

Mehmet Mihmanli\*, Mert Tanal, Emre Bozkurt and Onur Guven  
Department of General Surgery, Sisli Hamidiye Etfal Research and Training  
Hospital, Health Sciences University, Istanbul, Turkey

\*Address all correspondence to: [mmihmanli@yahoo.com](mailto:mmihmanli@yahoo.com)

## IntechOpen

© 2020 The Author(s). Licensee IntechOpen. This chapter is distributed under the terms of the Creative Commons Attribution License (<http://creativecommons.org/licenses/by/3.0>), which permits unrestricted use, distribution, and reproduction in any medium, provided the original work is properly cited. 

## References

- [1] Sahier M, Yalor MC, Greenberg HM. Canadian acquired hydatid disease: A case report. *Canadian Journal of Infectious Diseases*. 2001;**12**(3):178-182
- [2] World Health Organization. Surveillance and Response, 2001 Classification. Department of Communicable Disease. WHO; 2001
- [3] Belghiti et al. Sabiston's The Biological Basis of Modern Surgical Practice. 20th ed. Elsevier; 2016. pp. 42-48
- [4] De Diego CJ, Olaverri FJ, Franquet CT, Zubieta OS. Computed tomography in hepatic echinococcosis. *American Journal of Roentgenology*. 1982;**139**(4):699-702
- [5] Dryzka H, Sanghavi B, Peddamatham K. Hepatic hydatid disease: Findings on endoscopic retrograde cholangiography. *Gastrointestinal Endoscopy*. 1983;**29**(3):248-249
- [6] Ul-Bari S, Hussain A, Malik A, Dass TA. Role of albendazole in the management of hydatid cyst. *Saudi Journal of Gastroenterology*. 2011;**17**(5):343-347
- [7] World Health Organization. Tracking Universal Health Coverage. World Health Organization; 2015. ISBN: 978921564977
- [8] Akhan O, Ozmen MN, Dincer A, Sayek I, Gocmen A. Liver hydatid disease: Long-term results of percutaneous treatment. *Radiology*. 1996;**259**:259-264
- [9] Bret PM, Fond A, Bretagnolle M, Valette PJ, Thiesse P, Lambert R, et al. Percutaneous aspiration and drainage of hydatid cysts in the liver. *Radiology*. 1988;**168**(3):617-620
- [10] Pedrosa I, Saiz A, Arrazola J, Ferreiros J, Pedrosa CS. Hydatid disease: Radiologic and pathologic features and complications. *Radiographics*. 2000;**20**(3):795
- [11] Kelly K, Weber SM. Cystic disease of the liver and the bile ducts. *Journal of Gastrointestinal Surgery*. 2014;**18**:627-634
- [12] Khuroo MS, Wani NA, Javid G, Khan BA, Yattoo GN, Shah AH, et al. Percutaneous drainage compared with surgery for hepatic hydatid cysts. *New England Journal of Medicine*. 1997;**337**(13):881-887
- [13] Nunnari G, Pinzone MR, Gruttadauria S, et al. Hepatic echinococcosis: Clinical and therapeutic aspects. *World Journal of Gastroenterology*. 2012;**18**:1448-1458
- [14] Schwartz's Principles of Surgery. 10th ed. McGraw-Hill Education; 2015. pp. 1052-1056
- [15] Dziri C, Haouet K, Fingerhut A, et al. Management of cystic echinococcosis complications and dissemination: Where is the evidence? *World Journal of Surgery*. 2009;**33**:1266-1273
- [16] Bostanci O, Kartal K, Yazici P, Karabay O, Battal M, Mihmanli M. Laparoscopic versus open surgery for hydatid disease of the liver. A single center experience. *Annali Italiani di Chirurgia*. 2016;**87**:237-241
- [17] Tamarozzi F, Vuitton L, Brunetti E, et al. Non-surgical and non-chemical attempts to treat echinococcosis: Do they work? *Parasite*. 2014;**21**:75
- [18] Engler A, Rong S, Beer M, Schmidberger J, Greater T. Simple liver cysts and cystoid lesions in hepatic alveolar echinococcosis: A retrospective cohort study with Hounsfield analysis. *Parasite*. 2019:26-54