

We are IntechOpen, the world's leading publisher of Open Access books Built by scientists, for scientists

4,800

Open access books available

122,000

International authors and editors

135M

Downloads

Our authors are among the

154

Countries delivered to

TOP 1%

most cited scientists

12.2%

Contributors from top 500 universities



WEB OF SCIENCE™

Selection of our books indexed in the Book Citation Index
in Web of Science™ Core Collection (BKCI)

Interested in publishing with us?
Contact book.department@intechopen.com

Numbers displayed above are based on latest data collected.

For more information visit www.intechopen.com



Restoration of Cervical and Lumbar Lordosis: CBP® Methods Overview

Paul A. Oakley, Ibrahim M. Moustafa and Deed E. Harrison

Abstract

Low back and neck pain disorders are among the leading causes for work loss, suffering, and health care expenditures throughout the industrialized world. It has been extensively demonstrated that sagittal plane alignment of the cervical and lumbar spines impacts human health and well-being. Today there are reliable and predictable means through the application of extension spinal traction as part of comprehensive rehabilitation programs to restore the natural curvatures of the spine. High-quality evidence points to Chiropractic BioPhysics® (CBP®) methods offering superior long-term outcomes for treating patients with various craniocervical and lumbosacral disorders. CBP technique is a full spine and posture rehabilitation approach that incorporates mirror image® exercises, spinal and postural adjustments, and unique traction applications in the restoration of normal/ideal spinal alignment. Recent randomized controlled trials using CBP's unique extension traction methods in conjunction with various conventional physiotherapeutic methods have demonstrated those who restore normal lordosis (cervical or lumbar) get symptomatic relief that lasts up to 2 years after treatment. Comparative groups receiving various 'cookie-cutter' conventional treatments experience only temporary symptomatic relief that regresses as early as 3 months after treatment. The economic impact/benefit of CBPs newer sagittal spine rehabilitation treatments demand continued attention from clinicians and researchers alike.

Keywords: cervical lordosis, extension traction, lumbar lordosis, sagittal alignment, spinal subluxation, spine rehabilitation

1. Introduction

The Chiropractic BioPhysics® (CBP®) technique was invented in 1980 by Donald D. Harrison, a chiropractor who was also educated in engineering and mathematics [1]. After reading the 1974 paper by Panjabi [2] on the recommendation for the use of a Cartesian coordinate system to accurately describe the movement of body joints as rotations and translations around an origin, he applied this concept to upright human posture (**Figures 1 and 2**) [1, 3]. Instead of being applied to a single joint, Harrison presented the displacement of the head, thorax and pelvis as rotations and translations of the main masses of the body, with spinal coupling patterns that occur within the corresponding spinal junctions between the adjacent body masses for each particular movement/position.

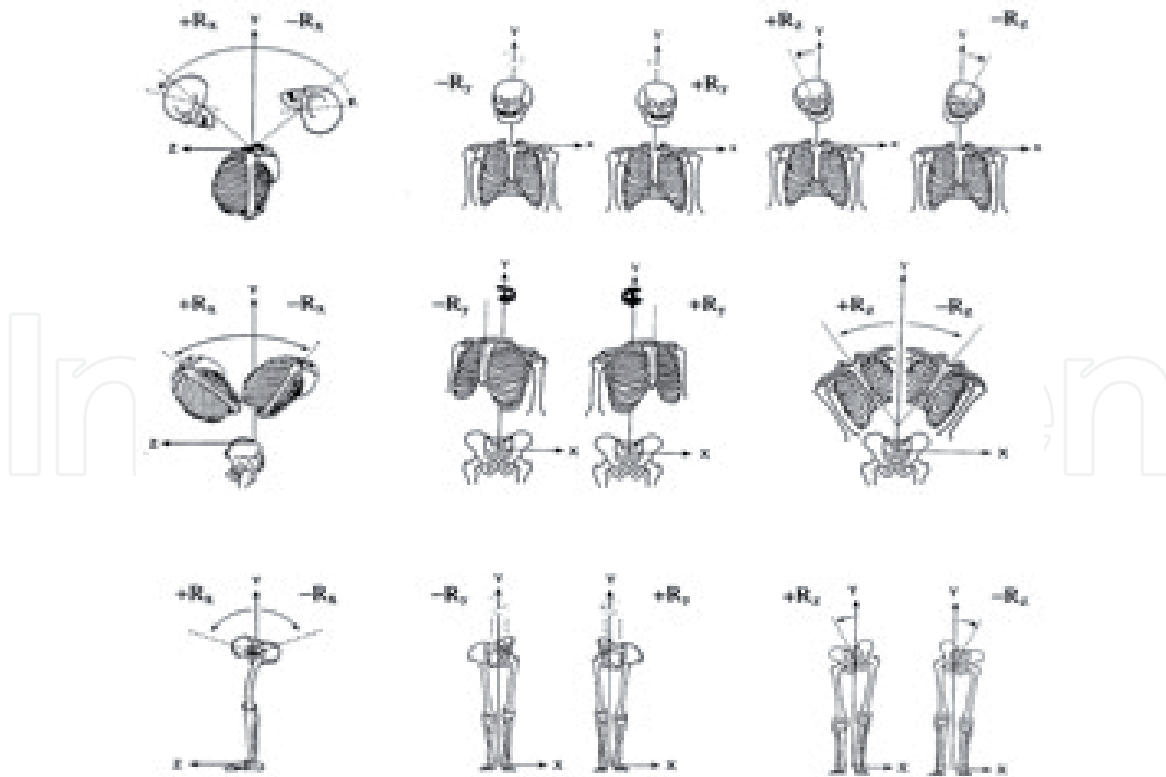


Figure 1.
Human posture described as rotations of the head, thorax, and pelvis about the x, y, and z-axes of the Cartesian coordinate system (Courtesy: CBP seminars).

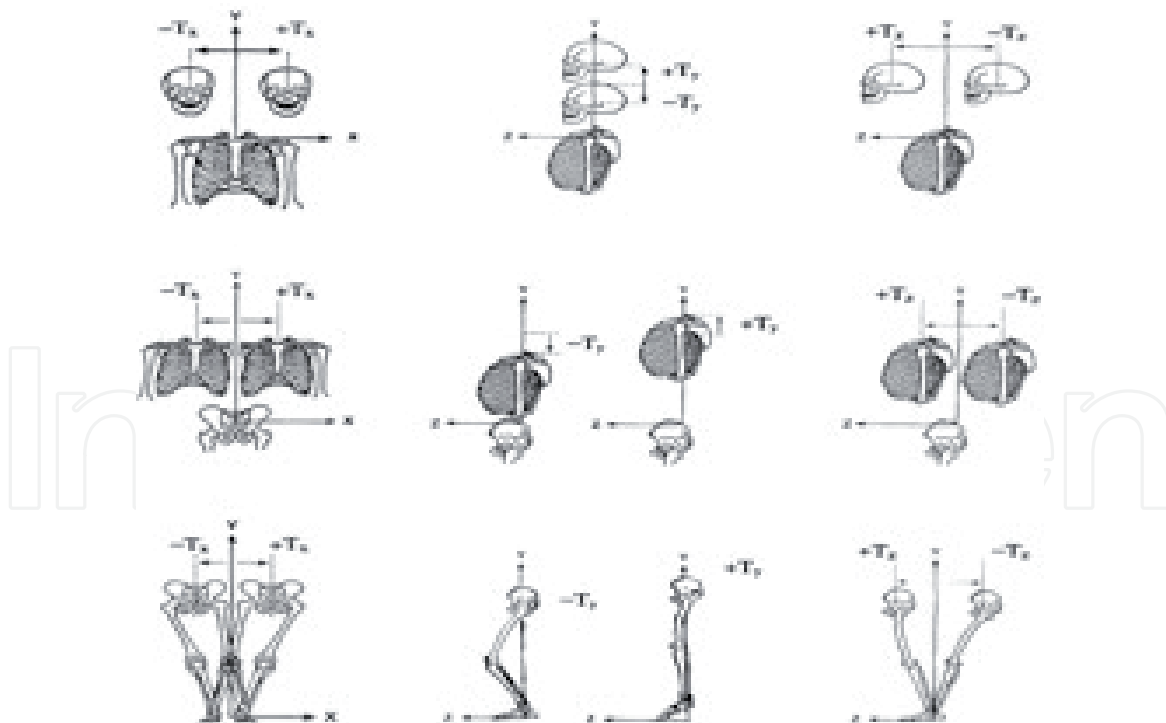


Figure 2.
Human posture described as translations of the head, thorax, and pelvis along the x, y, and z-axes of the Cartesian coordinate system (Courtesy: CBP seminars).

In an attempt to model the upright neutral sagittal spinal position, Don Harrison along with his son Deed Harrison and other colleagues performed a strategic set of studies. Although many research groups have attempted to model the shape of the normal human spine in the sagittal plane, few have done so as comprehensively and

systematically as the Harrison group [4–11]. Elliptical shape modeling of the path of the posterior longitudinal ligament along the posterior vertebral body margins was chosen due to the ease of clear identification of these spine landmark points and for the ability to easily make measurements of spine segmental and total angle of curvature on patient radiographs to compare patient measurements to model predictions. Modeling was performed on radiographic samples of asymptomatic participants. Computer iterations of spinal shape modeling was applied to determine best-fit geometric spine shapes by fitting various ellipses of altering minor-to-major axes ratios to digitized posterior vertebral body corners on samples of radiographs of the cervical [4–6], thoracic [7, 8], and lumbar spinal regions [9–11] (**Figure 3**).

The Harrison normal spinal model (**Figure 3**) features a circular cervical lordosis, and portions of an elliptical curve for both the thoracic kyphosis (more curvature cephalad), and lumbar lordosis (more curvature caudad). Consequently, features of the normal human spine reveal that the opposite thoracic and lumbar curves meet together at the thoraco-lumbar junction being essentially straight; the upper, deeper curve of the upper thoracic spine reflects oppositely at the cervico-thoracic junction (between T1 and T2) and continues into the cervical lordosis; the lower lumbar spine increases its lordotic alignment having two-thirds of its curve between L4-S1 as it meets the forward tilted sacral base. The spine is modeled as vertical in the front view. The spine alignment is easily quantified by repeatable and reliable methods from measuring its position from standing X-rays [12–16] (**Figure 3**).

The Harrison normal spinal model has been validated in several ways. Simple analysis of alignment data on samples of the normal, asymptomatic population has been done [4–11]. Comparison studies between normal samples to symptomatic samples [4, 17]; as well as between normal samples to theoretical ideal models have been done [4, 5, 8, 10]. The statistical differentiation of asymptomatic subjects from symptomatic pain group patients based on alignment data has been performed

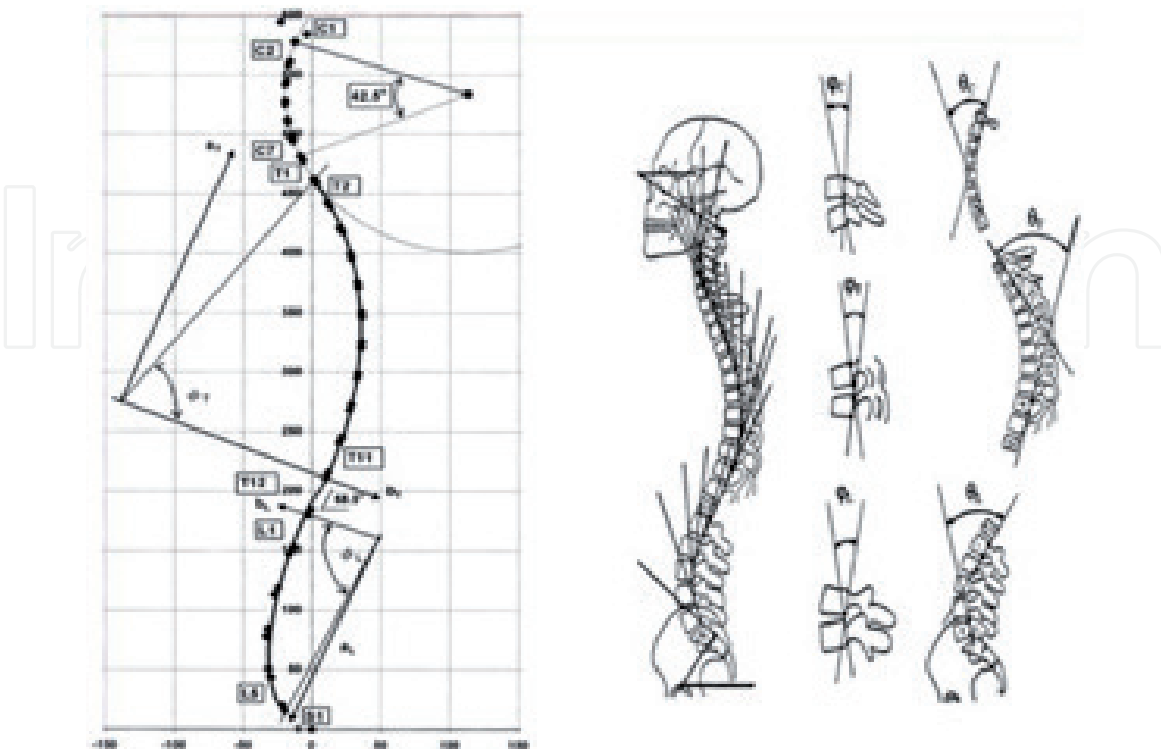


Figure 3.
Left: The Harrison normal spine model as the path of the posterior longitudinal ligament in the sagittal plane. Right: Harrison posterior tangent method are lines drawn contiguous with the posterior vertebral body margins used to quantify subluxation patterns (Courtesy: CBP seminars).

[6, 11]. The demonstration of paralleled spine alignment improvements with reductions in pain and disability, versus no change in untreated control groups in pre-post clinical trials have been performed [18–23]. The demonstration in randomized clinical trials that only patient groups achieving lordosis and sagittal posture improvement (lumbar or cervical) achieve long-term improvements in various outcome measures versus comparative treatment groups not getting spine alignment improvement who experience regression in multiple outcome measures at follow-up have also been done [24–35].

CBP technique is a full-spine posture and spine rehabilitation method that incorporates mirror image® (MI) exercises, adjustments, and traction applications in the restoration of normal/ideal spine alignment [1, 36–38]. Chiropractors and other manual therapists practicing CBP structural rehabilitation techniques have used this spine model as a structural goal of care for over 20 years. It is noted that this model serves as the baseline for generalized patient comparison, however, specific patient comparisons must include patient-specific considerations related to thoracic inlet parameters [39] as well as pelvic morphology [40] as these may dictate a structural modification to the sagittal plane model for a given patient [37]. There are software programs (i.e., PostureRay Inc., Trinity, FL, USA) that aid in the ability for practitioners to assess spine alignment quickly in daily practice (**Figure 4**).

Today the evidence supporting the CBP approach to the correction of cervical lordosis and lumbar lordosis is substantial. There are now many randomized controlled clinical trials (RCT) documenting the reduction of anterior head translation

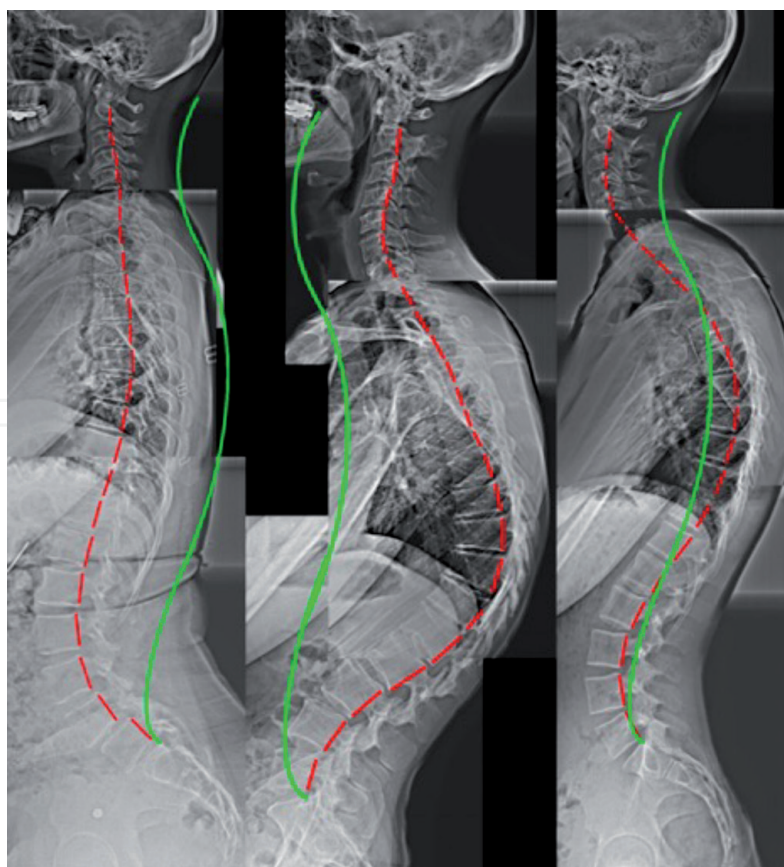


Figure 4. Three patients demonstrating dramatically different spine alignment patterns. Left: Excessive lumbar hyperlordosis, L4 anterolisthesis, and excessive anterior sagittal balance in a mid-aged female with disabling low back pain; Middle: Excessive thoracolumbar kyphosis and early degenerative changes in a mid-aged male; Right: Excessive thoracic hyperkyphosis in a young male with Scheuermann's disease. Red line is contiguous with posterior vertebral body margins; green line represents Harrison normal spinal model. (Courtesy: PAO).

[24, 28–35], as well as the increase in cervical lordosis [24, 28–35], and the increase in lumbar lordosis [25–27] in patients presenting with hypolordosis in each of these spinal areas. These trials have also demonstrated that the postural and spinal improvements are associated with improvements in various patient outcomes, including: pain, disability, quality of life, range of motion as well as specific physiological measures such as improved neurological central conduction times—the ability of the brain to communicate with the body.

We will now address in different sections the CBP approach to the restoration of cervical lordosis and then the restoration of lumbar lordosis.

2. Restoration of cervical lordosis

The first clinical trial using CBP methods for the restoration of cervical lordosis was a non-randomized controlled trial (nRCT) published in 1994 [18]. This first trial substantiated two trends: (1) Sagittal cervical alignment could be changed routinely, in patient cohorts receiving extension traction; (2) Spine alignment does not improve following spinal manipulative therapy (SMT) as a comparative group receiving spinal manipulation had no improvement in lordosis. Two other nRCTs were published in 2002 [20] and 2003 [21] confirming the results in the first trial and demonstrated that follow-up of patients experiencing improvements in lordosis by extension traction showed these improvements were relatively stable (small or no loss) at 14 [21] or 15.5 [20] months follow-up. These two latter trials also documented pain reductions coinciding with the lordosis improvements [20, 21] versus no improvements in untreated control groups.

More recently, Moustafa et al. [24, 28–35] has performed multiple RCTs showing improvements in cervical lordosis with extension traction protocols as part of physiotherapeutic treatment programs. These trials have demonstrated superior long-term patient outcomes versus comparative patient groups who only receive the physiotherapy minus the extension traction. In fact, there is now good evidence substantiating CBP cervical extension traction protocols show long-term reduction of anterior head translation (**Figure 5**), long-term improvement in cervical lordosis (**Figure 6**), and long-term reduction in pain levels (**Figure 7**) versus treatments that are ‘cookie-cutter’ for the purpose of pain-relief.

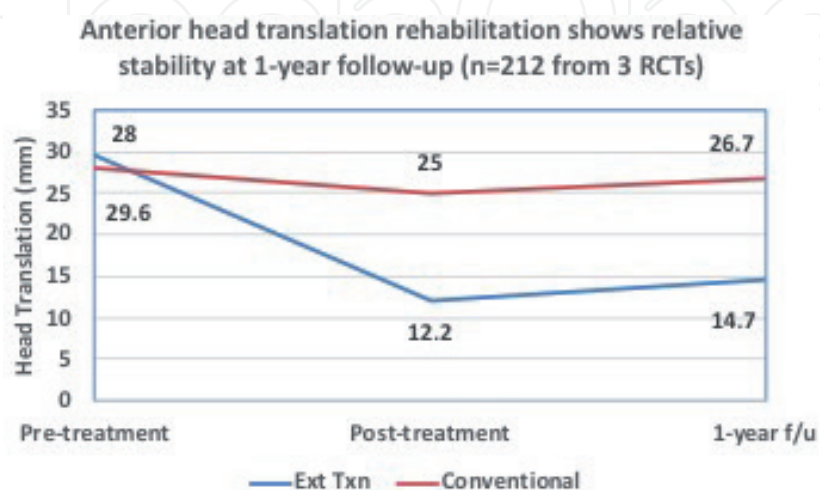


Figure 5.

Data from 3 RCTs demonstrates patients receiving cervical extension traction as well as conventional treatments have reduction of anterior head translation that is sustained for 1-year after stopping treatment versus the comparative groups (controls) remaining virtually unaffected by conventional treatments (Weighted averages from Moustafa et al. [28, 30, 31]).

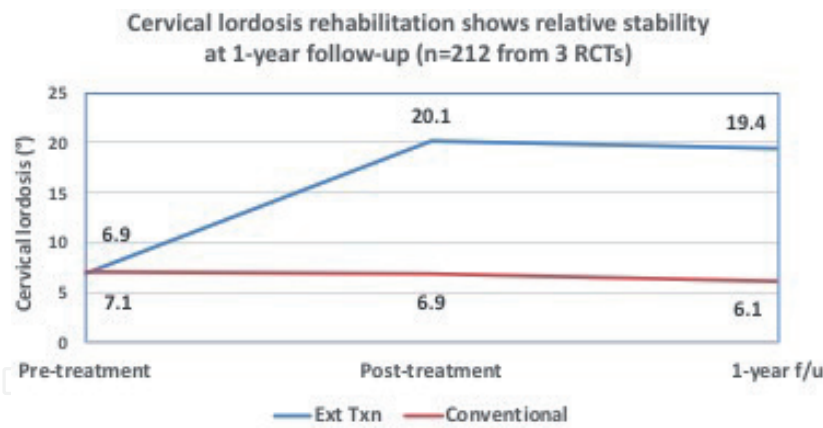


Figure 6. Data from 3 RCTs demonstrates patients receiving cervical extension traction as well as conventional treatments have lordosis improvements that are sustained for 1-year after stopping treatment versus the cervical curve of comparative groups (controls) remaining unaffected by conventional treatments (Weighted averages from Moustafa et al. [28, 30, 31]).

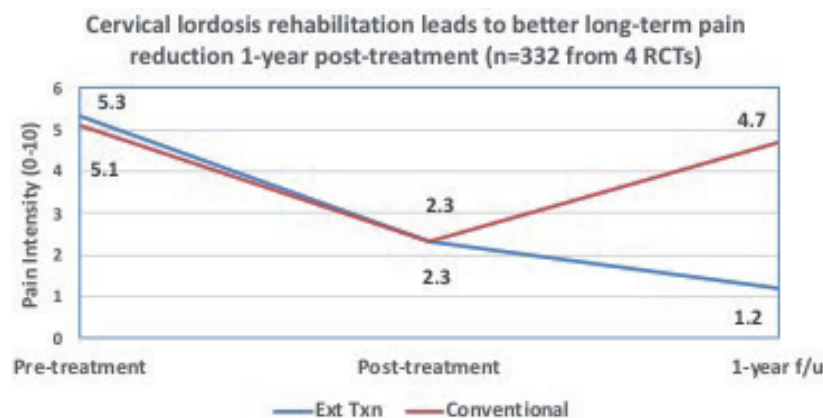


Figure 7. Data from four RCTs demonstrates patients receiving cervical extension traction as well as conventional treatments have pain reductions that are sustained for 1-year after stopping treatment versus comparative groups (controls) who show a regression (increasing) of pain intensity towards baseline after stopping treatment (Weighted averages from Moustafa et al. [28, 30, 31, 33]).

Table 1 summarizes the main outcomes from eight separate RCTs on CBPs extension traction as part of physiotherapeutic treatment programs versus comparative groups only receiving the physiotherapy and not the extension traction. Notably, and as demonstrated in **Figures 5–7**, pain-relief treatment programs (i.e., stretching/strengthening exercises, infrared irradiation, spinal manipulation, myofascial release, TENS, mobilization, hot packs – not including extension traction) do not improve the spinal parameters and only provide short-term pain relief that regresses after the cessation of treatment.

2.1 CBP protocol for restoring cervical lordosis

The classic CBP “E-A-T” protocol includes Exercises, spinal Adjustments, and Traction in a MI application. Corrective exercises for a cervical spine that is hypolordotic/kyphotic includes cervical extension exercises (**Figure 8**). A new patient may begin with head extension exercises in mid-air, and then progress to using a resistance band placed at the mid/low neck at the apex of their curve abnormality. Repetitions may vary but may begin at 25 and increase to 50 or 100. The patient may be instructed to hold each repetition for 3–5 s [36, 37]. After the patient sufficiently demonstrates proficiency, prescription for home exercises should be made.

Publication Details	Interv. & Treatment Details		No. of Studies	Cervical Curvature			Head Translation			Pain Intensity			Disability Scores			Other Outcomes Measures			
	Interv.	Control		Pre-treat	Post-treat	1yr	Pre-treat	Post-treat	1yr	Pre-treat	Post-treat	1yr	Pre-treat	Post-treat	1yr				
Shimada (RCT) 2011	FFPCU	Fibromyalgia	8	40.12°	34.03°	38	2.5cm	1.7cm	1.7	27.8mm/36.3mm	13.8mm	18.3mm	1.8/2.1	1.2	2.8	10.6/14.1	28.8	9.2	Improved OS position, pain, algometry, CDS, balance, depression, anxiety, stress, fibromyalgia
Mohtai (RCT) 2012	Cervical Mobilization	Lumbar Mobilization	8	40.1°	34.1°	38	2.5cm	1.7cm	1.7	28.2mm/22.0mm	2.5mm	2.0mm	n/s	n/s	84	10/21.7	27	13	Improved OS position, CDS, myofascial tenderness, HRQoL
Mohtai (RCT) 2012	EMM	Orthopedic Exercises	8	40.12°	34.14°	38	2.5cm	1.7cm	1.7	28.2mm/22.0mm	2.5mm	2.0mm	1.8/2.1	1.2	2.8	10.6/14.1	28.8	9.2	Improved electron capacity, frequency OLA, head monitoring accuracy
Mohtai (RCT) 2012	AMM	Manual Therapeutic Mobilization	8	40.12°	34.14°	38	2.5cm	1.7cm	1.7	28.2mm/22.0mm	2.5mm	2.0mm	1.8/2.1	1.2	2.8	10.6/14.1	28.8	9.2	Improved NDI, pain, post-CBP, cervical posture/extension-contracture time
Mohtai (RCT) 2012	EMM	Rehabilitation	8	41.1°	34.1°	38	2.5cm	1.7cm	1.7	n/s	n/s	n/s	n/s	n/s	n/s	n/s	n/s	n/s	Improved lordosis, pain, SBGP, Ruler extension-contraction
Mohtai (RCT) 2018	MAC MIA OLA	Cervical Mechanical Posture	8	40.12°	34.14°	38	2.5cm	1.7cm	1.7	28.2mm/22.0mm	2.5mm	2.0mm	1.8/2.1	1.2	2.8	10.6/14.1	28.8	9.2	Improved range of motion, post-pretreat posture, CINA-2 (0-100), NDI, pain
Mohtai (RCT) 2019	Cervical Mobilization	Cervical Exercises	8	40.12°	34.14°	38	2.5cm	1.7cm	1.7	28.2mm/22.0mm	2.5mm	2.0mm	1.8/2.1	1.2	2.8	10.6/14.1	28.8	9.2	Improved Mobilization (HR, HRV, HRVA, muscular frequency, Body definition) score
Mohtai (RCT) 2019	JMT	Therapeutic Posture Posture	8	40.12°	34.14°	38	2.5cm	1.7cm	1.7	28.2mm/22.0mm	2.5mm	2.0mm	1.8/2.1	1.2	2.8	10.6/14.1	28.8	9.2	Improved cervical semi-circular conductor time
	Weighted Average		8	40.12°	34.14°	38	2.5cm	1.7cm	1.7	28.2mm/22.0mm	2.5mm	2.0mm	1.8/2.1	1.2	2.8	10.6/14.1	28.8	9.2	

Table 1. Summary of eight RCTs documenting results in cervical lordosis improvements and reduction of anterior head translation corresponding with various pain, disability, quality of life and physiological parameter improvements.

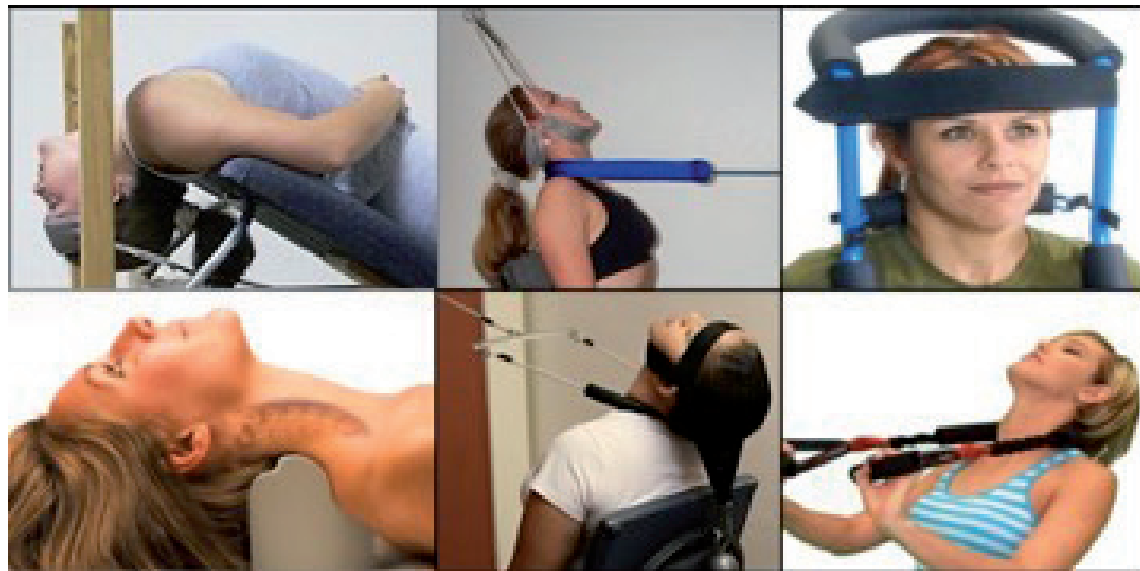


Figure 8. Cervical extension traction. Bottom right: Cervical extension exercises with resistance band (Courtesy: CBP seminars).

The rationale for corrective exercises is to strengthen the weak muscles, and stretch the shortened muscles as presumably the patient has had the spinal misalignment for some time, usually many years, and the soft tissues will have, over time, adapted to the poor posture [41]. It is generally accepted that exercises alone will not lead to any substantial improvement in lordosis or decreased head translation, but are still important in order to provide stability to the spinal area as the patient is being simultaneously treated with passive spinal traction as part of the CBP rehabilitation program.

Although many CBP practitioners provide spinal manipulative therapy, the MI approach to treat a patient having cervical hypolordosis/kyphosis includes cervical hyperextension drop-table adjustments. The rationale for the application of these force vectors are to reset the tone of the postural muscles [42]. More often patients presenting with cervical spine hypolordosis or kyphosis have accompanying anterior head translation. For this reason, it is commonplace for the manual therapist to place the patient in the prone position and elevate the head support to position the patient in the MI. At the same time the patient can extend their neck

backwards (i.e., look forward and place their chin on the head support) to further place the spine into a hyperextended position. The manual therapist would place their contact hand at the mid-neck and/or on the upper thoracic spine and provide a force downwards to engage the drop-piece on a “drop-table.”

Spinal traction is applied to increase the cervical lordosis and the spine must be placed in a hyperextended position (**Figure 8**). There are several extension traction variations; each is specific to the actual cervical alignment. For example, a cervical kyphosis with evident anterior head translation requires a posterior head translation and a “2-way” extension traction set-up [20], while a kyphosis without significant anterior head translation could be sufficiently reduced using a “Pope 2-way” extension traction without posterior head translation [21]. A patient having significant AHT having hypolordosis (but no kyphosis) should have sufficient reduction of AHT and increase in lordosis receiving extension-compression extension traction [18]. Initially, traction should be performed for 3–5 min and progress to 10–20 min per treatment session.

3. Restoration of lumbar lordosis

The first clinical trial using CBP methods for the restoration of lumbar lordosis was a non-randomized trial in 2002 [19]. In this trial, 48 patients with chronic low back pain (CLBP) were treated with SMT and extension traction to the lumbar spine for an average of 36 treatment sessions over an average of 12 weeks. There was an average of an 11.3° increase in lumbar lordosis from L1-L5 ARA (9.1° increase from T12-S1 Cobb). A control group of 30 CLBP patients had no pain reduction and no improvement in spine parameters. This trial demonstrated, for the lumbar spine with CLBP patients having hypolordosis, that routine increases in lumbar curvature is achievable; patients who get no treatment have no increase in lumbar curve and remain in pain. Harrison et al. concluded: “This new method of lumbar extension traction is the first nonsurgical rehabilitative procedure to show increases in lumbar lordosis in chronic LBP subjects with hypolordosis.”

Since the original trial outlining the CBP extension traction approach for lumbar hypolordosis, two more randomized controlled trials have documented that superior outcomes occur in mechanical LBP and sciatic patients receiving lumbar extension traction as part of comprehensive physiotherapeutic programs versus those who receive the physiotherapy without the extension traction (**Figures 9 and 10**) [25–27]. These results mirror the outcomes as found from the trials on the cervical spine by CBP extension traction methods [24, 28–35]. **Table 2** summarizes the two lumbar trials [25–27].

3.1 CBP protocol for restoring lumbar lordosis

Low back disorder patients who concurrently have lumbar hypolordosis require lumbar extension traction to increase their lumbar structural mal-alignment.

Figure 11 shows three different positions for the application of lumbar extension traction. Although there is not yet enough research to suggest one method over the other, the choice is up to the doctor/therapist. It is suggested that those having high intensity pain and/or those who are older and frail and/or those with balance and locomotor challenges perform lumbar traction in the supine position.

Similar to that discussed for the cervical spine, initial traction should be for 3–5 min and progress to 10–20 min per treatment session [19, 25–27]. Simultaneous physiotherapeutic treatments, including SMT, are in order to provide initial pain relief and improved mobility so that the patient is able to tolerate the traction [36–38].

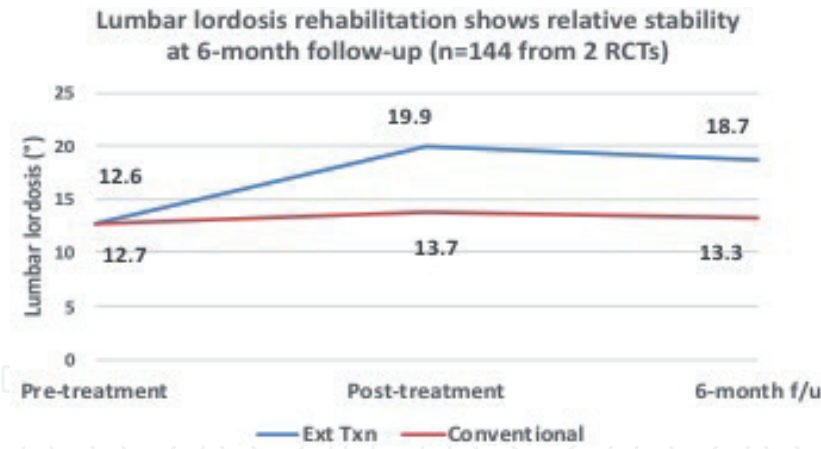


Figure 9. Data from two RCTs demonstrates patients receiving lumbar extension traction as well as conventional treatments have lordosis improvements that are sustained for 6-months after stopping treatment versus the lumbar curve of comparative groups (controls) remaining unaffected by conventional treatments (Weighted averages from Moustafa et al. [26, 27]).

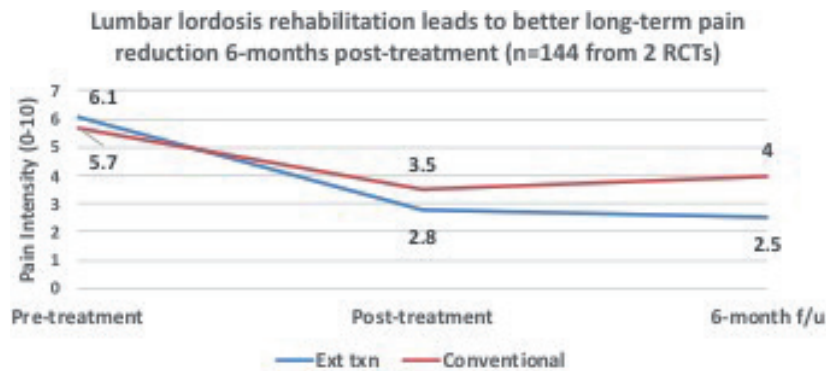


Figure 10. Data from two RCTs demonstrates patients receiving lumbar extension traction as well as conventional treatments have pain reductions that are sustained for 6-months after stopping treatment versus comparative groups (controls) who show a regression (increasing) of pain intensity towards baseline after stopping treatment (Weighted averages from Moustafa et al. [26, 27]).

Publication Details		Cohort & Treatment Details				Radiographic Measures				Pain Intensity			Disability Scores			Other Outcome Measures			
Author	Year	Journal	Primary Complaint	Eval Control	n	Age (SD)	Sex	Duration of rx	Pre-post lordosis	Lordosis Increase	% Increase	Pre-post LRP	Pain Decrease	% LRP	Pre-post ODI	ODI Increase	% ODI	Post-treatment & Long-term Treatment Exp. Improvements in Other Outcome Measures	% Time
Stah/Dob (RCT)	2012/2013	JMPT/JBMR	Chronic LBP	E	40 (195)	46.3 (12.8)	30	2.5m	13.9°/10.1°	6.2°	38.3%	6/3.1	3.8	2.8	31.4/21.8	9.6	23.8	Improved intervertebral movement, thoracic kyphosis, position of C7 plumbline	33%
Moustafa (RCT)	2015	Clin Rehabil	Lumbar/neck Radiolopapity	E	33 (135)	43.8 (1.7)	30	2.5m	11.7°/18.7°	8.7°	38.1%	6.3/1.8	3.8	2.4	31.8/28.8	3.0	23.1	Improved leg pain, Modified Schober test, # of falls, intervertebral movement	86%
Weighted Average		E			30	2.5m	12.6°/19.9°	7.3°	38.3%	5.4/1.9	3.5	2.5	31.4/26.9	11.5	23.5				
Weighted Average		C			30	2.5m	12.7°/13.3°	1.4°	13.2%	5.5/3.5	3.2	4	31.4/23.5	7.9	28.9				

Table 2. Summary of two RCTs documenting results in lumbar lordosis improvements corresponding with various pain, disability, quality of life and physiological parameter improvements.

4. Extension traction mechanisms

Spinal traction has been around for literally hundreds of years. The unique aspect of CBP’s traction for the purpose of increasing the physiologic lordosis whether for the cervical or lumbar spinal areas is performing traction in a hyper-extended position. The key to significant structural spine alignment changes lays in the viscoelastic creep properties of the intervertebral disk (and ligaments) and myofascial tissues under therapeutic conditions [43].

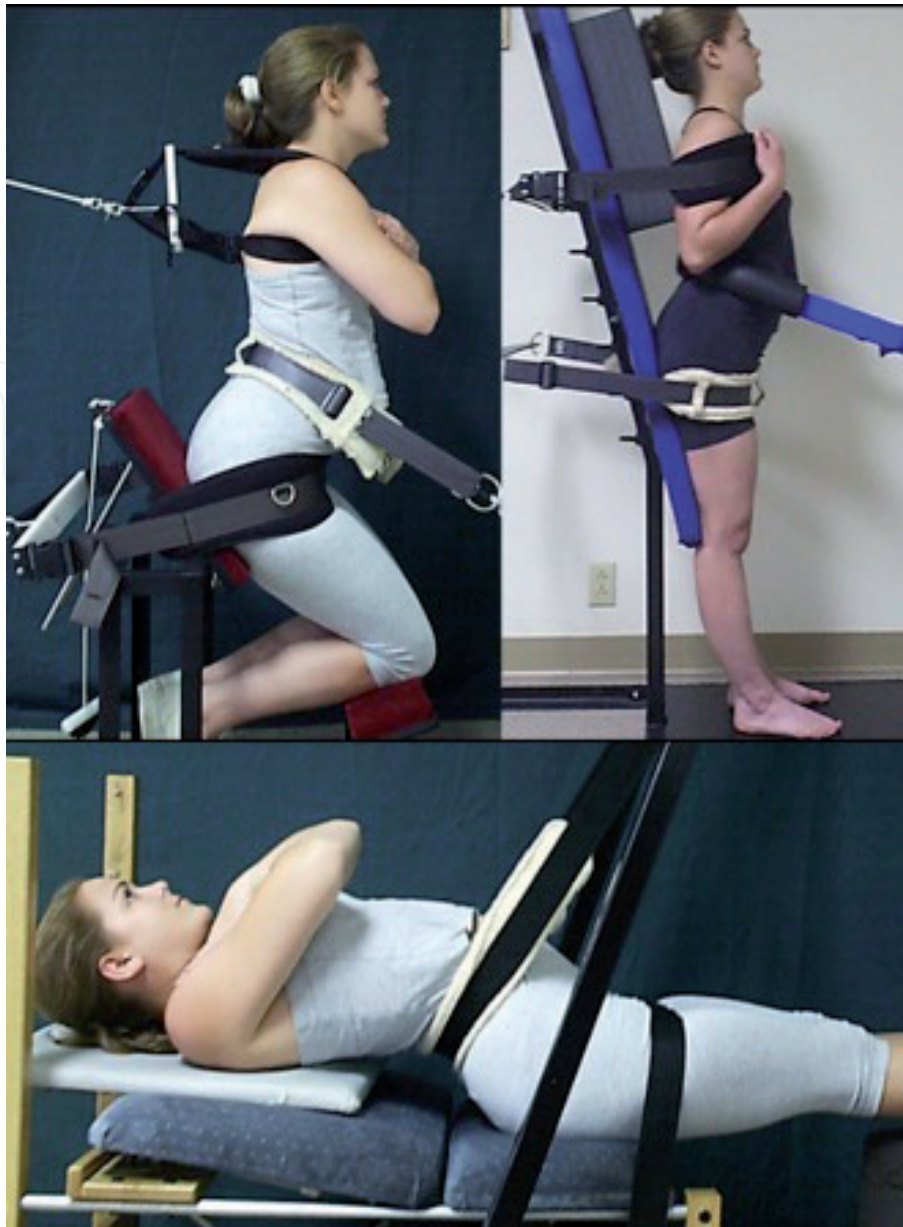

Figure 11. Lumbar extension traction as performed in the seated, standing and supine positions (Courtesy: CBP seminars).

Recently, Harrison and Oakley asked the question: *How does lumbar extension traction increase lordosis?* [44]. It was suggested that lumbar extension traction creates a sustained visco-elastic deformation in the soft tissues (muscles, ligaments, and discs) of the lumbar spine (or cervical spine). It is known that all soft tissues including tendons, ligaments, and discs display visco-elastic properties [45]. It is also known that when the soft tissues of the spine are subjected to a continuous load, the tissues will undergo three processes, “creep,” “stress relaxation” and “hysteresis.” Creep is the amount of deformation occurring in the tissues, stress relaxation is a reduction in the amount of the internal stress found in the tissues over time, and hysteresis is energy loss in the system from an exothermic reaction likely from the breaking of hydrogen-collagen bonds [45–49].

It is presumed that hyperextension traction targets the anterior portion of the discs, the anterior longitudinal ligament, and anterior column musculature specifically [36, 37]. Traction must be performed in a sustained and continuous manner for creep-relaxation and visco-elastic deformation to occur [45–49]. Thus, the biomechanical elongation of the anterior structures leads to a permanent

structural tissue resting length change and when performed in a frequent manner (i.e., daily or three times per week), a steady and consistent change to the spine alignment will occur as has been demonstrated by CBP for increasing the cervical lordosis by an average of 10–18° [18, 20, 21, 24, 28–35] and lumbar lordosis by an average of 7–11° [19, 25–27, 44] over the duration of 10–14 weeks. Note that the amount of change in the cervical and lumbar lordosis were measured radiographically on follow-up spine X-rays using standardized, reliable, and valid measurement methods [18, 20, 21, 24, 28–35].

5. Extension traction protocols

Although strict CBP technique methods incorporate exercises, spinal adjustments and spinal traction (E-A-T), these protocols have been discussed elsewhere [1, 36–38]. We will outline the critical protocol parameters that apply specifically to extension traction.

A patient must be screened for the presence of spinal hypolordosis in the cervical or lumbar spine by standard standing X-ray. External (non-imaging methods) body measurements are not valid for the assessment of the magnitude, segmental contributions, and geometric shape of a patient's lumbar or cervical lordosis. Furthermore, only direct spine imaging allows the visualization and quantification of a patient's pelvic and thoracic inlet morphologies which are known variables that influence the magnitude of sagittal curvature that should be present and can be achieved through rehabilitation [37, 39, 40]. In the majority of cases, all radiographs should be taken with the patient in a standardized position, standing freely without support, with arms fully flexed with the hands in the clavicle position [50, 51]. We recommend the feet to be positioned hip-widths apart without any shoes as well as the patient should have their eyes open and be staring straight ahead at eye level. Although full spine 36-inch lateral views may be used, it is recommended that a dedicated lateral cervical be taken to more accurately assess cervical subluxation as the 36-inch view projects the head more posteriorly and the cervical spine flatter [52, 53]. An obvious concern about routine X-rays is the exposure to radiation, we address this issue in the next section.

Although various measurement methods may be used, we recommend the Harrison posterior vertebral body tangent method as it is highly reliable (small standard error of measurement; i.e., <2° for regional measures of C2-7 and L1-5) [12–15]. Although C2-T1 absolute rotation angle (ARA) can be used, typically C2-C7 ARA is standard for measuring the cervical lordosis and L1-L5 ARA for the lumbar lordosis.

A patient may start traction for only 3–5 min initially. Increasing traction time may progress by 1–3 min on subsequent treatments pending their clinical tolerance and response. Total traction time should be between 10 to 20 min maximum. There is no significant benefit to performing traction longer than 20 min as the majority of visco-elastic creep deformation occurs in this time [48].

Typical treatment plans include seeing a patient three-times per week for 10–12 weeks prior to a repeat X-ray and analysis of structural improvement. As outlined in previous works [36–38], a patient may require several rounds of treatments to achieve a spinal alignment in the realm of normal/ideal; this is particularly true for patients having gross spinal deformities, high pain levels, and disability, as demonstrated in the treatment of non-iatrogenic flat back [44]. It is not untypical to treat a Patient three times per week, for 6–12 months in these cases.

6. Contraindications to extension traction

Generally, contraindications for extension traction protocols are the same as contraindications for SMT. Although traction protocols may be used in these cases, patients with a history of stroke, high blood pressure, bone spurring on the posterior aspect of the spine, spinal stenosis or other space occupying lesions represent potential high-risk, and therefore, extra caution should be taken to screen these patients for tolerance to this type of traction.

Patient screening for the ability to tolerate spinal extension traction should be performed for all patients. This typically includes assessing tolerance while laying supine on an extension traction device (e.g., Denneroll). The patient should be assessed for distress and/or an exacerbation of symptoms including the reporting of nausea, dizziness or increased pain. Those with rigid spine deformities and/or spinal osteoarthritis should have a stress view radiograph taken for flexion-extension as well as lying supine over an extension traction device.

The following represent absolute contraindications to the application of spinal extension traction [36, 37]:

- Pregnancy, especially in later stages nearing term;
- Infectious discitis and spinal tumors compromising vertebral stability;
- Abdominal aortic aneurysm;
- Severe osteoporosis and other bone diseases;
- Unstable vertebral fraction;
- Unstable segment under loading (verified by radiography) that cannot be reduced with extension traction loading;
- Multi-level spinal fusion;
- Recent spinal surgery;
- Abdominal hernias for lumbar traction;
- Other conditions that would be contraindicated for spinal manipulation;
- Patient having hyperlordosis of the cervical or lumbar spinal areas where extension traction is to be performed;
- Not having recent confirmatory standing X-rays of the spinal region to where the extension traction is to be applied.

The following represent relative contraindications to spinal extension traction that require diligent screening and clinical evaluation [36, 37]:

- Canal stenosis—although also proven useful for this [54];
- Spondylolisthesis—although also proven useful for this [55];
- Single-level fusions—to prevent hyperextension at the adjacent segment to the fusion;

- Hip replacement;
- Advanced osteoporosis;
- Locking (hyperextension) of the knees while in standing traction position—this may limit blood flow and induce syncope;
- Lack of food/nutrition and/or water several hours prior to treatment—may result in syncope;
- Extreme fatigue or illness or recently donating blood—may result in syncope;
- When pelvic morphology dictates a modification from ideal lumbar lordosis or thoracic inlet angle dictates a modification from ideal cervical lordosis such that the patient’s actual lordosis is more or less than expected [36, 37, 39, 40];
- Kissing spinous’s or Bastrup’s disease will inhibit segmental extension from occurring.

When applying extension traction protocols, it is important to realize the obvious notion that this applies only to those presenting with hypolordosis, straightening, or kyphosis of the cervical or Lumbar spinal areas, not to those with hyperlordosis. In such cases, different CBP traction protocols apply which are beyond the scope of this brief review [39, 56]. Also, in the performance of assessing patient tolerance to extension traction, the slow progression of increasing time and transitioning to a more challenging extension stretch is found in the skill and art of the hands of the practitioner. Fortunately, extension traction protocols have been proven safe as no reports of deleterious outcomes have been reported in the multiple RCT’s [24–35]. Further, this approach seems so safe that once thought of as contraindications, for example spondylolisthesis, have been shown to be able to be reduced by a special application of these methods [55]. Again, the experience and confidence of the practitioner will dictate whether this approach is selected for different candidate patients with their corresponding varying levels of difficult spinal conditions and case histories.

Concerns over radiation exposures during routine spinal X-ray imaging need discussion. Although this topic has been thoroughly discussed elsewhere [57–60], in brief, patient exposures from spinal X-rays are not harmful. First, the assumption that radiation exposures from low-doses are carcinogenic is false; low-doses of radiation (including X-rays and CT scans) stimulate the adaptive protection systems in the body to “over-repair” any genetic damage done, including DNA double strand breaks by imaging [61]. Second, because of point one, there is no cumulative effect; therefore, the only relative risk can be considered from a single session of X-rays (i.e., 1–3 mGy) [57, 58]. Third, due to point two, the amount of radiation from X-rays of 1–3 mGy is many times lower than the recognized dose threshold for leukemia of 1100 mGy (95% CI: 500–2600 mGy) [57, 62] and therefore cannot be carcinogenic.

7. Conclusions

Today there are reliable and predictable means through application of extension spinal traction as part of comprehensive rehabilitation programs to restore the natural curvatures of the spine. High-quality evidence points to CBP methods as

offering superior long-term outcomes for treating patients with sagittal plane spine and posture deformities who present with various craniocervical and lumbosacral disorders.

Conflict of interest

PAO is a paid consultant to CBP; DEH sells products related to the treatment of spine deformity as depicted herein.

Nomenclature

AHT	anterior head translation
ARA	absolute rotation angle
CBP	chiropractic BioPhysics®
CLBP	chronic low back pain
E-A-T	exercises, adjustments, traction (mirror image)
LBP	low back pain
MI	mirror image®
nRCT	non-randomized controlled trial
RCT	randomized controlled trial
SMT	spinal manipulative therapy

Author details

Paul A. Oakley^{1*}, Ibrahim M. Moustafa^{2,3} and Deed E. Harrison⁴

1 Private Practice, Newmarket, Ontario, Canada

2 Department of Physiotherapy, College of Health Sciences, University of Sharjah, Sharjah, UAE

3 Basic science department, Faculty of Physical Therapy, Cairo University, Naser City, Cairo, Egypt

4 CBP NonProfit, Inc., Eagle, Idaho, USA

*Address all correspondence to: docoakley.icc@gmail.com

IntechOpen

© 2019 The Author(s). Licensee IntechOpen. This chapter is distributed under the terms of the Creative Commons Attribution License (<http://creativecommons.org/licenses/by/3.0>), which permits unrestricted use, distribution, and reproduction in any medium, provided the original work is properly cited. 

References

- [1] Harrison DD, Janik TJ, Harrison GR, et al. Chiropractic Biophysics technique: A linear algebra approach to posture in chiropractic. *Journal of Manipulative and Physiological Therapeutics*. 1996;**19**:525-535
- [2] Panjabi MM, White AA 3rd, Brand RA Jr. A note on defining body parts configurations. *Journal of Biomechanics*. 1974;**7**(4):385-387
- [3] Harrison DD. Abnormal postural permutations calculated as rotations and translations from an ideal normal upright static posture. In: Sweere JJ, editor. *Chiropractic Family Practice*. Gaithersburg: Aspen Publishers; 1992. pp. 1-22. Chapter 6-1
- [4] Harrison DD, Janik TJ, Troyanovich SJ, Holland B. Comparisons of Lordotic cervical spine curvatures to a theoretical ideal model of the static sagittal cervical spine. *Spine*. 1996;**21**(6):667-675
- [5] Harrison DD, Janik TJ, Troyanovich SJ, Harrison DE, Colloca CJ. Evaluations of the assumptions used to derive an ideal normal cervical spine model. *Journal of Manipulative and Physiological Therapeutics*. 1997;**20**(4):246-256
- [6] Harrison DD, Harrison DE, Janik TJ, Cailliet R, Haas JW, Ferrantelli J, et al. Modeling of the sagittal cervical spine as a method to discriminate hypolordosis: Results of elliptical and circular modeling in 72 asymptomatic subjects, 52 acute neck pain subjects, and 70 chronic neck pain subjects. *Spine*. 2004;**29**:2485-2492
- [7] Harrison DE, Janik TJ, Harrison DD, Cailliet R, Harmon S. Can the thoracic kyphosis be modeled with a simple geometric shape? The results of circular and elliptical modeling in 80 asymptomatic subjects. *Journal of Spinal Disorders*. 2002;**15**(3):213-220
- [8] Harrison DE, Harrison DD, Janik TJ, Cailliet R, Haas JW. Do alterations in vertebral and disc dimensions affect an elliptical model of the thoracic kyphosis? *Spine*. 2003;**28**(5):463-469
- [9] Troyanovich SJ, Cailliet R, Janik TJ, Harrison DD, Harrison DE. Radiographic mensuration characteristics of the sagittal lumbar spine from a normal population with a method to synthesize prior studies of lordosis. *Journal of Spinal Disorders*. 1997;**10**(5):380-386
- [10] Janik TJ, Harrison DD, Cailliet R, Troyanovich SJ, Harrison DE. Can the sagittal lumbar curvature be closely approximated by an ellipse? *Journal of Orthopaedic Research*. 1998;**16**(6):766-770
- [11] Harrison DD, Cailliet R, Janik TJ, Troyanovich SJ, Harrison DE, Holland B. Elliptical modeling of the sagittal lumbar lordosis and segmental rotation angles as a method to discriminate between normal and low back pain subjects. *Journal of Spinal Disorders*. 1998;**11**(5):430-439
- [12] Harrison DE, Harrison DD, Cailliet R, Troyanovich SJ, Janik TJ, Holland B. Cobb method or Harrison posterior tangent method: Which to choose for lateral cervical radiographic analysis. *Spine*. 2000;**25**(16):2072-2078
- [13] Harrison DE, Cailliet R, Harrison DD, Janik TJ, Holland B. Centroid, Cobb or Harrison posterior tangents: Which to choose for analysis of thoracic kyphosis? *Spine*. 2001;**26**(11):E227-E234
- [14] Harrison DE, Cailliet R, Harrison DD, Janik TJ, Holland B. Radiographic analysis of lumbar lordosis: Cobb method, centroidal method, TRALL or Harrison posterior tangents? *Spine*. 2001;**26**(11):E235-E242

- [15] Harrison DE, Holland B, Harrison DD, Janik TJ. Further reliability analysis of the Harrison radiographic line drawing methods: Crossed ICCs for lateral posterior tangents and AP modified-riser Ferguson. *Journal of Manipulative and Physiological Therapeutics*. 2002;25:93-98
- [16] Harrison DE, Harrison DD, Colloca CJ, et al. Repeatability over time of posture, radiograph positioning, and radiograph line drawing: An analysis of six control groups. *Journal of Manipulative and Physiological Therapeutics*. 2003;26:87-98
- [17] McAviney J, Schulz D, Bock R, Harrison DE, Holland B. Determining the relationship between cervical lordosis and neck complaints. *Journal of Manipulative and Physiological Therapeutics*. 2005;28(3):187-193
- [18] Harrison DD, Jackson BL, Troyanovich S, Robertson G, de George D, Barker WF. The efficacy of cervical extension-compression traction combined with diversified manipulation and drop table adjustments in the rehabilitation of cervical lordosis: A pilot study. *Journal of Manipulative and Physiological Therapeutics*. 1994;17(7):454-464
- [19] Harrison DE, Harrison DD, Cailliet R, Janik TJ, Holland B. Changes in sagittal lumbar configuration with a new method of extension traction: Non-randomized clinical control trial. *Archives of Physical Medicine and Rehabilitation*. 2002;83(11):1585-1591
- [20] Harrison DE, Cailliet R, Harrison DD, Janik TJ, Holland B. New 3-point bending traction method of restoring cervical lordosis combined with cervical manipulation: Non-randomized clinical control trial. *Archives of Physical Medicine and Rehabilitation*. 2002;83(4):447-453
- [21] Harrison DE, Harrison DD, Betz J, Colloca CJ, Janik TJ, Holland B. Increasing the cervical lordosis with seated combined extension-compression and transverse load cervical traction with cervical manipulation: Non-randomized clinical control trial. *Journal of Manipulative and Physiological Therapeutics*. 2003;26(3):139-151
- [22] Harrison DE, Harrison DD, Haas JW, Betz JW, Janik TJ, Holland B. Conservative methods to correct lateral translations of the head: A non-randomized clinical control trial. *Journal of Rehabilitation Research and Development*. 2004;41(4):631-640
- [23] Harrison DE, Cailliet R, Betz JW, Harrison DD, Haas JW, Janik TJ, et al. Harrison mirror image methods for correcting trunk list: A non-randomized clinical control trial. *European Spine Journal*. 2005;14(2):155-162
- [24] Moustafa IM, Diab AM, Ahmed A, Harrison DE. The efficacy of cervical lordosis rehabilitation for nerve root function, pain, and segmental motion in cervical spondylotic radiculopathy. *Physical Therapy*. 2011;97(Suppl):846-847
- [25] Diab AA, Moustafa IM. Rehabilitation for pain and lumbar segmental motion in chronic mechanical low back pain: A randomized trial. *Journal of Manipulative and Physiological Therapeutics*. 2012;35(4):246-253
- [26] Moustafa IM, Diab AA. Extension traction treatment for patients with discogenic lumbosacral radiculopathy: A randomized controlled trial. *Clinical Rehabilitation*. 2012;27(1):51-62
- [27] Diab AA, Moustafa IM. The efficacy of lumbar extension traction for sagittal alignment in mechanical low back pain. A randomized trial. *Journal of Back and Musculoskeletal Rehabilitation*. 2013;26(2):213-222

- [28] Moustafa IM. Does improvement towards a normal cervical configuration aid in the management of fibromyalgia. A randomized controlled trial. *Bulletin of Faculty of Physical Therapy, Cairo University*. 2013;**18**(2):29-41
- [29] Moustafa IM, Diab AA, Harrison DE. Does improvement towards a normal cervical sagittal configuration aid in the management of lumbosacral radiculopathy: A randomized controlled trial. In: *Proceedings of the 13th World Federation of Chiropractic Biennial Congress/ECU Convention; Athens, Greece; May 13-16, 2015. Paper #184 Mediterranean Region Award Winning Paper*
- [30] Moustafa IM, Diab AA, Taha S, Harrison DE. Addition of a sagittal cervical posture corrective orthotic device to a multimodal rehabilitation program improves short- and long-term outcomes in patients with discogenic cervical radiculopathy. *Archives of Physical Medicine and Rehabilitation*. 2016;**97**:2034-2044
- [31] Moustafa IM, Diab AA, Harrison DE. The effect of normalizing the sagittal cervical configuration on dizziness, neck pain, and cervicocephalic kinesthetic sensibility: A 1-year randomized controlled study. *European Journal of Physical and Rehabilitation Medicine*. 2017;**53**:57-71
- [32] Moustafa IM, Diab AAM, Hegazy FA, Harrison DE. Does rehabilitation of cervical lordosis influence sagittal cervical spine flexion extension kinematics in cervical spondylotic radiculopathy subjects? *Journal of Back and Musculoskeletal Rehabilitation*. 2017;**30**:937-941
- [33] Moustafa IM, Diab AA, Hegazy F, Harrison DE. Does improvement towards a normal cervical sagittal configuration aid in the management of cervical myofascial pain syndrome: A 1- year randomized controlled trial. *BMC Musculoskeletal Disorders*. 2018;**19**:396
- [34] Moustafa IM, Diab AA, Harrison DE. The effect of normalizing the sagittal cervical configuration for the management of cervicogenic headaches: A 2-year pilot randomized controlled trial. In: *15th World Federation of Chiropractic Biennial Congress/78th European Chiropractor's Union Convention; March 20-23, 2019*. p. 142
- [35] Moustafa IM, Diab AAM, Taha S, Harrison DE. Demonstration of central conduction time and neuroplastic changes after cervical lordosis rehabilitation in asymptomatic subjects: A randomized, placebo-controlled trial. *Proceedings of the 14th biennial congress of the World Federation of Chiropractic, March 15-18, 2017*.
- [36] Harrison DE, Harrison DD, Haas JW. *Structural Rehabilitation of the Cervical Spine*. Evanston, WY: Harrison CBP® Seminars, Inc.; 2002
- [37] Harrison DE, Betz JW, Harrison DD, et al. *CBP Structural Rehabilitation of the Lumbar Spine*. Eagle, ID, USA: Harrison Chiropractic Biophysics Seminars. 2007
- [38] Oakley PA, Harrison DD, Harrison DE, Haas JW. Evidence-based protocol for structural rehabilitation of the spine and posture: Review of clinical biomechanics of posture (CBP®) publications. *Journal of the Canadian Chiropractic Association*. 2005;**49**:270-296
- [39] Lee SH, Kim KT, Seo EM, Suk KS, Kwack YH, Son ES. The influence of thoracic inlet alignment on the craniocervical sagittal balance in asymptomatic adults. *Journal of Spinal Disorders & Techniques*. 2011;**25**(2):E41-E47

- [40] Vrtovec T, Janssen MM, Likar B, Castelein RM, Viergever MA, Pernuš F. Evaluation of pelvic morphology in the sagittal plane. *The Spine Journal*. 2013;**13**(11):1500-1509
- [41] Khayatzaeh S, Kalmanson OA, Schuit D, Havey RM, Voronov LI, Ghanayem AJ, et al. Cervical muscle-tendon unit length differences between neutral and forward head postures: Biomechanical study using human cadaveric specimens. *Physical Therapy*. 2017;**97**(7):756-766
- [42] DeVocht JW, Pickar JG, Wilder DG. EMG activity levels of paraspinal muscles during spinal manipulation. In: *Proceedings from the 29th annual meeting of ISSLS 2002*; Vancouver, Canada; 2002
- [43] Owens SC, Brismée JM, Pennell PN, Dedrick GS, Sizer PS, James CR. Changes in spinal height following sustained lumbar flexion and extension postures: A clinical measure of intervertebral disc hydration using stadiometry. *Journal of Manipulative and Physiological Therapeutics*. 2009;**32**:358-363
- [44] Harrison DE, Oakley PA. Non-operative correction of flat back syndrome using lumbar extension traction: A CBP® case series of two. *Journal of Physical Therapy Science*. 2018;**30**:1131-1137
- [45] Panjabi MM, White AA. *Biomechanics in the Musculoskeletal System*. Philadelphia, PA, USA: Churchill Livingstone; 2001
- [46] Adams MA, Dolan P. Time-dependent changes in the lumbar spine's resistance to bending. *Clinical Biomechanics*. 1996;**11**:194-200
- [47] Hukins DW, Kirby MC, Sikoryn TA, et al. Comparison of structure, mechanical properties, and functions of lumbar spinal ligaments. *Spine*. 1990;**15**:787-795
- [48] Oliver MJ, Twomey LT. Extension creep in the lumbar spine. *Clinical Biomechanics*. 1995;**10**:363-368
- [49] Woo S, Livesay GA, Runco TJ, et al. Structure and function of tendons and ligaments. In: Mow VC, Hayes WC, editors. *Basics Orthopaedic Biomechanics*. 2nd ed. Philadelphia: Lippincott-Raven; 1997. pp. 209-252
- [50] Bess S, Protosaltis TS, Lafage V, Lafage R, Ames CP, Errico T, et al. International spine study group. Clinical and radiographic evaluation of adult spinal deformity. *Clinical Spine Surgery*. 2016;**29**:6-16
- [51] Horton WC, Brown CW, Bridwell KH, Glassman SD, Suk SI, Cha CW. Is there an optimal patient stance for obtaining a lateral 36" radiograph? A critical comparison of three techniques. *Spine*. 2005;**30**:427-433
- [52] Park SM, Song KS, Park SH, et al. Does whole-spine lateral radiograph with clavicle positioning reflect the correct cervical sagittal alignment? *European Spine Journal*. 2015;**24**:57-62
- [53] Carreon LY, Smith CL, Dimar JR 2nd, Glassman SD. Correlation of cervical sagittal alignment parameters on full-length spine radiographs compared with dedicated cervical radiographs. *Scoliosis and Spinal Disorders*. 2016;**11**:12
- [54] Weiner MT, Oakley PA, Dennis AK, Shapiro DA, Harrison DE. Increasing the cervical and lumbar lordosis is possible despite overt osteoarthritis and spinal stenosis using extension traction to relieve low back and leg pain in a 66-year-old surgical candidate: A CBP® case report. *Journal of Physical Therapy Science*. 2018;**30**:1364-1369
- [55] Fedorchuk C, Lightstone DF, McRae C, Kaczor D. Correction of grade 2 spondylolisthesis following

a non-surgical structural spinal rehabilitation protocol using lumbar traction: A case study and selective review of literature. *Journal of Radiology Case Reports*. 2017;**11**:13-26

[62] Cuttler JM. Evidence of dose threshold for radiation-induced leukemia: Absorbed dose and uncertainty. *Dose-Response*. 2019;**17**(1):1559325818820973

[56] Oakley PA, Ehsani NN, Harrison DE. Non-surgical reduction of lumbar hyperlordosis, forward sagittal balance and sacral tilt to relieve low back pain by Chiropractic BioPhysics® methods: A case report. *Journal of Physical Therapy Science*. 2019;**31**:860-864

[57] Oakley PA, Ehsani NN, Harrison DE. Repeat radiography in monitoring structural changes in the treatment of spinal disorders in chiropractic and manual medicine practice: Evidence and safety. *Dose-Response*. 2019;**17**(4):1559325819891043

[58] Oakley PA, Ehsani NN, Harrison DE. The scoliosis quandary: Are radiation exposures from repeated X-rays harmful? *Dose-Response*. 2019;**17**(2):1559325819852810

[59] Oakley PA, Cuttler JM, Harrison DE. X-ray imaging is essential for contemporary chiropractic and manual therapy spinal rehabilitation: Radiography increases benefits and reduces risks. *Dose-Response*. 2018;**16**(2):1559325818781437

[60] Oakley PA, Harrison DE. Radiophobia: 7 reasons why radiography used in spine and posture rehabilitation should not be feared or avoided. *Dose-Response*. 2018;**16**(2):1559325818781445

[61] Löbrich M, Rief N, Kühne M, et al. In vivo formation and repair of DNA double-strand breaks after computed tomography examinations. *Proceedings of the National Academy of Sciences of the United States of America*. 2005;**102**:8984-8989