

# We are IntechOpen, the world's leading publisher of Open Access books Built by scientists, for scientists

## 4,800

Open access books available

## 122,000

International authors and editors

## 135M

Downloads

Our authors are among the

## 154

Countries delivered to

## TOP 1%

most cited scientists

## 12.2%

Contributors from top 500 universities

**WEB OF SCIENCE™**Selection of our books indexed in the Book Citation Index  
in Web of Science™ Core Collection (BKCI)

Interested in publishing with us?  
Contact [book.department@intechopen.com](mailto:book.department@intechopen.com)

Numbers displayed above are based on latest data collected.

For more information visit [www.intechopen.com](http://www.intechopen.com)

# Role of Sentinel Node Biopsy in Endometrial Cancer

*Begoña Díaz de la Noval*

## Abstract

Lymphadenectomy, for early stages of endometrial cancer (EC), provides a low detection rate of lymphatic metastasis, without having demonstrated a therapeutic effect; so that the collection and histological analysis of the sentinel lymph node (SLN) might be an alternative to lymphadenectomy. The contribution of SLN to surgical staging represents a change in the paradigm of lymphadenectomy in EC, being an intermediate approach between not assessing the condition of the lymph nodes and complete pelvic and paraaortic dissection. Accurate identification of the main uterine drainage pathway increases the likelihood of detecting metastases during lymphatic mapping. In addition, pathological assessment by the ultrastaging of the SLN is the most important advance in the SLN biopsy (SLNB) technique. The application of the SLNB presumes a decrease in surgical and long-term morbidity, with an increase in the detection of lymphatic metastasis, mainly at the expense of detecting low tumour volume, selecting the group of patients that would benefit from a modification in adjuvant therapy. The SLNB can be established as an oncologically safe and effective method in the surgical staging of early-stage EC. Prospective studies are required to determine optimal behaviour and prognosis in the detection of low-volume metastases.

**Keywords:** endometrial cancer, lymphatic mapping, predictive value of tests, sentinel lymph node biopsy, ultrastaging

## 1. History and concept

The origins of lymphatic mapping date back more than 100 years, when Sappey injected mercury into the skin of cadavers to delineate the skin's lymphatic pathways [1, 2]. Lymphoscintigraphy was described by Shearman and Ter-Pogossian in 1953, both of whom confirmed Sappey's hypothesis that lymphatic drainage occurs in an orderly and predictable manner [2].

The origin of lymphatic drainage of tumours and its implications for surgical staging are traced back to 1850 with the studies of Virchow and Halsted on radical axillary lymphadenectomy for breast cancer.

The contribution of SLN to surgical staging represents a change in the paradigm of lymphadenectomy in EC. SLN represented an intermediate approach between not assessing the condition of the lymph nodes and complete pelvic and paraaortic dissection [3, 4]. The accurate identification of the main uterine drainage pathway increases the likelihood of detecting metastases during lymphatic mapping [5].

This information, provided by SLN, will change the therapeutic approach, with a potential benefit in the prognosis, both in survival and quality of life [6].

## 2. Detection method

Theoretically, the ideal method for studying SLN in EC should meet the following requirements:

1. Cause the least amount of patient discomfort possible, be easy to perform and be reproducible.
2. Be a preoperative procedure that enables planning of the surgical approach according to the anatomical location of the SLN.
3. Enable a laparoscopic approach according to the concept of minimally invasive surgery.
4. Enable the detection of SLN without complete dissection of the retroperitoneal space.
5. Obtain a lymphatic map representative of the tumour drainage or, at least, of the uterine body drainage [7].

### 2.1 Lymphatic drainage of the uterus

Unlike superficial tumours, such as melanoma, the physiology of lymphatic drainage in deeper/visceral tumours is not well established [8]. Uterine drainage, as well as being bilateral, is therefore complex [9]. Anatomically, three segments of uterine lymphatic drainage have been established:

1. The *lower uterine segment* drains from the paracervix to the parametrium and to the broad ligament, passing by the obturator, internal iliac and interiliac lymph node chains.
2. The *middle third* of the uterus drains the round ligament and the external iliac lymph node chain.
3. The *upper uterine segment* drains through the infundibular pelvic ligament, uterine-ovarian plexus and gonadal vessels towards the common iliac lymph node chain, presacral lymph nodes and paraaortic lymph nodes [10].

Physiologically, there are two main lymphatic pathways and a third accessory for uterine drainage [5]:

1. The main pathway or *upper paracervical*, located in the lymph trunks of the parametrium. The lymphatic vessels of the uterine body often cross the obliterated umbilical artery, which is the most common location of the pelvic SLN, rising over the upper part of the obturator region, medial to the external iliac vessels and ventral to the hypogastric vessels [5].
2. A less common pathway, the *lower paracervical*, is generally observed when the lymphatic vessels do not cross the obliterated umbilical artery and move

cranially over the course of the mesoureter. In these cases, SLN is usually observed in the internal iliac, common iliac or presacral region.

3. A third pathway has been described, the *infundibular pelvic*, but it is very rare except with fundal injections. This pathway has mainly fundal drainage towards the broad ligament and paraaortic chain [11].

## 2.2 Injection techniques

Three main areas of injection on the uterus have been described: (1) corporal, (2) endometrial and (3) cervical. Each area has been assessed with various approaches: hysteroscopic, laparoscopic and ultrasound-guided transvaginal and even with combined techniques.

1. **Corporal:** The injection can be subserosal or transmyometrial, in the anterior wall, posterior wall or uterine fundus. Corporal injection by laparotomy, using blue dye, was the first technique described. Subserosal injections have the drawback of multiple injections [12] and anatomical distortion when dealing with fibroids [13]. These injections might not be representative of the lesion if the tumour does not infiltrate the uterine fundus. Due to the lack of parametrial drainage, subserosal injections have a detection rate of 75–91% and bilaterality of 80%, which is lower than that of cervical injections ( $p = 0.005$ ) [11], although the former has superior paraaortic drainage (31–40%) [14].
2. **Endometrial:** Intratumoural and peritumoural infiltration have superior validity due to the proximity to the tumour lesion [10, 15]. The disadvantages of this injection pathway are lower rates of bilaterality and paraaortic drainage, which are determined by the location and size of the lesion [16]. Hysteroscopic injections achieve detection rates of 69–80% [17, 18], with greater paraaortic drainage (up to 60%) [15], without having shown superiority against other injection pathways [19]. The hysteroscopic injection procedure is a more complex and uncomfortable technique for the patient. Recent studies have concluded that hysteroscopic injections do not have a correlation between the location of the SLN and the location of the tumour in the uterine cavity [20]. The risk of tumour dissemination to the abdominal cavity has been shown to be irrelevant [21]. Clamping the tubes before or after the injection of the dye interferes with the detection rate by decreasing it [22].

In 2013, the group from the Hospital Clinic of Barcelona published their results with the transvaginal ultrasound-guided myometrial injection of radiotracer (TUMIR) technique, injecting 148 MBq of  $^{99m}\text{Tc}$ -albumin nanocolloid (in a volume of 8 mL) in the anterior and posterior peritumoural uterine wall, with migration of 90.5% and laparoscopic identification of 74.3%. The drainage was pelvic in 87.2%, pelvic and paraaortic in 45.4% and exclusively paraaortic in 12.8% of cases. Metastatic involvement of SLN in high-risk histology appeared in 24 patients, with paraaortic extension in 30% of cases. The authors concluded that the TUMIR technique is representative of tumour drainage and can be a promising detection method in high-risk histology, although further studies on the technique are needed [7]. The TUMIR technique has shown no differences compared with hysteroscopic injections ( $p = 0.2$ ) [7].

3. **Cervical:** The cervical injection is the modality most often reported in studies [23]. The technique is reproducible, because the uterine cervix is accessible and

rarely distorted in patients with EC [24]. The meta-analyses by Kang et al. [25] and Bodurtha-Smith et al. [26] showed that hysteroscopic or subserosal injections were associated with lower performance ( $p < 0.05$ ), while cervical administration was correlated with higher detection rates (92%; range, 62–100% [27];  $p = 0.031$ ) [4] and bilaterality (56 vs. 33%;  $p = 0.003$ ) (bilaterality is defined as the detection of sentinel node on both sides of the pelvis). The disadvantage was lower detection of paraaortic drainage (95% CI 3.4–10.1%) compared with other techniques (7% cervical vs. 27% corporal;  $p = 0.001$ ) [28–31].

In terms of the number of injections, there have been no differences between the injection in two or four quadrants (with detection rates of 92 vs. 88%;  $p = 0.38$ ), but there is less dye dissemination if the injection is limited to two quadrants [31]. Geppert et al. [11] performed pericervical injections at 2, 4, 8 and 10 o'clock thereby obtaining 5% paraaortic drainage. The MSKCC group recommended that cervical injections in EC be bilateral (at 3 and 9 o'clock), both superficial (in the submucosa) to 1–3 mm and deep (in the stroma) to 1–2 cm. In this way, the deep injection would therefore arrive at the isthmus, ensuring parametrial drainage. Applying this technique, a threefold greater detection of lymphatic metastases is achieved ( $p = 0.045$ ), without assuming an increase in the overall detection rates (86%) [32]. The systematic review by Cormier et al. [27] determined that paraaortic detection has been significantly greater with deep cervical infiltration (17 vs. 2%).

Taking into account the critical review of Frumovitz and Levenback [33] and knowing the uterine drainage pathways, the location of the tumour will determine the dissemination of the disease, and the injection technique might reflect the pattern of lymphatic mapping. However, the study by Geppert et al. [11] concluded that the cervical pathway (with submucosal and stromal injection) should be considered the standard pathway, not only due to being a safer injection technique but also because the two main pathways of lymphatic drainage of the uterus were identified regardless of the injection technique employed.

In terms of the lower cervical paraaortic drainage, numerous studies have verified that the incidence rate of paraaortic metastases isolated for EC in initial stages is 5%, with approximately 50% of metastatic pelvic and paraaortic lymph nodes [34]. Ninety percent of detected SLNs are located in the pelvic area; the rest are presacral or paraaortic. The other techniques likely obtain greater paraaortic drainage, at the expense of underestimating the main pathway of pelvic drainage [29, 30].

There is no known technique that detects with absolute bilaterality, and we still do not know why a central organ, such as the uterus, has cases in which bilateral drainage is not observed [20]. Ideally, the technique is considered valid if at least one SLN is identified in each hemipelvis [11].

There is no one ideal or superior technique; all have shown good results, with advantages and disadvantages [25]. Cervical injection is effective and reproduces pelvic drainage. Corporal injection better reproduces paraaortic drainage and the hysteroscopic pathway is representative of tumour drainage, although both are less reproducible than the cervical pathway [4]. A number of authors have advocated combined methods that provide better results. Studies such as the one by Holub et al. [35] have combined cervical and subserosal injections, achieving detection rates of 80%, without observing superiority over the two methods applied individually. In other studies with cervical and fundal injection, detection rates of 72.5% were achieved, comparable results without superior paraaortic drainage (4.9 vs. 9.8%;  $p = 0.18$ ) [6].

**Table 1** shows a comparison of the main characteristics of the abovementioned injection techniques.



## 2.3 Sentinel node identification

Various tracers have been shown to be useful. The most commonly used tracers in the lymphatic mapping of EC include  $^{99m}\text{Tc}$ -nanocolloid, blue dyes and indocyanine green (ICG), alone or in combination [36].

One inherent and necessary advantage of tracers is their high capacity for penetration and fixation in lymphatic tissues [30]. The objective of lymphatic mapping and preoperative marking with tracer is the ability to analyse at least one lymph node per lymph node chain, two in the case of bilaterality [37].

SLNB was initially performed by the colorimetric method with methylene blue (MB) or synthetic variants of blue dye. SLNB was later combined with the isotopic detection of radiocolloids, thanks to the development of endoscopic gamma-ray detection probes, becoming the standard for use. In recent years, the application of lymphatic mapping by fluorescence in the near-infrared (NIR) electromagnetic spectrum with ICG obviated the need for a nuclear medicine unit and avoiding the adverse effects of blue dye, providing excellent results.

### 2.3.1 Preoperative marking: radiocolloid

The approach to studying the lymphatic pathways using nuclear medicine techniques has gained considerable momentum in recent years with the development of SLNB.

A radiopharmaceutical is a radioactive compound used for the diagnosis and treatment of diseases. Radiopharmaceuticals's property of transmitting radioisotopes for remote detection is employed to diagnostic purposes [38].

Radiopharmaceuticals can be classified, according to their chemical structure, into primary radionuclides and labelled compounds, the latter of which are essentially a combination of two components: a radionuclide and a particle. The particles are small molecules, colloids, proteins and cells; the most widely used are colloidal sulphur (USA) and albumin (Europe). The particle serves as a vehicle that selectively directs the radiopharmaceutical to a specific tissue in response to physiological conditions or specific patterns of gene expression [38]. The size of the particles

Characteristic	Corporal	Endometrial	Cervical
Surgical approach for injection:	Subserosal or transmyometrial by laparoscopy or laparotomy	Hysteroscopy Transvaginal Ultrasound-guided	Transvaginal
Multiple injections	++	+	-
Influence on anatomical distortion or tumour size	++	+	-
Increase in economic cost	+/-	+	-
Technical complexity	+/-	+	-
Reproducibility	+	-	++
Detection rate/bilaterality	+	++	++
Paraortic drainage	+	++	-
Comfort for the patient	+/-	-	+/-

The score was assigned according to the following gradation: (-) = absence of the characteristic or negative evaluation, (+) = meets the characteristic or positive evaluation, (++) = complies being better; (+++) = it fulfils being superior.

**Table 1.**  
 Characteristics of injection techniques.

is important (range, 2–1500 nm) because it affects the drainage speed and retention of particles in the lymph node [34].

The most widely used diagnostic radiopharmaceutical in nuclear medicine is isomerised metastable  $^{99m}\text{Tc}$  [38], which is nontoxic and has almost ideal physical properties: a physical half-life to  $^{99}\text{Tc}$  (transition metal) of 6 h, a detectable emission and monochromatic gamma ray of 140 keV, complete disintegration within 24 h and low ionising radiation with negligible exposure [36, 39]. The greatest contribution of radiopharmaceuticals is the ability to use it as a marker of distinct pharmaceutical preparations, known as *cold kits*. The most used cold kit is the Nanocoll® 500 µg/vial (GE Healthcare Bio-Sciences, S.A.U., Madrid), a compound of colloidal particles of human serum albumin measuring  $\leq 80$  nm in diameter. The compound therefore has avidity for absorption through the lymphatic capillaries, and the size of its particles does not permit displacement of the lymph node.

To perform the SLNB, low doses of radioactivity are employed (40–185 MBq/0.2–4 mCi) because the distribution space is highly reduced. Only the drainage to the first or second lymph nodes needs to be assessed [38]. Furthermore, the injected dose of radiocolloid is calculated based on the estimated time to surgery; the longer the interval, the larger the dose to ensure an adequate signal. The  $^{99m}\text{Tc}$ -albumin nanocolloid is injected the day of the surgery (the radiocolloid injection is performed 6 h before the operation with preoperative imaging 30 min after the injection; the dose should be 0.2–1.0 mCi), a method known as the short protocol. If the nanocolloid is injected the day before the surgery (at a dose of 2.0–4.0 mCi), the method is known as the long protocol [40]. Therefore, the radioisotope compound deposited in the interstitial space near the tumour will migrate to the lymphatic capillaries until it reaches the first lymph node encountered by the capillaries. Due to the size of the compound, the capillaries will be trapped, indicating the first sentinel node into which the administered site drains. Moreover, both the short half-life and the low injected dose leave relatively little space for flexibility in surgical scheduling, given that hours-long delays and postponing the operation to the following day due to logistics will compromise the efficacy of the lymphatic mapping [36].

The compound is contraindicated when faced with hypersensitivity to the active ingredient or any of the excipients and during pregnancy. As the radiocolloid is primarily cleared by the kidneys but also by the hepatobiliary system, dose adjustment is required for patients with renal and/or hepatic failure [39]. There have been no reported adverse effects related to the radiopharmaceutical  $^{99m}\text{Tc}$ -nanocolloid, except the standard risks of the technical procedure: bleeding, vasovagal syncope and local infection [6].

### 2.3.1.1 Lymphoscintigraphy and single-photon emission computed tomography

The disadvantages of radiocolloid are the lack of visual assessment and the need for nuclear medicine procedures [30]. Lymphoscintigraphy and single-photon emission computed tomography (SPECT) can obtain preoperative images of the lymphatic drainage [38].

Lymphoscintigraphy obtains a flat static image with morphological information of the lymphatic drainage of the injected radiocolloid [8, 41]. Lymphoscintigraphy in EC offers varying results, depending on the injection method, with poorer detection rates than the overall rates and poor correlation between the preoperative findings and intraoperative detection [42, 43]. In the meta-analysis by Bodurtha-Smith and Tanner [26] of 55 articles and 4915 included patients, preoperative lymphoscintigraphy and the combined use of radiotracer with dye improved the overall SLN detection rates (86 vs. 76%;  $p = 0.016$  and 87 vs. 78%;  $p = 0.008$ ,

respectively); however, preoperative lymphoscintigraphy showed no benefit. An explanation for the low resolution and correlation could be the proximity of the injection site to the drainage, which can mask the SLN in flat images, and the anatomical complexity of the pelvic area, which can cause confusion in the correct anatomical description.

SPECT obtained a three-dimensional image with the fusion of the scintigraphic image with that of the traditional scanner. SPECT provides image information on the intensity of the scintigraphy and the precise anatomical location of the SLN(s) by scanner [44]. In the study by Naaman et al. [45], SPECT achieved a topographical accuracy of 91%, detecting a higher number of SLNs (1.4 vs. 2.13 SLNs/patient). Buda et al. achieved a detection rate of 50% and bilaterality of 39% for lymphoscintigraphy. For SPECT, the authors achieved a detection rate of 91%, bilaterality of 53% and sensitivity and a negative predictive value of 100% [46]. Compared with lymphoscintigraphy, the high sensitivity of SPECT seems to offer significant improvement in detecting SLNs and in the anatomical location [47, 82].

## 2.4 Surgical detection

The surgical SLN detection techniques can be applied to open surgery, laparoscopy and robot-assisted surgery [30], with overall detection rates of 60–100% [27]. Regarding the possibility of laparotomic detection, Mais et al. [48] used methylene blue (MB) as tracer and observed a significant difference between the laparoscopic pathway and laparotomy, with detection rates of 82 and 41%, respectively, although with the same false negative rate (FNR).

The mean number of SLNs detected per patient is 2.9 (95% CI  $2.5 \pm 3.3$ ; range 1–8) [26]. In terms of location, Abu-Rustum et al. [49] reported 89% of SLNs in the territory between the external iliac, obturator and internal iliac areas, with 4% of SLNs in the paraaortic area and 6% in the common iliac areas.

### 2.4.1 Radiocolloid

The gamma emissions of the radiocolloid can be tracked intraoperatively by a portable gamma probe adapted to open surgery or laparoscopy [42]. The use of laparoscopic gamma probe increases SLN identification guided anatomically by the previous images of SPECT and lymphoscintigraphy [50]. The gamma probe emits a signal proportional to the radioactivity uptake (analogue [counts per second] and auditory), enabling the accurate localisation of the radiocolloid in the lymph node station [38]. The activity will mark this lymph node regardless of whether it is normal or pathological [38].

The radiocolloid is often used along with dye to optimise the detection rate and visual assessment [30]. Studies with only radiotracer are therefore few, with a detection rate in the range of 70–96% [6]. In the Detection Rate and Diagnostic Accuracy of Sentinel-node Biopsy in Early Stage Endometrial Cancer (SENTI-ENDO) multicentre study, the long protocol with an injection of radiocolloid increased the detection rate of lymphoscintigraphy versus the short protocol (80.3 vs. 68.2%;  $p = 0.02$ ). The paraaortic detection was more frequent in the long protocol, with no intraoperative differences [40]. There was a weak correlation between preoperative and intraoperative detection ( $k = 0.3$ ) [40]. Other published data indicate good detection rates of 82% [6] and bilaterality with both protocols. While some authors use to perform another lymphoscintigraphy on the morning of the surgery [43, 51], with similarly poor improvement and weak correlation [22]. Other authors have proposed injecting the radiocolloid intraoperatively after the



induction of anaesthesia, omitting the preoperative imaging and identifying the SLN directly with the gamma probe 30 min after the injection [36].

The disadvantages of this procedure include the high financial and staff costs, the risk of radioactive exposure and patient discomfort during the preoperative preparation. The advantages include the longer duration of the marking and fixation in the lymph node [15]. The technical limitations are related to the massive and diffuse uptake by the tissue, the interference caused in the gamma probe (which hinders the proper differentiation of the lymphatic tissue, especially in the parametrium and obturator area) and the uptake by the reticuloendothelial system (liver, spleen and bone marrow) [6, 27].

#### 2.4.2 Dyes

##### 2.4.2.1 Blue dye

The dye enables the visual identification of the SLN marked or not with the radioisotope. Several dyes have been used: 1% isosulfan blue, 1% MB and 2.5% patent blue. Isosulfan blue is a blue-green hygroscopic powder that is prepared by diluting it in sterile water. MB was created in 1876 and is the first fully synthetic drug used in medicine. Patent blue is a dark blue synthetic dye used as food colouring, and its intensity fades quickly when exposed to sunlight [36].

The detection rates with only blue dye are lower (57–62%), with a bilaterality of 56.1% (50–60%) [17, 52]. MB has lower diffusion but acceptable detection rates (57.5%, range 45–92%) and bilaterality (42.4%, range 50–60%) [53]. Nevertheless, when SLNB is applied to other cancers, such as breast cancer, the various dyes have shown accuracy and equivalence in SLN marking [36]. MB is preferred due to the extensive experience with this dye and its better toxicity profile. Due to the lower detection and given that the combination with  $^{99m}\text{Tc}$  or ICG results in higher detection rates, MB is not recommended for use in isolation [21, 27].

After the blue dye is injected interstitially, it binds to the serum proteins and is filtered to the lymphatic vessels passing to the SLN, which will be stained in blue in approximately 5–10 min. This simple method requires no specific logistics, but the SLN must be identified at the start of the procedure before the dye vanishes or is displaced further along the lymphatic system and identifies a second nonsentinel step [36].

MB is more economical and safer than isosulfan blue. The half-life is 5–6 h, with mainly urinary and, to a lesser extent, biliary excretion. The recommendation is to use 2–4 ml of a 1% solution and to not take more than 10–20 min detecting the SLN due to the diffusion of the dye through the lymphatic tissue. A number of authors have estimated the mean procedure time, with an interval of  $13.4 \pm 6.2$  min between the injection and visualisation and a SLN excision time of  $17.4 \pm 11.2$  min [31].

Adverse effects related to the blue dye occur in 2% of cases [36]. The following effects have been reported: severe allergic reactions and anaphylactic crises (0.7–1.9%), thrombophlebitis at the injection site, tissue necrosis, haemolysis or paradoxical methemoglobinemia and serotonin syndrome in patients undergoing treatment with serotonin reuptake inhibitors [30, 54]. Patients and health professionals should be advised of transient colouring of the urine and the possibility of interference with pulse oximetry readings [36]. The use of the dye is contraindicated in cases of hypersensitivity (MD induced allergic reaction and methemoglobinemia), severe renal failure (dosage adjustments may be necessary as serum concentrations are increased in patients with impaired renal function) and glucose-6-phosphate-dehydrogenase deficiency (due to haemolytic anaemia when red blood cells are

exposed to the chemical). The dye is not recommended for use during pregnancy or breastfeeding because the dye's safety has not been established.

#### 2.4.2.2 Indocyanine green

Since the inclusion of fluorescence, the authors such as Holloway et al. [31] have replaced the radiocolloid and achieved equally good results. ICG is a tricarbocyanine dye with a short half-life of 3–4 min and hepatic excretion. ICG was developed by Kodak in the 1950s for use in photography and was approved by the US Food and Drug Administration in 1956 for IV administration [36]. The dye emits an intense blue colour detectable in real time when excited by laser in the near-infrared wavelength (range 750–900 nm, with an absorption peak at 800 nm) [6]. The high avidity by lymphatic tissue enables a high detection rate and accuracy compared with common tracers [4, 55, 56].

ICG has been used for years in laparoscopic and open surgery and in numerous other specialties (cardiology, general surgery, ophthalmology, vascular surgery, urology, etc.). The dye has recently been included in gynaecology. Lymph node mapping by fluorescence with ICG was first described by Furukawa et al. in 2010 in patients with cervical cancer. In 2012, Rossi et al. [57] applied ICG to 20 patients with cervical cancer or EC who underwent robot-assisted laparoscopic detection, achieving a detection rate of 85% and bilaterality of 60%.

The supposed benefits of this technology include high tissue penetration with low autofluorescence [58]. ICG has been shown to be superior to blue dyes, particularly in patients with obesity [30]. Following an interstitial injection, ICG is absorbed to the lymphatic system and travels quickly to the lymph nodes. ICG binds to plasma proteins and is excreted by the liver [36]. The dye lacks significant adverse effects. A single case of a severe allergic reaction after IV injection has been reported (incidence rate of 0.05%) [59]. However, the dye is contraindicated for use in patients with allergies to iodine [23, 55]. Nevertheless, given that iodine is a chemical element and an essential component of the human body, a number of authors have suggested the safety of using ICG in patients with iodine allergies, given that a type I allergic reaction (antibody-mediated and responsible for anaphylactic shock) will not occur [36]. The use of ICG in pregnant patients has been reported as safe [60].

To date, there has been no standard in the concentration and volume to be injected. Rossi et al. [57], Jewell et al. [61] and Holloway et al. [62] established the optimal ICG dose for detecting SLN at 1, 1.25 or 2.5 mg/mL in 4 mL [23]. Unlike  $^{99m}\text{Tc}$ , ICG does not remain confined to a lymph node but rather diffuses rapidly through the lymphatic tissue towards the second step lymph nodes without losing intensity. It is therefore crucial to quickly start the search for the SLNs after the administration of ICG, without delaying the start of detection by more than 10 min [23], thereby reducing the risk of sampling too many lymph nodes [36], which limits the technique beyond 25–30 min of the injection [63].

Erikson et al. [64] compared the isolated use of ICG and MB in 472 patients, obtaining a higher detection rate (95 vs. 81%;  $p < 0.001$ ) and bilaterality (85 vs. 54%;  $p < 0.001$ ) with ICG. In 2015, How et al. [65] compared ICG, MB and  $^{99m}\text{Tc}$ -nanocolloid, obtaining a higher detection rate (86 vs. 71%;  $p = 0.005$ ) and bilaterality (65 vs. 43%;  $p = 0.002$ ) with ICG than with MB and a similar rate (87 vs. 88%;  $p = 0.83$ ) and bilaterality (65 vs. 71%;  $p = 0.36$ ) to  $^{99m}\text{Tc}$ . In 2016, Papadia et al. [66] published the results of a retrospective, multicentre comparative study between detection with the combined technique using radiocolloid and blue dye versus radiocolloid and ICG. The overall detection rate was 97.3% for  $^{99m}\text{Tc}$ -blue and 96.9% for ICG ( $p = 0.547$ ). The bilaterality was 84.1% with ICG and 73.5% with

the blue dye; ICG was significantly superior ( $p = 0.007$ ). In a series by Martinelli et al. [19] of 202 cases using ICG plus  $^{99m}\text{Tc}$  as tracer, there were no differences in the detection rate (93.2%), and the bilateral detection was superior with ICG (72.8 vs. 53.3%;  $p = 0.0012$ ). All of the authors (and many not mentioned here) agree that ICG offers the highest detection rates comparable to those of the standard  $^{99m}\text{Tc}$ -blue technique but with superior bilaterality [11, 26].

ICG achieves greater diffusion; better visualisation; greater bilateral detection, which translates into a lower risk of lymphadenectomy (61% with MB vs. 39% with ICG;  $p < 0.001$  [64]); a shorter surgical time and long-term financial savings and can obviate the need for an injection of radiotracer [67]. It was initially stated that ICG represented an increase in the number of resected SLNs, a finding that became standard with experience in the technique [68]. Therefore, considering its good toxicity profile, its ease of use and high effectiveness, ICG is the current tracer of choice [69]. The main disadvantage of ICG is that the NIR detection equipment is expensive, because it requires specific optical systems [70].

Advances in the fluorescence technique are ongoing. New NIR detection systems, such as the PINPOINT® Endoscopic Fluorescence Imaging System, specifically identify the uptake intensity with colour codes, such that the primary lymph node is differentiated from the secondary nodes, preventing the excision of nonlymphatic or canalicular tissue [71].

#### 2.4.3 Combined method

The objective of the double injection method is to optimise the detection rate and bilaterality, given that single dyes (mainly blue dyes) have lower detection rates and bilaterality [27]. The recent systematic review by Cormier et al. [27] achieved superior results with a combination of two tracers. Various combinations have been applied.

##### 2.4.3.1 Radiocolloid and blue dye

Results vary significantly; however, the conclusion is that a better detection rate (81 vs. 57%;  $p = 0.01$ ) and bilaterality (54 vs. 28%;  $p = 0.009$ ) are achieved with the combination than with the isolated application of each tracer [45]. The multicentre prospective study by the AGO group with 590 patients obtained a better detection rate applying the combined method of radiocolloid and patent blue dye (88.6 vs. 93.5%;  $p < 0.001$ ). Other authors have achieved similarly improved surgical detection results by applying this double method, which has become established as the most appropriate combination of tracers. The review by Ruscito et al. [69] compared the detection by the combined technique (of  $^{99m}\text{Tc}$  and MB) with ICG and achieved superior bilaterality with ICG and a tendency to a higher overall detection rate, without differences compared with the combined method.

##### 2.4.3.2 Radiocolloid and ICG

How et al. [65] compared ICG and isosulfan blue with radiocolloid in a cervical injection in 100 patients with EC. The detection rate (87 vs. 88%;  $p = 0.83$ ) and bilaterality (71 vs. 65%;  $p = 0.36$ ) achieved with ICG and the radiocolloid were comparable to the data obtained with only an injection of ICG. In the meta-analysis by Lin et al. [72], the combined technique with  $^{99m}\text{Tc}$  and ICG achieved a detection rate of 92% and bilaterality of 86%, results comparable to those using only ICG (91% and 78%, respectively).

### 2.4.3.3 Blue dye and ICG

The prospective cohort study by Holloway et al. [31] combining blue dye with ICG achieved a significant increase in the detection rate (87.8% with blue-ICG vs. 76% for blue alone), bilaterality (83.9% with blue-ICG vs. 40% for blue alone;  $p < 0.001$ ) and detection of lymphatic metastases (21.1% with blue-ICG vs. 13.5% for blue alone;  $p = 0.056$ ) versus the isolated injection of blue dye. In the study by Jewell et al. [61], lymphatic mapping with ICG detected the SLN in 95% of cases, with bilaterality of 79% and no statistically significant differences versus the combined use with isosulfan blue (detection rate of 93%,  $p = 0.64$ ; bilaterality of 77%,  $p = 0.8$ ). Other authors have reached the same conclusion as Jewell: the high effectiveness in the identification with fluorescence is not increased by blue dye. The combination therefore appears unnecessary, which would avoid an increased risk of adverse effects [53].

### 2.4.4 Triple tracer

There are few published studies on this subject. How et al. [65] concluded that the triple injection (blue dye,  $^{99m}\text{Tc}$  and ICG) in the cervix (submucosa and stroma) provided a detailed mapping of the lymphatic canals, from the parametrium and presacral areas to the hypogastric vessels.

### 2.4.5 Paramagnetic tracer

New tracers are being applied. Recently, the Central-European SentiMAG multicentre clinical trial compared the use of the standard tracer ( $^{99m}\text{Tc}$ -nanocolloid and MB) with superparamagnetic iron oxide (SPIO) labelled nanoparticles, marketed under the name Sienna<sup>+</sup>®. The preliminary results indicated comparable detection rates of 97.3 versus 98% with the same number of SLNs

Characteristics	$^{99m}\text{Tc}$	Blue	ICG
Economic cost	+	-	+
Technical complexity	+	-	-
Detection rate/ bilaterality	++	+	+++
Comfort for the patient	-	+	+
Need for specific equipment	++ (Radiopharmaceutical/ lymphogammagraphy/SPECT-CT)	-	+
Adverse Reactions	- (1-6/100.000)	++ (2%)	- (<0.05%)
Lymphotropism	++	+	+++
Duration marking	24 h/+++	10- 20 min/+	20-30 min/++

The score was assigned according to the following gradation: (-) = absence of the characteristic or negative evaluation, (+) = meets the characteristic or positive evaluation, (++) = complies being better; (+++) = it fulfils being superior.  $^{99m}\text{Tc}$  =  $^{99m}\text{Tc}$ -nanocolloid albumin; ICG = indocyanine green; NIR = near-infrared electromagnetic spectrum. Reference source: Papadia et al. [36].

**Table 2.**  
 Characteristics of tracers.



per patient and a tendency for the SPIO tracer to identify more metastatic SLNs, although further research is needed [34].

**Table 2** shows a comparison of the main characteristics of the most widely used tracers.

### 3. Histological analysis

One of the main advantages that the SLN technique offers pathologists is the ability to select and minimise the number of lymph nodes to study, which enables a more exhaustive analysis and search for microscopic metastatic involvement.

#### 3.1 Intraoperative value

Classically, the most widely used method for analysing SLNs has been the intraoperative assessment with haematoxylin-eosin (H&E) of imprint cytology performed in fresh samples and in frozen sections with rapid Diff-Quik staining. Intraoperative examination is questionable due to its limitations, both in the processing and in the results. Its success depends greatly on the collaboration between the surgeon and pathologist [73]. An intraoperative assessment can only examine a small portion of the SLN, has low sensitivity (56–67%) for the intraoperative detection of metastases and has an FNR of 20–30%, which makes the procedure inadequate and unsafe for the patient [74]. The results of Kim et al. [75] indicate an intraoperative understaging of 24%. For Ballester et al. [76], the rate was 43.7%, with little assessment of low-volume metastases. Additionally, the frozen sections distort the lymph node tissue, thereby precluding lymph node ultrastaging [30] and precluding the detection of micrometastatic involvement in the case of initially negative lymph nodes [74]. Currently, the guidelines of the National Comprehensive Cancer Network (NCCN) do not recommend the routine intraoperative assessment of SLNs, except when there is high suspicion and a nonsentinel lymph node [5]. However, other authors have emphasised the importance of intraoperative study to avoid reoperations, especially in high-risk tumours [77].

#### 3.2 Ultrastaging

Conventional histological examination of a nonsentinel lymph node involves a single section along the lymph node's major longitudinal axis and H&E staining, with deeper levels or application of immunohistochemistry (IHC) at the pathologist's discretion [30].

Occasionally, the only evidence of extrauterine disease is the presence of metastases in the SLN. Considering the poorer prognosis associated with the detection of lymphatic metastases, a much more exhaustive analysis is justified [73, 78]. Therefore, pathological assessment by the ultrastaging of the SLN is the most important advance in the SLNB technique [79].

##### 3.2.1 Histological ultrastaging and immunohistochemistry

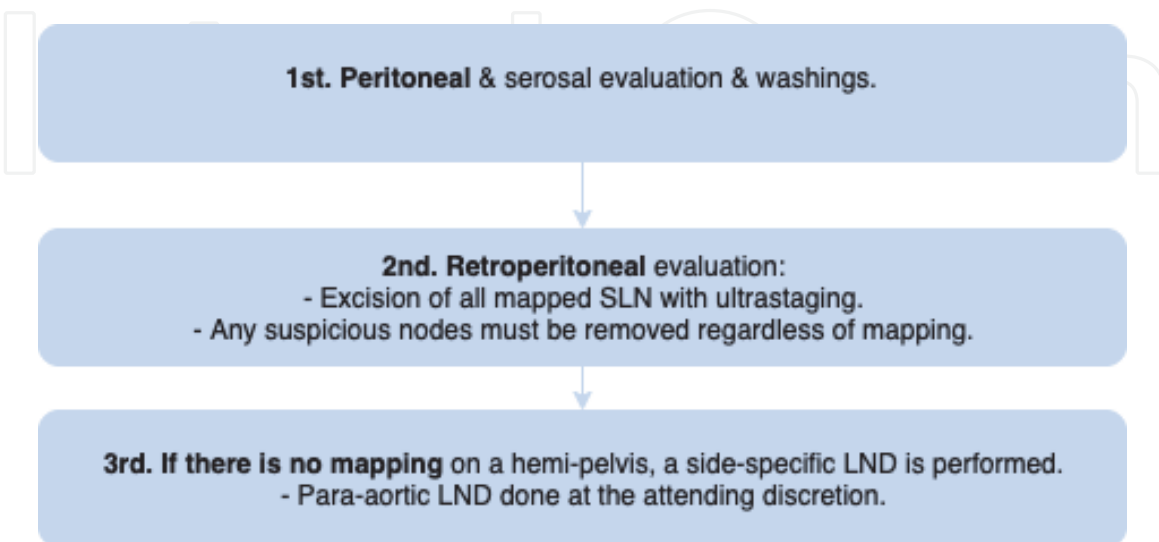
The histological ultrastaging procedure includes a protocol for the series of microscopic examinations of the SLN block fixed and imbedded in paraffin, with the addition of the immunohistochemical analysis with cytokeratin measurement (pan-cytokeratin kits AE1/AE2 or anti-CK19), thereby increasing the sensitivity [79]. There are no formal evidence-based regimens for the pathology assessment of SLNs in EC, which entails considerable variability among institutions and,

therefore, debatable results [30]. The study by Euscher et al. [80] compared two methods of ultrastaging by histological microsection, achieving increased detection of metastatic SLN in 32% of patients, with a mean metastasis size of 0.24–0.38 mm, with no differences in the detection rate by ultrastaging method. The algorithm proposed by the MSKCC consists of an initial assessment by H&E and, if negative, performing two adjacent 5- $\mu$ m slices at two levels separated by 50  $\mu$ m in the paraffin block, applying H&E staining and pan-cytokeratins AE1/AE3 in each slice [81]. Holloway et al. [82] performed three slices per level, two of which were then stained with H&E and one with AE1/AE3. Other authors have performed four levels with six slices at 40  $\mu$ m intervals (levels 1 and 2 with H&E and levels 3 and 4 with AE1/AE3) or five levels (levels 1, 3 and 5 with H&E and 2 and 4 with AE1/AE3) [30] (Figure 1).

Cytokeratin-19 (CK-19) is a protein of the intermediate filament responsible for the structural integrity of epidermal epithelial cells, which in normal conditions is not expressed in the lymphatic tissue and is expressed abnormally in more than 90% of cells by EC [83, 84]. CK-19 is a biomarker directly related to the capacity for tumour dissemination in EC, with high sensitivity and a capacity for discriminating between metastatic and nonmetastatic lymph nodes or areas of lymphovascular invasion [84, 85].

Ultrastaging is a more complex procedure, requiring significant dedication, and has the added risk of high intraobserver and interobserver variability. The diagnostic categories of the American Joint Committee on Cancer (AJCC) are applied for breast cancer, with the following classifications for SLN: negative (<200 individual tumour cells or tumour cell aggregates <0.2 mm in size, including the presence of isolated cytokeratin-positive tumour cells [ITC]), micrometastatic (size  $\geq$ 0.2 and <2 mm) ( $\mu$ M) or macrometastatic (>2 mm) (MM) [86]. The term low tumour volume includes the ITC and  $\mu$ M categories.

The ultrastaging of SLN has improved the validity of the technique and detects an additional 5–15%, with a high rate of low-volume lymph node disease (approximately 50% of patients with metastatic SLN), which would not be identified with the conventional technique. Ultrastaging represents an overall mean increase of 25% (range, 10–60%) in detecting metastatic lymph nodes [79, 84].



**Figure 1.**  
The SLN algorithm for surgical staging of endometrial cancer. Obtained from NCCN Guideline in Endometrial Carcinoma, Version 4.2019: 'Principles of evaluation and surgical staging when SLN mapping is used, Figure 4: The SLN algorithm for surgical staging of endometrial cancer'. SLN = sentinel lymph node; LND = lymph node dissection.

Analysis by histological microsection and H&E detects 6.9% more patients with metastatic SLN, while the inclusion of IHC provides an additional 4.5% (82.6% with low tumour volume), which represents 12.6% of patients with metastatic SLN [81]. In the multicentre retrospective study by Raimond et al. [87] with 136 low-intermediate risk cases, the detection of SLN and the ultrastaging analysis increased the detection of metastatic lymph nodes threefold over lymphadenectomy (16.2 vs. 5.1%;  $p = 0.03$ ); 11% of the cases were  $\mu\text{M}$  and 5.1% were MM, with an FNR of 0 (95% CI 0–1.6%). In the study, 6.1% of the metastatic SLN were detected by histological microsection, and 10.1% were detected by IHC. All MM cases were diagnosed by histological microsection, and 73.3% of the  $\mu\text{M}$  cases were diagnosed by IHC readings. Thus, by applying ultrastaging, the SLNB restaged 50% of the patients included in the study to an European Society of Medical Oncology (ESMO) high risk (14.7% of the sample), thereby changing the adjuvant therapy compared with women with negative or unassessed lymph nodes ( $p < 0.001$ ). In the study by Hagen et al. [88], 75% of patients with metastatic SLN were detected with histological microsection and an additional 25% with IHC. For Desai et al. [89], 50% of the metastatic SLNs were detected by IHC.

### 3.2.2. Molecular ultrastaging

The one-step nucleic acid amplification method (OSNA) is a validated technique for breast cancer and enables a quantitative, systematic, automated, nonobserver-dependent analysis for detecting lymph node metastases [73, 84]. The application of this method always requires prior confirmation of CK-19 expression in the tumour tissue [90, 91]. The application of radiocolloid or dye does not interfere with the process. The number of mRNA copies of CK-19 corresponds to the size of the metastatic foci present in the SLN [92], such that the results are visualised in four separate categories: negative ( $<10^2$  copies of mRNA/ $\mu\text{L}$ ), ITC ( $10^2$  to  $<2.5 \times 10^2$  copies of mRNA/ $\mu\text{L}$ ),  $\mu\text{M}$  ( $\geq 2.5 \times 10^2$  to  $<5 \times 10^3$  copies mRNA/ $\mu\text{L}$ ) and MM ( $>5 \times 10^3$  copies mRNA/ $\mu\text{L}$ ) [93].

The results of the Breast Complete Lymphadenectomy OSNA Study for Enhanced Review-I (B-CLOSER-I) [94] indicate that histopathology (compared with molecular detection) significantly underestimates the rate of metastases of axillary lymph nodes.

Preliminary results of its application in EC indicate superior diagnostic accuracy compared with conventional ultrastaging, although further research is needed. By applying the OSNA method, the study by Nagai et al. [84] achieved sensitivity of 93.3%, specificity of 99.5%, a negative predictive value (NPV) of 99.5% and a correlation of 99.1%. In the study by López-Ruiz et al. [85] of 34 patients with chronic diseases and 94 analysed SLNs, the OSNA method detected a larger portion of additional low tumour volume metastases, with diagnostic capacity (sensitivity of 100%, specificity of 87.5%, accuracy of 88.3% and an FNR of 2.8%).

## 4. Approach and prognosis for metastatic sentinel nodes

The increase in detection of lymphatic metastases resulting from the introduction of ultrastaging is mainly at the expense of the detection of low tumour volume. The NCCN guidelines [5] and the consensus of The Society of Gynecologic Oncology (SGO) [30] recommend the study of SLNs by ultrastaging, indicating that the significance of low-volume lymph node involvement is still uncertain and have not established an optimal treatment approach [55, 95, 96].



A number of authors have debated and hypothesised a different tumour biology and therefore a different behaviour between tumours with MM and  $\mu$ M. For other authors,  $\mu$ M metastases appear early and are reflections of isolated metastases in type 2 histology but would be metastases of late evolution in tumours with low oncologic aggressiveness [97]. It has also been suggested that  $\mu$ M metastases could represent an *intermediate state* between negative lymph nodes and positive lymph nodes for MM [98].

One of the aforementioned advantages of the SLNB technique in early stages is avoiding the implementation of lymphadenectomy [87]. However, the therapeutic benefit of completing the lymphadenectomy when faced with the finding of metastatic SLN with low tumour volume remains unknown, and its systematic implementation is not justified [83, 98, 120]. The FIRES trial performed postoperative radiological studies (with scanner or positron emission tomography-computed tomography [PET-CT]). When the findings showed voluminous residual metastases, the proposed treatment was surgical cytoreduction or a change in the adjuvant radiation therapy (RT) to include the paraaortic area [74].

In recent years, research has been conducted on the possible influence of adjuvant therapy and the prognosis for patients with low-volume lymphatic metastases [99]. There is still no evidence from prospective randomised studies on cases with detected low-volume metastatic tumours, resulting in heterogeneity among the published studies [56]. Moreover, it is important to determine the benefit provided to these patients by combining CT and/or adjuvant RT, considering the scarce survival benefit obtained. The study by Plante et al. [100] analysed the impact of adjuvant therapy on survival. Thirty-five percent of the patients with ITC in the SLN underwent CT and external beam RT, 32% only underwent external beam RT or vaginal brachytherapy and 32% underwent follow-up. The overall survival at 3 years in the group with ITC was 95.5%, with no differences compared with the patients without metastatic lymph nodes or with  $\mu$ M in the SLN (87.6 and 85.5%, respectively). However, the low tumour volume SLN was superior to the SLN with MM (58.5%;  $p < 0.001$ ).

Significant differences have not been observed between the prognosis of patients with only SLN excision versus those with lymphadenectomy (disease-free survival [DFS] at 3 years of 94.9 vs. 96.8%;  $p = 0.35$ ). However, it has been observed that the patient group with metastatic SLN increases the portion of adjuvant therapy received (27.1 vs. 10.8%;  $p < 0.001$ ) [101]. In the retrospective series by Raimond et al. [87], neither the absence of metastases in SLN, the detection of metastatic SLN nor the presence of  $\mu$ M in the SLN represented an improvement in DFS ([hazard ratio (HR), 0.89; 95% CI 0.42–1.90;  $p = 0.77$ ], [HR, 0.82; 95% CI 0.18–3.64;  $p = 0.8$ ] and [HR, 0.46; 95% CI 0.03–7.42;  $p = 0.59$ ], respectively). When comparing negative lymphadenectomy with the detection of lymphatic metastases, there were no differences in DFS (HR, 1.13; 95% CI 0.34–3.76;  $p = 0.84$ ) or overall survival (HR, 1.29; 95% CI 0.30–5.59;  $p = 0.73$ ).

Yabushita et al. [92] showed that the detection of  $\mu$ M and SLN was an independent factor for recurrence in early stages of EC. Kim et al. [75] measured a tendency to late distant metastasis when the SLN was metastatic for  $\mu$ M. For Todo et al. [97], ITCs in the paraaortic area were not associated with a greater risk of nonlymphogenic or extrapelvic recurrence. For Kim et al. [75], these ITCs did not represent increased relapses. In the study by Erkanli et al. [102], DFS and overall survival were significantly lower in patients with  $\mu$ M ( $p < 0.05$ ), while the presence of ITCs appeared to have no effect on survival. In another study by Todo et al. [103], the presence of low tumour volume was an independent factor for extrapelvic relapse (RR, 17.9), with 20% lower survival (overall survival of 71.4 vs. 91.9% and DFS of 55.6 vs. 84%;  $p = 0.074$ ) and a tendency towards late relapse



Authors/trial	Journal, year	Injection	Tracer	N	SLN/ case	DR	BL	Se (%)	NPN	FNR	FN localization	DR PAO	
Ballester et al. (SENTIENDO) [104]	Lancet Oncol. 2011	Cervical	<sup>99m</sup> Tc + Blue	125	2	89	69	84	97	15	PAO1	5	
Khoury-Collado et al. [78]	Gynecol Oncol. 2011	Cervical	<sup>99m</sup> Tc w/o Blue	266	3	84	67	78	93				
Barlin et al. [3]2	Gynecol Oncol. 2012	Cervical	Blue	498	3	81	51	98	99.8	1.9	PAO		
How et al. [105]	Gynecol Oncol. 2012	Cervical	<sup>99m</sup> Tc + Blue	100	2	92	72	89	99	1	PAO	16.3	
Raimond et al. [87]	Gynecol Oncol. 2014	Cervical	<sup>99m</sup> Tc + Blue	304	2.5	87.2	65.4			03			
Touhami et al. [77]	Gynecol Oncol. 2015	Cervical	<sup>99m</sup> Tc + Blue	268	2	94	73.5	97.2	99.4	0.64			
Hagen et al. [88]	Gynecol Oncol. 2016	Cervical	ICG	108	4	96	78			5.8			
Ehrisman et al. [106]	Gynecol Oncol Reports. 2016	Cervical	ICG or MB	36	2	83	56		92.3	7.75		3	
Holloway et al. [82]	Gynecol Oncol. 2016	Cervical	ICG + blue	780	3	98.3	80.7			2.8		9	
Rossi et al. (FIRES) [74]	Lancet Oncol. 2017	Cervical	ICG	385		86		97.2	99.6	2.7		1	
Plante et al. [100]	Gynecol Oncol. 2017	Cervical	<sup>99m</sup> Tc + Blue or ICG	519	2.2			98.4	99.7				
Soliman et al. [107]	Gynecol Oncol. 2017	Cervical	<sup>99m</sup> Tc + Blue or Blue or ICG	101	2	89	58	95	98.6	56		2	
				$\sum (\mu \pm \sigma)$		3490	2.3 ± 0.9	89 ± 5.5	67 ± 9.6	92 ± 7.6	97 ± 2.9	4.2 ± 4.5	6 ± 5.7
Bodurtha-Smith et al. Meta-analysis [26]	Am. J Obstet & Gynecol. 2016	Cervical or uterine corpus	Dye (MB or ICG) w/o <sup>99m</sup> Tc	4915	2.9	81	50	96	99.7			17	
Lin et al. Meta-analysis7 [72]	Oncotarget. 2017	Various	Various	2236	—	83	56	91					

The results of 13 methodologically comparable studies are cited; studies include more than a hundred of cases, except for the one of Ehrisman et al. [106] because it is one of the recently published studies that includes patients with high-risk endometrial cancer. The studies include cases with all histological type and two papers only high-risk cases, the one mentioned by Ehrisman et al. [106] and Soliman et al. [107] The average of the collected variables is estimated. Results of two meta-analyses, which have not been added in the estimation, are attached to the possibility that the previously mentioned studies were already included in their data. The word "Various" indicates that various injection methods or tracer combinations were collected. The blank box indicates that this information has not been mentioned in the article.

N = patients included; SLN = sentinel lymph node; DR = detection rate; BL = bilaterality; Se = sensibility; NPV = negative predictive value; FNR = false negative rate; FN = false negative; (+) = metastasis; w/o = with or without; (%) = proportion;  $\Sigma$  = summation;  $(\mu \pm \sigma)$  = mean  $\pm$  standard deviation;  $^{99m}\text{Tc}$  =  $^{99m}\text{Tc}$ -nanocolloid albumin; MB = methylene blue; ICG = indocyanine green; PAO = paraaortic.

<sup>1</sup>All three FNR cases had nonendometrioid histology, one with paraaortic positive drainage. There were no cases of isolated paraaortic drainage.

<sup>2</sup>The data are reflected after application of the MSKCC proposed surgical algorithm. Without applying the algorithm: Se of 85.1%, VPN of 98.1% and FNR of 14.9%. One FNR case with isolated paraaortic metastasis.

<sup>3</sup>The estimation of the FNR is performed from the total of negative lymphadenectomies; it does not include negative SLN and positive lymphadenectomy, in which case it would be a FNR of 9.1%.

<sup>4</sup>The predictive capacity is estimated only based on cases with SLN detected bilaterally.

<sup>5</sup>Null FNR with Se and NPV of 100% after the retrospective application of the MSKCC algorithm.

<sup>6</sup>The FNR would be 4.3% after adjusting by MSKCC algorithm.

<sup>7</sup>Surgical detection with dual technique: radiotracer and dye. ICG increases the overall detection rate to 93% and bilaterality of 78%. Cervical injection increases Se to 93% and detection rate to 86%.

**Table 3.**

Analysis of recent studies: Detection rate, predictive capacity, false negative rate and paraaortic drainage of the sentinel node.

Authors/trial	Journal year	Injection	Tracer	N	SLN+	Single SLN+	LTV				MM
							ITC	$\mu$ M	(%)		
Ballester et al. (SENTIENDO) [104]	Lancet Oncol. 2011	Cervical	$^{99m}\text{Tc}$ + Blue	125	17		8.5	1	7.5	8.5	
Khoury-Collado et al. [78]	Gynecol Oncol. 2011	Cervical <sup>(7)</sup>	$^{99m}\text{Tc}$ w/o Blue	266	12		3			9	
Barlin et al. [3]	Gynecol Oncol. 2012	Cervical	Blue	498	10						
How et al. [105]	Gynecol Oncol. 2012	Cervical	$^{99m}\text{Tc}$ + Blue	100	11	44					
Raimond et al. [87]	Gynecol Oncol. 2014	Cervical	$^{99m}\text{Tc}$ + Blue	304	16.2		11		11	5.1	
St. Clair et al. [108]	Annals of Surg Oncol. 2015	Cervical	ICG o Blue	844	10.8		5.3	2.7	2.6	5.6	
Touhami et al. [77]	Gynecol Oncol. 2015	Cervical	$^{99m}\text{Tc}$ + Blue	268	16			4.5	2.6	8.9	
Hagen et al. [88]	Gynecol Oncol. 2016	Cervical	ICG	108	16						
Holloway et al. [82]	Gynecol Oncol. 2016	Cervical	ICG + Blue	780	15.8	51.4	5.4	2.2	3.2	10.4	
Ehrisman et al. [106]	Gynecol Oncol Reports. 2016	Cervical	ICG o MB	36	15						
Rossi et al. (FIRES) [74]	The Lancet Oncol. 2017	Cervical	ICG	385	12						
Plante et al. [100]	Gynecol Oncol. 2017	Cervical	$^{99m}\text{Tc}$ + Blue o ICG	519	16.4		8.1	6	2.1	8.3	
Soliman et al. [107]	Gynecol Oncol. 2017	Cervical	$^{99m}\text{Tc}$ + Azul or Blue or ICG	101	23	40	9.9	2.5	7.4	13.1	
$\Sigma (\mu \pm \sigma)$				4334	14.7 $\pm$ 3.5	45.1 $\pm$ 5.8	7.3 $\pm$ 2.8	3.1 $\pm$ 1.8	5.2 $\pm$ 3.4	8.6 $\pm$ 2.5	

The results of 13 methodologically comparable studies are cited; studies include more than a hundred of cases, except for the one of Ehrisman et al. [106] because it is one of the recently published studies that includes patients with high-risk endometrial cancer. The studies include cases with all histological type and two papers only high-risk cases, the one mentioned by Ehrisman et al. [106] and Soliman et al. [107]. The average of the collected variables is estimated. The blank box indicates that this information has not been mentioned in the article.

N = patients included; SLN = sentinel lymph node; DR = detection rate; (+) = metastasis; LTV = low tumour volume (includes ITC and  $\mu$ M); ITC = isolated tumour cells;  $\mu$ M = micrometastasis; MM = macrometastasis; w/o = with or without; (%) = proportion;  $\Sigma$  = summation;  $(\mu \pm \sigma)$  = mean  $\pm$  standard deviation;  $^{99m}\text{Tc}$  =  $^{99m}\text{Tc}$ -nanocolloid albumin; MB = methylene blue; ICG = indocyanine green.

**Table 4.**

Analysis of recent studies: proportion of patients with metastatic sentinel node, proportion of single metastatic sentinel node and distribution by type of metastases detected.

(49 vs. 16.5 months;  $p = 0.066$ ) compared with the patient group without lymphatic metastasis. The conclusion of these studies is that the presence of  $\mu\text{M}$  can represent a prognostic biomarker in terms of survival, but whether the presence of ITCs should be used as such, regardless of other clinical-pathological risk factors, is still unknown [30] (Tables 3 and 4).

## 5. Recommendations for the clinical application of selective sentinel node biopsy

The published results of SLNB in EC have shown good diagnostic performance. SNLB is a promising and safe technique from the oncological point of view [10]. Given the mixed results, which have failed to show a therapeutic benefit [9], and the lack of long-term results [5], an appropriate interpretation is recommended [4, 29], considering SNLB a technique under study [78].

As with lymphadenectomy and adjuvant therapy, SNLB can be safely omitted for low-risk patients (endometrioid histology: IA G1, IA G2) [9, 55]. For intermediate-risk (endometrioid histology: IA G3, IB G1, IB G2) patients, SNLB has not shown a clear benefit in survival when performing systematic lymphadenectomy. This group does, however, have a greater risk of lymphatic involvement and typically undergo adjuvant therapy. SLNB in both patient groups has been shown to detect 2–3 times more cases of metastatic EC than lymphadenectomy, without changing the disease prognosis [87, 109]. These results justify extending the technique to low to intermediate risk, with the recommendation of including it in an algorithm or surgical protocol that includes the implementation when faced with failure of the technique. The potential benefit of detecting metastatic SLN in low-risk patients is however diluted by the low incidence of cases and the high proportion of low tumour volume. It appears we need to clarify the role of SLNB and the effect of low tumour volume, which is more frequently detected in this group [87, 109].

Two randomised clinical trials did not show that lymphadenectomy changed overall survival or relapse rates in high-risk patients [110–112], although retrospective series did show this change [113, 114]. The implementation of pelvic and paraaortic lymphadenectomy has been systematised due to the higher rate of lymphatic metastases and poorer prognosis associated with their detection. In contrast, sceptics of lymphadenectomy state that routine nodal assessment of high-risk patients rarely changes the recommendations for adjuvant therapy. EC (especially in high-risk cases) is not just a disease confined to the pelvis [50]. Patients with high-risk EC have a higher probability of recurrence and recidivism with or without detection of lymphatic metastases and should undergo systemic therapy regardless of the nodal state [115]. Nevertheless, published results on high-risk patients have shown no differences compared with those expected from studies that also include low- to intermediate-risk cases, with the same incidence of paraaortic metastasis estimated by lymphadenectomy. Survival data have shown no differences [30], which would assume that the benefit of SNLB in high-risk patients would be equivalent to lymphadenectomy alone [106, 107].

In terms of applying SLNB to high-risk patients, the greatest debate concerns paraaortic drainage, with a greater proportion of undetected metastatic paraaortic nonsentinel lymph nodes. A study by Naoura et al. [116] analysed 180 patients and achieved a much higher FNR in the high-risk group (2.3 vs. 20%;  $p < 0.001$ ). In this study, it was much more likely that the high-risk subtype (7 vs. 28%;  $p = 0.03$ ) and the nonendometrioid type (8 vs. 29%;  $p = 0.02$ ) were poorly assessed.

The FIRES study [74] on 385 patients represents the largest prospective series to date and included low and high-risk patients, achieving a sensitivity of 97.2% and



an NPV of 99.6%. Fifty percent of detected metastatic SLNs were in patients with low-risk EC, the most incidental group. Only 1% were isolated paraaortic metastases, with an FNR of 2.7%. Barlin et al. [3] and the FIRES study concluded that a pelvically located SLN could be sufficient for directing the treatment [74].

In light of these results and lacking a therapeutic benefit for lymphadenectomy, the current guidelines recommend that only pelvic SLNs should be determined (and with caution) in this high-risk patient group [5, 30]. Until there is better evidence, the recommendation is to perform systematic lymphadenectomy adding SLNB, which a number of authors have labelled as 'high-precision lymphadenectomy'.

To decrease the number of faults in the technique and the risk of underdiagnosis in high-risk cases, several research groups have performed PET-CT, excluding cases with peritoneal or lymphatic uptake [117]. Other authors have included postoperative scans or PET in cases in which the paraaortic lymphadenectomy was not completed [30]. Another option for managing high-risk patients includes implementing a combined injection pathway, ensuring both pelvic and paraaortic drainage.

The Selective Targeting of Adjuvant Therapy in Endometrial Cancer (STATEC) in the United Kingdom [30] and the Evaluation of Sentinel Node Policy in Early Stage Endometrial Carcinomas at Intermediate and High Risk of Recurrence (SENTIRAD) in France are two studies currently underway on high-risk patients, comparing the effect of SLNB versus systematic lymphadenectomy (bilateral pelvic and paraaortic) in high-risk EC in initial clinical stages. The STATEC study compares SLNB versus lymphadenectomy with the patient as the same control. The SENTIRAD study randomised patients to SLNB or lymphadenectomy, following an algorithm that performs bilateral pelvic and paraaortic lymphadenectomy when faced with a failure in detection or unilateral detection.

In 2014, the NCCN clinical guidelines assessed the technique as an acceptable alternative to systematic lymphadenectomy in selected cases [36]. In the latest edition, NCCN [5] (v.3.2019) accepted the technique as category 2A (based on lower level evidence with uniform consensus by the expert panel that the procedure was appropriate) and established a number of recommendations:

- SLN mapping may be considered
- The application of SLN mapping is appropriate for low intermediate-risk patients or those who do not tolerate standard lymphadenectomy.
- Recent evidence indicates that sentinel node mapping may also be used in high-risk histologies (serous carcinoma, clear cell carcinoma, carcinosarcoma).
- Cervical injection (superficial and optional deep) is a useful and valid option.
- The use of a radiocolloid with blue dye is recommended. The usefulness of ICG is admitted if NIR detection equipment is available.
- The key point in the normalisation of the technique is adherence to a surgical protocol.
- SLNB should be performed in institutions with experience in this procedure. The technique requires proper methodology and demands good anatomical knowledge and surgical ability. The MSKCC group recommends performing SLNB in centres with experience in endoscopic surgery and with an experience of at least 30 supervised cases during the learning process, with a specialised team that enables close collaboration between the surgeon and pathologist [32].

In the study by Papadia et al. [118], the implementation of at least 20 procedures decreased the number of SLNs obtained without compromising the FNR, improving the accuracy of the technique.

- The histological analysis should be performed by ultrastaging. Although the implication and proper management of low tumour volume are not known, its detection has a potential effect on staging.
- Lymphatic mapping implementation is contraindicated in uterine sarcoma.

Recently, the SGO published a first consensus on the application of SLNB in EC [30], which concluded with the following recommendations:

- Lymphatic mapping with cervical injection accurately predicts the detection of lymphatic metastasis, with an FNR <5%. In institutions with higher FNRs, the implementation of lymphadenectomy should be maintained (if it was previously indicated) until an FNR <5% has been ensured. Similarly, the SGO suggests adopting the indications of the American Society of Clinical Oncology applied to SLNB in breast cancer, such that lymphadenectomy is completed after SLNB in the first 20–30 cases. For low-risk patients, the recommendation is to increase the number of supervised cases during the learning process, given the lower risk of detecting lymphatic metastases [36, 119].
- The injection of radiocolloid and dye is acceptable. If ICG is available, it should be used instead.
- For patients with low- to intermediate-grade type I EC and tumour confinement to the uterus, lymphadenectomy can be skipped, performing only the SLNB.
- Although SLNB has been shown to increase the detection of lymphatic metastases, patients should be informed of the potential risk of undetected occult disease.
- The main demonstrated usefulness of SLNB is in detecting pelvic metastasis. The decision to perform paraaortic lymphadenectomy is at the surgical team's discretion, considering the patient's clinicopathological characteristics.
- Ultrastaging is recommended in the analysis of the SLN, although its involvement in detecting ITC requires more research.
- The application of SLNB to high-risk patients (type 1 G3 and type 2 histology) following the NCCN algorithm is feasible and has had good published results [30]. The combination of pelvic and paraaortic lymphadenectomy is reasonable until more safety and efficacy data for SLNB are available.

## Abbreviations

CT	chemotherapy
CK19	cytokeratin 19
EBRT	external boost radiotherapy
EC	endometrial cancer

DR	detection rate
FNR	false negative rate
H&E	haematoxylin and eosin
HR	hazard ratio
ICG	indocyanine green
IHQ	Immunohistochemistry
ITC	isolated tumour cells
MB	methylene blue
MM	macrometastases
NPV	negative predictive value
OSNA	one-step nuclear acid amplification
PET-CT	positron emission tomography-computed tomography
RR	relative risk
RT	radiotherapy (includes EBRT y vaginal-cuff brachytherapy)
Se	sensibility
SLN	sentinel lymph node
SLNB	sentinel lymph node biopsy
Sp	specificity
SPECT	single photon emission computed tomography
vs.	versus
95%CI	confidence interval of 95%
$^{99m}\text{Tc}$	$^{99m}\text{Tc}$ -albumin nanocolloid
$\mu\text{M}$	micrometastases
$\mu$	mean
$\Sigma$	summation or total
$\sigma$	standard deviation

IntechOpen


### Author details

Begoña Díaz de la Noval

Consultant at Gynaecology and Obstetrics, Hospital Universitario Central de Asturias, Spain

\*Address all correspondence to: [begodelanoval@gmail.com](mailto:begodelanoval@gmail.com)

### IntechOpen

© 2019 The Author(s). Licensee IntechOpen. This chapter is distributed under the terms of the Creative Commons Attribution License (<http://creativecommons.org/licenses/by/3.0/>), which permits unrestricted use, distribution, and reproduction in any medium, provided the original work is properly cited. 

## References

- [1] Tanis PJ, Nieweg OE, Valdés Olmos RA, Th Rutgers EJ, Kroon BB. History of sentinel node and validation of the technique [Review]. *Breast Cancer Research*. 2001;**3**(2):109-112
- [2] Nieweg OE, Uren RF, Thompson JF. The history of sentinel lymph node biopsy. *Cancer Journal*. 2015;**21**(1):3-6
- [3] Barlin JN, Khoury-Collado F, Kim CH, Leitao MM, Chi DS, Sonoda Y, et al. The importance of applying a sentinel lymph node mapping algorithm in endometrial cancer staging: Beyond removal of blue nodes. *Gynecologic Oncology*. 2012;**125**(3):531-535
- [4] Bogani G, Ditto A, Martinelli F, Signorelli M, Perotto S, Lorusso D, et al. A critical assessment on the role of sentinel node mapping in endometrial cancer. *Journal of Gynecologic Oncology*. 2015;**26**(4):252-254
- [5] NCCN Clinical Practice Guidelines in Oncology. Uterine Neoplasms. v4.2019 [Internet]. National Comprehensive Cancer Network (NCCN). Available from: [https://www.nccn.org/professionals/physician\\_gls/pdf/uterine.pdf](https://www.nccn.org/professionals/physician_gls/pdf/uterine.pdf) [Accessed: September 24, 2019]
- [6] Smith B, Backes F. The role of sentinel lymph nodes in endometrial and cervical cancer. *Journal of Surgical Oncology*. 2015;**112**(7):753-760
- [7] Torné A, Pahisa J, Vidal-Sicart S, Martínez-Roman S, Paredes P, Puerto B, et al. Transvaginal ultrasound-guided myometrial injection of radiotracer (TUMIR): A new method for sentinel lymph node detection in endometrial cancer. *Gynecologic Oncology*. 2013;**128**(1):88-94
- [8] Pelosi E, Arena V, Baudino B, Bellò M, Giusti M, Gargiulo T, et al. Pre-operative lymphatic mapping and intra-operative sentinel lymph node detection in early stage endometrial cancer. *Nuclear Medicine Communications*. 2003;**24**(9):971-975
- [9] Touboul C, Bentivegna E, Uzan C, Gouy S, Pautier P, Lhommé C, et al. Sentinel lymph node in endometrial cancer: A review. *Current Oncology Reports*. 2013;**15**(6):559-565
- [10] Abu-Rustum NR. Sentinel lymph node mapping for endometrial cancer: A modern approach to surgical staging. *Journal of the National Comprehensive Cancer Network*. 2014;**12**(2):288-297
- [11] Geppert B, Lönnerfors C, Bollino M, Arechvo A, Persson J. A study on uterine lymphatic anatomy for standardization of pelvic sentinel lymph node detection in endometrial cancer. *Gynecologic Oncology*. 2017;**145**(2):256-261
- [12] Burke TW, Levenback C, Tornos C, Morris M, Wharton JT, Gershenson DM. Intraabdominal lymphatic mapping to direct selective pelvic and paraaortic lymphadenectomy in women with high-risk endometrial cancer: Results of a pilot study. *Gynecologic Oncology*. 1996;**62**(2):169-173
- [13] Biliatis I, Thomakos N, Koutroumpa I, Haidopoulos D, Sotiropoulou M, Antsaklis A, et al. Subserosal uterine injection of blue dye for the identification of the sentinel node in patients with endometrial cancer: A feasibility study. *Archives of Gynecology and Obstetrics*. 2017;**296**(3):565-570
- [14] Abu-Rustum NR. The increasing credibility of sentinel lymph node mapping in endometrial cancer. *Annals of Surgical Oncology*. 2013;**20**(2):353-354
- [15] Sahbai S, Taran F-A, Fiz F, Staebler A, Becker S, Solomayer E, et al.



Pericervical injection of  $^{99m}\text{Tc}$ -nanocolloid is superior to peritumoral injection for sentinel lymph node detection of endometrial cancer in SPECT/CT. *Clinical Nuclear Medicine*. 2016;**41**(12):927-932

[16] Niikura H, Kaiho-Sakuma M, Tokunaga H, Toyoshima M, Utsunomiya H, Nagase S, et al. Tracer injection sites and combinations for sentinel lymph node detection in patients with endometrial cancer. *Gynecologic Oncology*. 2013;**131**(2):299-303

[17] Levinson KL, Escobar PF. Is sentinel lymph node dissection an appropriate standard of care for low-stage endometrial cancers? A review of the literature. *Gynecologic and Obstetric Investigation*. 2013;**76**(3):139-150

[18] Kataoka F, Susumu N, Yamagami W, Kuwahata M, Takigawa A, Nomura H, et al. The importance of para-aortic lymph nodes in sentinel lymph node mapping for endometrial cancer by using hysteroscopic radio-isotope tracer injection combined with subserosal dye injection: Prospective study. *Gynecologic Oncology*. 2016;**140**(3):400-404

[19] Martinelli F, Ditto A, Signorelli M, Bogani G, Chiappa V, Lorusso D, et al. Sentinel node mapping in endometrial cancer following hysteroscopic injection of tracers: A single center evaluation over 200 cases. *Gynecologic Oncology*. 2017;**146**(3):525-530

[20] Perrone AM, Casadio P, Formelli G, Levorato M, Ghi T, Costa S, et al. Cervical and hysteroscopic injection for identification of sentinel lymph node in endometrial cancer. *Gynecologic Oncology*. 2008;**111**(1):62-67

[21] Zivanovic O, Khoury-Collado F, Abu-Rustum NR, Gemignani ML. Sentinel lymph node biopsy in the

management of vulvar carcinoma, cervical cancer, and endometrial cancer. *Oncologia*. 2009;**14**(7):695-705

[22] Mais V, Cirronis MG, Piras B, Silvetti E, Cossu E, Melis GB. Intraoperative lymphatic mapping techniques for endometrial cancer. *Expert Review of Anticancer Therapy*. 2011;**11**(1):83-93

[23] Rocha A, Domínguez AM, Lécure F, Bourdel N. Indocyanine green and infrared fluorescence in detection of sentinel lymph nodes in endometrial and cervical cancer staging—A systematic review. *European Journal of Obstetrics, Gynecology, and Reproductive Biology*. 2016;**206**:213-219

[24] Abu-Rustum NR. Update on sentinel node mapping in uterine cancer: 10-year experience at Memorial Sloan-Kettering Cancer Center. *The Journal of Obstetrics and Gynaecology Research*. 2014;**40**(2):327-334

[25] Kang S, Yoo HJ, Hwang JH, Lim M-C, Seo S-S, Park S-Y. Sentinel lymph node biopsy in endometrial cancer: Meta-analysis of 26 studies. *Gynecologic Oncology*. 2011;**123**(3):522-527

[26] Bodurtha-Smith AJ, Tanner EJ. Sentinel lymph node assessment in endometrial cancer: A systematic review and meta-analysis. *American Journal of Obstetrics and Gynecology*. 2016;**216**(5):459.e10-476.e10

[27] Cormier B, Rozenholc AT, Gotlieb W, Plante M, Giede C, Communities of Practice (CoP), et al. Sentinel lymph node procedure in endometrial cancer: A systematic review and proposal for standardization of future research. *Gynecologic Oncology*. 2015;**138**(2):478-485

[28] Mariani A, Dowdy SC, Cliby WA, Gostout BS, Jones MB, Wilson TO, et al. Prospective assessment of lymphatic dissemination in endometrial cancer: A

paradigm shift in surgical staging. *Gynecologic Oncology*. 2008;**109**(1): 11-18

[29] Khoury-Collado F, Abu-Rustum NR. Lymphatic mapping in endometrial cancer: A literature review of current techniques and results. *International Journal of Gynecological Cancer*. 2008; **18**(6):1163-1168

[30] Holloway RW, Abu-Rustum NR, Backes FJ, Boggess JF, Gotlieb WH, Lowery WJ, et al. Sentinel lymph node mapping and staging in endometrial cancer: A Society of Gynecologic Oncology literature review with consensus recommendations. *Gynecologic Oncology*. 2017;**146**(2): 405-415

[31] Holloway RW, Ahmad S, Kendrick JE, Bigsby GE, Brudie LA, Ghurani GB, et al. A prospective cohort study comparing colorimetric and fluorescent imaging for sentinel lymph node mapping in endometrial cancer. *Annals of Surgical Oncology*. 2017; **24**(7):1972-1979

[32] Khoury-Collado F, Glaser GE, Zivanovic O, Sonoda Y, Levine DA, Chi DS, et al. Improving sentinel lymph node detection rates in endometrial cancer: How many cases are needed? *Gynecologic Oncology*. 2009;**115**(3): 453-455

[33] Frumovitz M, Levenback CF. Is lymphatic mapping in uterine cancer feasible? *Annals of Surgical Oncology*. 2008;**15**(7):1815-1817

[34] Maccauro M, Lorenzoni A, Crippa F, Manca G, Chondrogiannis S, Giammarile F, et al. Sentinel lymph node biopsy in pelvic tumors: Clinical indications and protocols under investigation. *Clinical Nuclear Medicine*. 2016;**41**(6):e288-e293

[35] Holub Z, Jabor A, Lukac J, Kliment L. Laparoscopic detection of

sentinel lymph nodes using blue dye in women with cervical and endometrial cancer. *Medical Science Monitor*. 2004; **10**(10):CR587-CR591

[36] Papadia A, Gasparri ML, Buda A, Mueller MD. Sentinel lymph node mapping in endometrial cancer: Comparison of fluorescence dye with traditional radiocolloid and blue. *Journal of Cancer Research and Clinical Oncology* [Internet]. 2017;**143**(10): 2039-2048

[37] Fishman A, Klein A, Zemer R, Zimlichman S, Bernheim J, Cohen I, et al. Detection of micrometastasis by cytokeratin-20 (reverse transcription polymerase chain reaction) in lymph nodes of patients with endometrial cancer. *Gynecologic Oncology*. 2000; **77**(3):399-404

[38] Chain Y, Illanes L. *Radiofármacos en medicina nuclear*. In: *Fundamentos y Aplicación Clínica*. 1st ed. Buenos Aires, Argentina: Universidad Nacional de la Plata, Libros de Cátedra; 2015. 188p

[39] Nanocoll Ficha Técnica y Resumen de las Características del Producto [Internet]. Ministerio de Sanidad, Política Social e Igualdad - Agencia Española de Medicamentos y Productos Sanitarios. Available from: [https://www.aemps.gob.es/cima/pdfs/es/ft/71080/71080\\_ft.pdf](https://www.aemps.gob.es/cima/pdfs/es/ft/71080/71080_ft.pdf) [Accessed: August 13, 2017]

[40] Frati A, Ballester M, Dubernard G, Bats AS, Heitz D, Mathevet P, et al. Contribution of lymphoscintigraphy for sentinel lymph node biopsy in women with early stage endometrial cancer: Results of the SENTI-ENDO study. *Annals of Surgical Oncology*. 2015; **22**(6):1980-1986

[41] Resino MC, Sánchez Hermosa C, Lapeña G, Pardo C, Ruibal A, Medina C, et al. Linfogammagrafía prequirúrgica para la identificación del ganglio centinela en el cáncer de mama. *Revista*

Española de Medicina Nuclear. 2016; **22**(6):410-417

[42] Frumovitz M, Levenback CF. Lymphatic mapping and sentinel node biopsy in vulvar, vaginal and cervical cancers. *Oncology*. 2008;**22**(5):529-536

[43] Niikura H, Okamura C, Utsunomiya H, Yoshinaga K, Akahira J, Ito K, et al. Sentinel lymph node detection in patients with endometrial cancer. *Gynecologic Oncology*. 2004; **92**(2):669-674

[44] Mucientes Rasilla J, Farge Balbín L, Cardona Arboniés J, Moreno Elola-Olaso A, Delgado-Bolton R, Izarduy Pereyra L, et al. SPECT-TAC: Una nueva herramienta para la localización del ganglio centinela en pacientes con cáncer de mama. *Revista Española de Medicina Nuclear*. 2008;**27**(3):183-190

[45] Naaman Y, Pinkas L, Roitman S, Ikher S, Oustinov N, Vaisbuch E, et al. The added value of SPECT/CT in sentinel lymph nodes mapping for endometrial carcinoma. *Annals of Surgical Oncology*. 2016;**23**(2):450-455

[46] Buda A, Elisei F, Arosio M, Dolci C, Signorelli M, Perego P, et al. Integration of hybrid single-photon emission computed tomography/computed tomography in the preoperative assessment of sentinel node in patients with cervical and endometrial cancer: Our experience and literature review. *International Journal of Gynecological Cancer*. 2012;**22**(5):830-835

[47] Perissinotti A, Paredes P, Vidal-Sicart S, Torné A, Albela S, Navales I, et al. Use of SPECT/CT for improved sentinel lymph node localization in endometrial cancer. *Gynecologic Oncology*. 2013;**129**(1):42-48

[48] López-De la Manzanara Cano C, Cordero García JM, Martín-Francisco C, Sánchez Hidalgo L, Delgado Portela M, Haya Palazuelos J. Eficacia del Estadaje

Quirúrgico con Ganglio Centinela en el Carcinoma de Endometrio [Internet]. Comunicación Oral 31 Congreso Nacional de la Sociedad Española de Ginecología y Obstetricia, Sevilla-2011. Available from: [http://www.sego.es/Content/pdf/CONGRESO\\_SEVILLA\\_2011/COMUNICACIONES/ONCOLOGIA/Files04/4.pdf](http://www.sego.es/Content/pdf/CONGRESO_SEVILLA_2011/COMUNICACIONES/ONCOLOGIA/Files04/4.pdf) [Accessed: August 13, 2017]

[49] Abu-Rustum NR, Khoury-Collado F, Pandit-Taskar N, Soslow RA, Dao F, Sonoda Y, et al. Sentinel lymph node mapping for grade 1 endometrial cancer: Is it the answer to the surgical staging dilemma? *Gynecologic Oncology*. 2009; **113**(2):163-169

[50] Bogani G, Martinelli F, Ditto A, Signorelli M, Chiappa V, Recalcati D, et al. Sentinel lymph node detection in endometrial cancer: Does injection site make a difference? *Journal of Gynecologic Oncology*. 2016;**27**(2):e23

[51] Farzaneh F, Moridi A, Azizmohammadi Z, J MA, Hosseini MS, Arab M, et al. Value of sentinel lymph node (SLN) mapping and biopsy using combined intracervical radiotracers and blue dye injections for endometrial cancer. *Asian Pacific Journal of Cancer Prevention*. 2017;**18**(2):431-435

[52] Vidal F, Leguevaque P, Motton S, Delotte J, Ferron G, Querleu D, et al. Evaluation of the sentinel lymph node algorithm with blue dye labeling for early-stage endometrial cancer in a multicentric setting. *International Journal of Gynecological Cancer*. 2013; **23**(7):1237-1243

[53] Sinno AK, Fader AN, Roche KL, Giuntoli RL, Tanner EJ. A comparison of colorimetric versus fluorometric sentinel lymph node mapping during robotic surgery for endometrial cancer. *Gynecologic Oncology*. 2014;**134**(2): 281-286

[54] Methylene Blue 1% Aqueous, Safety Data Sheet [Internet]. LabChem—EE.



UU. Available from: <http://www.labchem.com/tools/msds/msds/LC16940.pdf>  
[Accessed: August 13, 2017]

[55] Darin MC, Gómez-Hidalgo NR, Westin SN, Soliman PT, Escobar PF, Frumovitz M, et al. Role of indocyanine green in sentinel node mapping in gynecologic cancer: Is fluorescence imaging the new standard? *Journal of Minimally Invasive Gynecology*. 2016; **23**(2):186-193

[56] Cibula D, Oonk MHM, Abu Rustum NR. Sentinel lymph node biopsy in the management of gynecologic cancer. *Current Opinion in Obstetrics & Gynecology*. 2015; **27**(1):66-72

[57] Rossi EC, Ivanova A, Boggess JF. Robotically assisted fluorescence-guided lymph node mapping with ICG for gynecologic malignancies: A feasibility study. *Gynecologic Oncology*. 2012; **124**(1):78-82

[58] Frangioni JV. In vivo near-infrared fluorescence imaging. *Current Opinion in Chemical Biology*. 2003; **7**(5):626-634

[59] Hope-Ross M, Yannuzzi L, Gragoudas E, Guyer D, Slakter J, Sorenson J, et al. Adverse reactions due to indocyanine green: A case report and a review of the literature. *Ophthalmology*. 1994; **101**(3):529-533

[60] Papadia A, Mohr S, Imboden S, Lanz S, Bolla D, Mueller MD. Laparoscopic Indocyanine green sentinel lymph node mapping in pregnant cervical cancer patients. *Journal of Minimally Invasive Gynecology*. 2016; **23**(2):270-273

[61] Jewell EL, Huang JJ, Abu-Rustum NR, Gardner GJ, Brown CL, Sonoda Y, et al. Detection of sentinel lymph nodes in minimally invasive surgery using indocyanine green and near-infrared fluorescence imaging for uterine and cervical malignancies. *Gynecologic Oncology*. 2014; **133**(2):274-277

[62] Holloway RW, Bravo RAM, Rakowski JA, James JA, Jeppson CN, Ingersoll SB, et al. Detection of sentinel lymph nodes in patients with endometrial cancer undergoing robotic-assisted staging: A comparison of colorimetric and fluorescence imaging. *Gynecologic Oncology*. 2012; **126**(1): 25-29

[63] Surynt E, Reinholz-Jaskolska M, Bidzinski M. Laparoscopic sentinel lymph node mapping after cervical injection of indocyanine green for endometrial cancer—Preliminary report. *Videosurgery and Other Miniinvasive Techniques*. 2015; **10**(3):406-412

[64] Eriksson AG, Beavis A, Soslow RA, Zhou Q, Abu-Rustum NR, Gardner GJ, et al. A comparison of the detection of sentinel lymph nodes using indocyanine green and near-infrared fluorescence imaging versus blue dye during robotic surgery in uterine cancer. *International Journal of Gynecological Cancer*. 2017; **27**(4):743-747

[65] How J, Gotlieb WH, Press JZ, Abitbol J, Pelmus M, Ferenczy A, et al. Comparing indocyanine green, technetium, and blue dye for sentinel lymph node mapping in endometrial cancer. *Gynecologic Oncology*. 2015; **137**(3):436-442

[66] Papadia A, Zapardiel I, Bussi B, Ghezzi F, Ceccaroni M, De Ponti E, et al. Sentinel lymph node mapping in patients with stage I endometrial carcinoma: A focus on bilateral mapping identification by comparing radiotracer Tc99m with blue dye versus indocyanine green fluorescent dye. *Journal of Cancer Research and Clinical Oncology*. 2016; **143**(3):475-480

[67] Laios A, Volpi D, Tullis IDC, Woodward M, Kennedy S, Pathiraja PNJ, et al. A prospective pilot study of detection of sentinel lymph nodes in gynaecological cancers using a novel near infrared fluorescence



imaging system. *BMC Research Notes*. 2015;**8**:608

[68] Buda A, Passoni P, Corrado G, Bussi B, Cutillo G, Magni S, et al. Near-infrared fluorescence-guided sentinel node mapping of the ovary with Indocyanine green in a minimally invasive setting: A feasible study. *Journal of Minimally Invasive Gynecology*. 2017;**24**(1):165-170

[69] Ruscito I, Gasparri ML, Braicu EI, Bellati F, Raio L, Sehouli J, et al. Sentinel node mapping in cervical and endometrial cancer: Indocyanine green versus other conventional dyes—A meta-analysis. *Annals of Surgical Oncology*. 2016;**23**(11):3749-3756

[70] Buda A, Crivellaro C, Elisei F, Di Martino G, Guerra L, De Ponti E, et al. Impact of indocyanine green for sentinel lymph node mapping in early stage endometrial and cervical cancer: Comparison with conventional radiotracer (99m) Tc and/or blue dye. *Annals of Surgical Oncology*. 2015; **23**(7):2183-2191

[71] Lopez Labrousse MI, Frumovitz M, Guadalupe Patrono M, Ramirez PT. Sentinel lymph node mapping in minimally invasive surgery: Role of imaging with color-segmented fluorescence (CSF). *Gynecologic Oncology*. 2017;**146**(3):676-677

[72] Lin H, Ding Z, Kota VG, Zhang X, Zhou J. Sentinel lymph node mapping in endometrial cancer: A systematic review and meta-analysis. *Oncotarget*. 2017; **8**(28):46601-46610

[73] Guillén-Paredes MP, Carrasco-González L, Chávez-Benito A, Aguayo-Albasini JL. Aplicación de la técnica OSNA en el análisis intraoperatorio del ganglio centinela en el cáncer de mama. *Cirugía Española*. 2011;**89**(4):261-262

[74] Rossi EC, Kowalski LD, Scalici J, Cantrell L, Schuler K, Hanna RK, et al. A

comparison of sentinel lymph node biopsy to lymphadenectomy for endometrial cancer staging (FIRES trial): A multicentre, prospective, cohort study. *The Lancet Oncology*. 2017;**2045**(17):1-9

[75] Kim CH, Khoury-Collado F, Barber EL, Soslow RA, Makker V, Leitao MM, et al. Sentinel lymph node mapping with pathologic ultrastaging: A valuable tool for assessing nodal metastasis in low-grade endometrial cancer with superficial myoinvasion. *Gynecologic Oncology*. 2013;**131**(3): 714-719

[76] Ballester M, Dubernard G, Bats A-S, Heitz D, Mathevet P, Marret H, et al. Comparison of diagnostic accuracy of frozen section with imprint cytology for intraoperative examination of sentinel lymph node in early-stage endometrial cancer: Results of senti-endo study. *Annals of Surgical Oncology*. 2012; **19**(11):3515-3521

[77] Touhami O, Trinh X-B, Gregoire J, Sebastianelli A, Renaud M-C, Grondin K, et al. Predictors of non-sentinel lymph node (non-SLN) metastasis in patients with sentinel lymph node (SLN) metastasis in endometrial cancer. *Gynecologic Oncology*. 2015;**138**(1):41-45

[78] Khoury-Collado F, Murray MP, Hensley ML, Sonoda Y, Alektiar KM, Levine DA, et al. Sentinel lymph node mapping for endometrial cancer improves the detection of metastatic disease to regional lymph nodes. *Gynecologic Oncology*. 2011;**122**(2): 251-254

[79] Altgassen C, Müller N, Hornemann A, Kavallaris A, Hornung D, Diedrich K, et al. Immunohistochemical workup of sentinel nodes in endometrial cancer improves diagnostic accuracy. *Gynecologic Oncology*. 2009;**114**(2): 284-287

- [80] Euscher E, Sui D, Soliman P, Westin S, Ramalingam P, Bassett R, et al. Ultrastaging of sentinel lymph nodes in endometrial carcinoma according to use of 2 different methods. *International Journal of Gynecological Pathology*. 2017;**2**:1-10
- [81] Kim CH, Soslow RA, Park KJ, Barber EL, Khoury-Collado F, Barlin JN, et al. Pathologic ultrastaging improves micrometastasis detection in sentinel lymph nodes during endometrial cancer staging. *International Journal of Gynecological Cancer*. 2013;**23**(5): 964-970
- [82] Holloway RW, Gupta S, Stavitzski NM, Zhu X, Takimoto EL, Gubbi A, et al. Sentinel lymph node mapping with staging lymphadenectomy for patients with endometrial cancer increases the detection of metastasis. *Gynecologic Oncology*. 2016;**141**(2):206-210
- [83] Stewart CJR, Crook ML, Lacey J, Louwen K. Cytokeratin 19 expression in normal endometrium and in low-grade endometrioid adenocarcinoma of the endometrium. *International Journal of Gynecological Pathology*. 2011;**30**: 484-491
- [84] Nagai T, Niikura H, Okamoto S, Nakabayashi K, Matoda M, Utsunomiya H, et al. A new diagnostic method for rapid detection of lymph node metastases using a one-step nucleic acid amplification (OSNA) assay in endometrial cancer. *Annals of Surgical Oncology*. 2015;**22**(3):980-986
- [85] López-Ruiz ME, Diestro MD, Yébenes L, Berjón A, Díaz de la Noval B, Mendiola M, et al. One-step nucleic acid amplification (OSNA) for the detection of sentinel lymph node metastasis in endometrial cancer. *Gynecologic Oncology*. 2016;**143**(1):54-59
- [86] Amoroso V, Generali D, Buchholz T, Cristofanilli M, Pedersini R, Curigliano G, et al. International expert consensus on primary systemic therapy in the management of early breast cancer: Highlights of the Fifth Symposium on Primary Systemic Therapy in the Management of Operable Breast Cancer, Cremona, Italy (2013). *Journal of the National Cancer Institute. Monographs*. 2015;**2015**(51): 90-96
- [87] Raimond E, Ballester M, Hudry D, Bendifallah S, Daraï E, Graesslin O, et al. Impact of sentinel lymph node biopsy on the therapeutic management of early-stage endometrial cancer: Results of a retrospective multicenter study. *Gynecologic Oncology*. 2014;**133**(3): 506-511
- [88] Hagen B, Valla M, Aune G, Ravlo M, Abusland AB, Araya E, et al. Indocyanine green fluorescence imaging of lymph nodes during robotic-assisted laparoscopic operation for endometrial cancer. A prospective validation study using a sentinel lymph node surgical algorithm. *Gynecologic Oncology*. 2016; **143**(3):479-483
- [89] Desai P, Hughes P, Graebe K, Tchabo N, Heller P, Tobias D, Slomovitz B. Robotic Sentinel Lymph Node Detection (RSLD) for Patients with Endometrial Cancer (EC) [Internet]. ESGO eAcademy. 2013. p. 38305. Available from: <https://eacademy.esgo.org/esgo/2013/18th/38305/brian.slomovitz.robotic.sentinel.lymph.node.detection.28rsld29.for.patients.html?f=m2> [Accessed: August 13, 2017]
- [90] Ojima T, Kinami S, Nakamura K, Oyama K, Inokuchi M, Fujita H, et al. Advantages of the rapid double-staining method for intraoperative detection of micrometastasis in sentinel lymph nodes. *Oncology Reports*. 2013;**30**(3): 1067-1072
- [91] Bernet L, Piñero A, Vidal-Sicart S, Peg V, Giménez J, Algara M, et al. Consenso sobre la biopsia selectiva del

ganglio centinela en el cáncer de mama. Revisión 2013 de la Sociedad Española de Senología y Patología Mamaria. *Revista de Senología y Patología Mamaria*. 2014;**27**(1):43-53

[92] Yabushita H, Shimazu M, Yamada H, Sawaguchi K, Noguchi M, Nakanishi M, et al. Occult lymph node metastases detected by cytokeratin immunohistochemistry predict recurrence in node-negative endometrial cancer. *Gynecologic Oncology*. 2001;**80**(2):139-144

[93] RD-100 OSNA, Folleto Informativo [Internet]. Sysmex España S.L. Available at: [https://www.sysmex.es/fileadmin/media/f117/OSNA/OSNA\\_RD-100i\\_6p\\_ES.pdf](https://www.sysmex.es/fileadmin/media/f117/OSNA/OSNA_RD-100i_6p_ES.pdf) [Accessed: August 13, 2017]

[94] Vegué LB, Rojo F, Hardisson D, Iturriagagoitia AC, Panadés MJ, Velasco A, et al. Comparison of molecular analysis and histopathology for axillary lymph node staging in primary breast cancer: Results of the B-CLOSER-I study. *Diagnostic Molecular Pathology*. 2012;**21**(2):69-76

[95] Colombo N, Creutzberg C, Amant F, Bosse T, González-Martín A, Ledermann J, et al. ESMO-ESGO-ESTRO consensus conference on endometrial cancer: Diagnosis, treatment and follow-up. *International Journal of Gynecological Cancer*. 2016;**26**(1):2-30

[96] Weaver DL, Krag DN, Manna EA, Ashikaga T, Harlow SP, Bauer KD. Comparison of pathologist-detected and automated computer-assisted image analysis detected sentinel lymph node micrometastases in breast cancer. *Modern Pathology*. 2003;**16**(11):1159-1163

[97] Todo Y, Suzuki Y, Azuma M, Hatanaka Y, Konno Y, Watari H, et al. Ultrastaging of para-aortic lymph nodes in stage IIIC1 endometrial cancer: A

preliminary report. *Gynecologic Oncology*. 2012;**127**(3):532-537

[98] Morice P, Leary A, Creutzberg C, Abu-Rustum N, Darai E. Endometrial cancer. *Lancet*. 2016;**387**(10023):1094-1108

[99] Bats A, Clément D, Larousserie F, Le Frère-Belda M, Pierquet-Ghazzar N, Hignette C, et al. Does sentinel node biopsy improve the management of endometrial cancer? Data from 43 patients. *Journal of Surgical Oncology*. 2008;**97**(2):141-145

[100] Plante M, Stanleigh J, Renaud M-C, Sebastianelli A, Grondin K, Grégoire J. Isolated tumor cells identified by sentinel lymph node mapping in endometrial cancer: Does adjuvant treatment matter? *Gynecologic Oncology*. 2017;**146**(2):240-246

[101] Eriksson AGZ, Ducie J, Ali N, McGree ME, Weaver AL, Bogani G, et al. Comparison of a sentinel lymph node and a selective lymphadenectomy algorithm in patients with endometrioid endometrial carcinoma and limited myometrial invasion. *Gynecologic Oncology*. 2016;**140**(3):394-399

[102] Erkanli S, Bolat F, Seydaoglu G. Detection and importance of micrometastases in histologically negative lymph nodes in endometrial carcinoma. *European Journal of Gynaecological Oncology*. 2011;**32**(6):619-625

[103] Todo Y, Kato H, Okamoto K, Minobe S, Yamashiro K, Sakuragi N. Isolated tumor cells and micrometastases in regional lymph nodes in FIGO stage I to II endometrial cancer. *Journal of Gynecologic Oncology*. 2016;**27**(1):e1

[104] Ballester M, Dubernard G, Lécuru F, Heitz D, Mathevet P, Marret H, et al. Detection rate and diagnostic accuracy of sentinel-node



- biopsy in early stage endometrial cancer: A prospective multicentre study (SENTI-ENDO). *The Lancet Oncology*. 2011;**12**(5):469-476
- [105] How J, Lau S, Press J, Ferenczy A, Pelmus M, Stern J, et al. Accuracy of sentinel lymph node detection following intra-operative cervical injection for endometrial cancer: A prospective study. *Gynecologic Oncology*. 2012; **127**(2):332-337
- [106] Ehrisman J, Secord AA, Berchuck A, Lee PS, Di Santo N, Lopez-Acevedo M, et al. Performance of sentinel lymph node biopsy in high-risk endometrial cancer. *Gynecologic Oncology Reports*. 2016;**17**:69-71
- [107] Soliman PT, Westin SN, Dioun S, Sun CC, Euscher E, Munsell MF, et al. A prospective validation study of sentinel lymph node mapping for high-risk endometrial cancer. *Gynecologic Oncology*. 2017;**146**(2):234-239
- [108] St Clair CM, Eriksson AGZ, Ducie JA, Jewell EL, Alektiar KM, Hensley ML, et al. Low-volume lymph node metastasis discovered during sentinel lymph node mapping for endometrial carcinoma. *Annals of Surgical Oncology*. 2015;**23**(5):1653-1659
- [109] Jewell E. Chapter 76: Lymphadenectomy for endometrial cancer: Pro. In: *ESGO Textbook of Gynaecological Oncology*. Ankara, Turquía: Güneş, Publishing; 2016. pp. 660-664
- [110] Panici PB, Basile S, Maneschi F, Lissoni AA, Signorelli M, Scambia G, et al. Systematic pelvic lymphadenectomy vs no lymphadenectomy in early-stage endometrial carcinoma: Randomized clinical trial. *Journal of the National Cancer Institute*. 2008;**100**(23):1707-1716
- [111] Uccella S, Podratz KC, Aletti GD, Mariani A. Re: Systematic pelvic lymphadenectomy vs no lymphadenectomy in early-stage endometrial carcinoma: Randomized clinical trial. *JNCI: Journal of the National Cancer Institute*. 2009;**101**(12): 897-898
- [112] ASTEC Study Group, Kitchener H, Swart A, Qian Q, Amos C, Parmar M. Efficacy of systematic pelvic lymphadenectomy in endometrial cancer (MRC ASTEC trial): A randomised study. *Lancet*. 2010; **373**(9658):125-136
- [113] Todo Y, Kato H, Kaneuchi M, Watari H, Takeda M, Sakuragi N. Survival effect of Para-aortic lymphadenectomy in endometrial cancer (SEPAL study): A retrospective cohort analysis. *Lancet*. 2010;**375**(9721): 1165-1172
- [114] Kim HS, Suh DH, Kim M-K, Chung HH, Park NH, Song YS. Systematic lymphadenectomy for survival in patients with endometrial cancer: A meta-analysis. *Japanese Journal of Clinical Oncology*. 2012; **42**(5):405-412
- [115] Bendifallah S, Genin AS, Naoura I, Chabbert Buffet N, Clavel Chapelon F, Haddad B, et al. A nomogram for predicting lymph node metastasis of presumed stage I and II endometrial cancer. *American Journal of Obstetrics and Gynecology*. 2012;**207**(3):197.e1-197.e8
- [116] Naoura I, Canlorbe G, Bendifallah S, Ballester M, Daraï E. Relevance of sentinel lymph node procedure for patients with high-risk endometrial cancer. *Gynecologic Oncology*. 2015;**136**(1):60-64
- [117] Mayoral M, Paredes P, Domènech B, Fusté P, Vidal-Sicart S, Tapias A, et al. 18F-FDG PET/CT and sentinel lymph node biopsy in the staging of patients with cervical and endometrial cancer. Role of dual-time-point imaging. *Revista Española de*



Medicina Nuclear e Imagen Molecular.  
2016;**36**(1):20-26

[118] Papadia A, Imboden S,  
Gasparri ML, Siegenthaler F, Fink A,  
Mueller MD. Endometrial and cervical  
cancer patients with multiple sentinel  
lymph nodes at laparoscopic ICG  
mapping: How many are enough?  
Journal of Cancer Research and Clinical  
Oncology. 2016;**142**(8):1831-1836

[119] Lyman GH, Giuliano AE,  
Sommerfield MR, Benson AB,  
Bodurka DC, Burstein HJ, et al.  
American Society of Clinical Oncology  
Guideline recommendations for sentinel  
lymph node biopsy in early-stage breast  
cancer. Journal of Clinical Oncology.  
2005;**23**(30):7703-7720

[120] Buda A, Guerra L, Signorelli M.  
Regarding: Pathologic ultrastaging  
improves micrometastasis detection in  
sentinel lymph nodes during  
endometrial cancer staging.  
International Journal of Gynecological  
Cancer. 2014;**24**(6):964-965