

We are IntechOpen, the world's leading publisher of Open Access books Built by scientists, for scientists

4,800

Open access books available

122,000

International authors and editors

135M

Downloads

Our authors are among the

154

Countries delivered to

TOP 1%

most cited scientists

12.2%

Contributors from top 500 universities



WEB OF SCIENCE™

Selection of our books indexed in the Book Citation Index
in Web of Science™ Core Collection (BKCI)

Interested in publishing with us?
Contact book.department@intechopen.com

Numbers displayed above are based on latest data collected.
For more information visit www.intechopen.com



Chapter

Living with a Severe Spinal Deformity: An Innovative and Personal Patient Account of Self-Management Using a Corset, Postural Correction, and Exercises

Andrej Gogala

Abstract

Conservative treatment of scoliosis using brace and exercises usually ends when growth stops. Scoliosis may, however, deteriorate in adulthood especially when curves are larger. The author decided to try to help himself when he was 43 years old. He had been diagnosed with juvenile idiopathic scoliosis when he was 7 years old, but his treatment with a Milwaukee brace ended when he was 11 years old. When his growth ended, the author had a severe scoliosis with a thoracic curve of around 100° Cobb. In adulthood, a corset from fabric with steel reinforcements was used for part of the day intermittently which also included days without wear. To derotate the rib cage, pressure to the rib hump was applied from behind. After some years it was obvious from photo documentation that some derotation had been achieved. The rib hump is smaller; ribs can now be seen on the concave side where they were not seen previously, and a skin mark which was located laterally before moved to the front side. Curves to the side as seen in anteroposterior X-ray images, however, did not improve. But the therapy proved helpful as marked cosmetic improvement was achieved and curve increase was most likely prevented.

Keywords: self-management, conservative treatment, juvenile idiopathic scoliosis, adult with scoliosis, derotation

1. Introduction

In the human being, the spine is curved in the form of two S letters because of upright posture, if seen from the side. It is bent back in the thorax and sacrum and forward in the lumbar and neck regions. If you look from behind, the spine is usually straight when the body is upright. This is true for most healthy people, but asymmetric growth in children can lead to bending of the spine in a sideways manner. This state or condition is called scoliosis [1–4]. The name is of Greek origin, meaning curvature, and was already used by Hippocrates centuries ago [5]. Galen narrowed the meaning to a sideways curvature. Most often and seen from the back,

the backbone is curved to the right in the thoracic spine and to the left in the lumbar part. Vertebrae are also twisted, turned in their axis, causing a rib hump to develop in the back [1–4].

Guidelines of the SOSORT Society for the treatment of idiopathic scoliosis from 2011 [1] and 2016 [2] indicate that the goal of conservative treatment is to halt curve progression at puberty (or possibly even reduce it). Bracing is recommended to treat patients with curves above $20 \pm 5^\circ$ Cobb which are still growing. It is recommended that braces should be worn until the end of vertebral bone growth.

Weinstein et al. [6] recently found that wearing a brace prevents curve progression in people with adolescent idiopathic scoliosis, if it is worn for up to at least 13 h a day. Results are better, however, when the brace is worn over a longer time. 90% of children who wore a brace for at least 13 h a day reached the end of the growth period without the need for surgery. Further Aulisa et al. [7] reported that the brace is also very effective in the treatment of juvenile scoliosis. Curve correction was accomplished in 79% of patients, the curve stabilized in 16%, and only in 6% of children did it progress. Juvenile scoliosis starts at the age of 3–9 years and can lead to larger curvatures than adolescent scoliosis which starts between 10 and 17 years of age [1]. Lusini et al. [8] further found that wearing a brace can reduce the curvature even in patients with curve magnitudes over 45° Cobb, who had refused to have surgery.

After maturity, most adult patients are left without any prescribed therapy. But their scoliosis may worsen over time. Usually the curvature progresses slowly also in adulthood. The linear rate of progression is about 1° Cobb per year, and this has been demonstrated to occur in progressive adult scoliosis [9]. Curves larger than 50° are associated with a high risk of continued deterioration or progression throughout adulthood and thus usually indicate the need for surgery [6].

Scoliosis fusion surgery is generally considered the only means to stop the progression of the spinal deformity in patients with adult idiopathic scoliosis. However, when patients with adult scoliosis progress, scoliosis-specific exercises can be effective in order to obtain stability and in some cases to reduce the Cobb angles in degrees. In highly progressive curves, exercises appear to slow down the progression of the curvature [10]. Using traction and massage, Brooks et al. [11] were able to improve chest expansion and decrease thoracic curvature in an adult with idiopathic scoliosis. Negrini et al. [12] hypothesized that the improvement of adult scoliosis that was achieved by one of their patients is a consequence of recovery from a postural collapse without any changes in bone structure. The structural bony component of scoliosis cannot be improved with a cast or other corrective measures and can be seen in a radiograph of a person in the correction with a cast or a brace. The postural collapse component of scoliosis can be seen as the difference between the curvature on a radiograph taken while standing and the one taken while lying down.

For adult patients with late-onset idiopathic scoliosis, cosmetic concerns and pain are the main reasons for seeking treatment. Daily exercise and part-time bracing can also potentially reduce pain in the adult scoliosis population [13].

Rigid braces for the treatment of scoliosis were first used by Ambroise Paré (1510–1590). They were made out of metal. Among other things, he wrote that bracing does not help when the skeleton matures and growth stops [14]. This assertion has rarely been contradicted in the literature and is considered the “truth” up to this day. Brodhurst [15] describes and provides figures of a fairly successful treatment of an 18-year-old girl with his supporting device, which was the precursor of today’s rigid braces and acted in the same way. It put pressure on the convex side of the curve and lifted the shoulder in the concave side, just like a modern

Chêneau brace made of plastic. His instrument (**Figure 1**), as he called it, consisted of a frame made out of a pelvic hoop, upright crutches, and connecting dorsal band placed at the superior extremity of the primary curve. The shoulder sling or loop was placed on the shoulder which corresponded to the concavity of the primary curve and was connected to the lever. The convexity of the primary curve was supported by a large pad. The effectiveness of a combination of Schroth and SEAS exercises together with wearing a brace in adult patients with scoliosis was reported by Papadopoulos [16].

My scoliosis was discovered when I was around 7 years of age when I was treated with a Milwaukee brace in the orthopedic hospital in Valdoltra. But when I was 11 years old, I experienced acute renal failure. The inflammation that followed left lasting effects on my kidneys, and since 1978 when I was 16 years old, I had to attend hemodialysis regularly. As this was a life-threatening condition, my parents decided to stop the therapy of scoliosis which unfortunately was left unmanaged since then. For a few years, I still grew and unfortunately over the years the back curvature increased.

In 2005 I decided to finally do something about my scoliosis. I was 43 years old at that time, and the predominant view was that after growth is completed, the correction of scoliosis without surgery is no longer possible. The risk of complications in surgery in adults is very high, and long-term effects are questionable [17]. So I decided to take action by my own method.

From the archives of the Department of Dialysis of the Ljubljana Medical Centre, I got X-ray images showing my spine. I was able to measure Cobb angles, which are used to measure the curvature and to estimate the severity of deformation. In the images from the years 1997 and 2005, only the thoracic curvature is seen which is equal in both images, so it did not deteriorate over this time period before the



Figure 1.
Brodhurst's instrument for the treatment of scoliosis (Brodhurst, 1855).

treatment. The image from 2010 shows both curves. The upper thoracic curve is larger and measures 104° , while the lower lumbar measures 57° . Curves over 60° are considered a very severe form of scoliosis, and in curves over 80° , it affects lung function which is impaired. The vital capacity of my lungs measured 1380 ml in 2010, a value which is only 40% of the value that is estimated for a man without scoliosis, for my height.

Early-onset scoliosis like mine can result in larger curves than more common adolescent scoliosis because the unbalanced growth of the spine lasts longer. If untreated, juvenile scoliosis can cause serious cardiopulmonary complications and premature death [18]. In comparison untreated late-onset scoliosis causes little physical impairment other than back pain and cosmetic concerns [19]. The prognosis for most patients with more than 100° curvature of the spine is generally death in their 40s or 50s due to respiratory or heart failure, although there are exceptions to this [20].

2. The therapy

I found that my spine is not bent forward in the lumbar area as found in the lordosis of a person without scoliosis. It was only bent sideways. I assumed that the sideways curvature would diminish, if I managed to bend the spine forward, as is correct. I thought that this would also have a beneficial impact on the higher parts of the spine. I decided to buy an elastic bodice from a shop that sold medical equipment. I then stitched longitudinal metal braces to it, which I twisted to the form of my own body. The one that crossed the hump had to be bent almost at right angles to fit. With this corset I then carried out my activities of daily living; I also slept in it and went for walks in the bodice. Three months later, in the spring of 2006, I ordered an underbust corset of the waist cincher type on the Internet, otherwise used by ladies to constrict their waists (Axfords C225, the firm ceased trading since). It forced me into an upright posture and created a lumbar lordosis. I had to take it off before lunch so I could eat, but then I put it on again before I go to sleep. After some months I ordered a longer underbust corset, which grasped the pelvis and ribs better, but since it was not custom made, it did not fit perfectly (Axfords C229). When I received it by post, my mother showed me hers that was very similar, only it was laced by the side, not the rear. She had scoliosis at a young age too, and in that time (the 1950s) scoliosis was treated with corsets made from fabric, like the one I was using. I walked a lot wearing the corset, also in the mountains.

Flat back often accompanies scoliosis [1]. It has the same shortcomings as a flat foot, so it does not allow much flexibility. The spine should ideally be slightly curved, so the creation of a correct lordosis is very important. When the spine is curved in the sagittal plane, curves to the sides may be reduced [21]. In people without a lordotic curve, the head is not positioned above the pelvis, but in front of it. The center of gravity outside the body axis then causes overload of the back muscles causing pain.

When I lost hope that I would achieve anything with the corset that I had used for a couple of years, I then stopped wearing it. After a few days, however, I was surprised to find that there has been an improvement. Thus it was necessary to interrupt my treatment with the corset. I found that I needed a corset that would stretch all the way from the armpits to the pelvis and press the hump in order to reduce it. It needed to be custom made, and I found a website where I could order an overbust corset (reaching above the bust), made to my measures without too much additional charge (Corsetcurves Venus, the website does not exist anymore).

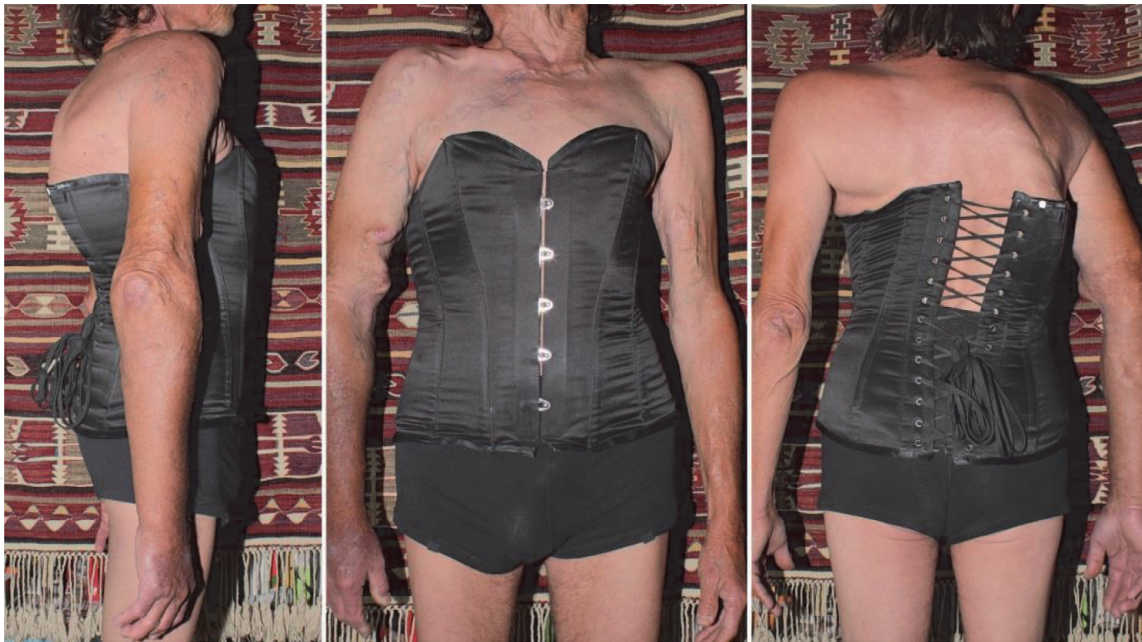

Figure 2.
Overbust corset used from September 2008 to October 2016. View from the side, front, and rear in July 2011.



Figure 3.
Extending to and hanging with the left hand on barely accessible holds has proven to be the most effective exercise for stretching the spine. If a right convex scoliosis is caused by the predominant use of the right hand, it may possibly be improved by the frequent use of the left hand in normal work and exercise.

It fitted me much better, but behind the hump it lay sideways; this was inevitable due to my rib hump (**Figure 2**). It was made from three layers of fabric with steel reinforcements. I wore it from September 2008 to October 2016.

To successfully derotate my chest, I used additional manipulation and physiotherapy. I pressed on the hump from behind and stretched muscles on the concave side by improvements and overcorrections of my posture. My walks with a backpack in nature were not intended to be part of the therapy; they were part of my job as a biologist, but they proved to be just that: therapy. The straps were forcing my shoulders to be at the same height when wearing a backpack with photo camera equipment. I also found that correcting my posture many times during the day was also very important as this eliminated any unbalanced loading of my skeleton [3]. I added occasional pressure to the hump from behind. This is similar to the treatment recommended also when applying plaster cast as an effective treatment for scoliosis in young children [22]. In order to stretch the spine and reduce side curvature, I also included stretching exercises for the left side of the body into the therapy in 2013. With my left hand, I pushed at the hip while standing or at the thigh while sitting and stretched the left side. I lifted the body with my hands holding the handles of a chair, and the spine stretched due to gravity. With my left hand, I stretched out to reach a shelf above the door. The last exercise in particular has proven to be effective, since the hump reduced during the exercise and the spine straightened significantly (**Figure 3**).

3. Results

3.1 July 2011 until January 2012

From July 2011 to January 2012, I continued to alternate the days when I wore the corset and days when I did not as I found this to be more effective than continuous wear as far as derotation was concerned. The corset improved the position of the ribs and arched my back, but it could not decrease the vertebral rotation and therefore did not reduce the hump immediately. But after I have taken off the corset, by pressing the hump from behind against the floor when lying or against the backrest when sitting and with contractions of the back muscles, I could decrease the hump slightly, moving the vertebrae slightly toward the correct position.

The comparison of images taken in July 2011 and January 2012 documents a substantial improvement. In side view from July, the hump was of a semicircular shape and at a right angle to back. The skin of the chest and abdomen in the front was loose and wrinkled as it was not supported by the ribs. On 10 January 2012, the back was evenly narrowing toward the waist in side view. At the front, the ribs supported the skin of the chest and abdomen. A skin mark which was located laterally in the earlier image moved to the front (**Figure 4**).

3.2 March 2012

I photographed myself again on 23 March 2012. The view from the rear, in comparison with the image taken in January, showed improvement on the left concave side where previously the ribs were hidden as they were shifted forward because of the rotation of the spine and chest (**Figure 5**).

If a line is drawn from the extremity of the curve to its upper and lower end, and the angle measured that is formed by these lines, we find that the angle was 140° in January and 150° in March: the apparent curve on the surface was reduced. In an upright spine, this angle would measure 180° ; a smaller angle thus means a larger

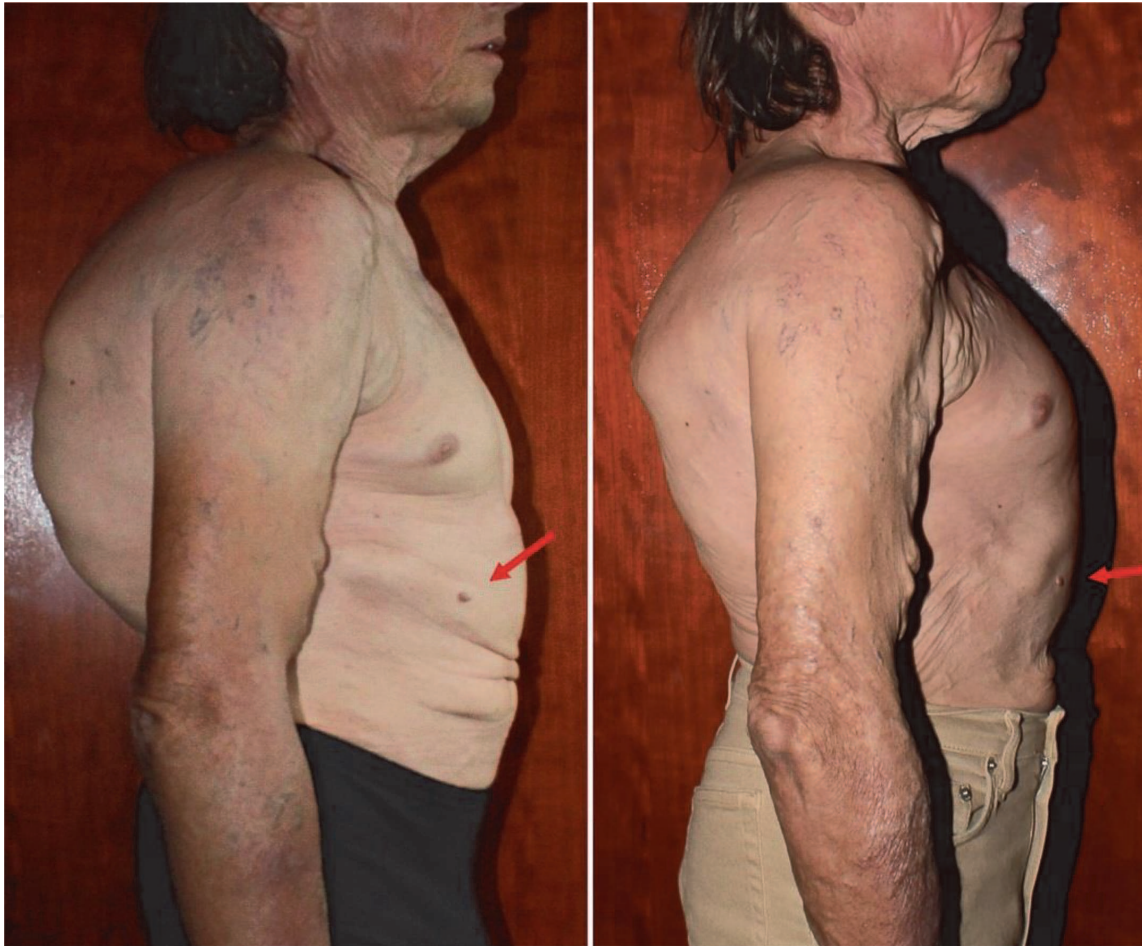

Figure 4.
The left image was taken on 1 July 2011. The hump is of a semicircular shape and connects with the back at a right angle. The skin of the chest and abdomen at the front is loose and wrinkled, because it is not supported by the ribs. The right view was created on 10 January 2012. The difference is obvious. From the side the blade down the back is evenly narrowing toward the waist. At the front, the ribs support the chest and skin of the abdomen. A skin mark (pointed by the arrows), located laterally in July 2011, moved to the front side in January 2012.

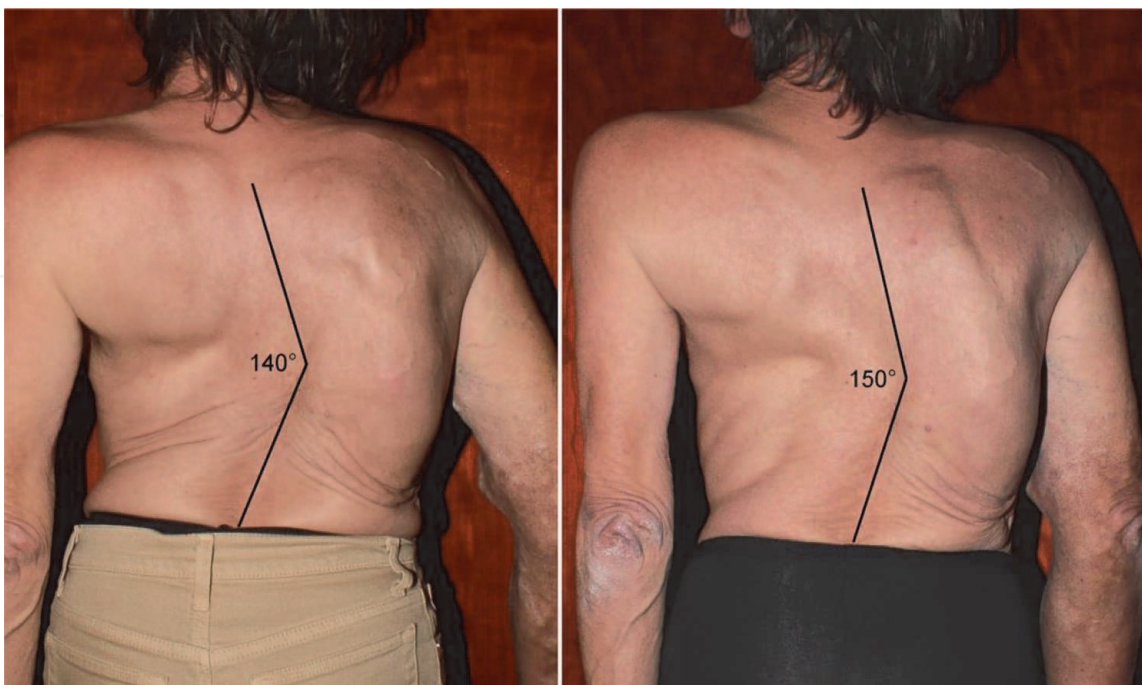


Figure 5.
Comparison of the back, photographed in January 2012 (left) and March 2012 (right). The apparent curve has been reduced in March, and on the left side of the body we see the ribs, which were not seen in January (left) as they were shifted forward because of rotation of the spine in its axis. We can only see the wrinkled skin in the place of ribs seen in the march image.

curvature. Digital photographs can be taken without limitations as the body is not exposed to radiation like in X-ray imaging. To measure the angles, the lines from the photos were transferred to a picture of a protractor in the Adobe Photoshop program. The apparent curve on the surface does not correspond with the curvature of the spine, however. It is just a simple indicator used in monitoring the development of the curve and is dependent of several factors. As proven in my case, it was an indicator of the degree of rotation.

In side view, in comparison with January, the hump seemed to have increased again at first sight. But a closer examination revealed that the scapula, which was previously raised by the hump, was lowered. The ribs, which previously had raised it, formed the curve of the hump. But the chest and abdomen at the front were supported well and were not loose, as they have been in July 2011. This means that the derotation, achieved between July 2011 and January 2012, was preserved.

3.3 April 2012

To find out the cause for a benefit of alternating days when wearing a corset or not, I wore the corset for 5 days in a row during the day and then had my back photographed on 6 April 2012. I found that in lateral view, the hump was reduced and the scapula was lifted. The view from behind showed that the apparent curve sideways measured 144° . Thus, it was more pronounced than in the previous image taken on 27 March 2012 (151°). The next day, the curve measured 151° again. I found that the corset could therefore temporarily increase rotation, but this was rapidly corrected when corset wear was interrupted. The chest easily rotates to a certain degree when the corset is tightened too much because of pressure to the ribs, diminishing the circumference of the chest. Then it derotates again when the corset is taken off. When this happens often, therapy should be discontinued for a longer time to allow ligaments to stiffen and prevent rotation. Care must also be taken not to tighten the corset too much.

3.4 June 2012

The apparent curvature (rotation) diminished over time during the therapy. The exceptional case of the 6th of April cannot be considered because it was not documented under the same conditions. On 10 January 2012, the curve was 140° ; 23rd of March, 150° ; 27th of March, 151° ; and 14th of April, 154° . If a graph is drawn on these data points, a straight line can be drawn through. However, on the 4th and 22nd of May and on the 9th of June 2012, the curve remained the same as in the 14th of April. The limits of any possible derotation had probably been reached.

The imaging on the 9th of June 2012 showed an important change from the previous state, however. My pelvis was no longer tilted as much as before, and the analysis of the photographs showed a significant difference. The pelvic obliquity may be the consequence of unequal leg length, but the pelvis could also be shifted due to rotation in the lumbar part of the spine that is present in scoliosis. Scoliosis can develop because of pelvic obliquity, but scoliosis also causes or increases pelvic tilt. It is difficult to determine what occurred first. I linked the iliac crests on the photos with a line and drew a line along the middle of the body (**Figure 6**). Then I measured the angle between these lines. It would measure 90° if the pelvis was not inclined as in a healthy person. In me, the angle at the right side of my body measured 96° on 4 May 2012, but only 92.5° on June 9. A mistake due to changes in posture was possible, so I waited for the imaging of June 22. The angle was the same, so the pelvic tilt was actually reduced.

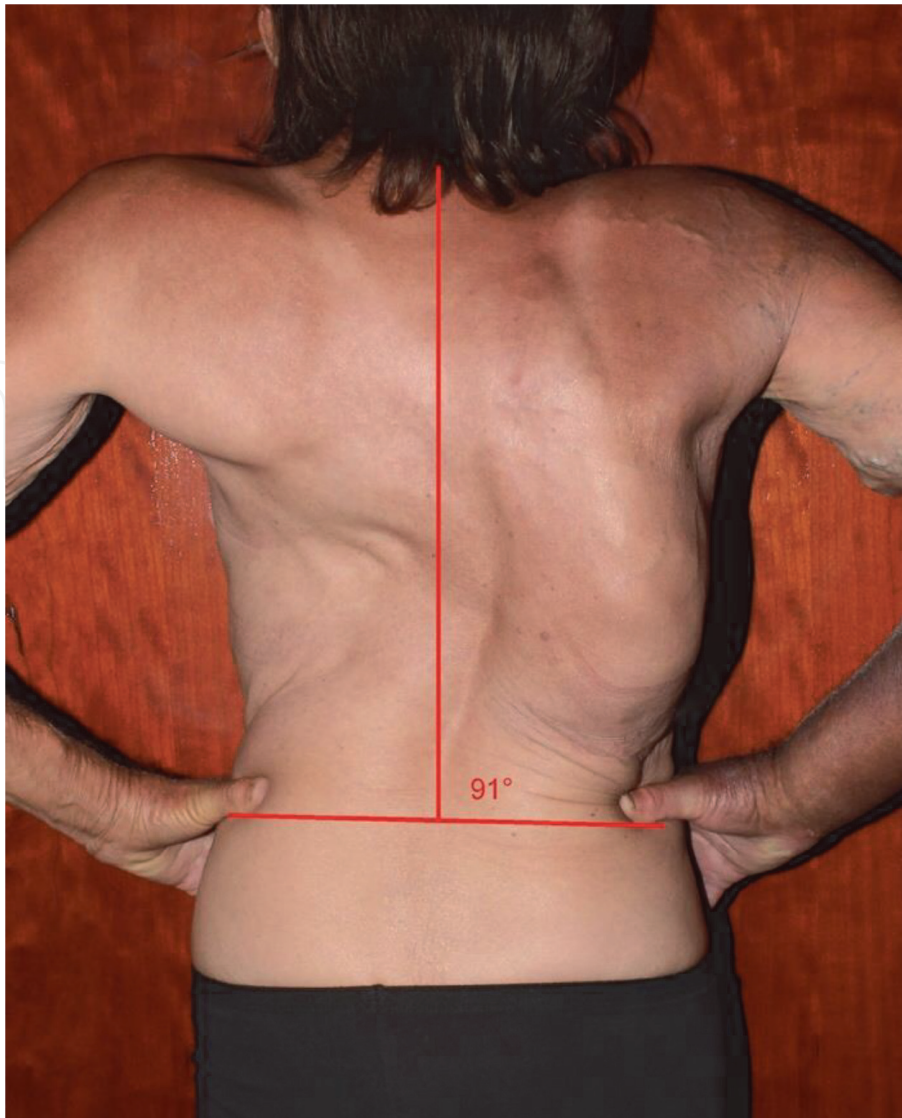

Figure 6.
Pelvic tilt measured on 17 August 2012. Thumbs are put to the iliac crests of the pelvis to mark them. The angle at the right side was 91°.

3.5 October 2012 and further

According to appearance, the scoliosis improved substantially since the beginning of treatment. The hump was markedly reduced. However, it is important to note that only X-rays can show the true state of the curves, so I was X-rayed on 8 October 2012. The comparison with X-ray image from 2010 showed that there was almost no change in spinal curvature (**Figure 7**). I have achieved derotation of the chest and improvement of the shape of the ribs as well as the lumbar lordosis. This reduced the hump and led to better rib support of the right side of the chest in front and left side in the rear (concave side). The changes had a positive effect on breathing and possibly prevented further deterioration of the curves. Lung volume reduction, which can be life-threatening, is not caused by curvature of the spine, but by the rotation of the rib cage which becomes flattened. Radiographs from 4 March 2015 also showed that the curvature did not improve. In years to come, I was still using the corset for at least some hours a week. I obtained a better corset in October 2016, which was much stiffer acting almost like a true brace (Vollers Eye Candy: <https://www.vollers-corsets.com/eye-candy-made-in-england>). But without reduction of the curve, additional derotation and rib hump reduction were not possible either.

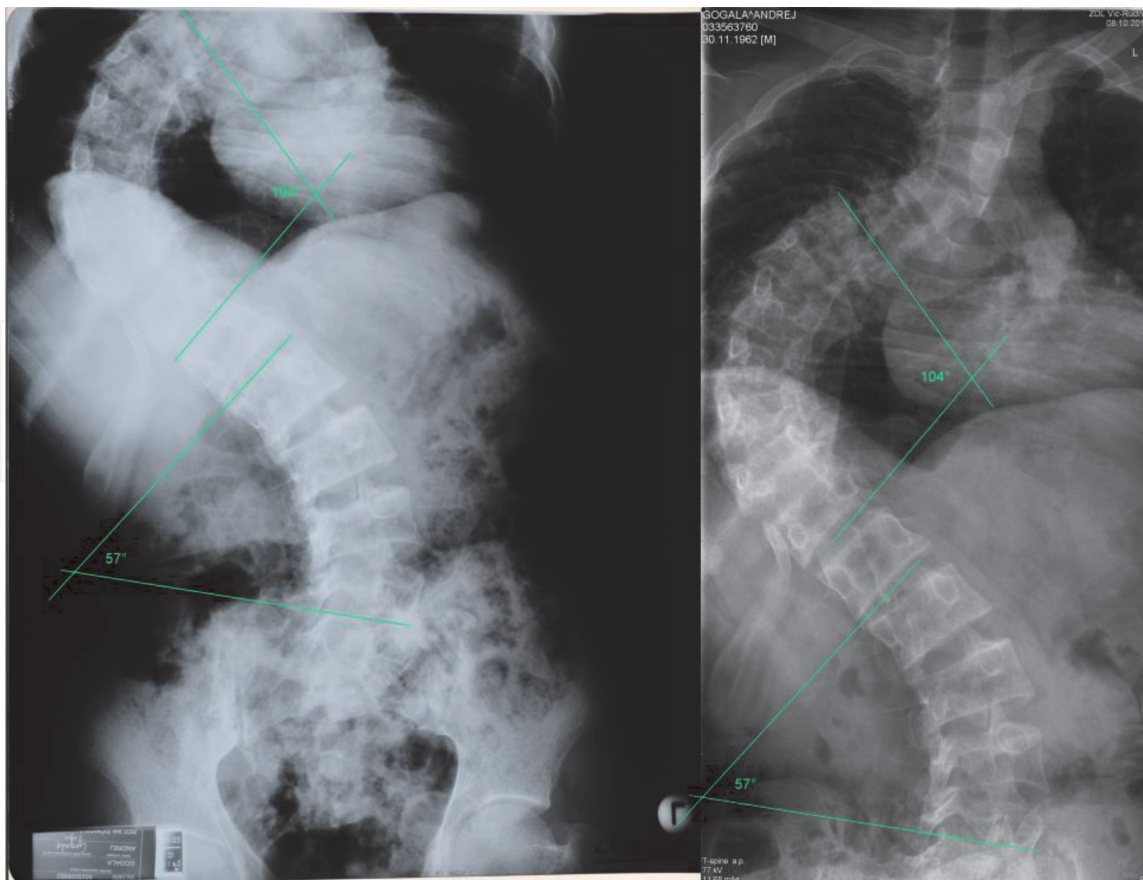


Figure 7.

At the left an X-ray image from 2010 with cobb angles measured. The thoracic curve measured 104° and lower lumbar 57°. At the right the X-ray image of the spine from 8 October 2012. The same angles are inserted as on the left image; there is almost no change.

I have never experienced back pain. Only when I started going on walks without the corset after I wore it almost every day for some time that a muscle started to ache on the left (concave) side of the back, which was shortened due to scoliosis and weakened during corset wear. But I persisted. If the pain was severe, I stopped for a rest and then went on. When the muscle strengthened again, the pain no longer occurred. The curves of my spine seem to be quite stiff and not mobile as they do not change between imaging sessions. But I do not have any problems with spine mobility during my activities. I have reduced lung capacity, however, and was never able to run over longer distances. With a long walk I had no problems; only when walking uphill, I was slower than others.

4. Discussion

Although corsets from textiles in the nineteenth and the first half of the twentieth century were sometimes used to treat or at least alleviate scoliosis, they were not accepted by the leading physicians at the time. Albee [23] published a picture of a textile corset for the treatment of scoliosis, but he recommended it only for the immobilization of the spine after spine surgery. A textile corset is more comfortable than a rigid brace as it adapts to the shape of the body. Since it is made of cloth, it is permeable to the air and moisture. Also the feeling of a hug given by the bodice is pleasant.

The corset should absolutely not be tightened too much, however. If it starts to pinch, then this means the grip must be released by loosening the lace at the back. This allows one to constantly adapt the corset to ones' body state. The body changes

its circumference with food intake and the degree of hydration. If the corset is tightened too much, it forces the ribs to rotate the vertebrae and diminish the chest circumference. It needs to be tightened only as much as is needed for good support and pressure to the prominent angles of the ribs; it should not press on the concave sides of the chest. Excessive tightening of the corset known as tightlacing or waist training was probably the cause of the bad reputation of wearing corsets as stated by medical experts in the Victorian times. The doctors cited corset wear in young women of the higher social classes as one of the main causes of scoliosis.

Textile corsets embrace the whole body, but the strongest pressure needs to be directed at the most prominent angles of the ribs to push them forward and inward posteriorly and backward anteriorly. Since the bodice acts with the same force on the ribs from the other side also, the ribs slowly get a more rounded shape, thus gaining a better form. Consequently the deformation of the chest is reduced. However, since the corset does not have empty spaces where the chest can expand into, treatment with a textile corset needs to be periodically interrupted.

After the corset is taken off, derotation forces directed to the back of the rib hump forward can then be applied to the thorax to derotate it, pushing the ribs in the opposite direction to the rotating forces. The hump needs to be pressed from behind, not laterally as this flattens the rib cage. A similar type of manipulation was performed to correct spinal deformities by Hippocrates and Galen millennia ago. While extending the body, they pressed the hump with the leg, whole body or with a plank, attached to the wall for leverage [5]. But pressing against the chair backrest or the hard floor when lying is sufficient. In the days when the corset is not worn, the chest can expand, and the muscles are more active and can be strengthened.

Corset wear also has an important effect on learning how to correct the erect posture. Patients with scoliosis have a distorted feeling of upright posture. When the corset forces them into it, they learn to keep an upright posture even when they are not braced.

While partial derotation was achieved with the help of a textile corset, the corset was not effective in diminishing the side curvatures of the spine as it is symmetrical. Modern rigid braces are far better at in-brace curve reduction, necessary for long-term improvement. But rigid braces for side curves of about 100° Cobb do not exist yet. In such cases we should be satisfied when deterioration is prevented.

The side curvature of the spine is always accompanied by rotation of the vertebrae and rib cage. Ribs are connected by intercostal muscles and cannot spread apart on the convex side when the spine bends. The curvature of the spine in the thoracic region is not possible without rotation of the vertebrae and deformation of the ribs. The ribs at the apex of the curve are pulled inward toward the vertebrae. Intercostal muscles under stress pull them up and down, but the composite force is directed toward the spine because the ribs at the apex of the curve are shifted further from the midline than other ribs [24]. The side curvature of the spine stretches the intercostal muscles like an archer pulls a bow string and the taut muscles push the ribs like the bow string pushes the arrow.

With rotation of the vertebrae at the apex of the curve, which are compressed between the ribs, the thoracic circumference diminishes, and the tension in the chest wall is alleviated. The deformation becomes irreversible if new growth or bone resorption and remodeling change the shape of the ribs and vertebrae or if the ligaments are not firm enough. When the rib cage and vertebrae become structurally rotated, the vertebrae lose the balanced support from the ribs from both sides. Shear forces from the ribs turn the vertebrae further and push the vertebral bodies toward the convexity (**Figure 8**). Continuous progression of scoliosis starts. With therapy one is able to diminish only the excessive rotation, while some rotation is

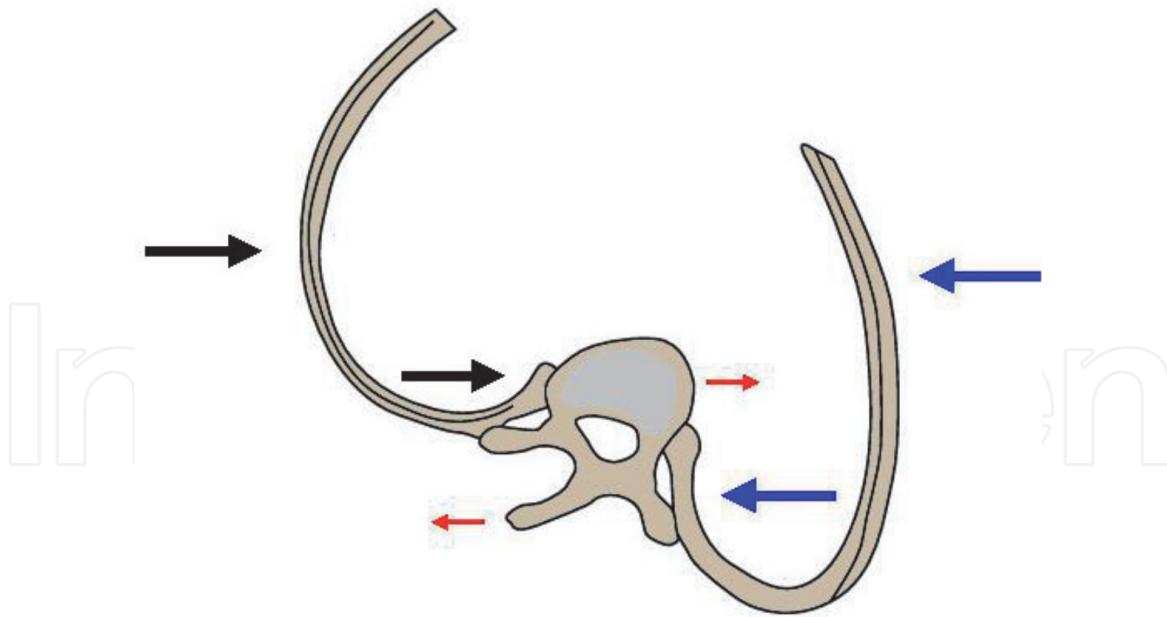


Figure 8.

In a rotated chest, forces transmitted by the ribs turn vertebrae and bend the spine sideways. Ribs on one side of the vertebrae are not opposed by equal support from the ribs on the contralateral side, so ribs on the concave side push vertebral bodies toward convexity, bending the spine [24].

necessary at a given curvature. The side curvature in the frontal view must be reduced for further improvement.

5. Conclusion

Although the reduction of spine curvature developed in scoliosis is unlikely during adulthood, therapy in this period of life is not without benefits. We can achieve partial derotation of the chest leading to a significant improvement of appearance. Deterioration of scoliosis may probably be prevented. Textile corset may be more acceptable than a rigid brace for active adult patients as it is more comfortable and not noticeable under clothing. Corset wear should be complemented with other therapies, like postural correction, exercises, and physical manipulation.

Conflict of interest

The author declares that he has no competing interests. The study was not supported by funding.

IntechOpen

IntechOpen

Author details

Andrej Gogala
Slovenian Museum of Natural History, Ljubljana, Slovenia

*Address all correspondence to: agogala@pms-lj.si

IntechOpen

© 2019 The Author(s). Licensee IntechOpen. This chapter is distributed under the terms of the Creative Commons Attribution License (<http://creativecommons.org/licenses/by/3.0>), which permits unrestricted use, distribution, and reproduction in any medium, provided the original work is properly cited. 

References

- [1] Negrini S, Aulisa AG, Aulisa L, Circo AB, de Mauroy JC, Durmala J, et al. 2011 SOSORT guidelines: Orthopaedic and rehabilitation treatment of idiopathic scoliosis during growth. *Scoliosis*. 2012;**7**:3
- [2] Negrini S, Donzelli S, Aulisa AG, Czaprowski D, Schreiber S, de Mauroy JC, et al. 2016 SOSORT guidelines: Orthopaedic and rehabilitation treatment of idiopathic scoliosis during growth. *Scoliosis and Spinal Disorders*. 2018;**13**:3. DOI: 10.1186/s13013-017-0145-8
- [3] Lehnert-Schroth C. *Three-Dimensional Treatment for Scoliosis. A Physiotherapeutic Method for Deformities of the Spine*. Palo Alto, California: The Martindale Press; 2007. 276 p
- [4] Cheng JC, Castelein RM, Chu WC, Danielsson AJ, Dobbs MB, Grivas TB, et al. Adolescent idiopathic scoliosis. *Nature Reviews Disease Primers*. 2015;**1**:15030
- [5] Vasiliadis ES, Grivas TB, Kaspiris A. Historical overview of spinal deformities in ancient Greece. *Scoliosis*. 2009;**4**:6
- [6] Weinstein SL, Dolan LA, Wright JG, Dobbs MB. Effects of bracing in adolescents with idiopathic scoliosis. *New England Journal of Medicine*. 2013; **369**:1512-1515
- [7] Aulisa AG, Guzzanti V, Marzetti E, Giordano M, Falciglia F, Aulisa L. Brace treatment in juvenile idiopathic scoliosis: A prospective study in accordance with the SRS criteria for bracing studies—SOSORT award 2013 winner. *Scoliosis*. 2014;**9**:3
- [8] Lusini M, Donzelli S, Minnella S, Zaina F, Negrini S. Brace treatment is effective in idiopathic scoliosis over 45°: An observational prospective cohort controlled study. *The Spine Journal*. 2014;**14**(9):1951-1956. DOI: 10.1016/j.spinee.2013.11.040
- [9] Marty-Poumarat C, Scattin L, Marpeau M, Garreau de Loubresse C, Aegerter P. Natural history of progressive adult scoliosis. *Spine*. 2007; **32**:1227-1234
- [10] Negrini A, Negrini MG, Donzelli S, Romano M, Zaina F, Negrini S. Scoliosis-specific exercises can reduce the progression of severe curves in adult idiopathic scoliosis: A long-term cohort study. *Scoliosis*. 2015;**10**:20. DOI: 10.1186/s13013-015-0044-9
- [11] Brooks WJ, Krupinski EA, Hawes MC. Reversal of childhood idiopathic scoliosis in an adult, without surgery: A case report and literature review. *Scoliosis*. 2009;**4**:27
- [12] Negrini A, Parzini S, Negrini MG, Romano M, Atanasio S, Zaina F, et al. Adult scoliosis can be reduced through specific SEAS exercises: A case report. *Scoliosis*. 2008;**3**:20
- [13] Weiss H-R, Moramarco K, Moramarco M. Scoliosis bracing and exercise for pain management in adults—A case report. *Journal of Physical Therapy Science*. 2016;**28**:2404-2407
- [14] Fayssoux RS, Cho RH, Herman MJA. History of bracing for idiopathic scoliosis in North America. *Clinical Orthopaedics and Related Research*. 2010;**468**:654-664
- [15] Brodhurst BE. *On Lateral Curvature of the Spine, its Pathology and Treatment*. London: John Churchill; 1855. 67 p
- [16] Papadopoulos D. Adult scoliosis treatment combining brace and exercises. *Scoliosis*. 2013;**8**(Suppl 2):O8

[17] Weiss HR, Goodall D. Rate of complications in scoliosis surgery—A systematic review of the Pub Med literature. *Scoliosis*. 2008;**3**:9

[18] Mohar J. Untreated early onset scoliosis—The natural progression of a debilitating and ultimately deadly disease. In: Grivas TB, editor. *Recent Advances in Scoliosis*. London: IntechOpen; 2012. pp. 311-328. DOI: 10.5772/2497

[19] Weinstein SL, Dolan LA, Spratt KF, Peterson KK, Spoonamore MJ, Ponseti IV. Health and function of patients with untreated idiopathic scoliosis. A 50-year natural history study. *JAMA*. 2003;**289**:559-567

[20] Rom WN, Miller A. Unexpected longevity in patients with severe kyphoscoliosis. *Thorax*. 1978;**33**:106-110

[21] van Loon PJ, Kühbauch BA, Thunnissen FB. Forced lordosis on the thoracolumbar junction can correct coronal plane deformity in adolescents with double major curve pattern idiopathic scoliosis. *Spine*. 2008;**33**: 797-801

[22] D'Astous JL, Sanders JO. Casting and traction treatment methods for scoliosis. *Orthopedic Clinics of North America*. 2007;**38**:477-484

[23] Albee FH. *Orthopedic and Reconstruction Surgery, Industrial and Civilian*. W. B. Saunders Company: Philadelphia and London; 1919. 1138 p

[24] Gogala A. Role of the ribs in the onset and progression of idiopathic scoliosis. *Zdravniški vestnik*. 2017;**86**:404-413. DOI: 10.6016/ZdravVestn.2483