

# We are IntechOpen, the world's leading publisher of Open Access books Built by scientists, for scientists

**4,800**

Open access books available

**122,000**

International authors and editors

**135M**

Downloads

Our authors are among the

**154**

Countries delivered to

**TOP 1%**

most cited scientists

**12.2%**

Contributors from top 500 universities



**WEB OF SCIENCE™**

Selection of our books indexed in the Book Citation Index  
in Web of Science™ Core Collection (BKCI)

Interested in publishing with us?  
Contact [book.department@intechopen.com](mailto:book.department@intechopen.com)

Numbers displayed above are based on latest data collected.

For more information visit [www.intechopen.com](http://www.intechopen.com)



# Wernicke Encephalopathy in Elderly Related to Severe Malnutrition

*Francisco Javier Ros Forteza*

## Abstract

Wernicke encephalopathy (WE) is the main neurologic complication of thiamine deficiency. Thiamine is a cofactor for several key enzymes important in energy metabolism. WE is a little-recognised and underdiagnosed condition, and the prevalence in the elderly is unknown. The classic triad of WE includes encephalopathy, oculomotor dysfunction, and gait ataxia. Diagnosis is clinical, and early treatment with thiamine is fundamental in preventing coma and death. In the cases reported in the literature, the cause of WE was fasting or malnutrition in 10.2% of cases. WE may in some cases constitute a public health problem. Being the prevalence unknown, we alert clinicians to keep severe malnutrition in elderly as a form of precipitation of WE. We review the cases published in the literature.

**Keywords:** Wernicke encephalopathy, elderly, severe malnutrition, underdiagnosed condition, thiamine deficiency

## 1. Introduction

Wernicke encephalopathy (WE) is the main neurologic complication of thiamine deficiency. Thiamine is a cofactor for several key enzymes important in energy metabolism [1]. Although the chronic alcoholism is recognised as the most common cause of WE, malnutrition has also been less documented [2] generating deprivation of other micronutrients (including in addition to albumin; thiamine; riboflavin; pyridoxine; vitamins B12, E and D; niacin; folate; ferritin; calcium; and magnesium mainly). WE is an acute syndrome characterised by mental confusion, ophthalmoplegia, and gait ataxia (classic triad), but they are not always present which likely leads to under-diagnosis [3]. In chronic alcohol abusers, they have also been used the following four Caine criteria: dietary deficiency, oculomotor abnormalities, cerebellar dysfunction, and either altered mental status or mild memory impairment. Two of the four criteria are sufficient for the diagnosis [4]. Structural diseases of the medial thalamus, hippocampus, or the inferior medial region of the temporal lobe should also be considered due to the similar neuroanatomical involvement to WE. Diagnosis is clinical, and early treatment is fundamental in preventing coma and death. Imaging studies can be helpful but should not delay treatment.

## 2. Malnutrition among the elderly

Nutrition is a significant determinant of health. Undernutrition presenting as malnutrition is a serious health concern for frail elderly people with many health problems [5].

### 2.1 Diagnosis of malnutrition

The following criteria for the diagnosis of malnutrition have been recommended in a consensus statement from the Academy of Nutrition and Dietetics (Academy) and the American Society for Parenteral and enteral Nutrition (ASPEN) [6].

Two or more of the following six characteristics:

- Insufficient energy intake.
- Weight loss (according to Zawada, 1996) is considered to be clinically significant with the following parameters: >2% decrease of baseline body weight in 1 month; >5% decrease in 3 months, or > 10% in 6 months.
- Loss of muscle mass.
- Loss of subcutaneous fat.
- Localised or generalised fluid accumulation that may mask weight loss.
- Diminished functional status as measured by handgrip strength.

### 2.2 Population at risk

The people most at risk are the frail elderly and with few or no social and environmental support [5]. These patients may have signs of nutritional deficiency living institutionalised or being hospitalised that can go unnoticed. They are clinical conditions that increase the use of thiamine and may precipitate WE in patients with marginal thiamine reserves such as poor dietary intake, unbalanced nutrition, prolonged intravenous feeding, terminal cancer, and gastrointestinal surgery.

### 2.3 Epidemiology of malnutrition

The epidemiology of malnutrition depends on the definition used, although in most studies it refers to the undernutrition concerning weight loss and deficiency of nutritional components. Housebound and institutionalised elderly people have most frequently been shown to be deficient in vitamins A, C, D, B complex, folic acid, and B<sub>12</sub> as well as calcium, iron, and zinc [5].

Nutritional deficiencies are ranked in the top 20 leading worldwide disease and disability burden in 2016, according to the Institute of Health Metrics Evaluation [7].

The prevalence of malnutrition in hospitalised adults has been extensively reported in the international literature and varies between 13 and 78% among acute-care patients [8]. The vulnerability in data may be due to terminology used, the diagnostic criteria, and variations in communities.

### 2.4 Aetiology of malnutrition

In examining the aetiology of malnutrition, we must consider risk factors that could cause the condition or exacerbate the underlying cause. Morley [9] has

developed a mnemonic *meals-on-wheels* for identifying potentially treatable causes of malnutrition (adapted from Morley):

Medications; emotional problems (depression); anorexia nervosa (tardive) and abnormal attitudes to food; late-life paranoia; swallowing problems; oral problems; no money (especially those on fixed incomes); wandering and other dementia-related behaviours; hyperthyroidism; hyperparathyroidism; entry problems (mal-absorption); eating problems (physical and cognitive); low-salt, low-cholesterol diets; and shopping (food availability).

## 2.5 Consequences of malnutrition

We know that malnutrition can lead to a weak immune system, which increases the risk of infections, a muscle weakness, a decreased bone mass, a higher risk of hospitalisation, and an increased risk of death.

According to Saunders J et al., 2011, the most relevant consequences of malnutrition on health include increased risk of infections, functional decline, delayed wound healing, cognitive decline, impaired respiratory function, muscle weakness and depression, delayed recovery from acute illness, and increased mortality [10].

## 2.6 Neurological disorders associated with malnutrition

- Neurological disorders caused by nutrient deficiency (**Table 1**)
- Potentially toxic food compounds that may contribute to neurological disorders (**Table 2**)

## 3. Thiamine deficiency in elderly people

Thiamine (vitamin B1), as thiamine pyrophosphate (TPP), is an essential coenzyme in several important energy yielding reactions, including the transketolase reaction in the pentose phosphate pathway.

We cognize that the recommended daily allowance for an adult is 1.1 mg/dl and the current UK recommended nutrient intake for elderly people is 0.4 mg of thiamine per 1000 kcal [11]. Also, there is evidence that subclinical thiamine deficiency may contribute to anorexia in the elderly [12].

The reported prevalence in the UK ranges from 8 to 31% for elderly people living at home and from 23 to 40% for those in nursing homes [13]. Biochemical thiamine deficiency has also been reported in 48% of patients admitted to an acute geriatric unit [13].

### 3.1 Thiamine deficiency in developed countries

Alcoholism is the most common cause of thiamine depletion in developed countries. Alcohol interferes with the active intestinal transport of vitamin B1. In chronic hepatopathy, the ability to store thiamine and transform it into its active form is diminished. The affinity of transketolase for thiamine pyrophosphate may be genetically decreased in some people, which predispose them to WE. A diet rich in carbohydrates or the administration of serum glucose in a patient with masked deficiency of vitamin B1 precipitates or aggravates EW, even to death. Thiamine reserves do not exceed 3 weeks, so it is not difficult to present a deficit in acute situations (e.g. post-surgery status, prolonged hospitalisation in intensive care unit, hunger strikes, etc.) [14].

Nutrient	RDA*	Neurological disorder when deficient
<b>Macronutrients</b>		
Total energy	2200 (kcal)	In childhood: long-term mental deficit
<b>Vitamins</b>		
Vitamin A	600 µg	Night-blindness
Vitamin B1 (thiamine)	1.1 mg	Beriberi, polyneuropathy, Wernicke encephalopathy, Korsakoff syndrome
Vitamin B3 (niacin)	15 mg NE	Pellagra including dementia and depression. Neuropsychiatric disorders
Vitamin B6 (pyridoxine)	1.6 mg	Polyneuropathy. neuropsychiatric disorders including seizures, migraine, chronic pain, and depression
Vitamin B12 (cobalamin)	2.0 µg	Progressive myelopathy with sensory disturbances in the legs. Ataxia. Dementia. Neuropsychiatric disorders
Vitamin D3 (cholecalciferol)	5 µg	Myopathy
Vitamin E (alpha-tocopherol)	10 mg	Ataxia, myopathy, retinopathy/ophthalmoplegia
Folate	180 µg	Neural tube defects (myelomeningocele) of the fetus, cognitive dysfunction in children and elderly. Neuropsychiatric disorders. Increased vascular risk (in hyper-homocysteine)
<b>Minerals</b>		
Iodine	150 µg	Iodine deficiency disorders: Cretinism (severe mental retardation, growth retardation, deaf-mutism, and physical disability). Decrease in IQ and lower school performance
Iron	15 mg	Delayed mental development in children
Zinc	12 mg	Delayed motor development in children, behavioural abnormalities, and depression. Visual disturbances
Selenium	55 mg	Adverse mood states, myopathy
Magnesium	400 mg	Behavioural, sleep, and memory abnormalities. Tremor and weakness. Depression. Seizures
Manganese	2 mg	Behavioural and memory abnormalities. Seizures

\*Recommended daily allowance for an adult.  
Source: Diop et al. [15] (completed by Ros Forteza).

**Table 1.**  
*Neurological disorders caused by nutrient deficiency.*

### 3.2 Wernicke encephalopathy

For WE and Korsakoff syndrome (KS), there are the acute phase and the residual state, respectively, of the same pathological process. Both are the result of thiamine deficiency.

It can occur at any age, and although it is more frequent in men, women are more susceptible [1].

Thiamine has an important role in catabolism of carbohydrates and neurotransmitter formation. Its utilisation depends on the individual's metabolic rate, increasing with a higher energy requirement [16].

In the gastrointestinal tract, this nutrient is actively absorbed at the duodenum level and then transported through the blood–brain barrier by passive and active processes [17].

Food compound	Potential neurological disorder when ingested
Alcohol	Fetal alcohol syndrome, retarded mental development in childhood, delirium, cerebral atrophy, dementia, Wernicke encephalopathy, Korsakoff syndrome, visual problems (amblyopia), ataxia, peripheral neuropathy, myopathy, epilepsy
<i>Lathyrus sativus</i>	Spastic paraparesis (lathyrism)
Cyanogenic glucosides from insufficiently processed cassava roots	Konzo (tropic ataxic neuropathy)

Source: Diop et al. [15] (completed by Ros Forteza).

**Table 2.**  
 Potentially toxic food compounds that may contribute to neurological disorders.

In its biologically active form (thiamine pyrophosphate), it is an essential coenzyme for various enzymes of catabolism of glucose-6-phosphate, such as transketolase, pyruvate dehydrogenase, and  $\alpha$ -ketoglutarate dehydrogenase [17, 18]. The first enzyme participates in the pentose-phosphate pathway, and its catalytic activity results in reduced ribose-5-phosphate and nicotinamide adenosine dinucleotide (NADPH) molecules. Both are crucial in the synthesis of various other compounds (e.g. nucleic acids and glutathione), and any cell requires optimal levels of these enzymes. The other two enzymes catalyse glycolysis and Krebs cycle reactions, respectively. These metabolic pathways result in the formation of adenosine triphosphate (ATP) molecules, vital in providing energy for cell metabolism. Low levels of mentioned enzymes lead to lower energy synthesis and cell death [18].

As thiamine reserves (30–50 mg) do not exceed 3 weeks, it is not difficult for a deficit to occur in acute situations. In some cases, low levels of magnesium, an essential cofactor of thiamine into its active diphosphate and triphosphate forms, have been implicated with thiamine deficiency in WE [19].

Only a subset of thiamine-deficient alcohol abusers develop WE. Investigators have found that in alcohol abusers with WE, the thiamine-dependent enzyme transketolase has an altered affinity for thiamine. Variants in the high affinity thiamine transporter gene have also been implicated [20].

The classic triad of WE includes encephalopathy, oculomotor dysfunction, and gait ataxia; these were recognised in only one-third of patients. The encephalopathy is characterised by profound disorientation, indifference, and inattentiveness. The ocular signs consist of nystagmus that is both horizontal and vertical and mainly evoked by gaze; this is the most common feature, weakness, or paralysis of the lateral rectus muscles and weakness or paralysis of conjugate gaze. Usually there is some combination of these abnormalities, according to Adams and Victor's, 2014. Ataxia primarily involves stance and gait and is likely due to a combination of polyneuropathy, cerebellar involvement, and vestibular dysfunction [1].

In one study of 106 autopsied alcohol abusers, the Caine criteria (two of four being enough: dietary deficiency, oculomotor abnormalities, cerebellar dysfunction, either altered mental status or mild memory impairment) increased the diagnostic sensitivity for WE from 22% using the classic triad to 85% [4].

Other signs in patients with WE may also be present as vestibular dysfunction without hearing loss; the presence of spontaneous nystagmus with absent caloric responses appears to be a relatively specific finding in WE [21]. Additionally, peripheral neuropathy, hypothermia, and cardiovascular signs and symptoms such as tachycardia, exertional dyspnoea, elevated cardiac output, and EKG abnormalities can be detected [1]. These reverse with thiamine administration.

Imaging studies should not delay treatment, especially a MRI. However, diagnostic imaging can be helpful by providing evidence of WE in many patients and may rule out alternative diagnoses [20].

Typical findings include lesions surrounding the aqueduct and third ventricle and within the medial thalamus, dorsal medulla, tectal plate, and mammillary bodies. Lesions may also be seen in atypical areas such as the cerebellum, cranial nerve nuclei, dentate nuclei, caudate, red nuclei, splenium, and cerebral cortex. Abnormal T2 signal disappears within as little as 48 h after treatment with thiamine [20]. Mammillary body atrophy is a relatively specific abnormality in patients with chronic lesions of WE [22] and can be detected within 1 week of the onset of WE [23].

There are no laboratory studies that are diagnostic of WE. WE is primarily a clinical diagnosis. WE should be considered in the differential diagnosis of all patients presenting with acute delirium or acute ataxia [20]. Also, structural diseases in the medial thalami, hippocampi, or inferior medial temporal lobes should be considered because of the neuroanatomic overlap with WE. These include top-of-the-basilar stroke, hypoxic–ischemic encephalopathy after cardiac arrest, herpes simplex encephalitis, and third ventricular tumours [24, 25].

The diagnosis of WE is difficult to confirm and, when untreated, most patients progress to coma and death. Therefore, diagnostic testing (measurement of biochemical thiamine deficiency [13]) should not delay treatment, which should immediately follow the consideration of the diagnosis [20].

Patients with suspected WE require immediate parenteral administration of thiamine. A recommended regimen is 500 mg of thiamine intravenously, infused over 30 min, 3 times daily for two consecutive days and 250 mg intravenously or intramuscularly once daily for an additional 5 days, in combination with other B vitamins. There are no randomised studies to support a particular dosing regimen. Administration of glucose without thiamine can precipitate or worsen WE; thus, thiamine should be administered before glucose. Subsequently daily 100 mg oral thiamine should be continued until patients are no longer considered at risk [20].

The disappearance of nystagmus and an improvement in ophthalmoparesis within hours or a day of the administration of thiamine confirms the diagnosis. Ataxia recovery begins during the second week, and confusion declines over days and weeks according to Adams and Victor, 2014. MRI resolves with clinical improvement. Only a minority of such patients (fewer than 20% in Victor's series) recover entirely.

## **4. Wernicke encephalopathy in elderly related to severe malnutrition**

### **4.1 Justification and literature**

The absence of a nutritional assessment method that can be considered a “gold standard” makes it very difficult to task. Also unfortunately there is no data in the medical records about nutritional evaluation nor in publications outside the field of nutrition, and healthcare professionals receive little education on nutrition. For these reasons all healthcare professionals should be involved and not just the nutritionist in this public health problem.

There are few cases published in the literature of WE in elderly related to malnutrition [26–32].

Magalhães Scoralick et al. describe a case of a 63-year-old man with grade IV chagasic mega oesophagus who developed WE. There was no past of alcohol, and the patient had not received nutritional therapy, and he was not taking a vitamin

supplement. The deficiency of vitamins B1 and B6 was found. The patient recovered from the acute symptoms; however 3 months after his admission, he died [26].

Another case of WE was due to dual deficiency of both thiamine (vitamin B1) and niacin (vitamin A PP) in an 80-year-old woman regular consumer of alcohol with severe malnutrition; vitamin D and B6 deficits were also found [27].

Differently, a case of autopsy-proven acute nonalcoholic thiamine-deficient encephalopathy without medical treatment antemortem. The patient was found dead in his room; he was a 62-year-old man and had BMI 11.7, and vitamin B1 and B12 deficits were detected [28].

On the other hand, other authors report a WE and pellagra in an alcoholic and malnourished patient. He was a 61-year-old man and had a vitamin deficiency of B1 and niacin. Thiamine and nicotinic acid were administered. Finally, the patient was transferred to a rehabilitation facility, where he gained the support of an alcohol abstinence education programme [29].

Also the case of a 65-year-old female, nonalcoholic with a 43-Kg weight loss (25% of baseline weight) over several weeks. On admission, she received a continuous intravenous glucose infusion, and 4 days later she developed symptoms suggestive of WE. A brain MRI demonstrated signal change in the medial thalami and mammillary bodies. The patient received intravenous thiamine therapy and was discharged on oral thiamine with clinical improvement [30].

We highlight a series of five elderly patients whose brain showed typical features of WE at the autopsy. All five were females with a mean age of 67 +/- years-old. One case was alcoholic, but the other four were nonalcoholics and developed the disease after prolonged malnutrition. WE was diagnosed clinically only in one case [31].

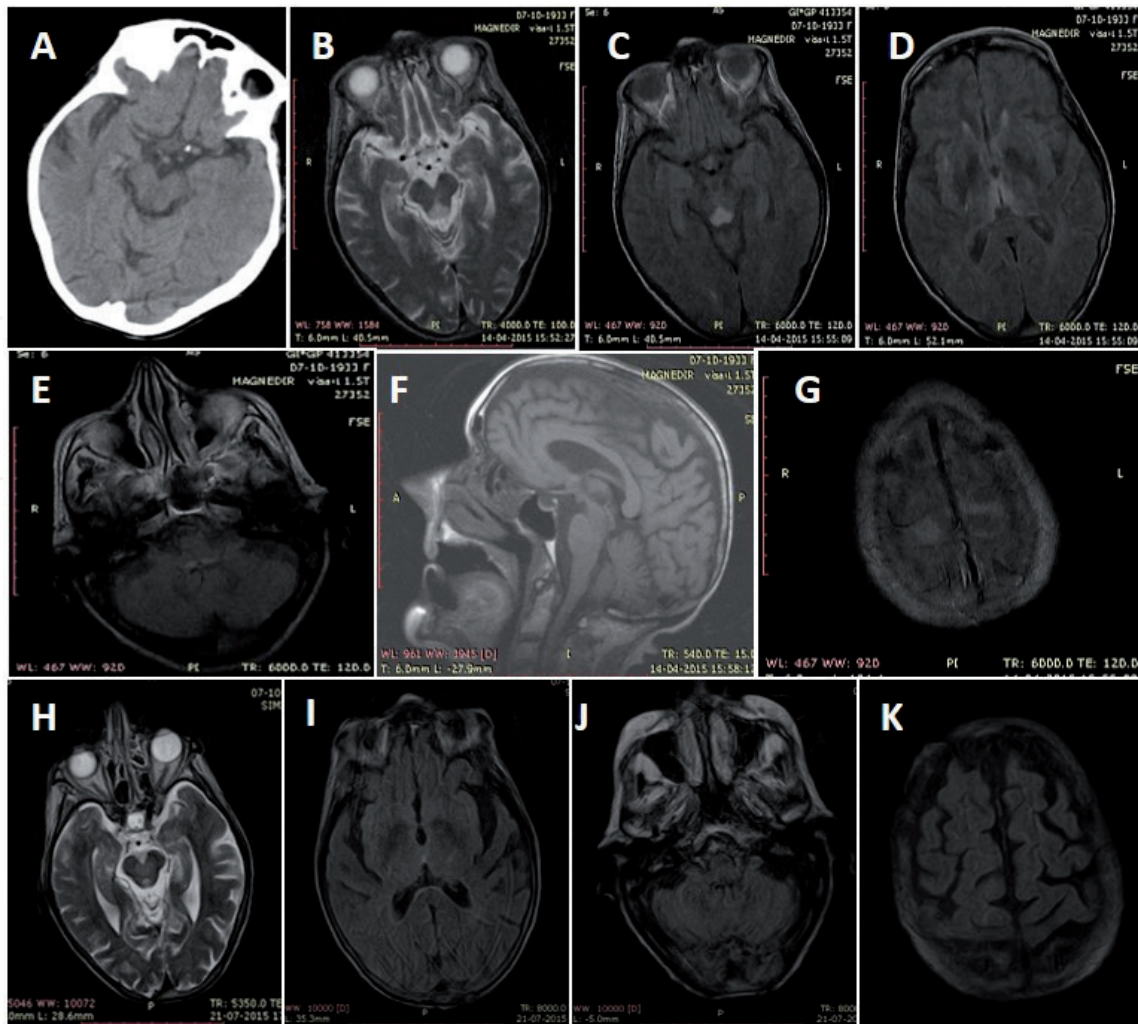
## 4.2 Special case report

We present the case [32] of an 81-year-old autonomous woman with 10 years of schooling and body mass index (BMI) previously of 23.2. There was no history of tobacco and alcohol use. Her medical history included hypertension, acute biliary pancreatitis, and hiatal hernia diagnosed 18 years previously. Her surgical history incorporated cholecystectomy and anti-reflux surgery 15 years previously. She was being treated with candesartan, pantoprazole, domperidone, ursodeoxycholic acid, mirtazapine, mexazolam, and brotizolam. Two to three weeks after an influenza episode, she developed anorexia, dehydration, mental confusion, altered sleep-wake cycle, and visual and gait impairment.

On physical examination, the patient showed somnolence, but easily aroused, disorientation in time but not space, incoherent speech, strabismus, persistent horizontal-rotary nystagmus, dysphagia for liquids, and hypotonia. A second head CT scan at 24 h revealed a suspected lacunar stroke of the right tectal plate (**Figure 1A**), requiring examination with brain MRI. A transthoracic echocardiography and lumbar puncture had normal results.

She started treatment with thiamine at high doses (500 mg IV every 8 h for 2 days, 500 mg IV every 24 h for 5 days), then at 100 mg IV every 8 h during the remaining days of hospitalisation, combined with a multivitamin solution [vitamins A, B, H (biotin), and F] and protein-calorie supplementation. We observed a significant clinical improvement, with decreased nystagmus, improved verbal expression, and corrected sleep pattern. A brain MRI (**Figure 1B-G**) performed at day 5 of admission revealed diffuse hyperintensity of the tectum, periaqueductal region, medial thalami, mammillary bodies, and structures adjacent to the diencephalon and cortical convexity with brain atrophy, which were indicative of WE.





**Figure 1.**

Published with permission of the editor. Source: Ros Forteza et al. [32]. Baseline findings: (A) head CT at 24 h: Hypodensity in the right tectal plate. (B) Axial T2-weighted MRI sequence. (C) Axial FLAIR MRI sequence: Lesion to the midbrain periaqueductal region. (D) Axial FLAIR MRI sequence: Bilateral thalamic lesions. (E) Axial FLAIR MRI sequence: Tectal lesion. (F) Sagittal T1-weighted MRI sequence: no alterations. (G) Axial FLAIR MRI sequence: Lesion to the superior frontal cortex and pia mater. Findings at resolution: (H) axial T2-weighted MRI sequence: Regressing periaqueductal lesion. (I) Axial FLAIR MRI sequence: no thalamic lesion. (J) Axial FLAIR MRI sequence: no bulbar lesion. (K) Axial FLAIR MRI sequence: no lesion to the cortex or pia mater.

At day 6 of admission, the patient was awake, with no spontaneous verbal response, exotropia of the right eye, and mild horizontal-rotatory nystagmus. Other tests were apparently normal. The BMI was 15.6.

Extensive work-up revealed a decrease in haemoglobin, vitamin B1 (27 ng/mL), vitamin B12, vitamin D, magnesium, sodium, and albumin. Intrinsic factor antibody test and serological test for syphilis yielded negative results.

Thiamine was maintained at 100 mg IV every 8 h; pantoprazole was withdrawn, and ranitidine started at 150 mg at night. The patient also started treatment with oral vitamin B12 at 5 mg/day, cholecalciferol 667 IU/day, magnesium 10 mL/12 h, calcium carbonate 500 mg/12 h, and 0.9% saline solution. During the first 2 weeks of admission, her speech improved, and she was able to produce sentences; nystagmus manifested only at extreme lateral gaze. Ataxic gait was later identified, and she started rehabilitation.

At 1 month of admission, an awake EEG revealed slow background activity, suggesting diffuse brain dysfunction (grades 2–3). From the second month of treatment, our patient presented good general appearance, fluent and coherent speech,

and an MMSE score of 23. The patient participated in craft activities and regular rehabilitation sessions.

At 3 months of admission, a brain MRI scan demonstrated complete remission of the brain lesions (**Figure 1H–K**).

The neuropsychological evaluation showed that autobiographical memory was preserved. We were able to apply only three subtests of the Wechsler Adult Intelligence Scale (WAIS-III): matrix reasoning, similarities, and digit span; results were higher level, average level, and average level, respectively. No areas of deficit were identified.

The age of our patient was atypical with clinical presentation of the classic triad. In this case, WE was caused by severe malnutrition [2]. The patient lost 33% of her body weight, with a BMI of 15.6 [BMI below 16 corresponds to grade 3/severe thinness according to the WHO classifications (1995, 2000)]. Protein-calorie deficiency is not always present; in a review of 625 cases reported in the literature, the cause of WE was fasting or malnutrition in 10.2% of cases [33].

Brain MRI showed typical findings of WE, although this test is more sensitive for detecting WE lesions in non-alcoholic than in alcoholic patients [34]; clinical recovery was excellent with vitamin supplementation.

Regarding the pathophysiology of these symptoms, thiamine reserves were depleted in 2–3 weeks due to caloric restriction. In the event of thiamine depletion, the function of the thiamine-dependent enzyme systems deteriorates, and blood thiamine levels decrease. This damage occurs 4 days after the onset of thiamine deficiency and eventually progresses to programmed cell death. At 14 days, brain lesions develop [2]. It is probable that some subjects with genetically reduced transketolase activity require higher levels of thiamine and therefore present a higher risk of WE in situations of increased demand or lower absorption [34].

Additionally, the low level of magnesium (a thiamine cofactor) also contributed to the genesis of this clinical picture. Many cases of WE may also have magnesium (Mg) depletion, and it is known that in elderly people, Mg intake may be suboptimum. If a depletion of Mg reserve impedes the phosphorylation of thiamine, Mg depletion could have an effect on other enzymes whose activities depend on Mg [35]. Other vitamin deficiencies were vitamin B12 and vitamin D. It is recognised that long-term use of pantoprazole suppresses gastric acid production, which may lead to vitamin B12 malabsorption [36].

This case is special because being the clinical picture of several weeks of evolution, the first diagnostic hypothesis was vertebrobasilar stroke. WE was diagnosed in a context of severe malnutrition little evident in a nonalcoholic patient, despite symptoms (complete classic triad present) and neuroimaging findings being more typical (except alterations of cerebral cortex) of an alcoholic patient [34]. There was also no atrophy of the mammillary bodies, a very specific pathological finding in chronic EW and KS and present in up to 80% of alcoholic patients with a history of EW [37–39].

We propose that WE should be considered in elderly patients with mental status changes of unknown cause and risk for thiamine deficiency, even in nonalcoholic patients. Infusion of thiamine should be started immediately when the disorder is suspected, even in the absence of typical symptoms. With this case, we aim to raise awareness of the need to identify this preventable, treatable, and high-mortality disease.

### 4.3 Future perspectives

Nowadays, despite the caloric density, the diet is often of poor nutrition quality and does not meet recommended dietary guidelines for micronutrient intake, making this an at-risk population for micronutrient malnutrition [40].

On the other hand, genetic factors may be involved in thiamine deficiency, i.e. pathogenic gene mutations in key regulators of the thiamine pathway, including thiamine pyrophosphokinase 1 (TPK1), thiamine diphosphate kinase (TDPK), thiamine triphosphatase (THTPA), and thiamine transporters (SLC25A19, SLC19A2/THTR1, and SLC19A3/THTR2) [40]. More recently, it has been defended that the organic cation transporter 1 (OCT1) plays a role as a hepatic thiamine transporter [41].

In addition, oxidative stress also is involved in this disease. In the near future, supplemental antioxidants will be incorporated for the prevention and treatment of the EW.

## 5. Conclusion

WE in elderly related to severe malnutrition is a little-recognised and underdiagnosed condition. Beyond an anamnesis of suspicion and a timely neurological semiology, nutrition education is necessary, and this information must be explicit in the clinical records. Parenteral thiamine should be given to all at-risk subjects admitted to the emergency room, and in every patient with WE, other nutritional deficiencies must be searched. It is necessary that a collaborative network of researchers in the field of malnutrition in older patients and clinicians should raise awareness of the need to identify this preventable, treatable, and high-mortality disease.

## Conflict of interest

There is no conflict of interest.

## Author details


Francisco Javier Ros Forteza<sup>1,2</sup>

1 Neurology Service, Local Health Unit of Guarda, E.P.E., Guarda, Portugal

2 Department of Medical Sciences, Faculty of Health Sciences, University of Beira Interior, Covilhã, Portugal

\*Address all correspondence to: javierros40@hotmail.com

## IntechOpen

© 2019 The Author(s). Licensee IntechOpen. This chapter is distributed under the terms of the Creative Commons Attribution License (<http://creativecommons.org/licenses/by/3.0>), which permits unrestricted use, distribution, and reproduction in any medium, provided the original work is properly cited. 

## References

- [1] Victor M, Adams RA, Collins GH. The Wernicke-Korsakoff Syndrome and Related Disorders Due to Alcoholism and Malnutrition. Philadelphia: FA Davis; 1989
- [2] Hutcheon DA. Malnutrition-induced Wernicke's encephalopathy following a water-only fasting diet. *Nutrition in Clinical Practice*. 2015;**30**:92-99
- [3] Harper CG, Giles M, Finlay-Jones R. Clinical signs in the Wernicke-Korsakoff complex: A retrospective analysis of 131 cases diagnosed at necropsy. *Journal of Neurology, Neurosurgery, and Psychiatry*. 1986;**49**:341-345
- [4] Caine D, Halliday GM, Kril JJ, Harper CG. Operational criteria for the classification of chronic alcoholics: Identification of Wernicke's encephalopathy. *Journal of Neurology, Neurosurgery, and Psychiatry*. 1997;**62**:51
- [5] Rauscher C. Canadian Family Physician. Malnutrition among the Elderly. 1993;**39**:1395-1403
- [6] White JV, Guenter P, Jensen G, et al. Consensus statement: Academy of nutrition and dietetics and American Society for Parenteral and Enteral Nutrition: Characteristics recommended for the identification and documentation of adult malnutrition (undernutrition). *Journal of Parenteral and Enteral Nutrition*. 2012;**36**:275
- [7] Ritchie H, Roser M. Micronutrient Deficiency. 2018. Published online at OurWorldInData.org. Retrieved from: <https://ourworldindata.org/micronutrient-deficiency>
- [8] van Tonder E, Gardner L, Cressey S, Tydeman-Edwards R, Gerber K. Adult malnutrition: Prevalence and use of nutrition-related quality indicators in south African public-sector hospitals. *South African Journal of Clinical Nutrition*. 2017;**32**(1):1-7
- [9] Bernard M, Rombeau J. Nutritional support for the elderly patient. In: Young E, editor. *Nutrition, Ageing and Health*. New York: Alan R. Liss Inc; 1986. pp. 229-258
- [10] Saunders J, Smith T, Stroud M. Malnutrition and undernutrition. *Medicine*. 2011;**39**:45-50
- [11] Department of Health and Social Security. Dietary Reference Values for Food Energy and Nutrients for the United Kingdom. Report on Health and Social Subjects, no. 41. London: HMSO; 1991
- [12] Smidt LJ, Cremin FM, Grivetti LE, Clifford AJ. Influence of thiamin supplementation on the health and general well-being of an elderly Irish population with marginal thiamin deficiency. *Journal of Gerontology*. 1991;**46**:M16-M22
- [13] O'Keeffe ST. Thiamine deficiency in elderly people. *Age and Ageing*. 2000;**29**:99-101
- [14] Zarranz JJ, Pérez-Concha T. Enfermedades carenciales. In: Zarranz JJ, editor. *Neurologia*. 3rd ed. Madrid: Elsevier Science; 2003. pp. 879-886
- [15] Diop AG, Millogo A, Obot I, Thiam I, Tylleskar T. Neurological disorders associated with malnutrition. In: Aarli JA, Avanzini G, Bertolote JM, de Boer H, Breivik H, Dua T, et al., editors. *Neurological Disorders: Public Health Challenges*. World Health Organization, Geneva. 2006. p. 111-126
- [16] Tanphaichitr V. Thiamin. In: Shils ME, Olson JA, Shike M, Ross AC,

editors. *Modern Nutrition in Health and Disease*. 9th ed. Baltimore: Williams and Wilkins; 1999. pp. 381-389

[17] Thomson AD, Cook CCH, Touquet R, Henry JA. The Royal College of Physicians report on alcohol: Guidelines for managing Wernicke's encephalopathy in the accident and emergency department. *Alcohol and Alcoholism. Supplement*. 2002;**37**:513-521

[18] Martin PR, Singleton CK, Hiller-Sturmhöfel S. The role of thiamine deficiency in alcoholic brain disease. *Alcohol Research & Health*. 2003;**27**:134

[19] McLean J, Manchip S. Wernicke's encephalopathy induced by magnesium depletion. *Lancet*. 1999;**353**:1768

[20] So YT, Aminoff MJ, Wilterdink JL. Wernicke encephalopathy. *UpToDate* May 2019;1-18

[21] Goor C, Endtz LJ, Muller Kobold MJ. Electro-nystagmography for the diagnosis of vestibular dysfunction in the Wernicke-Korsakow syndrome. *Clinical Neurology and Neurosurgery*. 1975;**78**:112

[22] Charness ME. Intracranial voyeurism: Revealing the mammillary bodies in alcoholism. *Alcoholism, Clinical and Experimental Research*. 1999;**23**:1941

[23] Park SH, Kim M, Na DL, Jeon BS. Magnetic resonance reflects the pathological evolution of Wernicke encephalopathy. *Journal of Neuroimaging*. 2001;**11**:406

[24] Yoneoka Y, Takeda N, Inoue A, et al. Acute Korsakoff syndrome following mammillothalamic tract infarction. *AJNR. American Journal of Neuroradiology*. 2004;**25**:964

[25] Renou P, Ducreux D, Batouche F, Denier C. Pure and acute Korsakoff

syndrome due to a bilateral anterior fornix infarction: A diffusion tensor tractography study. *Archives of Neurology*. 2008;**65**:1252

[26] Magalhães Scoralick F, Louzada LL, Toledo MA, Ruback M. Wernicke's encephalopathy as a complication of Chagas mega esophagus. *Journal of Aging Research & Clinical Practice*. 2012;**1**(2):178-180

[27] Chidlovskii E, Tahar A, Deschasse G, Couturier P. Wernicke's encephalopathy associated with pellagra encephalopathy: Rare and unusual complication in an elderly hospitalized for aspiration pneumonia. *La Revue de médecine interne*. 2012;**33**:453-456

[28] Hata Y, Takeuchi Y, Kinoshita K, Nishida N. An autopsy case of acute and nonalcoholic thiamine-deficient encephalopathy. *European Neurology*. 2014;**71**:230-232

[29] Terada N, Kinoshita K, Taguchi S, Tokuda Y. Wernicke encephalopathy and pellagra in an alcoholic and malnourished patient. *BML Case Reports*. 2015:Oct 21. DOI: 10.1136/bcr-2015-209412

[30] Nariai H, Mittelman E, Farmakidis C, Zampolin RL, Robbins MS. Bithalamic dysfunction in Wernicke's encephalopathy. *The Einstein Journal of Biology and Medicine*. 2016;**31**:23-24

[31] Yokote K, Yamanouchi H, Mizutani T, Shimada H. Clinical characteristics of Wernicke's encephalopathy in the elderly. *Nihon Ronen Igakkai Zasshi*. 1992;**29**:35-40

[32] Ros Forteza FJ, Cabrera H, Bousende M. Malnutrition and Wernicke encephalopathy in the elderly. *Neurología*. 2018;**34**:543-546. DOI: 10.1016/j.nrleng.2018.11.005

[33] Galvin R, Brathen G, Ivashynka A, Hillbom M, Tanasescu R, Leone MA.

EFNS guidelines for diagnosis, therapy and prevention of Wernicke encephalopathy. *European Journal of Neurology*. 2010;**17**:1408-1418

[34] Gascón-Bayarri J, Campdelacreu J, García-Carreira MC, Estela J, Martínez-Yélamos S, Palasí A, et al. Encefalopatía de Wernicke en pacientes no alcohólicos: una serie de 8 casos. *Neurología*. 2011;**26**:540-547

[35] McLean J, Manchip S. Wernicke's encephalopathy induced by magnesium depletion. *The Lancet*. 1999;**353**:1768

[36] Lam JR, Schneider JL, Zhao W, Corley DA. Proton pump inhibitor and histamine 2 receptor antagonist use and vitamin B12 deficiency. *Journal of the American Medical Association*. 2013;**310**:2435-2442

[37] Skullerud K, Andersen SN, Lundevall J. Cerebral lesions and causes of death in male alcoholics. A forensic autopsy study. *International Journal of Legal Medicine*. 1991;**104**:209-213

[38] Charness ME. Intracranial voyeurism: Revealing the mammillary bodies in alcoholism. *Alcoholism, Clinical and Experimental Research*. 1999;**23**:1941

[39] Zuccoli G, Pipitone N. Neuroimaging findings in acute Wernicke's encephalopathy: Review of the literature. *American Journal of Roentgenology*. 2009;**192**:501-508

[40] Dhir S, Tarasenko M, Napoli E, Giulivi C. Neurological, psychiatric and biochemical aspects of thiamine deficiency in children and adults. *Frontiers in Psychiatry*. 2019;**10**:207. DOI: 10.3389/fpsyt.2019.00207

[41] Chen L, Yee SW, Giacomini KM. OCT1 in hepatic steatosis and thiamine disposition. *Cell Cycle*. 2015;**14**:283-284. DOI: 10.1080/15384101.2015.1006532