

# We are IntechOpen, the world's leading publisher of Open Access books Built by scientists, for scientists

**4,800**

Open access books available

**122,000**

International authors and editors

**135M**

Downloads

Our authors are among the

**154**

Countries delivered to

**TOP 1%**

most cited scientists

**12.2%**

Contributors from top 500 universities



**WEB OF SCIENCE™**

Selection of our books indexed in the Book Citation Index  
in Web of Science™ Core Collection (BKCI)

Interested in publishing with us?  
Contact [book.department@intechopen.com](mailto:book.department@intechopen.com)

Numbers displayed above are based on latest data collected.

For more information visit [www.intechopen.com](http://www.intechopen.com)



# Meniere's Disease: Nonsurgical Treatment

*Yetkin Zeki Yilmaz, Begum Bahar Yilmaz  
and Aysegul Batioglu-Karaaltın*

## Abstract

Meniere's disease or syndrome is one of the most common inner ear diseases. Meniere's disease is characterized by episodic vertigo, sensorineural hearing loss that fluctuates during episodes, tinnitus, and ear fullness. Ideal treatment should stop vertigo attacks, restore hearing, get rid of tinnitus and ear fullness. Treatment options are decided upon the remaining hearing, severity, and intensity of vertigo attacks. Meniere's disease is progressive on hearing levels of the patient; some of them develop profound hearing loss that also could affect the other ear. In order to plan a treatment scheme for patient, these conditions should be assessed. It has a destructive and progressive nature, so the first step of treatment should contain more conservative treatment options. If symptom control could not be obtained, destructive treatment options should be considered.

**Keywords:** Meniere's disease, lifestyle changes, Meniett, vestibular rehabilitation, neuro-otology

## 1. Introduction

Meniere's disease was first described by Prosper Meniere in 1861 [1]. He described series of symptoms of a leukemic patient, and he suggested that vertiginous symptoms were caused by hemorrhage in the inner ear [2]. Knapp hypothesized inner ear hydrops, but its histologic confirmation was demonstrated in 1938 [3]. Still today, Meniere's disease etiology is not clear.

Meniere's disease is characterized by episodic vertigo, sensorineural hearing loss that fluctuates during episodes, tinnitus, and ear fullness. Some of the patients develop drop attacks called Tumarkin crisis, also known as otolithic crisis, and nausea [4, 5].

Meniere's disease or syndrome is one of the most common inner ear diseases. Its prevalence reported 3.5–513 per 100,000 in USA series [6]. It shows slightly female predominance 1.89:1 [7]. It is more common in white and older population; peak age is in the fourth and fifth decade but some early onset cases in children are reported [8, 9].

Meniere's usually starts in one ear, but bilateral disease is not uncommon. It may occur many years after the unilateral symptoms first started. Its prevalence is unclear and reported from 2 to 78% [9]. Familial Meniere's disease has been reported in 10–20% of cases [10]. Meniere's disease is strongly associated with Meniere's disease so as allergies.

Till this day, an effective treatment protocol is not established, because the pathogenesis of Meniere's disease is not clear.

## **2. Pathogenesis**

Most common histopathologic finding is “endolymphatic hydrops” but the exact pathology is unknown. The Committee on Hearing and Equilibrium of American Academy of Otolaryngology Head and Neck Surgery's (AAO-HNS) definition of certain Meniere's disease contains histopathological confirmation of endolymphatic hydrops [11].

Endolymph is produced by stria vascularis in the cochlea and by the dark cells in the vestibular labyrinth [12]. In autopsy studies, endolymphatic hydrops was observed in the temporal bones of patients who were diagnosed Meniere's disease, but not all individuals who had endolymphatic hydrops developed Meniere's disease symptoms [13, 14]. Perisaccular fibrosis and decreased endolymphatic duct size are observed in some of the patients. The CT images showed that individuals have hypoplastic endolymphatic sac and duct and inadequate periaqueductal pneumatization [15]. MRI studies showed that patients with Meniere's disease have significantly smaller and shorter drainage system [16]. After gadolinium enhancement, enhancement of endolymphatic sac and periventricular space was demonstrated in MRI [17, 18]. Nakashima et al. designed a study to demonstrate endolymphatic hydrops in Meniere's disease in 3 Tesla MRI. Gadolinium was injected transtympanically and MR images were taken a day after. They observed that the gadolinium moves first into the perilymphatic space and that can reveal the border between endolymph and perilymph. They successfully showed the endolymphatic hydrops in these patients [19]. Naganawa et al. study demonstrated same results with 1.5 Tesla MRI after intravenous administration of gadolinium. They reported their waiting time is much shorter (4 hours after contrast enhancement) and 95% success rate, while the intratympanic gadolinium method's rate of success is reported as 80–90% [20]. Imaging is also important as it helps in differential diagnosis of the other cases that could cause unilateral hearing loss, vertigo such as vestibular schwannoma.

It is hypothesized that the ruptures of membranous labyrinth and cicatrization in healing process could cause the drain blockage that leads to endolymphatic hydrops [21, 22]. Schuknecht explained that, the ruptures of membranous labyrinth cause the leakage of potassium enriched endolymph to perilymph depolarize the nerve cells. Acute inactivation results with hearing loss and vertigo, after healing process of the chemical distribution of ions normalize; so the effects are reversible. Since the Meniere's disease takes its course through lifetime, the effects on the inner ear is irreversible at some point, so the hearing loss is permanent and vertigo attacks subdue [23]. However, this theory is not accepted by all; some authors suggested that ruptures are occurred rarely and not adequate to explain all the symptoms [24].

## **3. Etiology**

Meniere's syndrome is the triad; fluctuating hearing loss, tinnitus, and episodes of vertigo; if the cause is unknown it is defined as Meniere's disease [25]. In experimental studies, the blockage of endolymphatic duct and its lead to endolymphatic hydrops is shown in animals. In order to create this, mechanical blockage, viral inoculation, and immune response-induced inflammation are used [26].

Some of the studies suggested that allergy and Meniere's disease could be linked. Derebery et al. studied patients who were diagnosed with Meniere's disease. The skin prick test results were positive of 41% of these patients, which were three times higher than general population [27]. Some mechanisms were proposed in order to explain the link between allergy and Meniere's disease.

1. The fenestrated blood vessels that are located in endolymphatic sac allow the antigen to enter that leads to mast cell degranulation. Inflammation around the perisaccular fibrous tissue and release of histamine cause vasodilatation and increase the secretion that causes endolymphatic sac resorption capacity over rules.
2. Immune complexes that enter the endolymphatic sac circulation through this fenestrated vessels start inflammation and increase vascular permeability.
3. Waldeyer's ring stimulated by viral antigens triggers T-cell migration to endolymphatic sac and leads to inflammation and excretion of fluid production [28].

In order to demonstrate this relationship, Derebery et al. investigated the effects of allergen immunotherapy and elimination of food allergens in Meniere's disease patients. Their results were surprisingly positive. They reported that the improvement of symptoms of Meniere's disease and allergic symptoms were significant [29].

Another mechanism that is suggested is viral infection; however, no specific virus is identified [30].

Ischemia is another factor that is suggested in Meniere's disease mechanism [31]. Migraine and Meniere's disease link by vascular mechanism [32].

## **4. Diagnosis**

In order to plan a treatment algorithm for Meniere's disease, it is important to diagnose it accurately. Diagnostic investigation is not bound to only one test result. The Committee on Hearing and Equilibrium of the AAO-HNS has described the symptoms. As per AAO-HNS, the major symptoms of Meniere's disease are vertigo, hearing loss, and tinnitus [11].

### **4.1 Vertigo**

Spontaneous, rotational vertigo that last at least 20 minutes accompanied usually with nausea and vomiting which are the definitive spells of Meniere's disease. During the spell, horizontal or horizontal rotatory nystagmus is observed.

### **4.2 Hearing loss**

Fluctuating hearing loss, commonly in low frequencies, is the most common audiological finding. In some cases, hearing loss is progressive and is usually unilateral.

Hearing loss is described as:

- the arithmetic mean of hearing thresholds of 250, 500, and 1000 Hz which is 15 dB or higher than the average of 1000, 2000, and 3000 Hz; or,

- average threshold of 500, 1000, 2000, and 3000 Hz which is 20 dB or higher in poorer ear in unilateral cases; or
- average threshold of 500, 1000, 2000, and 3000 Hz which is higher than 25 dB in bilateral cases.

About 10 dB change or more or 15% or more change in speech discrimination rate is considered clinically significant.

One of the prognostic factors that affects hearing function is duration of the disease [33]. It is documented by most of the authors [34–36]. Age is also an independent prognostic factor to determine hearing function and its responsiveness to medical treatment [37].

### 4.3 Tinnitus and aural fullness

It could be confirmed with the patients' history. Tinnitus is commonly of a low-frequency type [38]. Sometimes, patients describe it to be localized in affected ear or sense it in the whole head. Patients describe tinnitus differently from each other [39].

### 4.4 Clinical presentation

The initial symptom of Meniere's disease can be vertigo (37%), tinnitus (18%), fluctuating hearing loss (20%), or any combination of these. Only 25% of cases start with all of these symptoms [40].

Most of the patients describe recurrent vertigo attacks (96.2%) with tinnitus (91.1%) and ipsilateral hearing loss (87.7%) [41]. Most of the crippling symptom is vertigo. In an acute attack, it tends to stay 20 minutes to 24 hours [42].

The beginning of the Meniere's disease differs from patient to patient as well as the course of the disease. It is found that vertigo stops in 57% of the patients in 2 years and 71% of the cases in 8.3 years after the first onset [43].

Detailed clinical history should be taken as the first and most important step for diagnosis. Most of the distressing symptom is vertigo. It is usually present in horizontal axis, accompanied with nausea and vomiting. During this attack, horizontal or horizontal rotatory nystagmus could be observed.

Some of the patients could describe sudden drop attacks which were described by Tumarkin, and this symptom is named after him also called otolithic crisis of Tumarkin. This symptom is caused by utriculosaccular dysfunction [44]. Sudden changes in vertical gravity reference cause postural adjustments via vestibulospinal pathway and end up with sudden fall [45]. About 2–6% of patients with Meniere's disease were reported to experience drop attack [46].

Second common symptom is hearing loss usually accompanied with tinnitus and ear fullness sensation. Hearing loss is fluctuating, most in low frequencies and tends to be progressive; however, only 1–2% of patients end up with profound hearing loss [47]. Additionally, 43.6% of the patients have different perception of hearing between ears (diplacusis) and 56% recruitment [25].

Tinnitus description could be different between patients but it is usually nonpulsatile and could be continuous or appears only during the attack, or could get worse during the attacks.

The AAO-HNS Committee on Hearing and Equilibrium suggested staged diagnosis for Meniere's disease. They suggested to group patients in the order of their symptoms as possible, probable, definite, and certain Meniere's disease [11] (**Table 1**).

Possible Meniere's disease	<ul style="list-style-type: none"> <li>• Episodic vertigo without documented hearing loss, or</li> <li>• Sensorineural hearing loss (fluctuating or flat) with disequilibrium but without definitive vertigo attacks</li> </ul>
Probable Meniere's disease	<ul style="list-style-type: none"> <li>• One definite vertigo episode</li> <li>• Documented hearing loss at least once</li> <li>• Tinnitus or ear fullness</li> </ul>
Definite Meniere's disease	<ul style="list-style-type: none"> <li>• Two or more definite vertigo attacks lasted at least 20 minutes</li> <li>• Documented hearing loss at least one</li> <li>• Tinnitus or ear fullness</li> </ul>
Certain Meniere's disease	<ul style="list-style-type: none"> <li>• Definite Meniere's disease</li> <li>• Histopathological confirmation of endolymphatic hydrops</li> </ul>

**Table 1.**  
 Diagnosis of Meniere's disease.

Probable Meniere's disease	<ul style="list-style-type: none"> <li>• Two or more spontaneous episodes of vertigo (each lasts 20 minutes to 24 hours)</li> <li>• Fluctuating aural symptoms on the affected ear (tinnitus, hearing loss, or aural fullness)</li> <li>• Other vestibular diseases were excluded</li> </ul>
Definite Meniere's disease	<ul style="list-style-type: none"> <li>• Two or more spontaneous episodes of vertigo (each lasts 20 minutes to 12 hours)</li> <li>• Low- to mid-frequency sensorineural hearing loss in affected ear (documented with audiometry) at least on one occasion (before, during, or after the vertigo episode)</li> <li>• Fluctuating aural symptoms on the affected ear (tinnitus, hearing loss, or aural fullness)</li> <li>• Other vestibular diseases were excluded</li> </ul>

**Table 2.**  
 Amended 2015 criteria for diagnosis of Meniere's disease.

The AAO-HNS Committee on Hearing and Equilibrium revised their diagnostic criteria in 2015. The new definition of "Definite" and "Probable" Meniere's disease is summed up in **Table 2** [48].

#### 4.4.1 Diagnostic workup

To treat Meniere's disease successfully, diagnosis should be confirmed. There is not a single test exists to confirm Meniere's disease alone, so the patient should be evaluated with possible diagnostic tests.

#### 4.4.2 Videonystagmography

Eye movements are observed after caloric or vestibular stimulation. Caloric response is found to decrease in 48–73.5% of the patients' affected ear, and complete absence is reported in 6–11% of patients [49, 50].

#### 4.4.3 Electrocochleography

Summation potentials are larger and more negative in Meniere's disease. Most valuable ratio is summation potential/action potential. SP/AP ratio is found to be increased in Meniere's disease. However, this is not definitive, and only 62% of patients with Meniere's disease have elevated ratios [51].

#### 4.4.4 Dehydrating agents

Dehydrating agent such as glycerol, urea used to reduce endolymph volume and improvement of symptoms were such as improved hearing, reduction of SP negativity in electrocochleography, trying to be observed. It is reported 60% sensitivity for Meniere's disease [52].

#### 4.4.5 Vestibular evoked myopotentials

Loud clicks are used to stimulate stapedial movement in order to stimulate the saccule. Stimulation saccule triggers the pathway that relaxes sternocleidomastoid muscle. Normal ear response is recorded as 500 Hz, and affected ear's response is recorded in elevated thresholds with flattened tuning [53].

The AAO-HNS's guideline is suggested in 1995 and does not contain these diagnostic vestibular battery; it is only suggested to the use of full audiometric workup.

One of the recent guidelines for diagnosis and treatment of Meniere's disease is from French Otorhinolaryngology-Head and Neck Surgery Society (SFORL) in 2016. They describe that "definite" Meniere's disease could be diagnosed if another cause could not be described to explain the following four clinical findings;

- two or more rotational vertigo attacks that last 2 minutes to 12 hours or, Tumarkin's crises;
- low-frequency hearing loss on two consecutive frequencies, 30 dB or more if the other ear hearing is normal, or 35 dB or more if hearing is affected bilaterally; and
- tinnitus or aural fullness; and
- fluctuating otologic findings.

MRI of inner ear is suggested to rule out cerebellopontine angle or endolymphatic sac tumors, anatomic deformity, or a degenerative pathology such as multiple sclerosis that could mimic the symptoms of Meniere's disease. Also audiovestibular workup could lead the clinician to intralabyrinthine pressure disorder. The workup should include at least pure-tone and speech audiometry with VNG or VEMP or VHIT [54].

## 5. Treatment

Ideal treatment should stop vertigo attacks, restore hearing, and get rid of tinnitus and ear fullness. Unfortunately, ideal treatment is absent nowadays. Our limited knowledge of pathophysiology of the disease makes it impossible to treat patients ideally. Also symptoms and course of the disease differ between patients, so treatment should be individualized.

The aim of the treatment is to reduce frequency and severity of vertigo attacks and improve hearing results [55]. All current treatment options are symptomatic.

Due to natural course of the disease, vertigo attacks of 60–80% of patients improve without any intervention [56, 57]. Patients who refused to take any medical or surgical assistance had spontaneous improvement of their symptoms at the rate of 71% [43]. Green et al. reported complete vertigo control in 50% of the

patients, partial control in 28% of the patients, and only 17% of their patient needed medical treatment in their 14 years of follow-up [58].

Treatment options are decided upon the remaining hearing, severity, and intensity of vertigo attacks. Meniere's disease is progressive on hearing levels of the patient; some of them develop profound hearing loss which also could affect the other ear. In order to plan a treatment scheme for a patient, these conditions should be assessed. It has destructive and progressive nature, so the first step of treatment should contain more conservative treatment options. If symptom control could not be obtained, destructive treatment options should be considered.

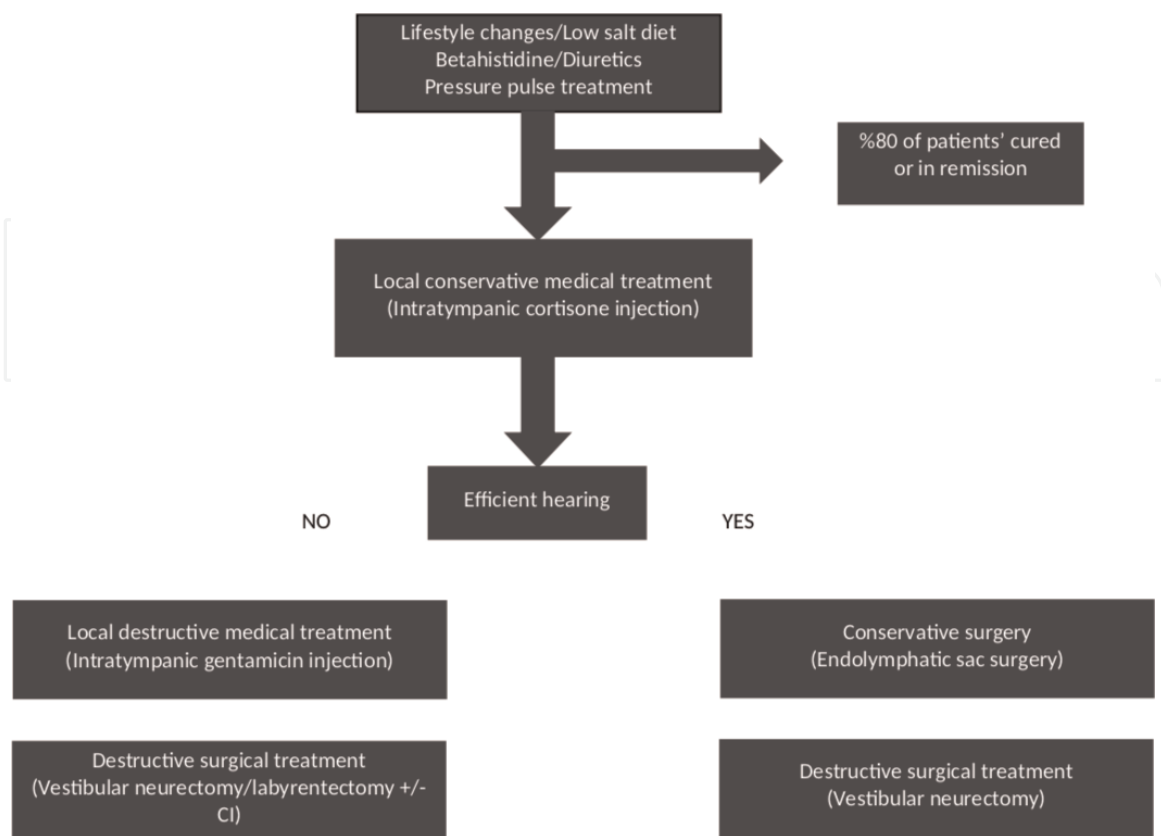
AAO-HNS suggested a staging system based on a four-tone average of 500, 1000, 2000, and 3000 Hz on the worst pure-tone audiometry, and this system should be obtained to the patients who were diagnosed with "definite" or "certain" Meniere's disease (**Table 3**) [11].

International Consensus (ICON) on treatment of the Meniere's disease proposed a treatment algorithm in 2018 (**Figure 1**) [59].

ICON's proposal for treatment algorithm summarizes the logic of the treatment for Meniere's disease. When the course of the disease is considered, Meniere's disease could make the affected ear to deteriorate and also could affect the other ear

Stage	Four-tone average (dB)
I	25 or less
II	26–40
III	41–70
IV	>70

**Table 3.**  
 Staging of definite and certain Meniere's disease.



**Figure 1.**  
 Treatment algorithm of Meniere's disease proposed by ICON in 2018.



at any time. Most logical approach for treatment is starting with less invasive option and assessing the patient periodically. If the suggested treatment fails, more invasive methods should be offered.

Also in SFORL guideline of treatment, a step-by-step approach from conservative to destructive is suggested.

If a patient seeks for medical attention during vertigo attack, treatment is symptomatic. The rest of the chapter contains nonsurgical treatment options, acute attack treatment, and vestibular rehabilitation options.

## 5.1 Preventive treatment options

### 5.1.1 Lifestyle changes and low salt diet

The first line of treatment is to encourage the patient to change his lifestyle into a healthier one. Regulation of sleeping cycle, avoiding stress, caffeine, alcohol, and tobacco, and changing into a low salt diet should be advised [60–62]. Caffeine is accused to increase the endolymph volume due to its sympathomimetic actions, and it is suggested to be restricted to 100 mg/day by AAO-HNS [63]. More active lifestyle should be offered, like taking at least 20 minutes of walking.

Low salt diet has been suggested to Meniere's disease patients since the 1930s, where daily intake of sodium is recommended to be under 2 grams [64, 65]. Low salt intake increases serum aldosterone levels [66]. It has been found that endolymphatic sac contains receptors for mineral corticoids [67]. Aldosterone controls Na/K ATPase, thiazide-sensitive Na/Cl co-transporter, and epithelial Na channels which are also expressed on endolymphatic sac [68–73]. It has been shown that canrenoate, an aldosterone antagonist, reduced electrical potentials of endolymphatic sac after applied [74, 75]. Elevation of aldosterone levels may increase the endolymph absorption [70]. However, restriction of salt intake could not be proven to change the levels of sodium of plasma and endolymph [64, 65, 76].

In Miyashita et al.'s study, Meniere's disease patients were grouped in order to their sodium intake. After initiation of low sodium diet, patients were observed for 2 years. Low sodium group (daily intake of 3 grams or less) had better hearing levels and less vertigo attacks than high sodium group (daily intake more than 3 grams). However, serum aldosterone levels were not different although low sodium group had higher serum levels [77].

Also Tadros and colleagues investigated elder population and those who had higher serum aldosterone levels had better hearing levels, and they suggested that aldosterone might have a protective effect on hearing [78].

Low sodium intake has known benefits on cardiovascular health; hence, there is no harm to suggest it.

### 5.1.2 Betahistine

Betahistine is a weak histamine H1 receptor agonist and a potent histamine H3 receptor antagonist.

It is suggested to improve microvascular circulation in stria vascularis that reduces the endolymph pressure [79], and it inhibits vestibular nuclei activity that results longer and easier recovery [80, 81]. It reaches its peak plasma concentration in 1 hour, and maximal therapeutic effects start in 3–4 hours after intake [82].

Betahistine is a popular agent in Europe and Japan. FDA does not approve its use in vertigo as it is not commonly used in the USA. Its beneficial effects are based on the clinical observation; some studies report favorable results on vertigo control and hearing improvement and some studies do not. In betahistine's case, literature

findings are controversial. In SFORL guideline, betahistine is suggested as the first line of treatment.

Tootoonchi et al. reported improvement of 6.35 dB in hearing levels after 6 months of betahistine administration [37]. However, patient's first hearing levels should be considered; if the patient has poor hearing levels at the first visit, he is less likely to benefit from the treatment [36]. Cochrane reviews support the positive effect of betahistine on vertigo attack frequency and hearing levels. They highlighted the fact that the investigated studies have serious study design flaws and tend to bias [83]. Therapeutic benefits of betahistine were reported in Nauta's meta-analysis [84].

BEMED study is a multi-central, placebo-controlled study that investigates the effects of betahistine. The results on vestibular symptoms were not any different compared to placebo [85]. In order to establish the benefits of betahistine, more well-designed, placebo-controlled studies are required.

Literature seems to be controversial but it is suggested as the first line of treatment in the European, French, and Japanese guidelines as its beneficial effects on patients are observed clinically.

### *5.1.3 Diuretics*

Another treatment agent widely used for Meniere's disease treatment is diuretics. Thiazide group of diuretics is usually suggested. The cells that produce endolymph, such as dark cells and stria vascularis, contain carbonic anhydrase. Carbonic anhydrase inhibitors like acetazolamide are recommended in order to reduce the production endolymph [86].

Recent systematic review on diuretics was conducted by Crowson and colleagues. They reviewed four retrospective studies. One of the studies compared betahistine and diuretics and reported improved results on vertigo in both groups but lack of placebo group [87]. In another study, diuretics showed beneficial effects on vestibular symptoms compared to placebo [88]. Another placebo-controlled retrospective study reported beneficial effects of hydrochlorothiazide on hearing loss and vertigo control [89]. Most of the studies have low level of evidence. Cochrane report in 2006 on diuretics reported beneficial but it highlighted the fact that most of the studies were lack of high quality of evidence [90]. However, studies indicate improvement in vertigo and lesser effect on hearing. Still they are suggested as the first line of treatment options in many guidelines.

### *5.1.4 Pulse pressure treatment*

Around three decades ago, it has been reported that positive pressure to middle ear could have helped release of Meniere's disease's symptoms [91]. The underlying mechanism is still unclear. Meniett device was introduced by Medtronic company in 2000 and approved by FDA for Meniere's disease treatment. After insertion of a ventilation tube, the device is placed to external ear canal and sends low-pressure pulses.

There are many studies about Meniett's effect on Meniere's disease and symptom control. Gates et al.'s randomized controlled studies showed benefits of Meniett device in short term. They demonstrated a significant decrease of vertigo attacks in first 3 months but this could not be observed in long term [92]. Other studies reached different conclusions about Meniett.

Ahsan et al. suggested that Meniett could be useful for Meniere's disease treatment, but Syed and van Sonsbeek were unable to show this effect in their randomized controlled studies where they compared the device effect to placebo [93–95].

Recent meta-analysis reported that Meniett device provided complete remission of 52% of patients and 34% of patients had not complete but significant release of symptoms [96]. This meta-analysis also investigated the suggested treatment protocols. Initiation of Meniett after 2 weeks of ventilation tube insertion seemed to have better control over the symptoms. Effects on vertigo seem to begin in first 6 months, reach its peak in 6–18 months, and stabilize after 18 months. Also it was observed that the shorter initiation of the therapy after placement of ventilation tube had a better effect on hearing preservation and vertigo control [96].

However, some authors have different opinions when it comes to ventilation tubes. They suggest that ventilation tube insertion alone could control Meniere's disease symptoms [97–100]. In hypoxia theory, it is hypothesized that vertigo attacks are triggered by anoxia in inner ear, which can decrease endolymphatic potentials and microcirculation of cochlea [101, 102]. Ventilation tube enriches middle ear oxygenation and helps anoxic environment of inner ear [103]. Also ventilation tube decreases the middle ear pressure, and it is hypothesized that this could help to balance the increased inner ear pressure that could lead to Meniere's attack [104]. It remains inconclusive that the decrease of symptoms after Meniett device is only from the ventilation tube or ventilation tube insertion alone. However, Zhang et al.'s meta-analysis reviewed studies that compare Meniett to placebo device and reached a conclusion. They report that if the interval between ventilation tube insertion and Meniett device is longer than 2 weeks, beneficial effects may be due to Meniett device alone [96].

Recent Cochrane database reviewed Meniett device-based studies that were published until 2014. Randomized controlled trials that compare Meniett and placebo devices were included in their study. Due to heterogeneity of data, calculation of outcome was reported not possible. Most of the studies found no significant difference between Meniett and placebo on vertigo control. Only one study showed a significant vertigo control after 8 weeks of usage of Meniett. Secondary outcomes like improvement on hearing, Meniett group significantly had better outcomes with 7.38 dB increase, effects on tinnitus and aural fullness could not be determined due to heterogeneity of data. Their conclusion is that data due to these studies are not adequate to determine the beneficial effects of Meniett [95].

Long-term results of Meniett device was published by Dornhoffer et al. Treated patients' improvement rates reported 75%, similar of untreated patients [105]. University of Colorado stated that the device is expensive and lacks cost-beneficiality [106].

None of the studies that investigated Meniett device reported any complications. Therefore it is harmless to propose this treatment. It is advised as the first-line treatment of ICON's guideline as well as Italian and Australian treatment algorithms [59, 95]. It is reported as the most common second-line treatment option in the USA [107]. With its potential benefits and low risk of complication rates, Meniett device could be advised to patients.

### *5.1.5 Ventilation tubes*

Though it is a surgical procedure, it is minimally invasive so its effects on Meniere's disease will be discussed in this chapter. After myringotomy of the anteroinferior quadrant of tympanic membrane, ventilation tube could be inserted as an office procedure. Sugawara et al. and Montandon et al. reported that ventilation tube insertion has control over Meniere's disease symptoms without further treatment [97, 98].

Kimura and Hutta's experimental study on guinea pigs is that the middle ear ventilation reduced endolymphatic hydrops. It is hypothesized that ventilation of middle ear decreases the pressure in middle and inner ear [103].

Tumarkin was the first physician who introduced ventilation tubes as a treatment option in 1966. Tumarkin also reported that eustachian tube dysfunction is correlated with endolymphatic hydrops and his data was supported by Lall [108, 109]. However, Cinnamond, Hall, and Brackmann reported that eustachian tube dysfunction was not always observed with Meniere's disease patients and insertion of ventilation tube could worsen the symptoms of patients [110, 111].

Montadon et al. reported that complete remission or improvement rates of their patients were 82%. They also reported that the patient whose ventilation tube blocked had recurrence of symptoms and immediate relief after reinsertion of ventilation tubes [98]. Thomsen published results of patients who received transmastoid endolymphatic decompression surgery compared with patients who were inserted ventilation tube. Each group had significant control over their symptoms but found no difference between these groups [112].

Among the most recent studies in literature in 2015, Ogawa et al. studied ventilation tube insertion and its effects on intractable Meniere's disease patients. All of their patients were treated medically at least 6 months before ventilation tube insertion was advised. After a year, 20% of their patients had complete remission, 47% had partial remission. Two years later, complete vertigo control rates increased to 47%. Secondary benefits of procedure on hearing levels had no significant difference. They reported that ventilation tube insertion could be beneficial and postponed more invasive procedures [100]. Therefore, it could be advised as a first-line surgical procedure to patients who have symptoms after medical treatment.

The SFORL guideline does not recommend this procedure due to lack of evidence [54]. Not considered in ICON's guideline or the European Position Statement on diagnosis and Treatment of Meniere's disease [59, 113].

However, it is worthwhile to try because literature findings of some authors showed beneficial effects and it is minimally invasive and has low-complication rates.

### *5.1.6 Intratympanic steroid injections*

Intratympanic steroid treatment will be discussed in later chapters.

## **5.2 Treatment of acute attacks**

It is important to control the effects and related vegetative symptoms of vertigo during acute attack. Meniere's attacks are sudden onset and could last 20 minutes to 24 hours. In order to suppress the symptoms, benzodiazepines, meclizine, or other antihistamines could be used [106]. Drugs that are used to suppress the symptoms of Meniere's disease have no effect on progression of the disease.

Antihistamines, such as dimenhydrinate, meclizine, benzodiazepines, and scopolamine, and anti-dopamines, which had antiemetic effects, such as metoclopramide and fenotiazines, are used to suppress the vestibular symptoms. These agents also have sedative effects that could help to reduce the patients' anxiety. Diazepam is effective on GABA receptors in vestibular nucleus and inhibits their response. It should only be used during acute attack because the long-term usage decreases vestibular compensation mechanisms. Dimenhydrinate could also provide relief during acute attack but it could affect concentration and cause dizziness in long term [114].

Diazepam inhibits vestibular response with its effect on GABA-ergic receptors located in cerebellar system [115]. However, clinical and experimental studies show that the long-term usage of diazepam prolongs the vestibular compensation [116, 117].

Meclizine is useful to reduce vegetative symptoms like nausea, benzodiazepines are also well tolerated anxiolytic, in order of intractable vomiting promethazine suppositories could be used [106].

Transdermal scopolamine patches reaches therapeutic blood level 4 hours after placement and release drug to system 72 hours; however, this could not be useful because of the attacks' sudden onset nature [118].

Intravenous lidocaine has found to be effective during acute attack of Meniere's disease [119].

### 5.3 Vestibular rehabilitation and psychological support

Meniere's disease is a chronic attack characterized by their sudden onset. It is observed by most of the physicians that it also burdens patients psychologically. Also it is observed that stress and anxiety could trigger the attacks. Increase of vertigo severity is associated with worse quality of life scores of Meniere's disease [120]. Most of the guidelines suggest psychological support and behavioral therapy for the patients so they could have a better understanding of their condition and help themselves to cooperate with this condition.

Van Crujisen et al. suggested that the symptoms could be worsened in negative emotional state [121]. Many studies reported the relation between symptoms and behavioral characteristics; the worse perception of the disease could create a vicious circle [122–124]. Patients suffering from Meniere's disease were found to be having more stress-causative behavioral characteristics than normal controls. This information leads to hypothesis that higher stress-related hormone levels could cause endolymphatic hydrops [124]. Another study by Van Crujisen that assesses the psychological state of Meniere's disease patients compared to patients who had chronic vestibular diseases documented that 63% of Meniere's disease patients had psychologic pathology, such as depression or anxiety, but found no significant difference between non-Meniere's disease patients. It is also reported that Meniere's disease patients quality of life questionnaire results were worse than normal results [125].

Yokota et al. studied the treatment outcomes of both surgical and nonsurgical treatment due to patients' psychological status. Patients who had no mental distress had benefitted from both of the treatments more than the patients who had mental problems. Also surgical treatment options tend to have been found more beneficial over nonsurgical treatment among the patients who had psychological disorders. In order to improve treatment results of both surgical and nonsurgical options, it is advised that psychological support is necessary [126].

Better understanding of the disease and psychological state and their relation with better results seem to be beneficial for patients. Healthier psychology, encouragement to participate in active life, and providing psychological support in any chronic illness are important to help patients to remain as functional individuals in the society.

Traditionally, vestibular rehabilitation is ineffective in episodic vertigo patients. Stable conditions are better candidates for successful rehabilitation. Due to its chronic and progressive nature, rehabilitation of these patients is tricky. In order to obtain rehabilitation, physical therapy must be customized. It is not advised to initiate a rehabilitation program in acute onset.

The success of rehabilitation depends on the patient. First step of a successful rehabilitation program is education of the patient. Each patient is unique, and their characteristics, mental status, and understanding capacity differ between each other. Patients have to be informed about their disease, its nature and treatment options. Detailed explanation should be given about the effectiveness of physical

therapy, coping mechanisms, and possible sequels for each person's understanding level. It is also important to correct the patient if they were misinformed [127].

Before customizing a rehabilitation program, the patient should be examined systemically. Mecagni et al.'s study demonstrated that limited ankle motion range affects the patient's performance on balance tests [127]. Lower extremities should be examined on their functional levels and sense of proprioception. Impaired vision could affect oculomotor functions negatively. In order to determine relationships between the input mechanisms of balance system, posturography could be used if it is available [128]. It is reported that static platform posturography is more sensitive and specific in Meniere's disease than caloric and rotational tests, both in diagnosing and detecting other deficits that accompany these patients' vestibular system [129, 130].

Although there is not a test battery that could predict the effects of attacks on patients daily life, most of the patients describe the attacks debilitating [131]. Most of the time attacks occur suddenly and being prepared for those attacks is important. It should be discussed with the patient about special sensations or feelings before the attack. At least half of the patients could identify a trigger [132]. In order to identify these conditions, a symptom diary could be advised.

Some protective advices should be given to the patient to be performed during the attack. Also most of the patients tend to close their eyes during the attack, and it should be taught that keeping their eyes open and targeting them onto something would help them to suppress nystagmus [127]. Instead of panicking over symptoms, they should be advised to stay calm and sit or lie down in order to prevent themselves from further injuries.

When the attack subdued, refractory effects could continue to debilitate the patient. The patient should be advised to avoid any sudden movements. In order to minimize the effects on their personal lifestyles, some modifications should be advised like performing daily activities, sitting instead of standing while cooking, dressing up, etc.

In order to prevent patients' social isolation, patients should be encouraged about informing their social circle about their condition. Also series of exercises should be programmed for each patient's current status, and patients should be encouraged to participate in social life. In our clinic, we advise our patients to go to a mall for window shopping. It helps patients to overcome their fear to be in public, helps them to use visual object to train their vestibulo-ocular system, and also improves their walking and sense of proprioception. In addition to these advices, if a specific problem was found on their posturography, it is consulted with related departments.

Rehabilitation and its importance are well documented in Meniere's disease patients who received a destructive protocol [133–135]. However, studies about the effects of vestibular rehabilitation on patients who suffer from post-vertigo disequilibrium are limited. Clendaniel and Tucci reported the importance of vestibular rehabilitation of patients after vertigo attack [136].

Gottshall et al.'s study demonstrated the beneficial effects of vestibular exercises on post-vertigo symptoms with unilateral Meniere's disease. Patients reported that their balance function was significantly improved, only experiencing subtle discomfort [137]. In bilateral disease, it is reported by Cohen et al. that vestibular rehabilitation was not effective and advised to evaluate other adaptive strategies with these patients [138].

Vestibular rehabilitation between attacks could help patients to cooperate with disease and help them to keep their functionality levels up. Vestibular rehabilitation's effect on patients' mental status is not reported in the current literature but logically it could improve mental health. Recent guidelines recommend behavioral therapies and vestibular rehabilitation programs.

## 5.4 Hearing loss and tinnitus in Meniere's disease

Meniere's disease symptoms are episodic vertigo attacks, fluctuating hearing loss, tinnitus, and ear fullness. Most disturbing symptom of this condition is vertigo according to most of the studies that evaluated the quality of life scores of the patients. So the preservation of hearing function and reducing the tinnitus intensity are always evaluated as secondary outcomes in studies. During follow-up of the patients, it is important to document hearing levels because remained hearing function is the key factor in decision-making process of the treatment.

One of the diagnostic criteria of Meniere's disease according to AAO-HNS's guideline is hearing loss.

It is recommended to stage the disease and underline as an important factor to monitor the treatment results [11].

In ICON's guideline, destructive treatment options are recommended if there is no functional hearing left [59]. Hearing loss is usually located in lower frequencies, and in early stages of the disease, it has a fluctuating pattern [139, 140]. In later phases, it could decrease, and after 5–10 years, hearing thresholds usually settle to 50–60 dB as well as speech discrimination scores decrease to 50–60% [141]. Tinnitus is mostly a low-frequency type due to hearing loss, which could be localized to affected ear and could be described globally [38]. Low-frequency tinnitus is difficult to be masked with environmental sounds [142].

Havia et al. reported the relationship between vertigo, hearing loss, and tinnitus. Patients with more profound hearing loss had worse outcomes on their posturography tests and caloric test responses found decreased on the affected ear [35]. Recent studies demonstrated that hearing loss in these patients is associated with sensory element degeneration [143].

The intensity of tinnitus reported to increase with duration symptoms. Intense tinnitus is found to be related with hearing loss specifically at 500 Hz. However, vertigo attack frequency or duration of the attacks was not related with tinnitus intensity [35]. Gentamicin injections proven to be effective to reduce the tinnitus but surgical interventions found to be ineffective on tinnitus control [144, 145]. In order to compensate with tinnitus, behavioral therapy should be advised. Betahistine and nasal oxytocin were studied in Meniere's disease and they reported to decrease tinnitus perception but data are limited [146, 147]. Cochlear implants have reported that they decrease tinnitus significantly; although the data are limited and still relatively new, it is reported to decrease tinnitus of patients after 6 months [148].

## 5.5 Treatment of bilateral Meniere's disease

Bilateral Meniere's disease prevalence is reported in 2–47% of the cases, and it could occur after several years of the first onset of the disease [9]. Temporal bone studies suggest that bilateral Meniere's disease incidence is higher and bilateral endolymphatic hydrops observed 25–30% of the inspected temporal bones [149–151]. Bilateral Meniere's disease should be treated conservatively; bilateralization could occur at any time, and there is no test that could prevent this. This condition is the main reason of the emphasis on being conservative while choosing the treatment option.

Meniere's disease rarely start bilaterally, it usually starts with unilaterally [152–154]. Most of the cases, contralateral involvement occurs after 2–5 years after the first initiation of symptoms [155]. Clinical presentation of these cases is different from each other. Most important step in diagnosis is suspicion and knowledge of the possible nature of the disease could affect the contralateral side at some point of patients' follow-up. Severity of the disease should be established independently for

each ear, in pure-tone audiometry average of 500, 1000, 2000, and 3000 Hz >25 dB [11]. Tinnitus is reported to be more intense in bilateral Meniere's patients. Also they reported that patients who had bilateral Meniere's disease had significantly longer history of disease and worse pure-tone average [35].

In EcoG, Iseli and Gibson reported that summation potential/action potential ratio has a limited value to determine endolymphatic hydrops and should be combined with summation potential amplitude and summing potential bias ratio [156]. Lin et al. proposed to combine VEMP tuning and VEMP thresholds to detect the hydrops in the contralateral ear before the symptoms' onset [157]. In imaging, studies suggest that affected side has endolymphatic dilatation and due to this perilymph volume seem decreased [158]. Combination of these diagnostic strategies could help physicians to detect bilateral involvement and avoid from destructive procedures in suspected patients.

In ICON's guideline, they reported that the bilateral tendency of the disease attributed as an important factor of most clinic treatment protocol shift from intratympanic gentamicin to intratympanic steroid. Also as a surgical treatment option, endolymphatic sac procedures are recommended for bilateral Meniere's disease [59]. In SFORL guideline, gentamicin injections are contraindicated in single intact ear or bilateral Meniere's disease. They recommend endolymphatic sac surgery if medical treatments failed in bilateral Meniere's disease. Destructive surgeries such as vestibular neurectomy and labyrinthectomy are not recommended in bilateral Meniere's disease [54].

Treatment options of bilateral disease are restricted. Conservative treatment options should be advised and symptomatic treatment should be prescribed during attack. Peterson et al. conduct a survey study among American otorhinolaryngologists about their choice of treatment with patient who had only hearing ear and most common option is Meniett device when other conservative treatment options failed. After Meniett, intratympanic steroid injection comes second in their choice of treatment. Endolymphatic sac procedures come in third; first decompression is advised than shunt procedures. Selective vestibular nerve section comes later [107].

Intratympanic steroid injection could be advised to patients with bilateral Meniere's disease. Recent randomized controlled study conducted in 2005 reported that intratympanic steroid injections are the effective way of treatment [159]. However, another study found no difference between intratympanic steroid injection and saline injection [160, 161]. The literature findings are controversial.

Intravenous streptomycin sulfate in debilitating bilateral Meniere's disease reported to reduce the symptoms [162–164]. If complete or near complete bilateral hypo-function has occurred, streptomycin sulfate is found to be effective [163]. Immune-mediated bilateral Meniere's disease is a subgroup of Meniere's disease, and methotrexate treatment is found to be effective on symptom control [165]. Another treatment option for immune-mediated group is systemic steroids, its efficacy is reported in a few studies [153, 166–170]. Prospective study on treatment of bilateral Meniere's disease with systemic steroids reported significant improvement on decrease in vertigo attacks but had no effect on hearing loss or tinnitus or aural fullness [170].

Surgical option of these patients is endolymphatic sac surgery; it has lowest complication rates on sensorineural hearing loss, <2% [171]. Kitahara et al.'s study reported the results of patients who had endolymphatic sac drainage with and without insertion of steroid induced silastic and nonsurgical group. The vertigo control rates were similar in surgery groups with or without steroid, but hearing levels of steroid group had better long-term results than nonsteroid surgery group and nonsurgical group [172]. Their findings were also supported with review of Wetmore. In order of retractable disease ablative surgeries combined with cochlear implant insertion should be considered.



IntechOpen

IntechOpen

### **Author details**

Yetkin Zeki Yilmaz\*, Begum Bahar Yilmaz and Aysegul Batioglu-Karaaltın  
Istanbul University-Cerrahpasa Medical Faculty ENT, Istanbul, Turkey

\*Address all correspondence to: [dr\\_yzy@hotmail.com](mailto:dr_yzy@hotmail.com)

### **IntechOpen**

---

© 2019 The Author(s). Licensee IntechOpen. This chapter is distributed under the terms of the Creative Commons Attribution License (<http://creativecommons.org/licenses/by/3.0>), which permits unrestricted use, distribution, and reproduction in any medium, provided the original work is properly cited. 

## References

- [1] Pearce JMS. Marie-Jean-Pierre Flourens (1794-1867) and cortical localization. *European Neurology*. 2009; **61**(5):311-314. DOI: 10.1159/000206858
- [2] Baloh RW. Prosper Ménière and his disease. *Archives of Neurology*. 2001. DOI: 10.1001/archneur.58.7.1151
- [3] Knapp HJ. *A Clinical Analysis of the Inflammatory Affections of the Inner Ear.*; 1871
- [4] Perez-Fernandez N, Montes-Jovellar L, Cervera-Paz J, Domenech-Vadillo E. Auditory and vestibular assessment of patients with Ménière's disease who suffer Tumor attacks. *Audiology and Neurotology*. 2010. DOI: 10.1159/000310899
- [5] Hägnebo C, Andersson G, Melin L. Correlates of vertigo attacks in Meniere's disease. *Psychotherapy and Psychosomatics*. 1998. DOI: 10.1159/000012296
- [6] Alexander TH, Harris JP. Current epidemiology of Meniere's syndrome. *Otolaryngologic Clinics of North America*. 2010. DOI: 10.1016/j.otc.2010.05.001
- [7] Shojaku H, Watanabe Y, Fujisaka M, et al. Epidemiologic characteristics of definite Ménière's disease in Japan: A long-term survey of Toyama and Niigata prefectures. *ORL; Journal for Oto-rhino-laryngology and its Related Specialties*. 2005. DOI: 10.1159/000089413
- [8] Choung YH, Park K, Kim CH, Kim HJ, Kim K. Rare cases of Ménière's disease in children. *The Journal of Laryngology and Otology*. 2006. DOI: 10.1017/S0022215106000569
- [9] House JW, Doherty JK, Fisher LM, Derebery MJ, Berliner KI. Meniere's disease: Prevalence of contralateral ear involvement. *Otology & Neurotology*. 2006. DOI: 10.1097/00129492-200604000-00011
- [10] Morrison AW, Mowbray JF, Williamson R, Sheeka S, Sodha N, Koskinen N. On genetic and environmental factors in Ménière's disease. *The American Journal of Otology*. 1994
- [11] Committee on Hearing and Equilibrium. Committee on hearing and equilibrium guidelines for the diagnosis and evaluation of therapy in Meniere's disease. *Otolaryngology-Head and Neck Surgery*. 1995; **113**(3):181-185. DOI: 10.1016/S0194-5998(95)70102-8
- [12] Jansson B, Rask-Andersen H. Erythrocyte removal and blood clearance in the endolymphatic sac. An experimental and TEM study. *Acta Oto-Laryngologica*. 1996
- [13] Rauch SD, Merchant SN, Thedinger BA. Meniere's syndrome and endolymphatic hydrops: Double-blind temporal bone study. *The Annals of Otology, Rhinology, and Laryngology*. 1989. DOI: 10.1177/000348948909801108
- [14] Wackym PA. Histopathologic findings in Meniere's disease. *Otolaryngology and Head and Neck Surgery*. 1995. DOI: 10.1016/S0194-5998(95)70307-1
- [15] Valvassori GE, Dobben GD. Multidirectional and computerized tomography of the vestibular aqueduct in Meniere's disease. *The Annals of Otology, Rhinology, and Laryngology*. 1984. DOI: 10.1177/000348948409300604
- [16] Albers FWJ, Van Weissenbruch R, Casselman JW. 3DFT-magnetic resonance imaging of the inner ear in Meniere's disease. *Acta*

- Oto-Laryngologica. 1994. DOI: 10.3109/00016489409126111
- [17] Fitzgerald DC, Mark AS. Endolymphatic duct/sac enhancement on gadolinium magnetic resonance imaging of the inner ear: Preliminary observations and case reports. *The American Journal of Otology*. 1996
- [18] Carfrae MJ, Holtzman A, Eames F, Parnes SM, Lupinetti A. 3 Tesla delayed contrast magnetic resonance imaging evaluation of Meniere's disease. *The Laryngoscope*. 2008. DOI: 10.1097/MLG.0b013e31815c1a61
- [19] Nakashima T, Naganawa S, Sugiura M, et al. Visualization of endolymphatic hydrops in patients with Meniere's disease. *The Laryngoscope*. 2007;117(3):415-420. DOI: 10.1097/MLG.0b013e31802c300c
- [20] Naganawa S, Nakashima T. Visualization of endolymphatic hydrops with MR imaging in patients with Ménière's disease and related pathologies: Current status of its methods and clinical significance. *Japanese Journal of Radiology*. 2014; 32(4):191-204. DOI: 10.1007/s11604-014-0290-4
- [21] Schuknecht HFIM. Pathophysiology of Meniere's disease. In: Pfaltz CR, editor. *Controversial Aspects of Meniere's Disease*. New York: Georg Thieme; 1986
- [22] Flock Å, Flock B. Micro-lesions in Reissner's membrane evoked by acute hydrops. *Audiology & Neuro-Otology*. 2003. DOI: 10.1159/000069002
- [23] Schuknecht HF. The pathophysiology of Meniere's disease. *The American Journal of Otology*;5(6): 526-527
- [24] Brown DH, McClure JA, Downar-Zapolski Z. The membrane rupture theory of Ménière's disease—is it valid? *The Laryngoscope*. 1988. DOI: 10.1288/00005537-198806000-00003
- [25] Paparella MM. Pathogenesis of Meniere's disease and Meniere's syndrome. *Acta Oto-Laryngologica*. 1983. DOI: 10.3109/00016488309122996
- [26] Kimura RS. Animal models of inner ear vascular disturbances. *American Journal of Otolaryngology - Head and Neck Medicine and Surgery*. 1986. DOI: 10.1016/S0196-0709(86)80042-4
- [27] Derebery MJ, Berliner KI. Prevalence of allergy in Meniere's disease. *Otolaryngology-Head and Neck Surgery*. 2000. DOI: 10.1016/S0194-5998(99)80287-3
- [28] Derebery MJ, Berliner KI. Allergy and its relation to Meniere's disease. *Otolaryngologic Clinics of North America*. 2010. DOI: 10.1016/j.otc.2010.05.004
- [29] Derebery MJ. Allergic management of Meniere's disease: An outcome study. *Otolaryngology-Head and Neck Surgery*. 2000. DOI: 10.1016/S0194-5998(00)70235-X
- [30] Bergström T, Edström S, Tjellström A, Vahlne A. Ménière's disease and antibody reactivity to herpes simplex virus type 1 polypeptides. *American Journal of Otolaryngology and Head and Neck Surgery*. 1992. DOI: 10.1016/0196-0709(92)90051-T
- [31] Lee KS, Kimura RS. Ischemia of the endolymphatic sac. *Acta Oto-Laryngologica*. 1992. DOI: 10.3109/00016489209137456
- [32] Radtke A, Lempert T, Gresty MA, Brookes GB, Bronstein AM, Neuhauser H. Migraine and Ménière's disease: Is there a link? *Neurology*. 2002. DOI: 10.1212/01.WNL.0000036903.22461.39

- [33] Paparella MM, Mcdermott JC, Sousa LCA. Meniere's disease and the peak audiogram. *Archives of Otolaryngology*. 1982. DOI: 10.1001/archotol.1982.00790570021005
- [34] Katsarkas A. Hearing loss and vestibular dysfunction in Meniere's disease. *Acta Oto-Laryngologica*. 1996. DOI: 10.3109/00016489609137819
- [35] Havia M, Kentala E, Pyykkö I. Hearing loss and tinnitus in Meniere's disease. *Auris, Nasus, Larynx*. 2002; **29**(2):115-119. DOI: 10.1016/S0385-8146(01)00142-0
- [36] Sato G, Sekine K, Matsuda K, et al. Long-term prognosis of hearing loss in patients with unilateral Ménière's disease. *Acta Oto-Laryngologica*. 2014. DOI: 10.3109/00016489.2014.923114
- [37] Seyed Tootoonchi SJ, Ghiasi S, Shadara P, Samani SM, Fouladi DF. Hearing function after betahistine therapy in patients with Ménière's disease. *Brazilian Journal of Otorhinolaryngology*. 2015. DOI: 10.1016/j.bjorl.2015.08.021
- [38] Vernon J, Johnson R, Schleuning A. The characteristics and natural history of tinnitus in Meniere's disease. *Otolaryngologic Clinics of North America*. 1980. DOI: 10.1002/nur.20223
- [39] Stouffer JL, Tyler RS. Characterization of tinnitus by tinnitus patients. *The Journal of Speech and Hearing Disorders*. 1990. DOI: 10.1044/jshd.5503.439
- [40] Pfaltz C, Matefi L. Meniere's disease-or syndrome? A critical review of diagnose criteria. In: Vosteen K-H, Schuknecht H, Pfaltz C, et al., editors. *Meniere's Disease, Pathogenesis, Diagnosis and Treatment*. Stuttgart: Georg Thieme Verlag; 1981. pp. 1-10
- [41] Paparella MM, Mancini F. Vestibular Meniere's disease. *Otolaryngology-Head and Neck Surgery*. 1985. DOI: 10.1177/019459988509300203
- [42] Oosterveld W. Meniere's disease, signs and symptoms. *The Journal of Laryngology and Otology*. 1980;**94**(8): 885-892. DOI: 10.1017/S0022215100089647
- [43] Silverstein H, Smouha E, Jones R. Natural history vs. surgery for Meniere's disease. *Otolaryngology-Head and Neck Surgery*. 1989. DOI: 10.1177/019459988910000102
- [44] Tumarkin A. The otolithic catastrophe. *British Medical Journal*. 1936. DOI: 10.1136/bmj.2.3942.175
- [45] Ödkvist LM, Bergenius J. Drop attacks in Meniere's disease. *Acta Oto-Laryngologica, Suppl*. 1988
- [46] Oku R, Shigeno K, Kumagami H, Takahashi H. Otolith dysfunction during vertiginous attacks in Meniere's disease. *Acta Oto-Laryngologica*. 2003. DOI: 10.1080/00016480310000377
- [47] Friberg U, Stahle J, Svedberg A. The natural course of Meniere's disease. *Acta Oto-Laryngologica*. 1983. DOI: 10.3109/00016488309123007
- [48] Goebel JA. 2015 equilibrium committee amendment to the 1995 AAO-HNS guidelines for the definition of Ménière's disease. *Otolaryngology-Head and Neck Surgery*. 2016. DOI: 10.1177/0194599816628524
- [49] Black FO, Kitch R. A review of vestibular test results in Meniere's disease. *Otolaryngologic Clinics of North America*. 1980. DOI: 10.1177/0194599816628524
- [50] Maire R, Van Melle G. Vestibulo-ocular reflex characteristics in patients with unilateral Ménière's disease. *Otology & Neurotology*. 2008. DOI: 10.1097/MAO.0b013e3181776703

- [51] Goin DW, Staller SJ, Asher DL, et al. Summating potential in Meniere's disease. *The Laryngoscope*. 1982. DOI: 10.3757/jser.55.419
- [52] Klockhoff I. Diagnosis of Meniere's disease. *Archives of Oto-Rhino-Laryngology*. 1976. DOI: 10.1007/BF00453679
- [53] Rauch SD, Zhou G, Kujawa SG, Guinan JJ, Herrmann BS. Vestibular evoked myogenic potentials show altered tuning in patients with Ménière's disease. *Otology & Neurotology*. 2004. DOI: 10.1097/00129492-200405000-00022
- [54] Nevoux J, Franco-Vidal V, Bouccara D, et al. Diagnostic and therapeutic strategy in Meniere's disease. Guidelines of the French Otorhinolaryngology-Head and Neck Surgery Society (SFORL). *European Annals of Otorhinolaryngology, Head and Neck Diseases*. 2017;134(6):441-444. DOI: 10.1016/j.anorl.2016.12.003
- [55] Van Esch BF, Van Der Zaag-Loonen HJ, Bruintjes TD, Van Benthem PPG. Interventions for Meniere's disease: Protocol for an umbrella systematic review and a network meta-analysis. *BMJ Open*. 2016. DOI: 10.1136/bmjopen-2015-010269
- [56] Hamill TA. Evaluating treatments for Meniere's disease: Controversies surrounding placebo control. *Journal of the American Academy of Audiology*. 2006. DOI: 10.3766/jaaa.17.1.4
- [57] Torok N. Old and new in Ménière disease. *The Laryngoscope*. 1977. DOI: 10.1002/lary.1977.87.11.1870
- [58] Green JD, Blum DJ, Harner SG. Longitudinal follow up of patients with Meniere's disease. *Otolaryngology-Head and Neck Surgery*. 1991. DOI: 10.1177/019459989110400603
- [59] Nevoux J, Barbara M, Dornhoffer J, Gibson W, Kitahara T, Darrouzet V. International consensus (ICON) on treatment of Ménière's disease. *European Annals of Otorhinolaryngology, Head and Neck Diseases*. 2017. DOI: 10.1016/j.anorl.2017.12.006
- [60] Holgers K-M, Finizia C. Health profiles for patients with Meniere's disease. *Noise & Health*. 2001
- [61] Nakayama M, Masuda A, Ando KB, et al. A pilot study on the efficacy of continuous positive airway pressure on the manifestations of Ménière's disease in patients with concomitant obstructive sleep apnea syndrome. *Journal of Clinical Sleep Medicine*. 2015. DOI: 10.5664/jcsm.5080
- [62] Luxford E, Berliner KI, Lee J, Luxford WM. Dietary modification as adjunct treatment in Ménière's disease: Patient willingness and ability to comply. *Otology & Neurotology*. 2013. DOI: 10.1097/MAO.0b013e3182942261
- [63] Sánchez-Sellero I, San-Román-Rodríguez E, Santos-Pérez S, Rossi-Izquierdo M, Soto-Varela A. Caffeine intake and Meniere's disease: Is there relationship? *Nutritional Neuroscience*. 2017
- [64] Coelho DH, Lalwani AK. Medical management of Ménière's disease. *The Laryngoscope*. 2008. DOI: 10.1097/MLG.0b013e31816927f0
- [65] Sharon JD, Trevino C, Schubert MC, Carey JP. Treatment of Meniere's disease. *Current Treatment Options in Neurology*. 2015;17(4). DOI: 10.1007/s11940-015-0341-x
- [66] He FJ, Li J, Macgregor GA. Effect of longer-term modest salt reduction on blood pressure. *Cochrane Database of Systematic Reviews*. 2013. DOI: 10.1002/14651858.CD004937.pub2
- [67] Furuta H, Sato C, Kawaguchi Y, Miyashita T, Mori N. Expression of mRNAs encoding hormone receptors in

the endolymphatic sac of the rat. *Acta Oto-Laryngologica*. 1999. DOI: 10.1080/00016489950181936

[68] Kim G, Masilamani S, Turner R, et al. The thiazide-sensitive Na-Cl cotransporter is an aldosterone-induced protein. *Proceedings of the National Academy of Sciences of the United States of America*. 1998. DOI: 10.1093/icb/23.2.347

[69] Rossier BC, Baker ME, Studer RA. Epithelial sodium transport and its control by aldosterone: The story of our internal environment revisited. *Physiological Reviews*. 2015. DOI: 10.1152/physrev.00011.2014

[70] Miyashita T, Tatsumi H, Hayakawa K, Mori N, Sokabe M. Large Na<sup>+</sup> influx and high Na<sup>+</sup>, K<sup>+</sup>-ATPase activity in mitochondria-rich epithelial cells of the inner ear endolymphatic sac. *Pflügers Archiv - European Journal of Physiology*. 2007. DOI: 10.1007/s00424-006-0166-2

[71] Akiyama K, Miyashita T, Mori T, Inamoto R, Mori N. Expression of thiazide-sensitive Na<sup>+</sup>-Cl<sup>-</sup> cotransporter in the rat endolymphatic sac. *Biochemical and Biophysical Research Communications*. 2008. DOI: 10.1016/j.bbrc.2008.04.081

[72] Kim SH, Park HY, Choi HS, Chung HP, Choi JY. Functional and molecular expression of epithelial sodium channels in cultured human endolymphatic sac epithelial cells. *Otology & Neurotology*. 2009. DOI: 10.1097/MAO.0b013e31819a8e0e

[73] Matsubara A, Miyashita T, Inamoto R, Hoshikawa H, Mori N. Cystic fibrosis transmembrane conductance regulator in the endolymphatic sac of the rat. *Auris, Nasus, Larynx*. 2014. DOI: 10.1016/j.anl.2014.02.005

[74] Mori N, Uozumi N, Yura K, Sakai SI. Effect of aldosterone antagonist on the

DC potential in the endolymphatic SAC. *The Annals of Otology, Rhinology, and Laryngology*. 1991. DOI: 10.1177/000348949110000112

[75] Mori N, Uozumi N, Yura K, Sakai S. The difference in endocochlear and endolymphatic sac d.c. potentials in response to furosemide and canrenoate as diuretics. *European Archives of Oto-Rhino-Laryngology*. 1990. DOI: 10.1007/BF00179010

[76] Thai-Van H, Bounaix MJ, Fraysse B. Ménière's disease: Pathophysiology and treatment. *Drugs*. 2001. DOI: 10.2165/00003495-200161080-00005

[77] Miyashita T, Inamoto R, Fukuda S, et al. Hormonal changes following a low-salt diet in patients with Ménière's disease. *Auris, Nasus, Larynx*. 2017; 44(1):52-57. DOI: 10.1016/j.anl.2016.03.001

[78] Tadros SF, Frisina ST, Mapes F, Frisina DR, Frisina RD. Higher serum aldosterone correlates with lower hearing thresholds: A possible protective hormone against presbycusis. *Hearing Research*. 2005. DOI: 10.1016/j.heares.2005.05.009

[79] Martinez DM. The effect of serc (betahistine hydrochloride) on the circulation of the inner ear in experimental animals. *Acta Oto-Laryngologica*. 1972. DOI: 10.3109/00016487209122697

[80] Lacour M, van de Heyning PH, Novotny M, Tighilet B. Betahistine in the treatment of Ménière's disease. *Neuropsychiatric Disease and Treatment*. 2007

[81] Timmerman H. Pharmacotherapy of vertigo: Any news to be expected? *Acta Oto-Laryngologica*. 1994. DOI: 10.3109/00016489409127323

[82] Betahistine dihydrochloride. *Electronic Medicines Compendium*.

2015. Available from: <https://www.medicines.org.uk/emc/medicine/266172015>

[83] Murdin L, Hussain K, Schilder AGM. Betahistine for symptoms of vertigo. *Cochrane Database of Systematic Reviews*. 2013. DOI: 10.1002/14651858.CD010696

[84] Nauta JJP. Meta-analysis of clinical studies with betahistine in Ménière's disease and vestibular vertigo. *European Archives of Oto-Rhino-Laryngology*. 2014. DOI: 10.1007/s00405-013-2596-8

[85] Adrion C, Fischer CS, Wagner J, Gürkov R, Mansmann U, Strupp M. Efficacy and safety of betahistine treatment in patients with Meniere's disease: Primary results of a long term, multicentre, double blind, randomised, placebo controlled, dose defining trial (BEMED trial). *BMJ*. 2016;352. DOI: 10.1136/bmj.h6816

[86] Shinkawa H, Kimura RS. Effect of diuretics on endolymphatic hydrops. *Acta Oto-Laryngologica*. 1986. DOI: 10.3109/00016488609108606

[87] Petermann W, Mulch G. Long-term therapy of Meniere's disease. Comparison of the effects of betahistine dihydrochloride and hydrochlorothiazide. *Fortschritte der Medizin*. 1982

[88] Van Deelen GW, Huizing EH. Use of a diuretic (Dyazide®) in the treatment of ménière's disease: A double-blind cross-over placebo-controlled study. *ORL; Journal for Oto-rhino-laryngology and its Related Specialties*. 1986. DOI: 10.1159/000275884

[89] Klockhoff I, Lindblom U. Ménière's disease and hydrochlorothiazide dichloride®—A critical analysis of symptoms and therapeutic effects. *Acta Oto-Laryngologica*. 1967. DOI: 10.3109/00016486709128769

[90] Thirlwall AS, Kundu S. Diuretics for Meniere's disease or syndrome. *Cochrane Database of Systematic Reviews*. 2006. DOI: 10.1002/14651858.CD003599.pub2

[91] Ingelstedt S, Ivarsson A, Tjernström Ö. Immediate relief of symptoms during acute attacks of Meniere's disease, using a pressure chamber. *Acta Oto-Laryngologica*. 1976. DOI: 10.3109/00016487609120921

[92] Gates GA, Green JD, Tucci DL, Telian SA. The effects of transtympanic micropressure treatment in people with unilateral Ménière's disease. *Archives of Otolaryngology – Head & Neck Surgery*. 2004. DOI: 10.1001/archotol.130.6.718

[93] Ahsan SF, Standring R, Wang Y. Systematic review and meta-Analysis of Meniett therapy for Meniere's disease. *The Laryngoscope*. 2015;125(1):203-208. DOI: 10.1002/lary.24773

[94] Syed MI, Rutka JA, Hendry J, Browning GG. Positive pressure therapy for Meniere's syndrome/disease with a Meniett device: A systematic review of randomised controlled trials. *Clinical Otolaryngology*. 2015. DOI: 10.1111/coa.12344

[95] van Sonsbeek S, Pullens B, van Benthem PP. Positive pressure therapy for Ménière's disease or syndrome. *Cochrane Database of Systematic Reviews*. 2015. DOI: 10.1002/14651858.CD008419.pub2

[96] Zhang S-L, Leng Y, Liu B, Shi H, Lu M, Kong W-J. Meniett therapy for Meniere's disease: An updated Meta-analysis. *Otology & Neurotology*. 2016; 37(3):290-298. DOI: 10.1097/MAO.0000000000000957

[97] Sugawara K, Kitamura K, Ishida T, Sejima T. Insertion of tympanic ventilation tubes as a treating modality for patients with Meniere's disease: A short- and long-term follow-up study in

- seven cases. *Auris, Nasus, Larynx*. 2003. DOI: 10.1016/S0385-8146(02)00105-0
- [98] Montandon PB, Guillemin P, Häusler R. Prevention of vertigo in Mènièr's syndrome by means of transtympanic ventilation tubes. *ORL: Journal for Oto-rhino-laryngology and its Related Specialties*. 1988. DOI: 10.1159/000276016
- [99] Ballester M, Liard P, Vibert D, Häusler R. Menière's disease in the elderly. *Otology & Neurotology*. 2002
- [100] Ogawa Y, Otsuka K, Hagiwara A, et al. Clinical study of tympanostomy tube placement for patients with intractable Ménière's disease. *The Journal of Laryngology and Otology*. 2015;129(2):120-125. DOI: 10.1017/S0022215115000079
- [101] Masutani H, Nakai Y, Kato A. Microvascular disorder of the stria vascularis in endolymphatic hydrops. *Acta Oto-Laryngologica*. 1995. DOI: 10.3109/00016489509121874
- [102] Yazawa Y, Kitano H, Suzuki M, Tanaka H, Kitajima K. Studies of cochlear blood flow in Guinea pigs with endolymphatic hydrops. *ORL; Journal for Oto-rhino-laryngology and its Related Specialties*. 1998. DOI: 10.1159/000027554
- [103] Kimura RS, Hutta J. Inhibition of experimentally induced endolymphatic hydrops by middle ear ventilation. *European Archives of Oto-Rhino-Laryngology*. 1997. DOI: 10.1007/BF00874091
- [104] Chi FL, Liang Q, Wang ZM. Effects of hyperbaric therapy on function and morphology of Guinea pig cochlea with endolymphatic hydrops. *Otology & Neurotology*. 2004. DOI: 10.1097/00129492-200407000-00024
- [105] Dornhoffer JL, King D. The effect of the Meniett device in patients with Ménière's disease: Long-term results. *Otology & Neurotology*. 2008. DOI: 10.1097/MAO.0b013e318182025a
- [106] Foster CA. Optimal management of Ménière's disease. *Therapeutics and Clinical Risk Management*. 2015. DOI: 10.2147/TCRM.S59023
- [107] Peterson WM, Isaacson JE. Current management of Ménière's disease in an only hearing ear. *Otology & Neurotology*. 2007;28(5):696-699. DOI: 10.1097/mao.0b013e3180577963
- [108] Tumarkin A. Thoughts on the treatment of labyrinthopathy. *The Journal of Laryngology and Otology*;80(10):1041-1053. DOI: 10.1017/S0022215100066366
- [109] Lall M. Meniere's disease and the grommet (survey of its therapeutic effects). *The Journal of Laryngology and Otology*. 1977;83(8):787-791. DOI: 10.1017/S002221510007095X
- [110] Cinnamond MJ. Eustachian tube function in Menière's disease. *The Journal of Laryngology and Otology*. 1975. DOI: 10.1017/S0022215100080075
- [111] Hall CM, Brackmann DE. Eustachian tube blockage and Meniere's disease. *Archives of Otolaryngology – Head & Neck Surgery*. 1977;103(6):355-357. DOI: 10.1001/archotol.1977.00780230077012
- [112] Thomsen J, Bonding P, Birgit B. The non-specific effect of endolymphatic sac surgery in treatment of Meniere's disease: A prospective, randomized controlled study comparing "classic" endolymphatic sac surgery with the insertion of a ventilating tube in the tympanic membrane. *Acta Oto-Laryngologica*. 1998;118(6):769-773. DOI: 10.1080/00016489850182413
- [113] Magnan J, Ozgirgin ON, Trabalzini F, et al. European position statement on diagnosis, and treatment of Meniere's



- disease\*. The Journal of International Advanced Otolaryngology. 2018;14(2):317-321. DOI: 10.5152/iao.2018.140818
- [114] Guneri EA. Endolenfatik hidrops ve Meniere hastaligi. In: Onerci M, editor. Kulak Burun Boğaz Baş Boyun Cerrahisi Cilt 2 Nörootoloji. Ankara: Matsa Basimevi; 2016. pp. 523-536
- [115] Bienhold H, Flohr H. Role of cholinergic synapses in vestibular compensation. Brain Research. 1980. DOI: 10.1016/0006-8993(80)90083-9
- [116] Ishikawa K, Igarashi M. Effect of diazepam on vestibular compensation in squirrel monkeys. Archives of Oto-Rhino-Laryngology. 1984. DOI: 10.1007/BF00464344
- [117] Schaefer K, Meyer D. Aspects of vestibular compensation in Guinea pig. In: Flohr H, Precht E, editors. Lesion-Induced Neuronal Plasticity in Sensorimotor System. New York: Springer; 1981. pp. 197-297
- [118] Antor MA, Uribe AA, Erminy-Falcon N, et al. The effect of transdermal scopolamine for the prevention of postoperative nausea and vomiting. Frontiers in Pharmacology. 2014. DOI: 10.3389/fphar.2014.00055
- [119] Gejrot T. Intravenous xylocaine in the treatment of attacks of Meniere's disease. Acta Oto-Laryngologica. 1976. DOI: 10.3109/00016487609120911
- [120] Orji F. The influence of psychological factors in Meniere's disease. Annals of Medical and Health Sciences Research. 2014;4(1):3. DOI: 10.4103/2141-9248.126601
- [121] Van Crujisen N, Wit H, Albers F. Psychological aspects of Ménière's disease. Acta Oto-Laryngologica. 2003. DOI: 10.1080/0036554021000028125
- [122] House JW, Crary WG, Wexler M. The inter-relationship of vertigo and stress. Otolaryngologic Clinics of North America. 1980
- [123] Eagger S, Luxon LM, Davies RA, Coelho A, Ron MA. Psychiatric morbidity in patients with peripheral vestibular disorder: A clinical and neuro-otological study. Journal of Neurology, Neurosurgery, and Psychiatry. 1992. DOI: 10.1136/jnnp.55.5.383
- [124] Takahashi M, Ishida K, Iida M, Yamashita H, Sugawara K. Analysis of lifestyle and behavioral characteristics in Ménière's disease patients and a control population. Acta Oto-Laryngologica. 2001. DOI: 10.1080/000164801300043721
- [125] Van Crujisen N, Jaspers JPC, Van De Wiel HBM, Wit HP, Albers FWJ. Psychological assessment of patients with Ménière's disease. International Journal of Audiology. 2006. DOI: 10.1080/14992020600753239
- [126] Yokota Y, Kitahara T, Sakagami M, et al. Surgical results and psychological status in patients with intractable Ménière's disease. Auris, Nasus, Larynx. 2016;43(3):287-291. DOI: 10.1016/j.anl.2015.10.007
- [127] Dowdal-Osborn M. Early vestibular rehabilitation in patients with Meniere's disease. Otolaryngologic Clinics of North America. 2002;35(3):683-690. DOI: 10.1016/S0030-6665(02)00026-9
- [128] Di Fabio RP. Sensitivity and specificity of platform posturography for identifying patients with vestibular dysfunction. Physical Therapy. 1995. DOI: 10.1093/ptj/75.4.290
- [129] Black FO, Wall C. Comparison of vestibulo-ocular and vestibulospinal screening tests. Otolaryngology-Head and Neck Surgery. 1981. DOI: 10.1177/019459988108900523
- [130] Di Fabio RP. Meta-analysis of the sensitivity and specificity of platform

- posturography. *Archives of Otolaryngology – Head & Neck Surgery*. 1996. DOI: 10.1001/archotol.1996.01890140036008
- [131] Cohen H, Ewell LR, Jenkins HA. Disability in Meniere's disease. *Archives of Otolaryngology-Head and Neck Surgery*. 1995. DOI: 10.1001/archotol.1995.01890010017004
- [132] Haybach P. Meniere's disease—What you need to know. In: *Vestibular Disorders Association*. Portland, Oregon; 1998
- [133] Odkvist L. Gentamicin cures Vertigo, but what happens to hearing? *The International Tinnitus Journal*. 1997
- [134] Gottshall K, Hoffer ME, Kopke R. Vestibular physical therapy rehabilitation after low dose microcatheter administered gentamicin treatment for Meniere's disease. In: *4th International Symposium on Meniere's Disease*. Hauge (Netherlands): Kugler Publications; 2000. pp. 663-668
- [135] Suryanarayanan R, Cook JA. Long-term results of gentamicin inner ear perfusion in Ménière's disease. *The Journal of Laryngology and Otology*. 2004. DOI: 10.1258/0022215041615083
- [136] Clendaniel RA, Tucci DL. Vestibular rehabilitation strategies in Meniere's disease. *Otolaryngologic Clinics of North America*. 1997
- [137] Gottshall KR, Topp SG, Hoffer ME. Early vestibular physical therapy rehabilitation for Meniere's disease. *Otolaryngologic Clinics of North America*. 2010;43(5):1113-1119. DOI: 10.1016/j.otc.2010.05.006
- [138] Cohen H. Vestibular rehabilitation improves daily life function. *American Journal of Occupational Therapy*. 1994. DOI: 10.1097/IGC.0b013e31828b4f19
- [139] Antoli Candela F Jr. The histopathology of Meniere's disease. *Acta Oto-Laryngologica*. 1976
- [140] Lee CS, Paparella MM, Margolis RH, Le C. Audiological profiles and Meniere's disease. *Ear, Nose, & Throat Journal*. 1995
- [141] Stahle J, Friberg U, Svedberg A. Long-term progression of Meniere's disease. *Acta Oto-Laryngologica*. 1991. DOI: 10.3109/00016489109128047
- [142] Kolbe U, Brehmer D, Schaaf H, Hesse G, Laubert A. Tinnitus and morbus Meniere. In: Sterkers O, Ferrary E, Dauman R, Sauvage JP, Tran Ba Huy P, editors. *Meniere's Disease 1999-Update*. Kugler Publications; 2000. pp. 459-462
- [143] Vasama JP, Linthicum FH. Meniere's disease and endolymphatic hydrops without Meniere's symptoms: Temporal bone histopathology. *Acta Oto-Laryngologica*. 1999. DOI: 10.1080/00016489950181279
- [144] Sala T. Transtympanic gentamicin in the treatment of Meniere's disease. *Auris, Nasus, Larynx*. 1997
- [145] Kaasinen S, Pyykkö I, Ishizaki H, Aalto H. Effect of intratympanically administered gentamicin on hearing and tinnitus in Meniere's disease. *Acta Oto-Laryngologica*. 1995. DOI: 10.3109/00016489509125223
- [146] Ganança MM, Caovilla HH, Gazzola JM, Ganança CF, Ganança FF. Betahistine in the treatment of tinnitus in patients with vestibular disorders. *Brazilian Journal of Otorhinolaryngology*. 2011. DOI: 10.1590/S1808-86942011000400014
- [147] Azevedo AA, Figueiredo RR, Elgoyhen AB, Langguth B, Penido NDO, Schlee W. Tinnitus treatment with oxytocin: A pilot study. *Frontiers in*

Neurology. 2017. DOI: 10.3389/fneur.2017.00494

[148] Langguth B, Kreuzer PM, Kleinjung T, De Ridder D. Tinnitus: Causes and clinical management. *Lancet Neurology*. 2013. DOI: 10.1016/S1474-4422(13)70160-1

[149] Perez R, Chen JM, Nedzelski JM. The status of the contralateral ear in established unilateral Menière's disease. *The Laryngoscope*. 2004. DOI: 10.1097/00005537-200408000-00010

[150] Yazawa Y, Kitahara M. Bilateral endolymphatic hydrops in Meniere's disease: Review of temporal bone autopsies. *The Annals of Otology, Rhinology, and Laryngology*. 1990. DOI: 10.1177/000348949009900705

[151] Tsuji K, Velazquez-Villasenor L, Rauch S, Glynn R, Wall CI, Merchant S. Temporal bone studies of the human peripheral vestibular system. Meniere's disease. *The Annals of Otology, Rhinology, and Laryngology*. 2000. DOI: 10.1177/00034894001090S502

[152] Kitahara M. Bilateral aspects of Meniere's disease: Meniere's disease with bilateral fluctuant hearing loss. *Acta Oto-Laryngologica*. 1991. DOI: 10.3109/00016489109128046

[153] Agrawal S, Parnes L. Systemic treatment of bilateral Meniere's disease. In: Roland P, Rutka J, editors. *Ototoxicity*. Hamilton, Canada: BC Decker; 2004

[154] Mizuta K, Furuta M, Ito Y, et al. A case of Meniere's disease with vertical nystagmus after administration of glycerol. *Auris, Nasus, Larynx*. 2000. DOI: 10.1016/S0385-8146(00)00050-X

[155] Paparella MM, Griebie MS. Bilaterality of Meniere's disease. *Acta Oto-Laryngologica*. 1984. DOI: 10.3109/00016488409130984

[156] Iseli C, Gibson W. A comparison of three methods of using transtympanic electrocochleography for the diagnosis of Meniere's disease: Click summing potential measurements, tone burst summing potential amplitude measurements, and biasing of the summing potential using a low frequency tone. *Acta Oto-Laryngologica*. 2010. DOI: 10.3109/00016480902858899

[157] Lin MY, Timmer FCA, Oriel BS, et al. Vestibular evoked myogenic potentials (VEMP) can detect asymptomatic saccular hydrops. *The Laryngoscope*. 2006. DOI: 10.1097/01.mlg.0000216815.75512.03

[158] Fukuoka H, Tsukada K, Miyagawa M, et al. Semi-quantitative evaluation of endolymphatic hydrops by bilateral intratympanic gadolinium-based contrast agent (GBCA) administration with MRI for Meniere's disease. *Acta Oto-Laryngologica*. 2010. DOI: 10.3109/00016480902858881

[159] Garduño-Anaya MA, De Toledo HC, Hinojosa-González R, Panebianese C, Ríos-Castañeda LC. Dexamethasone inner ear perfusion by intratympanic injection in unilateral Ménière's disease: A two-year prospective, placebo-controlled, double-blind, randomized trial. *Otolaryngology-Head and Neck Surgery*. 2005. DOI: 10.1016/j.otohns.2005.05.010

[160] Silverstein H, Isaacson JE, Olds MJ, Rowan PT, Rosenberg S. Dexamethasone inner ear perfusion for the treatment of Meniere's disease: A prospective, randomized, double-blind, crossover trial. *American Journal of Otolaryngology*. 1998. DOI: 10.1111/j.1467-6494.1954.tb02338.x

[161] Alles MJRC, Der Gaag MA, Stokroos RJ. Intratympanic steroid therapy for inner ear diseases, a review of the literature. *European Archives of*

Oto-Rhino-Laryngology. 2006. DOI:  
10.1007/s00405-006-0065-3

[162] Balyan FR, Taibah A, De Donato G, et al. Titration streptomycin therapy in Meniere's disease: Long-term results. *Otolaryngology-Head and Neck Surgery*. 1998. DOI: 10.1016/S0194-5998(98)80028-4

[163] Graham MD. Bilateral Meniere's disease. Treatment with intramuscular titration streptomycin sulfate. *Otolaryngologic Clinics of North America*. 1997

[164] Kilpatrick JK, Sismanis A, Spencer RF, Wise CM. Low-dose oral methotrexate management of patients with bilateral Meniere's disease. *Ear, Nose, & Throat Journal*. 2000

[165] Schessel D, Minor L, Nedzelski J. Meniere's disease and other peripheral vestibular disorders. In: Cummings C, Flint P, Haughey B, editors. *Cummings Otolaryngology: Head and Neck Surgery*. 4th ed. Philadelphia: Elsevier Inc; 2005

[166] Shea JJJ, Ge X. Dexamethasone perfusion of the labyrinth plus intravenous dexamethasone for Meniere's disease. *Otolaryngologic Clinics of North America*. 1996

[167] Shea JJ. The role of dexamethasone or streptomycin perfusion in the treatment of Meniere's disease. *Otolaryngologic Clinics of North America*. 1997

[168] Hirvonen TP, Peltomaa M, Ylikoski J. Intratympanic and systemic dexamethasone for Meniere's disease. *ORL; Journal for Oto-rhino-laryngology and its Related Specialties*. 2000. DOI: 10.1159/000027730

[169] Morales-Luckie E, Cornejo-Suarez A, Zaragoza-Contreras MA, Gonzalez-Perez O. Oral administration of prednisone to control refractory vertigo

in Ménière's disease: A pilot study. *Otology & Neurotology*. 2005. DOI: 10.1097/01.mao.0000185057.81962.51

[170] Paparella M. Revision of endolymphatic sac surgery for recurrent Meniere's disease. *Otolaryngologic Clinics of North America*. 2002;35(3): 607-619. DOI: 10.1016/S0030-6665(02)00032-4

[171] Kitahara T, Kubo T, Okumura SI, Kitahara M. Effects of endolymphatic sac drainage with steroids for intractable Ménière's disease: A long-term follow-up and randomized controlled study. *The Laryngoscope*. 2008. DOI: 10.1097/MLG.0b013e3181651c4a

[172] Wetmore SJ. Endolymphatic sac surgery for Ménière's disease: Long-term results after primary and revision surgery. *Archives of Otolaryngology – Head & Neck Surgery*. 2008. DOI: 10.1001/archotol.134.11.1144