

We are IntechOpen, the world's leading publisher of Open Access books Built by scientists, for scientists

4,800

Open access books available

122,000

International authors and editors

135M

Downloads

Our authors are among the

154

Countries delivered to

TOP 1%

most cited scientists

12.2%

Contributors from top 500 universities



WEB OF SCIENCE™

Selection of our books indexed in the Book Citation Index
in Web of Science™ Core Collection (BKCI)

Interested in publishing with us?
Contact book.department@intechopen.com

Numbers displayed above are based on latest data collected.

For more information visit www.intechopen.com



The Role of Magnetic Resonance Imaging (MRI) in Autonomic Nervous System Monitoring

Yousif Mohamed Y. Abdallah and Nouf H. Abuhadi

Abstract

Medical imaging of the nervous system is the methodology used to achieve pictures of parts of the nervous system for therapeutic uses to recognize the ailments. Magnetic resonance imaging (MRI) is a kind of medical imaging tool that utilizes solid magnetic fields and radio waves to deliver point-by-point pictures of the inside of the body. There are large number of imaging methodologies done each week around the world. Medical imaging is developing rapidly due to developments in image acquisition tools including functional MRI and hybrid imaging modalities. This chapter abridged the role of magnetic resonance imaging (MRI) in autonomic nervous system monitoring. This chapter also summarizes the image interpretation challenges in diagnosing autonomic nervous system disorders.

Keywords: medical, imaging, autonomic nervous system

1. Introduction

The nervous system is divided into two parts, the central (CNS) and peripheral (PNS) part. The CNS includes the majority of the neural tissues and comprises the brain and spinal cord. PNS comprises all the structures outside the CNS and includes the special sense, spinal and cranial, and autonomic nervous system (ANS) [1–4]. The nervous system is composed mostly of the axons of sensual and motor neurons that permit between the CNS and the body. The autonomic sensory system (ANS) is divided into the peripheral sensory parts that provision the muscles and organs and influence the capacity of inner organs [5–7]. This system is considered as a regulatory framework that stimulates the action of those organs and muscles. This system manages in essence capacities, for example, the pulse, absorption, optical reaction, pee, and voluptuous stimulation [8–11]. This framework is the essential instrument responsible for the battle or flight reaction. Inside the mind, the central nerves manage this system. Autonomic capacities incorporate control of breath, heart guideline (the cardiovascular control focus), vasomotor action (the vasomotor focus), and certain reflex activities, for example, hacking, wheezing, gulping, and heaving [11–14]. This system is then subdivided into different zones that are connected additionally to ANS and sensory structures outside to the cerebrum. The central nerve over the cerebrum trunk goes as an integrator for autonomic capacities, accepting ANS administrative contribution from the limbic framework to do as such. The ANS has three subdivisions: the thoughtful sensory, the parasympathetic

sensory, and the enteric anxious system. [15–18] Some researchers exclude the enteric sensory as a component of this organization. [8] The thoughtful sensory organization frequently includes “fight or flight” framework, although the parasympathetic sensory organization regularly includes the “rest and digest” or “feed and breed” framework. Most of the time, both of these frameworks have “inverse” activities where one framework actuates a physiological reaction and the other hinders it [19–23]. A more established improvement of thoughtful and parasympathetic structures as “excitatory” and “inhibitory” was toppled because of the numerous exemptions found. In ANS, there are many constrainers and excitatory neurotransmitters, which locate among neural cells.

The non-noradrenergic system affects the gut and the lungs [24, 25]. Magnetic resonance imaging (MRI) is a medicinal imaging method utilized to frame photos of the life systems and the functional procedures of the body. MRI machines utilize solid magnetic fields and RF pulse to create pictures of the structures of the body. MRI does not use ionizing radiation like CT, PET, and other scanners. MRI is a restorative utilization of nuclear magnetic resonance (NMR) [26–28]. This technique can be utilized for NMR spectroscopy. Although the risks of conventional radiography are presently very much protected in utmost medicinal settings, an MRI examination may at present be viewed as a superior decision than a CT exam. MRI is generally utilized in emergency clinics and facilities for therapeutic determination. An MRI may produce diverse data in contrast to CT scan. There might be dangers and inconvenience related to MRI scans. In contrast to CT filters, this procedure commonly is more intense and risky. In the 1970–80s, MRI has demonstrated to be a flexible imaging method. Although MRI is utmost unmistakably utilized in analytic prescription and biological researches, it additionally might be utilized to make pictures of inorganic particles. The supported increment sought after for MRI inside wellbeing frameworks has prompted worries about cost adequacy and overdiagnosis [29–32].

2. Anatomy of autonomic nervous system (ANS)

The ANS is partitioned into the thoughtful and the parasympathetic sensory system. The thoughtful division starts in the thoracic spines and ends up in the L2–3. The parasympathetic division includes both cranial (III, IX, X) and sacral (S2–4) nerves (**Figure 1**) [33, 34].

The thoughtful sensory system consists of neural cells that appear beyond T1 and continue to level L2/3. There are a few areas whereupon preganglionic neurons can be able neurotransmitters because of their postganglionic neuron stability.

These ganglia assign the postganglionic neurons beside which innervation of goal structures pursues. Instances regarding splanchnic (instinctive) nerves are as follows:

1. Cervical cardiovascular nerves then thoracic instinctive nerves, which are neural ligature of the thoughtful band
2. Thoracic splanchnic nerves
3. Lumbar splanchnic nerves, which are neural connection of the prevertebral ganglia
4. Sacral splanchnic nerves, which are neural concretion of the second quantity hypogastric plexus [35–40]

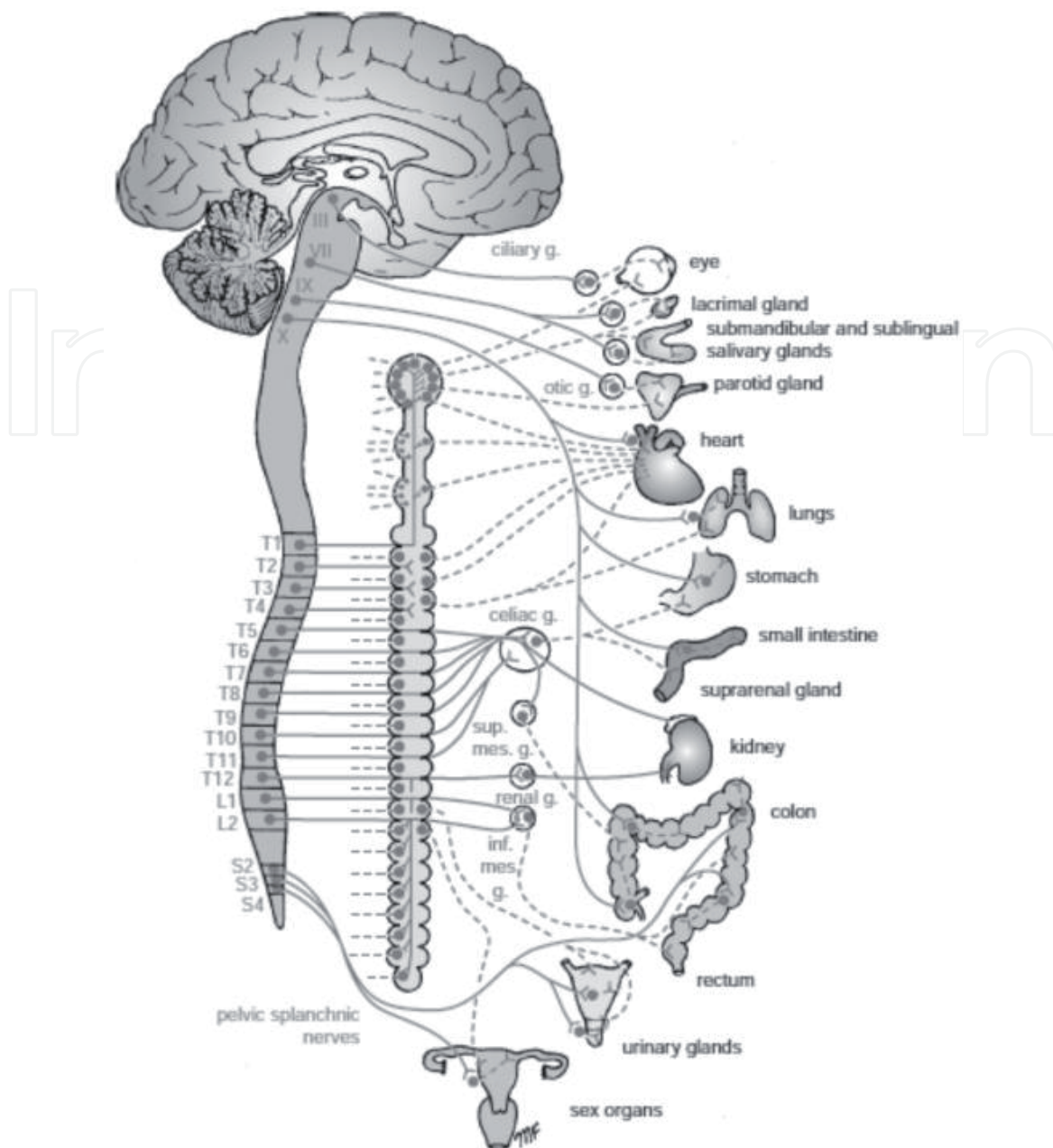


Figure 1.
 Autonomic nervous system [1, 3, 8].

2.1 Sensory neurons

The sensory part is taken outdoors concerning necessary instinctive true neurons determined in the hem sensory dictation (PNS), of cranial real ganglia: the geniculate, petrosal, or nodose ganglia, annexed one at a time after cranial nerves. These tactile neurons are responsible of organization of the degrees of charcoal dioxide, oxygen, or grit between the blood, blood boat ounce yet the artificial business enterprise about the belly and intestine content [41–44]. The nTS gets the performance beside an adjacent chemosensory focus, the area postrema, who recognizes poisons among the blood yet the cerebrospinal melted and is necessary because synthetically instigated spewing and restrictive style repugnance (the intelligence as ensures so a life as has been harmed through sustenance in no way connection such again). These instinctive tactile data constantly then unknowingly regulate the labor regarding the machine neurons about the ANS (**Figure 2**) [45, 46].

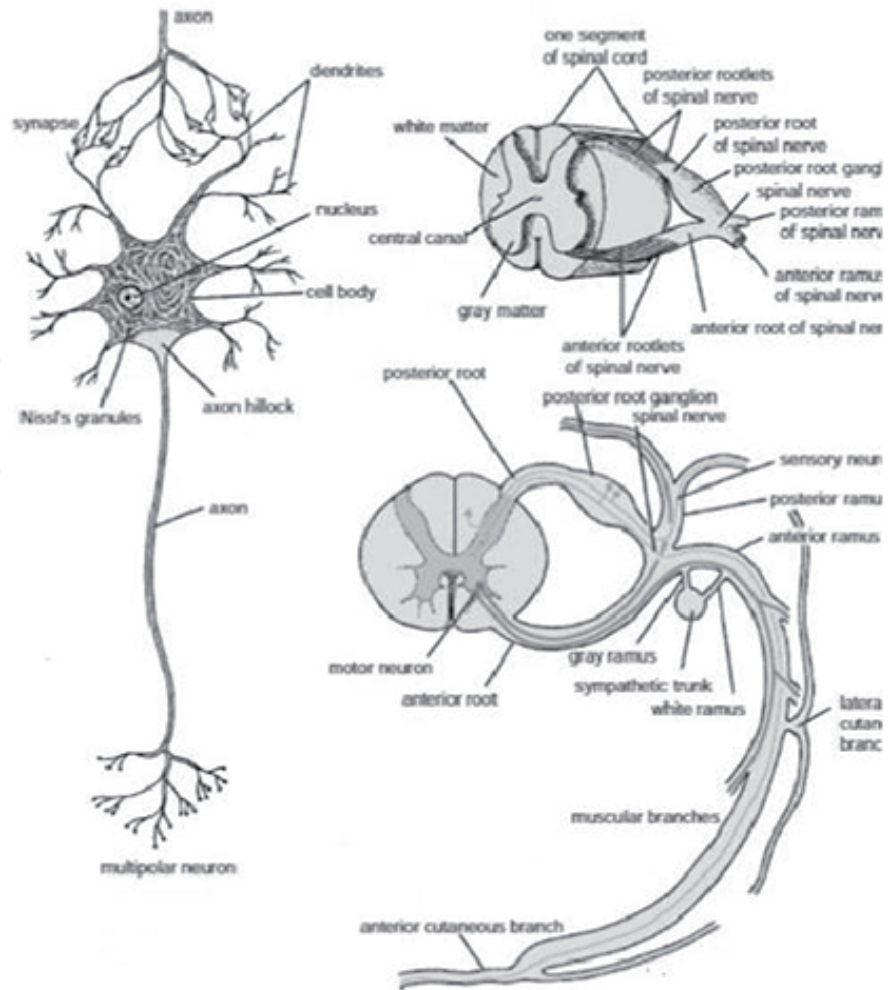


Figure 2.
Sensory neurons [1, 3, 8].

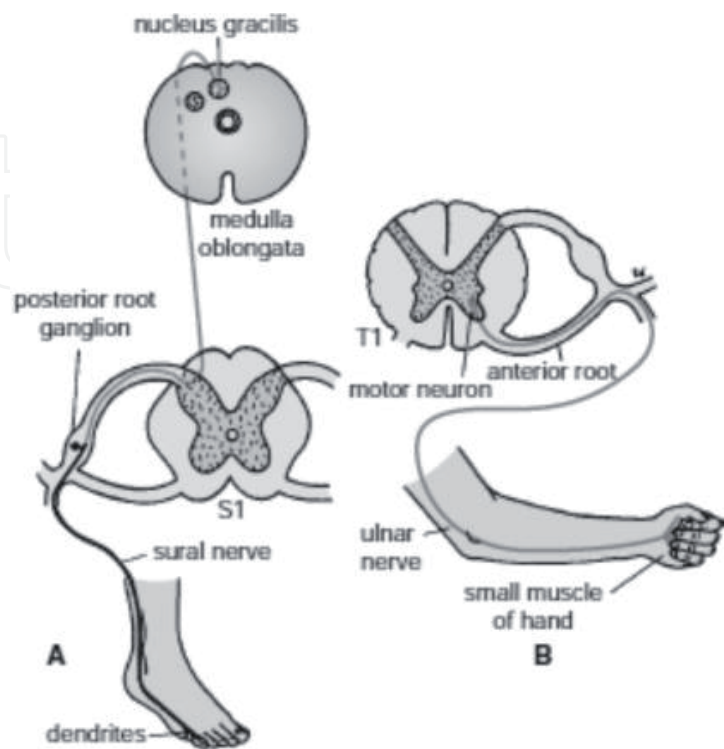


Figure 3.
The central and peripheral nervous system [1, 3, 8].

2.2 Innervation

Autonomic nerves travel in accordance with organs via the entire body. The true portion on the of the autonomic nerves remaining achieves the spinal piece at definitive spinal fragments. The neural signal travel from the autonomic system to the other body part through number pf the nerves that distributed throughout the body (Figure 3) [47, 48].

3. Physiology of autonomic nervous system

Thoughtful and parasympathetic divisions regularly work contrary to one another. Yet, this resistance is better named reciprocal in nature as opposed to hostile. The thoughtful partition regularly works in activities needing fast reactions. The thoughtful framework is regularly the “battle or flight” framework, while the other framework is frequently the “rest and summary” or “feed and breed” framework [49–51]. In any case, numerous cases of thoughtful and parasympathetic movement cannot be credited to “battle” or “rest” circumstances. For example, adjustable over out of a leaning again and placing role would contain an unsustainable decline between circulatory pressure notwithstanding a compensatory rise within the blood vessel’s thoughtful tonus. Another mannequin is the steady, second-to-second tweak of the bough with the aid of thoughtful then parasympathetic impacts, so an aspect on the respiratory cycle. When all is said and done, these two frameworks ought to be viewed as for all time tweaking imperative capacities, in normally hostile design, to accomplish homeostasis. Higher living beings keep up their honesty by means of homeostasis, which depends on negative criticism guideline, which, thusly, ordinarily relies upon the autonomic anxious system [52–55]. Some run-of-the-mill activities of the thoughtful and parasympathetic sensory systems are recorded beneath [55].

4. Pathology of autonomic nervous system

4.1 Sweating abnormalities

Sudomotor or perspiring changes can likewise be highlights of autonomic brokenness, inferring changes in perspiring not related legitimately to side effects of orthostatic narrow mindedness or on the other hand presyncope [56–58]. Patients may report either expanded or on the other hand over the top perspiring or diminished perspiration yield and warmth narrow mindedness, either internationally, segmentally, or on the other hand sketchy in appropriation. Numerous patients with distal perspiration misfortune report expanded perspiration yield, which may happen as a compensatory reaction is unaffected territories, for example, the head and upper-middle, yet which is seen by the patient as unnecessary perspiring [59].

Sudomotor brokenness might be because of anomalies in focal control instruments (as in the different framework decay), or all the more generally in patients with autonomic fringe neuropathy, either as a disconnected variation from the norm of postganglionic thoughtful nerve strands just in hypohidrosis or worldwide anhidrosis, or as a component of an increasingly summed up autonomic neuropathy, either essential (immune system autonomic neuropathy) or auxiliary (amyloidosis, diabetic fringe neuropathy, or little fiber tangible neuropathy because of Sjögren’s disorder) in nature [60, 61].

4.2 Secretomotor symptoms

Secretomotor indications incorporate sicca manifestations of dry eyes (xerophthalmia) and dry mouth (xerostomia). Patients do not visit the physicians for more investigations unless they becomes serious, however, with cautious addressing, they might be evoked. The brokenness of autonomic innervation might be seen in autonomic neuropathies or part of summed up autonomic disappointment, albeit even more ordinarily found previously [62–65].

5. Magnetic resonance imaging (MRI)

For MRI examination, the patient is situated inside an MRI scanner up to expectation constructions a consolidated alluring discipline around the sector in imitation of keep imaged. In utmost therapeutic applications, protons (hydrogen particles) that containing cloud particles was passed into tissues in order to create a sign that later use to make a photograph of internal structure of the body. Initially, energy of swaying magnetic field is temporarily related after the patient at the becoming reverberation recurrence. The energized hydrogen iotas beam a radio recurrence signal, which is estimated with the aid of an accepting curl. The radio sign may stay instituted to encode role data with the aid of altering the foremost pleasing subject utilizing bias loops. As those curls are rapidly became concerning or far away that redact the trademark stupid concussion on an MRI check. The difference in a number of tissues is managed by using the dimensions at which energized particles appear returned to a coherent state. Exogenous division specialists would possibly lie fond in accordance with the unaccompanied in conformity to perform the photograph clearer. [65] The actual parts of an MRI machine are precept magnet and the RF framework, which admits the NMR signal. The complete framework is restrained by using at least certain PCs. The area virtue on the magnet is estimated in teslas then preserving in thinking so just concerning the frameworks labor at 1.5 T, business frameworks are on hand someplace in the extent concerning 0.2 yet 7 T. For claustrophobic patient usually the open superconducting magnet machine is used. Recently, MRI has been shown either at ultra-low fields. The place ample sign quality is done conceivable via prepolarization (on the pray of 10 up to -100 mT) then by estimating the Larmor antecedence fields at around one hundred microteslas including very delicate superconducting quantum arrest gadgets (SQUIDS) [66]. Each art comes lower back according to its harmony administration and then exasperation by using the unrestricted unwinding approaches regarding T1 or T2. The T1 weighted picture is treasured because surveying the brain tissues, distinguishing greasy structure, describing average lung accidents and now every is pointed out in performed because

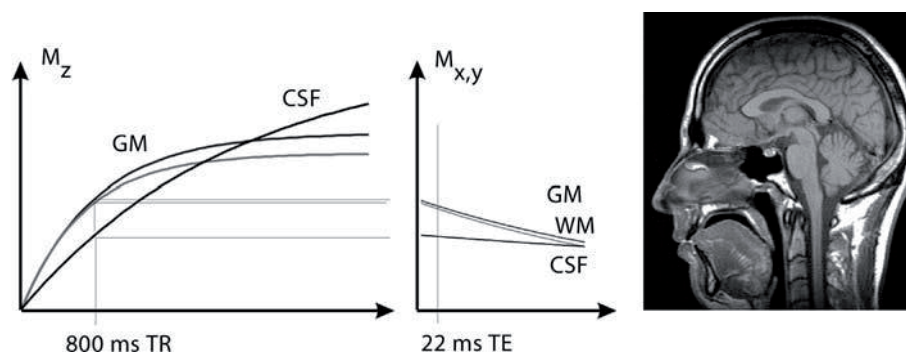


Figure 4.
MRI T1-weighted image [30, 64–66]

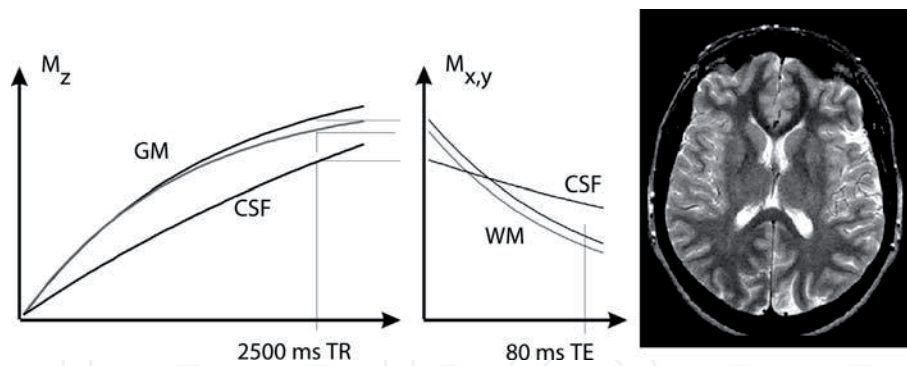


Figure 5.
MRI T2-weighted image [30, 64–66].

of acquiring morphological data, simply namely because of post-differentiate imaging (**Figure 4**) [30, 67, 68].

The T2-weighted picture shows a valuable structure for identifying and recognition of the pathophysiological problems of ANS and gives useful information that enable the neurosurgeons to perform a successful procedure (**Figure 5**).

6. Conclusion

In nervous system disorders, the non-ionizing radiation is used to scan and produce multi-dimension images with and without contrast media utilization. In the 1970s, Ian Robert Young and Hugh Clow had first brain images using MRI. In 1990, Seiji Ogawa who used the oxygen-depleted blood phenomena introduced functional MRI (fMRI). In the 1990s, the development and introduction of the new MRI protocols helped in the demonstration of gray and white matter areas of the nervous system. Many MRI scans later were done by using high magnetic strength (3.0 up to 9.4 T).

Acknowledgements

The authors are thankful to the Deanship of Scientific Research, at Majmaah University, for funding this research.

Conflict of interest

There are no conflicts of interest.

IntechOpen

Author details

Yousif Mohamed Y. Abdallah^{1*} and Nouf H. Abuhadi²

1 Radiological Science and Medical Imaging Department, College of Applied Medical Science, Majmaah University, Majmaah, Saudi Arabia

2 Diagnostic Radiology Department, College of Applied Medical Science, Jazan University, Jazan, Saudi Arabia

*Address all correspondence to: y.yousif@mu.edu.sa

IntechOpen

© 2019 The Author(s). Licensee IntechOpen. This chapter is distributed under the terms of the Creative Commons Attribution License (<http://creativecommons.org/licenses/by/3.0>), which permits unrestricted use, distribution, and reproduction in any medium, provided the original work is properly cited. 

References

- [1] Schmidt A, Thews G. Autonomic nervous system. In: Janig W, editor. *Human Physiology*. 2nd ed. New York, NY: Springer-Verlag; 1989. pp. 333-370
- [2] Allostatic Load Notebook: Parasympathetic Function Archived 2012-08-19 at the Wayback Machine - 1999, MacArthur research network, UCSF
- [3] Langley JN. *The Autonomic Nervous System Part 1*. Cambridge: W. Heffer; 1921
- [4] Jänig W. *Integrative Action of the Autonomic Nervous System: Neurobiology of Homeostasis (Digitally Printed Version)*. Cambridge: Cambridge University Press; 2008. p. 13. ISBN 978052106754-6
- [5] Abdallah Y. Improvement of sonographic appearance using HAT-TOP methods. *International Journal of Science and Research (IJSR)*. 2015;4(2):2425-2430
- [6] John F. Enteric Nervous System. Scholarpedia. Archived from the original on 8 October 2017; 2007. Retrieved 8 October 2017. DOI: 10.4249/scholarpedia.4064
- [7] Willis WD. The autonomic nervous system and its central control. In: Berne RM, editor. *Physiology*. 5th ed. St. Louis, Mo: Mosby; 2004. ISBN 0323022251
- [8] Pocock G. *Human Physiology*. 3rd ed. London, United Kingdom: Oxford University Press; 2006. pp. 63-64. ISBN 978-0-19-856878-0
- [9] Belvisi Maria G, David Stretton C, Yacoub Magdi, Barnes Peter J. "Nitric oxide is the endogenous neurotransmitter of bronchodilator nerves in humans". *European Journal of Pharmacology*. 1992; 210(2):221-222. DOI: 10.1016/0014-2999(92)90676-U. PMID 1350993
- [10] Costanzo LS. *Physiology*. Hagerstown, MD: Lippincott Williams & Wilkins; 2007. p. 37. ISBN 0-7817-7311-3
- [11] Moore KL, Agur AM. *Essential Clinical Anatomy*. 2nd ed. Lippincott Williams & Wilkins, Inc.; 2002. p. 199. ISBN 978-0-7817-5940-3
- [12] Neil A. Campbell, Jane B. Reece: *Biologie*. Spektrum-Verlag Heidelberg-Berlin; 2003. ISBN 3-8274-1352-4
- [13] Goldstein D. *Principles of Autonomic Medicine (PDF) (Free Online Version Ed.)*. Bethesda, Maryland: National Institute of Neurological Disorders and Stroke, National Institutes of Health, USA; 2016. ISBN 9780824704087
- [14] Hadhazy A. Think Twice: How the Gut's "Second Brain" Influences Mood and Well-Being. *Scientific American*; 2010. Archived from the original on December 31, 2017
- [15] Zimmerman-Viehoff F, Thayer J, Koenig J, Herrmann C, Weber CS, Deter H-C. Short-term effects of espresso coffee on heart rate variability and blood pressure in habitual and non-habitual coffee consumers- a randomized crossover study. *Nutritional Neuroscience*. 2016;19(4):169-175. Retrieved February 20, 2017
- [16] Bunsawat K, White DW, Kappus RM, Baynard T. Caffeine delays autonomic recovery following acute exercise. *European Journal of Preventive Cardiology*. 2015;22(11):1473-1479. Retrieved February 20, 2017
- [17] Monda M, Viggiano An, Vicidomini C, Viggiano Al, Iannaccone T, Tafuri D, De Luca,

- B. "Espresso coffee increases parasympathetic activity in young, healthy people". *Nutritional Neuroscience*. 2009;12(1):43-48. Retrieved February 20, 2017
- [18] Information Reed Business. Britain's Brains Produce First NMR Scans. *New Scientist*: 588;1978
- [19] Blood-flow checker. *Popular Science*: 12;1987
- [20] Le Bihan D, Breton E. Method to Measure the Molecular Diffusion and/or Perfusion Parameters of Live Tissue. US Patent # 4809701;1987
- [21] Abdallah YM. History of medical imaging. *Archives of Medicine and Health Sciences*. 2017;5:275-278
- [22] Villringer A, Rosen BR, Belliveau JW, Ackerman JL, Lauffer RB, Buxton RB, et al. Dynamic imaging with lanthanide chelates in normal brain: Contrast due to magnetic susceptibility effects. *USA: Magnetic Resonance in Medicine*. 1988;6(2):164-174
- [23] Faro SH, Mohamed FB. *Bold fMRI. A Guide to Functional Imaging for Neuroscientists*. Springer; 2010. ISBN 978-1-4419-1328-9. Retrieved 10 June 2015
- [24] Howe FA, Filler AG, Bell BA, Griffiths JR. Magnetic resonance neurography. *Magnetic Resonance in Medicine*. 1992;28(2):328-338. DOI: 10.1002/mrm.1910280215. PMID: 1461131
- [25] Filler AG, Howe FA, Hayes CE, Kliot M, Winn HR, Bell BA, et al. Magnetic resonance neurography. *Lancet*. 1993;341(8846):659-661. DOI: 10.1016/0140-6736(93)90422-d. PMID 8095572
- [26] Filler A. Magnetic resonance neurography and diffusion tensor imaging: Origins, history, and clinical impact of the first 50,000 cases with an assessment of efficacy and utility in a prospective 5000-patient study group. *Neurosurgery*. USA. 2009;65 (4 Suppl):A29-A43. DOI: 10.1227/01.neu.0000351279.78110.00. PMC 2924821. PMID 19927075
- [27] Basser PJ. Invention and Development of Diffusion Tensor MRI (DT-MRI or DTI) at the NIH. *Diffusion MRI*. Oxford University Press; 2010. pp. 730-740. DOI: 10.1093/med/9780195369779.003.0047. ISBN 9780195369779
- [28] Hajnal JV, De Coene B, Lewis PD, Baudouin CJ, Cowan FM, Pennock JM, et al. High signal regions in normal white matter shown by heavily T2-weighted CSF nulled IR sequences. *Journal of Computer Assisted Tomography*. 1992;16(4):506-513. DOI: 10.1097/00004728-199207000-00002. PMID: 1629405
- [29] Koretsky AP. Early development of arterial spin labeling to measure regional brain blood flow by MRI. *NeuroImage*. 2012;62(2):602-607. DOI: 10.1016/j.neuroimage.2012.01.005. PMC 4199083. PMID 22245338
- [30] Abdallah Y. *An Introduction to PACS in Radiology Service: Theory and Practice*. Vol. 2. Berlin, Germany: LAP LAMBERT Academic Publishing; 2012. pp. 140-153. ISBN 978-3846588987
- [31] Reichenbach JR, Venkatesan R, Schillinger DJ, Kido DK, Haacke EM. Small vessels in the human brain: MR venography with deoxyhemoglobin as an intrinsic contrast agent. *Radiology*. July 1997;204(1):272-277. DOI: 10.1148/radiology.204.1.9205259. PMID: 9205259
- [32] Mansfield P, Coxon R, Glover P. Echo-planar imaging of the brain at 3.0 T: First normal volunteer results. *Journal of Computer Assisted*

Tomography. 1994;**18**(3):339-343. DOI: 10.1097/00004728-199405000-00001. PMID 8188896

[33] Robitaille PM, Abduljalil AM, Kangarlu A, Zhang X, Yu Y, Burgess R, et al. Human magnetic resonance imaging at 8 T. *NMR in Biomedicine*. 1998;**11**(6):263-265. DOI: 10.1002/(SICI)1099-1492(199810)11:6<263:AID-NBM549>3.0.CO;2-0. PMID: 9802467

[34] Abdallah Y. Increasing of edges recognition in cardiac Scintigraphy for ischemic patients. *Journal of Biomedical Engineering and Medical Imaging*. 2016;**2**(6):39-40

[35] Vaughan T, DelaBarre L, Snyder C, Tian J, Akgun C, Shrivastava D, et al. 9.4T human MRI: Preliminary results. *USA: Magnetic Resonance in Medicine*. 2006;**56**(6):1274-1282. DOI: 10.1002/mrm.21073. PMC 4406343. PMID 17075852

[36] Ebel K, Benz-Bohm G. *Differential Diagnosis in Pediatric Radiology*. Thieme; 1999. 538 p. ISBN 978-3-13-108131-5. Retrieved 18 July 2011

[37] Bradley WG, Brant-Zawadzki M, Cambray-Forker J. *MRI of the Brain*. India: Surendra Kumar; 2001. ISBN 978-0-7817-2568-2. Retrieved 24 July 2011

[38] Roos KL, Tunkel AR. *Bacterial Infections of the Central Nervous System*. India: Elsevier Health Sciences; 2010. 69 p. ISBN 978-0-444-52015-9. Retrieved 18 July 2011

[39] American Medical Society for Sports Medicine. "Five Things Physicians and Patients Should Question," Choosing Wisely: An initiative of the ABIM Foundation, American Medical Society for Sports Medicine; 2014. Retrieved 29 July 2014

[40] Churchill Nathan W, Hutchison Michael G, Doug R, General L, Graham

Simon J, Schweizer Tom A. The first week after concussion: Blood flow, brain function and white matter microstructure. *NeuroImage: Clinical*. USA. 2017;**14**:480-489

[41] Garel C. *MRI of the Fetal Brain: Normal Development and Cerebral Pathologies*. USA: Springer; 2004. ISBN 978-3-540-40747-8. Retrieved 24 July 2011

[42] Butler P, Mitchell AW, Ellis H. *Applied Radiological Anatomy for Medical Students*. United Kingdom: Cambridge University Press; 2007. 12 p. ISBN 978-0-521-81939-8. Retrieved 18 July 2011

[43] Tofts P. *Quantitative MRI of the Brain: Measuring Changes Caused by Disease*. USA: John Wiley and Sons; 2005. 86 p. ISBN 978-0-470-86949-9. Retrieved 18 July 2011

[44] Chowdhury R, Wilson I, Rofe C, Lloyd-Jones G. *Radiology at a Glance*. USA: John Wiley and Sons; 2010. 95 p. ISBN 978-1-4051-9220-0. Retrieved 18 July 2011

[45] Granacher RP. *Traumatic Brain Injury: Methods for Clinical and Forensic Neuropsychiatric Assessment*. CRC Press. 247 p; 2007. ISBN 978-0-8493-8138-6. Retrieved 18 July 2011

[46] Goss CH, Ratjen F. Update in cystic fibrosis. *American Journal of Respiratory and Critical Care Medicine* 2013. 2012;**187**:915-919. DOI: 10.1164/rccm.201301-0184UP

[47] Elborn JS. Cystic fibrosis. *The Lancet*. 2016;**388**:2519-2531. DOI: 10.1016/S0140-6736(16)00576-6

[48] Ramsey BW, Welsh MJAJRCCM. 100-year anniversary. Progress along the pathway of discovery leading to treatment and cure of cystic fibrosis. *American Journal of Respiratory and Critical Care Medicine*. 2017;**195**:1092-1099

- [49] Ratjen F, Bell SC, Rowe SM, et al. Cystic fibrosis. *Nature Reviews. Disease Primers*. 2015;**1**
- [50] Ong T, Ramsey BW. Update in cystic fibrosis. *American Journal of Respiratory and Critical Care Medicine* 2015. 2014;**192**:669-675. DOI: 10.1164/rccm.201504-0656UP
- [51] Weill D, Benden C, Corris PA, et al. A consensus document for the selection of lung transplant candidates: 2014--an update from the pulmonary transplantation Council of the International Society for heart and lung transplantation. *The Journal of Heart and Lung Transplantation*. 2015;**34**:1-15
- [52] Reznikov LR. Cystic fibrosis and the nervous system. *Chest*. 2017;**151**:1147-1155
- [53] Liou TG. The clinical biology of cystic fibrosis transmembrane regulator protein: Its role and function in extrapulmonary disease. *Chest*. 2019;**155**:605-616
- [54] Willison HJ, Muller DP, Matthews S, et al. A study of the relationship between neurological function and serum vitamin E concentrations in patients with cystic fibrosis. *Journal of Neurology, Neurosurgery, and Psychiatry*. 1985;**48**:1097-1102
- [55] Cynamon HA, Milov DE, Valenstein E, et al. Effect of vitamin E deficiency on neurologic function in patients with cystic fibrosis. *The Journal of Pediatrics*. 1988;**113**:637-640
- [56] Hamid B, Khan A. Cerebral hemorrhage as the initial manifestation of cystic fibrosis. *Journal of Child Neurology*. 2007;**22**:114-5. 12-46
- [57] Mérelle ME, Griffioen RW, Dankert-Roelse JE. Cystic fibrosis presenting with intracerebral haemorrhage. *Lancet*. 2001;**358**
- [58] Sritippayawan S, MacLaughlin EF, Woo MS. Acute neurological deficits in a young adult with cystic fibrosis. *Pediatric Pulmonology*. 2003;**35**:147-5114
- [59] Rao DS, Infeld MD, Stern RC, et al. Cough-induced hemiplegic migraine with impaired consciousness in cystic fibrosis. *Pediatric Pulmonology*. 2006;**41**:171-176
- [60] Goldstein AB, Goldstein LS, Perl MK, et al. Cystic fibrosis patients with and without central nervous system complications following lung transplantation. *Pediatric Pulmonology*. 2000;**30**:203-206
- [61] Živković SA, Jumaa M, Barišić N, et al. Neurologic complications following lung transplantation. *Journal of the Neurological Sciences*. 2009;**280**:90-93
- [62] Atlante A, Favia M, Bobba A, et al. Characterization of mitochondrial function in cells with impaired cystic fibrosis transmembrane conductance regulator (CFTR) function. *Journal of Bioenergetics and Biomembranes*. 2016;**48**:197-210
- [63] Kelly M, Trudel S, Brouillard F, et al. Cystic fibrosis transmembrane regulator inhibitors CFTR(inh)-172 and GlyH-101 target mitochondrial functions, independently of chloride channel inhibition. *The Journal of Pharmacology and Experimental Therapeutics*. 2010;**333**:60-69
- [64] Abdallah Y. *Application of Analysis Approach in Noise Estimation, Using Image Processing Program*. Germany: Lambert Publishing Press GmbH & Co. KG; 2011. pp. 123-125 [4]
- [65] Abdallah Y, Yousef R. Augmentation of X-rays images using pixel intensity values adjustments. *International Journal of Science and Research (IJSR)*. 2015;**4**(2):2425-2430

[66] Abdallah Y. Increasing of Edges Recognition in Cardiac Scintigraphy for Ischemic Patients. Germany: Lambert Publishing Press GmbH & Co. KG; 2011. pp. 123-125

[67] Abdallah YMY, Abdallah M. Using basic morphology tools in improvement of kidneys detection. International Journal of Science and Research (IJSR). 2015;4(5):1383-1386

[68] Abdallah Y. Increasing of edges recognition in cardiac scintigraphy for ischemic patients. Journal of Biomedical Engineering and Medical Imaging. 2016;2(6):40-48

IntechOpen