

We are IntechOpen, the world's leading publisher of Open Access books Built by scientists, for scientists

4,800

Open access books available

122,000

International authors and editors

135M

Downloads

Our authors are among the

154

Countries delivered to

TOP 1%

most cited scientists

12.2%

Contributors from top 500 universities



WEB OF SCIENCE™

Selection of our books indexed in the Book Citation Index
in Web of Science™ Core Collection (BKCI)

Interested in publishing with us?
Contact book.department@intechopen.com

Numbers displayed above are based on latest data collected.

For more information visit www.intechopen.com



The Esteem[®], Fully Implantable Middle Ear Device

Maurizio Barbara and Simonetta Monini

Abstract

The active middle ear implant (AMEI) may be considered, in selected cases, a valid alternative to conventional hearing aids (cHA) for rehabilitation of bilateral sensorineural hearing loss (SNHL). Since 2007, at the Implanting Centre of the University Hospital Sant'Andrea in Rome, 43 subjects underwent surgery for application of the Esteem[®], after ascertaining by CT scan its feasibility for allocating its transducers within the mastoid space. The surgical procedure is longer than for the other AMEI, and the switch on of the device is usually performed 4–6 weeks after surgery. All the Esteem[®] implantees underwent a pre- and postoperative assessment via pure tone and speech audiometry with headset in a soundproof booth. Along with the recommended population with moderate-to-severe hearing loss, subjects also with a worse hearing loss (severe or severe-to-profound) were selected for this implant for different reasons. The auditory outcome in label and off-label implantees was analyzed. Complications included the need for a minor revision, due to middle ear fibrosis, or for an explant that was followed by ossicular reconstruction with return to a cHA (two subjects), cochlear implantation (five subjects) or no alternative solution (one case).

Keywords: Esteem, active middle ear implant, fully-implantable device, sensorineural hearing loss, hearing rehabilitation

1. Introduction

Active middle ear implants (AMEI) represents today one of the possible rehabilitative solutions for hearing-impaired individuals. These devices utilize, for their function, a vibratory effect instead of the classical, physiological air-conducted sound stimulation. This natural sound transmission way, if warranting the perfect solution under normal hearing conditions, usually generates several negative issues on a hearing-impaired ear, going from an insufficient stimulation to the presence of distortions when the conventional hearing amplifiers, i.e. hearing aids (HA), are in use. In fact, despite their striking technological improvement over the last decades (advanced miniaturization, open-fitting systems, sophisticated digital signal processing software, and wide connectivity), the latter are rarely showing to be optimal for the patients' auditory needs while generating distorted amplification issues (feedback, occlusion effect, and insufficient high-frequency gain). As a consequence, the number of HA users is far from equaling the purchased devices worldwide. Another playing factor is due to the scarce impact on some quality of life issues (manual difficulty, stigma, pathology, or reduced caliber of the external

auditory canal, earmold allergies, and impossibility to use them during water contact, physical activities, and overnight, while sleeping).

The advent of AMEI with the stimulation pathway different from the normal (or amplified) sound, i.e., the electromechanical one, has paved the way for the possible theoretical resolution of the above-mentioned annoying cHA-related issues. In fact, these devices are directly coupled to middle or inner ear elements (ossicular chain or part of it, round window membrane) for achieving close-field cochlear stimulation, and should theoretically overcome most of the issues deriving from the obligatory acoustic over-stimulation that needs to be delivered by an external amplifier, such as a cHA. Moreover, all of them leave the external ear canal free, so as to improve the auditory and physical occlusion issues, as well as the compatibility with external ear canal or middle ear pathologies.

In relation to the presence of an external component, the AMEI can be distinguished in semi- or fully implantable devices, this latter term inherently meaning that all their components remain completely invisible under the skin. At the present time, only two fully implantable devices are available for the rehabilitation of sensorineural hearing loss (SNHL): the Carina[®] (Cochlear, Lane Cove, Australia) and the Esteem[®] (Envoy Medical Corporation, St. Paul, MN, USA). Both devices have in common the complete allocation inside the skull, while carrying at the same time some major differences, as listed in **Table 1**.

This last appealing factor is surely playing an important role for the decision-making process while counseling with a possible candidate, but it would not be wise to consider it as primary factor for its choice, and anyhow never replacing a preoperative use or trial with a best-fitted last-generation digital cHA.

At Sant'Andrea University Hospital, Rome, Italy, an extensive rehabilitative program for hearing impairment has been applied since nearly 15 years, mostly aiming at the resolution of different types and severity of conductive, mixed and SNHL. In particular, from 2007, a series of subjects affected by bilateral SNHL have undergone Esteem[®] surgical application. The Esteem[®] (Envoy Medical, St Paul, MN, USA) middle ear implant has recently been reported to be beneficial for individuals affected by moderate-to-severe bilateral SNHL, with low morbidity and complication rate [1, 2]. This device works via a piezoelectric vibratory stimulus on the stapes and thereafter to the inner ear fluids, also vibrating the intact eardrum that plays as natural microphone. Following this physiological route, a natural sound quality is likely to be perceived by preserving auricular filtering (at high frequencies) and leaving the ear canal open, thus eliminating the occlusion effect.

The aim of the present report is to highlight specific clinical issues including those that have emerged while following up the Esteem[®]-implanted patients over several years. In particular, special attention is devoted to the surgical procedure; to the functional outcome, also in comparison with the performance with cHA, and its impact on the quality of life; to the battery, in terms of its variable duration and surgical replacement; and, finally, to the complication occurrence and rate.

Essential features of fully implantable AMEI				
	Microphone	Battery	Stimulation	FDA approval (by June 2019)
Esteem	No	Periodic surgical change	Piezoelectric	Yes
Carina	Yes	Daily recharge	Electromagnetic	No

Table 1. Features of the two fully implantable hearing systems available today; FDA: Food and Drug Administration.

The implantable components of the Esteem[®] are represented by a sound processor (SP), powered by a nonrechargeable battery, and two piezoelectric transducers, i.e., the sensor and the actuator (driver) (**Figure 1**).

The SP titanium case is housed in a temporal bone niche and receives the electrical signals from the sensor cemented to the incus body. After being processed, the signals are sent to the driver cemented to the stapes head, with a vibrational movement that generates the perilymphatic wave for cochlear stimulation (**Figure 2**).

The Envoy Medical Company recommendations for candidacy include moderate to severe types of SNHL whilst its application is discouraged in patients with word recognition score (WRS) in quiet inferior to 40%. Nevertheless, recent reports have shown that Esteem[®] may provide large amplification ranges up to 2–4 kHz, regardless of degree of hearing loss [3].



Figure 1. The Esteem[®] middle ear implant. The sound processor is connected to the two transducers, namely the sensor and the driver.

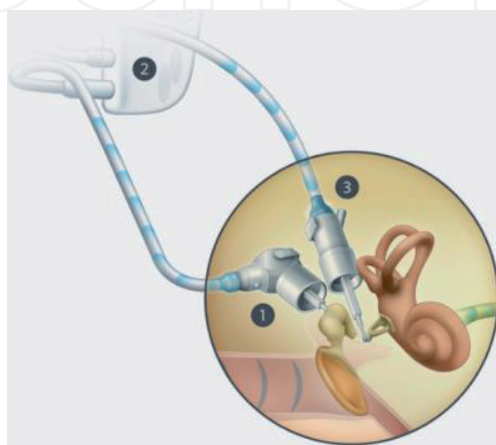


Figure 2. The two transducers connected to the sound processor (2) are then placed in contact with the ossicular chain: The sensor (1) to the incus body and the driver (3) to the stapes head.

2. Material and methods

All selected candidates were implanted with the Esteem[®] AMEI. Potential candidates were selected after a thorough audiometric assessment, which included pure tone and speech audiometry. In accordance with the Envoy Medical data, the advised threshold range is that reported in **Figure 3**, with a speech discrimination score better than 40%.

Once the audiological clearance is given, a preliminary CT scan of the petrous bone is carried out to assess the feasibility of the procedure, in particular, if the space inside the mastoid cavity would be sufficient for housing the two transducers: the sensor on the incus body, by measuring the distance between the incus body and the sino-dural angle, and the driver on the stapes head, through a wide posterior tympanotomy, going posteriorly toward the sigmoid sinus region and lateral to the mastoid facial nerve course. At this point, all the information regarding use, time of use, and performances with a cHA is taken and thoroughly evaluated by speech audiometry in quiet and noise as well as by specific questionnaires.

The surgical procedure is performed under general anesthesia, with facial nerve monitoring and under hypotensive control all along the surgical steps, especially when cementing is taking place. The main steps of the surgical procedure are summarized as follows:

1. Identification of a flat, retro-auricular area in which a bony niche for the sound processor (SP) can be drilled. Accordingly, the skin incision is outlined and injected with vasoconstrictor solution.
2. A lazy-C retro-auricular incision, including skin and subcutaneous tissue, is carried out. After placement of self-retaining retractors, a large Palva flap is created and elevated with an anteriorly based pedicle. The SP bone well is then drilled by using large (6–8 mm) cutting and diamond burs, ending up by drilling two small holes on both sides for securing the SP to the skull at the end of surgery by nylon thread.
3. An enlarged mastoidectomy is then drilled, completely exposing the presigmoid area, the sino-dural angle, and the inferior mastoid cell tip area.

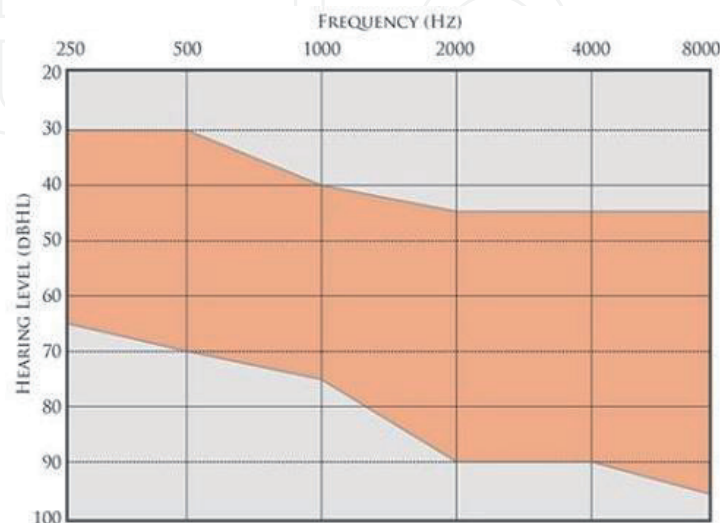


Figure 3.
The audiometric range of indication for the Esteem[®] fully implantable hearing device.

4. Posterior epitympanectomy is then carried out until getting the complete exposure of the incus body and the malleus head, with the incudomalleolar joint.
5. Posterior tympanotomy is then drilled, thinning out—but keeping intact—the posterior buttress; drilling is continued until a gross trapezoidal-shaped opening is obtained at the expense of the chorda tympani nerve, which needs to be severed in all cases to avoid its eventual contact with the driver transducer. The lateral aspect of the posterior tympanotomy will correspond to the fibrous tympanic annulus. The superior corner of the posterior tympanotomy is drilled until obtaining an acute angle. The whole long process of the incus and the pyramidal eminence needs to be optimally visualized.
6. After placing a soft insert microphone—connected to a laser Doppler vibrometer (LDV) System—into the external auditory canal, two small reflectors are placed on the incus body and on the posterior crus of stapes for allowing the assessment of the normal mobility of the intact ossicular chain [4]. LDV, mounted on a second microscope, checks first the intact chain movement, which should mandatorily give normal values before continuing the procedure. LDV is a very accurate (G1 10 j4 Km), noncontact instrument that works by comparing the frequency of the emitted laser diode light with the frequency of the reflected light of the moving object (**Figure 4**). Sound at 100-dB SPL and a sweep of 50 frequencies ranging from 125 to 8.000 Hz are used.
7. Separation of the incudostapedial joint is performed after gently removing the overlying mucosa.
8. By diode laser, then, part of the long incus process is sectioned.
9. At this point, removal by scraping of the mucosa over the stapes head is accomplished after dyeing the area with methylene blue, and finally drying it with low-watt laser beam.
10. A drop of EnvoyCem[®] (a bioglass type of biological cement) is then applied on the stapes head, so that a “precoat” is obtained.
11. Both sensor and drivers transducers are then attached to the Glasscock stabilizers screwed on the posterior edge of the mastoidectomy cavity and are then placed on the incus body and on the precoated stapes head, respectively.
12. MedCem[®] (an hydroxyapatite type of biological cement) is then composed and syringed into the mastoidectomy cavity for keeping and permanently fixing the transducers’ bodies in place.
13. A small drop of EnvoyCem[®] is then placed to cement the tip of the driver on the precoated stapes capitulum, as well as between the sensor tip and the incus body, followed by creation of a new joint (detachment of the cemented sensor tip from the incus body).
14. Laser Doppler vibrometer (LDV) measurements are then performed, for testing both sensor and driver efficiency.

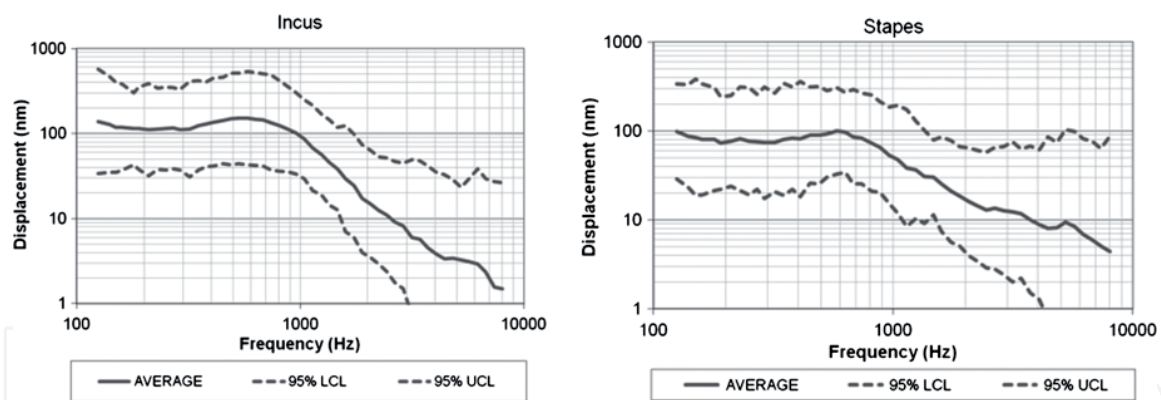


Figure 4. Normative data regarding displacement of the incus (left) and stapes (right) when measured by laser Doppler vibrometry.

15. The SP is then put in place and attached to the sensor and driver cables. Final LDV measurements of the whole system are then carried out and precede the end of surgery with a three-layer closure.

A bandage is then wrapped around the head and kept for 24 h. The implant is activated approximately 2 months after surgery, with the first fitting session, and later upgraded every 3 months during the first postoperative year.

Once required, the SP will be substituted via a minor surgical procedure, often-times performed under local anesthesia. The procedure entails a C-shaped, 5-cm long skin incision behind the SP that is subsequently exposed to allow first the disconnection from the cables of the two transducers, then their reconnection to the new SP.

3. Results

Eighty-two surgeries were performed in total, being 46 as primary intervention, 6 explantation, 4 revisions, and 27 battery changes. In three of the 46 primary surgeries, the procedure was interrupted due to low motility of the ossicular chain as shown by LDV in two cases and insufficient mastoid space in one case. So, the overall number of implants was 43. Implantation was always performed unilaterally, in the worse functioning ear of bilaterally hearing-impaired subjects; one subject was implanted while presenting with a unilateral severe SNHL. Bilateral application was completed in two subjects. Revision surgery was needed in three subjects for a developed fibrous tissue formation that impeded the normal movement of the ossicular chain and the transducers.

The outcome from Esteem[®] implantation has been analyzed taking into account several aspects, going from (a) the auditory improvement, (b) the comparison with the efficacy of a conventional hearing aid, (c) the patient's quality of life, and (d) the complication rate and the solutions for resolving these latter.

4. Auditory improvement

The mean postoperative pure tone threshold measured between 250 and 4000 Hz revealed an improvement of 5–10 dB in 9 subjects, 11–20 dB in 17 cases, 21–30 dB in 5 cases, and more than 30 dB in 3 cases. A –10/–20-dB deterioration was found in two subjects, and a –5/–10-dB deterioration was found in three subjects. Overall, more than 80% of the implanted subjects showed an improvement in respect to the preoperative unaided bone conduction thresholds. More specifically,

an improved threshold at 4 kHz was measured in 62.5% of the implantees, while at 8 kHz, it was detected in 35% of them.

4.1 Esteem vs. hearing aids

The data relative to the efficacy of the Esteem[®] AMEI in comparison with the hearing aids has already been object of a previous publication [5]. In that report, two groups of subjects were identified: the first one with a moderate-to-severe SNHL and the other one with severe-to-profound SNHL, being theoretically beyond the indication range limit recommended by the manufacturer (off-label). In moderate-to-severe cases, no statistical differences with the hearing aids were shown in the speech-in-noise tests, while subjectively, the implanted subjects reported a higher level of satisfaction in terms of a better quality of life. In the severe-to-profound subjects, similar results were obtained so as to also consider this range of hearing loss, a plausible threshold for implantation, as also outlined by other investigators [6]. The mean gain difference in favor of the Esteem[®] versus a cHA was equal to 13.1 dB, thus very similar to what previously reported by Kraus et al. [6].

4.2 Quality of life

The data relative to the quality of life issue has already been reported [7]. This group of patients has been pooled together with other subjects receiving different types of auditory implant. In total, this survey has taken into consideration the 26 Esteem[®] subjects who were all asked to fill different questionnaires including the General Glasgow Benefit Inventory, the visual analogue scale (VAS), and the abbreviated profile of hearing aid benefit (APHAB). The improvement of quality of sound was similar to the other implanted devices, whilst the score for quality of life was superior to both percutaneous bone conductive implants and to the Vibrant Soundbridge[®] (Medel, Innsbruck, Austria), equaling only that measured with the Bonebridge[®] (Medel, Innsbruck, Austria).

4.3 Complications

It is important to distinguish two typologies of complications: one related to the surgical procedure, being inescapably part of it, and the other one as true complications. The surgical procedure implies the disconnection between incus and stapes so that an additional conductive component to the subject's hearing loss is always postoperatively evident. The other aspect regards the need for sacrificing the chorda tympani nerve so that a taste disturbance could be the consequence of it. In this regard, however, only a very limited number of subjects reported a permanent dysgeusia. Finally, it has also to be considered that the need to reconstruct the ossicular chain should an explantation be needed. Among the true complications, the need for explantation occurred in six subjects: for skin dehiscence (one subject), loud noise (one subject), tinnitus (one subject), and hearing threshold deterioration (three subjects). Four subjects required a surgical revision and in about 9% of the cases, a delayed transient facial palsy was observed, with remarks that were object of a previous publication [8].

5. Discussion

The Esteem[®] fully implantable AMEI represents a real alternative to conventional hearing aids when this latter one show to be inappropriate or unable

to provide an efficient auditory amplification and in highly selected cases. More specifically, with a vibratory, direct stimulation of the anatomical structures located close to the cochlea, such as the stapes, footplate, or round window membrane, the delivered energy is much lower than that required for a cHA.

The activity of the Implanting Centre at Sapienza University has been displayed by the application of several types of bone conductive implants and AMEI, these latter as semi- and fully implantable devices. Among them, the Esteem[®] AMEI was specifically considered attractive for the invisibility as well as for the absence of an implanted microphone. This premise has allowed us to collect the largest European experience since 2007, with several subjects that have reached today a long-term use of the device so as to allow us to draw some interesting remarks that are worth being shared with the interested professionals (audiologists, otologists, etc.).

First to mention is the typology of mechanical stimulation that is obtained via a piezoelectric modality. The bellow of both transducers is in fact made of several layers of crystals that are able to deliver energy when displaced, and to be displaced when reached by energy. Furthermore, this type of modality can be considered optimal for high-frequency stimulation with limited energy consumption. This latter factor explains why for the Esteem[®] there is no need to recharge the battery that, however, needs to be replaced after a certain time of use (around 5 years on average in our overall experience). In this regard, it has been noticed that the battery was more likely to be extinguished faster in case of a continuous (24/24, 7/7) use and in case of more advanced forms of SNHL.

The surgical procedure is somewhat demanding even for experienced otosurgeons who must undergo laboratory training before starting with clinical application. The complexity of the procedure is mostly related to a few, important steps that require the use of different types of cement, as well as to specific dexterity in working in very narrow spaces opened during the procedure, like for example when cementing the driver together with the precoated stapes head through the posterior tympanotomy. This is explaining why the surgical procedure can take long time especially with the first cases. In this regard, it is noteworthy to stress the importance of a bioengineer present in the operating theater, carrying out objective measurements by LDV during and at the end of surgery, thus offering confident and supporting data to the surgeon for a beneficial final functional outcome. As far as cement is concerned, two different types were used: a bio glass cement in small amounts for stapes pre-coating, incus neo-joint and stapes/driver fusion, and when larger amounts of cement were needed, as for stabilization of the transducers body within the mastoidectomy cavity, a hydroxyapatite compound was used.

Apart from the inescapable complications related to the laser resection of part of the incus long process and to the ablation of the chorda tympani nerve, no other intraoperative complications were recorded in our series. However, in less than 10% of the subjects, delayed, transient facial nerve palsy developed, with return to normality in all cases within the first month after onset.

The auditory outcome has been shown to be positive in over 80% of the subjects, although with variable degrees of improvement. In very few cases, it has been necessary to perform a revision surgery for debridement of newly formed fibrous tissue in the middle ear that was impeding the normal motility of the transducers. Another interesting finding relates to the observation of a striking decrease of the auditory threshold (as bone conduction) observed over time especially in those individuals who presented an advanced SNHL, being severe-to-profound, while not affecting the contralateral, non-implanted ear, so as to rule out to be dependent upon the causative factor. This new functional situation was in some cases still managed by setting the Esteem SP accordingly, while in a few subjects required the “transition” to cochlear implantation.

As mentioned before, the Esteem[®] is not requiring a daily battery recharge, contrary to the other fully implantable device existing today (Carina[®]). Therefore, the protocol entails a surgical substitution when the battery is going to extinguish (signaled by a double beep heard by the subject, a few weeks before end of the function). While the company mentioned a duration between 5 and 9 years, our personal experience showed a shorter duration, on average being 4–5 years, related mostly to the duration of use and to the severity of SNHL. In fact, most of the subjects were never switching off the device, as proof of achievement of a better quality of life in several daily moments (washing, bathing, sleeping, and performing physical activities). This important feature belonging to an invisible system has also been object of a previous report [7].

6. Conclusions

The fully implantable Esteem[®] active middle ear device has shown to provide a beneficial hearing gain in the majority of the implanted subjects. Our experience has shown that this may be achieved with very low morbidity as verified by the low incidence of complications. Other than for moderate-to-severe SNHL, the Esteem[®] may be indicated also for worse hearing threshold for which it can still provide a beneficial auditory and quality of life outcome. Despite its active mechanical role for eliciting cochlear stimulation, in certain candidates, it has been shown a progressive deterioration of the bone conduction threshold so as to limit the use of the implant and rather suggest cochlear implantation.

Acknowledgements

The authors wish to express their gratitude to Dr Kelly Brooks who helped with intra-operative measurements and patients' audiological fitting.

Conflict of interest

No conflict of interest to declare.

Author details

Maurizio Barbara* and Simonetta Monini
ENT Clinic, NESMOS Department, Sapienza University, Rome, Italy

*Address all correspondence to: maurizio.barbara@uniroma1.it

IntechOpen

© 2019 The Author(s). Licensee IntechOpen. This chapter is distributed under the terms of the Creative Commons Attribution License (<http://creativecommons.org/licenses/by/3.0>), which permits unrestricted use, distribution, and reproduction in any medium, provided the original work is properly cited. 

References

- [1] Kraus EM, Shohet JA, Catalano PJ. Envoy Esteem totally implantable hearing system: Phase 2 trial. I-year hearing results. *Otolaryngology and Head and Neck Surgery*. 2011;**23**:1-10
- [2] Kraus EM, Shohet JA, Catalano PJ. Totally implantable hearing system: Five-year hearing results. *Laryngoscope*. 2018;**128**:210-216
- [3] Barbara M, Biagini M, Monini S. The totally implantable middle ear device 'Esteem' for rehabilitation of severe sensorineural hearing loss. *Acta Oto-Laryngologica*. 2011;**131**:399-404
- [4] Seidman MD, Standing RT, Ahsan S, et al. Normative data of incus and stapes displacement during middle ear surgery using laser Doppler vibrometry. *Otology & Neurotology*. 2013;**34**:1719-1724
- [5] Monini S, Biagini M, Atturo F, Barbara M. Esteem middle ear device versus conventional hearing aids for rehabilitation of bilateral sensorineural hearing loss. *European Archives of Oto-Rhino-Laryngology*. 2013;**270**:2027-2033
- [6] Shohet JA, Kraus EM, Catalano PJ. Profound high-frequency sensorineural hearing loss treatment with a totally-implantable hearing system. *Otology & Neurotology*. 2011;**32**:1428-1431
- [7] Monini S, Bianchi A, Talamonti R, Atturo F, Filippi C, Barbara M. Patient satisfaction after auditory implant surgery: Ten-year experience from a single implanting unit center. *Acta Oto-Laryngologica*. 2016;**137**:389-397
- [8] Barbara M, Volpini L, Monini S. Delayed facial nerve palsy after surgery for the Esteem fully implantable middle ear hearing device. *Acta Oto-Laryngologica*. 2014;**134**:429-432