

We are IntechOpen, the world's leading publisher of Open Access books Built by scientists, for scientists

4,800

Open access books available

122,000

International authors and editors

135M

Downloads

Our authors are among the

154

Countries delivered to

TOP 1%

most cited scientists

12.2%

Contributors from top 500 universities



WEB OF SCIENCE™

Selection of our books indexed in the Book Citation Index
in Web of Science™ Core Collection (BKCI)

Interested in publishing with us?
Contact book.department@intechopen.com

Numbers displayed above are based on latest data collected.

For more information visit www.intechopen.com



Robotic Sacrocolpopexy for Treatment of Prolapse of the Apical Segment of the Vagina

Kwang Jin Ko and Kyu-Sung Lee

Abstract

Abdominal sacrocolpopexy for apical prolapse repair is the gold standard treatment and is more effective and durable than the transvaginal approach. The increase in minimally invasive surgery has led to attempts at laparoscopic sacrocolpopexy, but this technique has not gained popularity due to complex procedures and a steep learning curve. Robotic sacrocolpopexy overcomes these issues and has yielded good results for more than 15 years, with equivalent outcomes and safety to open and laparoscopic sacrocolpopexy (LSC). LSC is still a useful procedure for experienced surgeons, but it is expected that robot-assisted sacrocolpopexy (RSC) will have better results overall due to the advantages of the robotic instrument. The most important advantage is that surgeons who are inexperienced with minimally invasive approaches can more readily master RSC compared to overcoming the steep learning curve of LSC.

Keywords: pelvic organ prolapse, robot, sacrocolpopexy

1. Introduction

Apical prolapse surgeries can broadly be separated into obliterative and restorative approaches. Restorative approaches can be performed transvaginally or abdominally. For patients desiring a restorative outcome, abdominal sacrocolpopexy remains the gold standard procedure, assuring superior outcomes for a variety of vaginal procedures. Sacrocolpopexy has traditionally been performed through laparotomy; however, attempts to develop minimally invasive approaches have increased to overcome the increased morbidity, longer surgery time, and longer hospital stay associated with open surgery. According to reports to date, laparoscopic sacrocolpopexy (LSC) has the advantages of a shorter hospital stay and decreased blood loss, but no benefit has been confirmed regarding surgery time, and its relatively longer learning curve has been seen as a limitation. To overcome these problems, robotic procedures began to be applied to sacrocolpopexy. After Di Marco et al. published the first study with five patients who underwent robot-assisted sacrocolpopexy (RSC) in 2004 [1], many cases have been reported, and good outcomes of RSC have been reported in apical prolapse repair. The main advantages of RSC are the three-dimensional view afforded by use of a robotic instrument, increased degrees of freedom in movement, elaborate sutures, and easy knot tying. Through the advantages of robotic surgery, LSC's technical limitations

and steep learning curve can be overcome. This chapter summarizes the case results, surgical methods, and latest trends of RSC.

2. Efficacy

Although open sacrocolpopexy is a good treatment option for apical prolapse repair, with long-term success rates of 78–100%, it is associated with increased length of hospital stay, analgesic requirements, and cost compared with transvaginal procedures [2, 3]. To overcome these limitations, new surgical techniques, such as LSC or RSC, have been developed. Compared with open sacrocolpopexy, LSC and RSC decrease overall morbidity and have good anatomical durability [4–10]. Although LSC overcomes many of the shortcomings of open sacrocolpopexy, it is more technically challenging for those not proficient in laparoscopy. Since 2004, implementation of RLC has provided surgeons the dexterity and precision of LSC without the learning curve needed for laparoscopic skills. One of the largest prospective studies (n = 120) of RSC had an anatomical success rate of 89% over a 12-month follow-up [11]. According to a recent systematic review of LSC vs. RSC, RSC is associated with longer surgery time, increased postoperative pain, and higher cost than LSC; however, the surgical options showed similar results in terms of improvement in symptoms [12].

According to the first systematic review of RSC in 2014, the cure rate for apical prolapse was 97–100%, and the overall objective cure rate (all compartments) was 84–100% [13]. In another systematic review, the anatomic cure rate was 98.6% with a mean follow-up of 26.9 months [14]. Relapse occurred in 6.4% of the patients, with anterior, apical, and posterior recurrent prolapse rates of 3.4, 0.4, and 2.6%, respectively. The reoperation rate was 3.3%, with 0.4% caused by apical recurrent prolapse and 2.9% caused by nonapical recurrent prolapse [13]. According to a recent prospective observational study of 144 patients who received RSC and follow-up observation for at least 1 year; the cure rate of apical prolapse after 12 months was 91%; the overall cure rate was 67%; and the recurrence rates of anterior, apical, and posterior prolapse were 15.7, 0.7, and 4.3%, respectively [15]. **Table 1** reports the perioperative outcomes and cure rates.

Recently, interest has increased regarding the subjective cure rate as well as the objective anatomical cure rate, and the results of subjective evaluations are increasingly reported. Evaluation of a subjective cure, though not meeting the strict standards for anatomic success determined using POP-Q stages, emphasizes the improvement in patient's overall symptoms after the surgery and their satisfaction with the outcome. The parameters evaluated are heterogeneous but often include pelvic floor distress inventory (PFDI), pelvic floor impact questionnaire (PFIQ-7), pelvic organ prolapse/urinary incontinence sexual function questionnaire (PISQ-12), urogenital distress inventory (UDI-6), and global quality of life (QOL). Therefore, though it is necessary to note how the results are analyzed, the subjective cure rate is approximately 95% with RSC, and the satisfaction rate is high at 90–100% [13, 15, 16].

3. Safety and complications

According to two meta-analyses, estimated blood loss with RSC is 50–82.5 ml, and length of hospital stay is 2–2.4 days. Median surgery time is 194 min, with a wide range from 75 to 536 min, depending on the study. Hysterectomy was conducted in 33% of the patients included in the meta-analyses, and anti-incontinence

Study	Year	Study design	Robot cases	Mean or median follow-up (month)	Objective cure rate (%)	Mean or median estimated blood loss (ml)	Mean or median hospital stay (day)	Conversion rate (%)	Mean or median (range) op time (min)	Overall complication rate (%)	Mesh extrusion (%)
Anger	2014	RCT	40	6	NR	85.1	NR	0	294 (180–648)	15	0
Barbogilo	2014	RS	127	12	92	127.7	2	0	124.2	10	2.4
Belsante	2013	RS	35	28	91	71	1.7	0	288 (210–390)	14	3
Benson	2010	RS	33	32	97	71	1.1	0	227 (137–346)	6	0
Culligan	2014	PS	143	12	84	51.2	1	0	148 (75–250)	NR	0
Elliott, D	2006	RS	31	24	95	NR	1.03	3	186 (129–285)	23	6
Kramer	2009	RS	21	25.2	93	<50	1.1	0	194	NR	NR
Louis-Sylvestre	2013	RS	90	15.6	93	NR	3.5	0	246 (180–415)	9	0
Salamon	2013	PS	120	12	89	49	1	0	161	1	0
Seror	2012	PS	20	15	98.5	55	5.1	5	125	30	0
Siddiqui	2012	RS	125	18.3	94	90	NR	0	NR	19	2.4
Tan-Kim	2011	RS	43	6	90	86	1	0	281	NR	5
Xylinas	2010	RS	12	19.1	100	60	3.4	0	144	0	0
Parasio	2011	RCT	40	NR	88	NR	1.8	9	257 (191–381)	43	5

Study	Year	Study design	Robot cases	Mean or median follow-up (month)	Objective cure rate (%)	Mean or median estimated blood loss (ml)	Mean or median hospital stay (day)	Conversion rate (%)	Mean or median (range) op time (min)	Overall complication rate (%)	Mesh extrusion (%)
Jong	2018	RS	56	64	93	56	2.7	NR	234	NR	3
Zanten	2019	PS	188	12	91	25	1.0	4.3	145.3	5.3	2.1

Table 1.

Summary of efficacy, perioperative outcomes, and complications in robot-assisted laparoscopic sacrocolpopexy (PS, prospective study; RCT, randomized controlled trial; RS, retrospective study).

surgery was conducted simultaneously in 38% of patients. Therefore, it is likely that concomitant surgical procedures (including total hysterectomy, anti-incontinence procedures, and other transvaginal prolapse surgeries) contribute to the heterogeneity of surgery time [13, 14].

In the analyses above, diverse complications were reported. The overall conversion rate to open surgery was 0–8.6%, and the overall postoperative complication rate was approximately 10%. Using the Clavien-Dindo classifications for complications, 7% were Grade 1–2, <1% were Grade 3a, 2% were Grade 3b, and no Grade 4–5 complications were reported. The mesh erosion rate was 0–8% [13, 14]. Recently, a prospective, long-term study of mesh erosion after implementation of the RSC was published. Of the 69 patients analyzed, three experienced mesh erosion (3.1%) during a median 48.1 months of follow-up. Subsequent Kaplan-Meier analysis estimated an erosion rate of 5.3% in 5 years of RSC. Through additional literature analysis, the authors found that the reported erosion rate varied from 0 to 13.3% but was less than 5% in 83% of the studies, and the overall erosion rate was approximately 1.9%. Due to mesh-related complications, its use has been limited recently; however, the risk associated with transabdominally placed synthetic mesh is extremely low, and the mesh-related risk does not increase with RSC. **Table 1** lists the complications.

4. Surgical procedures

4.1 Patient positioning and port placement

The patient is placed in the lithotomy position with the Trendelenburg position to displace the bowel loops upward, providing more working space. The ports are placed in a W-shaped configuration. Generally, attached to three robot arms are one camera port and a fenestrated Grasper (Pro Grasp), robotic scissors (Hot Shears™), and one large needle driver; another port is used if necessary.

4.2 Vaginal dissection

The peritoneal cavity is assessed after robot docking. Because of the history of hysterectomy in vault prolapse patients, they may experience bowel adhesion, which must be addressed first. The mesh should be fixed to the anterior and posterior walls of the vagina; therefore, during vaginal dissection, it is important to properly detach the space between the bladder attachment to the anterior and the rectum attachment to the posterior (**Figure 1**). It is difficult to clearly distinguish the space between the cervix and bladder in patients with previous hysterectomy. Transvaginal use of a vagina manipulator aids in evaluating the anatomical structure of the surroundings. Retrograde bladder filling using a Foley catheter placed before surgery may be helpful in dissection by delineating the bladder margin. Since the plane between the anterior vaginal wall and the bladder is relatively avascular, if there is bleeding during dissection, it is typically because the wrong plane is being dissected, specifically the detrusor muscle or the vaginal muscularis.

There are no clear guidelines concerning the extent to which anterior dissection should proceed. In a systematic review of 21 randomized controlled trials, depth of vaginal dissection was a commonly described determination in the procedure that, however, involved significant heterogeneity [17]. In a survey conducted among the members of International Urogynecological Association and the American Urogynecological Society, 18% responded that they dissect only in the apex of the vagina, 56% to the mid-level of the vagina, and 25% to the level of the trigone. The

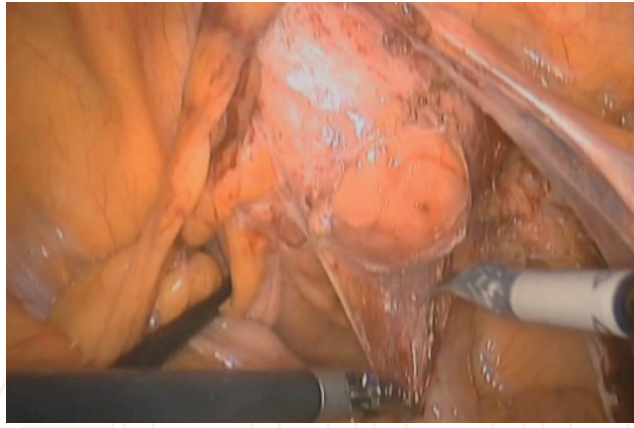


Figure 1.
Vaginal wall dissection.

generally accepted rule is to approach as close as possible to prevent recurrence but to not dissect deep to the trigone. Recently, preliminary data have been published measuring the bladder neck-mesh distance (BMD) using transvaginal ultrasound at the end of promontofixation. The BMD inversely correlated with the changes in C ($p = 0.01$) and Bp ($p = 0.04$) before and after surgery and with the complication rate ($p = 0.01$) but not with the difference in Ba. A BMD greater than 6 mm predicted the absence of postoperative *de novo* symptoms, and a short BMD predicted postoperative *de novo* symptoms such as urinary stress incontinence [18]. This indicates that BMD predicts the need for apical repair. It is necessary to conduct a well-organized study of surgical outcomes based on depth of anterior vaginal wall dissection; however, the authors judge that it is empirically sufficient to detach the anterior and posterior vaginal wall to the extent that the mesh arm is fixed (approximately the upper third of the vagina). If it is necessary to fix the mesh to the posterior vaginal wall as well, the vaginal wall should be carefully mobilized and dissected from the rectum followed by attempting to approach the recto-vagina space.

4.3 Presacral dissection

Presacral dissection is performed after dissection of the vaginal wall. The proximal arm of the mesh is fixed at the sacral promontory. The recommended sacral fixation point has changed due to concerns regarding hemorrhage and maintenance of the most natural vaginal axis. In the early 1970s, fixation of the mesh was typically at the level of S3/S4, but this was associated with a marked risk for hemorrhage. In 1981, Sutton et al. described fixation at the S1/S2 level for better visualization of the middle sacral artery and less risk of bleeding. Currently, the consensus is to affix the sacral arm of the mesh to the most superior point of the anterior surface of S1. However, even though attachment to the S1 region can decrease the risk of bleeding compared to other levels, it is necessary to use caution in dissection since the promontory can be anatomically unfamiliar, and there is a risk of bleeding due to the close proximity of the nerve to the surrounding blood vessels. Most of all, it is clearly necessary to be well informed regarding the anatomic relationships of the sacral promontory to other structures.

The first step in presacral dissection is retraction of the sigmoid colon to expose the peritoneum that covers the promontory. If it is difficult to expose the promontory due to surrounding bowel adhesion, adhesiolysis is performed. An important anatomical feature to aid in finding the promontory is the pulsating right common iliac artery (**Figure 2**). Starting from this point, the peritoneum in the most prominent region of the endoscopic view is opened first. It may be difficult for

inexperienced practitioners to find the exact position when the peritoneum is covered. In patients with thick presacral fat pads, it is especially difficult to identify the surrounding structures. In these cases, the right ureter may be a useful landmark as it is found approximately 30 mm lateral to the sacral promontory. Therefore, measuring 30 mm medial to the right ureter along the pelvic brim should allow the surgeon to identify the most likely location of the sacral promontory [19]. The peritoneum is then dissected, and the incision is typically extended to the cul-de-sac region to make space to cover the mesh. However, we prefer to make space by tunneling into the region of vaginal dissection instead of using a long incision in the posterior peritoneum. This is because tunneling can lessen the inconvenience of subsequent closure of the peritoneum.

4.4 Mesh and fixation

In an effort to decrease the morbidity associated with open sacrocolpopexy, RSC has rapidly gained popularity because it decreases the difficulty with laparoscopic knot tying and aids in sacral dissection due to three-dimensional visualization. However, variables in surgical technique include amount of vaginal dissection, type of mesh, number or location of sutures that should be placed to secure the suspending mesh, retroperitonealization of the mesh, and cervix preservation.

The chemical makeup of the synthetic material used in the mesh does not affect the success of the procedure. However, pore size is important in the ability of the host to eliminate bacteria. Macrophages and leukocytes can enter macroporous mesh and prevent infection. Fiber composition is interconnected with pore size; in multifilament mesh material, there are microporous interstices between the filaments. Thus, Type 1 mesh (i.e., macroporous and monofilament) should be used. We use pre-fashioned Y-shaped DynaMesh®-PRS, which is a polyvinylidene fluoride (PVDF) monofilament material. The use of pre-fashioned Y-shaped mesh compared to a self-fashioned mesh does not have a major impact on the success rate of the surgery [20]. The mesh is fixed to the anterior and posterior vaginal wall with multiple sutures to distribute tension on the vagina (Figure 3). The choice of suture material, suture gauge, and number of sutures may vary highly depending on surgical approach [17]. The traditional open sacrocolpopexy uses a nonabsorbable suture to prevent detaching the mesh from the vagina and sacral promontory and decreasing the risk of mesh exposure and suture erosion. In a study of RSC with a median follow-up of 33 months, the use of absorbable sutures for both vaginal and sacral mesh attachment was effective, and the 3-year rate of survival without repeat prolapse surgery was 93%. However, there was no benefit of the risk of

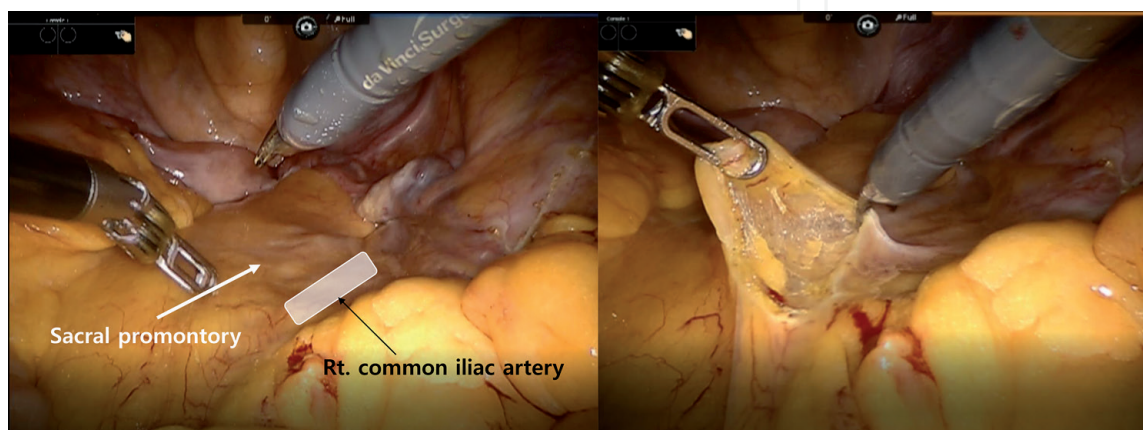


Figure 2.
Anatomy of sacral promontory (left) and presacral dissection (right).

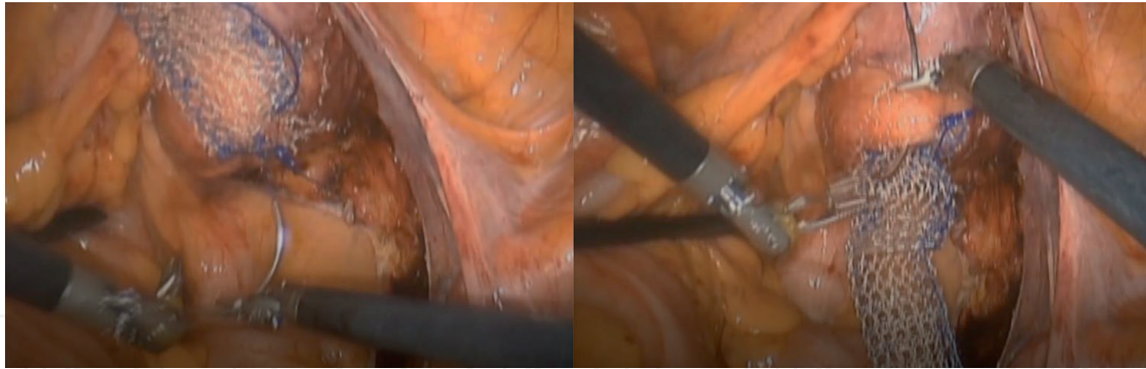


Figure 3.
Fix the mesh to the anterior and posterior vaginal wall.

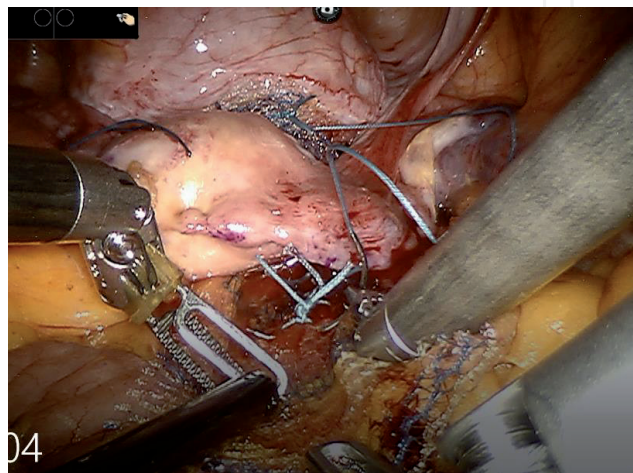


Figure 4.
Fixation of the proximal arm of mesh.

mesh erosion [21]. Although the evidence is still lacking, it is unlikely that absorbable sutures are a risk factor for mesh detachment. Further studies are needed to determine the proper location, number, and type of suture. Recently, a barbed absorbable suture material has been used in a continuous running suture along the vaginal wall with good results. Tan-Kim et al. [22] conducted a randomized study comparing non-barbed, interrupted sutures to barbed sutures (Quill™) for anchoring mesh to the vaginal wall during RSC. Among the patients, the non-barbed suture group had significantly longer surgery times than the barbed suture group (42 vs. 29 minutes, $p < 0.001$), and there was no significant difference in anatomic failure between the two groups at 12 months postoperation. Another retrospective study reported the outcomes of 20 patients who underwent RSC using barbed, delayed-absorption sutures (3-0 V-Loc 180, Covidien) to fix the mesh to the vaginal wall. There was no recurrence of apical prolapse or mesh exposure during the 1-year follow-up [23].

The proximal arm of the mesh should be fixed in the sacral promontory (**Figure 4**). At this time, the tension of the mesh should be adjusted while the prolapse is restored using the vaginal manipulator. Excessive tension may cause pain or irritative bladder symptoms after surgery. The mesh is sutured to the anterior longitudinal ligament overlying the sacrum with 2–5 sutures. As the endoscopic approach becomes more common, reports of postoperative discitis are gradually increasing. This is primarily caused by penetration of the L5-S1 disc; therefore, surgeons should ensure attachment to the S1 body below the disc. According to a study of spinal magnetic resonance images of subjects in the supine position, the

most prominent point of the promontory was the L5-S1 disc in 73% of cases, and the S1 body was located within 5 mm inferior to the promontory in 100% of the images reviewed [24]. Unless the position of the S1 body can be confirmed, surgeons should take into account the thickness of the anterior longitudinal ligament, which ranges from 1 to 2 mm, and should avoid deep suture bites that may penetrate into the disc.

It is optimal to suture the peritoneum after mesh fixation. A few reports have stated that they found no complications even though peritoneal closure was not conducted; however, it is preferable to perform this step to prevent bowel adhesion or intraabdominal mesh complications.

4.5 Single-port approach

The “single-port approach” is a sign of a new era in the field of minimally invasive surgeries with good cosmetic results and reduced patient morbidity compared with multiport surgery. Though single-port robotic surgery is in the early stage of application, it has been implemented in various surgical fields. Since 2017, a few reports on single-port RSC have been published and are being accepted as feasible techniques [25–28]. In 2017, Matanes et al. [27] reported the first 25 cases of single-port RSC. They demonstrated significant decreases in median total operative and console times (226 minutes for the first 15 cases vs. 156 minutes for the next 10 cases), which was in the same range as that reported for the initial experience with multiport access. There were no intraoperative adverse events. One case of small bowel obstruction required reoperation; however, that patient did not receive retroperitonealized mesh. That event altered the surgeon’s approach with all subsequent patients, who had mesh covered by the peritoneum. Recently, Liu et al. [26] published another case series of single-port RSC with a modified technique. They used retroperitoneal tunneling techniques and asserted that they could more easily perform a single-port approach as a result. A retroperitoneal tunnel was created by undermining the peritoneum with an articulated needle driver. The needle driver was placed in the peritoneal opening over the sacral promontory, and the tunnel was created just medial to the right uterosacral ligament in the direction of the vaginal vault. The tunnel was created using forward pressure and a sweeping motion to create a space within the retroperitoneum. This allowed easier adjustment and maintenance of mesh tension during placement of sutures in the sacral promontory compared with opening the entire retroperitoneal space and may reduce operative time and adhesion formation.

5. Conclusions

Despite the limitation that various methods are used by individual surgeons for evaluating the outcomes of pelvic organ prolapse repair and other surgical procedures, the use of RSC in apical prolapse repair has led to good long-term results in terms of efficacy and safety over the last 15 years. LSC is still a useful procedure for experienced surgeons, but it is expected that RSC will have better results overall due to the advantages of the robotic instrument. The most important advantage is that surgeons who are inexperienced with minimally invasive approaches can more readily master RSC compared to overcoming the steep learning curve of LSC.

IntechOpen

Author details

Kwang Jin Ko¹ and Kyu-Sung Lee^{2,3*}

1 Department of Urology, Kangnam Sacred Heart Hospital, Hallym University College of Medicine, Seoul, Republic of Korea

2 Department of Urology, Samsung Medical Center, Sungkyunkwan University School of Medicine, Seoul, Republic of Korea

3 Biomedical Engineering Research Center, Samsung Medical Center, Seoul, Republic of Korea

*Address all correspondence to: ksleedr@skku.edu

IntechOpen

© 2019 The Author(s). Licensee IntechOpen. This chapter is distributed under the terms of the Creative Commons Attribution License (<http://creativecommons.org/licenses/by/3.0>), which permits unrestricted use, distribution, and reproduction in any medium, provided the original work is properly cited. 

References

- [1] Di Marco DS, Chow GK, Gettman MT, Elliott DS. Robotic-assisted laparoscopic sacrocolpopexy for treatment of vaginal vault prolapse. *Urology*. 2004;**63**(2):373-376
- [2] Lee RK, Mottrie A, Payne CK, Waltregny D. A review of the current status of laparoscopic and robot-assisted sacrocolpopexy for pelvic organ prolapse. *European Urology*. 2014;**65**(6):1128-1137
- [3] Nygaard IE, McCreery R, Brubaker L, Connolly A, Cundiff G, Weber AM, et al. Abdominal sacrocolpopexy: A comprehensive review. *Obstetrics and Gynecology*. 2004;**104**(4):805-823
- [4] Anger JT, Mueller ER, Tarnay C, Smith B, Stroupe K, Rosenman A, et al. Robotic compared with laparoscopic sacrocolpopexy: A randomized controlled trial. *Obstetrics and Gynecology*. 2014;**123**(1):5-12
- [5] Costantini E, Mearini L, Lazzeri M, Bini V, Nunzi E, di Biase M, et al. Laparoscopic versus abdominal Sacrocolpopexy: A randomized, controlled trial. *The Journal of Urology*. 2016;**196**(1):159-165
- [6] Freeman RM, Pantazis K, Thomson A, Frappell J, Bombieri L, Moran P, et al. A randomised controlled trial of abdominal versus laparoscopic sacrocolpopexy for the treatment of post-hysterectomy vaginal vault prolapse: LAS study. *International Urogynecology Journal*. 2013;**24**(3):377-384
- [7] Geller EJ, Siddiqui NY, Wu JM, Visco AG. Short-term outcomes of robotic sacrocolpopexy compared with abdominal sacrocolpopexy. *Obstetrics and Gynecology*. 2008;**112**(6):1201-1206
- [8] Nosti PA, Umoh Andy U, Kane S, White DE, Harvie HS, Lowenstein L, et al. Outcomes of abdominal and minimally invasive sacrocolpopexy: A retrospective cohort study. *Female Pelvic Medicine & Reconstructive Surgery*. 2014;**20**(1):33-37
- [9] Paraiso MF, Jelovsek JE, Frick A, Chen CC, Barber MD. Laparoscopic compared with robotic sacrocolpopexy for vaginal prolapse: A randomized controlled trial. *Obstetrics and Gynecology*. 2011;**118**(5):1005-1013
- [10] Siddiqui NY, Geller EJ, Visco AG. Symptomatic and anatomic 1-year outcomes after robotic and abdominal sacrocolpopexy. *American Journal of Obstetrics and Gynecology*. 2012;**206**(5):435.e1-435.e5
- [11] Salamon CG, Lewis C, Priestley J, Gurshumov E, Culligan PJ. Prospective study of an ultra-lightweight polypropylene Y mesh for robotic sacrocolpopexy. *International Urogynecology Journal*. 2013;**24**(8):1371-1375
- [12] Pan K, Zhang Y, Wang Y, Wang Y, Xu H. A systematic review and meta-analysis of conventional laparoscopic sacrocolpopexy versus robot-assisted laparoscopic sacrocolpopexy. *International Journal of Gynaecology and Obstetrics: The Official Organ of the International Federation of Gynaecology and Obstetrics*. 2016;**132**(3):284-291
- [13] Serati M, Bogani G, Sorice P, Braga A, Torella M, Salvatore S, et al. Robot-assisted sacrocolpopexy for pelvic organ prolapse: A systematic review and meta-analysis of comparative studies. *European Urology*. 2014;**66**(2):303-318
- [14] Hudson CO, Northington GM, Lyles RH, Karp DR. Outcomes of robotic sacrocolpopexy: A systematic review and meta-analysis. *Female Pelvic Medicine & Reconstructive Surgery*. 2014;**20**(5):252-260

- [15] van Zanten F, Schraffordt Koops SE, O'Sullivan OE, Lenters E, Broeders I, O'Reilly BA. Robot-assisted surgery for the management of apical prolapse: A bi-Centre prospective cohort study. *BJOG: An International Journal of Obstetrics and Gynaecology*. 2019;**126**(8):1065-1073
- [16] Jong K, Klein T, Zimmern PE. Long-term outcomes of robotic mesh sacrocolpopexy. *Journal of Robotic Surgery*. 2018;**12**(3):455-460
- [17] Moroni RM, Juliato CRT, Cosson M, Giraudet G, Brito LGO. Does sacrocolpopexy present heterogeneity in its surgical technique? A systematic review. *Neurourology and Urodynamics*. 2018;**37**(8):2335-2345
- [18] Habib N, Centini G, Pizzoferrato AC, Bui C, Argay I, Bader G. Laparoscopic promontofixation: Where to stop the anterior dissection? *Medical Hypotheses*. 2019;**124**:60-63
- [19] McCullough M, Valceus J, Downes K, Hoyte L. The ureter as a landmark for robotic sacrocolpopexy. *Female Pelvic Medicine & Reconstructive Surgery*. 2012;**18**(3):162-164
- [20] Ferrando CA, Paraiso MFR. A prospective randomized trial comparing Restorelle Y mesh and flat mesh for laparoscopic and robotic-assisted laparoscopic Sacrocolpopexy. *Female Pelvic Medicine & Reconstructive Surgery*. 2019;**25**(2):83-87
- [21] Linder BJ, Anand M, Klingele CJ, Trabuco EC, Gebhart JB, Occhino JA. Outcomes of robotic Sacrocolpopexy using only absorbable suture for mesh fixation. *Female Pelvic Medicine & Reconstructive Surgery*. 2017;**23**(1):13-16
- [22] Tan-Kim J, Nager CW, Grimes CL, Lubber KM, Lukacz ES, Brown HW, et al. A randomized trial of vaginal mesh attachment techniques for minimally invasive sacrocolpopexy. *International Urogynecology Journal*. 2015;**26**(5):649-656
- [23] Borahay MA, Oge T, Walsh TM, Patel PR, Rodriguez AM, Kilic GS. Outcomes of robotic sacrocolpopexy using barbed delayed absorbable sutures. *Journal of Minimally Invasive Gynecology*. 2014;**21**(3):412-416
- [24] Abernethy M, Vasquez E, Kenton K, Brubaker L, Mueller E. Where do we place the sacrocolpopexy stitch? A magnetic resonance imaging investigation. *Female Pelvic Medicine & Reconstructive Surgery*. 2013;**19**(1):31-33
- [25] Guan X, Ma Y, Gisseman J, Kleithermes C, Liu J. Robotic single-site Sacrocolpopexy using barbed suture anchoring and peritoneal tunneling technique: Tips and tricks. *Journal of Minimally Invasive Gynecology*. 2017;**24**(1):12-13
- [26] Liu J, Bardawil E, Zurawin RK, Wu J, Fu H, Orejuela F, et al. Robotic single-site Sacrocolpopexy with retroperitoneal tunneling. *JLS: Journal of the Society of Laparoendoscopic Surgeons*. 2018;**22**(3):e2018.00009
- [27] Matanes E, Lauterbach R, Mustafa-Mikhail S, Amit A, Wiener Z, Lowenstein L. Single port robotic assisted Sacrocolpopexy: Our experience with the first 25 cases. *Female Pelvic Medicine & Reconstructive Surgery*. 2017;**23**(3):e14-ee8
- [28] Lowenstein L, Matanes E, Burke YZ. Surgical technique for robot-assisted Sacrocolpopexy performed via a single port. *Urology*. 2017;**103**:272