

# We are IntechOpen, the world's leading publisher of Open Access books Built by scientists, for scientists

4,800

Open access books available

122,000

International authors and editors

135M

Downloads

Our authors are among the

154

Countries delivered to

TOP 1%

most cited scientists

12.2%

Contributors from top 500 universities



WEB OF SCIENCE™

Selection of our books indexed in the Book Citation Index  
in Web of Science™ Core Collection (BKCI)

Interested in publishing with us?  
Contact [book.department@intechopen.com](mailto:book.department@intechopen.com)

Numbers displayed above are based on latest data collected.  
For more information visit [www.intechopen.com](http://www.intechopen.com)



# Congenital Aural Atresia: Hearing Rehabilitation by Bone-Anchored Hearing Implant (BAHI)

*Giampietro Ricci, Arianna Di Stadio, Valeria Gambacorta  
and Antonio Della Volpe*

## Abstract

Auris atresia (AA) is a congenital pathology characterized by aplasia or hypoplasia of the external ear with associated middle ear malformation. The AA has a different degree of severity, and the severe form of the disorder presents no identifiable ear canal (complete atresia) and absence or significative underdevelopment of the middle ear structures. Sometimes AA is associated with a malformation of the ear called “microtia.” The alterations of the external auditory canal and of the middle ear structures are responsible for the conductive hearing loss which affects the patients. The hearing restoration procedures may recreate a normal external and middle ear anatomy to favor the recovery of the hearing function, or the surgeon may simply restore the hearing capacity through bypassing the malformed structures by bone-anchored hearing implants (BAHIs). The restoring of normal anatomy is generally associated with episode of restenosis of the external ear canal due to bony regrowth. The formulation of a therapeutic strategy may be supported by using Jahrsdoerfer classification to identify the severity of malformation. In the chapter we discuss various bone anchoring prostheses currently used (Baha, Ponto, Alpha2 by Sophono, Bonebridge) and the results that can be obtained by the use of these implants.

**Keywords:** congenital aural atresia, hearing loss, hearing restoration, bone-anchored hearing implant, memory function

## 1. Introduction

Congenital aural atresia (CAA) is a congenital malformation of the ear that causes both esthetic and functional impairments. The malformation presents different severities of impairment; CAA may be the only malformation in the body or be associated with other malformation as observed in syndromic patients.

CAA is a failure in the ear development that happens in the first gestation<sup>’</sup> weeks; the failure may be complete by affecting the external and the middle ear or partial, as, for example, a stenotic external canal with normal middle ear structures.

In all cases, the hearing function is impaired, despite having different hearing threshold.

Our group showed that independently from the severity of the hearing impairment, children with hearing loss present a reduction of the memory function and scholar abilities [1], so the restoration of hearing function should be considered

the first goal in CAA followed, eventually, before the adolescent age by an esthetic reconstruction of the external ear [2]. In 1992 Jahrsdoerfer et al. [3] proposed a CT grading system for CAA that was shown to correlate with postoperative hearing outcomes, as a supporting method during the decisional process of treatment of CCA malformation; the suggestion of the author was to treat the high score of malformation with external canal bone reconstruction and eventually ossiculoplasty, while in the case of lower scores, the bone-anchored hearing implants (BAHIs) were the most appropriate treatment.

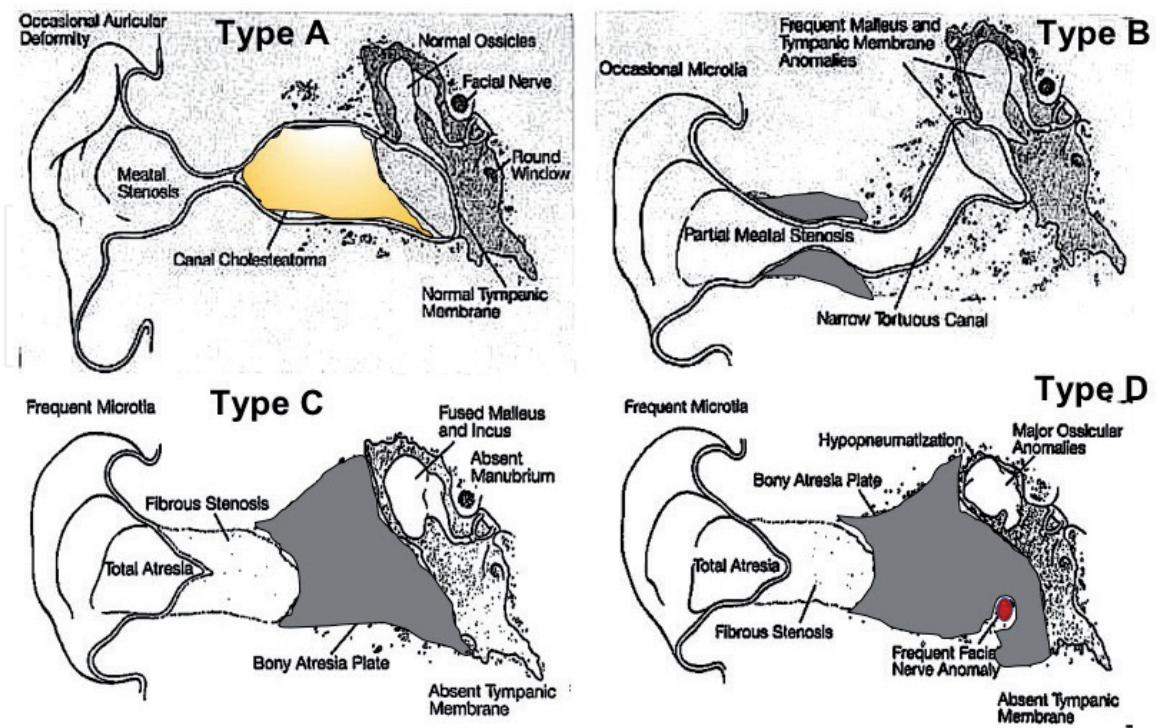
Other more recent scoring systems as the Lübeck score have been proposed; this system is based on strong analyses conducted on high-resolution CT scan. The proposed method used a 16-score grading for addressing to the best ear implant [4] that has the same efficacy as the Jahrsdoerfer et al. classification [3].

In this chapter we discuss the CCA management with BAHIs by illustrating the different implants available on the market and the implantation method and finally reporting the results that we obtained in more than 10 years of experience with these systems.

## 2. Congenital auris atresia (CCA)

Congenital aural atresia is an ear malformation that may have different severity and may affect the external ear only or the middle ear too. The ear malformation may be a single problem or be part of a syndromic picture. An altered development of the first and second branchial arches and the first branchial cleft may be responsible for the CCA [5].

Schuknecht [6] classified four degree of severity based on the combination of high-resolution computer tomography (CT) scan and surgical findings: (1) Type



**Figure 1.** The image shows the four types of CAA as described by Schuknecht. In Type A, the yellow indicates the presence of the cholesteatoma behind the meatal stenosis. The gray areas in Types B, C, and D represent the portion with bone atresia. The red dot in type D shows the aberrant exit of facial nerve.

A: narrowing of the fibrocartilaginous canal and presence of cholesteatoma distal to the stenotic area. (2) Type B: narrowing and tortuosity of fibrocartilaginous and bony part of the canal, commonly associated with abnormal tympanic membrane and malleus. (3) Type C: complete atresia with different combination of fibrous tissue and bone. Typically, malleus and incus are fused together, the manubrium and the tympanic membrane are missing, and the stapes is mobile. (4) Type D: totally atresia with decreased pneumatization of mastoid. More severe ossicular anomalies than type C and frequently the facial nerve being aberrant (**Figure 1**).

Other authors classified the CAA; one of the most famous is Weerda [7] that classified these malformations in three types (A, B, and C), while Altmann described a histopathological classification correlating the severity of CAA [8] by identifying three categories: mildly, moderately, and severely malformed types. Many authors have since modified this classification system, further subclassifying type II based on the surgical findings and functional outcome [9].

### **3. Embryology and etiopathogenesis of CAA**

The mandibular (I) and the hyoid (II) branchial arches contribute to the auricular development, and both may be involved in the etiopathogenesis of CAA. Auricular pinna starts to develop between the third to sixth weeks of embryonic life, when hillocks appear on the arches, and its formation is complete at the fourth month of gestation. The basis of tragus, the helical root, and the superior part of the helix comes from the anterior three hillocks, derived from the first arch. The posterior hillock that derives from second arch is responsible for the formation of the antihelix, antitragus, and lobule. The middle ear cavity derives from the first pharyngeal arch starting from 4 weeks of gestation. The pinna develops around the external meatus which becomes canalized at week 28 of embryologic life. At 8 weeks the middle ear cleft is formed, and the cavity is complete developed at 30 weeks. The first arch cartilage generates malleus and incus by 8 weeks of gestation that start to ossify at the 4 months of pregnancy. From the second arch, cartilage comes out the stapes except the medial lamina of the footplate which derives from the otic capsule [10]. At week 9, ectodermal cells proliferate, fill the meatus lumen, and form the “meatal plug” (MP); then on week 10, the MP extends in a disclike fashion by following a horizontal plane, and the internal part of MP starts to thin for generating the future tympanic membrane. At the same time, the plug in the proximal portion of the neck starts to be resorbed. At week 13 the MP is in contact with the primordial malleus, and this contact will contribute to the thinness of internal part of MP that will create the tympanic membrane at week 15. At week 16 the external ear canal is fully patent but still narrow and curved. At week 18 the meatus is fully extended and starts its opening that will be completed at 28 weeks [11].

Any type of adverse event that occurs during the 4 and 25 weeks of gestation and interrupts one of more of these developments may be responsible for one of the different types of CAA. The adverse event may be related to genetic aberrations, vascular accident (fetal hypoxia), teratogenic substances (aminoglycoside antibiotics, hydantoin, alcohol, nicotine, herbicides), maternal infection (rubella, *Cytomegalovirus*, measles, hepatitis, toxoplasmosis, lues), and maternal metabolic disease (deficiency of thyroid hormone or diabetes) [12].

CAA may be a single malformation or be associated with other malformations as in the case of oto-facial dysostosis (Treacher-Collins syndrome, Goldenhar syndrome), craniofacial dysostosis (Crouzon syndrome, Apert syndrome), oto-cervical dysostosis (Klippel-Feil syndrome, Wildervanck syndrome), oto-skeletal



dysostosis (Van der Hoeve-De Klein syndrome, Albers-Schonberg disease), and chromosomal syndromes (trisomy 13, 18, 21, and 18q syndrome) [2].

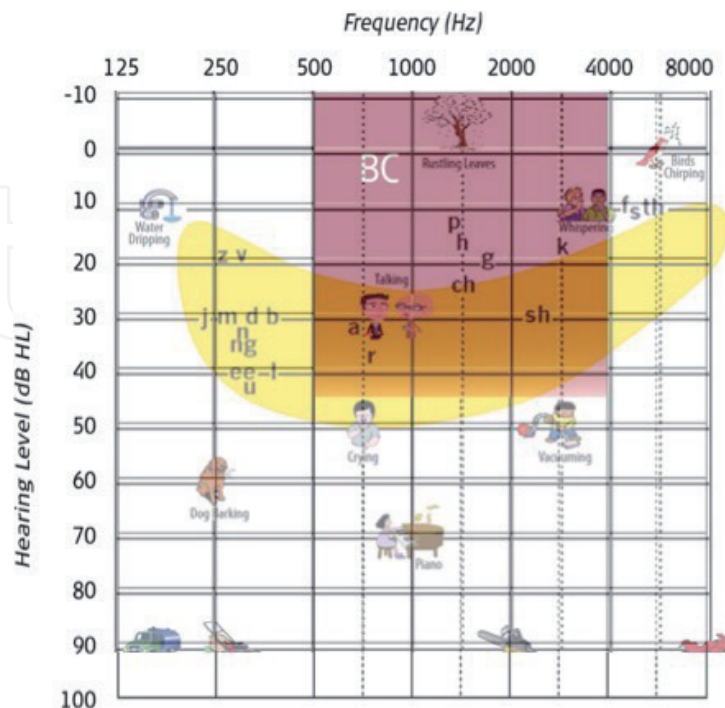
#### 4. Indications to use BAHI in patients with CAA

CAA is predominantly unilateral (ca. 70–90%) and the malformation mostly affects the right ear, perhaps because this side can suffer more frequently of hypoperfusion even rather than the left side in which the heart is located and that generally has a pressure 10 mmHg higher to the right side. The incidence of ear malformations is approximately 1 in 3800 newborns. Some children may present a bilateral CAA, when the malformation is not an isolated disease, but it is contextualized in a syndrome as, for example, CHARGE syndrome, in which children are affected by bilateral atresia up to 60% of cases [13].

Patients may be affected from different severity of external and middle ear malformation (**Figure 1**): due to the severity we can identify different forms of hearing loss. CAA typically results in conductive hearing loss (CHL) in 80–90% of the cases with the remaining patients demonstrating a sensorineural hearing loss (SNHL) component [10]. The CHL is typically in the moderate hearing loss range of 40–60 dB; this is the range in which BAHIs work better (**Figure 2**).

In the case of children suffering from unilateral CAA [14] and sensorineural hearing loss (10–20% of children with CAA), BAHI may be used for restoring the hearing function if the contralateral normal hearing function is preserved [15–17].

We use to utilize the Jahrsdoerfer et al. method during our decisional process for identifying the most appropriate surgery technique that has to be used. The authors proposed a CT grading system for CAA that was shown to correlate with postoperative hearing outcomes; based on the scores reached in the preliminary



**Figure 2.** The back image shows the ideal condition to use BAHI, while the supra-impressed yellow banana illustrates the distribution of vocal frequency. CHL that presents an auditory threshold within 45 dB may benefit from a BAHI because the implant guarantees a good recover of auditory functions in the range between 500 and 4000 Hz.

patient evaluation, the authors proposed different surgical options. In the case of high scores (better option), a canaloplasty with eventual ossiculoplasty may be a good option for the treatment of CAA, while, in the case of low scores, the authors' suggestion is to use a BAHI [3]. Specifically, the authors concluded that the patient with a score of 8–9 is a very good candidate (80% chance to reach postoperative PTA threshold of 30 dB or lower) for surgical reconstruction of the auditory canal and the middle ear, while a score of 5/6 or less disqualifies patients for surgery. Furthermore, they identified that syndromic patients rarely present a grade higher than 6/7 and, in general, are poor surgical candidates (**Table 1**).

Anyway even in the case of success (**Table 2**), a surgical reconstruction presents a several postsurgical complication as stenosis of the new external auditory canal (15–20%), recurrent otitis externa (10%), sensorineural hearing loss (5%) cholesteatoma (2–4%), and facial nerve injury (0.1%), and often a hearing aid is necessary to allow a good hearing function [15, 18–21].

Parameter	Points
Stapes present	2
Oval window open	1
Middle ear space	1
Facial nerve normal	1
Malleus/incus complex presence	1
Mastoid well pneumatized	1
Incus-stapes connection	1
Round window normal	1
Appearance external ear	1
Total available points	10

**Table 1.**  
*The Jahrsdoerfer grading system of candidacy for CAA repair.*

Authors and year	Number of patients	Mean PTA ≤ 30 dBHL
Lambert, 1988	16	12 (67%)
Bellucci, 1981	71	39 (55%)
Mattox and Fisch, 1986	11	5 (45%)
De la Cruz et al., 1985	56	41 (73%)
Schuknecht, 1989	50	15 (50%)
Jahrsdoerfer, 1992	126	61 (48%)
Murphy et al., 1997	19	4 (21%) (20 dB)
Teufert and De la Cruz, 2004	115	55 (48%)
Digoy and Cueva, 2007	54	27 (50%)
El-Hoshy, 2008	40	26 (65%)
Yellon et al., 2011	19	8 (45%)
Nadaraja et al., 2013	390	235 (60.3%)

**Table 2.**  
*The experiences of different authors on the surgical reconstruction of external ear canal are reported.*

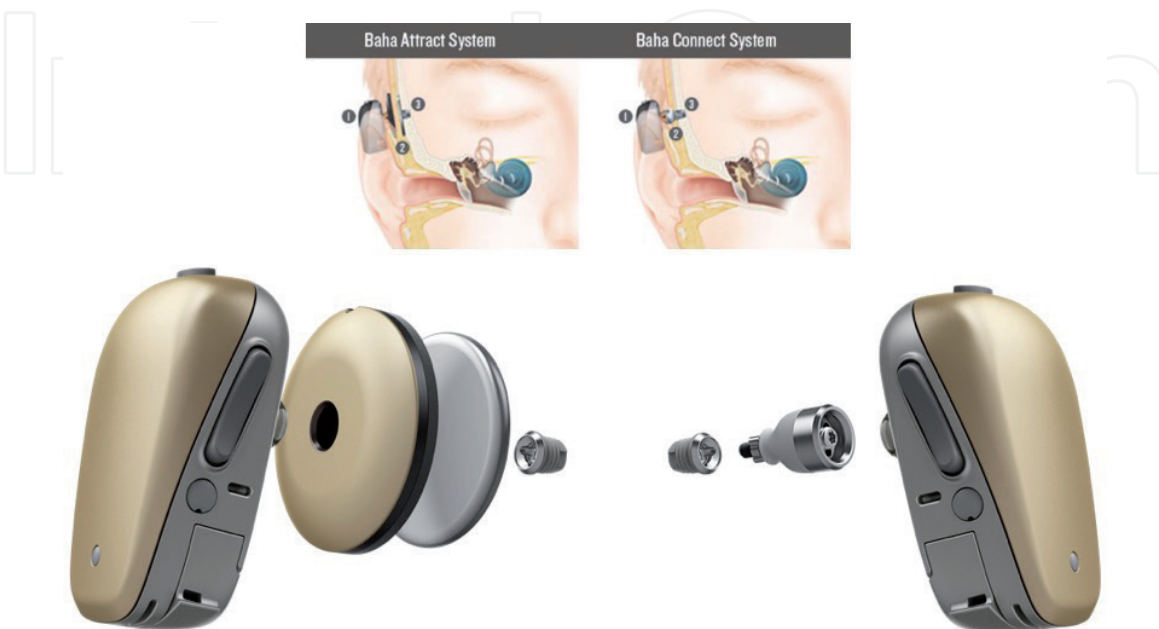
Based on our experience and according to the Jahrsdoerfer study, we can affirm that patients with CAA and a score of  $< 7$  rarely benefit from an external and middle ear reconstruction with good functional results. In such cases, the implantation of a BAHI is a viable option for obtaining a stable, satisfactory, and long-term result in terms of hearing function recovery [18]. In conclusion we think that BAHI could be quite always the best method for restoring hearing function in patients with CAA, even in the case of high score in the Jahrsdoerfer grading system.

## 5. Available product

The hearing restoration by bone stimulation did not obtain an immediate success; in fact in 1920 the first electronic implantable device was the preferred method, and bone stimulation prostheses were considered as the last alternative. Furthermore, after the Second World War, with the advent of transistor, the electronic prosthesis became smaller and more manageable, similar to the actual hearing aids. Anyway, in the recent decades, thanks to the new discoveries which better explained the physiologic stimulation of the inner by bone stimulation and to the improved technologies that miniaturize the systems and make the system implantable (BAHI **Figure 3**), the system is widely used for the treatment of hearing impairments [21, 22]. BAHI solved the old problems related to the external bone stimulation as the difficulties in maintaining constant position and correct pressure on the mastoid and, in addition, the reduced bone stimulation due to the skin impedance [23, 24].

In the light of multiple observations and experiments, it was concluded that the bone pathway is a type of natural sound conduction and that the sound characteristics are normal and quite similar to that conducted by air.

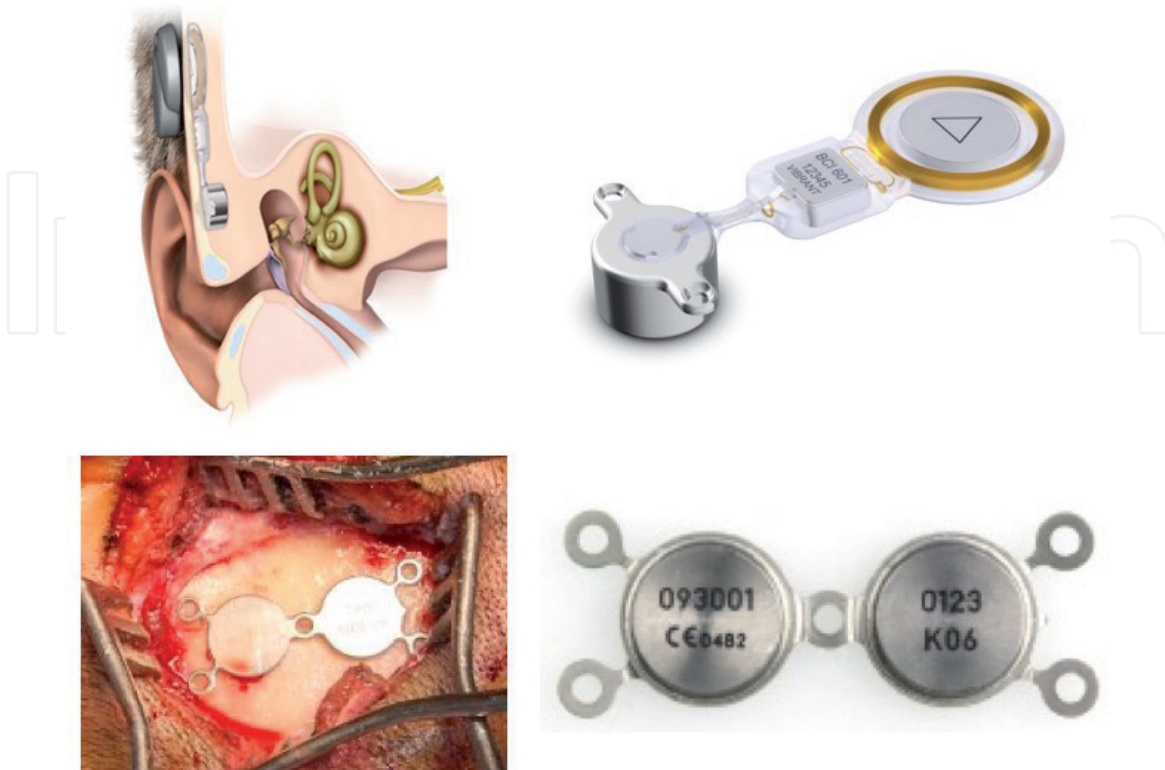
The BAHI solves the problems of the traditional retro-auricular bone stimulation as poor performance due to inadequate contact between the vibrator and the skin, pain or decubitus at the site of contact, and poor esthetic acceptance of arch prostheses by combining a pin implanted in the temporal bone with an external transducer; the vibration of the transducer on the bone induces a stimulation of the inner ear cells with consequently sound perception.



**Figure 3.**  
*On the left side, the transcutaneous BAHI, and on the right side, the percutaneous.*



**Figure 4.**  
*Percutaneous BAHI (PONTO) produced by Oticon Medical.*



**Figure 5**  
*On the top of the image, a semi-implantable transcutaneous device BONEBRIDGE (Medel) and on the bottom another model of transcutaneous BAHI ALPHA 2 by SOPHONO (Medtronic).*



The coupling between the pin and the transducer determines the type of BAHl: percutaneous or transcutaneous. Both methods of implant need a surgery.

The difference between the transcutaneous and the percutaneous system is the way in which the titanium screw is placed related to the skin plan; in the first one, the skin is surgically open, and the abutment is placed directly on the mastoid; then the surgical opening is closed by suturing the skin [25]. The percutaneous system instead consists of a titanium implant placed “through” the skin by perforating it [26].

All BAHl systems are composed of three main components:

1. An internal titanium fixture that is surgically anchored to the temporal bone behind the ear
2. An external abutment that is connected to the implant at the time of surgery
3. An external sound processor that is snapped on to the abutment

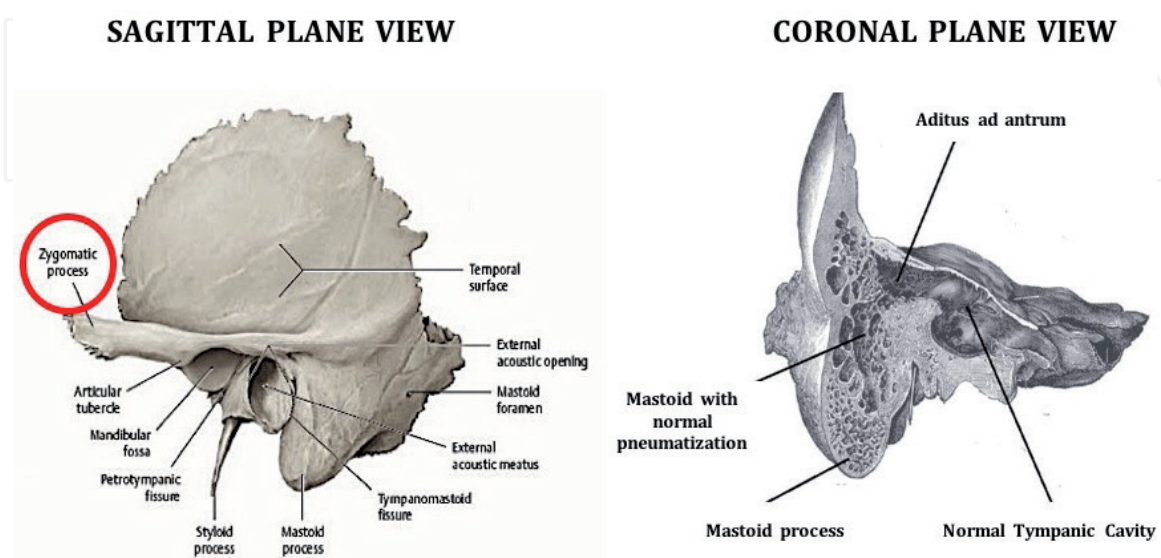
All systems currently available on the market present these characteristics: high amplification power, working independently in the presence/absence of the ear canal and middle ear, a direct bone transmission giving a clear sound, may be tested preoperatively, and all systems being quite similar in terms of comfort [27–29] (Figures 3–5).

## 6. Temporal bone anatomy and BAHl

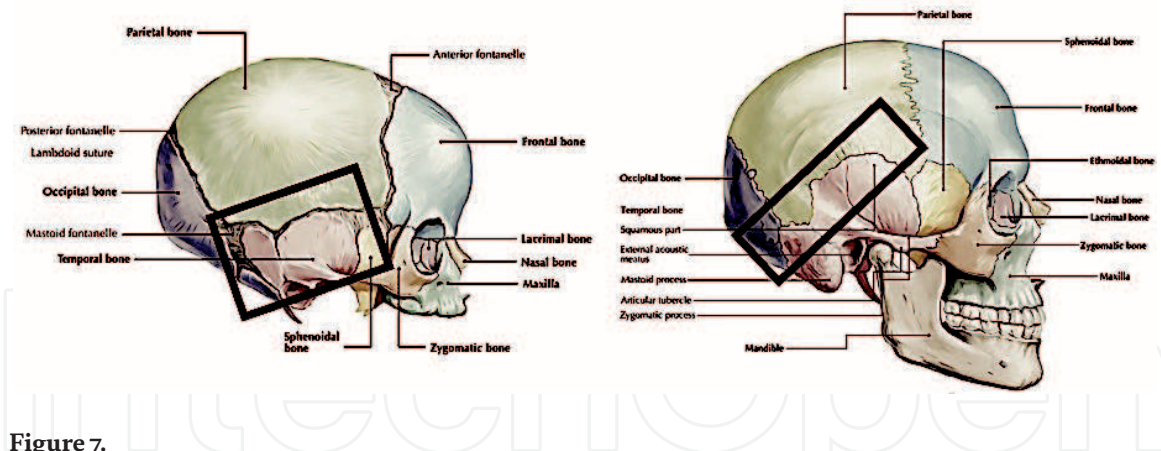
Surgeons have to keep in mind the normal anatomy of temporal bone because it is helpful for remembering the anatomic landmarks when severe malformations occurred in the patient that should be implanted.

When CAA is associated with microtia, the main anatomic landmarks are the zygomatic process (image 7 sagittal plane view); in fact this structure is generally quite preserved also in the case of craniofacial malformation.

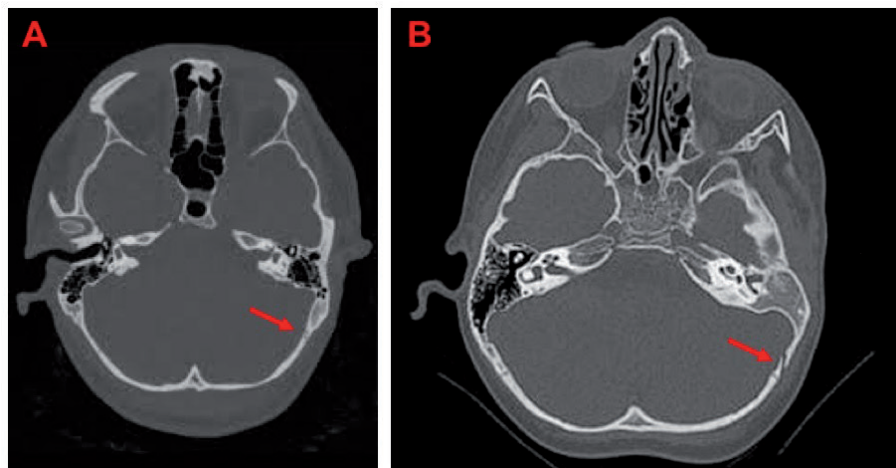
In the case of the absence of zygomatic process, the squamosal suture should be identified as alternative landmarks (Figure 6).



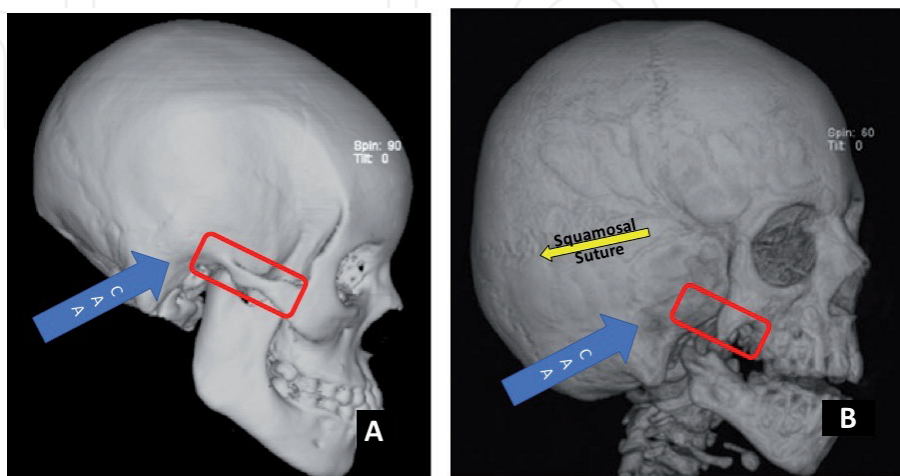
**Figure 6.** The normal anatomy of human temporal bone in sagittal and coronal views. The red circle indicates the zygomatic process, the only landmark that may be present in the case of CAA associated with craniofacial malformation (Figures 7–9).



**Figure 7.** The image shows the squamosal suture in a normal head. In the left side the cranium of a child before the closure of the suture; in the right the squamosal suture as appears in the adult head.



**Figure 8.** CT scan high-resolution images. (A) Type D CAA with preservation of the normal mastoid pneumatization. The red arrow indicates the squamosal suture. (B) Type D CAA with absence of mastoid pneumatization; the red arrow shows the clear presence of the squamosal suture that is still not closed.



**Figure 9.** (A) CAA in a non-syndromic patient with complete preservation of zygomatic arch anatomy (red rectangle). (B) CAA in a syndromic patient; the zygomatic arch is extremely malformed (red rectangle) and cannot be used as a surgical anatomic landmark. The squamosal suture is well identifiable (yellow arrow) and can be used as an alternative to zygomatic arch.

## 7. Surgical method of implant and timing

The FDA recommends to apply the device in children not younger than 5 years. Authors say that the ideal age for implanting a BAHl is between 2 and 4 years, because at this age the thickness of retromastoid bone (2.5–3 mm) allows to perform a totally safe surgery, without risk of damaging the dura. Additionally, regarding the age of implant, we have to consider that children need to possess a sufficient manual dexterity to maintain the device and a good psychological tendency to follow the suggestions of parents and caregivers. We usually correct hearing aids before 5 years by using an elastic band (Softband).

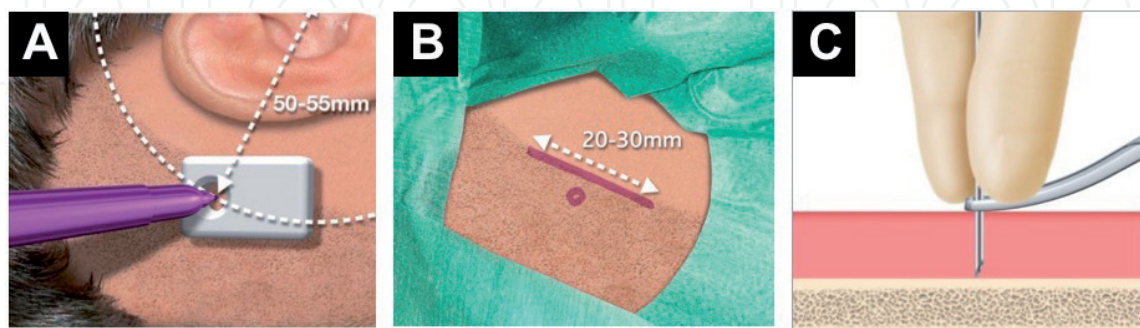
The Tjellström et al. technique, proposed in 1977, suggest the creation of a thin muscle-cutaneous flap. The main disadvantage is an altered vascularization that may lead to infection and wound healing problems, dysesthesia in the retro-auricular area and alopecia. For solving these problems, a less invasive technique by using a linear retro-auricular incision has been proposed and currently is the mostly used. The main benefit of this new technique is the good preservation of the vascularization in the surgical area that allows to avoid all the problems of muscle-cutaneous flap (infection, healing problems, dysesthesia, etc.). Another suggested low invasive technique is based on the removal of a very small piece of skin in the area in which the titanium implant should be placed. The skin removed has the same dimension of a biopsy. This technique also presents the advantages of the liner incision, due to the reduced trauma on tissue and vascular structures [30].

### 7.1 BAHA® (<https://www.cochlear.com/it/home>) and PONTO® (<https://www.oticonmedical.com/it>)

See **Figures 10** and **11**.

### 7.2 Alpha 2 ([www.sophono.com](http://www.sophono.com))

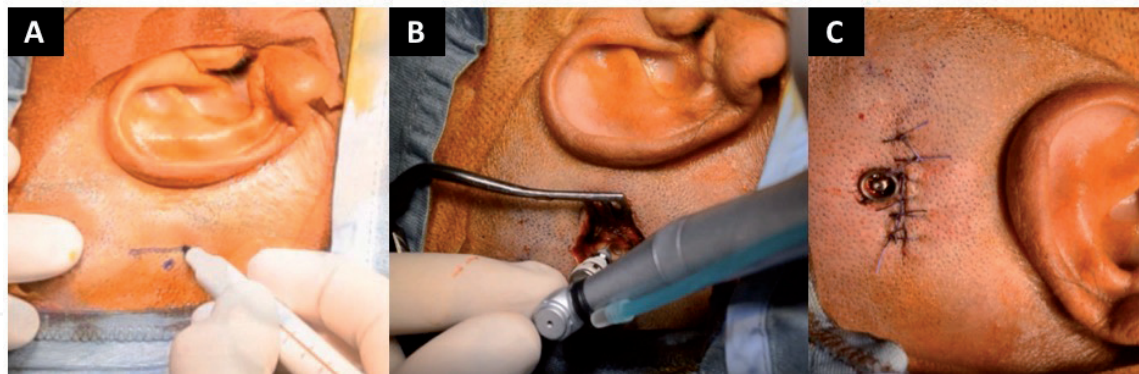
The Alpha 2 by Sophono is another bone-anchored prosthesis without percutaneous screw and consists of a processor that is coupled to the skin transcutaneously with a titanium component implanted subcutaneously, containing two magnets.



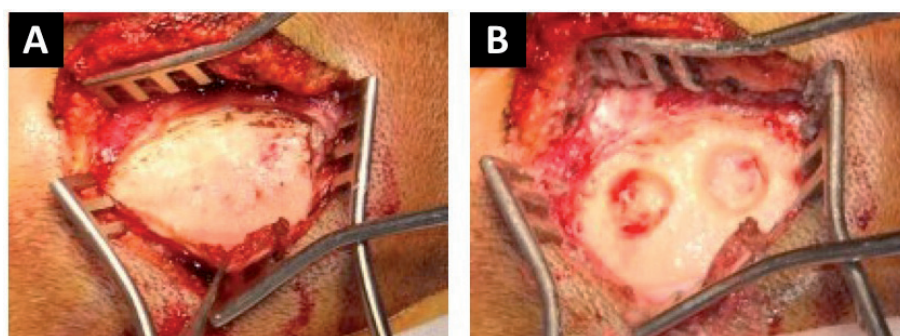
**Figure 10.**

(A) BAHl model is placed on the skin exactly in the area where it will be placed. After considering the distance from the superior margin of the external auditory canal, a point is designed on the skin as landmark. A meter is used to measure the distance from the external auditory canal where the BAHl that is approximately 50–55 mm is placed. This distance is necessary to avoid the prosthesis from touching the pinna. (B) A line parallel to the point previously identified is then designed in the skin of the retro-auricular area. (C) After using the BAHl model for designing the location of the implant, a blue mytilene solution is injected for delineating on the mastoid bone the lodgment of the implant.

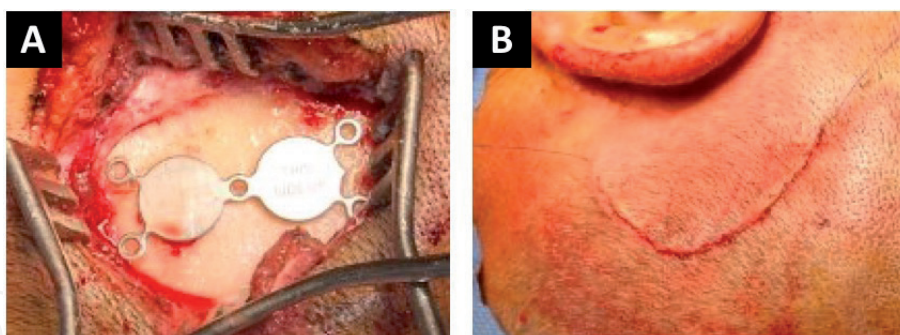




**Figure 11.**  
(A) By using a dermographic pen, the incision line is designed on the skin. (B) After surgical incision the lodgment for the bone anchorage is performed by using a drill. (C) The anchorage after the skin closure with head in vertical position. Final result. Live surgery: <https://www.youtube.com/watch?v=Pz2qZxzkV1I>.



**Figure 12.**  
(A) Musculocutaneous flap with exposure of mastoid (B) using a cutting burr creation of lodgment area.



**Figure 13.**  
(A) BAHI is placed and fixed with titanium screw. (B) Continuous cutaneous suture to guarantee sterility. Live surgery traditional method: <https://www.youtube.com/watch?v=AagsHvgsmDs>. Live surgery simplified method: [https://www.youtube.com/watch?v=gJM1jt8W\\_rI](https://www.youtube.com/watch?v=gJM1jt8W_rI).

The magnetic attraction allows to hold the processor in place and to transmit acoustic energy [31]. The limits of this kind of device are represented by energy loss through the skin layer and possible discomfort and complications due to soft tissue pressure [21] (Figures 12 and 13).

### 7.3 Bonebridge (<https://www.medel.com/hearing-solutions/bonebridge>)

The Bonebridge by MED-EL is a semi-implantable bone conduction auditory system comprising a processor that is coupled transcutaneously to a titanium component and silicone implanted subcutaneously. The transducer, lodged in the

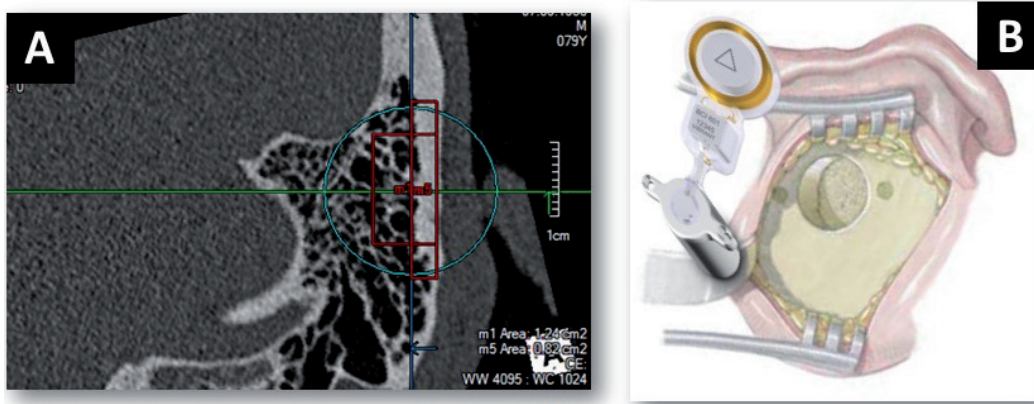


mastoid bone, transmits mechanical vibrations directly to the inner ear jumping middle and outer ear. The conduction system is light (~10 g), and it has an area of ~8.7 mm (height) × 15.8 mm (diameter). Two titanium screws—responsible for the vibrations transduced to the system—are located to a distance of around 24 mm between them.

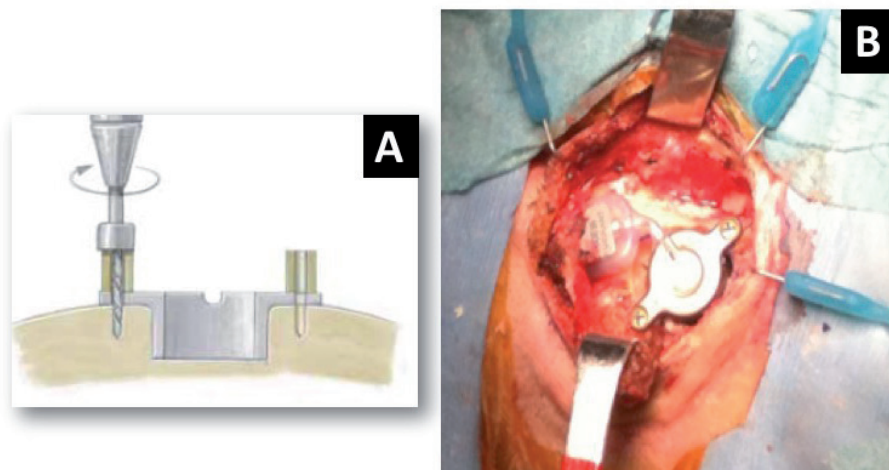
Bonebridge is the unique BAHl with active mechanism; the information analyzed by the audio-processor are sent to the antenna and transmitted through the skin to the system. It converts the received signals into mechanical vibrations, which are transmitted to the inner ear by bone conduction. The transducer is surgically positioned at the seno-dural angle. However, due to its slightly bulky internal implant, the most optimal location for placing BB implant should be carefully selected preoperatively using 3D reconstruction software [32].

As compared to percutaneous BCI, Bonebridge's transcutaneous technology enables the avoidance of several complications including skin reaction, growth of skin over the abutment, implant extrusion, and wound infection.

BB presents the same risks of the other BAHls (skin infection and skin necrosis), and currently nobody described severe complications by using this implant. We suggest to use a double flap for minimizing the skin trauma and improving the outcomes (Figures 14 and 15).



**Figure 14.** (A) Measurement of temporal bone thickness before surgery and (B) lodgment for BAHl created posteriorly to the pinna.



**Figure 15.** (A) After lodged BAHl is fixed to the temporal bone with a screw and (B) way in which the implant appears before the closure of the skin. Live surgery: <https://www.youtube.com/watch?v=Wlh6YxEnJl8>.

## 8. Our results

We widely use BAHIs both in the case of aural atresia (singular or bilateral form) [1, 15, 21] and as treatment of single side deafness [1], and our results are supported by other authors' observations [16–19, 29, 30].

We observed that BAHI not only improved the hearing abilities of children in noise condition but also their dictation capacity during the school activity [1, 15, 21].

We compared children wearing BAHI immediately after the implant and then 3 months later they were implanted, and we noticed that their abilities in speech perception increased time by time by reaching the same scores observed in healthy children after 3 months [1]. In addition, we analyzed the short and working memory abilities in children with BAHI, before and after implantation, and we identified that both these memory functions improved by restoring the hearing with BAHIs. The memory abilities, as the speech perception done, increased time by time by overlapping the score obtained by healthy children in the same age range [1]. Finally, we observed that children after being implanted with BAHI improved their school scores and increased their relationship with friend and environment [21].

Reported complications are slight skin problems as localized irritation and hypertrophic scare around the titanium implant. The skin inflammation may be explained as an immune answer to an external body (the screw). In the literature the rates go from 5 to 7.5% for skin regrowth and from 1.3–10% for extrusion of the abutment [15].

## 9. Conclusions

We think that BAHIs are a very good solution for restoring hearing abilities. Although we have a wide experience on children, due to the excellent results obtained on these patients, in terms of speech discrimination but much more for the impressive benefit obtained in memory function, we suggest BAHIs as treatment of hearing loss in adults' population too.

As we have shown in our chapter, BAHIs are simple to implant, with very low side effects, and their surgery is poor and time-consuming. We speculate that due to the new theories on BAHIs' stimulation of the inner ear [33–37], these implants could be a valid alternative to the traditional hearing aids in slight-mild form of asymmetric hearing loss; we suggest BAHIs not only in the case of conductive hearing loss (CHL) but also in the sensorineural form (SNHL).

## Conflict of interest

The authors declare no conflict of interest.

IntechOpen

### **Author details**


Giampietro Ricci<sup>1</sup>, Arianna Di Stadio<sup>2\*</sup>, Valeria Gambacorta<sup>1</sup>  
and Antonio Della Volpe<sup>2</sup>

1 Otolaryngology Department, University of Perugia, Perugia, Italy

2 Otolaryngology Department, Santobono-Posilipon Children Hospital, Cochlear Implant Unit, Naples, Italy

\*Address all correspondence to: [arianna.distadio@unipg.it](mailto:arianna.distadio@unipg.it)

### **IntechOpen**

© 2019 The Author(s). Licensee IntechOpen. This chapter is distributed under the terms of the Creative Commons Attribution License (<http://creativecommons.org/licenses/by/3.0>), which permits unrestricted use, distribution, and reproduction in any medium, provided the original work is properly cited. 

## References

- [1] Di Stadio A, Dipietro L, Toffano R, Burgio F, De Lucia A, Ippolito V, et al. Working memory function in children with single side deafness using a bone-anchored hearing implant: A case-control study. *Audiology & Neuro-Otology*. 2018;**23**(4):238-244. DOI: 10.1159/000493722
- [2] Elder LM, Zur KB, editors. *Congenital Malformation of Head and Neck*. New-York: Springer; 2014. pp. 23-66
- [3] Jahrsdoerfer RA, Yeakley JW, Aguilar EA, et al. Grading system for the selection of patients with congenital aural atresia. *The American Journal of Otology*. 1992;**13**(1):6-12
- [4] Frenzel H, Sprinzl G, Widmann G, Petersen D, Wollenberg B, Mohr C. Grading system for the selection of patients with congenital aural atresia for active middle ear implants. *Neuroradiology*. 2013;**55**:895-911
- [5] Abdel-Aziz M. Congenital aural atresia. *The Journal of Craniofacial Surgery*. 2013;**24**(4):e418-e422. DOI: 10.1097/SCS.0b013e3182942d11
- [6] Schuknecht HF. Congenital aural atresia. *The Laryngoscope*. 1989;**99**(9):908-917
- [7] Weerda H. *Chirurgie der Ohrmuschel: Verletzungen, defekte und anomalien*. Stuttgart: Thieme; 2004. pp. 105-226
- [8] Altmann F. Congenital atresia of the ear in man and animals. *The Annals of Otology, Rhinology, and Laryngology*. 1955;**64**(3):824-858
- [9] Declau F, Offeciers F, Van de Heyning P. Classification of the non-syndromal type of meatalatresia. In: Devranoglu I, editor. *Proceedings of the XVth World Congress of Otorhinolaryngology Head and Neck Surgery: Panel Discussions*. Istanbul, Turkey. 1999. pp. 135-137
- [10] Beahm EK, Walton RL. Auricular reconstruction for microtia: Part I. anatomy, embryology, and clinical evaluation. *Plastic and Reconstructive Surgery*. 2002;**109**(7):2473-2482
- [11] Stilianos E. Kountakis *Encyclopedia of Otolaryngology, Head and Neck Surgery* y. Switzerland: Edition Springer Link; 2013
- [12] Kelley PE, Scholes MA. Microtia and congenital aural atresia. *Otolaryngologic Clinics of North America*. 2007;**40**(1):61-80
- [13] Bartel-Friedrich S, Wulke C. Classification and diagnosis of ear malformations. *GMS Current Topics in Otorhinolaryngology, Head and Neck Surgery*. 2007;**6**:Doc05
- [14] Zhang L, Gao N, Yin Y, et al. Bone conduction hearing in congenital aural atresia. *European Archives of Oto-Rhino-Laryngology*. 2016;**273**:1697-1703
- [15] Ricci G, Della Volpe A, Faralli M, Longari F, Gullà M, Mansi N, et al. Results and complications of the Baha system (bone-anchored hearing aid). *European Archives of Oto-Rhino-Laryngology*. 2010;**267**(10):1539-1545. DOI: 10.1007/s00405-010-1293-0
- [16] Sprinzl G, Lenarz T, Ernst A, et al. First European multicenter results with a new transcutaneous bone conduction hearing implant system: Short-term safety and efficacy. *Otology & Neurotology*. 2013;**34**:1076-1083
- [17] Bianchin G, Bonali M, Russo M, Tribi L. Active bone conduction system: Outcomes with the Bonebridge



- transcutaneous device. *ORL: Journal for Otorhinolaryngology and Its Related Specialties*. 2015;**77**:17-26
- [18] Bouhabel S, Arcand P, Saliba I. Congenital aural atresia: Bone-anchored hearing aid vs. external auditory canal reconstruction. *International Journal of Pediatric Otorhinolaryngology*. 2012;**76**(2):272-277. DOI: 10.1016/j.ijporl.2011.11.020
- [19] Lo JF, Tsang WS, Yu JY, Ho OY, Ku PK, Tong MC. Contemporary hearing rehabilitation options in patients with aural atresia. *BioMed Research International*. 2014;**2014**:761579
- [20] Yu JK, Wong LL, Tsang WS, Tong MC. A tutorial on implantable hearing amplification options for adults with unilateral microtia and atresia. *BioMed Research International*. 2014;**2014**:703256
- [21] Ricci G, Della Volpe A, Faralli M, Longari F, Lancione C, Varricchio AM, et al. Bone-anchored hearing aids (Baha) in congenital aural atresia: Personal experience. *International Journal of Pediatric Otorhinolaryngology*. 2011;**75**(3):342-346. DOI: 10.1016/j.ijporl.2010.11.027
- [22] Reinfeldt S, Hakansson B, Taghavi H, Eeg-Olofsson M. Bone conduction hearing sensitivity in normal-hearing subjects: Transcutaneous stimulation at BAHA vs BCI position. *International Journal of Audiology*. 2014;**53**:360-369
- [23] Gavilan J, Adunka O, Agrawal S, et al. Quality standards for bone conduction implants. *Acta Oto-Laryngologica*. 2015;**135**(12):1277-1285
- [24] Bento RF, Kiesewetter A, Ikari LS, Brito R. Bone-anchored hearing aid (BAHA): Indications, functional results, and comparison with reconstructive surgery of the ear. *International Archives of Otorhinolaryngology*. 2012;**16**(3):400-405. DOI: 10.7162/S1809-97772012000300017
- [25] Håkansson B, Eeg-Olofsson M, Reinfeldt S, Stenfelt S, Granström G. Percutaneous versus transcutaneous bone conduction implant system: A feasibility study on a cadaver head. *Otology & Neurotology*. 2008;**29**(8):1132-1139. DOI: 10.1097/MAO.0b013e31816fdc90
- [26] Fuchsmann C, Tringali S, Disant F, et al. Hearing rehabilitation in congenital aural atresia using the bone-anchored hearing aid: Audiological and satisfaction results. *Acta Oto-Laryngologica*. 2010;**130**(12):1343-1351
- [27] Pross S, Layton A, Tong K, Lustig L. Cost of placement and complications associated with osseointegrated bone conduction hearing prostheses: A retrospective analysis of Medicare billing data. *Otology & Neurotology*. 2014;**35**:476-481
- [28] Monini S, Bianchi A, Talamonti R, Atturo F, Filippi C, Barbara M. Patient satisfaction after auditory implant surgery: Ten-year experience from a single implanting unit center. *Acta Oto-Laryngologica*. 2016;**5**:1-9
- [29] DI Giustino F, Vannucchi P, Pecci R, Mengucci A, Santimone R, Giannoni B. Bone-anchored hearing implant surgery: Our experience with linear incision and punch techniques. *Acta Otorhinolaryngologica Italica*. 2018;**38**(3):257-263. DOI: 10.14639/0392-100X-1694.
- [30] Siegert R, Kanderske J. A new semi-implantable transcutaneous bone conduction device: Clinical, surgical, and audiologic outcomes in patients with congenital ear canal atresia. *Otology & Neurotology*. 2013;**34**:927-934

[31] Zanetti D, Di Bernardino D. A bone conduction implantable device as a functional treatment option in unilateral microtia with bilateral stapes ankylosis: A report of two cases. *American Journal of Case Reports*. 2018;**19**:82-89. DOI: 10.12659/AJCR.904907

[32] Stenfelt S. Inner ear contribution to bone conduction hearing in the human. *Hearing Research*. 2015;**329**:41-51. DOI: 10.1016/j.heares.2014.12.003

[33] Sohmer H, Freeman S, Geal-Dor M, Adelman C, Savion I. Bone conduction experiments in humans—A fluid pathway from bone to ear. *Hearing Research*. 2000;**146**(1-2):81-88

[34] Brinker T, Stopa E, Morrison J, Klinge P. A new look at cerebrospinal fluid circulation. *Fluids Barriers CNS*. 2014;**11**:10. DOI: 10.1186/2045-8118-11-10. eCollection 2014

[35] Eeg-Olofsson M, Stenfelt S, Granström G. Implications for contralateral bone conducted transmission as measured by cochlear vibrations. *Otology & Neurotology*. 2011;**32**(2):192-198. DOI: 10.1097/MAO.0b013e3182009f16

[36] Di Stadio A. Which factors to induce hearing loss in professional musicians? Extensive literature review and histopathology findings can answer it. *Hearing, Balance and Communication (IHBC)*. 2017;**15**(2):63-71

[37] Nadaraja GS, Gurgel RK, Chang KW. Hearing outcomes of atresia surgery versus osseointegrated bone conduction device in patients with congenital aural atresia: A systematic review. *Otology & Neurotology*. 2013;**34**(8):1394-1399