

We are IntechOpen, the world's leading publisher of Open Access books Built by scientists, for scientists

4,800

Open access books available

122,000

International authors and editors

135M

Downloads

Our authors are among the

154

Countries delivered to

TOP 1%

most cited scientists

12.2%

Contributors from top 500 universities



WEB OF SCIENCE™

Selection of our books indexed in the Book Citation Index
in Web of Science™ Core Collection (BKCI)

Interested in publishing with us?
Contact book.department@intechopen.com

Numbers displayed above are based on latest data collected.
For more information visit www.intechopen.com



Concurrent Rhinoplasty and Endoscopic Sinus Surgery

Balwant Singh Gendeh

Abstract

Combining rhinoplasty and endoscopic sinus surgery (ESS) was first reported in 1991 by Sheman and Matarasso. Since then, many authors have documented a large series showing the overall efficacy of combining the two procedures. The focus of this manuscript is to document the author's recent experience with combining rhinoplasty and endoscopic sinus surgery and highlight the changes that have occurred during the author's 2-years experience. A retrospective data review was performed on 53 (31 females and 22 men, age range 16–55 years) patients who underwent combined rhinoplasty and ESS between January 2016 and December 2018 at Pantai Hospital Kuala Lumpur by the same surgeon. The mean age was 31.8 years. All patients had severe nasal obstruction with chronic rhinosinusitis and were followed up for a minimum of 6 months post-surgery and underwent ENT workup, which included history, office rigid endoscopy, CT scans of paranasal sinuses and preoperative photography. Initially, the ESS was performed followed by the open rhinoplasty with or without osteotomy. The ESS consisted of middle turbinate reduction [15/53 (28.3%)], maxillary antrostomy [36/53 (67.9%)], ethmoidectomy [38/53 (71.6%)], frontal sinusotomy [7/53 (13.2%)], and sphenoidotomy [9/53 (16.9%)]. Most of the sinus symptoms resolved postoperatively with 47 (88.6%) of 53 patients describing their improvement as significant. Fifty (94.3%) of 53 patients stated that they would recommend the concurrent procedure. The benefits of these advances are illustrated by a review of the literature with good results (functional and cosmetic) and minimal complications.

Keywords: rhinoplasty, open, concurrent, endoscopic sinus surgery, one team approach

1. Introduction

There is an increasing demand for facial plastic surgery with more awareness of the procedure and its outcome. Many patients who seek surgery for their nasal aesthetics also have complaints of nasal obstruction and snoring [1, 2]. Severe gross septal deviations present big surgical challenges for the operating surgeon. The role of functional rhinoplasty in the management of internal nasal valve has been discussed by numerous authors (**Figure 1**).

A complete evaluation of these groups of patients with nasal endoscopy and CT scan of paranasal sinuses will often reveal concurrent chronic rhinosinusitis (CRS).

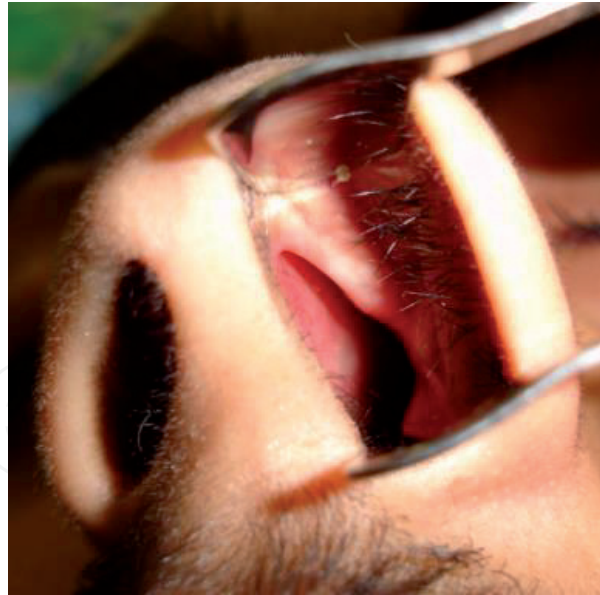

Figure 1.
A close-up view showing the anatomical relationship of the left internal nasal valve to the septum anteromedially and the inferior turbinate laterally.

Procedures of endoscopic sinus surgery (ESS), septoplasty (SP), and rhinoplasty (RP) were initially meant for functional improvement to which today an aesthetic aim is added. The functional aim of rhinoplasty is meant for recovery of normal sinonasal physiology and ventilatory function.

CRS is an inflammation of the nose and paranasal sinuses manifesting with two or more significant symptoms for 12 weeks with endoscopic and/or CT scan signs of disease. The symptoms include nasal obstruction, thick nasal discharge, and/or facial pain/pressure and/or reduction or loss of sense of smell [3]. Diagnosis of CRS is primarily based on symptoms that are confirmed by nasal endoscopy and CT scans in coronal and axial views (**Figures 2 and 3**).

In functional rhinoplasty, the role of the spreader graft [4], columellar extension graft [5], shield graft [6, 7], onlay conchal graft [8], nasal valve suture suspension [9], and flaring sutures [10] has been advocated by numerous authors. Endoscopic sinus surgery (ESS) has also been accepted as a safe and efficient modality for the treatment of CRS. The combination of both these procedures would offer great benefit to the indicated patient group.

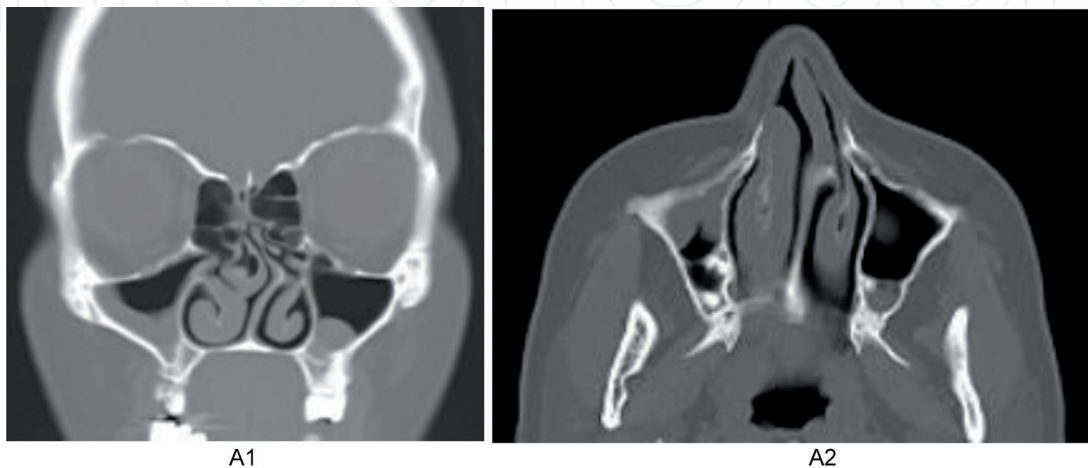


Figure 2.
Coronal (A1) and axial (A2) CT scan serial cuts of paranasal sinuses showing a markedly deviated nasal septum with pneumatized diseased right middle turbinate and evidence of sinusitis.

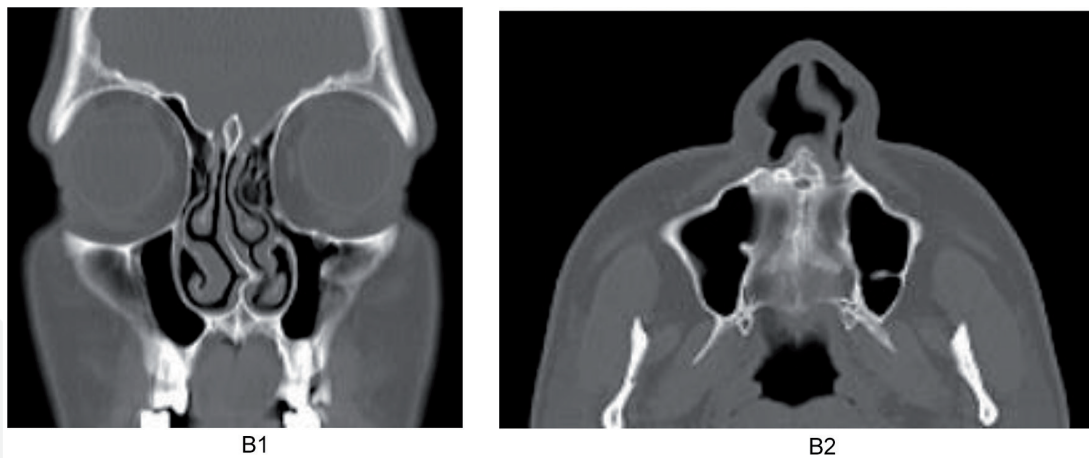


Figure 3.
Coronal (B1) and axial (B2) CT scan serial cuts of paranasal sinuses showing a grossly deviated nasal septum post-trauma with evidence of paranasal sinus mucosal thickening.

Concurrent ESS, SP, and RP are affordable, reliable, and safe procedures when performed as a single surgical procedure to reduce operative time, general anesthetic, and recovery period [11]. The additional RP leads to an increase in postoperative complications but when analyzed separately is considered minor in the literature [12, 13]. Thus, the result of surgery and the patient's quality of life are not exceedingly compromised and therefore considered acceptable. Traditional surgeons have been concerned of combining rhinoplasty and ESS to avoid the possibility of increased postoperative complications. Recent publications have reported initial success with this combined technique [14].

Therefore, a larger sample study like this can better define how RP affects outcomes of concurrent ESS and SP.

We present a novel one surgeon combined endoscopic sinus surgery and rhinoplasty technique to evaluate patient satisfaction, efficacy, safety, and clinical outcomes of them undergoing concurrent surgery.

2. Methods and materials

2.1 Patients

A retrospective clinical chart review was performed on all of the author's patients who had nasal surgery from January 2016 through December 2018 at the ENT unit of Pantai Hospital Kuala Lumpur (PHKL). All patients had severe nasal obstruction with chronic rhinosinusitis and were followed up for a minimum of 6 months post-surgery. The data revealed that 53 patients out of the 116 patients (45.6%) underwent concurrent open rhinoplasty and ESS by the same surgeon at PHKL. Patients who underwent rhinoplasty and ESS at different sittings (54.4%) were excluded from the study because the SNOT 22 subjective scoring system which was used only for the evaluation of patient symptoms in the concurrent group before and after surgery was sufficient, and therefore the need to compare with patients who underwent rhinoplasty and ESS at different sittings was not necessary. A history of nasal trauma and snoring was documented.

Patients with primary nasal dysfunction and sinus complaints were seen by the same surgeon. All the patients underwent ENT workup which included history, head and neck examination, nasal endoscopy, and CT scans of paranasal sinuses

and were treated with oral antibiotics and topical nasal steroids prior to the CT scan and a full facial analysis including standardized photography.

2.2 Evaluation

The main complaints of the patients prior to surgery were chronic nasal obstruction, postnasal drip, headaches with occasional voice changes, and snoring. External nasal examination was performed to detect a twisted/crooked/saddled nose.

Nasal endoscopy revealed that all these patients had significant anterior septal deviation involving the internal nasal valve, in addition to posterior septal deviation. Nasal endoscopic examination was performed to detect the grading of septal deviations, namely, I, II, III, IV, and V (**Figure 4**), and diseased mucosal or polypoidal tissue (grade 1, 2, 3) involving the paranasal sinuses. If there was evidence of mucopurulent discharge from the paranasal sinuses on nasal endoscopy on admission, the patients were commenced on systemic antibiotics prior to surgery.

2.3 Surgical technique

All the cases were performed as an inpatient procedure by a one surgeon and two procedure approach under general anesthesia at Pantai Hospital Kuala Lumpur. At the time of induction, all patients received IV antibiotics (ceftriaxone 1 gm) and steroids (dexamethasone 8 mg). The CT scans of the paranasal sinuses were reviewed again in OR prior to performing the surgery. A throat pack was inserted, and the nasal cavity was packed with soaked spacers for vasoconstriction. Infiltration was performed at the nasal dorsum, alar rim, septum, and greater palatine fossa transversally with levobupivacaine (20 cc), adrenaline (0.2 mg), and aqua (1.8 cc). Surgery was initiated with ESS procedure followed by open rhinoplasty approach, but in gross septal deviations, the septoplasty was performed prior to the ESS.

For the open rhinoplasty approach, an inverted transcolumellar V-shaped incision was made, and the SMAS elevated all the way to the dorsum of the nose (**Figure 5**). The domes are divided in the midline, and the upper lateral cartilages released laterally, creating excellent exposure of the septum. Bilateral submucoperichondrial flaps are elevated, exposing the entire cartilaginous and anterior bony septum. The cartilaginous and bony septum is then resected by paramedian

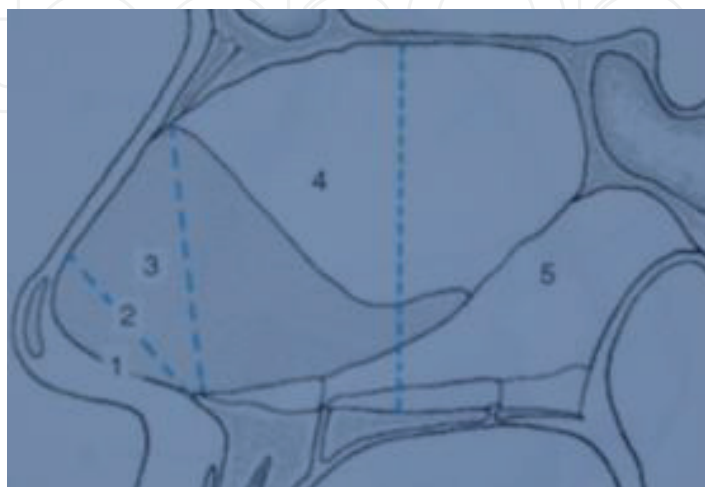

Figure 4.

The five areas of the internal nose most commonly involved in nasal septal deviations. Open approach rhinoplasty is indicated in anterior deviations of nasal septum involving areas I, II, and III along with significant internal nasal valve involvement, whereas closed approach is indicated for posterior septal deviations restricted to areas IV and V only.

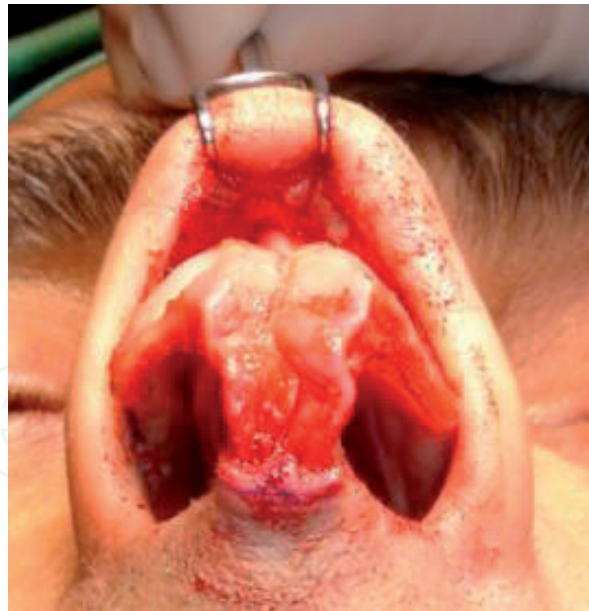

Figure 5.
Close-up view of open rhinoplasty via a transcolumellar incision and elevation of SMAS all the way to the nasal dorsum.

osteotomy, separating cartilaginous septum from maxillary crest and fracturing bony septum as posterior as possible leaving behind the cribriform plate and sphenoid rostrum. Extracorporeal approach was performed on all patients with gross high septal deviation, which requires complete removal of the entire cartilaginous septum, which is then straightened and returned to the nose. In revision rhinoplasty cases where adequate quadrangular cartilage and septal bone grafts were not available, conchal cartilage graft was harvested. Bilateral spreader grafts are then placed on the dorsal part of the septum. K-wire drill was used to drill multiple holes on the septal bone graft for use as spreader/ columella strut/columella extension graft. Straight 4/0 Monosyn mattress sutures were used to secure the spreader graft. Then lateral osteotomies are performed by external subcutaneous method if required. Nasal spine if deviated more than 30° is gauged out or drilled. Neo-septum with spreader graft is inserted in the nose. Areas of fixation are the caudal end of the nasal bones, upper lateral cartilage, and maxillary crest. A hole is drilled through the nasal bones and the nasal spine and suturing the neo-septum with Monosyn 4/0 sutures. Other required steps like columellar strut, rim grafts, and tip grafts are performed. Soft silicon splints are placed along either side of septum and sutured in place with through-and-through 3/0 Monosyn sutures. Curve Monosyn 4/0 and 5/0 were used for tip plasty (transcrural, intercrural, shield graft), dorsal augmentation, caudal augmentation, septum augmentation, and alar rim suturing. Ethicon 6/0 sutures were used for the skin.

For the ESS, the mucosa on the lateral wall of the nose and the anterior face of the sphenoid was infiltrated and the diseased sinuses addressed by performing ethmoidectomy, middle meatal antrostomy, sphenoidotomy or frontal sinusotomy. Prior to performing middle meatal antrostomy, an uncinectomy was performed using thru-cut instruments along with a microdebrider.

The nasal and sinus cavities were packed with Nasapore. Steri-Strip was applied externally on the nasal dorsum along with Denver splints which were removed between 7 and 10 days postoperatively. Nasal cavity suction was performed on the third postoperative day along with the removal of the nasal septal splints and patient sent home the same day. The ESS was performed using a technique adapted

from Stammberger [12] and Kennedy [13]. The ESS instruments included high-definition Spice monitor, 4 mm endoscopes (0, 30 and 70°), and powered instruments (debrider by Medtronic). IGS was used in revision sinus surgery cases. All patients received postoperative antibiotics and nasal rinse. The one surgeon team performed the postoperative endoscopic debridement and nasal function and documented aesthetic alterations with standardized postoperative photography.

2.4 Data collection

The medical charts of included patients were retrieved for analysis and demographic data obtained (**Table 1**). The medical and surgical history, presenting complaints and physical and endoscopic examination results, was documented. The details of the rhinoplasty and sinus surgery subtype procedures are listed in **Tables 2** and **3**, respectively. Patient follow-ups were obtained with standardized questionnaires (SNOT 22) of presenting complaints, satisfaction with surgical experience, and self-evaluation of aesthetic outcome.

Patient number	Race/country of origin	Age	Sex	Open rhinoplasty (ORP) procedure	ESS procedure	Duration (minutes)	Blood loss (ml)
1	M	34	F	SP, SprG, CEG SG, O	TR, E, MMA	179	95
2	Canada	54	F	SP, SprG, SG	TR	145	115
3	M	39	F	SP, SprG, CEG, SG, O	TR, E, MMA	181	115
4	I	36	M	SP, SprG, SG, HR	TR	148	110
5	I	32	F	SP, SprG, CS, SG	TR, E, MMA	179	90
6	C	50	F	SP, SprG, CEG SG, O, CCG	TR, E, MMA, FS	287	235
7	C	26	F	SP, SprG, CEG SG	TR	152	80
8	M	30	F	SP, SprG, CEG SG	TR, E, MMA	177	85
9	I	32	F	SP, SprG, SG, CSR	TR, E, MMA, Sph	211	105
10	M	32	M	SP, SprG, CEG SG, O	TR, E, MMA	189	120
11	I	23	F	SP, SprG, SG	TR	141	90
12	Australia	45	F	SP, SprG, SG	TR, E, MMA	185	100
13	I	32	F	SP, SprG, CS, SG	TR, E, MMA	195	95
14	M	18	M	SP, SprG, CEG, SG	TR, E	190	75
15	C	22	F	SP, SprG, CEG, SG	TR, E, MMA	184	110
16	C	40	F	SP, SprG, CEG, SG	TR	164	85
17	M	28	M	SP, SprG, CEG, SG	TR, E, MMA	168	90
18	M	55	M	SP, SprG, CEG, SG, O	TR, E, MA, FS, Sph, CCG	277	240
19	I	32	F	SP, SprG, SG	TR, E, MMA	171	110
20	M	40	F	SP, SprG, CEG, SG	TR, E, MMA	154	85
21	I	25	M	SP, SprG, CS, SG	TR	159	85
22	I	25	F	SP, SprG, SG	TR	167	105
23	I	29	M	SP, SprG, SG	TR, E, MMA	143	115
24	C	31	F	SP, SprG, CEG, SG	TR, E, MMA	156	95

Patient number	Race/country of origin	Age	Sex	Open rhinoplasty (ORP) procedure	ESS procedure	Duration (minutes)	Blood loss (ml)
25	C	40	F	SP, SprG, CEG, SG	TR, E, MMA	169	105
26	I	25	F	SP, SprG, SG, CSR, O	TR, E, MMA, Sph	191	180
27	United Kingdom	37	M	SP, SprG, SG, O	TR, E, MMA, FS, Sph	261	245
28	M	26	F	SP, SprG, CEG, SG	TR, E, MMA	189	160
29	I	31	M	SP, SprG, CS, SG	TR	148	140
30	C	23	M	SP, SprG, CEG, SG, O	TR, E, MMA, FS	253	215
31	M	25	F	SP, SprG, CEG, SG	TR, E, MMA, Sph	214	120
32	M	36	F	SP, SprG, CEG, SG	TR, E, MMA	197	100
33	I	41	F	SP, SprG, CS, SG	TR	154	80
34	M	25	F	SP, SprG, CEG, SG	TR, E, MMA	176	130
35	I	22	M	SP, SprG, SG	TR, E, MMA, Sph	187	110
36	I	16	M	SP, SprG, SG	TR	160	80
37	C	50	M	SP, SprG, CEG, SG, O	TR, E, MMA	181	105
38	I	23	M	SP, SprG, CS, SG, O, HR, CCG	TR, E, MMA, FS, Sph	267	210
39	I	33	M	SP, SprG, CEG, SG	TR, E, MMA	191	115
40	Indonesia	38	F	SP, SprG, CEG, SG	TR	169	75
41	I	28	F	SP, SprG, SG, CSR	TR, E, MMA, FS	189	90
42	C	52	F	SP, SprG, CEG, SG	TR, E, MMA	212	95
43	C	30	F	SP, SprG, CEG, SG	TR	172	85
44	I	23	F	SP, SprG, SG, O, HR	TR, E, MA, FS, Sph	265	220
45	I	36	M	SP, SprG, CS, SG	TR	97	110
46	M	41	F	SP, SprG, CEG, SG	TR	163	75
47	C	17	M	SP, SprG, CEG, SG	TR, E, MMA	191	105
48	M	27	M	SP, SprG, CEG, SG, O	TR, E, MMA	183	120
49	Indonesia	32	M	SP, SprG, CEG, SG	TR,E	193	105
50	M	28	M	SP, SprG, CEG, SG	TR, E, MMA	176	115
51	I	18	M	SP, SprG, CS, SG	TR	163	95
52	I	18	F	SP, SprG, CEG, SG, O, HR	TR, E, MMA, FS, Sph	259	250
53	Iran	35	M	SP, SprG, CS, SG	TR, E, MMA	197	120

TR, turbinate reduction; SP, septoplasty; Spr G, spreader graft; CEG, columella extension graft; SG, shield graft; HR, hump reduction; CS, columella strut; CCG, conchal cartilage graft; CSR, caudal septal resection; E, ethmoidectomy; MMA, middle meatal antrostomy; Sph, sphenoidotomy; FS, frontal sinusotomy; M, Malay; C, Chinese; I, Indian Revision cases

Table 1.
 Demographics of 53 patients who underwent concurrent rhinoplasty and ESS.

Septoplasty (SP)	53 (100%)
Turbinate reduction (TR)	53 (100%)
Ethmoidectomy (E)	38 (71.7%)
Middle meatal antrostomy (MMA)	36 (67.9%)
Sphenoidotomy (Sph)	9 (16.9%)
Frontal sinusotomy (FS)	8 (15.1%)

Table 2.

Summary of endoscopic sinus subtype procedures performed on 53 patients who underwent concurrent two procedural approaches.

Spreader graft (SprG)	53 (100%)
Shield graft (SG)	53 (100%)
Columella extension graft (CEG)	29 (54.7%)
Osteotomy (O)	13 (24.5%)
Columella strut (CS)	9 (16.9%)
Hump reduction (HR)	4 (7.5%)
Caudal septal resection (CSR)	3 (5.6)
Conchal cartilage graft (CCG)	3 (5.6)

Table 3.

Summary of rhinoplasty subtype procedures performed on 53 patients who underwent concurrent two procedural approaches.

3. Results

Between January 2016 and December 2018, 53 patients underwent rhinoplasty combined with endoscopic sinus surgery (ESS). The demography of the patients is listed in **Table 1**. There were 31 females and 22 males with age ranging from 16 to 55 years with a mean of 31.8 years. There were three referred revision cases where rhinoplasty [1] and septoplasty [2] were performed elsewhere. All patients had open approach rhinoplasty. The average operative time was 45 minutes for endoscopic sinus surgery and 141.20 minutes for rhinoplasty. The average operating time for the concurrent procedure was 186.20 minutes, and average blood loss was 121.4 ml. Out of the 53 patients, there were 15 Malays, 11 Chinese, and 21 Indians, and the remaining 6 were foreigners (one each from Australia, Canada, Iran, and the United Kingdom and two from Indonesia). Thirty-eight (71.6%) of the 53 patients had a history of chronic snoring and 27 (50.9%) history of nasal trauma.

Regarding the ESS, the most common procedure performed was septoplasty and turbinate reduction in all patients, followed by ethmoidectomy (71.7%), middle meatal antrostomy (67.9%), sphenoidotomy (16.9%), and frontal sinusotomy (15.1%). Majority of the patients had extensive mucosal disease requiring sinus surgery.

Regarding the rhinoplasty procedures, the most common aesthetic procedure was spreader graft and shield graft in all patients followed by columella extension graft (54.7%), osteotomy (24.5%), columella strut (11.9%), hump reduction (7.5%) caudal septal resection, and conchal cartilage graft (5.6%). It is of interest to note that 53 patients had some type of cartilage graft performed (spreader graft, shield graft, columellar extension graft, caudal septal resection, columella strut, and conchal cartilage graft). Pictures of spreader and shield grafts are illustrated in **Figures 6** and **7**. All patients were followed up for a minimum of 6 months of post-surgery at the time of this report. All patients reported an improvement in

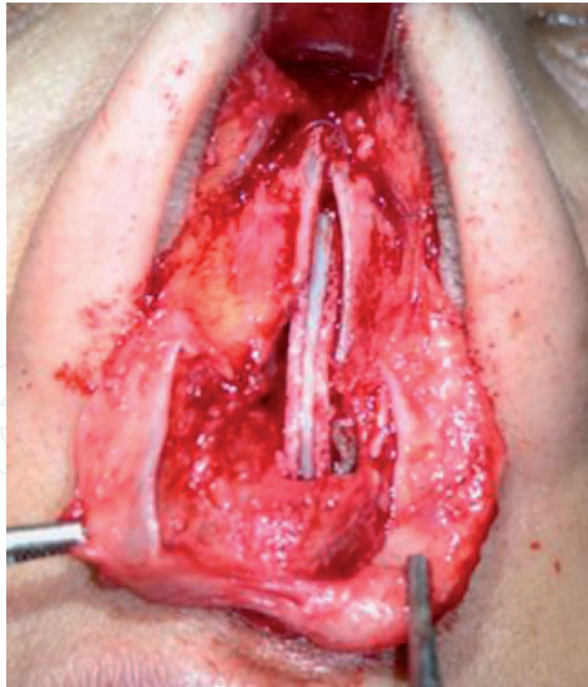


Figure 6.
Picture showing spreader graft sandwiched between the septum just before mattress sutures are applied in a case of twisted nose.

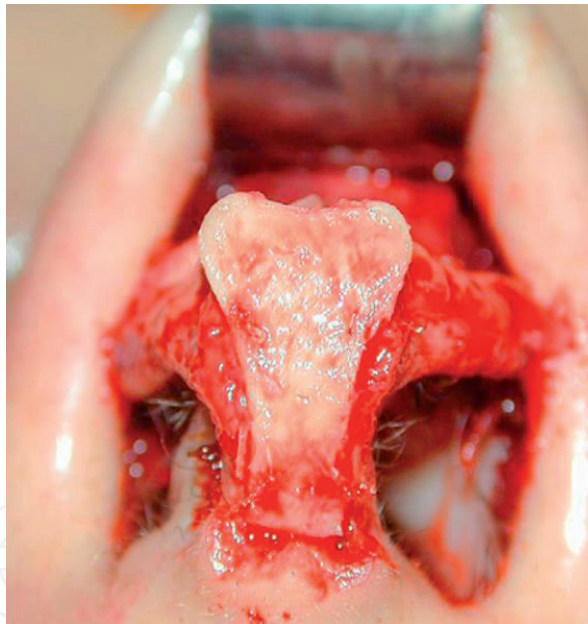


Figure 7.
Close-up view of shield graft augmentation tip plasty.

their sinus symptoms and were adequately satisfied with their nasal appearance. No revision rhinoplasty or ESS was performed on this group at the time of reporting.

There were no major complications noted in this study. There were minor complications reported which were mainly delayed wound healing [2], minor irregularities of the nasal dorsal skin lining [2], alar asymmetry [2], and pinching of the nose [1]. None of the patients were interested in further surgical intervention at that moment in time.

4. Discussion

In the population, there are patients with cosmetic nasal concerns who will also have functional problems (nasal obstruction and/or sinus problems) which should be

fully evaluated. Moreover, patients with functional nasal problems would like a cosmetic nasal improvement (Figures 8, 9, and 10). It is meaningful that patients who would benefit from rhinoplasty and ESS would wish to combine the two procedures which would save patients time, money, and inconvenience. Advances in powered sinus instrumentation have made combining rhinoplasty and ESS more attractive. In 1991, Sheman and Matarasso [15] first reported combining rhinoplasty and ESS, and since then various authors have reported a bigger series demonstrating the safety and efficacy of combining these two procedures [16–21].

Since the main complaint on presentation was chronic nasal obstruction (DNS with enlarged turbinates) with rhinosinusitis, all the patients had septal surgery with turbinate reduction. The CT scan of the paranasal sinuses performed on all the patients showed evidence of involvement of more than one paranasal sinus; the ESS was performed on more than one sinus. The most common sinuses involved were the ethmoid and the maxillary sinuses, with less incidence of involvement of sphenoid and frontal sinuses. Since all the patients presented with internal nasal valve problems, all the patients had spreader with shield graft performed.

Since all patients had caudal septal deviation with narrow nasal valve, spreader graft was performed on all patients. Only 24.5% of patients had mid-vault deformity which required osteotomy.

Powered instrumentation combining suction, irrigation, debridement, and cautery reduces surgical steps, operative time, and blood loss. IGS is a valuable

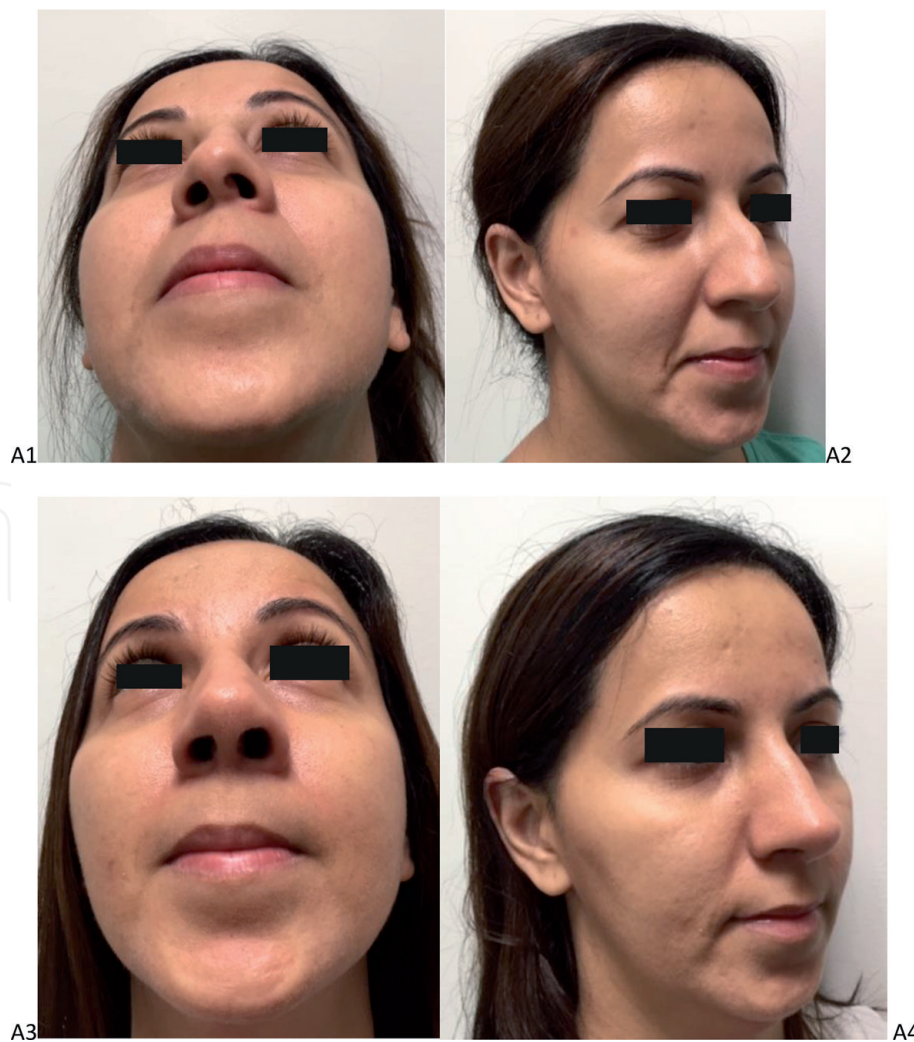

Figure 8. Pre (A1 and A2) and postoperative (A3 and A4) pictures of patient no. 38 who presented with twisted nose, prominent nasal hump, and CRS.

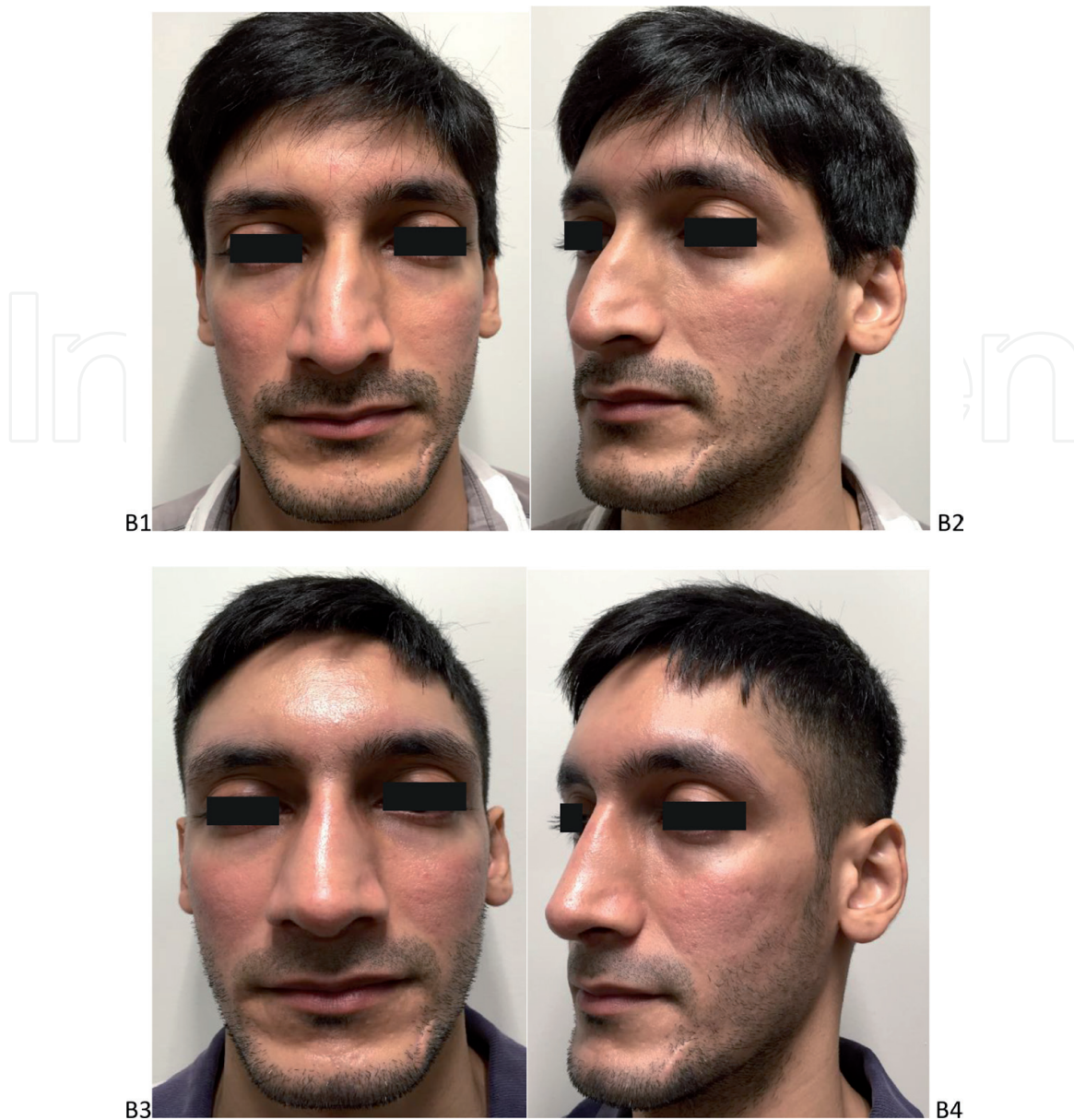

Figure 9. Pre- (B1 and B2) and postoperative (B3 and B4) pictures of patient no. 13 who presented with crooked nose, pseudo-hump nasal hump, and CRS.

instrument used for anatomic confirmation especially in revision cases. Absorbable sinus packing has increased patient comfort. Advances in ESS instrumentation have made the procedure faster, safer, precise, and comfortable.

This addition of 53 cases of rhinoplasty with ESS to the literature by one surgeon technique illustrates the overall safety and efficacy of combining the two procedures. This study shows that the ESS using powered instrumentation is not too time-consuming, on average taking about 45 minutes in this study compared to 50 minutes in other reported cases [13]. Total blood loss for the combined procedure was about three times more (121 cc) in our study compared to blood loss in other studies (40 cc) [21] which could likely be due to the more extensive paranasal sinus mucosal disease involvement. The average operating time for the concurrent procedure was 186.20 minutes compared to 110 minutes in other reports [22] which could likely be due to time-consuming remodeling utilizing autografts. All the patients had some type of cartilage grafting with no evidence of infection, extrusion, malposition, or resorption since autologous grafts were used in all 53 patients. Minor complications like erythematous columellar incisions were treated aggressively with a course of oral antibiotics.

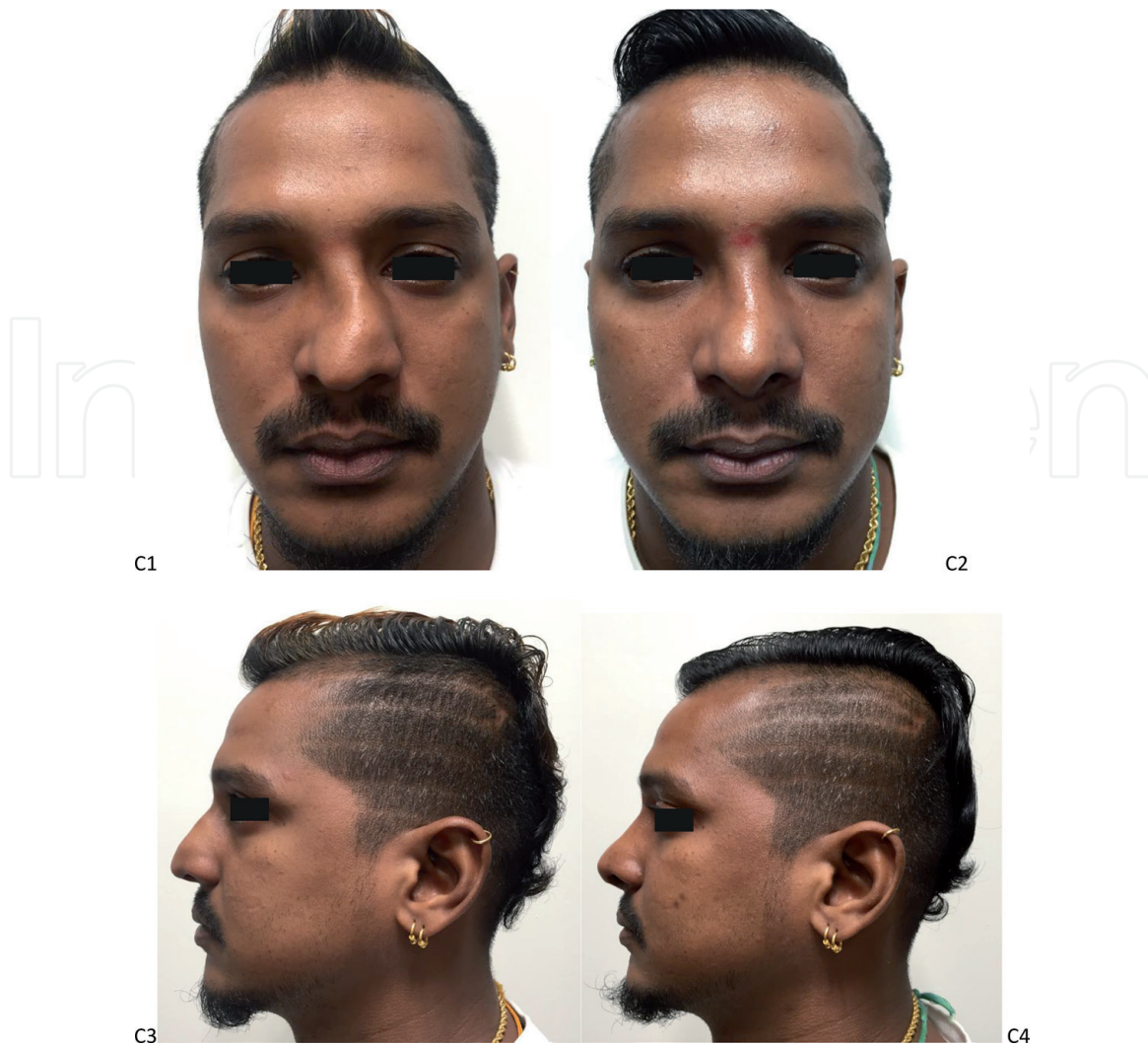

Figure 10. Pre- (C1 and C2) and postoperative (C3 and C4) pictures of patient no. 26 who presented with twisted nose, pseudo-nasal hump, and CRS post-trauma.

A review of 268 rhinoplasties between 1997 and 2001 demonstrated 11 cases with concurrent surgery, and there were no complications noted in this study [17]. Furthermore, the authors mention a case report of a 22-year-old patient who underwent a septorhinoplasty and ESS on an outpatient basis at another institution and developed edema over the nose, cheek, glabella, and forehead regions with fever. A CT scan of paranasal sinuses showed evidence of opacification of the frontal sinuses with dehiscence of nasal bones which responded to intravenous medication and frontal trephination. Herzon in 1971 reported a 12% incidence of bacteremia in patients undergoing nasal septal surgery requiring nasal packing [23]. In 1978, Todd et al. reported the first case of toxic shock syndrome (TSS) [24]. Four years later the first case of TSS after septorhinoplasty was reported [25].

Most authors agree that performing the sinus surgery first allows the surgeon to determine if there is ongoing rhinosinusitis. Millman B who performs combination rhinoplasty with ESS recommends not proceeding with rhinoplasty if there are signs of infection [17].

There have been only 4 reported cases of MRSA associated postoperative complications following septorhinoplasty reported in the literature across all specialities [26]. Patients who are susceptible to MRSA infections may also be at higher risk for nasal colonization, and this includes elderly patients, patients recently hospitalized or treated in a rehabilitation center, and health-care workers. Few cases of MRSA infection following septorhinoplasty have been reported in the literature. Elimination

of nasal colonization is a major step in preventing these infections, and preoperative systemic antibiotic use should be considered, especially in revision cases [27].

Most of the sinus symptoms resolved postoperatively with 47 (88.6%) of 53 patients describing their improvement as significant. Fifty (94.3%) of 53 patients stated that they would recommend the concurrent procedure.

5. Conclusion

The author has reasonably good results combining rhinoplasty and ESS, and the benefits of these advances are illustrated by a review of the literature with good results (functional and cosmetic) and minimal complications. Extracorporeal approach was performed on all patients with gross high septal deviation. All the patients had some type of cartilage grafting with no evidence of infection, extrusion, malposition, or resorption since all the patients had autologous grafts inserted. Minor complications like erythematous columellar incisions were treated aggressively with a course of oral antibiotics. Advances in rhinoplasty and sinus surgery technique and equipment have made this one surgeon combined procedure safe and cost-effective with good results in selected patients.

Author details

Balwant Singh Gendeh
Pantai Hospital Kuala Lumpur, Kuala Lumpur, Malaysia

*Address all correspondence to: bsgendeh@gmail.com

IntechOpen

© 2019 The Author(s). Licensee IntechOpen. This chapter is distributed under the terms of the Creative Commons Attribution License (<http://creativecommons.org/licenses/by/3.0>), which permits unrestricted use, distribution, and reproduction in any medium, provided the original work is properly cited. 

References

- [1] Murakami C. Nasal valve collapse. *Ear, Nose, & Throat Journal*. 2004;**83**:163-164
- [2] Beekhuis GJ. Nasal obstruction after rhinoplasty: Etiology and techniques for correction. *The Laryngoscope*. 1976;**86**:540-548
- [3] Scadding GK, Durham SR, Mirakian R, et al. BSACI guidelines for the management of rhinosinusitis and nasal polyposis. *Clinical and Experimental Allergy*. 2008;**38**(2):260-275
- [4] Sheen JH. Spreader graft: A method of reconstructing the roof of the middle nasal vault following rhinoplasty. *Plastic and Reconstructive Surgery*. 1984;**73**(2):230-239
- [5] Byrd HS, Andochick S, Copit S, et al. Septal extension grafts: A method of controlling tip projection shape. *Plastic and Reconstructive Surgery*. 1997;**100**:999-1010
- [6] Whitaker EG, Johnson CM Jr. The evolution of open structure rhinoplasty. *Archives of Facial Plastic Surgery*. 2003;**5**:291-300. DOI: 10.1001/archfaci.5.4.291
- [7] Toriumi DM. New concepts in nasal tip contouring. *Archives of Facial Plastic Surgery*. 2006;**8**:156-185. DOI: 10.1001/archfaci.8.3.156
- [8] Clark JM, Cook TA. The "butterfly" graft in functional secondary rhinoplasty. *Laryngoscope*. 2002;**112**:1917-1925
- [9] Lee DS, Glasgold AI. Correction of nasal valve stenosis with lateral suture suspension. *Archives of Facial Plastic Surgery*. 2001;**3**:237-240
- [10] Schlosser RJ, Park SS. Surgery of the dysfunctional nasal valve: Cadaveric analysis and clinical outcomes. *Archives of Facial Plastic Surgery*. 1999;**1**:105-110
- [11] Marchica P, Bassetto F, Vindigni V, Galici R, Dispenza F, Gallina S, et al. Endoscopic sinus surgery associated with rhinoseptoplasty: A case-control study. *Plastic and Reconstructive Surgery Global Open*. 2018;**10**:1-5
- [12] Terrel JE. Primary sinus surgery. In: Cummings CW, Friedrickson JM, Harker LA, et al, editors. *Otolaryngology Head Neck Surgery*. Vol. 2. St Louis: Mosby; 1998. pp. 1160-1162
- [13] Levine HL, May M, Schaitkin B, Mester SJ. Results of surgery. In: Levine H, May M, editors. *Endoscopic Sinus Surgery*. New York: Thieme Medical Publishes Inc; 1993. pp. 176-192
- [14] Rizk SS, Edelstein DR, Matarasso A. Concurrent functional endoscopic sinus surgery and rhinoplasty. *Annals of Plastic Surgery*. 1997;**38**:323-329
- [15] Sheman LJ, Matarasso A. Combined endoscopic sinus surgery and aesthetic rhinoplasty: A pilot study. *American Journal of Rhinology*. 1991;**5**:131-136
- [16] Toffel PH. Simultaneous secure endoscopic sinus surgery and rhinoplasty. *Ear, Nose and Throat Journal*. 1994;**73**(8):554-573
- [17] Milman B, Smith R. The potential pitfalls of concurrent rhinoplasty and endoscopic sinus surgery. *Laryngoscope*. 2002;**112**(71):1193-1196
- [18] Mazzola RF, Felisati G. Rhinoplasty and endoscopic surgery for functional and inflammatory nasal/sinus disorders. *Plastic and Reconstructive Surgery*. 2005;**115**(3):705-710
- [19] Lee JH, Sherris DA, Moore EJ. Combined open septorhinoplasty and

functional endoscopic sinus surgery.
Otolaryngology. 2005;**133**(3):436-440

[20] Inanli S, Sari M, Yazici MZ. The results of concurrent functional endoscopic sinus surgery and rhinoplasty. *The Journal of Craniofacial Surgery*. 2008;**19**(3):701-704

[21] Marcus B, Patel Z, Busquets J, Hwang PH, Cook TA. The utility of concurrent rhinoplasty and sinus surgery: A 2-team approach. *Archives of Facial Plastic Surgery*. 2006;**8**(4):260-262

[22] Murrell GL. Rhinoplasty and functional endoscopic sinus surgery. *Plastic Surgery International*. 2011;**10**:1-6. DOI: 10.155/2011/473481

[23] Herzon FS. Bacteremia and local infections with nasal packing. *Archives of Otolaryngology*. 1971;**94**:31-32

[24] Todd J, Fishaut M, Kapral F, Welch T. Toxic shock syndrome associated with phase group! *Staphylococcus*. *Lancet*. 1979;**1**:1116-1118

[25] Thomas SW, Baird IM, Frazier RD. Toxic shock syndrome following submucous resection and rhinoplasty. *JAMA*. 1982;**247**:2402-2403

[26] Lohr GD, Hollabaugh B, Waters P, Tiwana PS. Methicillin-resistant *Staphylococcus aureus* and antibiotic use in septorhinoplasty: Case report and review of literature. *Journal of Oral Medicine, Oral Surgery, Oral Pathology and Oral Radiology*. 2017;**123**(6):e 177-e 188

[27] Angelos PC, Wang TD. Methicillin-resistant *Staphylococcus aureus* infection in septorhinoplasty. *Laryngoscope*. 2010;**120**(7):1309-1311