

We are IntechOpen, the world's leading publisher of Open Access books Built by scientists, for scientists

4,800

Open access books available

122,000

International authors and editors

135M

Downloads

Our authors are among the

154

Countries delivered to

TOP 1%

most cited scientists

12.2%

Contributors from top 500 universities



WEB OF SCIENCE™

Selection of our books indexed in the Book Citation Index
in Web of Science™ Core Collection (BKCI)

Interested in publishing with us?
Contact book.department@intechopen.com

Numbers displayed above are based on latest data collected.

For more information visit www.intechopen.com



The Practice of Computer-Assisted Planning and Navigation for Hip Arthroscopy

Naomi Kobayashi, Shota Higashihira and Yutaka Inaba

Abstract

Despite significant developments in hip arthroscopic surgery in recent years, precise preoperative planning and accurate performance remain challenging. Preoperative planning is particularly important in cases of osteochondroplasty for cam-type femoroacetabular impingement (FAI), and can be aided by several computer-assisted tools, including three-dimensional imaging analysis or kinematic analysis. Initially, the exact point of the bony impingement is identified using simulation analysis; then, virtual osteochondroplasty is performed. Improvements in the range of motion can then be evaluated using computer simulation again. In this way, the required area and depth of bone resection can be assessed preoperatively. In addition, computed tomography-based navigation assistance can be used to complete the osteochondroplasty in accordance with the preoperative planning. After surgery, postoperative evaluation provides valuable feedback to improve future planning and procedures. In this chapter, we describe the practice of computer-assisted planning and navigation for hip arthroscopy.

Keywords: hip arthroscopy, femoroacetabular impingement, computer-assisted surgery, navigation

1. Introduction

In the last decade, hip arthroscopic surgery has become widely recognized as an effective option for the treatment of femoroacetabular impingement (FAI). In order to achieve optimal clinical results, it is essential to correct the bony impingement, and therefore, precise osteochondroplasty is one of the most important factors. However, it is not possible to predict the impingement point in each case based only on radiographic images [1]; and computer simulation modeling is important to provide three-dimensional identification. This is the starting point of computer-assisted hip arthroscopy; thereafter, preoperative planning is conducted by virtual osteochondroplasty in a computer model, before transferring to a navigation system. Therefore, the computer-assisted tool not only provides surgical assistance, but also supports the preoperative planning. The real value of the computer navigation system lies in the ability to undertake precise preoperative planning, and it is difficult to achieve precise and reliable surgical results without computer navigation. After surgery, the area of impingement can be re-evaluated using postoperative computed tomography (CT) data. Furthermore, it is possible to validate the

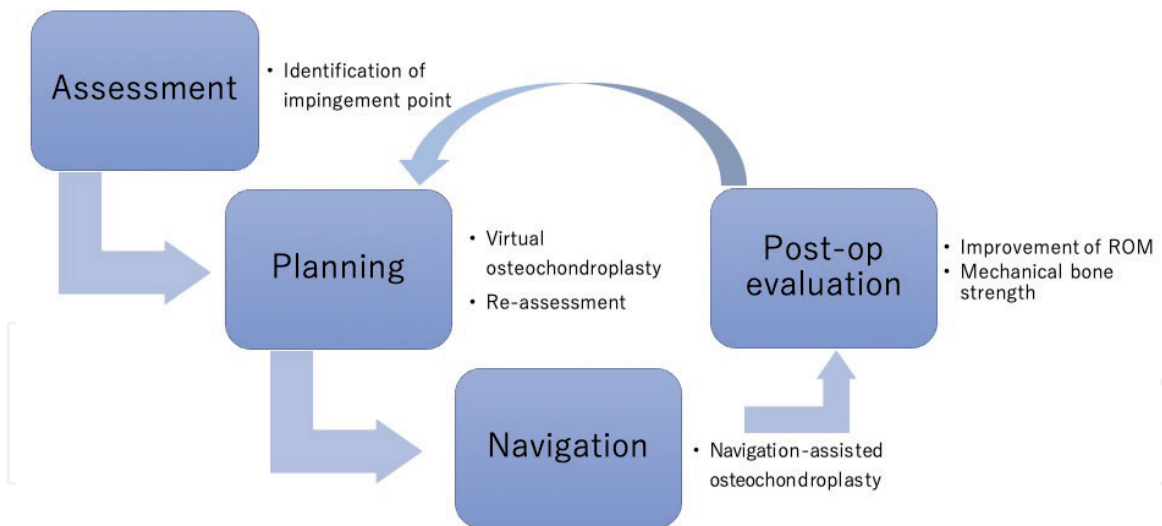


Figure 1.
Flow of computer-assisted hip arthroscopy for FAI.

mechanical bone strength after osteochondroplasty using finite element analysis. These postoperative evaluations provide important feedback for future cases, as illustrated in **Figure 1**.

2. Identification of impingement points

The distribution of impingement points in cam lesions is dependent on the morphology in each femoral head-neck junction, as well as acetabular morphology, such as dysplasia [2]. Bone-to-bone impingement occurs during the dynamic phase of hip motion, such as flexion and internal rotation. Therefore, it is not possible to identify the impingement point by radiograph only. Computer modeling based on CT data allows the identification of the exact impingement point in each lower limb position. As a representative position for anterior impingement, maximum internal rotation at a 90° flexion is preferred for impingement simulation (**Figure 2**). The ZedHip (Lexi, Tokyo) system is used for the computer simulation analysis. It is important to note that the impingement point is dependent on the hip position setting, i.e., flexion angle or additional adduction of the hip. The position setting is

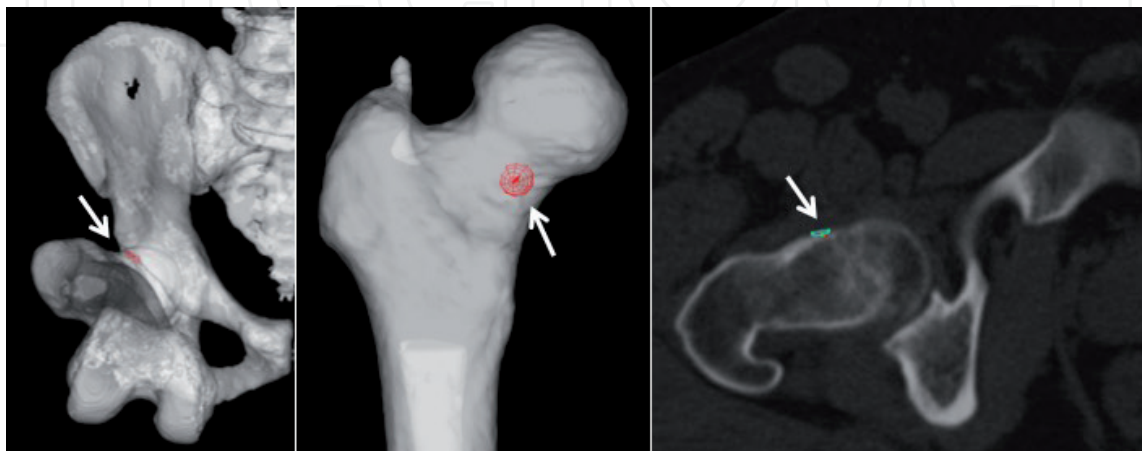


Figure 2.
Identification of the impingement point by computer simulation. Impingement simulation with 90° flexion and maximum internal rotation is conducted. The impingement point is identified in the three-dimensional femur model and axial image (arrow).

variable, and it is difficult to define the optimal setting, which is one of the limitations of this approach, as discussed later in this chapter.

In a previous study by Oishi et al. [3], impingement simulation was applied and compared with the abnormal uptake point by positron emission tomography. This study showed that impingement may occur more frequently at $<90^\circ$ flexion in patients with FAI syndrome with cam morphology. In addition, the range of hip motion in daily life is activity-dependent. Therefore, further evaluation is required to establish the appropriate hip position setting for impingement simulation representing the variety of hip positions during different activities associated with daily life.

3. Virtual osteochondroplasty and assessment of improved range of motion

The next step in the preoperative planning process is computerized “virtual osteochondroplasty” (Figure 3). The bony region is deleted in the editing mode of the ZedHip software with the central focus on the impingement point. It is important to delete the bony region smoothly, rather than creating a notch, as it is with the actual osteochondroplasty. Flexion angle at 70° or 45° should be added as a simulation condition. It should be noted that virtual osteochondroplasty should be performed using the same assumptions as actual surgery, i.e., excessive osteochondroplasty should be avoided to maintain bone strength. A previous study using an animal model of mechanical testing and finite element analysis revealed that up to 36% of the femoral neck diameter could be safely resected during simulated osteochondroplasty [4]. By contrast, residual cam deformity is one of the most important risk factors for revision surgery [5]. It is, therefore, important to pay close attention to the trade-off between bone strength and the risk of residual deformity.

After deleting the impinging bony region during virtual osteochondroplasty, a bone model is reconstructed. Using this model, the range of motion can be re-evaluated and compared with the situation prior to virtual osteochondroplasty. It is difficult to judge the improvement in maximum internal rotation angle; however, we suggest that the threshold is set at 10° . Therefore, virtual osteochondroplasty should be performed until an improvement of more than 10° is confirmed. Kubota et al. evaluated the improvement of range of motion after virtual osteochondroplasty, comparing FAI and borderline dysplasia cases [6]. Figure 4 shows the difference in improvement between cam-type FAI and borderline dysplasia with or without

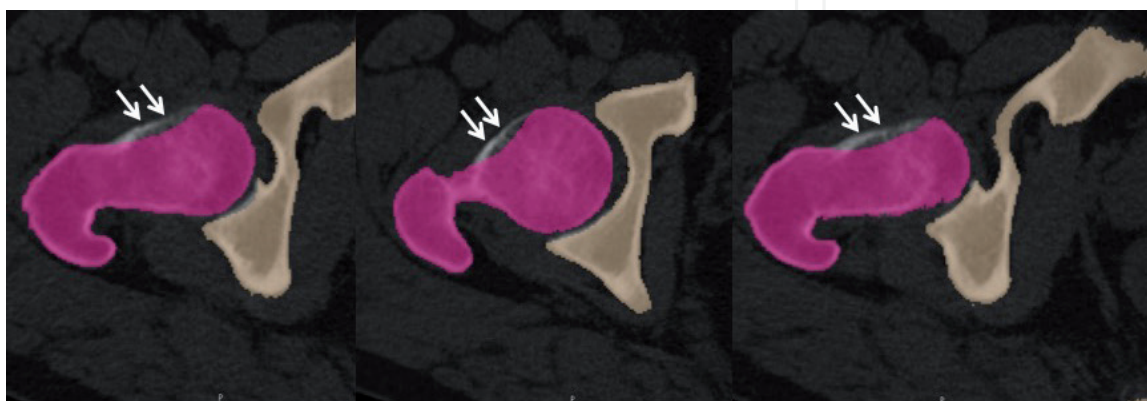
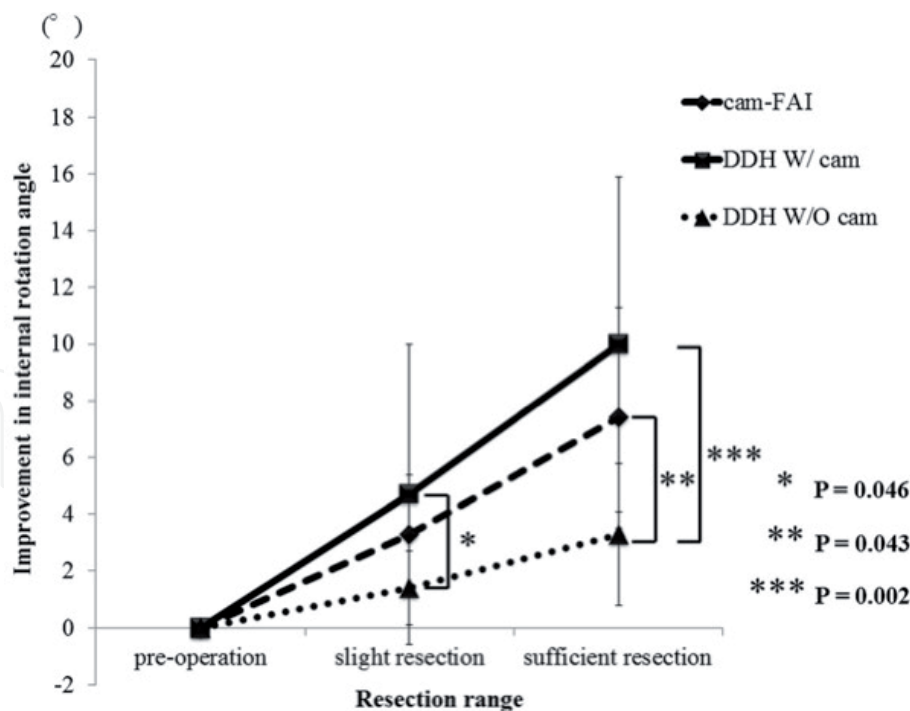


Figure 3. Virtual osteochondroplasty in preoperative planning. With the central focus on the impingement point, osteochondroplasty is performed in the computer simulation model. The purple colored area shows the post-resected bone region; bone resection must be conducted smoothly to avoid creating a notch (arrows).



Kubota et al. BMC Musculoskeletal Disorders (2017) 18:417

Figure 4.

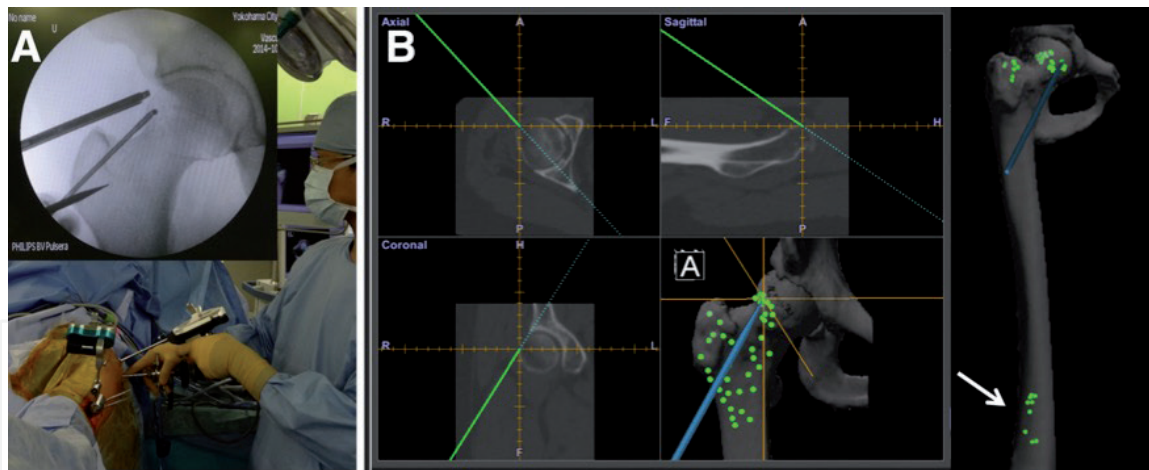
Improvement in the internal rotation angle after each type of resection. The mean improvement in the internal rotation angle in the DDH with cam group after slight resection was significantly greater than that in the DDH without cam group ($P = 0.046$), as was that after sufficient resection ($P = 0.002$). The improvement in the cam-FAI group was significantly greater than that in the DDH without cam group ($P = 0.043$). DDH: developmental dysplasia of the hip.

cam morphology [6], demonstrating that the improvement in the range of motion is dependent on the extent of bone resection. An interesting clinical implication in this study is that borderline dysplasia with cam morphology showed the most significant improvement by virtual osteochondroplasty. Therefore, even in cases of borderline dysplasia, the co-existence of cam morphology should be considered.

4. Computer navigation-assisted arthroscopic osteochondroplasty

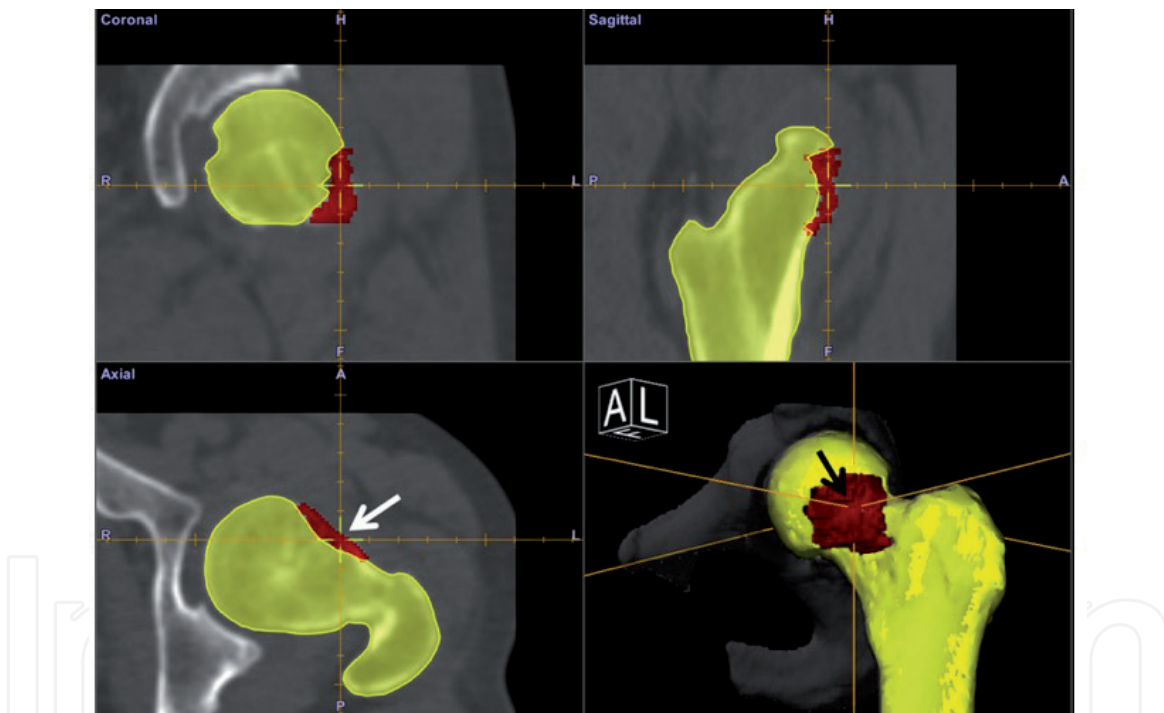
The planning data are transferred directly to a CT-based navigation system (Orthomap 3D; Stryker, Kalamazoo, MI). The technical details of computer navigation-assisted arthroscopic surgery have been published previously [7]. The most important and challenging aspect is point-to-point matching under fluoroscopic guidance (Figure 5). After matching five or six landmark points, surface matching of 40–50 points is performed. It is important to add several distal femur points to ensure accurate registration, and to add points from as large an area as possible. The final mean deviation error after registration must be <1 mm. After registration, an instrument tracker device is attached to the abrader burr. The tracker device must be fixed securely to the abrader burr, as any loosening of the device will result in variance in the navigation. Computer navigation-assisted osteochondroplasty is then initiated, during which time fluoroscopic guidance is not required.

The most notable advantage of navigation assistance is that it provides information on the actual depth and range of the resected area in real-time, seen as the tip of abrader burr (Figure 6). In addition, the planned resection area can also be seen as a red zone. It is, therefore, possible to accurately resect a cam lesion, without deficiency or excess. Using a pointer device, the resected region can be reliably



Kobayashi et al. Arthroscopy Techniques, Vol 7, No 4 (April), 2018: pp e397-e403

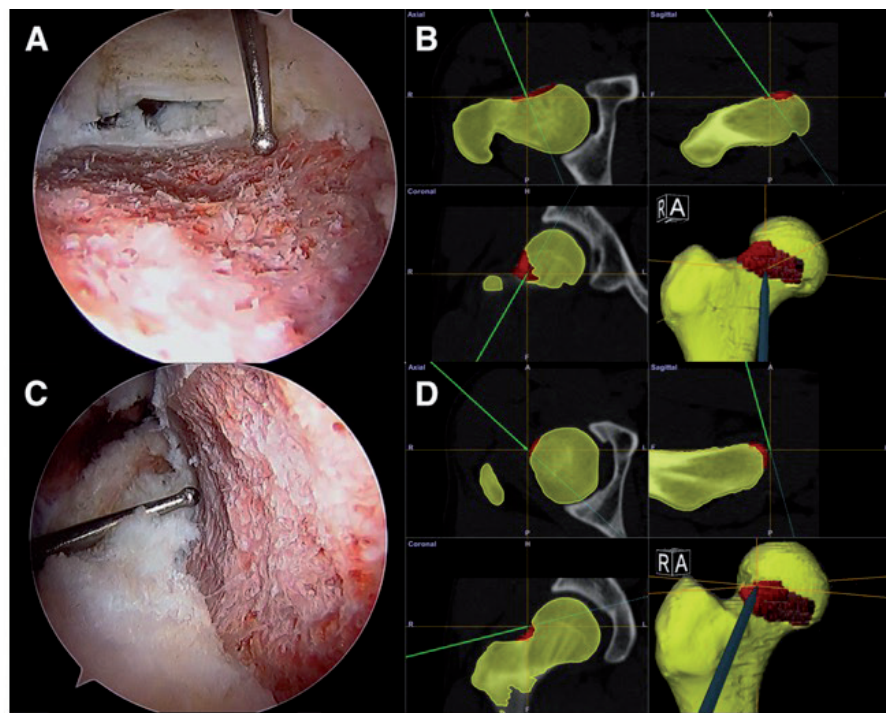
Figure 5. Point matching under fluoroscopic guidance (A) and surface matching (B) during navigation system registration. Point matching is performed under fluoroscopic guidance for 5–6 landmark points (A). Thereafter, surface matching is performed without fluoroscopic guidance for 40–50 points, including on the distal femur (arrow) (B).



Kobayashi et al. Arthroscopy Techniques, Vol 7, No 4 (April), 2018: pp e397-e403

Figure 6. Navigation assistance during osteochondroplasty. The center of the cross (arrow) indicates the tip of the abrader burr located in the planned resection area (red area).

verified (**Figure 7**). Occasionally, it may be necessary to use pincer resection. In these cases, it is also possible to plan the pincer resection and to use navigation assistance once pelvic registration has been completed (**Figure 8**). Particularly in pincer resection, it is difficult to identify the acetabular rim three-dimensionally by fluoroscopy, while navigation assistance can clearly identify the actual point on acetabula rim. Thus, the navigation assistance may contribute to the reduction of operative time during lower limb traction. This is important in terms of reducing the complication such as neurological disturbance caused by perineal post.



Kobayashi et al. Arthroscopy Techniques, Vol 7, No 4 (April), 2018: pp e397-e403

Figure 7.

Verification of resected area and depth using a pointer device. The pointer device indicates the distal margin of the resected area from the anterolateral portal view with the pointer via the mid-anterior portal (A), which is also identified by the computer navigation monitor (B). The lateral margin of the resected area is clearly verified from the mid-anterior portal view with the pointer via the anterolateral portal (C, D).

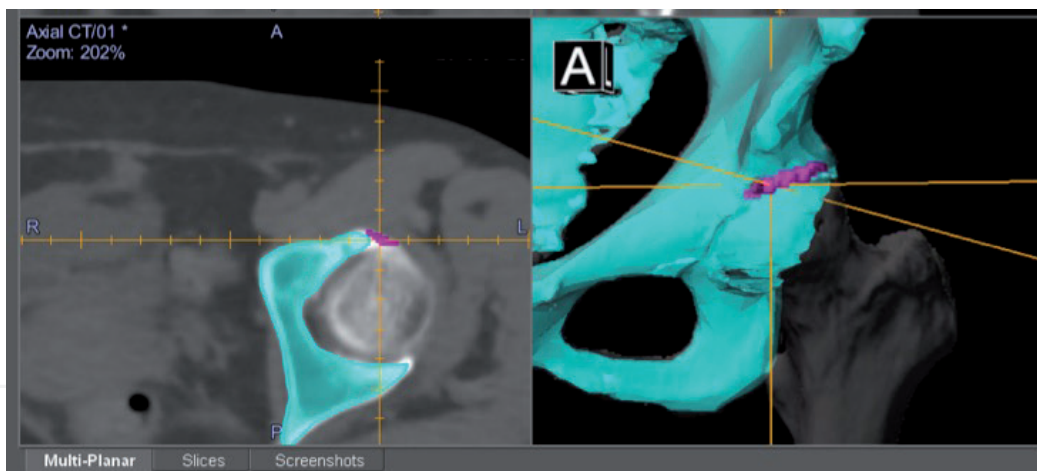


Figure 8.

Navigation assistance for pincer resection. The purple colored area shows the planned resection for a pincer lesion. The center of the cross indicates the tip of the abrader burr.

5. Postoperative evaluation

Postoperative evaluation is also possible and provides useful clinical feedback. Improvement in the maximum internal rotation angle indicates a release from the bony impingement. Ross et al. also adopted computer simulation analysis to evaluate the three-dimensional morphology of hips with residual symptoms prior to revision FAI surgery [5].

Another application of postoperative evaluation after osteochondroplasty is the assessment of mechanical bone strength by finite element analysis. This approach was used by Oba et al. to calculate changes in simulated fracture load between pre- and postoperative femur models in a clinical study of postoperative

FAI subjects [8]. The results suggested that the bone resection depth measured at the head-neck junction and transcervical reference plane correlates with fracture risk after osteochondroplasty. By contrast, bone resection at more proximal areas did not have a significant influence on the postoperative femur model strength [8]. Similarly, Alonso-Rasgado et al. concluded that resection depth should be kept to <10 mm or 1/3 of the diameter of the neck based on their finite element study [9]. These clinical implications provide valuable feedback to improve the preoperative planning of future cases (**Figure 1**).

6. Limitations and future prospects

There are several important limitations in the methodology of computer simulation. First, the bone model used in the simulation does not assess factors related to the soft tissue, including the labrum. Therefore, impingement simulation that includes consideration of the soft tissues may be required. Secondly, the simulation conditions, i.e., the variation of flexion angle, have not yet been fully established. In addition, the influence of pelvic tilt must be considered, as dynamic changes significantly influence the impingement location and simulated range of motion [10]. Currently, we use the functional pelvic plane as the reference plane; however, pelvic tilt would certainly be influenced by interventions, such as rehabilitation or surgery [11].

7. Conclusion

A summary of the preoperative assessment, planning, and navigation for arthroscopic FAI surgery using computer-assisted technology is presented. Each step of computer-assisted technology is mutually related, and it is important to comprehend this technology as a sequential flow. Although there are several limitations that need to be addressed, the notable benefits can contribute to the successful treatment of FAI.

Acknowledgements

The authors gratefully acknowledge Takayuki Oisi, Msastoshi Oba, and So Kubota for contributing related study projects.

Reprinted from [7] with permission from Elsevier.

Conflict of interest

The authors have no conflict of interest to declare.

IntechOpen

Author details

Naomi Kobayashi^{1*}, Shota Higashihira² and Yutaka Inaba²

1 Department of Orthopaedic Surgery, Yokohama City University Medical Center, Yokohama, Kanagawa, Japan

2 Department of Orthopaedic Surgery, Yokohama City University, Yokohama, Kanagawa, Japan

*Address all correspondence to: naomik58@aol.com

IntechOpen

© 2019 The Author(s). Licensee IntechOpen. This chapter is distributed under the terms of the Creative Commons Attribution License (<http://creativecommons.org/licenses/by/3.0>), which permits unrestricted use, distribution, and reproduction in any medium, provided the original work is properly cited. 

References

- [1] Bedi A, Dolan M, Magennis E, Lipman J, Buly R, Kelly BT. Computer-assisted modeling of osseous impingement and resection in femoroacetabular impingement. *Arthroscopy: The Journal of Arthroscopic & Related Surgery*. 2012;**28**(2):204-210
- [2] Kobayashi N, Inaba Y, Kubota S, Nakamura S, Tezuka T, Yukizawa Y, et al. The distribution of impingement region in cam-type femoroacetabular impingement and borderline dysplasia of the hip with or without cam deformity: A computer simulation study. *Arthroscopy: The Journal of Arthroscopic & Related Surgery* [Internet]. 2017;**33**(2):329-334. DOI: 10.1016/j.arthro.2016.08.018
- [3] Oishi T, Kobayashi N, Inaba Y, Choe H, Tezuka T, Kubota S, et al. The relationship between the location of uptake on positron emission tomography/computed tomography and the impingement point by computer simulation in femoroacetabular impingement syndrome with cam morphology. *Arthroscopy: The Journal of Arthroscopic & Related Surgery*. 2018;**34**(4):1253-1261
- [4] Maquer G, Bürki A, Nuss K, Zysset PK, Tannast M. Head-neck osteoplasty has minor effect on the strength of an ovine cam-FAI model: In vitro and finite element analyses. *Clinical Orthopaedics and Related Research*. 2016;**474**(12):2633-2640
- [5] Ross JR, Larson CM, Adeoyo O, Kelly BT, Bedi A. Residual deformity is the most common reason for revision hip arthroscopy: A three-dimensional CT study. *Clinical Orthopaedics and Related Research*. 2015;**473**(4):1388-1395
- [6] Kubota S, Inaba Y, Kobayashi N, Choe H, Tezuka T, Saito T. Comparison of improved range of motion between cam-type femoroacetabular impingement and borderline developmental dysplasia of the hip-evaluation by virtual osteochondroplasty using computer simulation. *BMC Musculoskeletal Disorders*. 2017;**18**(1):3-9
- [7] Kobayashi N, Inaba Y, Kubota S, Higashihira S, Choe H, Ike H, et al. Computer-assisted hip arthroscopic surgery for femoroacetabular impingement. *Arthroscopy Techniques* [Internet]. 2018;**7**(4):e397-e403. DOI: 10.1016/j.eats.2017.10.013
- [8] Oba M, Kobayashi N, Inaba Y, Choe H, Ike H, Kubota S, et al. Mechanical strength of the proximal femur after arthroscopic osteochondroplasty for femoroacetabular impingement: Finite element analysis and 3-dimensional image analysis. *Arthroscopy: The Journal of Arthroscopic & Related Surgery* [Internet]. 2018;**34**(8):2377-2386. DOI: 10.1016/j.arthro.2018.03.036
- [9] Alonso-Rasgado T, Jimenez-Cruz D, Bailey CG, Mandal P, Board T. Changes in the stress in the femoral head neck junction after osteochondroplasty for hip impingement: A finite element study. *Journal of Orthopaedic Research*. 2012;**30**(12):1999-2006
- [10] Ross JR, Nepple JJ, Philippon MJ, Kelly BT, Larson CM, Bedi A. Effect of changes in pelvic tilt on range of motion to impingement and radiographic parameters of acetabular morphologic characteristics. *The American Journal of Sports Medicine*. 2014;**42**(10):2402-2409
- [11] Oh J-S, Cynn H-S, Won J-H, Kwon O-Y, Yi C-H. Effects of performing an abdominal drawing-in maneuver during prone hip extension exercises on hip and back extensor muscle activity and amount of anterior pelvic tilt. *The Journal of Orthopaedic and Sports Physical Therapy*. 2007;**37**(6):320-324