

# We are IntechOpen, the world's leading publisher of Open Access books Built by scientists, for scientists

## 4,800

Open access books available

## 122,000

International authors and editors

## 135M

Downloads

Our authors are among the

## 154

Countries delivered to

## TOP 1%

most cited scientists

## 12.2%

Contributors from top 500 universities



WEB OF SCIENCE™

Selection of our books indexed in the Book Citation Index  
in Web of Science™ Core Collection (BKCI)

Interested in publishing with us?  
Contact [book.department@intechopen.com](mailto:book.department@intechopen.com)

Numbers displayed above are based on latest data collected.

For more information visit [www.intechopen.com](http://www.intechopen.com)



# The Effects of Maxillomandibular Advancement and Genioglossus Advancement on Sleep Quality

*Takako Sato, Ryota Nakamura, Akio Himejima,  
Akemi Kusano, Serim Kang, Saori Ohtani,  
Kentarou Yamada, Kanako Yamagata,  
Hiroaki Azaki, Junya Aoki, Keiichi Yanagawa,  
Keiji Shinozuka, Takeya Yamada and  
Morio Tonogi*

## Abstract

Maxillomandibular advancement (MMA) using a standardized surgical procedure consisting of a LeFort I osteotomy and bilateral sagittal split ramus osteotomy and genioglossus advancement (GA) using a genioplasty improve airway volume, oxygen desaturation, and the AHI in patients with OSA. However, there are few reports on changes in sleep quality following MMA and GA. We assessed the effects of MMA and GA on sleep quality by comparing oxygen desaturation, AHI, and sleep architecture before and after surgery. Methods: Eight patients underwent polysomnography (PSG) and CT scan before and after surgery. Conclusions: Our study finds that %TST and %REM were both increased, while %S1 and NA both decreased. Based on these results, it appears that both the quality and quantity of sleep were improved. MMA and GA improve sleep respiratory disturbance and can also improve sleep quality.

**Keywords:** maxillomandibular advancement, sleep quality, genioplasty, respiratory disturbance

## 1. Introduction

Obstructive sleep apnea (OSA) is a disorder characterized by intermittent and recurrent episodes of partial or complete upper airway obstruction during sleep. Obesity, a narrow nasopharynx and oropharynx, large soft palate, large tonsils, large tongue, tongue retroposition, micrognathia, mandibular retrognathia, and maxillary retrusion can all cause upper airway obstruction [1–8].

Maxillomandibular advancement (MMA) and genioglossus advancement (GA) improve airway volume, oxygen desaturation, and the apnea-hypopnea index (AHI) in patients with OSA. However, there are few reports on changes in sleep quality and architecture following MMA and GA [9]. Therefore, we assessed the

effects of MMA and GA on sleep quality by comparing oxygen desaturation, AHI, and sleep architecture before and after MMA and GA.

## **2. Materials and methods**

Nine OSA patients who had MMA and GA underwent polysomnography (PSG) before and after surgery, which was assessed using the same scoring criteria. One subject was excluded because computed tomography (CT) data were not collected, neither before nor after surgery. Our study included a total of eight subjects (six males and two females). The average age and body mass index (BMI) of the participants were  $43.75 \pm 8.17$  years and  $21.8 \pm 1.8$  kg/m<sup>2</sup>, respectively.

### **2.1 Surgical procedure**

All patients underwent MMA using a standardized surgical procedure consisting of a LeFort I osteotomy and bilateral sagittal split ramus osteotomy and GA using a genioplasty to pull the genioglossus and geniohyoid muscles. The amount of maxillary advancement was routinely set at a minimum of 5 mm or more in consideration for unavoidable change in facial appearance. The mandibular jaw was advanced to match the maxilla, to restore the preoperative jaw relationship. The average amount of mandibular advancement was 13.2 mm. The average amount of skeletal advancement in GA was 6.3 mm. All patients were informed regarding the study protocol and provided consent.

### **2.2 Morphological evaluation**

The lateral cephalometric radiograph were taken and calculated with manual hand-tracing.

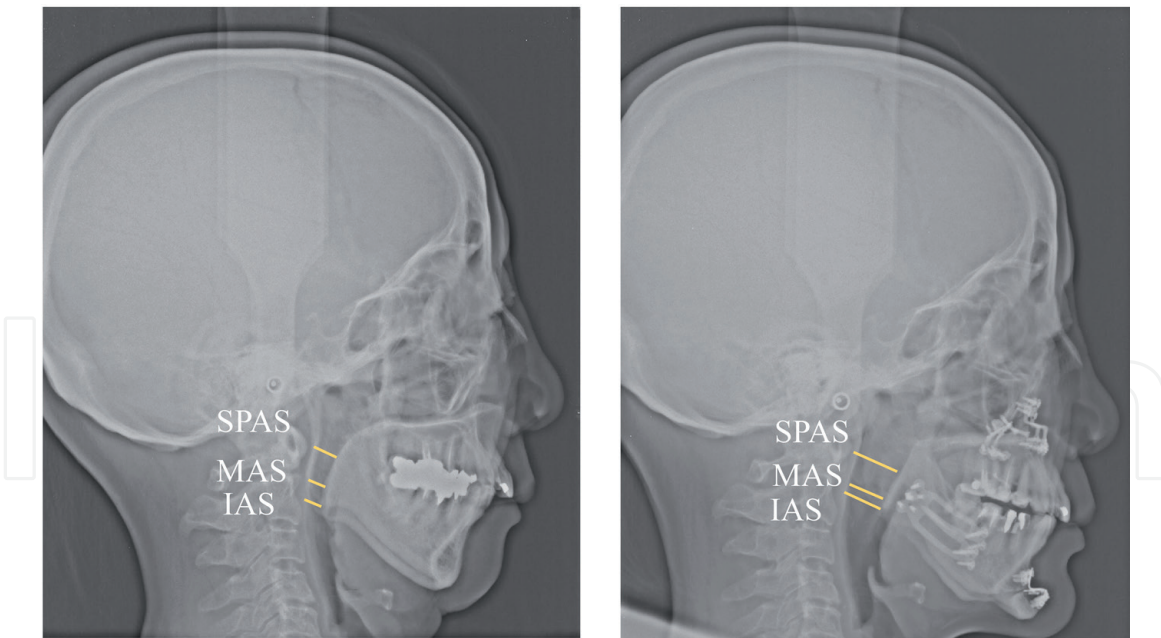
The CT evaluation (1-mm slices) was performed with the aid of an Asteion device (TSX-021B/4; Toshiba, Tokyo, Japan), before and at 1 year after surgery. For standard reproducibility the patient was placed in the supine position, with the head and neck positioned on a pillow to maintain the Frankfurt plane at right angles to the floor. CT scans were performed during inspiration at rest, without swallowing. The upper airway area was measured in three regions: the superior posterior airway space (SPAS), which is the airway region at the midpoint between the inferior tip of the soft palate (P point) and the posterior nasal spine (PNS) point, parallel to the line from the gonion point to the point at the deepest midline concavity on the mandibular alveolus between the infradentale and pogonion (B point) (GO-B line); the middle airway space (MAS), which is the airway region on the P point parallel to the GO-B line; and the inferior airway space (IAS), which is the airway region on the GO-B line [10] (**Figures 1, 2**).

The volume between PNS and Eb was also measured (**Figure 3**).

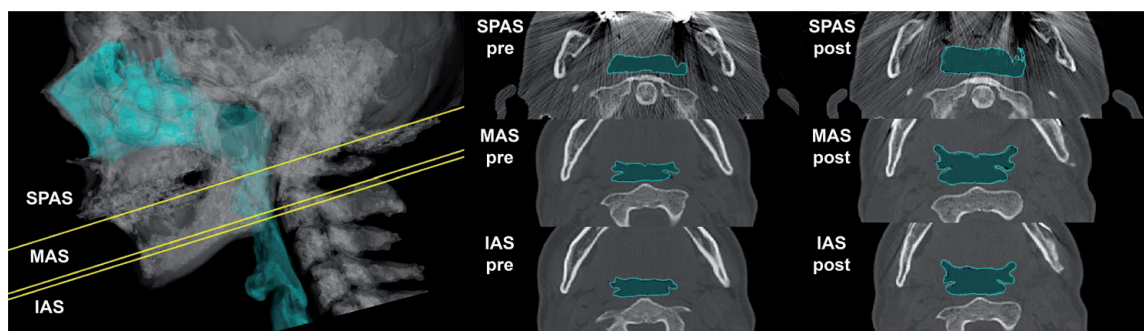
All data analyses were performed using Mimics software (Materialize, Leuven, Belgium).

### **2.3 Physiological evaluation (polysomnography)**

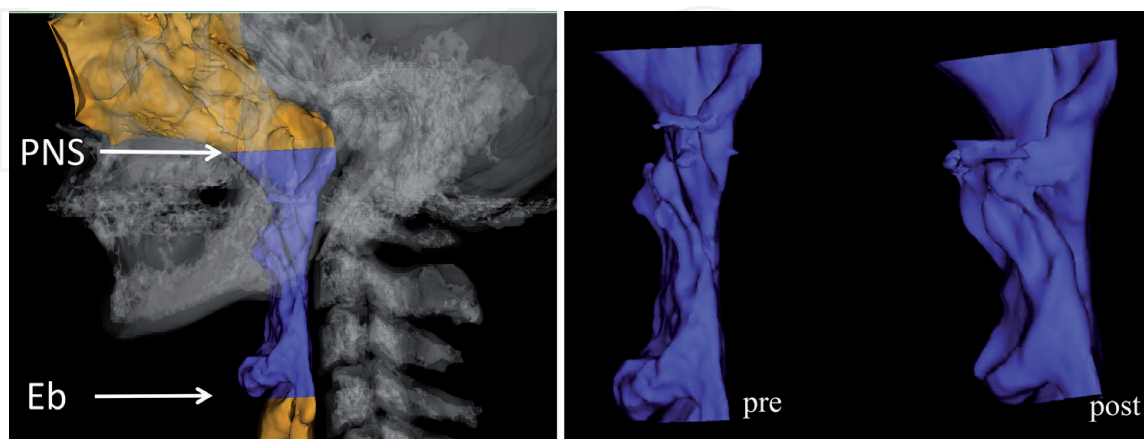
Polysomnographic recordings were performed before and within 1 year after surgery. We used a 16-channel PSG instrument (Alice 5; Philips Respironics, Murrysville, PA, USA) with continuous monitoring performed by a technician.



**Figure 1.** Scheme of each of the measurement regions (anteroposterior dimension). SPAS, superior posterior airway space; MAS: Middle airway space; IAS: Inferior airway space.



**Figure 2.** Scheme of each of the measurement regions (cross-sectional area). SPAS, Superior posterior airway space; MAS, Middle airway space; IAS, Inferior airway space.



**Figure 3.** Scheme of the measurement regions (volume). PNS, Posterior nasal spine; Eb, Epiglottal base.

The measures taken included electroencephalography (EEG), electrooculogram (EOG), electromyogram (EMG), electrocardiogram (ECG), snore, thermocouple airflow, nasal pressure, chest and abdominal movement, pulse oximetry, and body

position. Polysomnographic analyses were performed according to the American Academy of Sleep Medicine guidelines. Apnea was defined as complete cessation of airflow for more than 10 seconds. Hypopnea was defined as a decrease in airflow of 90% or more from the baseline, as measured by an oronasal thermistor for at least 10 seconds, a 30% or greater reduction in respiratory airflow lasting for more than 10 seconds, or at least a 3% decrease in oxygen saturation ( $SpO_2$ ) from the pre-event baseline. The 3% oxygen desaturation index (ODI) represents the average number of times per hour that the blood oxygen level drops by 3% from the baseline during sleep [9].

Arousal was defined as a sudden change in EEG frequency. We collected data on AHI, apnea index (AI), hypopnea index (HI), 3% ODI, lowest  $SpO_2$ , percentage at which  $SpO_2$  was  $<90\%$  of TST ( $\%SpO_2 < 90\%$ ), total sleep time (TST), sleep efficiency (SE: TST/time in bed [TIB]), number of awakenings (NA), percentage of nonrapid eye movement sleep stage 1 (NREM1) of TST ( $\%S1$ ), percentage of NREM2 of TST ( $\%S2$ ), percentage of NREM3 of TST ( $\%S3$ ), percentage of rapid eye movement (REM) sleep of TST ( $\%REM$ ), wakefulness after sleep onset (WASO), WASO as a proportion of sleep period time (SPT) ( $\%WASO$ ), sleep latency, and REM latency.

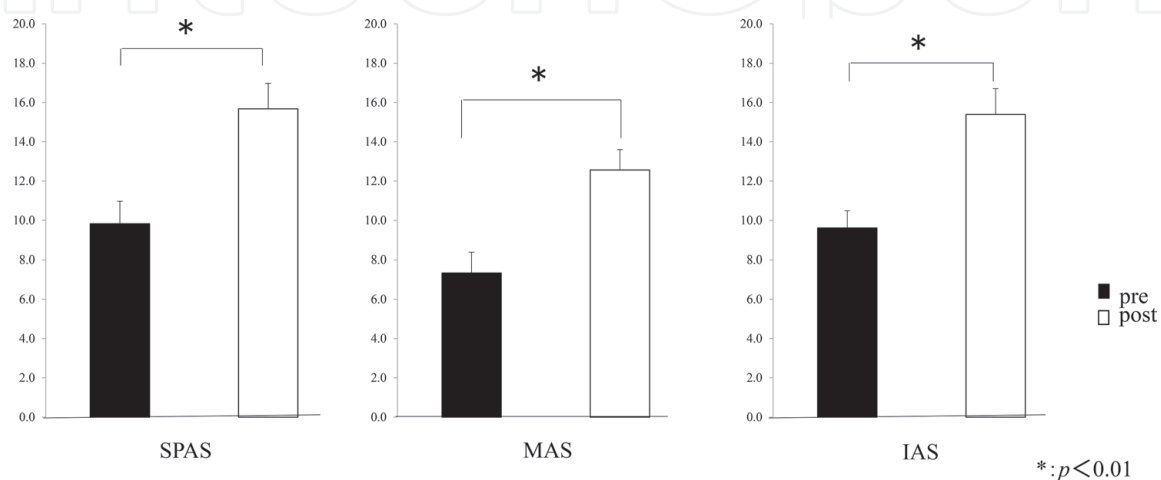
All data were analyzed using the Wilcoxon t-test, with a value of  $p < 0.05$  considered statistically significant.

### 3. Results

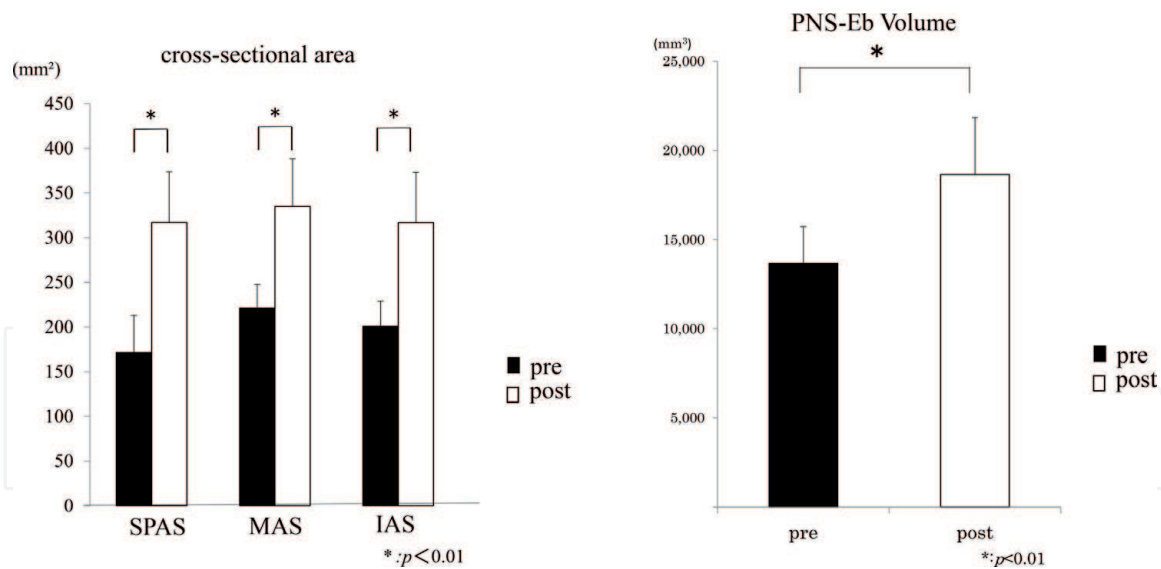
#### 3.1 Change in the airway before versus after MMA and GA

The mean anteroposterior dimension of the SPAS, MAS, and IAS increased from  $9.8 \pm 3.24$ ,  $7.3 \pm 2.93$ , and  $9.6 \pm 2.47$  to  $15.7 \pm 3.67$  ( $p < 0.005$ ),  $12.6 \pm 2.94$  ( $p < 0.005$ ), and  $15.4 \pm 3.73$  ( $p < 0.005$ ), respectively (Figure 4).

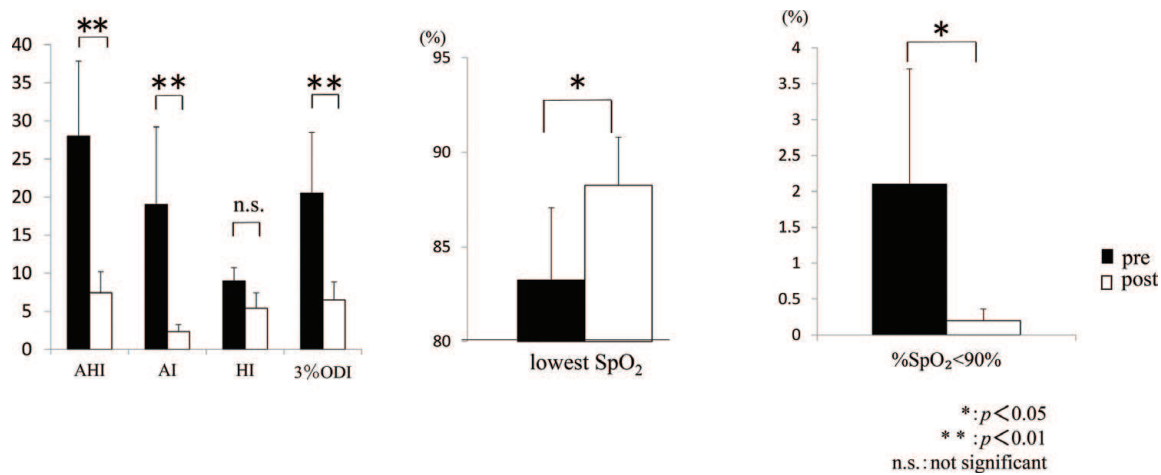
The mean cross-sectional area of the SPAS, MAS, and IAS increased from  $171.3 \pm 104.6$ ,  $221.3 \pm 66.6$ , and  $200.9 \pm 70.2$  to  $317.1 \pm 141.7$  ( $p < 0.005$ ),  $335.0 \pm 132.8$  ( $p < 0.01$ ), and  $316.9 \pm 140.4$  ( $p < 0.01$ ), respectively. The mean enlargement factor of SPAS, MAS, and IAS was  $213.0 \pm 70.6\%$ ,  $152.1 \pm 47.3\%$ , and  $160.9 \pm 54.8\%$ , respectively. The mean volume between PNS and Eb increased from  $13664.2 \pm 5458.6$  to  $18647.0 \pm 8456.0$  ( $p < 0.01$ ). The mean volume expansion rate was  $136.5 \pm 30.2\%$  ( $p < 0.01$ ) (Figure 5).



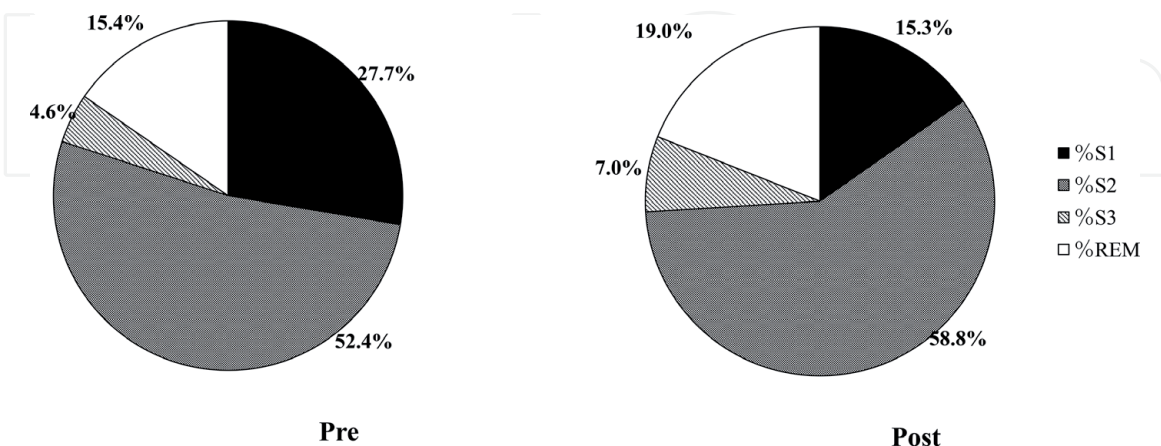
**Figure 4.** Change in each anteroposterior dimension of airway before and after MMA and GA.



**Figure 5.**  
 Change in each cross-sectional area and volume of airway before and after MMA and GA.



**Figure 6.**  
 Change in polysomnography parameter before and after MMA and GA (sleep-disordered breathing).



**Figure 7.**  
 Change in polysomnography parameter before and after MMA and GA (sleep stage).

### 3.2 Changes in PSG parameters in subjects before versus after MMA and GA

The mean AHI decreased from  $28.0 \pm 24.6$  to  $7.4 \pm 6.9$  events/hour ( $p < 0.005$ ), the AI decreased from  $19.0 \pm 25.4$  to  $2.3 \pm 2.4$  ( $p < 0.008$ ), the

ODI decreased from  $20.5 \pm 19.9$  to  $6.5 \pm 5.9$  ( $p < 0.008$ ), and the  $\%SpO_2 < 90\%$  decreased from  $2.1 \pm 4.0$  to  $0.2 \pm 0.4$  ( $p < 0.02$ ), while the mean lowest  $SpO_2$  increased from  $83.3 \pm 9.5\%$  to  $88.3 \pm 6.4\%$  ( $p < 0.02$ ) (**Figure 6**).

The mean SE increased from  $81.2 \pm 12.8$  to  $86.2 \pm 7.7$  ( $p < 0.03$ ), and  $\%REM$  increased from  $15.4 \pm 5.7\%$  to  $19.0 \pm 3.6\%$  ( $p < 0.02$ ); meanwhile, the mean  $\%S1$  and NA decreased from  $27.7 \pm 21.2\%$  to  $15.3 \pm 7.6\%$  ( $p < 0.01$ ) and  $184.7 \pm 108.4$  to  $119.5 \pm 40.7$  ( $p < 0.008$ ), respectively (**Figure 7**).

#### 4. Discussion

In this study, we divided airway space into retropalatal and retroglossal spaces: SPAS and MAS corresponded to retropalatal, while IAS corresponded to retroglossal. We found an increase in anteroposterior dimension and cross-sectional area of both the retropalatal and retroglossal spaces following MMA and GA, consistent with previous studies. The volume of airway space was also increased.

The retropalatal space is influenced by the position of the maxilla, soft palate, and tonsils, while the retroglossal space is influenced by the mandibular position and glossal shape and position [11–13]. The soft palate is comprised of the musculus uvulae, tensor veli palatini, levator veli palatini, and palatoglossus. The former three muscles are attached to the maxilla, while the latter is attached to the mandible. The genioglossus and geniohyoid muscles are attached to the mental spine and hyoid bone [14]. Airway enlargement is primarily caused by elevation of the tissues attached to the jaw and hyoid bone. Therefore, the most effective surgical approach to resolve this issue is to move both the upper and lower jaw.

Surgical success of MMA is defined as an AHI with less than 20 events/hour or an AHI showing a greater than 50% reduction after surgery. Meanwhile, surgical cure is defined as an AHI with less than five events/hour following surgery [15].

In this study, all patients were in the surgical success category, and 50% of patients were also classified as surgical cure.

The ODI and  $\%SpO_2 < 90\%$  both decreased, while the lowest  $SpO_2$  increased; these results are consistent with previous reports [16]. These findings indicate that although achieving complete cure is difficult, MMA remains an effective method for treating sleep-disordered breathing. Furthermore, improvements in the lowest  $SpO_2$  and  $\%SpO_2 < 90\%$  levels prevent the development of oxygen-desaturation-related diseases. A number of previous studies demonstrated that hypoxia-induced oxidative stress, sympathetic activation, and inflammatory responses increase the long-term risk of multiple comorbidities, including hypertension, heart attack, stroke, and diabetes [17–22].

The sleep architecture was also altered after MMA. There is currently no consensus on how “better sleep” should be quantitatively and qualitatively defined [9]. However, some researchers have suggested that decreased SE, TST, and percentage of slow-wave sleep (SWS) of TST ( $\%SWS$ ) and increased WASO are indicators of poor sleep quality [23–25]. Others believe that improved sleep quality is reflected by the increases in  $\%REM$  and  $\%SWS$ , based on prior CPAP treatment data [26]. Our study did not find any decrease in WASO. However, TST and  $\%REM$  were both increased, while  $\%S1$  and NA both decreased. Furthermore, there is no significant difference, but SWS tends to increase. Based on these results, it appears that both the quality and quantity of sleep were improved.

OSA interrupts the normal sleep cycle: REM sleep disappears or becomes irregular, while SWS disappears. In our study, some subjects exhibited a REM pattern similar to that of healthy subjects, while in others no therapeutic effect of MMA was observed, despite sufficient airway expansion. Given the small number of subjects

in our study, it was not possible to identify factors affecting the therapeutic efficacy. However, the most common causative factors of OSA include poor upper airway anatomy (collapsibility), weak upper airway dilator muscle responsiveness, a low respiratory arousal threshold, and an unstable ventilatory control system (loop gain) [27–30]. Taken together, we consider that oxygen inhalation and sleeping medication, for example, may prove therapeutic for patients with symptoms not improved by surgical intervention alone.

MMA and GA cannot provide equal effect for every patient. The airway expansion is affected by the amount of jaw movement. However, even if the airway expansion is made bigger, it does not necessarily improve the quality of sleep. So, I must further explore other factors involved in affecting sleep quality.

## **5. Conclusion**

MMA and GA can increase the anteroposterior dimension, cross-sectional area, and volume of the retropalatal and retroglottal spaces, consistent with previous studies.

MMA and GA may be able to improve not only sleep respiratory disturbance but also improve sleep quality.

## **Acknowledgements**

This study was supported by the Sato Fund, Nihon University School of Dentistry; a grant from the Dental Research Center, Nihon University School of Dentistry; and the Uemura Fund, Nihon University School of Dentistry.

Data herein have been previously applied to Nichidai Shigaku (in Japanese) by Ryota Nakamura.

## **Conflict of interest**

The authors declare no conflict of interest.

## **Ethical approval**

This study was performed with the approval of the Ethics Committee of Nihon University School of Dentistry.

## **Informed consent**

Informed consent was obtained from all individual participants included in the study.



# IntechOpen

## Author details

Takako Sato<sup>1\*</sup>, Ryota Nakamura<sup>1</sup>, Akio Himejima<sup>1</sup>, Akemi Kusano<sup>1</sup>, Serim Kang<sup>1</sup>, Saori Ohtani<sup>1</sup>, Kentarou Yamada<sup>1</sup>, Kanako Yamagata<sup>1</sup>, Hiroaki Azaki<sup>1</sup>, Junya Aoki<sup>1</sup>, Keiichi Yanagawa<sup>1</sup>, Keiji Shinozuka<sup>1</sup>, Takeya Yamada<sup>2</sup> and Morio Tonogi<sup>1</sup>

1 Department of Oral and Maxillofacial Surgery, Nihon University School of Dentistry, Tokyo, Japan

2 Hikone Municipal Hospital, Hikone, Japan

\*Address all correspondence to: sato.takako@nihon-u.ac.jp

## IntechOpen

© 2019 The Author(s). Licensee IntechOpen. This chapter is distributed under the terms of the Creative Commons Attribution License (<http://creativecommons.org/licenses/by/3.0>), which permits unrestricted use, distribution, and reproduction in any medium, provided the original work is properly cited. 

## References

- [1] Yagi H, Nakata S, Tsuge H, Yasuma F, Noda A, Morinaga M, et al. Morphological examination of upper airway in obstructive sleep apnea. *Auris Nasus Larynx*. 2009;**36**:444-449
- [2] Hugel DW, Hendricks C. Palate and hypopharynx—Sites of inspiratory narrowing of the upper airway during sleep. *The American Review of Respiratory Disease*. 1988;**138**:1542-1547
- [3] Trudo FJ, Gefter WB, Welch KC, Gupta KB, Maislin G, Schwab RJ. State-related changes in upper airway caliber and surrounding soft-tissue structures in normal subjects. *American Journal of Respiratory and Critical Care Medicine*. 1998;**158**:1259-1270
- [4] Zonato AI, Bittencourt LR, Martinho FL, Junior JF, Gregorio LC, Tufik S. Association of systematic head and neck physical examination with severity of obstructive sleep apnea-hypopnea syndrome. *Laryngoscope*. 2003;**113**:973-980
- [5] Schellenberg JB, Maislin G, Schwab RJ. Physical findings and the risk for obstructive sleep apnea. The importance of oropharyngeal structures. *American Journal of Respiratory and Critical Care Medicine*. 2000;**162**:740-748
- [6] Petrou-Amerikanou C, Belazi MA, Daskalopoulou E, Vlachoyiannis E, Daniilidou NV, Papanayiotou PC. Oral findings in patients with obstructive sleep apnea syndrome. *Quintessence International*. 2005;**36**:293-298
- [7] Tsai WH, Remmers JE, Brant R, Flemons WW, Davies J, Macarthur C. A decision rule for diagnostic testing in obstructive sleep apnea. *American Journal of Respiratory and Critical Care Medicine*. 2003;**167**:1427-1432
- [8] Riley RW, Powell N, Guilleminault C. Current surgical concepts for treating obstructive sleep apnea syndrome. *Journal of Oral and Maxillofacial Surgery*. 1987;**45**:149-157
- [9] Liu SY-C, Huon L-K, Ruoff C, Riley RW, Strohl KP, Peng Z. Restoration of sleep architecture after maxillomandibular advancement: Pp beyond the apnea-hypopnea index. *International Journal of Oral and Maxillofacial Surgery*. 2017;**46**:1533-1538
- [10] Furuhashi A, Yamada S, Shiomi T, Sasanabe R, Aoki Y, Yamada Y, et al. Effective three-dimensional evaluation analysis of upper airway form during oral appliance therapy in patients with obstructive sleep apnoea. *Journal of Oral Rehabilitation*. 2013;**40**:582-589
- [11] Schendel SA, Broujerdi JA, Jacobson RL. Three-dimensional upper-airway changes with maxillomandibular advancement for obstructive sleep apnea treatment. *American Journal of Orthodontics and Dentofacial Orthopedics*. 2014;**146**(3):385-393
- [12] Powell NB, Mihaescu M, Mylavarapu G, Weaver EM, Guilleminault C, Gutmark E. Patterns in pharyngeal airflow associated with sleep-disordered breathing. *Sleep Medicine*. 2011;**12**:966-974
- [13] Stephen S, Powell N, Jacobson R. Maxillary, mandibular, and chin advancement: Treatment planning based on airway anatomy in obstructive sleep apnea. *Journal of Oral and Maxillofacial Surgery*. 2011;**69**:663-676
- [14] Okushi T, Tonogi M, Arisaka T, Kobayashi S, Tsukamoto Y, Morishita H, et al. Effect of maxillomandibular advancement on morphology of velopharyngeal space. *Journal of Oral and Maxillofacial Surgery*. 2011;**69**:877-884

- [15] Sher AE, Schechtman KB, Piccirillo JF. The efficacy of surgical modifications of the upper airway in adults with obstructive sleep apnea syndrome. *Sleep*. 1996;**19**:156-177
- [16] Holty JE, Guilleminault C. Maxillomandibular advancement for the treatment of obstructive sleep apnea: A systematic review and meta-analysis. *Sleep Medicine Reviews*. 2010;**14**:287-297
- [17] Vasu TS, Grewal R, Doghramji K. Obstructive sleep apnea syndrome and perioperative complications: A systematic review of the literature. *Journal of Clinical Sleep Medicine*. 2012;**8**:199-207
- [18] Peppard PE, Young T, Palta M, Skatrud J. Prospective study of the association between sleep-disordered breathing and hypertension. *The New England Journal of Medicine*. 2000;**342**:1378-1384
- [19] Tasali E, Mokhlesi B, Van Cauter E. Obstructive sleep apnea and type 2 diabetes: Interacting epidemics. *Chest*. 2008;**133**:496-506
- [20] Sharma B, Owens R, Malhotra A. Sleep in congestive heart failure. *The Medical Clinics of North America*. 2010;**94**:447-464
- [21] Yaggi HK, Concato J, Kernan WN, Lichtman JH, Brass LM, Mohsenin V. Obstructive sleep apnea as a risk factor for stroke and death. *The New England Journal of Medicine*. 2005;**353**:2034-2041
- [22] Marin JM, Carrizo SJ, Vicente E, Agusti AG. Long-term cardiovascular outcomes in men with obstructive sleep apnoea-hypopnoea with or without treatment with continuous positive airway pressure: An observational study. *Lancet*. 2005;**365**:1046-1053
- [23] Means MK, Edinger JD, Glenn DM, Fins AI. Accuracy of sleep perceptions among insomnia sufferers and normal sleepers. *Sleep Medicine*. 2003;**4**:285-296
- [24] Coaters TJ, Killen JD, George J, Marchini E, Silverman S, Thoresen C. Estimating sleep parameters: A multitrait-multimethod analysis. *Journal of Consulting and Clinical Psychology*. 1982;**50**:345-352
- [25] Perlis ML, Smith MT, Andrews PJ, Orff H, Giles DE. Beta/gamma EEG activity in patients with primary and secondary insomnia. *Journal of Psychosomatic Research*. 2009;**66**:59-65
- [26] Riley RW, Powell NB, Guilleminault C. Maxillofacial surgery and nasal CPAP. A comparison of treatment for obstructive sleep apnea syndrome. *Chest*. 1990;**98**:1421-1425
- [27] Eckert DJ, Owens RL, Kehlmann GB, Wellman A, Rahangdale S, Yim-Yeh S, et al. Eszopiclone increases the respiratory arousal threshold and lowers the apnoea/hypopnoea index in obstructive sleep apnoea patients with a low arousal threshold. *Clinical Science (London)*. 2011;**120**:505-514
- [28] Heinzer RC, White DP, Jordan AS, Lo YL, Dover L, Stevenson K, et al. Trazodone increases arousal threshold in obstructive sleep apnea. *The European Respiratory Journal*. 2008;**31**:1308-1312
- [29] Wellman A, Malhotra A, Jordan AS, Stevenson KE, Gautam S, White DP. Effect of oxygen in obstructive sleep apnea: Role of loop gain. *Respiratory Physiology & Neurobiology*. 2008;**162**:144-151
- [30] Edwards BA, Sands SA, Eckert DJ, White DP, Butler JP, Owens RL, et al. Acetazolamide improves loop gain but not the other physiological traits causing obstructive sleep apnoea. *The Journal of Physiology*. 2012;**590**:1199-1211