

We are IntechOpen, the world's leading publisher of Open Access books Built by scientists, for scientists

4,800

Open access books available

122,000

International authors and editors

135M

Downloads

Our authors are among the

154

Countries delivered to

TOP 1%

most cited scientists

12.2%

Contributors from top 500 universities



WEB OF SCIENCE™

Selection of our books indexed in the Book Citation Index
in Web of Science™ Core Collection (BKCI)

Interested in publishing with us?
Contact book.department@intechopen.com

Numbers displayed above are based on latest data collected.

For more information visit www.intechopen.com



Caesarean Scar Ectopic Pregnancy

Workineh Getaneh Tadesse

Abstract

Caesarean scar ectopic pregnancy (CSEP) is one of the rarest forms of ectopic pregnancy. It is characterised by a gestation implanted in a caesarean section scar and surrounded by the myometrium and the fibrous tissue of the scar. With rising caesarean delivery rates and widespread use of ultrasound in early pregnancy, there is a parallel upward trend in the incidence of CSEP. The most significant risk associated with a CSEP is an early uterine rupture with life-threatening maternal haemorrhage leading to hysterectomy and loss of reproductive potential. An early diagnosis can offer conservative treatment options capable of preserving the uterus. This chapter discusses the clinical presentation, diagnosis and evidence-based treatment options of CSEP.

Keywords: scar ectopic pregnancy, caesarean section, complications of early pregnancy, uterine rupture

1. Introduction

CSEP is one of the rarest forms of ectopic pregnancies [1–5]. However, in the last two to three decades, an increasing number of case reports and case series have been published [4]. CSEP results from the implantation of the embryo in a previous caesarean scar (CS) instead of the endometrial cavity [6]. The pregnancy is surrounded by the myometrium and the fibrous tissue of the scar. It usually manifests with painless vaginal bleeding and often misdiagnosed as spontaneous miscarriage or cervical ectopic pregnancy [1, 4]. A misdiagnosis or a late diagnosis of CSEP can result in early uterine rupture with life-threatening maternal haemorrhage leading to hysterectomy and loss of reproductive potential [6]. Ultrasonography with colour flow Doppler is the primary diagnostic tool in the workup of CSEP [4]. An early diagnosis can offer conservative treatment options that enable the preservation of the uterus [2, 5, 6].

2. Epidemiology

The exact incidence of CSEP is unknown. It is estimated to occur in 0.05–0.4% (1 in 1800 to 1 in 2500) of all pregnancies [1]. A recent publication from the UK's Early Pregnancy Surveillance Service (UKEPSS) reported an estimated incidence of 1.5 per 10,000 maternities [7]. The incidence of CSEP is rising, which is believed to be due to the increasing caesarean delivery rate itself and improved detection rate as a result of widespread use of ultrasonography during early pregnancy [8].

CSEP has been reported in women with only one previous caesarean delivery as well as in those with multiple caesarean deliveries. It is not clear whether the

number of previous caesarean delivery (CD) or the time interval between the CD and subsequent pregnancy affect the incidence of CSEP. Similar to other types of ectopic pregnancies, CSEP has been reported in both spontaneously conceived pregnancy as well as after in vitro fertilisation (IVF) and embryo transfer [9, 10].

3. Pathophysiology

The exact cause and mechanism are not well understood. The most plausible mechanism is that the blastocyst implants into microtubular tracts, which persisted at the site of the caesarean scar as a result of incomplete healing [1]. However, it is not clear if an increase in the number of previous caesarean deliveries or short interval between caesarean delivery and subsequent pregnancy increase the risk of CSEP by way of affecting the healing process at the caesarean scar. Additionally, there is no evidence if uterine closure technique (e.g. single vs. double layer closure) has any effect on the risk of CSEP.

Two types of CSEP have been described [8]. Type I (endogenic type) is characterised by implantation on the CS with progression towards the direction of the endometrial cavity. Type II (exogenic type) CSEP is a deep implantation in the CS defect growing mainly towards the abdominal cavity. Type I CSEP can potentially continue to develop into the endometrial cavity and may even progress to the second and third trimesters. Type II is associated with early uterine rupture or invasion into the urinary bladder [8].

CSEP should be differentiated from placenta accreta or increta, where the pregnancy is intrauterine with an invasion of the trophoblast into the myometrium. In contrast, CSEP is characterised by a gestation separated from the endometrial cavity and surrounded by the myometrium and the fibrous tissue of the scar.

4. Clinical presentation and diagnosis

A large proportion of patients with CSEP are asymptomatic and diagnosed incidentally during a routine first-trimester ultrasound [1, 4]. The most frequent symptom of CSEP is light and painless vaginal bleeding [4, 6]. Some patients may have associated mild to moderate lower abdominal pain. Severe pain with or without haemodynamic instability, may indicate ruptured CSEP. There may be mild lower abdominal or uterine tenderness on palpation; however, clinical examination in stable women is usually unremarkable. The gestational age at diagnosis ranges from 5 to 16 weeks, with an average of 7.5 ± 2.5 weeks [4].

4.1 Investigations

4.1.1 Serum beta – human chorionic gonadotropin (hCG)

Quantitative serum beta-hCG measurement confirms the presence of pregnancy, and also provides a baseline for posttreatment follow up.

4.1.2 Ultrasound

Ultrasonography is the primary diagnostic tool [1, 4, 6]. Transvaginal ultrasound (TVS) has a diagnostic sensitivity of around 85% [1, 4]. There are

proposed ultrasound diagnostic criteria, allowing a differential diagnosis from cervical ectopic pregnancy and miscarriage. These include (1) Empty uterus with clearly visualised endometrium, (2) Empty cervical canal, (3) Gestational sac located within the anterior isthmic portion of the uterus at the presumed site of the CS, (4) Thinned (<5 mm) or absent myometrium between the gestational sac and bladder [5]. Additionally, Doppler colour flow may show distinct circular peritrophoblastic perfusion surrounding the gestational sac (see **Figures 1** and **2**).

The crossover sign (COS) is an ultrasound sign that is proposed to describe the relationship between the gestational sac, the caesarean scar and the anterior uterine wall [12]. In a sagittal view of the uterus a straight line connecting the internal os and the uterine fundus through the endometrium is drawn (endometrial line). The superior–inferior (S-I) diameter of the gestational sac, perpendicular to the endometrial line, is traced (see **Figure 3**).

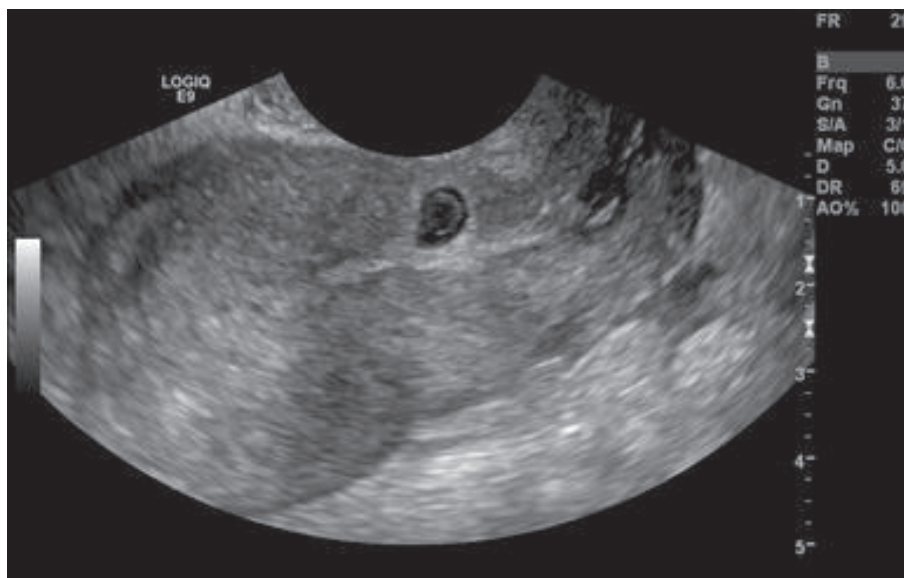


Figure 1.
Transvaginal ultrasound, sagittal view of a gestational sac with a yolk sac within a caesarean scar [11].

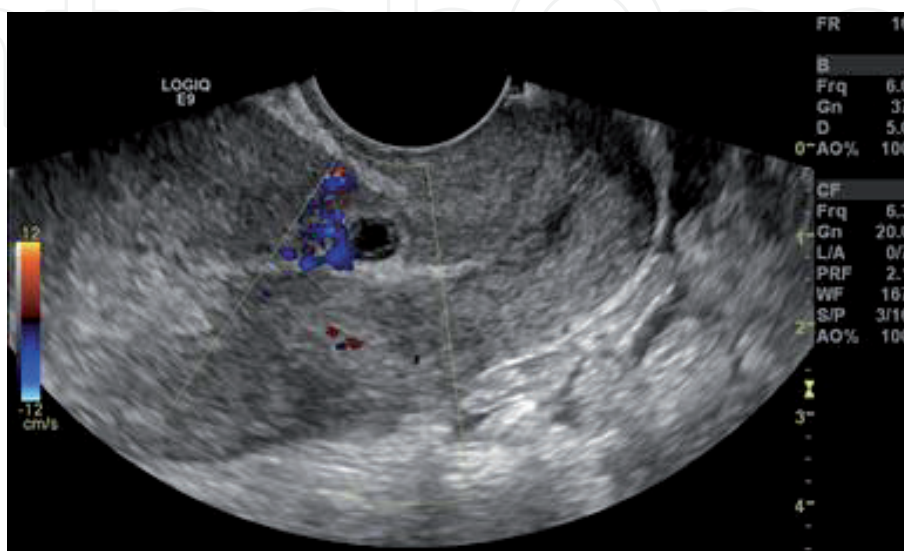


Figure 2.
Transvaginal ultrasound, sagittal view with colour Doppler demonstrating peritrophoblastic perfusion [11].

Patients can be categorised into groups based on the relationship between the endometrial line and the S-I diameter of the gestational sac [12]:

1. Normal - gestational sac implanted away from the caesarean scar and close to the fundus.
2. COS-1 - gestational sac implanted within the caesarean scar and at least two-third of the S-I diameter of the gestational sac is above the endometrial line.
3. COS-2+ – gestational sac implanted within the caesarean scar and less than two-third of the S-I diameter of the gestational sac is above the endometrial line.
4. COS-2– - gestational sac implanted within the caesarean scar and less than two-third of the S-I diameter of the gestational sac is above the endometrial line, but there is no intersection between the S-I diameter and the endometrial line (see **Figure 4**).

This categorisation based on the COS may help to determine the natural progression of CSEP [12].

4.1.3 Magnetic resonance imaging

Magnetic resonance imaging (MRI) is rarely required to clarify the diagnosis of CSEP [1]. Sagittal, coronal and transverse sections of T1- and T2- weighted MRI sequences can clearly show the gestational sac embedded in the anterior lower uterine wall [5] (**Figure 5**). MRI can also help in decision making and pre-operative planning through detailed characterisation of CSEP location, depth of myometrial invasion and presence of bladder involvement [1, 5] (**Figure 6**).

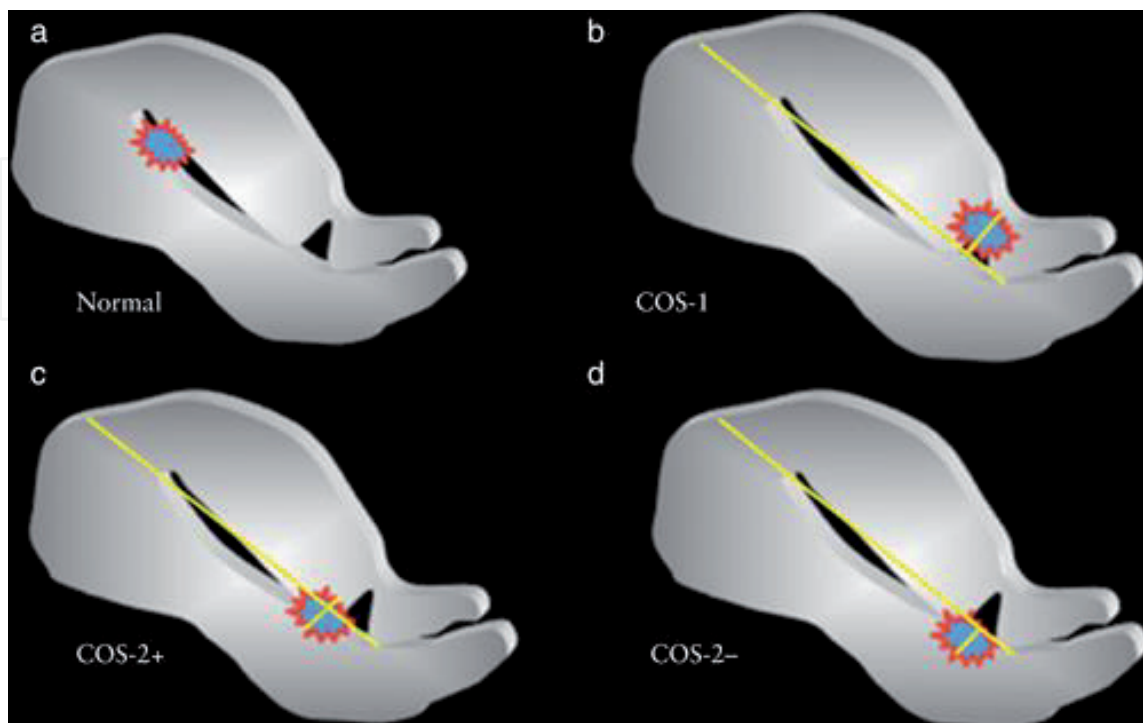


Figure 3. Diagrammatic representation of relationship between gestational sac, caesarean scar and anterior uterine wall, defined as crossover sign (COS) [12]. (a) Normal implantation, (b) COS-1, (c) COS-2+, (d) COS-2-.

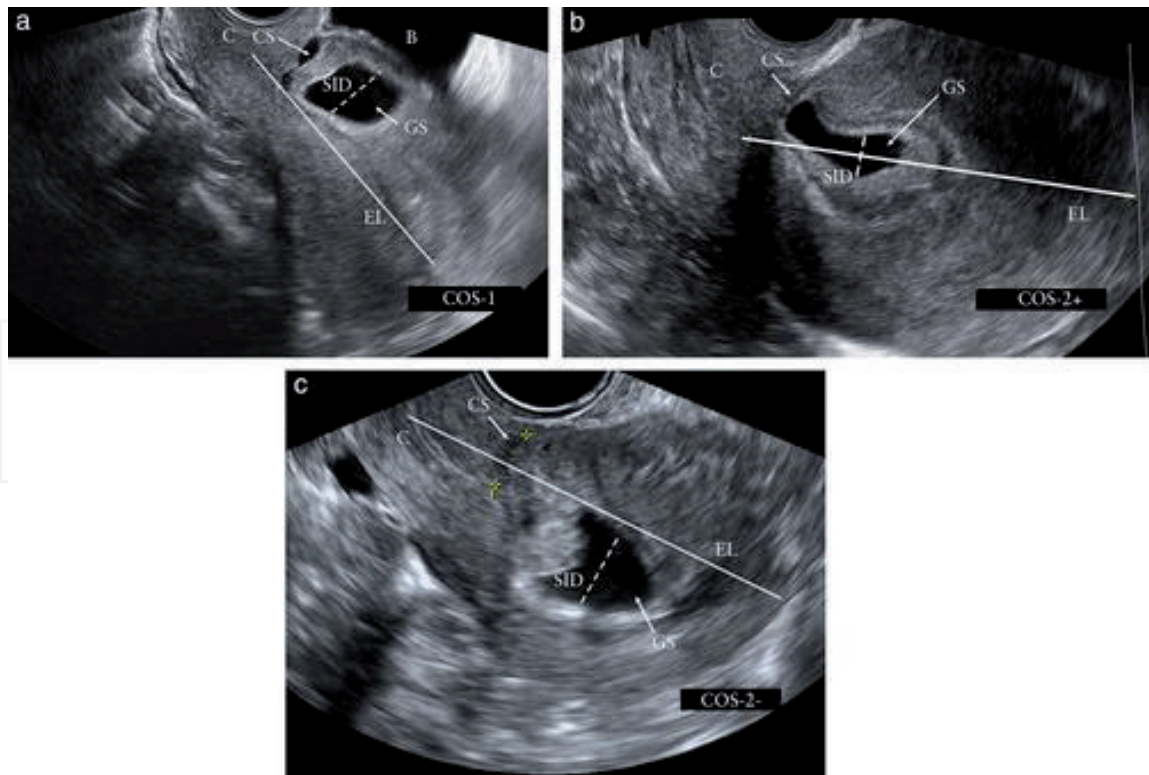


Figure 4.
Ultrasound images of different types of crossover sign (COS): (a) COS-1, (b) COS-2⁺ and (c) COS-2⁻.
B = bladder, C = cervix, CS = caesarean scar, EL = endometrial line, GS = gestational sac, SID = superior-inferior diameter [12].

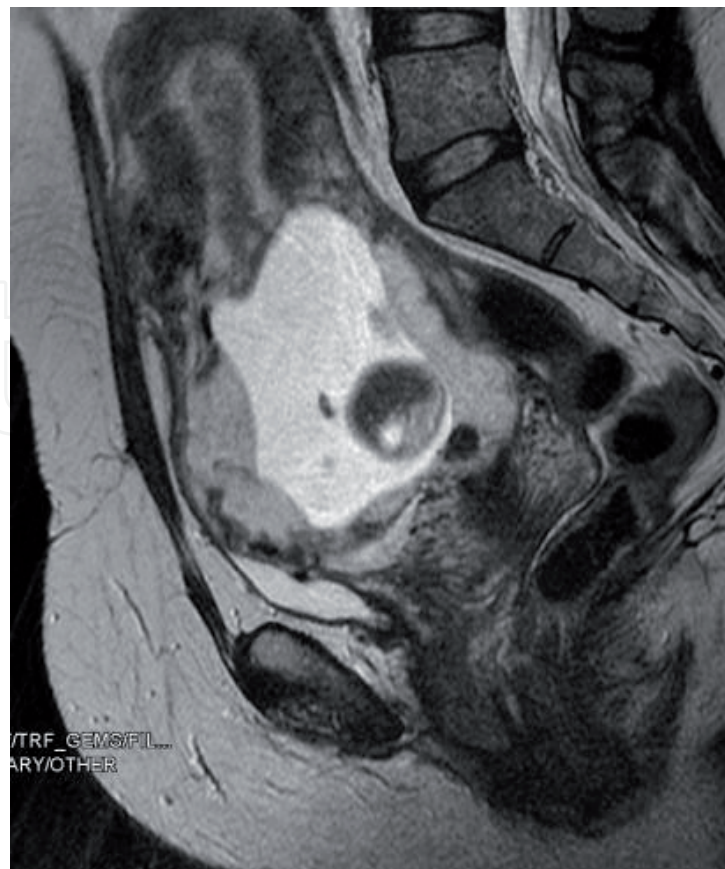

Figure 5.
MRI from a case of a 2nd trimester CSEP (see **Figure 6** for the surgical specimen from the same patient).

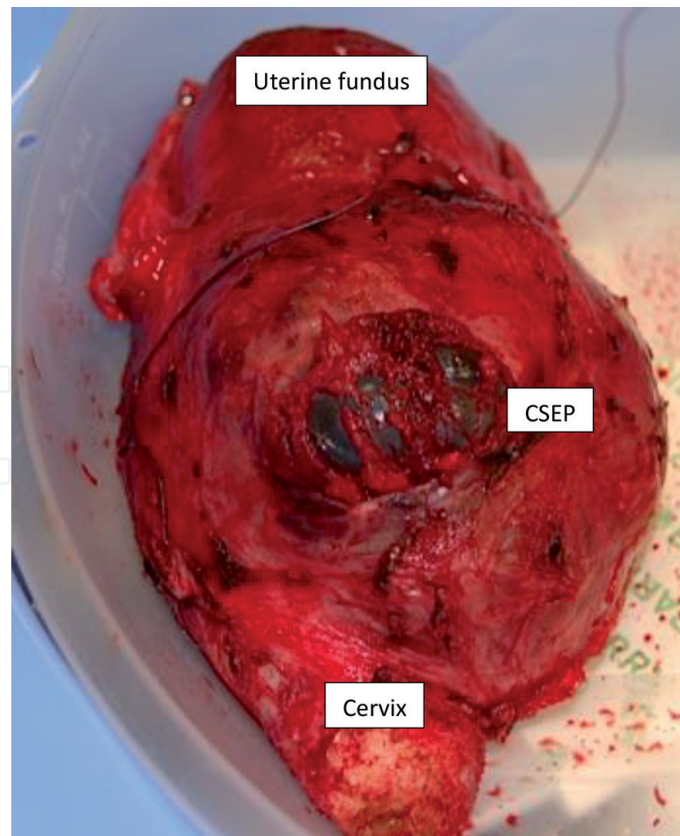


Figure 6. Surgical specimen of a total hysterectomy from a case of a 2nd trimester CSEP. Note the distended lower segment of the uterus with near total absence of myometrium at the previous caesarean scar.

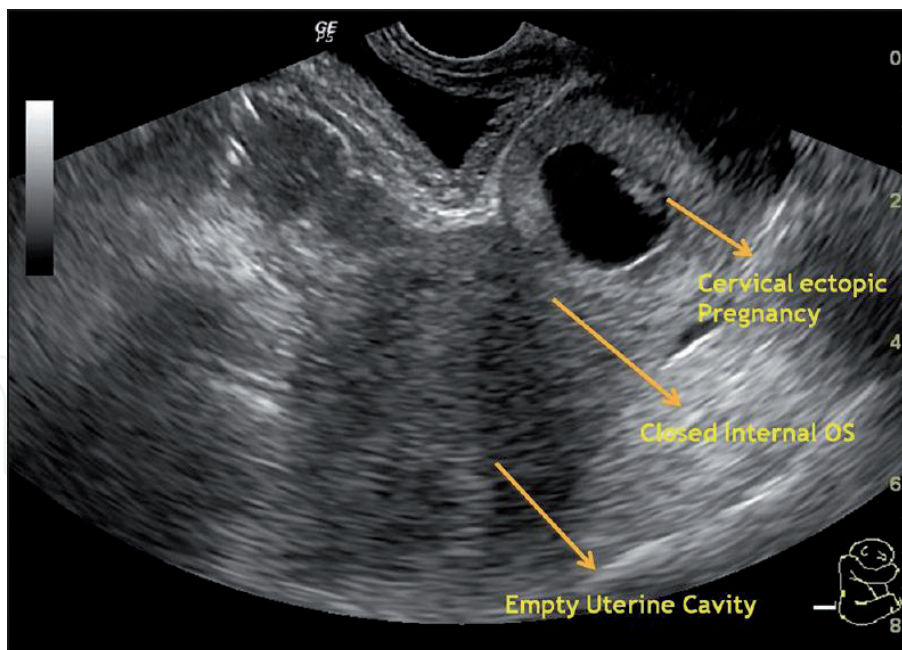


Figure 7. Cervical ectopic pregnancy: Hourglass appearance of the uterus with gestational sac in the intracervical canal [14].

4.2 Differential diagnoses

CSEP can be mistaken for spontaneous miscarriage in progress [11, 13] or cervical ectopic pregnancy [13]. In cervical pregnancy, unlike CSEP, there would be a layer of myometrium visible between the bladder and the gestational sac and bleeding as the presenting symptom is much more substantial [5, 6, 11, 13]. The uterus

is empty with an endometrial stripe, the gestational sac presents predominantly within the cervix, giving an hour-glass shape of the uterus with a ballooned cervical canal (see **Figure 7**) [5, 6, 14]. In case of spontaneous miscarriage in progress, an avascular gestational sac is seen in the cervical canal indicating that it has been detached from its implantation site, in contrast to the well-perfused CSEP located in the anterior lower uterine wall [5, 13]. A significant fall in serum beta-hCG level would also be noticed in a miscarriage.

5. Treatment

Due to the rarity of CSEP, there is no consensus regarding its management. Treatment options discussed here are mostly based on case reports and small case series. In general, there are expectant, medical and surgical options of treatment. Factors influencing the choice of treatment options include the type of the CSEP (Type I or II), haemodynamic stability, size of the pregnancy mass and gestational age, serum beta-hCG level, presence or absence of fetal cardiac activity, wish for future fertility, and availability of expertise (e.g. endoscopic surgery, interventional radiology) [8, 15–17]. A comprehensive review from UKEPSS demonstrates that the success rate of expectant, medical and surgical management were 43, 46 and 96%, respectively [7]. The complication rates were 71% with expectant, 60% with medical and 36% with surgical management [7].

5.1 Expectant management

Even though expectant management of CSEP has been described [2, 3, 15, 18], the safety of continuing pregnancy is questionable. Caution must be exercised when choosing expectant management in cases of viable CSEP as it carries a significant risk of complications, including uterine rupture, severe haemorrhage and hysterectomy [4, 18, 19]. In a systematic review of a total of 56 cases (including 44 cases with fetal cardiac activity) of CSEP managed expectantly, live births were achieved in 73% with a very high hysterectomy rate of 70% [18]. Women with viable CSEP and relatively favourable findings on imaging such as endogenic type, COS-2 on ultrasound and residual myometrial thickness of >5 mm on MRI may continue with the pregnancy if they have a strong desire to do so [19]. Women need to understand that expectant management of a viable CSEP carries a significant risk of severe haemorrhage, uterine rupture, hysterectomy and severe invasive placenta-tion [7, 15, 19]. Expectant management can be considered in those with no fetal cardiac activity and with evidence of spontaneous resolution [18–20].

5.2 Medical management

5.2.1 Methotrexate

Methotrexate (MTX) can be administered locally or systemically as single or multiple doses. Primary systemic treatment with MTX is indicated in patients with non-viable CSEP. CSEPs have been shown to respond well to systemic administration of MTX (50 mg/m²), especially in those with low serum beta-hCG levels (<5000 mIU/ml). Like in tubal ectopic pregnancy, MTX is appropriate for a woman who is pain-free and hemodynamically stable with unruptured pregnancy of <8 weeks' gestation. While a single dose treatment may be adequate for cases with low serum beta-hCG levels (<5000 mIU/ml), multiple doses may be necessary in those with high beta-hCG levels.

Methotrexate can also be given directly into the gestational sac. Local MTX administration is preferable in cases with viable CSEP. Ramkrishna et al. have described their medical management protocol [21]. They use ultrasound guided intra-sac injection of 50 mg of MTX into the gestational sac using 18G chorionic villus sampling needle after aspirating the content of the sac. Prior injection of 2 ml (30 mmol/ml) KCL is used when fetal cardiac activity is present [21]. Additional dose(s) of systemic MTX is used for those cases with plateaued serum hCG level. The success rate of primary medical management (systemic/local) was 86% for CSEP in their study subjects [21].

There is a suggestion that direct injection of MTX into the sac achieves a high concentration locally and therefore interrupts the pregnancy more rapidly than a systemic administration of the drug [22]. The local injection can be done under ultrasound guidance (transabdominal or transvaginal), or direct vision through laparoscopy or hysteroscopy. A larger gauge needle is preferable to ensure better aspiration of the content of the gestational sac at the same time.

A high dose of intravenous MTX infusion, followed by oral folinic acid rescues, has also been used with a success rate of 85.7% [23].

5.2.2 Local embryocidal injection

Local injection of potassium chloride (or other embryocides- e.g. lignocaine [1]) can be used when there is fetal cardiac activity, or for selective embryocidal action in cases of heterotopic pregnancies [10, 24]. Similar to local MTX injection, this can be done under ultrasound guidance (transabdominal or transvaginal), or direct vision through laparoscopy or hysteroscopy followed by local or systemic MTX.

5.3 Surgical treatment

Several surgical treatment options are described.

5.3.1 Uterine curettage

By definition, the gestational mass in a CSEP is not actually within the uterine cavity. Therefore, not only the trophoblastic tissue is inaccessible by the curettage but also such attempts can potentially rupture the uterine scar leading to severe haemorrhage and cause more harm [4]. A recently published meta-analysis suggested favourable outcomes (less blood loss, lower incidence of adverse events and shorter duration of hospital stay) following high-intensity focused ultrasound compared to uterine artery embolization before uterine curettage [25]. In a case-control study, advanced gestational age, higher serum hCG level, bigger gestational sac diameter, thinner myometrial layer and significant peritrophoblastic perfusion were associated with excessive intra-operative haemorrhage (≥ 200 ml) during suction evacuation of CSEP [26].

5.3.2 Hysteroscopy or laparoscopy

Aspiration/resection of gestational contents can be accomplished either through operative hysteroscopy or laparoscopy [27–29]. The choice between laparoscopy and hysteroscopy depends on the type of CSEP. The hysteroscopic approach is more appropriate for CSEP that grows inward towards the uterine cavity (Type I), while a laparoscopy is more justified for a deeply implanted CSEP growing towards the abdominal cavity (type II).

5.3.3 Laparotomy

Wedge resection of the gestation (hysterotomy) or hysterectomy should be considered in women who do not respond to conservative medical or surgical treatments, present too late or if facilities and expertise for operative endoscopy are not available. Laparotomy is mandatory when uterine rupture is confirmed or strongly suspected.

5.4 Uterine artery embolization

Uterine artery embolization (UAE) in combination with other treatment modalities such as MTX, dilatation and curettage (D & C) or hysteroscopic resection has been used to treat CSEP [15, 30]. Catheterisation of the uterine arteries is carried out through a transfemoral approach under local anaesthesia. If embolization is combined with a dose of MTX it is split between the two uterine arteries and infused via the arterial catheter. Finally, both uterine arteries are embolized with gelatin sponge particles or polyvinyl alcohol [15].

In a systematic review, UAE combined with D & C was highly effective with only 6.4% of cases needed additional treatment and severe complications (haemorrhage, hysterectomy) occurred in 3.4% of cases [15]. A combination of UAE, D & C and hysteroscopy also resulted in a high success rate of 95.4% and a very low complication rate of 1.2%. In women treated with a combination of UAE, D & C and MTX, additional treatment was needed in 31.4% because of treatment failure and hysterectomy rate was 2.8%. In comparison, between one-fourth to one-third of patient treated primarily with MTX required additional treatment [15].

5.5 Combination

In reality, most cases of CSEP are managed with a combination of both medical and surgical approaches [31]. Medical treatment - systemic or local, single agent or combined regiment can be used in conjunction with surgical treatment options. e.g.

- Ultrasound-guided sac aspiration, local MTX injection with or without local potassium chloride (KCL) [32]
- Local intra-sac KCL injection, systemic MTX injection [33, 34].
- Ultrasound/laparoscopic guide sac aspiration, local MTX injection, systemic MTX injection [16, 35]
- Systemic MTX, local KCL injection, laparoscopic resection [36]
- Intra-sac injection of KCL and MTX, systemic MTX, laparoscopic resection [37]
- Systemic MTX, dilatation and curettage [38, 39]
- UAE and intra-arterial MTX infusion [40]

Uterine artery embolization, bilateral uterine artery ligation, local vasopressin injection and intrauterine balloon tamponade have been used successfully as an adjunct to other conservative treatments for the prevention and control of heavy bleeding.

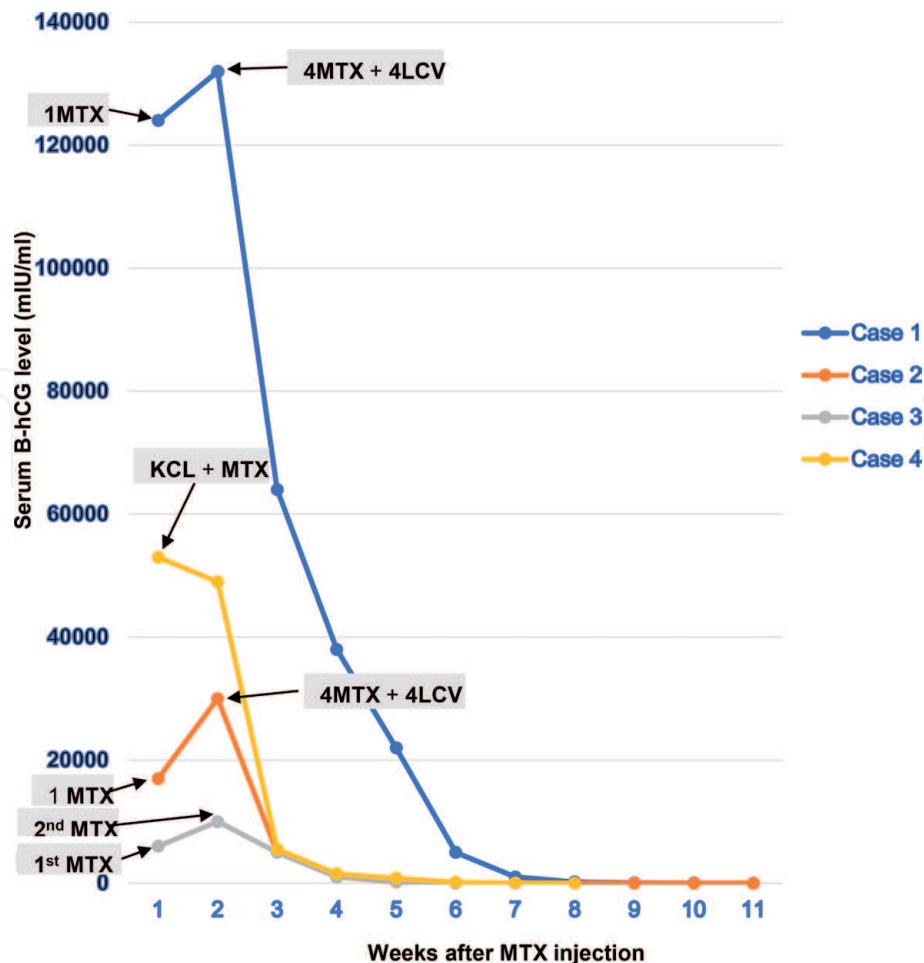


Figure 8. Changes in weekly serum beta-hCG levels of four patients with CSEP before and after the medical treatment. The values on the curve represent the beta-hCG measurements at each given week. MTX = methotrexate; LCV = Leucovorin; KCl = potassium chloride [42].

5.6 Post-treatment follow-up

Close follow up is essential to confirm complete resolution of the CSEP. Patients need serial serum beta-hCG measurements and pelvic ultrasound until the hCG level is undetectable, and the pregnancy mass disappears, which may take several weeks (see **Figure 8**) [34, 41]. In general, posttreatment weekly measurement of serum beta-hCG is required to confirm resolution [42, 43]. Patients who have undergone hysterectomy do not require hCG monitoring. Serial transvaginal colour flow Doppler is useful for monitoring the response to medical treatment. It is worth to note that uterine rupture and severe maternal haemorrhage can occur despite a satisfactory drop in serum hCG levels [1]. Continuation of fetal cardiac activity or growth of the sac with rising serum hCG concentration indicates failure of medical treatment. In a tubal ectopic pregnancy, a higher failure rate of medical treatment is associated with a gestational age of ≥ 9 weeks, a fetal pole of >10 mm, presence of fetal cardiac activity and a serum beta-hCG concentration $> 10,000$ mIU/ml. However, no similar or consistent pattern could be observed for a CSEP.

6. Recurrence and management of subsequent pregnancies

The risk of recurrence in subsequent pregnancies is unknown. Uneventful viable intrauterine pregnancies have been reported after all modalities of conservative management of CSEP [34, 44]. Additionally, there are case reports whereby

patients had one or more episodes of recurrence of CSEP [44–46]. Owing to insufficient data, patients should be counselled about this uncertain risk of recurrence, and like patients with other types of ectopic pregnancies, they should be advised to avail of an early ultrasound examination in subsequent pregnancies to localise the pregnancy. Likewise, no reliable statistics exist on the safe interval between successfully treated CSEP and subsequent pregnancy. In the absence of other obstetric indication for repeat caesarean delivery, women who are pregnant following successful treatment of CSEP can consider delivering vaginally.

7. Conclusion

CSEP is a rare form of ectopic pregnancy but potentially associated with severe maternal complications. The incidence of CSEP is rising owing to the rise in caesarean delivery rate worldwide and widespread use of imaging in early gestation. Little is known about its exact mechanism and natural history. Ultrasonography with colour flow Doppler yields a high diagnostic accuracy. Recommendations of treatment options for CSEP are based on pieces of evidence from case reports and small case series. Therefore, treatment is individualised according to clinical presentation, availability of treatment options and expertise as well as the wish of the woman for future fertility.

Conflict of interest

The authors declare no conflict of interest.

Author details

Workineh Getaneh Tadesse
Coombe Women and Infants University Hospital, Dublin, Republic of Ireland

*Address all correspondence to: wtadesse@coombe.ie

IntechOpen

© 2019 The Author(s). Licensee IntechOpen. This chapter is distributed under the terms of the Creative Commons Attribution License (<http://creativecommons.org/licenses/by/3.0>), which permits unrestricted use, distribution, and reproduction in any medium, provided the original work is properly cited. 

References

- [1] Odgers HL, Taylor RA, Balendran J, Benness C, Ludlow J. Rupture of a caesarean scar ectopic pregnancy: A case report. *Case Reports in Women's Health*. 2019;**22**:e00120. DOI: 10.1016/j.crwh.2019.e00120
- [2] Jayaram PM, Okunoye GO, Konje J. Caesarean scar ectopic pregnancy: Diagnostic challenges and management options. *Obstetrics and Gynecology*. 2017;**19**:13-20
- [3] Elson CJ, Salim R, Potdar N, Chetty M, Ross JA, Kirk EJ. Diagnosis and management of ectopic pregnancy. *BJOG: An International Journal of Obstetrics & Gynaecology*. 2016;**123**:e15-e55. DOI: 10.1111/1471-0528.14189
- [4] Rotas MA, Haberman S, Levigur M. Caesarean scar ectopic pregnancies: Aetiology, diagnosis, and management. *Obstetrics and Gynecology*. 2006;**107**:1373-1381
- [5] Osborn DA, Williams TR, Craig BM. Cesarean scar pregnancy. *Journal of Ultrasound in Medicine*. 2012;**31**:1449-1456
- [6] Deepika GT, Wahi S. A rare case report of caesarean scar ectopic pregnancy. *Journal of Clinical and Diagnostic Research*. 2017;**11**(8):QD10-QD11. DOI: 10.7860/JCDR/2017/24611.10523
- [7] Harb HM, Knight M, Bottomley C, Overton C, Tobias A, Gallos ID, et al. Caesarean scar pregnancy in the UK: A national cohort study. *BJOG: An International Journal of Obstetrics and Gynaecology*. 2018;**125**(13):1663-1670. DOI: 10.1111/1471-0528.15255
- [8] Gonzalez N, Tulandi T. Cesarean scar pregnancy: A systematic review. *Journal of Minimally Invasive Gynecology*. 2017;**24**:731-738
- [9] Ouyang Y, Li X, Yi Y, Gong F, Lin G, Lu G. First-trimester diagnosis and management of caesarean scar pregnancies after in vitro fertilisation - embryo transfer: A retrospective clinical analysis of 12 cases. *Reproductive Biology and Endocrinology*. 2015;**13**:126. DOI: 10.1186/s12958-015-0120-2
- [10] Litwicka K, Greco E, Prefumo F, Fratelli N, Scarselli F, Ferrero S, et al. Successful management of a triplet heterotopic caesarean scar pregnancy after in vitro fertilisation-embryo transfer. *Fertility and Sterility*. 2011;**95**(1):291.e1-291.e3
- [11] Kim DJ, Welch M, Kendall JL. A case of cesarean scar ectopic: A rare but important form of ectopic pregnancy. *Critical Ultrasound Journal*. 2011;**3**(1):55-57. DOI: 10.1007/s13089-011-0064-5
- [12] Cali G, Forlani F, Timor-Tritsch IE, Palacios-Jaraquemade J, Minneci G, D'Antonio F. Natural history of caesarean scar pregnancy on prenatal ultrasound: The crossover sign. *Ultrasound in Obstetrics & Gynecology*. 2017;**50**(1):100-104
- [13] Collins K, Kothari A. Catastrophic consequences of caesarean scar pregnancy missed on ultrasound. *Australasian Journal of Ultrasound in Medicine*. 2015;**18**(4):150-156. DOI: 10.1002/j.2205-0140.2015.tb00222.x
- [14] Samal SK, Rathod S. Cervical ectopic pregnancy. *Journal of Natural Science, Biology and Medicine*. 2015;**6**:257-260
- [15] Petersen KB, Hoffmann E, Larsen CR, Nielsen HS. Caesarean scar pregnancy: A systematic review of treatment studies. *Fertility and Sterility*. 2016;**105**:958-967
- [16] Tadesse WG, Von Bunau G. A combination of surgery and

methotrexate for successful treatment of a caesarean scar pregnancy. *Irish Medical Journal*. 2018;**111**(6):774

[17] Tahaoglu AE, Dogan Y, Bakir MS, Peker N, Cavus Y, Togrul C, et al. A single centre's experience of caesarean scar pregnancy and proposal of a management algorithm. *Journal of Obstetrics and Gynaecology*. 2019;**39**(2):259-264. DOI: 10.1080/01443615.2018.1499714

[18] Jayaram P, Okunoye G, Al Ibrahim AA, Ghani R, Kalache K. Expectant management of caesarean scar ectopic pregnancy: A systematic review. *Journal of Perinatal Medicine*. 2018;**46**(4):365-372. DOI: 10.1515/jpm-2017-0189

[19] Cali G, Timor-Tritsch IE, Palacios-Jaraquemada J, Monteaugudo A, Buca D, Forlani F, et al. Outcome of cesarean scar pregnancy managed expectantly: Systematic review and meta-analysis. *Ultrasound in Obstetrics & Gynecology*. 2018;**51**(2):169-175

[20] Jabeen K, Karuppaswamy J. Non-surgical management of caesarean scar ectopic pregnancy - a five-year experience. *Journal of Obstetrics and Gynaecology*. 2018;**38**(8):1121-1127. DOI: 10.1080/01443615.2018.1451986

[21] Ramkrishna J, Kan GR, Reidy KL, Ang WC, Palma-Dias R. Comparison of management regimens following ultrasound diagnosis of non-tubal ectopic pregnancies: A retrospective cohort study. *BJOG: An International Journal of Obstetrics & Gynaecology*. 2018;**125**:567-575

[22] Uludag SZ, Kutuk MS, Ak M, Ozgun MT, Dolanbay M, Aygen EM, et al. Comparison of systemic and local methotrexate treatments in caesarean scar pregnancies: Time to change conventional treatment and follow-up protocols. *European*

Journal of Obstetrics, Gynecology, and Reproductive Biology. 2016;**206**:131-135

[23] Tanaka K, Coghill E, Ballard E, Sekar R, Amoako A, Khalil A, et al. Management of caesarean scar pregnancy with high dose intravenous methotrexate infusion therapy: 10-year experience at a single tertiary centre. *European Journal of Obstetrics, Gynecology, and Reproductive Biology*. 2019;**237**:28-32. DOI: 10.1016/j.ejogrb.2019.04.008

[24] Paoletti D. A heterotopic pregnancy involving a caesarean section scar. *Australasian Journal of Ultrasound in Medicine*. 2011;**14**(3):34-35

[25] Xiao X, Feng Z, Li T, Zhang S, Wang W. Comparing the efficacy and safety of high-intensity focused ultrasound and uterine artery embolisation in caesarean scar pregnancy: A meta-analysis. *Advances in Therapy*. 2019;**36**(6):1314-1325. DOI: 10.1007/s12325-019-00959-w

[26] Wang Q, Ma H, Peng H, He L, Bian C, Zhao X. Risk factors for intra-operative haemorrhage and bleeding risk scoring system for caesarean scar pregnancy: A case-control study. *European Journal of Obstetrics, Gynecology, and Reproductive Biology*. 2015;**195**:141-145. DOI: 10.1016/j.ejogrb.2015.06.023

[27] Fuchs N, Manoucheri E, Verbaan M, Einarsson JI. Laparoscopic management of extrauterine pregnancy in caesarean section scar: Description of a surgical technique and review of the literature. *BJOG: An International Journal of Obstetrics and Gynaecology*. 2015;**122**(1):137-140

[28] He M, Chen MH, Xie HZ, Yao SZ, Zhu B, Feng LP, et al. Transvaginal removal of ectopic pregnancy tissue and repair of uterine defect for caesarean scar pregnancy. *BJOG: An International Journal of Obstetrics and Gynaecology*. 2011;**118**(9):1136-1139

- [29] Yang Q, Piao S, Wang G, Wang Y, Liu C. Hysteroscopic surgery of ectopic pregnancy in the caesarean section scar. *Journal of Minimally Invasive Gynecology*. 2009;**16**(4):432-436
- [30] Maheux-Lacroix S, Li F, Bujold E, Nesbitt-Hawes E, Deans R, Abbott J. Caesarean scar pregnancy: As systematic review of treatment options. *Journal of Minimally Invasive Gynecology*. 2017;**24**(6):915-925
- [31] Alalade AO, Smith FJE, Kendall CE, Odejinmi F. Evidence-based management of non-tubal ectopic pregnancies. *Journal of Obstetrics and Gynaecology*. 2017;**37**(8):982-991. DOI: 10.1080/01443615.2017.1323852
- [32] Tanigaki S, Nagata C, Ueno K, Ozawa N, Nagaoka S, Tanaka K, et al. Successful treatment of caesarean scar pregnancies by local treatment only. *Obstetrics and Gynecology International*. 2017;**2017**:9543570. DOI: 10.1155/2017/9543570
- [33] Gupta M, Kriplani A, Mahey R, Kriplani I. Successful management of caesarean scar live ectopic pregnancies with local KCL and systemic methotrexate. *BML Case Reports* 2017; 2017.pii: bcr-2017-221844. doi: 10.1136/bcr-2017-221844
- [34] Piejani R, Bayani L, Shirazi M. Successful local and systemic medical treatment of caesarean scar pregnancy and a subsequent term pregnancy after treatment: A case series. *Iranian Journal of Reproductive Medicine*. 2015;**13**(7):445-450
- [35] Seow KM, Wang PH, Huang LW, Hwang JL. Transvaginal sono-guided aspiration of gestational sac concurrent with a local methotrexate injection for the treatment of unruptured caesarean scar pregnancy. *Archives of Gynecology and Obstetrics*. 2013;**288**(2):361-366
- [36] Mahgoub S, Gabriele V, Faller E, Langer B, Wattiez A, Lecointre L, et.al. Caesarean scar ectopic pregnancy: Laparoscopic resection and total scar dehiscence repair. *Journal of Minimally Invasive Gynecology* 2018; **25**(2): 297-298
- [37] Ades A, Parghi S. Laparoscopic resection of caesarean scar ectopic pregnancy. *Journal of Minimally Invasive Gynecology*. 2017;**24**(4):533-535
- [38] Mahapatro AK, Shankar K, Varma T. Caesarean scar ectopic pregnancy: Reports of two cases. *Journal of Clinical and Diagnostic Research*. 2016;**10**(5):QD05-QD06
- [39] Datta S, Jha C. Suction evacuation with methotrexate as a successful treatment modality for caesarean scar pregnancies: Case series. *Sultan Qaboos University Medical Journal*. 2015;**15**(4):e539-e545. DOI: 10.18295/squmj.2015.15.04.017
- [40] Elmokadem AH, Abdel-Wahad RM, El-Zayadi AA, Elrakhawy MM. Uterine artery embolisation and methotrexate infusion as sole management of caesarean scar and cervical ectopic pregnancies: A single- centre experience and literature review. *Canadian Association of Radiologists Journal* 2019; pii: S0846-5371(18)30210-9. doi: 10.1016/j.carj.2018.12.002
- [41] Ko JK, Li RH, Cheung VY. Caesarean scar pregnancy: A 10-year experience. *The Australian & New Zealand Journal of Obstetrics & Gynaecology*. 2015;**55**(1):64-69. DOI: 10.1111/ajo.12273
- [42] Boza A, Boza B, Api M. Cesarean scar pregnancy managed with conservative treatment. *Iranian Journal of Medical Sciences*. 2016;**41**(5):450-455
- [43] Qian ZD, Weng Y, Du YJ, Wang CF, Huang LL. Management of persistent caesarean scar pregnancy after curettage

treatment failure. *BMC Pregnancy and Childbirth*. 2017;**17**(1):208. DOI: 10.1186/s12884-017-1395-4

[44] Gao L, Huang Z, Zhang X, Zhou N, Huang X, Wang X. Reproductive outcomes following cesarean scar pregnancy - a case series and review of the literature. *European Journal of Obstetrics, Gynecology, and Reproductive Biology*. 2016;**200**:102-107

[45] Holland MG, Bienstock JL. Recurrent ectopic pregnancy in a cesarean scar. *Obstetrics and Gynecology*. 2008;**111**(2 Pt 2):541-545

[46] Bennett TA, Morgan J, Timor-Tritsch IE, Dolin C, Dziadosz M, Tsai M. Fifth recurrent cesarean scar pregnancy: Observations of a case and historical perspective. *Ultrasound in Obstetrics & Gynecology*. 2017;**50**(5):658-660

IntechOpen