

We are IntechOpen, the world's leading publisher of Open Access books Built by scientists, for scientists

4,800

Open access books available

122,000

International authors and editors

135M

Downloads

Our authors are among the

154

Countries delivered to

TOP 1%

most cited scientists

12.2%

Contributors from top 500 universities



WEB OF SCIENCE™

Selection of our books indexed in the Book Citation Index
in Web of Science™ Core Collection (BKCI)

Interested in publishing with us?
Contact book.department@intechopen.com

Numbers displayed above are based on latest data collected.

For more information visit www.intechopen.com



Can Orofacial Structures Affect Tooth Morphology?

*Amanda Valentim, Renata Furlan, Mariana Amaral
and Fernanda Martins*

Abstract

This chapter presents how orofacial muscles can affect teeth positioning, occlusion, and also the size/shape of teeth. Pressures exerted on teeth will be discussed in specific cases such as mouth breathing, chronic mastication disorders, oral habits, like thumb sucking or tongue thrust, and also when there is hyperfunction of masticatory muscles during sleep or wakefulness. In these situations, the imbalance of muscle forces brings undesirable consequences to the dentition. Each condition will be explained, showing which muscle is affected, how it changes, and what consequences to the teeth it brings. It is a chapter that shows how close the relationship is between dentistry and speech language pathology (orofacial myology).

Keywords: tooth, malocclusion, tongue, lip, cheek, bruxism, mastication

1. Introduction

Malocclusions are generally considered alterations in the normal field of craniofacial growth and morphology. Due to its different possibilities of etiological factors, it is often difficult to determine its specific cause [1].

There are four main structures that can cause malocclusions: the craniofacial skeleton, the teeth, the orofacial neuromuscular system, and other soft tissues. An example of how the musculature can generate malocclusion is the constantly open mandible in the mouth breathing leading to a constant anteriority of the tongue, which may force the incisors or prevent the eruption of the mandibular incisors [1]. Another example is that if a patient has a tongue with anterior posture during rest, the duration of this pressure, even if very light, may interfere with the eruption process or move the anterior teeth, resulting in an open bite [2]. There are also environmental influences, such as oral habits and balance between the orofacial musculature and the teeth, both at rest and during the functions [3]. Mouth breathing is one of these conditions. It causes muscle posture alteration that changes the balance in the oral cavity and modifies the forces exerted on teeth and bones, impacting facial growth and tooth positioning.

Other muscles that can influence tooth morphology are masseter and temporalis, which are jaw elevators. When they are active during rest or sleep, it is considered as bruxism, and may cause tooth wear.

2. Orofacial forces on the teeth

The teeth are structures of the stomatognathic system, classified as static [4]. These structures are subject to innumerable forces that balance [5].

There are four main factors responsible for the dental balance: intrinsic forces of the tongue, lips, and cheeks; extrinsic forces such as oral habits or orthodontic appliances; forces of the dental occlusion; and forces of the periodontal membrane, as for example, the eruption of teeth. Among these, the most important are the resting position of tongue and lips, in addition to the periodontal forces, since they have a long duration [1]. When one of these forces stands out, tooth movement occurs, and the teeth are susceptible to adaptations when subjected to some pressure or force [4].

The balance between the pressure of the tongue, lip, and cheek contributes to the maintenance of the teeth in their positions. The forces exerted by these structures are lighter than those of the masticatory function, but longer in duration. Even though the magnitude of force is low, it can cause a movement in the teeth when applied for a sufficient amount of time [6, 7].

The final position of the tooth, responsible for final shape of the dental arches, results from the balance between the perioral musculature represented by the mechanism of the buccinator and the intraoral pressure exerted by the musculature of the tongue [7].

A study of 3041 children [8] found that individuals without myofunctional disorders had significantly fewer malocclusions. In addition, a significantly larger number of children with anterior open bite were observed among those with functional alterations, and also the opposite, children with open bite had more functional disorders. Another study [9] found that children with occlusal alterations presented more myofunctional disorders such as lack of lip seal and altered tongue habitual position, compared to children with normal occlusion.

2.1 Tongue

The tongue is a mobile muscular organ that composes the stomatognathic system and is located on the mouth floor. This structure assists in the functions of chewing, swallowing, sucking, and speaking [10].

Eight pairs of muscles compose the tongue and they can be divided into intrinsic and extrinsic. The muscles denominated intrinsic are responsible for the alteration of their form: longitudinal superior, inferior longitudinal, transverse, and vertical. The extrinsic muscles originate in the proximal bony structures and are responsible for the movements of the tongue: genioglossus, styloglossus, palatoglossus, and hyoglossus [11].

Cheeks, lips, and tongue exert a great influence on the occurrence and persistence of malocclusions. In view of these facts, it is expected that the lingual structure exerts a certain force during its rest. When this structure is improperly positioned, its pressure can reach the teeth and promote inadequate occlusion.

Efforts to answer the question “what factors or combination of factors control physiologic movement of teeth” lead researchers to measure the magnitude of forces exerted by the relaxed tongue in the region of the mandibular canines. The conclusions were that the normal relaxed tongue produces a very low force against the lingual surfaces of the mandibular dentition [12].

One study [13] aimed to verify the force threshold that causes displacement of the maxillary central incisor teeth. Their findings indicated that the forces caused by the orofacial organs can initiate a dental displacement of the incisors.

Thus, gentle pressure, but continuous, exerted by the tongue against the teeth is able to move them, producing negative effects on the occlusion [14]. The resting tongue posture has a long duration, many hours during 1 day, which makes it

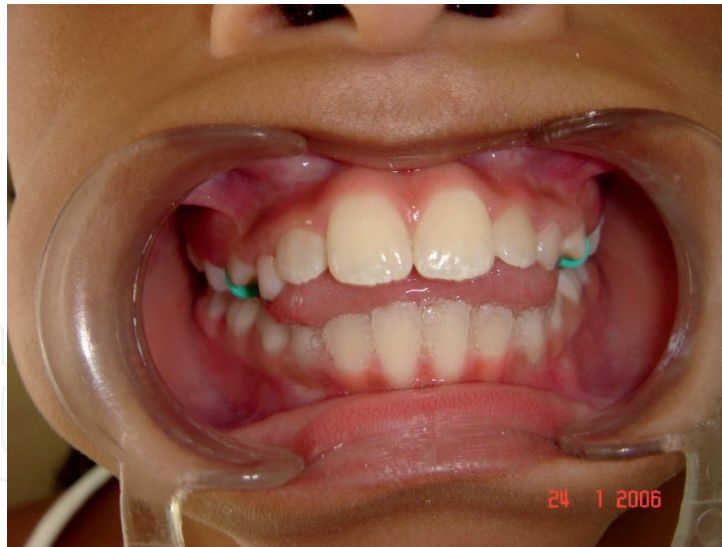

Figure 1.
Tongue rest in anterior position and open bite malocclusion.

clinically important, and can impede eruption of the incisors, causing and maintaining the anterior open bite [2].

Individuals who rest their tongue in anterior position may have the position of the teeth affected (**Figure 1**). On the other hand, the tongue interposition during swallowing has a very short duration to have an impact on dental position. In a typical swallowing, the pressure made by the tongue lasts about 1 second. Normal individuals swallow about 800 times a day when awake, which totals only a few minutes, which would be insufficient to affect the intraoral balance [15].

Furthermore, the low position of the tongue can promote the eruption of the back teeth and cause constriction of the upper arch in the absence of the tongue on the palate [16]. Some authors have confirmed that the inadequate position of the tongue is one of the main causes of the occurrence of oral recurrences with regard to the maintenance of occlusal stability [2, 17, 18].

Many clinicians feel that pressures exerted by tongue prevent teeth from erupting in patients with open bite malocclusion. This view amounts to an extension of the equilibrium theory to the vertical plane of space [19]. Lower lip resting pressure affects more the position of the upper incisors rather than the upper lip (**Figure 2**). In some studies, high lip line was shown as the reason behind the retroclined position of the upper incisors, while in others, the hyperactive lip or mentalis muscle were shown as the reason [20].

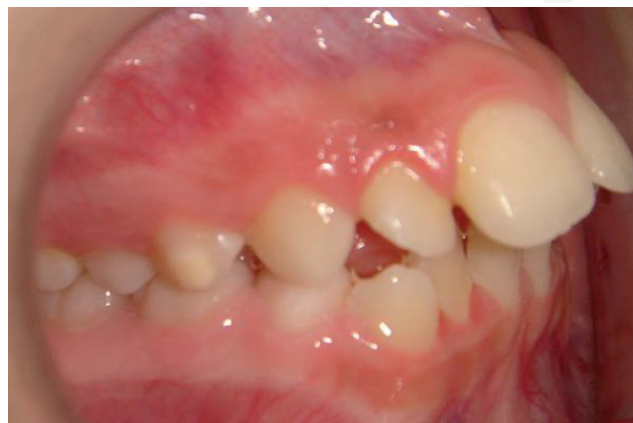

Figure 2.
Teeth position influenced by lower lip.

To test the hypothesis that an imbalance in buccolingual pressure plays a role in dental compensation of the molars and asymmetry in the mandibular dental arch, researchers [21] compared the pressure of cheek and tongue between the shifted and nonshifted side in 12 individuals with facial asymmetry. Asymmetry was defined as 4 mm or more deviation of the midline in the mandibular incisors. The results showed that regardless of the side, there were significant negative correlations between the buccolingual position of the mandibular first molars and cheek pressure and significant positive correlations between the buccolingual position of the first molars and tongue/cheek pressure ratio.

A study [22] compared a group of individuals with anterior open bite who did only orthodontic treatment and another group who did orthodontic treatment and orofacial myofunctional therapy. This therapy exercises the muscles and promotes modification on orofacial functions. They observed that participants who only did orthodontic treatment presented more occlusion recurrence compared to those who also did therapy. This finding indicates that when the form is altered, often the function will also be and that the correction of the former will not necessarily lead to the adequacy of the latter.

3. Different types of tooth have specific function on mastication

The teeth are structures that together with the gums, the tongue, the palate, the palatine tonsils, and the oral cavity form the oral region. Teeth have many different functions, like:

- cutting, reducing, and mixing food with saliva during mastication;
- helping their own support in the dental alveoli, assisting the development and protection of the tissues that sustain them; and
- participating as an articulator in speech [23].

Humans have two generations of teeth, the deciduous (primary) dentition and the permanent (secondary) dentition. There are 20 teeth in the deciduous dentition with 10 in each jaw. There are 32 teeth in the permanent dentition with 16 in each jaw [23].

The characteristics of teeth define their functions in the oral cavity. The incisors have fine cutting margins, the canines have single prominent cusps, the premolars have two cusps and molars have three or more cusps [23].

Humans have four maxillary incisors and four mandibular incisors, two central and two lateral in each jaw. The mandibular incisors are very similar in form and are usually smaller than the maxillary incisors. The incisors cut food, aid in articulation of speech, and support the upper lip [24].

There are four canines, one left and one right in each jaw. They are located at the corners of the dental arch and are often referred to as fangs. They are the longest of all permanent teeth from root to crown tip and usually have a single long root. The canines are the teeth responsible for cutting and piercing food and they also help to guide the jaws to occlude correctly, therefore protecting the posterior teeth from horizontal forces. They also play a role in preventing the appearance of premature aging by supporting the lips and facial muscles [24].

There are four maxillary and four mandibular premolars, two right and two left in each jaw. They only appear in the permanent dentition. Their crowns are shorter (cervico-occlusally) than the anterior tooth and have two cusps. The premolars work along with the molars to grind food and also assist the canines with cutting

and slicing through food. They play a role in preventing the appearance of premature aging by maintaining the vertical dimension of the face and supporting the corners of the mouth and the cheeks [24].

There are six molars in each jaw in the permanent dentition and eight molars in the deciduous dentition, four in each jaw. The molar most anteriorly positioned is designed the “first molar,” the one behind it, the second molar. In the permanent dentition, the tooth most posteriorly positioned is the third molar. The main function of molars is to grind food and maintain the integrity of the dental arch to avoid the other teeth from moving out of alignment. Like premolars, they also play a role in preventing the appearance of premature aging [24].

A literature review [25] concluded that the contraction of the muscles involved in mastication stimulates bone growth. The effect of food consistency on orofacial development suggests that a diet with harder textures is partly responsible for enhancing muscle and bone growth. That can be seen in subjects with thin masseters which generally have longer faces, due to the lack of both bone and muscle volume, while subjects with a thick masseter have a short lower anterior face. According to studies in animals [26, 27] and humans [28], a diet based in liquid and puree consistencies results in a size reduction of masseter and temporal muscles. This theory is supported by an author [29] who suggests that modern, softer foods are responsible for a failing chewing function and the stress on the growth process is often insufficient, causing functional atrophies of masticatory muscles and bone and, consequently, malocclusions.

4. Impact of mouth breathing on the dentition

Nasal breathing is important to ensure a functional environment for the harmonious craniofacial growth [30]. When breathing occurs continuously through the mouth, the craniofacial growth changes its pattern, leading to consequences as high and narrow hard palate, convex facial profile [31], increased vertical facial height [32] and malocclusion. A study carried out on 3017 children verified that mouth breathing is closely related to increased or reduced overjet, anterior or posterior crossbite, open bite, and displacement of contact points [30]. In another study [33] with 401 mouth breathers, posterior crossbite was detected in almost 30% of the sample during primary and mixed dentitions and in 48% in permanent dentition. This prevalence is higher than in the general population [34, 35]. Anterior open bite and Class II malocclusion were also highly prevalent in children during mixed and permanent dentitions [33].

The causes of mouth breathing includes anatomical predisposition and several pathologies, such as palatine and pharyngeal tonsils hypertrophy, septal deviation, allergic rhinitis, and nasal turbinate hypertrophy, among others. The literature showed no association between the type of obstruction and the presence of malocclusion [33] and there seems to be a similar effect on mandibular growth irrespective of the etiology of mouth breathing [32]. However a study verified that children with adenotonsillar hypertrophy have a higher lower posterior facial height than the children with isolated adenoid hypertrophy. An explanation to this fact is that the palatine tonsils, when hypertrophied, could occupy a huge space in the pharynx. Thus, children protruded their mandible in order to breathe better, stimulating the growth of mandible and increasing their lower posterior facial height [32].

Mouth breathing leads to muscle changes including lip incompetence [31, 36, 37]; low position of the tongue in the mouth floor [36, 37]; and lack of force of lips, tongue, and mandibular elevator muscles [31, 36]. The lack of orofacial muscle force and the posture alterations are strictly related. The individual keeps the tongue low

to allow airflow to pass and this habitual posture causes a decrease in tongue tone, which contributes even more to the lower position of the tongue. The same happens with the lips. Postural alterations in soft tissues change the equilibrium of the pressure that they exert on teeth and facial bones, thus altering these structures.

The muscles that depress the jaw to open the mouth exert a backward pressure upon it, which displaces the mandible distally and retards its growth, causing a Class II malocclusion and a skeletal Class II profile with increased overjet. The tongue has an anterior and low position to allow the airflow through the mouth while the buccinator muscles exert pressure on the buccal surface of molars, but there is no pressure of the tongue on the lingual surface, so the maxillary arch and the palate get narrow. There is also lip dysfunction, characterized by shorter upper lip, eversion of lower lip, and hypofunction of both, with no lip sealing, (**Figure 3**), which causes an imbalance especially when tongue exerts a forward pressure on the incisors. The lower lip sometimes forces up under the upper incisor, increasing the overjet [30].

Mouth breathing also impacts the other stomatognathic functions, such as mastication and swallowing, indirectly impairing dentition development. The mouth breather tends to prefer soft food, that is easy to chew. Also, they tend to ingest fluids during mastication in order to help the process. The mastication of the mouth breather has a shorter duration with less masticatory cycles, because of the necessity to liberate the mouth to breathe [38]. Swallowing usually occurs with an atypical pattern, involving tongue protrusion against the incisors or lip interposition which contributes to maintain the overjet [33].

An author [39] pointed out to the irrefutable evidence of a significant genetic influence in many dental and occlusal variables. According to him, phenotype is the result of both genetic and environmental factors. Other authors, who investigated prevalence of malocclusion in mouth breathers, agree with the primary role of heredity in malocclusion in sagittal plane, with mouth breathing as secondary etiological factor to Class II development. According to them, mouth breathers have unbalanced muscular forces, which are not enough to change a strong Class I or III pattern into a Class II. However, some children have genetic tendency to develop a Class II occlusion. These children, depending on environmental stimuli, can become Class I or, if there is a factor like mouth breathing, can develop Class II [33]. In the same way, vertical and transversal dental relationship also has heredity as the major determinant, but environmental factors such as mouth breathing work as secondary causes of anterior open bite or posterior crossbite [33].

Sometimes, changing the breath mode to nasal is not enough to avoid the consequences on occlusion. For this reason, we recommend an early intervention on etiological factors of mouth breathing to prevent the development or worsening of malocclusion.

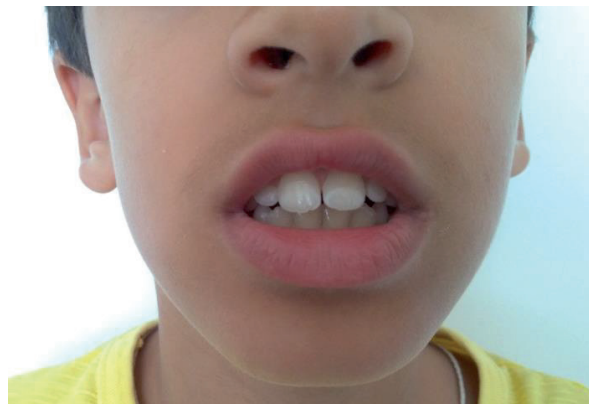

Figure 3.
Mouth breather with abnormal lip function, with no sealing.

5. Impact of oral habits on the dentition

Deleterious oral habits can interfere not only with the position of the teeth, but also with the normal skeletal growth pattern [30]. Pacifier sucking, bottle sucking, finger sucking, nail biting, and tongue thrusting are examples of deleterious oral habits which may result in long-term problems and can affect the stomatognathic system, leading to an imbalance between external and internal muscle forces. The most frequent occlusion alterations caused by oral habits are protrusion of the upper incisors [30], anterior open bite [30, 40], and posterior crossbite [40, 41]. The consequences are dependent on the nature, age of initiation, intensity, frequency and duration of habits, as well as individual biological and genetic features [30].

A study [40] concluded that children with non-nutritive sucking activity and accustomed to using a bottle had more than double the risk of posterior crossbite right from the primary dentition. The low position of the tongue due to sucking, with lack of thrust of the tongue on the palate and increased activity of the muscles of the cheeks, causes an alteration of muscle pressure on the upper arch resulting in the posterior crossbite [40]. Breastfeeding seems to have a protective effect on development of posterior crossbite. A study found a low prevalence of posterior crossbite in breastfed children, even when they have non-nutritive sucking activity [40]. This happens because the mechanism of sucking is different in these two methods of infant feeding. During breastfeeding, lips and tongue apex squeeze the areola where the lactiferous sinuses are located, the tongue compresses the soft breast nipple against the palate using a peristaltic-like motion. In bottle feeding, the tongue acts in a piston-like motion compressing the artificial teat against the palate, with higher force exerted by cheeks [40]. Breastfeeding has also a protective effect on development of artificial sucking habits [41].

Finger sucking generally results in anterior open bite and increased overjet with labial inclination of the upper incisors. The influence of finger sucking on teeth position depends on the position of the finger during the habit. There are two main types of finger sucking (**Figure 4**). The typical type is thumb sucking with the ventral side of the finger facing the palate and maxillary incisors. The thumb acts as a lever, forcing the maxilla forward. The second type, less common, is sucking with the dorsal side of the finger facing upward. In this case, the finger or fingers are passive and the effect is similar to that of the pacifier [42].

The use of pacifier before the teeth have erupted can hinder the full eruption of the primary incisors as well as the growth of the alveolar processes, resulting in anterior open bite, which can be worse at the time of eruption of the permanent incisors if the habit persists. When the pacifier is tied together with more pacifiers

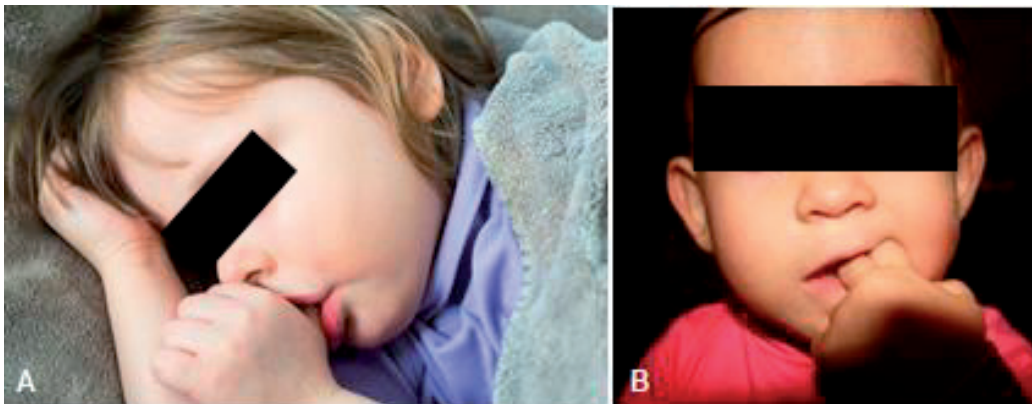


Figure 4.
(A) Child sucking with the ventral side of the finger. (B) Child sucking with the dorsal side of the finger.

or with other objects, the extra weight acts as a lever, affecting the dentition in a similar way as finger sucking [42].

If the pacifier is kept in the mouth for extend periods, the tongue will stay in a lower and anterior position, reducing the palatal support of the primary canines and molars against the pressure exerted by cheeks and increasing lateral pressure on the lower canines and first molars. This position can result in a narrower upper arch and wider lower arch, creating a posterior crossbite [41, 42].

A common question is whether spontaneous resolution of the malocclusion occurs when deleterious oral habits stop. This question, however, remains unanswered because each individual has a different genetic predisposition. On the other hand, some authors have found that anterior openbite and posterior crossbite were associated with habits in children with age 36 months or more. Sustained pacifier habits in children with 24–47 months of age were associated with anterior openbite and Class II molar relationships, while digit habits in children with 60 months of age or longer were associated with anterior openbite [43]. The author concluded that the risk for malocclusion appears to increase with longer habit duration, and that, while in some cases malocclusions resolve soon after the habits are discontinued, in other cases the malocclusions persist [43]. For this reason, we strongly recommend breastfeeding as a protection against the development of oral habits and, if they are already installed, an early intervention in order to decrease their frequency, intensity, and duration and finally to encourage the child to stop those oral habits.

6. Bruxism and tooth wear

Tooth wear (**Figure 5**) is a condition that leads to the loss of dental hard tissues (enamel and dentine) changing size and/or shape of tooth, with multifactorial causes. It can be divided into mechanical and chemical wear. Mechanical wear can happen with attrition of tooth-to-tooth contact made on mastication or bruxism, and it also happens with abrasion, made by oral hygiene procedures and habits such as nail-biting and biting objects. Chemical wear is the erosion that happens due to the action of extrinsic acids on the tooth [44].

Extensive tooth wear (TW) can be caused by chemical factors, mechanical factors, or a combination of both. The most common factors associated with TW were daily functions (e.g., chewing); oral habits (e.g., bruxism, nail biting); having a diet full of acid foods or some diseases that involve acids from the own body (e.g., gastric reflux); and also medicines, stress, and salivary dysfunctions [45].

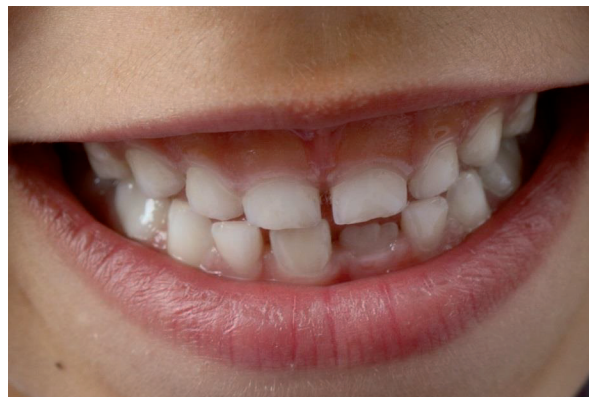

Figure 5.
Child with tooth wear.

TW has become more prevalent and severe in developed countries due to changes in lifestyle and nutritional habits, and also the population is aging and retaining teeth for longer time [45].

As mentioned above, tooth wear and bruxism have a close relationship. According to the international consensus on the assessment of bruxism, sleep bruxism is a rhythmic or non rhythmic masticatory muscle activity during sleep. Awake bruxism is a masticatory muscle activity during wakefulness that is characterized by repetitive or sustained tooth contact and/or by bracing or thrusting of the mandible. Both cannot be considered as a movement or sleep disorder in otherwise healthy individuals. Bruxism is not a disorder in healthy individuals but might be defined as a motor behavior with multifactorial causes. It can be a risk factor for negative oral health consequences, but can also be a potential protective factor when associated with other clinical conditions (e.g., sleep apnea or other sleep disorders) or symptoms (e.g., xerostomia) without a cause-and-effect relationship. Or it can be harmless behavior (not risk or protective factor) in terms of consequences [46].

The main masticatory muscles are masseter and temporalis. They are responsible for elevating the jaw and pressing teeth against each other on the mastication function.

Non-instrumental approaches for assessing bruxism include self-report and clinical inspection. It is important to investigate the presence of sleep or awake bruxism, and how often it happens. Clinical signs of bruxism include masticatory muscle hypertrophy, indentations on the tongue or lip, and/or a linea alba on the inner cheek. However, these signs can also be present on orofacial myofunctional disorders, such as atypical swallowing. Damage to the dental hard tissues, repetitive failures of restorative work, or mechanical wear of the teeth may also be indicators of awake bruxism and sleep bruxism. Yet, it does not assure that it is still active. A bruxism in the past would have left the same signs on the teeth [46].

A study with 440 school children found prevalence of probable sleep bruxism in 40.0% of them. It was more prevalent between children with history of nail biting or biting objects [47].

A population-based study made in Brazil showed prevalence of possible bruxism in 8.1% of the adults, and it was associated with higher level of education and psychological stress [48].

A research investigated the correlation between the masseter electromyographic (EMG) activity during sleep and tooth wear in 41 healthy adults. The individuals underwent a two-night in-home evaluation of EMG activity of muscle masseter and a tooth wear evaluation. The canines and mandibular incisors were the teeth with the highest wear scores. No significant correlation was found between tooth wear and sleep masseter muscle activity. They discussed that even if tooth wear was a consequence of bruxism, it could not be used as a diagnostic tool for sleep bruxism, because the wear is irreversible and bruxism is an unstable phenomenon that may have happened in the past, but stopped [49].

A review was made to investigate the relationship between bruxism and occlusion. The conclusion was that neither occlusal interferences nor factors related to the anatomy of the orofacial skeleton had any evidence available to suggest their involvement in the etiology of bruxism. On the other side, psychosocial and behavioral factors were related as important in the etiology of bruxism [50].

Another review investigated to what extent bruxism is associated to musculoskeletal signs and symptoms. The data from the studies included were very heterogeneous, considering age of participants, type of bruxism (during sleep or wakefulness), and methodology of diagnosis. Most of the studies based the diagnosis of bruxism only on information given by self report, which is not the most reliable information. Besides that, it was concluded that bruxism is somehow

associated with musculoskeletal symptoms. There is no support for a linear causal relationship, but the literature points more to a multifactorial relationship [51].

Besides bruxism, other factors can change tooth aspect and morphology. A systematic review with meta-analysis investigated if eating disorders increase the risk of tooth erosion. Fourteen papers from eight databases were included in the meta-analysis. It showed that patients with eating disorders had 12.4 times more risk of tooth erosion than controls, and patients with eating disorders who self-induced vomiting had 19.6 times more risk of tooth erosion than those patients who did not self-induce vomiting. So it is an important aspect that dentists should be aware of, to prevent disturbs that can be serious [52].

7. Conclusion

It is a fact that orofacial postural alterations can significantly influence the development of the occlusion. So, myofunctional and dentoocclusal changes are quite related. Thus, for the maintenance of correct dental positioning, the balance between orofacial muscular forces becomes primordial. The work of dentistry and speech therapy (orofacial myology) together brings more effective results, since the first professional will be responsible for the improvement of the occlusal structures and the second for the balance of the dynamic structures, especially the tongue, due to its great impact on the occlusion.

Author details

Amanda Valentim*, Renata Furlan, Mariana Amaral and Fernanda Martins
Federal University of Minas Gerais, Belo Horizonte, MG, Brazil

*Address all correspondence to: amandafvalentim@gmail.com

IntechOpen

© 2019 The Author(s). Licensee IntechOpen. This chapter is distributed under the terms of the Creative Commons Attribution License (<http://creativecommons.org/licenses/by/3.0>), which permits unrestricted use, distribution, and reproduction in any medium, provided the original work is properly cited. 

References

- [1] Valentim AF. Avaliação da força sofrida pelos dentes com a ação de lábios e língua [dissertação]. Belo Horizonte (MG): Universidade Federal Minas Gerais; 2012
- [2] Justus R. Correction of anterior open bite with spurs: Long-term stability. *World Journal of Orthodontics*. 2001;2(3):219-231
- [3] Proffit WR, Fields HW Jr, Sarver DM. A Etiologia dos problemas ortodônticos. In: Proffit WR, Fields HW Jr, Sarver DM, editors. *Ortodontia Contemporânea*. 4th ed. Rio de Janeiro: Elsevier; 2007. pp. 121-153
- [4] Douglas CR. Fisiologia geral do sistema estomatognático. In: Douglas CR, editor. *Fisiologia aplicada à fonoaudiologia*. 2nd ed. Guanabara Koogan: Rio de Janeiro; 2006. pp. 270-282
- [5] Valentim AF, Furlan RMMM, Perilo TVC, Berbert MCB, Motta AR, Casas EBL. Evaluation of the force applied by the tongue and lip on the maxillary central incisor tooth. *Codas*. 2014;26(3):235-240
- [6] Menezes LF, Neto AMR, Paulino CEB, Laureano Filho JR, Studant-Pereira LM. Pressão da língua em pacientes com má-oclusão classe II e III. *Revista Cefac*. 2018;20(2):166-174
- [7] Silva Filho OG, Garib DG, Lara TS. *Ortodontia interceptativa Protocolo de tratamento em duas fase*. Artes médicas: São Paulo; 2013
- [8] Stahl F, Grabowski R, Gaebel M, Kundt G. Relationship between occlusal findings and orofacial myofunctional status in primary and mixed dentition. Part II: Prevalence of orofacial dysfunctions. *Journal of Orofacial Orthopedics*. 2007;68(2):74-90
- [9] Grabowski R, Kundt G, Stahl F. Interrelation between occlusal findings and orofacial myofunctional status in primary and mixed dentition part III: Interrelation between malocclusions and orofacial dysfunctions. *Journal of Orofacial Orthopedics*. 2007;68(6):462-476
- [10] Motta AR, Duarte LIM, Migliorucci RR, TVC P. Vocabulário técnico científico em Motricidade Orofacial. In: Rahal A, Motta AR, Fernandes AG, Cunha DA, Migliorucci RR, Felix GB, editors. *Manual de Motricidade Orofacial*. 1st ed. São José, dos Campos: Pulso; 2014. pp. 77-122
- [11] Hanson ML, Barret RH. *Fundamentos da miologia orofacial*. Rio de Janeiro: Enelivros; 1995
- [12] Christiansen RL, Evans CA, Sue SK. Resting tongue pressures. *The Angle Orthodontist*. 1979;49(2):92-97
- [13] Lear CSC, Flanagan JB, Moorrees CFA. The frequency of deglutition in man. *Archives of Oral Biology*. 1965;10(1):83-99
- [14] Artese A, Drummond S, Nascimento JM, Artese F. Criteria for diagnosing and treating anterior open bite with stability. *Dental Press Journal of Orthodontics*. 2011;16(3):136-161
- [15] Proffit WR, Ackerman JL, Sinclair PM, Thomas PM, Tulloch JFC. *Ortodontia Contemporânea*. 2nd ed. Rio de Janeiro: Guanabara Koogan; 1995
- [16] Proffit WR. Equilibrium theory revisited: Factors influencing position of the teeth. *The Angle Orthodontist*. 1978;48(3):175-186
- [17] Cheng CF, Peng CL, Chiou HY, Tsai CY. Dentofacial morphology and tongue function during swallowing. *American Journal of Orthodontics and Dentofacial Orthopedics*. 2002;122(5):491-499

- [18] Mendes ACS, Costa AA, Nerm K. O papel da fonoaudiologia na ortodontia e na odontopediatria: avaliação do conhecimento dos odontólogos especialistas. *Revista Cefac*. 2005;7(1):60-67
- [19] Wallen TR. Vertically directed forces and malocclusion: A new approach. *Journal of Dental Research*. 1974;53(5):1015-1021
- [20] Partal I, Aksu M. Changes in lips, cheeks and tongue pressures after upper incisor protrusion in class II division 2 malocclusion: A prospective study. *Progress in Orthodontics*. 2017;18:29
- [21] Takada J, Takashi O, Myamoto JJ, Yokota T, Moriyama K. Association between intraoral pressure and molar position and inclination in subjects with facial asymmetry. *European Journal of Orthodontics*. 2010;33:243-249
- [22] Smithpeter J, Covell D Jr. Relapse of anterior open bites treated with orthodontic appliances with and without orofacial myofunctional therapy. *American Journal of Orthodontics and Dentofacial Orthopedics*. 2010;137:605-614
- [23] Moore KL, Dalley AF, Agur AMR. *Anatomia orientada para a clínica*. 7th ed. Rio de Janeiro: Guanabara Koogan; 2014. pp. 919-925
- [24] Dental hygiene. In: *Primal Pictures*. London: Informa UK Limited; 2019. Available from: http://www.anatomy-tv.ez27.periodicos.capes.gov.br/html5ui_2018/#/product/dental_higiene/release/2018_04/
- [25] Le Révérend BJ, Edelson LR, Loret C. Anatomical, functional, physiological and behavioral aspects of the development of mastication in early childhood. *The British Journal of Nutrition*. 2014;111(3):403-414
- [26] Ikeda K. Development of jaw muscles' function in rats fed a kneaded diet. *Orthod Waves Journal of the Japanese Orthodontic Society*. 1998;57:163-172
- [27] Ciochon RL, Nisbett RA, Corruccini RS. Dietary consistency and craniofacial development related to masticatory function in minipigs. *Journal of Craniofacial Genetics and Developmental Biology*. 1997;17:96-102
- [28] Larsson E. Orthodontic aspects on feeding of young children: 1. A comparison between Swedish and Norwegian Sami children. *Swedish Dental Journal*. 1998;22:117-121
- [29] Limme M. The need of efficient chewing function in young children as prevention of dental malposition and malocclusion. *Archives de Pédiatrie*. 2010;17:S213-S219
- [30] Grippaudo C, Paolantonio EG, Antonini G, Saulle R, La Torre G, Deli R. Association between oral habits, mouth breathing and malocclusion. *Acta Otorhinolaryngologica Italica*. 2016;36:386-394
- [31] Costa M, Valentim AF, Becker HMG, Motta AR. Findings of multiprofessional evaluation of mouth breathing children. *Revista Cefac*. 2015;17(3):864-878
- [32] Sousa JBR, Anselmo-Lima WT, Valera FCP, Gallego AJ, Matsumoto MAN. Cephalometric assessment of the mandibular growth pattern in mouth-breathing children. *International Journal of Pediatric Otorhinolaryngology*. 2005;69:311-317
- [33] Souki BQ, Pimenta GB, Souki MQ, Franco LP, Becker HMG, Pinto JA. Prevalence of malocclusion among mouth breathing children: Do expectations meet reality? *International Journal of Pediatric Otorhinolaryngology*. 2009;73:767-773

- [34] Thilander B, Pena L, Infante C, Parada SS, Mayorga C. Prevalence of malocclusion and orthodontic treatment need in children and adolescents in Bogota, Colombia. An epidemiological study related to different stages of dental development. *European Journal of Orthodontics*. 2001;**23**:153-167
- [35] Petren S, Bondemark L, Soderfeldt B. A systematic review concerning early orthodontic treatment of unilateral posterior crossbite. *The Angle Orthodontist*. 2003;**73**:588-596
- [36] Valera FC, Travitzki LV, Mattar SE, Matsumoto MAN, Elias AM, Anselmo-Lima WT. Muscular, functional and orthodontic changes in preschool children with enlarged adenoids and tonsils. *International Journal of Pediatric Otorhinolaryngology*. 2003;**67**:761-770
- [37] Cattoni DM, Fernandes FDM, Di Francesco RC, Latorre MRDO. Characteristics of the stomatognathic system of mouth breathing children: Anthroposcopic approach. *Pró-Fono: Revista de Atualização Científica*. 2007;**19**(4):347-351
- [38] Silva MAA, Natalini V, Ramires RR, Ferreira LP. Comparative analysis of mastication in children with nasal and mouth breathing with first teething. *Revista Cefac*. 2007;**9**(2):190-198
- [39] Mossey PA. The heritability of malocclusion. Part 2. The influence of genetics in malocclusion. *British Journal of Orthodontics*. 1999;**26**:195-203
- [40] Viggiano D, Fasano D, Monaco G, Strohmer L. Breast feeding, bottle feeding and non-nutritive sucking; effects on occlusion in deciduous dentition. *Archives of Disease in Childhood*. 2004;**89**:1121-1123
- [41] Larsson E. Sucking, chewing and feeding habits and the development of crossbite: A longitudinal study of girls from birth to 3 years of age. *The Angle Orthodontist*. 2001;**71**:116-119
- [42] Larsson E, Bishara S. Pacifier- and digit-sucking habits. *The Canadian Journal of Dental Hygiene*. 2007;**41**:23-29
- [43] Warren JJ, Slayton RL, Bishara SE, et al. Effects of nonnutritive sucking habits on occlusal characteristics in the mixed dentition. *Pediatric Dentistry*. 2005;**27**:445-450
- [44] Wetselaar P, Lobbezoo F. The tooth wear evaluation system: A modular clinical guideline for the diagnosis and management planning of worn dentitions. *Journal of Oral Rehabilitation*. 2016;**43**(1):69-80
- [45] Hammoudi W, Trulsson M, Smedberg J, Svensson P. Phenotypes of patients with extensive tooth wear—A novel approach using cluster analysis. *Journal of Dentistry*. 2019;**82**:22-29
- [46] Lobbezoo F, Kato T, Ahlberg J, et al. International consensus on the assessment of bruxism: Report of a work in progress. *Journal of Oral Rehabilitation*. 2018;**45**:1-8
- [47] Drummond CL, Ramos-Jorge J, Vieira-Andrade RG, Paiva SM, Serra-Negra JMC, Ramos-Jorge ML. Prevalence of probable sleep bruxism and associated factors in Brazilian schoolchildren. *International Journal of Paediatric Dentistry*. 2018;**29**(2):221-227
- [48] Pontes LDS, Prietsch SOM. Sleep bruxism: Population based study in people with 18 years or more in the city of Rio Grande, Brazil. *Revista Brasileira de Epidemiologia*. 2019;**22**:e190038
- [49] Manfredini D, Lombardo L, Visentin A, Arreghini A, Siciliani G. Correlation between sleep-time masseter muscle activity and tooth wear: An electromyographic study. *Journal of*

Oral & Facial Pain and Headache.
2019;**33**(2):199-204

[50] Lobbezoo F, Ahlberg J, Manfredini D, Winocur E. Are bruxism and the bite causally related? *Journal of Oral Rehabilitation*. 2012;**39**(7):489-501

[51] Baad-Hansen L, Thymi M, Lobbezoo F, Svensson P. To what extent is bruxism associated with musculoskeletal signs and symptoms? A systematic review. *Journal of Oral Rehabilitation*. 2019;**46**(9):845-861

[52] Hermont AP, Oliveira PAD, Martins CC, Paiva SM, Pordeus IA, Auad SM. Tooth erosion and eating disorders: A systematic review and meta-analysis. *PLoS One*. 2014;**9**(11):e111123

IntechOpen