

We are IntechOpen, the world's leading publisher of Open Access books Built by scientists, for scientists

4,800

Open access books available

122,000

International authors and editors

135M

Downloads

Our authors are among the

154

Countries delivered to

TOP 1%

most cited scientists

12.2%

Contributors from top 500 universities



WEB OF SCIENCE™

Selection of our books indexed in the Book Citation Index
in Web of Science™ Core Collection (BKCI)

Interested in publishing with us?
Contact book.department@intechopen.com

Numbers displayed above are based on latest data collected.

For more information visit www.intechopen.com



Surgical Procedures for Ménière's Disease

Ricardo Ferreira Bento and Paula Tardim Lopes

Abstract

The aim of this chapter is to present a literature review on some of the main articles describing different interventions for the treatment in patients with progressive intractable Ménière disease symptoms. Even though each paper presents good results in defending its techniques, there have been few well-designed clinical studies, that is, studies involving control groups or long-term observation, in the efficacy of surgery with respect to vertigo control and hearing preservation. Focusing on presenting the different techniques established in the literature, we discuss the main indications and results obtained regarding the control of vertigo and the audiological outcomes after the procedure. Physicians should offer additional treatment strategies for Meniere's disease patients with a long history of limiting symptoms or associated hearing loss. The surgical options for such patients should be considered carefully because surgery can damage the ipsilateral ear and the hearing function of the contralateral ear is often suboptimal. Its importance is that alternatives for treatment can only be offered to a patient when doctor knows them.

Keywords: Ménière's disease, hearing loss, vertigo, endolymphatic sac, vestibular rehabilitation

1. Introduction

Ménière's disease is a clinical diagnosis based on the 1995 classification by the American Academy of Otolaryngology-Head and Neck Surgery (AAO-HNS) Committee on Hearing and Equilibrium [1]. The definitive diagnosis of Ménière's disease can be made with specific tests such as audiometry and electrocochleography in the exacerbated states of the disease. Recently, a study by Bernaerts [2] showed diagnostic evidences with the use of magnetic resonance imaging (MRI) scans, which showed an enlargement of the perilymphatic spaces in Ménière's disease.

The endolymphatic sac physiologically maintains the hydrostatic pressure and endolymph homeostasis in the inner ear, and its dysfunction may contribute to the pathophysiology of Ménière's disease. The classic tetrad of symptoms in endolymphatic hydrops includes recurrent attacks of vertigo lasting for hours, fluctuating hearing loss, auricular fullness, and tinnitus. Ménière's disease is idiopathic, as its aetiology remains unknown. Over the years, different surgical procedures for intractable vertigo secondary to Ménière's disease have been carried out, and although many authors consider these procedures effective, some argue that they only have a placebo effect. Usually, surgical procedures are indicated in about 20% of the patients when the possibilities of treatment with drugs for vestibular rehabilitation have already been exhausted [3–6].

The surgical technique for the treatment of vertigo depends on the diagnostic hypothesis, clinical condition, age, and hearing level of the patient.

2. Conservative procedures for Ménière's disease

This chapter describes the different surgical procedures performed for Ménière's disease. They can be divided into two types: non-destructive surgery, aimed at altering the disease expression and at reducing the frequency and intensity of vestibular drop attacks; and destructive surgery, aimed at controlling vertigo by stopping the vestibular function.

The most common procedures are the endolymphatic sac decompression with or without the endolymphatic duct opening and shunt in the endolymphatic sac, endolymphatic duct blockage, and intratympanic corticosteroid injection.

2.1 Endolymphatic sac decompression and shunt in the endolymphatic sac

Decompression of the endolymphatic sac involves reducing pressure in this space. It is considered a conservative procedure because of the low rate of hearing loss and the high success rate (around 80% or more) of vertigo control [7, 8].

The first surgical procedure for the treatment of Ménière's disease was described in 1927 by Portmann [9, 10], who first opened the endolymphatic sac to decrease the endolymphatic pressure. In 1938, Hallpike and Cairns [11] showed the pathological findings of endolymphatic hydrops in post-mortem temporal bones of patients who were also diagnosed with Ménière's disease. These bones showed signs of ischemia in the sensory terminal endings at the lateral walls of the membranous labyrinth, which could have been caused by the presence of hydrops.

In 1962, William House [12] showed that draining endolymphatic hydrops using a subarachnoid shunt had good outcomes. In 1967, Kimura [13] obliterated the endolymph duct and attenuated the endolymphatic hydrops in guinea pigs, following which surgeons innovated new techniques of mastoid shunts. In 1976, Paparella [14] described a technique that emphasised the need to make a wide incision in the dura mater of the posterior fossa to completely decompress the endolymphatic sac and duct, increasing its drainage through a valve created in this duct with the placement of a T-tube.

Paparella described that this surgical technique was a modification of the surgical technique of the endolymphatic sac described by Portmann and showed a 94% control rate for vertigo [15].

In a 2014 meta-analysis conducted by Sood et al. [16], the various endolymphatic surgical techniques were analysed, along with their efficacy in vertigo control and hearing maintenance. The study demonstrated that the decompression procedures of the endolymphatic sac both alone and associated with shunt placement in the mastoid were effective, without any statistical difference in the 75% control of vertigo symptoms in a short period of 12–24 months.

Bento et al. [17] conducted a retrospective study of endolymphatic sac decompression using the retrolabyrinthine approach in 95 patients with Ménière's disease who did not undergo long-term clinical treatment. In the group with unilateral disease, vertigo was controlled in 94.3%, cochlear function significantly improved in 14%, and hearing was preserved or improved in 88% of patients. In the group with bilateral disease, vertigo was controlled in 85.7%, cochlear function improved in 28%, and auditory function was preserved in 71% of patients. Considerable improvement in hearing was an improvement of more than 20 dB in the bone conduction threshold or improvement by more than 20% in the discrimination score (**Figures 1 and 2**).

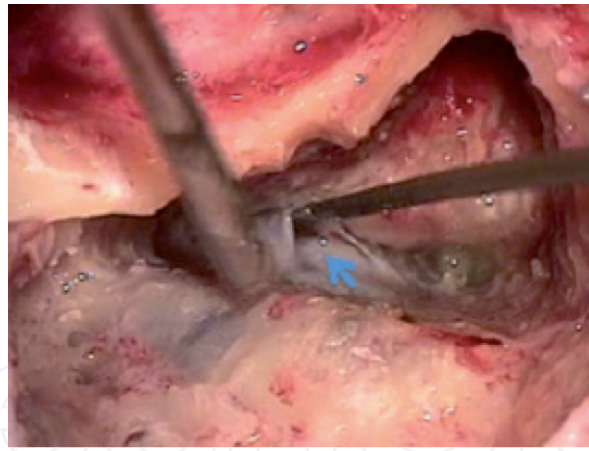


Figure 1.
The sac is opened (arrowhead).

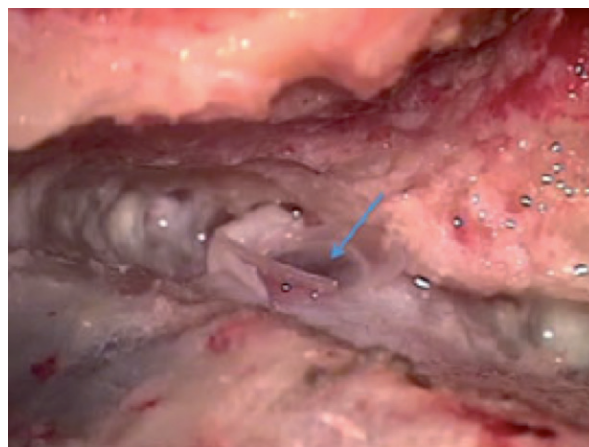


Figure 2.
A silastic sheet (arrow) is placed to keep the sac opened.

The surgical method of endolymphatic sac decompression and drainage of the endolymphatic duct, as previously described by Paparella et al. [18–20], involves a broad exposure of the mastoid cortex, wall-up mastoidectomy, and extensive removal of the pre-sigmoidal and retrolabyrinthine cells.

A very thin skeletal bone should cover the sigmoid sinus, and a small bone island should be left over it to avoid damage from pressure and bleeding. With the Trautmann's triangle fully exposed, the overlying bone is removed with a curette or microdissector, and the sac is then identified as a dense white thickening in the dura mater pointing toward the lower portion of the posterior semicircular canal. Mostly, the sac is clearly differentiated from the adjacent dura mater by its greater thickness in the region and lack of blood vessels. After identifying the endolymphatic sac, a small aperture is created in it with a paracentesis blade or a scalpel, often below the bone border, by retracting the dura mater with a suction tip to expose the lumen. To keep the opening intact, a T-shaped silastic sheet is cut to about 0.127 mm thickness and positioned in the opening, or a T-tube is used. After the procedure, an absorbable gelatine haemostatic sponge is placed in the mastoid cavity, and the wound is closed.

2.2 Endolymphatic duct block

In this technique, the sac is not incised. The surgeon dissects the bone around the endolymphatic duct to expose it and blocks it with two small titanium clips.

The endolymphatic sac gets isolated, so the production and absorption of endolymph in the inner ear balance. Saliba et al. [21] conducted a randomised controlled, non-blinded study comparing this technique with the endolymphatic sac decompression and showed that 96.5% of the patients in the endolymphatic block group achieved vertigo control compared to 37.5% of the patients in the endolymphatic sac decompression group, with no statistical differences between the groups in pre- and post-operative auditory thresholds.

In summary, endolymphatic duct blockade has potential as a surgical technique that results in good control of vertigo.

2.3 Corticosteroid therapy

In 1986, Brookes [22] showed the presence of high levels of circulating immunocomplexes in up to 54% of patients with Ménière's disease. Later, Alleman et al. [23] extracted the circulating immunocomplexes from patients with Ménière's disease and exposed them to endolymphatic sac tissue from other patients with the disease, showing that in only 10% of cases, there was a reaction between the immune complexes and tissues. Hence, it is suggested that although the levels of circulating immunocomplexes in these patients is high, they can represent an induction (viral, allergic, or traumatic) that is greater than an autoimmune phenomenon. Another pathophysiological analysis of Ménière's disease showed that the immune-mediated responses in the inner ear, endolymphatic sac, and vascular striae could be the main causative factors. In 1997, Shea et al. [24] showed that combined administration of systemic and intratympanic dexamethasone completely suppressed vertigo in 63.4% and significantly improved hearing in 35.4% of patients within 2 years after treatment. Later in 2001, Sennaroglu et al. [25] reported that intratympanic perfusion of dexamethasone completely suppressed vertigo in 42.0% and significantly improved hearing in 16% of patients within 2 years after treatment.

3. Destructive surgeries for Ménière's disease

These labyrinthine surgeries cure the patient of vertigo by destroying the final vestibular organ. The brain compensates for the loss of vestibular function on one side using the contralateral labyrinth, as long as it is functioning properly. Destructive labyrinthine procedures have a high risk of destroying the cochlea and should be avoided in patients with adequate hearing. Vestibulocochlear nerve neurectomy, chemical labyrinthectomy, surgical labyrinthectomy, and sacculotomy are common destructive surgeries.

3.1 Vestibulocochlear nerve neurectomy

The neurectomy of the vestibulocochlear nerve for the treatment of Ménière's disease was described in 1933 by Dandy [26]. It is a surgical technique involving a selective section of the vestibular nerve at its entrance to the brain to reduce vertigo but inevitably causing total hearing loss in the operated ear.

Several authors modified the original technique. In 1989, Silverstein [27] proposed the retrosigmoid approach for neurectomy and observed a substantial improvement in dizziness in 92% with a significant hearing loss in only 4% of patients.

House [28] introduced the middle fossa approach. Regardless of the access, the decompression technique had a success rate of up to 90% in the control of vertigo [29–33]. Colletti et al. [4] conducted a comparative study on 209 patients who

underwent neurectomy, comparing a group of 24 patients who received intratympanic gentamicin (ITG), chemical labyrinthectomy neural ablation therapy. To perform a homogenous comparison of results in the present paper, it considered all the 24 ITG patients and the last 24 patients who underwent VN from 2000 to 2002 via the retrosigmoid approach.

Vertigo was controlled in 95.8% of neurectomy patients and in 75% of gentamicin patients. Speech discrimination in the neurectomy group was reduced from 85 to 82% and in the gentamicin group from 87% to 65%.

3.2 Chemical labyrinthectomy: intratympanic application of gentamicin in the middle ear

This technique was first used in 1978 by Beck [34, 35] and aims to perform a chemical ablation of the labyrinth to decrease the frequency and intensity of vertigo episodes but can result in hearing loss, as gentamicin is ototoxic and reduces labyrinthine activity. It can be injected directly into the tympanic cavity using a thin needle or applied daily through a Politzer ventilation tube first placed at the tympanic membrane for penetrating the round and oval windows. A study [36] showed 90% efficacy in the cessation of vertigo among 92 patients.

In the 2000 literature review by Blakley et al. [37], 18 articles were found on the techniques of intratympanic injection of gentamicin in the treatment of Ménière's disease. The articles reported high success rates in vertigo treatment, but the technique, dose, duration, and treatment philosophy varied considerably among them. Hearing loss was typically reported in about 30% of patients, and no technique had any significant medical advantage over the other. Until new controlled studies indicate otherwise, this therapy is an alternative treatment for patients with major comorbidities.

3.3 Surgical labyrinthectomy

This technique can decrease vertigo by the total destruction of the labyrinth but leads to total hearing loss in the operated ear.

Lake first described this procedure in 1904 [38], and in the mid-twentieth century, labyrinthectomy was established as a less-invasive alternative to neurectomy of the vestibular nerve [39, 40]. The surgical technique involves opening the semicircular canals up to the endolymphatic ducts in the opening of the vestibule with the complete destruction of neuroepithelium and Scarpa's ganglion [41, 42]. No technique was observed to be superior in vertigo control among labyrinthectomy, neurectomy, and a combination of both [43, 44].

Labyrinthectomy, in particular, is an alternative [45] (demonstrating approximately 100% success rate in vertigo treatment) for old patients, and in this case, the transmastoid technique presented a lower permanent imbalance rate after the procedure than the transcanal technique. Labyrinthectomy is the treatment of choice for patients over 60 years of age [46]. Surgical labyrinthectomy of the affected labyrinth always ends in total deafness. Therefore, it should be reserved for patients with non-functional hearing and should be one of the last therapeutic options (**Figure 3**).

3.4 Sacculotomy

In 1964, Fick [47, 48] described a procedure in which a fenestra is made in the stapes footplate or round window membrane, and therefore, a permanent shunt for draining of the saccule is created with the destruction of the cochlear function [49].

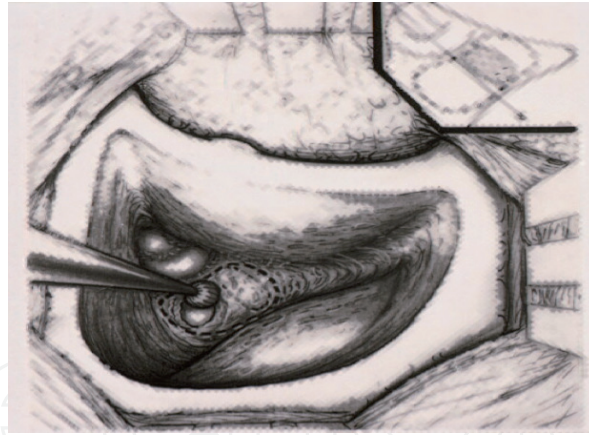


Figure 3.
Schematic drawing of Labyrinthectomy.

Giddings et al. [50] reported hearing loss after cochleo-sacculotomy in 80% of the patients and recurrent vertigo episodes in a mean follow-up of 17 months in 4 of 11 patients so that a destructive intervention had to be carried out again. Kinney et al. [51] and Wielinga et al. [52] recommended cochleo-sacculotomy as a minimally invasive surgical method, especially for old patients, as an alternative to neurectomy because good results were obtained with regard to vertigo control, although with significant hearing loss in almost all patients.

In 2015, in a comparative study [53] between cochlear sacculotomy techniques and endolymphatic sac decompression, the control of vertigo was significantly better in patients after cochleo-sacculotomy but also with significant deterioration of hearing. The cochleo-sacculotomy procedure performed simultaneously with cochlear implant surgery in patients with deafness and persistent vertigo in Ménière's disease is an alternative already proposed by some authors [54–56], and they have reported good results.

4. Conclusion

The surgical procedures described in this chapter demonstrated satisfactory results in the control of incapacitating vertigo in patients diagnosed with endolymphatic hydrops refractory to clinical drug treatment, adequate diet, and vestibular rehabilitation. The choice of method would depend on the quality of residual hearing, contralateral hearing, and on the ability to develop compensatory mechanisms if surgical techniques destroyed vestibular function.

Conflict of interest

The authors have no conflict of interest.

IntechOpen

IntechOpen

Author details

Ricardo Ferreira Bento and Paula Tardim Lopes*
Department of Otorhinolaryngology and Neurotology, Hospital das Clínicas—
University of São Paulo, São Paulo, Brazil

*Address all correspondence to: paula.tardim@hc.fm.usp.br

IntechOpen

© 2019 The Author(s). Licensee IntechOpen. This chapter is distributed under the terms of the Creative Commons Attribution License (<http://creativecommons.org/licenses/by/3.0>), which permits unrestricted use, distribution, and reproduction in any medium, provided the original work is properly cited. 

References

- [1] Committee on Hearing and Equilibrium. Committee on hearing and equilibrium guidelines for the diagnosis and evaluation of therapy in Meniere's disease. American Academy of Otolaryngology—Head and Neck Foundation, Inc. *Otolaryngology and Head and Neck Surgery*. 1995;**113**(3):181-185
- [2] Bernaerts A, Vanspauwen R, Blaivie C, et al. The value of four stage vestibular hydrops grading and asymmetric perilymphatic enhancement in the diagnosis of Menière's disease on MRI. *Neuroradiology*. 2019;**61**(4):421-429. DOI: 10.1007/s00234-019-02155-7
- [3] Liston SL, Nissen RL, Paparella MM, Da Costa SS. Surgical treatment of vertigo. In: Paparella MM, Shumrick DA, Gluckman JL, Meyerhoff WL, editors. *Otolaryngology*. Volume II. Philadelphia: WB Saunders Company; 1991. pp. 1715-1732
- [4] Colletti V, Carner M, Colletti L. Auditory results after vestibular nerve section and intratympanic gentamicin for Ménière's disease. *Otology & Neurotology*. 2007;**28**(2):145-151. DOI: 10.1097/MAO.0b013e31802c7989
- [5] Sajjadi H, Paparella MM. Ménière's disease. *Lancet*. 2008;**372**(9636):406-414. DOI: 10.1016/S0140-6736(08)61161-7
- [6] Yokota Y, Kitahara T, Sakagami M, Ito T, Kimura T, Okayasu T, et al. Surgical results and psychological status in patients with intractable Ménière's disease. *Auris, Nasus, Larynx*. 2016;**43**(3):287-291. DOI: 10.1016/j.anl.2015.10.007
- [7] Brinson GM, Chen DA, Arriaga MA. Endolymphatic mastoid shunt versus endolymphatic sac decompression for Ménière's disease. *Otolaryngology and Head and Neck Surgery*. 2007;**136**(3):415-421. DOI: 10.1016/j.otohns.2006.08.031
- [8] Kitahara T, Horii A, Imai T, Ohta Y, Morihana T, Inohara H, et al. Effects of endolymphatic sac decompression surgery on vertigo and hearing in patients with bilateral Ménière's disease. *Otology & Neurotology*. 2014;**35**(10):1852-1857. DOI: 10.1097/MAO.0000000000000469
- [9] Portmann G. The saccus endolymphaticus and the operation for draining the same for relief of vertigo. *The Journal of Laryngology and Otology*. 1927;**42**:809-817
- [10] Portamann G. Surgical treatment of vertigo by opening of the saccus endolymphaticus. *Archives of Otolaryngology*. 1969;**89**(6):809-815
- [11] Hallpike CS, Cairns H. Observation on pathology of Ménière's syndrome. *The Journal of Laryngology and Otology*. 1938;**53**:624-654
- [12] House WF. Subarachnoid shunt for drainage of endolymphatic hydrops. A preliminary report. *Laryngoscope*. 1962;**72**:713-729. DOI: 10.1288/00005537-196206000-00003
- [13] Kimura RS. Experimental blockage of the endolymphatic duct and sac and its effects on the inner ear of the guinea pig. A study on endolymphatic hydrops. *The Annals of Otology, Rhinology, and Laryngology*. 1967;**76**(3):664-687. DOI: 10.1177/000348946707600311
- [14] Paparella MM, Hanson DG. Endolymphatic sac drainage for intractable vertigo (method and experiences). *The Laryngoscope*. 1976;**86**(5):697-703. DOI: 10.1288/00005537-197605000-00010

- [15] Paparella MM, Goycoolea M. Panel of Ménière's disease. Endolymphatic sac enhancement surgery for Ménière's disease: An extension of conservative therapy. *The Annals of Otolaryngology, Rhinology, and Laryngology*. 1981;**90**(6 Pt 1):610-615. DOI: 10.1177/000348948109000620
- [16] Sood AJ, Lambert PR, Nguyen SA, Meyer TA. Endolymphatic sac surgery for Ménière's disease: A systematic review and meta-analysis. *Otology & Neurotology*. 2014;**35**(6):1033-1045. DOI: 10.1097/MAO.0000000000000324
- [17] Bento RF, Cisneros JC, De Oliveira Fonseca AC. Endolymphatic sac drainage for the treatment of Ménière's disease. *The Journal of Laryngology and Otology*. 2016;**131**(2):144-149. DOI: 10.1017/S0022215116009713
- [18] Paparella MM, Goycoolea M. Panel of Ménière's disease. Endolymphatic sac enhancement surgery for Ménière's disease: An extension of conservative therapy. *The Annals of Otolaryngology, Rhinology, and Laryngology*. 1981;**90**(6 Pt 1):610-615. DOI: 10.1177/000348948109000620
- [19] Paparella MM, Sajjadi H. Endolymphatic sac enhancement. *Otolaryngologic Clinics of North America*. 1994;**27**(2):381-402
- [20] Paparella MM. Revision of endolymphatic sac surgery for recurrent Ménière's disease. *Otolaryngologic Clinics of North America*. 2002;**35**(3):607-619
- [21] Saliba I, Gabra N, Alzahrani M, Berbiche D. Endolymphatic duct blockage: A randomized controlled trial of a novel surgical technique for Ménière's disease treatment. *Otolaryngology and Head and Neck Surgery*. 2015;**152**(1):122-129. DOI: 10.1177/0194599814555840
- [22] Brookes GB. Circulating immune complexes in Meniere's disease. *Archives of Otolaryngology—Head & Neck Surgery*. 1986;**112**(5):536-540
- [23] Alleman AM, Dornhoffer JL, Arenberg IK, Walker PD. Demonstration of autoantibodies to the endolymphatic sac in Meniere's disease. *The Laryngoscope*. 1997;**107**(2):211-215
- [24] Shea JJ Jr. The role of dexamethasone or streptomycin perfusion in the treatment of Meniere's disease. *Otolaryngologic Clinics of North America*. 1997;**30**(6):1051-1059
- [25] Sennaroglu L, Sennaroglu G, Gursel B, Dini FM. Intratympanic dexamethasone, intratympanic gentamicin, and endolymphatic sac surgery for intractable vertigo in Meniere's disease. *Otolaryngology and Head and Neck Surgery*. 2001;**125**(5):537-543. DOI: 10.1067/mhn.2001.119485
- [26] Dandy WE. Treatment of Meniere's disease by section of only the vestibular portion of the acoustic nerve. *Bulletin of the Johns Hopkins Hospital*. 1933;**53**:52-55
- [27] Silverstein H, Jackson LE. Vestibular nerve section. *Otolaryngologic Clinics of North America*. 2002;**35**(3):655-673
- [28] House WF. Surgical exposure of the internal auditory canal and its contents through the middle cranial fossa. *The Laryngoscope*. 1961;**71**:1363-1385. DOI: 10.1288/00005537-196111000-00004
- [29] Reid CB, Eisenberg R, Halmagyi GM, Fagan PA. The outcome of vestibular nerve section for intractable vertigo: The patient's point of view. *The Laryngoscope*. 1996;**106**(12 Pt 1):1553-1556
- [30] Pappas DG Jr, Pappas DG Sr. Vestibular nerve section: Long-term

follow-up. *The Laryngoscope*. 1997;**107**(9):1203-1209

[31] De Diego JI, Prim MP, Melcon E, de Sarriá MJ, Gavilán J. Result of middle fossa vestibular neurectomy in Meniere's disease. *Acta Otorrinolaringológica Española*. 2001;**52**(4):283-286

[32] Nakahara H, Takemori S, Seki Y, Umezu H. Hearing changes and questionnaire responses in patients with paramedian suboccipital vestibular neurectomy. *Acta Oto-Laryngologica Supplementum*. 2001;**545**:108-112

[33] Schlegel M, Vibert D, Ott SR, Häusler R, Caversaccio MD. Functional results and quality of life after retrosigmoid vestibular neurectomy in patients with Ménière's disease. *Otology & Neurotology*. 2012;**33**(8):1380-1385

[34] Beck C, Schmidt CL. 10 years of experience with intratympanally applied streptomycin (gentamycin) in the therapy of morbus Meniere. *Archives of Oto-Rhino-Laryngology*. 1978;**221**(2):149-152

[35] Beck C. Intratympanic application of gentamicin for treatment of Meniere's disease. *The Keio Journal of Medicine*. 1986;**35**(1):36-41

[36] Lange G. Gentamicin and other ototoxic antibiotics for the transtympanic treatment for Meniere's disease. *Archives of Oto-Rhino-Laryngology*. 1989;**246**(5):269-270

[37] Blakley BW. Update on intratympanic gentamicin for Meniere's disease. *The Laryngoscope*. 2000;**110** (2 Pt 1):236-240

[38] Lake R. Removal of the semicircular canals in a case of unilateral aural vertigo. *Lancet*. 1904;**1**:1567-1568

[39] Cawthorne TE, Hallpike CS. Some recent work on the investigation and

treatment of "Ménière's" disease. *Proceedings of the Royal Society of Medicine*. 1943;**36**(10):533-550

[40] Day KM. Surgical treatment of hydrops of the labyrinth; surgical destruction of the labyrinth for Ménière's disease. *The Laryngoscope*. 1952;**62**(6):547-555

[41] Jones R, Silverstein H, Smouha E. Long-term results of transmeatal cochleovestibular neurectomy: An analysis of 100 cases. *Otolaryngology and Head and Neck Surgery*. 1989;**100**(1):22-29

[42] Langman AW, Lindeman RC. Surgery for vertigo in the nonserviceable hearing ear: Transmastoid labyrinthectomy or translabyrinthine vestibular nerve section. *The Laryngoscope*. 1993;**103**(12):1321-1325

[43] Gacek RR, Gacek MR. Comparison of labyrinthectomy and vestibular neurectomy in the control of vertigo. *The Laryngoscope*. 1996;**106** (2 Pt 1): 225-230

[44] Eisenman DJ, Speers R, Telian SA. Labyrinthectomy versus vestibular neurectomy: Long-term physiologic and clinical outcomes. *Otology & Neurotology*. 2001;**22**(4):539-548

[45] Schwaber MK, Pensak ML, Reiber ME. Transmastoid labyrinthectomy in older patients. *The Laryngoscope*. 1995;**105**(11):1152-1154

[46] Langman AW, Lindeman RC. Surgical labyrinthectomy in the older patient. *Otolaryngology and Head and Neck Surgery*. 1998;**118**:739-742

[47] Fick IA. Decompression of the labyrinth: A new surgical procedure for Meniere's disease. *Archives of Otolaryngology*. 1964;**79**:447-458

- [48] van Fick IA. Symposium: Management of Ménière's disease. VI. Sacculotomy for hydrops. *The Laryngoscope*. 1965;**75**(10):1539-1546
- [49] Schuknecht HF. Cochleosacculotomy for Meniere's disease: Theory, technique and results. *The Laryngoscope*. 1982;**92**(8 Pt 1):853-858
- [50] Giddings NA, Shelton C, O'Leary MJ, Brackmann DE. Cochleosacculotomy revisited: Long-term results poorer than expected. *Archives of Otolaryngology—Head & Neck Surgery*. 1991;**117**(10):1150-1152
- [51] Kinney WC, Nalepa N, Hughes GB, Kinney SE. Cochleosacculotomy for the treatment of Ménière's disease in the elderly patient. *The Laryngoscope*. 1995;**105**(9 Pt 1):934-937
- [52] Wielinga EW, Smyth GD. Long-term results of sacculotomy in older patients. *The Annals of Otology, Rhinology, and Laryngology*. 1989;**98**(10):803-806
- [53] Soheilipour S, Abtahi SH, Soltani M, Khodadadi HA. Comparison the results of two different vestibular system surgery in patients with persistent Meniere's disease. *Advanced Biomedical Research*. 2015;**4**:198. DOI: 10.4103/2277-9175.166134
- [54] Mukherjee P, Eykamp K, Brown D, Curthoys I, Flanagan S, Biggs N, et al. Cochlear implantation in Ménière's disease with and without labyrinthectomy. *Otology & Neurotology*. 2017;**38**(2):192-198. DOI: 10.1097/MAO.0000000000001278
- [55] Prenzler NK, Bültmann E, Giourgas A, Steffens M, Salcher RB, Stolle S, et al. Cochlear implantation in patients with definite Meniere's disease. *European Archives of Oto-Rhino-Laryngology*. 2017;**274**(2):751-756. DOI: 10.1007/s00405-016-4356-z
- [56] Heywood RL, Atlas MD. Simultaneous cochlear implantation and labyrinthectomy for advanced Ménière's disease. *The Journal of Laryngology and Otology*. 2016;**130**(2):204-206. DOI: 10.1017/S0022215115003345