

We are IntechOpen, the world's leading publisher of Open Access books Built by scientists, for scientists

4,800

Open access books available

122,000

International authors and editors

135M

Downloads

Our authors are among the

154

Countries delivered to

TOP 1%

most cited scientists

12.2%

Contributors from top 500 universities



WEB OF SCIENCE™

Selection of our books indexed in the Book Citation Index
in Web of Science™ Core Collection (BKCI)

Interested in publishing with us?
Contact book.department@intechopen.com

Numbers displayed above are based on latest data collected.
For more information visit www.intechopen.com



Oral Mesotherapy: Might Be Considered as An Adjunctive Technique for the Different Surgical Procedures?

Nermin Yussif

Abstract

The bidirectional relationship between local and systemic pathways makes it difficult to provide a safe intraoral treatment. Nowadays, mesotherapy has become more necessary in dentistry to overcome the huge number of surgical interventions either for therapeutic or for cosmetic purposes. It also limits the need for systemic drugs achieving favorable outcomes with minimal side effects. Further researches are needed to examine the usage of mesotherapy in different oral problems. In dermal mesotherapy, dermatologists used several materials as hyaluronic acid, collagen, hydroxyapatite, carboxymethyl cellulose, and silicone. Such materials exhibit different manners according to their resorption rate: temporary, semipermanent, permanent, and combinations. Furthermore, B-tricalcium phosphate and hydroxyapatite are considered as tissue stimulators by stimulation of collagen formation. Combinations of temporary materials in order to achieve immediate filling effect with tissue stimulator as HA or B-TCP achieve better results.

Keywords: oral mesotherapy, intraepidermic injection, minimally invasive techniques, vitamins, tooth traction, depigmentation, connective tissue thickening

1. An overview on the original mesotherapy technique for dermatological uses

The aim behind mesotherapy was to create a new technique, which favors the supplementation of needed agents directly and locally to the site of complaint. As previously mentioned, the proposed theory by *Pistor* depends mainly on the direct effect of the used drug on the tissue originating from the mesoderm [1, 2]. The mesoderm is one of the primary germ layers of the embryo that is responsible for the development of skin, connective tissue, muscles, tendons, and circulatory system. It is mainly responsible for skin vitality and health [3]. The injection technique of mesotherapy depends mainly on the anatomical, histological and geometrical landmarks of the target tissues. Mesointerface is the horizontal interface between the injected agents and the injected region. For maximum benefits, the injected surface is inversely proportional to the amount and molecular weight of the injected

agent. The wider the mesointerface is, the greater the number of the dermal receptors that are activated [4].

On the other hand, the vertical component depends on the depth of penetration. Mesotherapy could be injected in the epidermis, dermis, or subcutaneous [1]. The more superficial injection is, the longer the drug remains in the tissue. It permits sustained release of the drug with slow and progressive diffusion into the surrounding tissues [2, 5, 6].

The technique depends on the skin characteristics and components. It determines the type of drug injected, the technique of injection, and the drug dosage. The skin has a natural sustained releasing property. Therefore, the nature of the skin determines the layers that are suitable for injection. The injection process must be in the superficial layers (intradermal) for the drug to remain as long as possible and for its clearance to become slower. If the drug is injected deeper, its clearance becomes faster. So the more superficial the injection is, the longer the drug remains in place (being far more powerful and efficient) [6].

2. FDA and mesotherapy

The FDA is the association concerning about the assurance of the food and drug safety. Although FDA did not approve the mesotherapy technique, it approved many drugs that have been used in mesotherapy as aminophylline, yohimbine, procaine, lidocaine, and marcaine [7]. Other drugs do not have the FDA approval for any purpose of usage as it is beyond the scope of FDA because they do not consider drugs as vitamins and minerals [8]. It also approved the delivery method using mesogun [1].

All the drugs used in mesotherapy are considered by the FDA as off-label used drugs. The off-label approval includes the approved drug and the approved route of administration of this drug. The local anesthetic agents calcitonin, hyaluronidase, and collagenase are not approved by the FDA [9].

3. Benefits and uses of mesotherapy

The local treatment in mesotherapy has superior advantages over the systemic one either oral or parental. Firstly, it avoids the side effects resulted from drug metabolism and excretion in the stomach, intestine, liver, and kidneys. Secondly, the effectiveness of the local drug is directly administrated into the area of interest. Finally, it minimizes the dosage used into 1% of the dosage used systemically [1].

Improvement of blood flow, removal of fibrotic tissue, an increase in the connective tissue quality and amount, hair loss (mesohair), skin rejuvenation (mesoglow), excessive fat and cellulite removal, improvement of the lymphatic drainage, osteoarthritis, and pain relief are the main medical indications of mesotherapy [10]. On the financial point of view, it is a cost-effective modality that provides successful drug delivery using inexpensive equipment with short-term practice needed for the general practitioner [11].

Oral mesotherapy is an old technique which was commonly applied in order to introduce various agents. Infiltration, intraligamentary, intramucosal, intralesional, and intraepidermic injection are common names for oral mesotherapy technique that have been used previously. The different names were more related to different layers and structures of the oral cavity.

4. Common agents delivered by oral mesotherapy

4.1 Local anesthesia

Local anesthesia is a reversible blockage of nerve conduction in a defined area that resulted in loss of sensation [12]. It can be performed using various techniques which differ according to the width of the area needed to be anesthetized as well as tissue depth and its relation to target nerve.

Local infiltration is one of the techniques in which the local anesthetic solution is administrated submucosal, intradermal, or intraligamentary in order to anesthetize the nerve endings that innervate the target region. The submucosal injection involves the drug administration in the deep dermis layer reaching the lipid layer with 45 angulation and thicker needle, while the intradermal injection involves introduction of anesthetic agent into the superficial dermis (papillary dermis) with 10 to 15 degrees using fine needle [13, 14]. Intraligamentary (or periodontal) anesthesia is a type of the locally delivered anesthetic technique in which the needle is introduced in the mesiobuccal and distobuccal directions delivering the anesthetic agent in an apical direction. Its accuracy, easiness, minimal administration of anesthetic solution, efficiency, and the lack of harmful effects to the adjacent periodontal apparatus are the main advantages of this technique [15, 16]. The pressure needed for such technique is necessary, and it remains the main cause behind the development of local inflammation and pain which may last up to 7 days as well as bone and root resorption in relation to the injection site [17]. Defective enamel disorders were also detected following intraligamentary injection of local anesthesia. In hemophilic patients, intraligamentary injections are usually not recommended to avoid hematoma formation. It was also avoided in deciduous teeth [18] (**Figure 1**).

On the other hand, the field block technique involves the introduction of the anesthetic agent in a circular configuration around the operative site [19].

The interseptal technique is a simple technique which provides adequate control of pain and bleeding especially during emergency conditions. During infection and inflammatory conditions, interseptal technique is usually preferred. A 27 gauge needle is inserted at 45° at the center of the interdental papilla. Minimal amount (0.2–0.4 ml) of the anesthetic agent is injected. It was found that interseptal technique showed higher anesthetic efficiency than the intraligamentary and intraosseous injection [18, 19].

The intrapulpal technique is one of the most common techniques that are used during endodontic treatment especially in acute phases of pulpal inflammation.

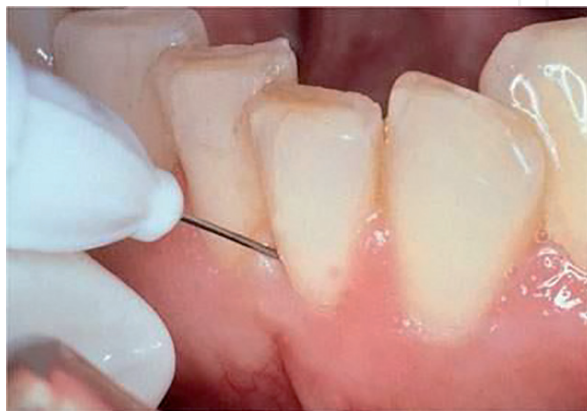

Figure 1.
Intraligamentary injection [18].

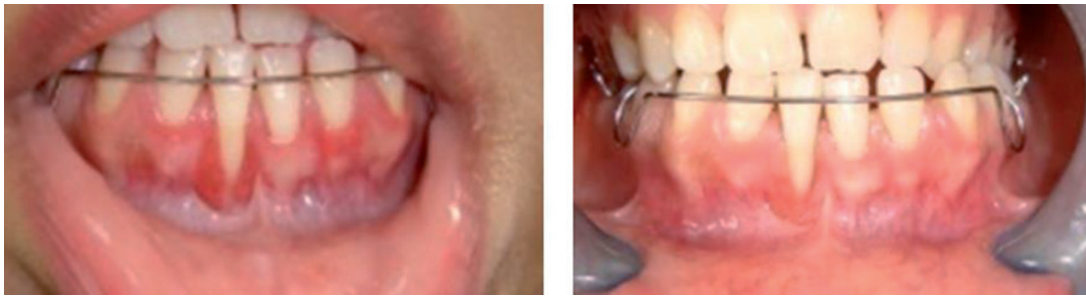

Figure 2.
Corticosteroids and chronic gingival inflammation.

Despite its rapid onset, effectiveness, and safeness, its action has shorter duration than other techniques [18]. Finally, the intraosseous technique provides rapid introduction, which is commonly used following failure of the field or nerve block technique. It depends on the direct introduction of the anesthetic agent to the interdental bone resulting in rapid delivery of the anesthetic agent to the blood circulation which should be avoided in cardiovascular patients [19] (**Figure 2**).

4.2 Corticosteroids

Corticosteroids are widely used for the management of numerous oral inflammatory conditions due to their anti-inflammatory and immune modulatory effects. They could be delivered either intramucosally (within the lesion), topically, or systemically [20].

Intralesional (intralesional) corticosteroid injection is a favorite method in delivering the drug directly to the target site resulting in rapid action as well as less systemic complications. Injectable steroids are clear fluids; their color and dose depend on the formulation of steroids used. It is commonly used in managing the longstanding oral lichen planus lesions and oral submucous fibrosis, but it has a localized side effect such as mucosal atrophy [21, 22]. Hydrocortisone and triamcinolone are the commonest formulas used in local delivery with weekly injections reaching up to 11 injections [22, 23].

Although surgical excision is considered the gold standard technique for treating mucocele and orofacial granulomatosis, the use of intralesional corticosteroid injection was also reported. However, some investigators have suggested that the intralesional corticosteroid could be used as a new modality in the treatment, but cases of relapse with corticosteroid have been reported [24, 25]. Great differences were detected in the used doses and the number of sessions according to the severity, extension, and the systemic condition of the patient [22, 23, 26–28].

4.3 Vitamins

According to literature, vitamins were usually introduced either by intraligamentary or intraepidermic techniques. The intraepidermic technique was conducted in 2016 by Yussif et al. [29].

4.3.1 Vitamin D

Although vitamin D has a great role in maintaining the bone health and metabolism, it is just recently discovered that vitamin D deficiency has a great role in the occurrence and progression of various periodontal diseases. It is a steroid hormone that controls the bone metabolism and calcium homeostasis [30–32].

It was detected that the level of vitamin D reaches its lowest levels during periodontal disease especially aggressive periodontitis. The daily supplementation is important to maintain the periodontal health [30–33].

The introduction of locally delivered vitamin D injections provides short treatment visits, non-traumatic, less patient morbidity, non-stressful procedure with no post-operative side effects. The procedure is not painful. There is also no need for preoperative local anesthesia. It could be either delivered alone [34] or in combination with calcium [35]. The promising improvement of the regenerative power was attributed to minimal trauma and preserving the periosteum adapted over the alveolar bone. Great reduction of the clinical attachment loss and the absence of bleeding on probing were also detected indicating the absence of inflammation. On the radiographic examination, improvement of the alveolar bone density as well as accentuation of lamina dura was also reported [34, 35].

In orthodontic therapy, locally delivered vitamin D is commonly introduced in small doses using periodontal injection technique in order to accelerate the osteoclastic activity in the pressure site which in role accelerates the orthodontic movement. The dose and the number of the treatment sessions are determined according to the distance that the tooth needed to travel [34, 36] (**Figure 3**).

4.3.2 Vitamin C

Ascorbic acid is also an essential vitamin in the treatment of periodontal diseases. Its deficiency causes impaired wound healing with higher bleeding index. Lower levels of serum vitamin C were reported in periodontitis. The importance of vitamin C lies behind its powerful scavenging and antioxidant effect as it usually

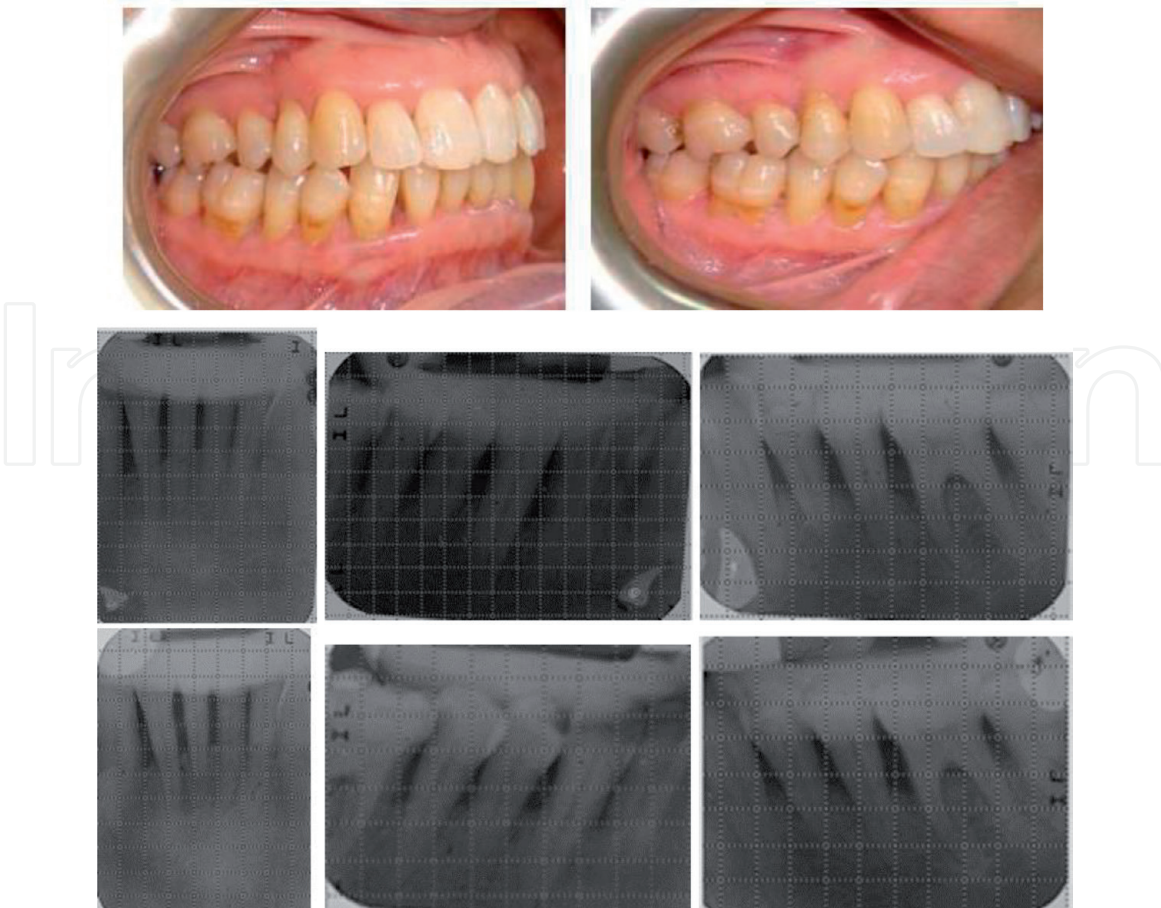


Figure 3.
Vitamin D injection and periodontitis [37].

accumulates in the immune cells as PMNs and macrophages and significantly enhances chemotaxis, phagocytic, opsonization, degranulation, and killing functions of immune cells [33, 38]. It also has a great role in collagen biosynthesis [39]. It could be supplied orally, topically, or by intraepidermal injection [37, 40]. Vitamin C is widely used in dermal mesotherapy as it restores the tissue integrity and brightness by neutralizing the free radicals in the newly formed tissues, stimulates the collagen formation, and inhibits melanogenesis [10, 41].

Growing evidence has suggested the role of vitamin C in enhancing the quality and outcome of the orthodontic treatment. This is proven when tooth movement was enhanced following systemic administration of vitamin C for 17 days [42, 43]. It was also noticed that its deficiency is accompanied with limited tooth movement and arrested osteogenesis [44].

Vitamin C induces its action through modifying the osteoclastic activity, osteogenesis, tissue healing, and periodontal ligament organization. It increases the collagen I synthesis that represents the main component of bone matrix and periodontal ligament [45]. It also accelerates the bone mineralization, calcium absorption, formation of collagen type X, expression of alkaline phosphatase, and osteoblast growth and differentiation [46, 47] (**Figure 4**).

Furthermore, the depigmenting effect of vitamin C depends mainly on its antioxidant property. The efficiency of vitamin C in the treatment of physiologic or pathologic dermal problems such as hyperpigmentation, aging, and dryness was promising due to several factors that are not only related to its direct interaction with melanin and melanocytes but also due to the overall effect on the applied tissues. Once vitamin C is introduced to the target tissue, it binds efficiently to melanin because melanin is the main store of ROS, calcium, and copper content that causes intracellular deficiency of these items. Lower intracellular calcium level causes failure of melanocytes to perform cellular adhesion as calcium is essential to form cadherins [48, 49]. The contact to keratinocytes is important simulator to

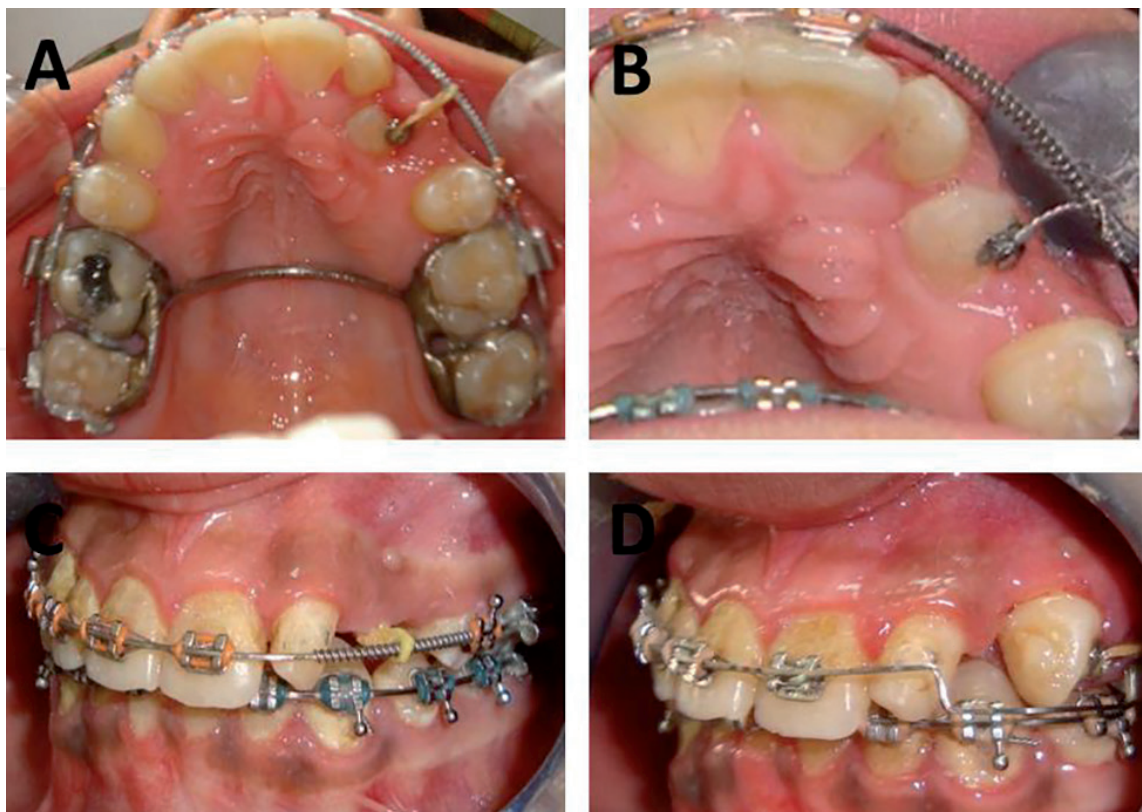


Figure 4.
Pre- and postoperative local vitamin C injection in impacted canine traction [37].

melanocytes to produce melanin, formation of dendrites and transfer the produced melanin to neighboring cells [48, 50]. Also, shortage of the intercellular copper limits the formation of tyrosine, tyrosinase enzyme, and peroxidase enzyme which in turn stops the melanin production [41].

Pain and itching were regarded as painful stimuli. Itching may transit to pain due to increased discharge frequency of nociceptors (intensity theory) [51] (**Figure 5**).

In 2016, Yussif et al. used the intraepidermic injection technique (oral mesotherapy technique) in order to treat physiological hyperpigmentation. Vitamin C injection is a safe, minimally invasive nonsurgical depigmenting technique which also improves health of gingival tissues. They concluded that the direct effect of vitamin C could be due to the affinity of melanin to react with it, which in turn affects the cellular junctions (causing the immediate fainting) and forces such cells to spell out their contents of melanin leading to tissue darkening after a while. Further investigations and studies are recommended to detect its long-term effect on the melanocytes and keratinocytes [29] (**Figure 6**).

During persistent gingival inflammation, Yussif et al. [45] have reported significant enhancement of the gingival health by the usage of the intraepidermic vitamin C injection as an adjunctive approach for the conventional nonsurgical treatment modality.

During inflammation, it was found that the tissue antioxidant level (as vitamin C, vitamin E, etc.) decreases rapidly indicating the need of its supplementation. On the other hand, the free radical production increases at the site of inflammation [52, 53]. Extra doses of antioxidants especially vitamin C are essential. In localized inflammatory conditions, the administration of the needed higher doses via systemic route (higher than 500 mg) cannot be absorbed by the gastrointestinal tract, which is easily excreted through urine. Moreover, in order to reach this dose at the site of inflammation, it needs administration of very high systemic doses that could be harmful to the patient. The local injection provides the needed dose efficiently [54] (**Figure 7**).

In 2014, [55] reported that the switch of the gingival tissue to the thick biotype is important to gingival and periodontal health as well as esthetic outcome. Ascorbic acid enhances the periodontal ligament maturation and renewal by induction of the collagen formation especially collagen III (young collagen) and keeps the balance between collagen I (mature collagen) and III for tissue maturation. It also modifies the rate of fibroblast proliferation [56]. In 2016, Yussif et al. reported the improvement of the gingival biotype following the intraepidermic vitamin C injection ranging between 0.5 and 1 mm [29].

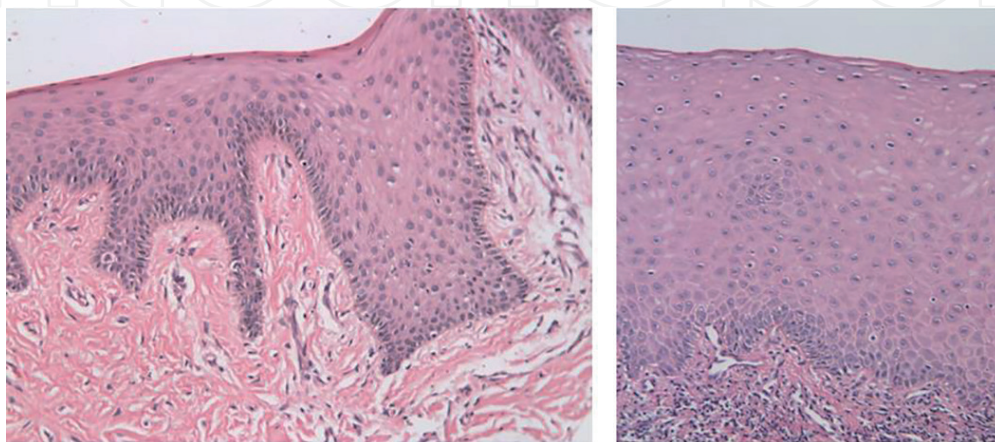


Figure 5.
Pre- and postoperative histopathological photos of local vitamin C injection in treatment of gingival hyperpigmentation [29].

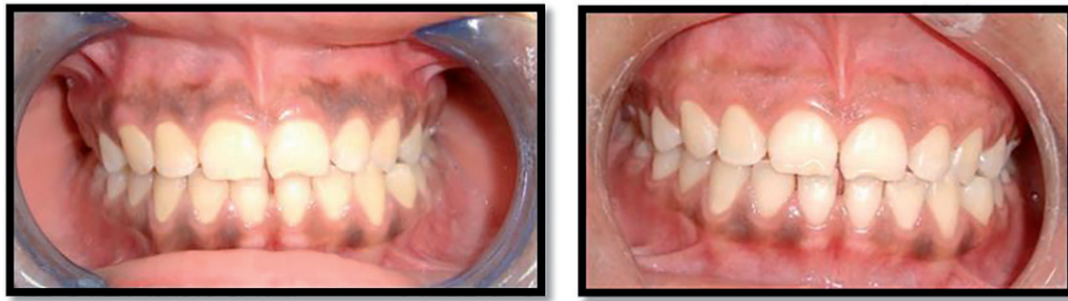

Figure 6.
Pre- and postoperative local vitamin C injection in physiologic gingival hyperpigmentation [29].

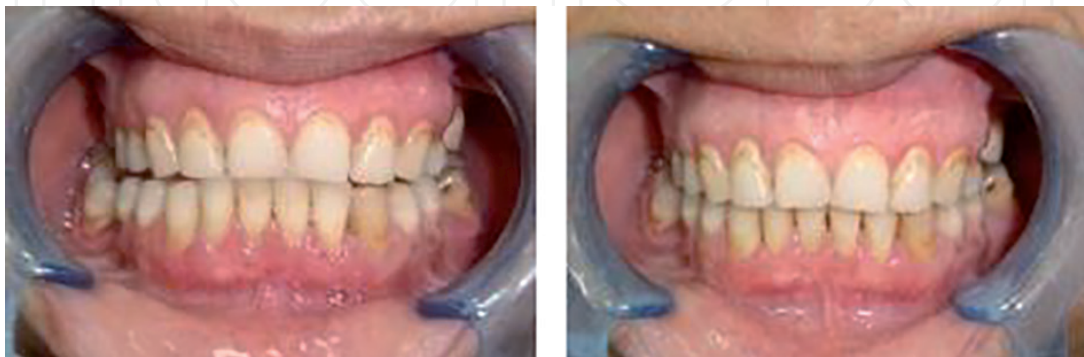

Figure 7.
Pre- and postoperative local vitamin C injection in gingival inflammation [45].

4.4 Autogenous blood products

Platelet-rich plasma (PRP) is defined as a portion of the plasma element of autologous blood having a platelet concentration above baseline [56, 57]. It is considered as a growth factor agonist [58] with both mitogenic and chemotactic properties [56].

It was found that intralesional injection is a newly described method for application of PRP and represents an effective therapeutic option when dealing with non-healing wounds [59]. These findings open the door for using intralesional PRP in oral chronic ulcers. In 2015, El-Komy and his colleagues conducted a pilot study on seven patients suffering from resistant chronic oral pemphigus vulgaris (PV). All patients reported improvement in pain scores, ability to eat, and healing score [60].

In orthodontic therapy, significant improvement was reported following the introduction of local submucosal PRP injection in the pressure side. A single injection of PRP was enough during active orthodontic treatment (just 2 injections; pre and after 6 months). Acceleration of orthodontic tooth movement was reported 1.7-fold when compared to the conventional traction technique [61] (**Figure 8**).

4.5 Hyaluronic acid

Black triangles or insufficient interdental papillae are considered a serious esthetic problem especially in patients with high lip line [62, 63].

Hyaluronic acid is an important component of the extracellular matrix, which has great role in maintaining the health of the oral tissues and healing and repair process. The mechanism of its action depends mainly on stimulating the cellular proliferation, migration, and vasculature and restoring the integrity of epidermal and dermal layer. It is also effective in stimulating collagen formation through enhancing the proliferation of fibroblasts. In dentistry, it is recently used

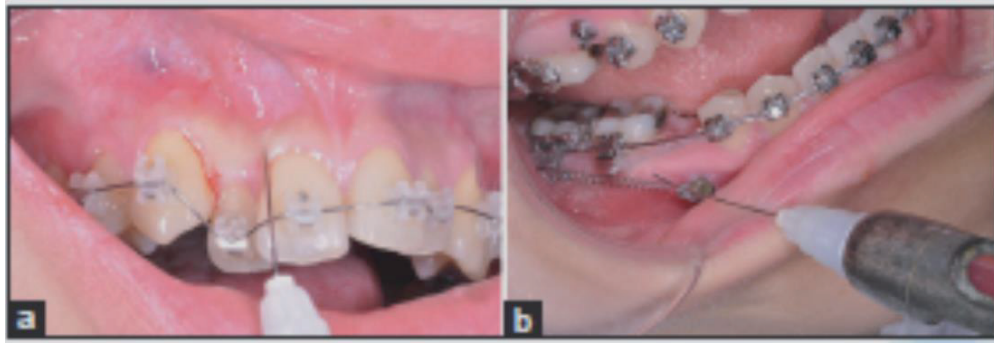


Figure 8.
Submucosal injection of PRP during orthodontic treatment [61].

to accelerate the healing of oral ulcers [64], extraction socket [65], and gingival inflammation [66] either through injection or topical application. It was also used in reconstruction of the interdental papilla as a minimally invasive technique instead of the conventional surgical intervention [67, 68].

4.6 Parathyroid hormone injection

Parathyroid hormone is one of the essential hormones that affect the bone metabolism. It was found that its local injection provides acceleration of the orthodontic tooth movement 1.6 times faster than the normal movement range. A daily local injection of parathyroid hormone (PTH) was also used to induce local bone resorption by reducing the concentration of the gel medium using saline [69, 70].

4.7 Relaxin hormone injection

Relaxin is a specialized hormone which was detected in the periodontal ligament providing proper remodeling of the soft tissue rather than the alveolar bone surrounding teeth. It provides the needed balance of the collagen content in the pressure and tension sites especially during application of forces as orthodontic treatment. It was found that the local injection of relaxin could provide an accelerated tooth movement by reducing the organization of the related periodontal ligaments and increasing the tooth mobility. A weekly injection of 50 μg of relaxin hormone was also found to accelerate tooth movement via soft tissue remodeling, rather than bone, through increasing the collagen at the tension side over its amount in the compression side. It also decreases the organization of the periodontal ligaments surrounding the tooth causing extra mobility [70–72].

4.8 Prostaglandin injection

Prostaglandin is one of the most important inflammatory mediators that is usually secreted during the inflammatory process. It is also considered as a paracrine hormone which affects mainly bone resorption level around the teeth by affecting the osteoclastic activity. It was found that its local application provides 1.6-fold of accelerated tooth movement than the normal range. Formerly, exogenous single or multiple prostaglandin injections were used [70, 73, 74].

4.9 Simvastatin

Simvastatin is a chemical agent that is usually used to reduce the serum cholesterol level. It was found that it has a positive, stimulatory effect to the bone by stimulation

of bone growth factors (e.g., BMP-2). On local injection, it was found that simvastatin could efficiently treat the infrabony defects and furcation defects and be used for guided bone regeneration. The injection visits could range from one to three times with 0.5–2 ml per visit. It is considered a successful nonsurgical treatment approach [75] (**Figure 9**).

4.10 Bone morphogenic proteins (BMPs)

In orthopedics, recombinant BMPs were commonly used during distraction of long bones in order to accelerate osteogenic potentials, increase bone volume (both width and height), improve bone density, and reduce relapse possibilities. BMP-2 was commonly used with or without delivery systems as collagen sponge and chitosan hydrogel in sequential injections [75, 76] (**Figure 10**).

4.11 Combinations

Hyaluronidase is one of the proteolytic enzymes that are providing a physiologic limiting factor for intercellular cement substance, hyaluronic acid. It was used in the treatment of submucous fibrosis by promoting the lysis of accumulated fibrous tissues and relieving the stiffness of tissues by intralesional injection. It provides a rapid short-term improvement [29, 78]. In addition, corticosteroids could be combined with bisphosphonates in the treatment of central giant cell lesions with neither recurrence nor clinical side effects being detected [27].

Steroids are well-known immunosuppressive agents which offer a control of the inflammation. Up till now, different types of cortisone were used to undergo the needed outcome as triamcinolone and dexamethasone. Despite its potency, it was preferred because of its cost-effectiveness. Single-dose injection per week was needed till improvement is detected, which may extend to 4 months. Progression could be detected after two injections [29, 77].

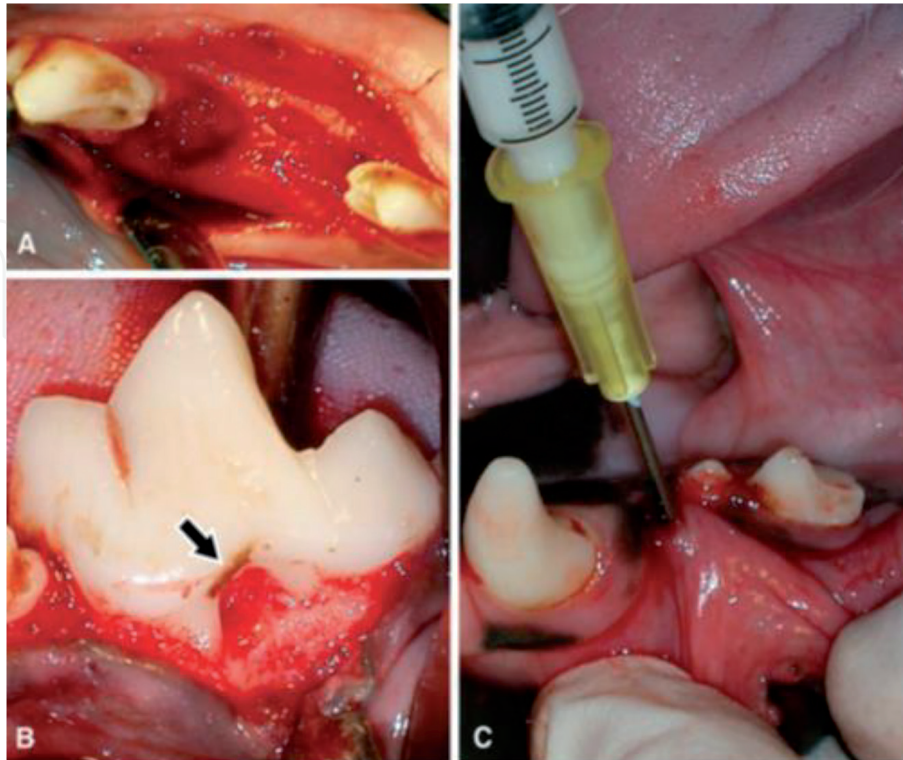


Figure 9.
Simvastatin injection [75].

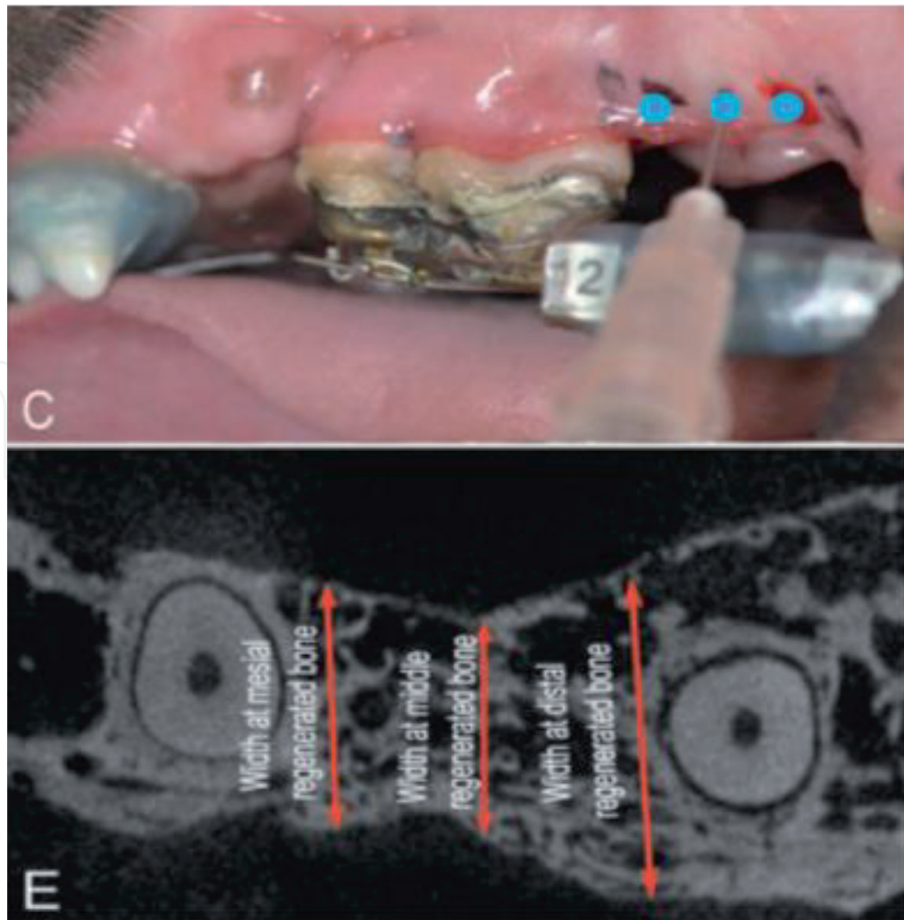


Figure 10.
Bone morphogenic protein injection [75].

The usage of hyaluronidase and cortisone injection combination provides long-term improvement of the signs and symptoms associated with such diseases, bringing sensation, ulceration, and pain [29, 77].

5. Oral mesotherapy injection protocol

According to literature, up till now there is no definite protocol for dermal mesotherapy. In the oral cavity, it was more difficult to add specific rules due to the presence of multiple geometry, types, and dimensions of tissues as gingiva, buccal mucosa, palate, tongue, etc.; we have tried to establish guidelines for general practitioners and beginners.

- Oral mesotherapy technique needs longer time for practice in order to achieve better results.
- Only minute quantities of injectable agent ranging between 0.05 and 0.1 ml/point are permissible according to the range of the injected tissue expansion.
- In 1965, *Woodard* recommended that the pH of any injected material should range between 4.5 and 8.0. Local injections show lower rate of buffering capacity than intravenous and intramuscular route. During oral mesotherapy injection, higher pH is preferred.

- The used needle has to be short, beveled. The needle's gauge should range between 25 and 30.
- Numerous sites for administration of different injectable products are still acceptable till now. The buccal mucosa, buccal vestibule, palate, labial gingival tissues, interdental papilla, and tongue are the most common sites for local injections.
- On the contrary to the skin, oral mucosa is always wet. Surface cleaning and dryness using dry gauze is recommended without the usage of surface disinfectant. Local anesthetic or analgesic agent (specific for intraoral usage) is also recommended accompanying the usage of specific agents as vitamin C due to its nature as a weak acid. In general, the usage of any injectable agent causes local inflammation and induces pain and itching.
- Preoperative treatment plan and patient preparation are the most important steps in the whole treatment procedure. Detailed patient's medical history is an important issue. The target tissue should be free of infection and clean. Two visits for periodontal debridement are recommended; the first is preferred to be performed 2 weeks prior to the procedure, while the other is usually performed prior to the injection visit especially if the injection will be more related to the teeth. The patient should be instructed to keep away from vitamin E and aspirin 1 week before the injection session. After the session, the patient must be instructed that discomfort or burning could occur for 20 minutes. Analgesics are not permitted.

6. Complications and criticism of mesotherapy

The main complications reported in this technique include ulceration, bleeding, infections, allergy, abscess, hyperpigmentation, and swelling related to the area to be injected [78, 79]. The main problems of mesotherapy are the lack of training of the practitioner, the difficulty to be evaluated except with biopsy, the inability to diagnose and treat a complication, and the lack of standardized dosage or formulation [1].

Author details

Nermin Yussif^{1,2,3}

1 NILES, Cairo University, Cairo, Egypt

2 Periodontology Department, Faculty of Dentistry, Cairo University, Cairo, Egypt

3 Periodontology Department, Faculty of Dentistry, MSA University, Giza, Egypt

*Address all correspondence to: dr_nermin_yusuf@yahoo.com

IntechOpen

© 2019 The Author(s). Licensee IntechOpen. This chapter is distributed under the terms of the Creative Commons Attribution License (<http://creativecommons.org/licenses/by/3.0>), which permits unrestricted use, distribution, and reproduction in any medium, provided the original work is properly cited. 

References

- [1] Materasso A, Pfeifar T. Mesotherapy for body contouring. *Plastic and Reconstructive Surgery*. 2005;**115**:1420-1424
- [2] Mammucari M, Gatti A, Maggiori S, Bartoletti C, Sabato A. Mesotherapy, definition, rationale and clinical role: A consensus report from the Italian society of mesotherapy. *European Review for Medical and Pharmacological Sciences*. 2011;**15**:682-694
- [3] Adelson H. French mesotherapy for the treatment of pain. *Bulletin SFM*. 2006;**4**:57
- [4] Herreros F, de Moraes A, Velho P. Mesotherapy: A bibliographical review. *Anais Brasileiros de Dermatologia*. 2011;**86**(1):96-101
- [5] Binaglia L, Marconi P, Pitzurra M. The diffusion of intradermally administered procaine. *Journal of Mesotherapy*. 1981;**1**:15-28
- [6] American Society of Plastic Surgeons (ASPS) guiding principles for mesotherapy. 2008;**7**(8)
- [7] Menkes C et al. Controlled trial of injectable diclofenac in mesotherapy for the treatment of tendinitis. *Bulletin SFM*. 2002;**4**:250-252
- [8] Palermo S et al. Mesotherapy association in the therapy of cervicobrachialgia. *Minerva Anestesiologica*. 1991;**57**:1084-1085
- [9] Rutunda A, Kolodney M. Mesotherapy and phosphatidylcholine injections: Historical clarification and review. *Dermatologic Surgery*. 2006;**32**:465
- [10] Bryant R. Aloe vera: Nature's soothing healer to periodontal disease - controversial mesotherapy. *Dermatology Times*. 2004;**25**(1):4-8
- [11] Sivagnanam G. Mesotherapy—The French connection. 2010;**1**(1):4-8
- [12] Achar S, Kundu S. Principles of office anesthesia: Part I. Infiltrative anesthesia. *American Family Physician*. 2002;**66**(1):91-94
- [13] McGee D. Local and topical anesthesia. In: Roberts JR, Hedges J, editors. *Clinical Procedures in Emergency Medicine*. 4th ed. Philadelphia, PA: WB Saunders; 2004. pp. 533-551
- [14] Heavner J. Local anesthetics. *Current Opinion in Anaesthesiology*. 2007;**20**(4):336-342
- [15] Tsirlis A, Iakovidis D, Parisis N. Dry socket: Frequency of occurrence after intra-ligamentary anesthesia. *Quintessence International*. 1992;**23**(8):575-577
- [16] Meechan J, Thomason J. A comparison of 2 topical anesthetics on the discomfort of intraligamentary injections: A double-blind, split-mouth volunteers clinical trial. *Oral Surgery, Oral Medicine, Oral Pathology, and Oral Radiology*. 1999;**87**(3):62-65
- [17] Lalabonova P, Kirova D, Dobрева D. Intraligamentary anesthesia in general dental practice. *Hristina Journal of IMAB—Annual Proceeding*. 2005;**11**:22-24
- [18] Gazal G, Fareed W, Zafar M. Role of intraseptal anesthesia for pain-free dental treatment. *Saudi Journal of Anesthesia*. 2010;**10**(1):81-86
- [19] Tom K, Aps J. Intraosseous anesthesia as a primary technique for local anesthesia in dentistry. *Clinical Research in Infectious Diseases*. 2015;**2**(1):1012
- [20] Masthan K, Aravindhya BN, Jha A, Elumalai M. Steroids application in oral

- diseases. *International Journal of Pharma and Bio Sciences*. 2013;4:829-834
- [21] Xia J, Li C, Hong Y, Yang L, Huang Y, Cheng B. Short-term clinical evaluation of intralesional triamcinolone acetonide injection for ulcerative oral lichen planus. *Journal of Oral Pathology and Medicine*. 2006;35(6):327-331
- [22] Singh M, Niranjana H, Mehrotra R, Sharma D, Gupta S. Efficacy of hydrocortisone acetate/hyaluronidase vs triamcinolone acetonide/hyaluronidase in the treatment of oral submucous fibrosis. *The Indian Journal of Medical Research*. 2010;131:665-669
- [23] Schlosser B. Lichen planus and lichenoid reactions of the oral mucosa. *Dermatologic Therapy*. 2010;23:251-267
- [24] Baharvand M, Sabounchi S, Mortazavi H. Treatment of labial mucocele by intralesional injection of dexamethasone: Case series. 2014;3:128-133
- [25] Javali M, Tapashetti R, Deshmukh J. Esthetic management of gingival hyperpigmentation: Report of two cases. *International Journal of Dental Clinics*. 2011;3(2):115-116
- [26] da Silva NG, Carreira S, Pedreira E, Tuji F, Ortega K, Pinheiro J. Treatment of central giant cell lesions using bisphosphonates with intralesional corticosteroid injections. *Head and Face Medicine*. 2012;8:23
- [27] Fedele S, Fung P, Bamashmous N, Petrie A, Porter S. Long-term effectiveness of intralesional triamcinolone acetonide therapy in orofacial granulomatosis: An observational cohort study. 2014:794-801
- [28] Goswami R, Gangwani A, Bhatnagar S, Singh D. Comparative study of oral nutritional supplements vs intralesional triamcinolone and hyaluronidase in oral submucous fibrosis. *International Journal of Medical Research and Review*. 2014;2(2):114-118
- [29] Yussif N, Zayed S, Hasan S, Sadek S. Evaluation of injectable vitamin C as a depigmenting agent in physiologic gingival melanin hyperpigmentation: A clinical trial. 2016;8(6):113-120
- [30] Amano Y, Komiyama K, Makishima M. Vitamin D and periodontal disease. *Journal of Oral Science*. 2009;51(1):11-20
- [31] Liu K, Meng H, Lu R, Xu L, Zhang L, Chen Z, et al. Initial periodontal therapy reduced systemic and local 25-hydroxy vitamin D3 and interleukin-1b in patients with aggressive periodontitis periodontal inflammation. *Journal of Periodontology*. 2010;81:260-266
- [32] Zhang X, Meng H, Xu L, Zhang L, Shi D, Feng X, et al. Vitamin D-binding protein levels in plasma and gingival crevicular fluid of patients with generalized aggressive periodontitis. *International Journal of Endocrinology*. 2014;783575:1-6
- [33] Van der Velden U, Kuzmanova D, Chapple I. Micronutritional approaches to periodontal therapy. *Journal of Clinical Periodontology*. 2011;38(11):142-158
- [34] Al-Hasani N, Al-Bustani A, Ghareeb M, Hussain S. Clinical efficacy of locally injected calcitriol in orthodontic tooth movement. *International Journal of Pharmacy and Pharmaceutical Sciences*. 2011;3(5):139-143
- [35] Yussif N, Korany N, Abbass M. Evidence of the effect of intraepidermic vitamin C injection on melanocytes and keratinocytes in gingival tissues: In vivo study. *Dentistry*. 2017;7(3):2-6

- [36] Collins M, Sinclair P. The local use- of vitamin D to increase the rate of orthodontic tooth movement. *American Journal of Orthodontics and Dentofacial Orthopedics*. 1988;**94**:278-284
- [37] Yussif NM, El-Mahdi FM, Wagih R. Hypothyroidism as a risk factor of periodontitis and its relation with vitamin D deficiency: Mini-review of literature and a case report. *Clinical Cases in Mineral and Bone Metabolism*. 2017;**14**(3):312-316
- [38] Kuzmanova D, Jansen I, Schoenmaker T, Nazmi K, Teeuw W, Bizzarro S, et al. Vitamin C in plasma and leucocytes in relation to periodontitis. *Journal of Clinical Periodontology*. 2012;**39**:905-912
- [39] Padayatty S, Katz A, Wang Y, Eck P, Kwon O, Lee J, et al. Vitamin C as an antioxidant: Evaluation of its role in disease prevention. *Journal of the American College of Nutrition*. 2003;**22**(1):18-35
- [40] Shimada Y, Tai H, Tanaka A, Ikezawa-Suzuki I, Takagi K, Yoshida Y, et al. Effects of ascorbic acid on gingival melanin pigmentation in vitro and in vivo. *Journal of Periodontology*. 2009;**80**:317-323
- [41] Chase C. Common complications and adverse reactions. *Bulletin SFM*. 2005;**10**(8)
- [42] Strause L, Saltman P, Glowacki J. The effect of deficiencies of manganese and copper on osteoinduction and on resorption of bone particles in rats. *Calcified Tissue International*. 1987;**41**(3):145-150
- [43] De Laurenzi V, Melino G, Savini I, Annicchiarico-Petruzzelli M, Finazzi-Agrò A, Avigliano L. Cell death by oxidative stress and ascorbic acid regeneration in human neuroectodermal cell lines. *European Journal of Cancer*. 1995;**31A**(4):463-466
- [44] Miresmaeili A, Mollaei N, Azar R, Farhadian N, Kashani K. Effect of dietary vitamin C on orthodontic tooth movement in rats. *Journal of Dentistry*. 2015;**12**(6):409-413
- [45] Yussif N, Abdul AM, Abdel RA. Evaluation of the anti-inflammatory effect of locally delivered vitamin C in the treatment of persistent gingival inflammation: Clinical and histopathological study. *Journal of Nutrition and Metabolism*. 2016;**2978741**:1-8
- [46] Aghajanian P, Hall S, Wongworawat M, Mohan S. The roles and mechanisms of actions of vitamin C in bone: New developments. *Journal of Bone and Mineral Research*. 2015;**30**(11):1945-1955
- [47] Jokar A, Farahi F, Asadi N, Salehi M, Foruhari S, Sayadi M. The effect of vitamin C on bone mineral/mass density of menopausal women with equilibrated regime: A randomized clinical trial. *Biomedical Research*. 2015;**26**(2):239-244
- [48] Kippenberger S, Bernd A, Bereiter-Hahn J, Amirez-Bosca A, Kaufmann R. The mechanism of melanocyte dendrite formation: The impact of differentiating keratinocytes. *Pigment Cell Research*. 1998;**11**:34-37
- [49] Tolleson W. Human melanocyte biology, toxicology and pathology. *Journal of Environmental Science and Health*. 2005;**23**:105-161
- [50] Letort V, Fouliard S, Letort G, Adanja I, Kumasaka M, Gallagher S, et al. Quantitative analysis of melanocyte migration in vitro based on automated cell tracking under phase contrast microscopy considering the combined influence of cell division and cell-matrix interactions. *Mathematical*

Modelling of Natural Phenomena, EDP Sciences. 2010;5(1):4-33

[51] Schmelz M. Translating nociceptive processing into human pain models. *Experimental Brain Research*. 2009;196(1):173-178

[52] Mohammed BM, Fisher BJ, Huynh QK, et al. Resolution of sterile inflammation: Role for vitamin C. *Mediators of Inflammation*. 2014;2014:Article ID:173403

[53] Daniels A, Jefferies S. Analysis of capacity of novel, anti-oxidant tooth paste, small population clinical study: Comparison to levels of gingival inflammation reduction reported in historical control and therapeutic tooth brushing studies. 2003

[54] Shimabukuro Y, Nakayama Y, Ogata Y, Tamazawa K, Shimauchi H, Nishida T, et al. Effects of an ascorbic acid derivative dentifrices in patients with gingivitis: A double masked, randomized, controlled clinical trial. *Journal of Periodontology*. 2015;86:27-35

[55] Abraham S, Deepak K, Ambili R, Preeja C, Archana V. Gingival biotype and its clinical significance: A review. *The Saudi Journal for Dental Research*. 2014;5:3-7

[56] Marx R. Platelet-rich plasma (PRP): What is PRP and what is not PRP? *Implant Dentistry*. 2001;10:225-228

[57] Mehta S, Watson J. Platelet rich concentrate: Basic science and current clinical applications. *Journal of Orthopaedic Trauma*. 2008;22:432-438

[58] Petrova N, Edmonds M. Emerging drugs for diabetic foot ulcers. *Expert Opinion on Emerging Drugs*. 2006;11:709-724

[59] Wasterlain AS, Braun HJ, Harris AH, Kim HJ, Dragoo JL. The systemic

effects of platelet-rich plasma injection. *American Journal of Sports Medicine*. 2013;41(1):186-193. DOI: 10.1177/0363546512466383. Epub 2012 Dec 4

[60] El-Komy M, Hassan A, Raheem H, Doss S, El-Kaliouby M, Saleh N, et al. Platelet-rich plasma for resistant oral erosions of *Pemphigus vulgaris*: A pilot study. *Wound Repair and Regeneration*. 2015;23:953-955

[61] Liou E. The development of submucosal injection of platelet rich plasma for accelerating orthodontic tooth movement and preserving pressure side alveolar bone. *APOS Trends in Orthodontics*. 2016;6:5-11

[62] McGuire MK, Scheyer ET. A randomized, double-blind, placebo-controlled study to determine the safety and efficacy of cultured and expanded autologous fibroblast injections for the treatment of interdental papillary insufficiency associated with the papilla priming procedure. *Journal of Periodontology*. 2007;78(1):4-17

[63] Mansouri S, Ghasemi M, Salmani Z, Shams N. Clinical application of hyaluronic acid gel for reconstruction of interdental papilla at the esthetic zone. *The Journal of Islamic Dental Association of IRAN (JIDA)*. 2013;25(2):191-196

[64] Nolon A, Baillie C, Badminton J, Rudralinglam M, Seymour R. The efficacy of topical hyaluronic acid in the management of recurrent aphthous ulceration. *Journal of Oral Pathology and Medicine*. 2006;35(8):461-465

[65] Mendes R, Silva G, Lima M, Calliari M, Almeida A, Alves J, et al. Sodium hyaluronate accelerates the healing process in tooth sockets of rats. *Archives of Oral Biology*. 2008;53(12):1155-1162

- [66] Jentsch H, Pomowski R, Kundt G, Göcke R. Treatment of gingivitis with hyaluronan. *The Journal of Clinical Periodontology*. 2003;**30**(2):159-164
- [67] Becker W, Gabitov I, Stepanov M, Kois J, Smidt A, Becker B. Minimally invasive treatment for papillae deficiencies in the esthetic zone: A pilot study. *Clinical Implant Dentistry and Related Research*. 2010;**12**(1):1-8
- [68] Mansouri SS, Ghasemi M, Salmani Z, Shams N. Clinical application of hyaluronic acid gel for reconstruction of interdental papilla at the esthetic zone. *Journal of Islamic Dental Association of Iran*. 2013;**25**:152-157
- [69] Soma S, Matsumoto S, Higuchi Y, Takano-Yamamoto T, Yamashita K, Kurisu K, et al. Local and chronic application of PTH accelerates tooth movement in rats. *Journal of Dental Research*. 2000;**79**(9):1717-1724
- [70] Nimeri G, Kau C, Abou-Kheir N, Corona R. Acceleration of tooth movement during orthodontic treatment—A frontier in orthodontics. *Progress in Orthodontics*. 2013;**14**:42
- [71] Liu Z, King G, Gu G, Shin J, Stewart D. Does human relaxin accelerate orthodontic tooth movement in rats? *Annals of the New York Academy of Sciences*. 2005;**1041**:388-394
- [72] McGorray S, Dolce C, Kramer S, Stewart D, Wheeler T. A randomized, placebo-controlled clinical trial on the effects of recombinant human relaxin on tooth movement and short-term stability. *American Journal of Orthodontics and Dentofacial Orthopedics*. 2012;**141**(2):196-203
- [73] Yamasaki K, Shibata Y, Imai S, Tani Y, Shibasaki Y, Fukuhara T. Clinical application of prostaglandin E1 (PGE1) upon orthodontic tooth movement. *American Journal of Orthodontics*. 1984;**85**(6):508-518
- [74] Seifi M, Eslami B, Saffar AS. The effect of prostaglandin E2 and calcium gluconate on orthodontic tooth movement and root resorption in rats. *European Journal of Orthodontics*. 2003;**25**(2):199-204
- [75] Morris M, Lee Y, Lavin MT, Giannini PJ, Schmid MJ, Marx DB, et al. Injectable simvastatin in periodontal defects and alveolar ridges: Pilot studies. *Journal of Periodontology*. 2008;**79**:1465-1473
- [76] Terbish M, Yoo S, Kim H, Yu H, Hwang C, Baik H, et al. Accelerated bone formation in distracted alveolar bone after injection of recombinant human bone morphogenetic protein-2. *Journal of Periodontology*. 2015;**86**:1078-1086
- [77] James L, Shetty A, Rishi D, Abraham M. Management of oral submucous fibrosis with injection of hyaluronidase and dexamethasone in grade III oral submucous fibrosis: A retrospective study. *Journal of International Oral Health*. 2015;**7**(8):1-4
- [78] Davis M, Wright T, Shehan J. A complication of mesotherapy: Noninfectious granulomatous panniculitis. *Archives of Dermatology*. 2008;**144**:808
- [79] Conforti G, Capone L, Corra S. Intradermal therapy (mesotherapy) for the treatment of acute pain in carpal tunnel syndrome: A preliminary study. *The Korean Journal of Pain*. 2014;**27**(1):49-53