

We are IntechOpen, the world's leading publisher of Open Access books Built by scientists, for scientists

4,800

Open access books available

122,000

International authors and editors

135M

Downloads

Our authors are among the

154

Countries delivered to

TOP 1%

most cited scientists

12.2%

Contributors from top 500 universities



WEB OF SCIENCE™

Selection of our books indexed in the Book Citation Index
in Web of Science™ Core Collection (BKCI)

Interested in publishing with us?
Contact book.department@intechopen.com

Numbers displayed above are based on latest data collected.
For more information visit www.intechopen.com



A Retrospective Analysis of Amputation Risk Due to Diabetic Foot and Angioplasty and Free Flap Transfer to Reduce Major Amputation

Masaki Fujioka

Abstract

Foot ulceration in persons with diabetes is the most frequent precursor to amputation, which impairs their activities. The aim of this chapter is to describe factors that lead to amputation of a diabetic foot, and propose a management strategy to prevent major amputation. I analyzed 233 patients who were admitted at the National Nagasaki Medical Center between 2008 and 2017 with foot ulcer and/or infection. We divided them into two groups: 152 patients with diabetes mellitus (DM) and 81 without DM. We analyzed their laboratory data, and evaluated the wound severity, complications of peripheral artery disease (PAD) and renal failure, and infection. Patients with DM ulcer were significantly more likely to receive amputation. Patients with DM were significantly more likely to develop infection, and tended to undergo emergency debridement. Among the patients with DM, the amputation group (85) showed significantly higher levels of CRP and WBC, and was more likely to develop infection, PAD, and renal failure. My results suggest that risk factors leading to leg amputation are severe infection and reduction of arterial blood flow. Early debridement to reduce infectious inflammation and angioplasty following free flap transfer are recommended to preserve legs.

Keywords: diabetic foot, diabetic gangrene, leg amputation, angioplasty, free flap transfer

1. Introduction

In the past four decades, over 42–56% of major lower extremity amputations in the United States and Western European countries have been due to diabetes mellitus (DM) [1–4]. The relative risk of major leg amputations for diabetes ranges from 5.1 to 31.5 times in comparison with that of nondiabetic populations [5, 6]. Extensive efforts have been made to improve the treatment of diabetes in regard to glycemic control and the prevention of diabetic complications, and foot ulcer treatments have improved for diabetic patients [7, 8]. Before 2004, trauma accounted for most amputations in the majority of hospitals, followed by malignancies [9]. However, the most common cause of amputation at present is diabetes mellitus [10, 11].

Amputation is the most appropriate therapy for an ischemic or infected limb, but the level at which to amputate is often difficult to determine. Patients who undergo only toe or trans-metatarsal amputation can walk on their own feet; however, those with major amputation require an artificial leg or a cane, which impairs their activities [12, 13]. The aim of this chapter is to describe factors that lead to amputation of a diabetic foot and propose a management strategy to prevent major amputation.

2. Materials and methods

A retrospective descriptive study including 152 diabetic patients among 233 patients with leg ulcers who were treated in our medical center was carried out between January 2008 and December 2017. All patients had been diagnosed with type II diabetes. Diabetic foot ulcers represent more than 65 percent of all leg ulcers.

To clarify the clinical characteristics of the diabetic foot, a comparison of foot ulcer patients with and without diabetes mellitus is conducted first, risk factors leading to amputation in cases of diabetic foot ulcer and “major” amputation in cases of diabetic foot are discussed, and a recommended strategy to avoid major leg amputation is presented.

Statistical analysis was performed using the *Wilcoxon signed-rank test and chi-square test*. The *value of $p < 0.05$* was determined as *significant*.

The ethical committee of our medical center approved this study.

3. Results

3.1 Comparison of foot ulcer patients with and without diabetes mellitus

Profiles of foot ulcer patients with and without diabetes mellitus are shown in **Table 1**. Of the 233 patients with a foot ulcer, 63% (147) were men, and 37% (86) were women. Of course, levels of HbA1C and blood sugar in the diabetic foot group were significantly higher than those in the nondiabetic foot group, and men were more likely to develop leg ulcers in the diabetic patient group. There were no significant differences in CRP, WBC, serum albumin, or hemoglobin between the groups.

The severity of leg ulcers at discovery in patients with and without diabetes mellitus is shown in **Table 2**. In the groups, the ulcer stage based on the Wagner classification showed similar tendencies. About 80% of the diabetic foot group developed infection, being a significantly higher rate than in the nondiabetic foot. Methicillin-resistant *Staphylococcus aureus* (MRSA), methicillin-susceptible *Staphylococcus aureus* (MSSA), and *Streptococcus* were ranked high and accounted for over three-quarters of infections in both groups (**Figure 1**).

Because patients with diabetes are likely to develop severe infection, more than 50% of foot ulcer patients with diabetes required immediate debridement surgery, being a significantly higher rate than in the nondiabetic foot group (25%) (**Figure 2**).

The frequencies of peripheral artery disease in foot ulcer patients with and without diabetes were 38.2 and 34.6%, respectively. There were no significant differences between the groups.

The frequencies of hemodialysis in patients with and without diabetes were 7.2 and 6.2%, respectively. There were no significant differences between the groups.

	Diabetic foot ulcer (152)	Non-diabetic foot ulcer (81)	P-value
Male/Female	104/48	43/38	P<0.05*
Age	66.3±14.0	65.0±17.1	0.11
Hb A1C (%)	8.7±2.6	5.4±0.8	p<0.001
Blood Sugar (mg/L)	258.5±127.8	119.5±6.4	p<0.001
CRP (mg/L)	128.2±90.6	110.9±89.8	0.24
WBC (× 10⁹/L)	12.1±7.1	11.5±5.5	0.83
S-Albumin (g/dL)	2.9±0.8	3.3±1.2	0.05
Hemoglobin (g/dL)	10.8±2.5	11.0±2.1	0.98
Hospitalization period (days)	39.6±36.6	32.1±32.6	0.45

(Wilcoxon rank sum test *: Chi-squared test)

Table 1.
Profile of foot ulcer patients with and without diabetes mellitus.

Wagner Classification	Diabetic foot ulcer (152)	Non-diabetic foot ulcer(81)	P-value Chi-squared test
1 (superficial ulcer)	14(9.2%)	9(11.1%)	P>0.05
2 (deep ulcer)	24(15.8%)	21(25.9%)	P>0.05
3 (osteomyelitis or abscess)	47(31.0%)	19(23.5%)	P>0.05
4 (forefoot gangrene)	25(16.4%)	13(16.0%)	P>0.05
5 (whole foot gangrene)	42(27.6%)	19(23.4%)	P>0.05

Table 2.
Severity of leg ulcers at discovery in patients with and without diabetes mellitus.

The frequencies of amputation in foot ulcer patients with and without diabetes were 53.9 and 34.6%, respectively. More than half of the patients with diabetes underwent amputation surgery, being a significantly higher rate than that in the nondiabetic foot group (**Figure 3**).

3.2 Comparison of foot ulcer patients with and without diabetes mellitus

We evaluated 85 amputated legs in 152 diabetic foot patients. Sixty-eight percent (104) of the patients were men, and 32% (48) were women. Profiles of diabetic patients with/without leg amputation are shown in **Table 3**.

Men were more likely to require amputation. CRP and WBC were significantly higher, and serum albumin was significantly lower in the major amputation group, suggesting that severe infection and malnutrition are risk factors for major leg amputation in diabetic foot patients.

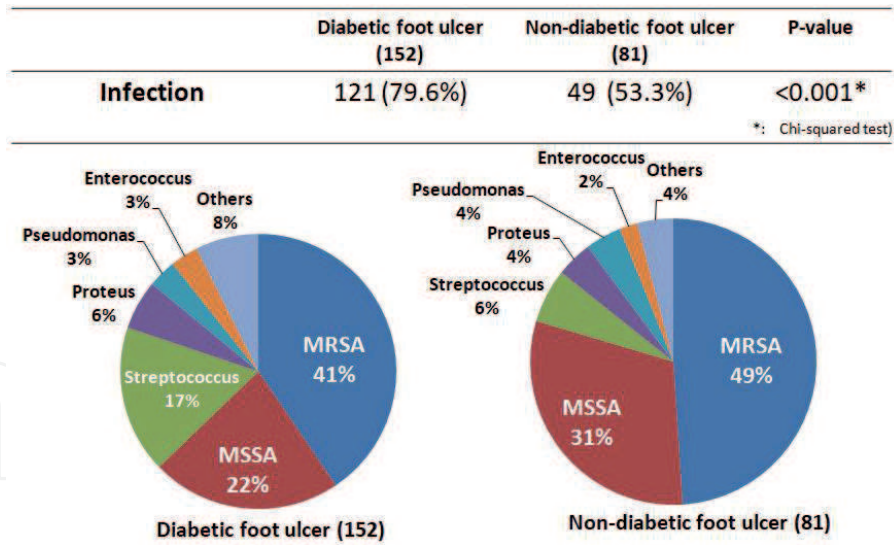


Figure 1. Infection of leg ulcers at discovery in patients with and without diabetes mellitus (MRSA, methicillin-resistant *Staphylococcus aureus*; MSSA, methicillin-susceptible *Staphylococcus aureus*).

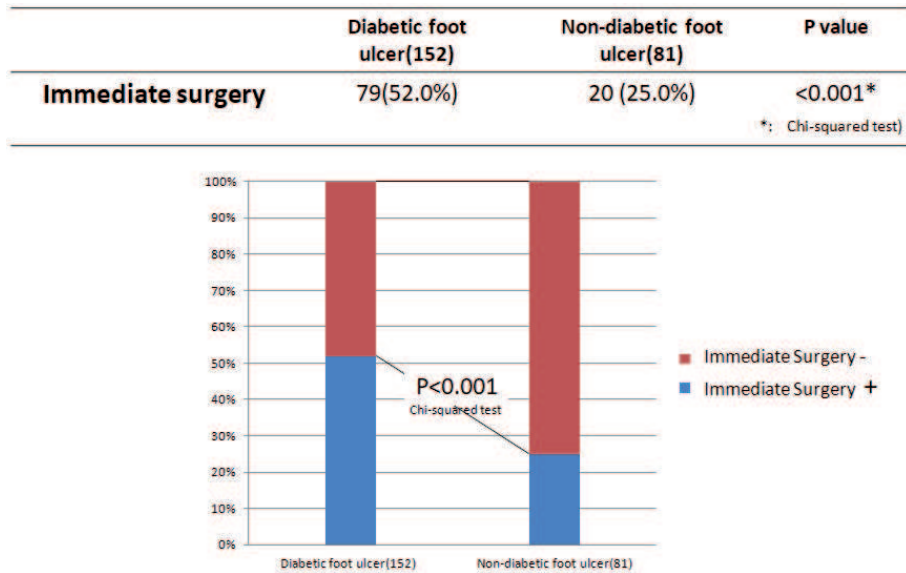


Figure 2. The frequency of foot ulcer patients with and without diabetes, who required immediate debridement surgery.

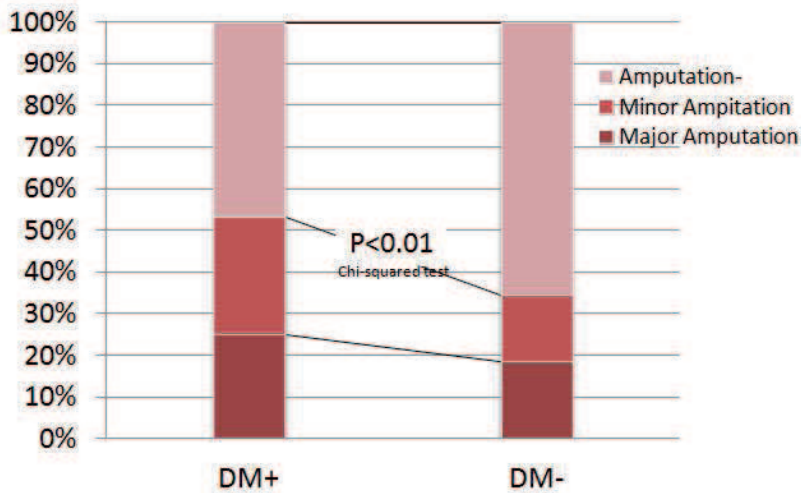


Figure 3. The frequency of amputation in foot ulcer patients with and without diabetes.

	Amputation+ (85)	Amputation- (67)	P-value
Male/Female	61/24	43/24	<0.05*
Age	65.0±17.1	66.3±14.0	0.35
Hb A1C (%)	8.5±2.2	8.8±2.7	0.67
Blood Sugar (mg/L)	251.2±122.6	262.1±129.5	0.90
CRP (mg/L)	202.0±93.1	115.6±89.9	0.001
WBC (× 10 ⁹ /L)	17.1±8.8	10.9±6.1	0.017
S-Albumin (g/dL)	2.5±0.7	3.0±0.8	0.016
Hemoglobin (g/dL)	10.5±2.2	11.0±2.6	0.10

(Wilcoxon rank sum test *: Chi-squared test)

Table 3.
 Profiles of diabetic patients with and without leg amputation.

Sixty-nine (82%) of 85 amputees and 36 (57.6%) of 67 non-amputees with diabetes developed infection, showing a significant difference between the groups. More than half of amputated and only 17.9% of non-amputated patients with diabetes were complicated by peripheral artery disease, showing a significant difference between the groups (**Figure 4**). Furthermore, the frequency of hemodialysis in amputated patients (11.8%) was also significantly higher than that in non-amputated patients (1.5%) (**Figure 5**).

3.3 Comparison of diabetic foot ulcer patients who underwent major and minor leg amputation

Of the 85 amputees with diabetes, 44 patients underwent minor amputation, and 38 received major amputation. Seventy-one percent (58) were men and 29% (24) were women. Profiles of diabetic patients with/without leg amputation are shown in **Table 4**. Men were more likely to require major amputation. CRP and WBC were significantly higher, and serum albumin was significantly lower in the

	Diabetic foot ulcer(152)	Non-diabetic foot ulcer(81)	P value Chi-squared test
Peripheral Artery Disease	58(38.2%)	28 (34.6%)	>0.05*

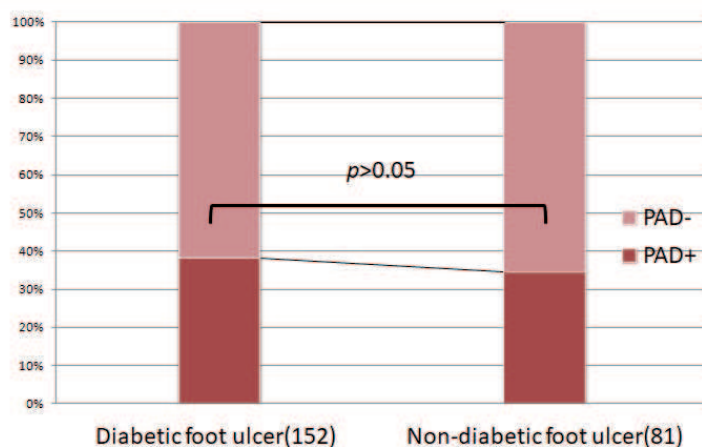


Figure 4.
 The frequency of amputation in diabetic foot ulcer patients with and without peripheral artery disease.

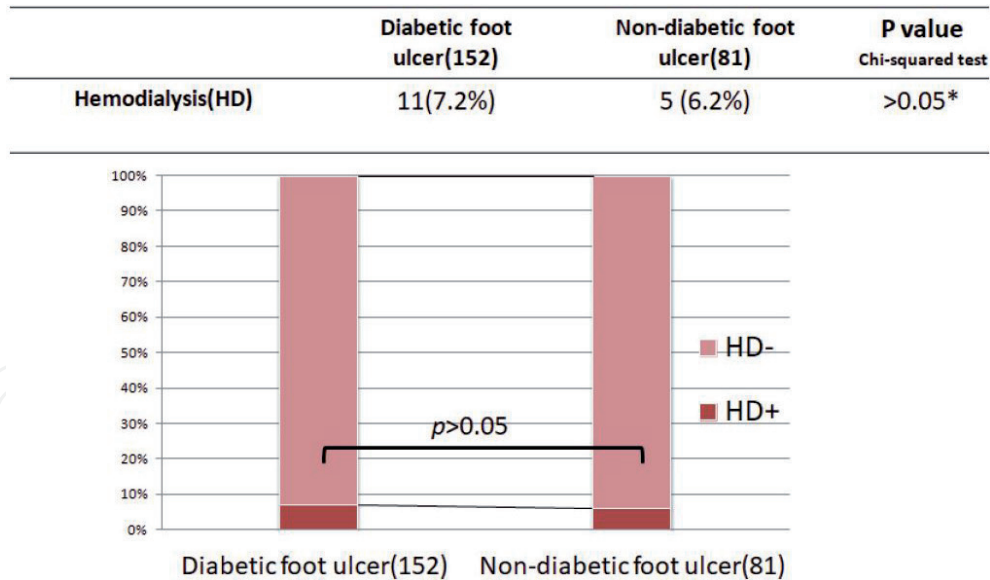


Figure 5.
The frequency of amputation in diabetic foot ulcer patients with and without hemodialysis.

	Major Amputation+ (38)	Minor Amputation- (44)	P-value
Male/Female	31/7	27/17	<0.05*
Age	68.7.0±14.4	65.9±12.5	0.31
Hb A1C (%)	8.5±2.2	9.2±3.2	0.18
Blood Sugar (mg/L)	250.2±121.1	269.6±145.1	0.61
CRP (mg/L)	200.8±92.3	85.4±58.6	<0.001
WBC (× 10 ⁹ /L)	17.0±8.7	9.0±4.8	<0.001
S-Albumin (g/dL)	2.5±0.7	3.1±0.7	0.002
Hemoglobin (g/dL)	10.4±2.2	10.6±2.4	0.50

(Wilcoxon rank sum test * : Chi-squared test)

Table 4.
Profiles of diabetic patients who underwent major and minor leg amputation.

major amputation group, suggesting that severe infection and malnutrition are risk factors for major leg amputation in diabetic foot patients.

4. Risk factors leading to leg amputation and strategy to prevent major amputation

Diabetic foot ulcers sometimes lead to minor or major amputation, with a high impact on patients' life and its quality [14]. Our results suggest that risk factors for leg amputation in diabetic foot patients include male, complication of severe infection, complication of peripheral artery disease, complication of hemodialysis, and malnutrition.

4.1 Improvement of malnutrition

The importance of nutritional support in patients with wounds has been examined. Malnourished patients showed not only a higher frequency of

impaired wound healing but also an increased risk of postoperative cardiopulmonary and septic complications [15, 16]. Malnutrition cannot be improved in a short time after developing foot ulcers. Thus, patients requiring surgical treatment should also receive supplemental nourishment in the perioperative period [17]. Luo et al. suggested that the geriatric nutritional risk index was a reliable and effective predictive marker of patients' amputation-free survival, and it could identify patients early with a high risk of amputation [18]. Appropriate blood sugar control and nutritional support are required for diabetic patients to prevent leg amputation. Malnutrition usually occurs in critical limb ischemia patients as well, because of a lack of appetite and sleeplessness due to chronic pain. These patients with peripheral artery disease also require pain control and nutritional support services [18].

4.2 Foot care for patients undergoing hemodialysis

The number of patients requiring hemodialysis has been growing because obesity-related renal diseases such as diabetes mellitus are increasing [19, 20]. Diabetic patients with renal failure had high risks of foot ulceration and lower limb complications [21]. Regarding cutaneous infection, Bencini et al. reported that the incidence of fungal infection in patients undergoing hemodialysis was 67% [22]. Because chronic renal failure patients exhibit impaired cellular immunity due to a decreased T-lymphocyte cell count, this could explain the increased prevalence of fungal infections [23]. Thus, difficulty healing wounds is a frequent problem in patients on hemodialysis [24]. Amputations of limbs are sometimes performed for these complex ulcers, because when patients receiving hemodialysis develop aggressive life-threatening infections such as sepsis, immediate surgical debridement is required in order to salvage the blood access line and save lives [25]. Fujioka reported that 13 of 17 wounds required immediate surgery, including amputation and debridement in patients with DM, while only 1 of 13 required immediate surgery in patients without DM [26].

Poor management of foot ulcers in patients receiving hemodialysis leads to prolonged ulceration, gangrene, amputation, depression, and death [27].

Marn et al. investigated the association between the implementation of a routine foot check program in diabetic incident hemodialysis patients and concluded that monthly foot checks are associated with a reduction of major lower limb amputations [28]. All patients on hemodialysis should be considered as being at high risk of developing foot complications and undergo foot checks frequently. If infection is suspected, antibiotics should be administered through the dialysis line immediately during dialysis.

4.3 Infection control

Diabetic foot infection is a common diabetic complication, which results in lower limb amputation if not treated properly. Patients with diabetes are likely to develop infections, because of the alteration of immune defense mechanisms such as a change in the neutrophil function, suppression of the antioxidant system, and modified humoral activity due to the hyperglycemic environment [29].

Once a diabetic foot develops infection, it progresses rapidly and requires the removal of all necrotizing tissue involving the bone, tendons, and skin (**Figure 6**).

If the toe infection progresses and spreads widely, the patient may have to undergo major amputation (**Figures 7a and b**). Thus, early and appropriate debridement to reduce infection is important.

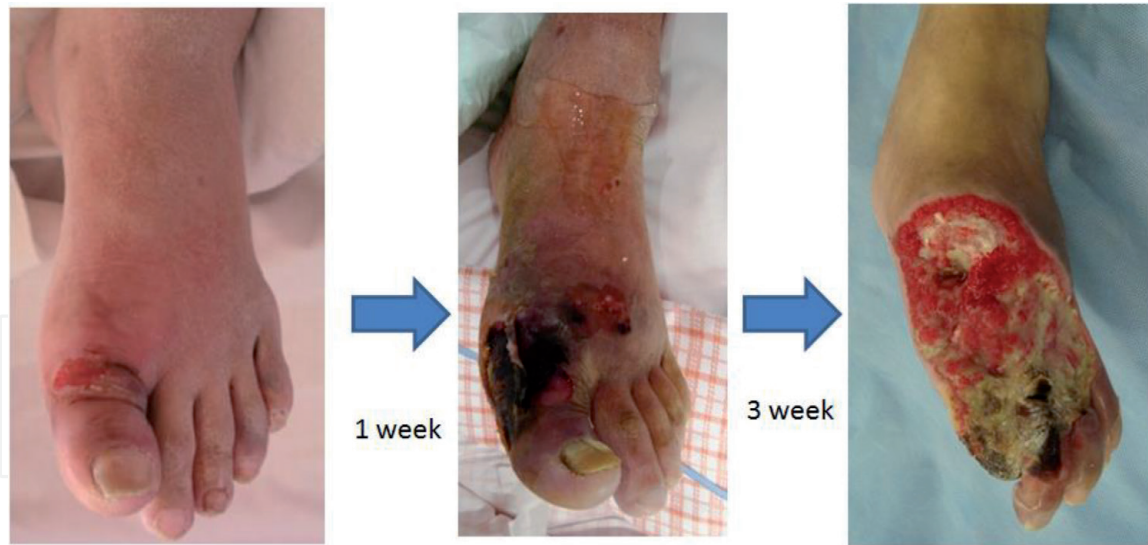

Figure 6.
A view of progressing diabetic infection in the big toe, which aggravated rapidly and required the removal of toes and metatarsal bones within 3 weeks.

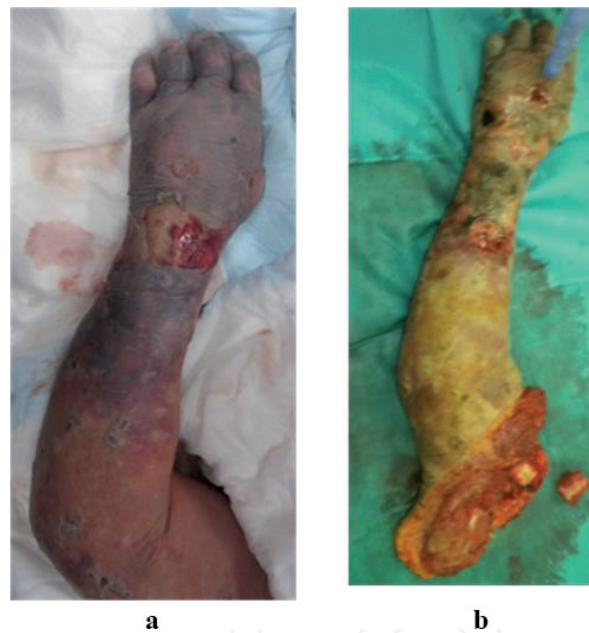

Figure 7.
(a) A view of necrotizing fasciitis in the left forearm at the first examination, which progressed rapidly to the upper arm, and the patient developed septic shock in 2 days. (b) Amputation of the infected hand at the upper arm was immediately performed to control the aggressive infection.

4.3.1 Antibiotic treatment

Soft tissue infections in diabetic patients require multidisciplinary treatment including rapid surgical intervention, antibiotic treatment, and hyperbaric oxygen therapy to restrict the growth of pathogens [30–32]. Antibiotic therapy should be instituted immediately. The initial antibiotic should act on aerobic Gram-positive and Gram-negative bacteria but also on anaerobic bacteria. Systemic antibiotics have been demonstrated in many trials to be effective in treating acute diabetic foot infections. Tchero et al. performed a systematic review to assess the clinical efficacy of antibiotic regimens in the treatment of diabetic foot infections and concluded that piperacillin/tazobactam should be recommended for severe infections and the adjuvant use of topical agents with systemic antibiotics improved the outcomes compared with systemic antibiotics alone [33]. Mustățea et al. suggested that an

initial combination of third-generation cephalosporin, quinolone, and metronidazole was initially administered. After germ identification, antibiotic therapy was administered according to the antibiogram [29]. Cellulitis, which shows inflammation and infection of the skin and subcutaneous tissue, can be treated with systemic Gram-positive bactericidal antibiotics only. However, if deep tissue infection, especially osteomyelitis, is suspected, removal of the infected bone and soft tissue, followed by 2–4 weeks of antibiotics, is required [30].

4.3.2 Surgical debridement

Regarding surgical intervention, early and appropriate debridement to reduce infection is recommended to achieve infection control (**Figure 8**).

If the infection invades deeper to the tendon, the lesions can often be extended and spread upward rapidly along the tendon tract, which can lead to systematic sepsis and require immediate limb amputation (**Figure 9a and b**). As the infection developing in the diabetic patients' limbs progresses rapidly, physicians must decide on whether to carry out debridement before the infected lesion spreads upward.

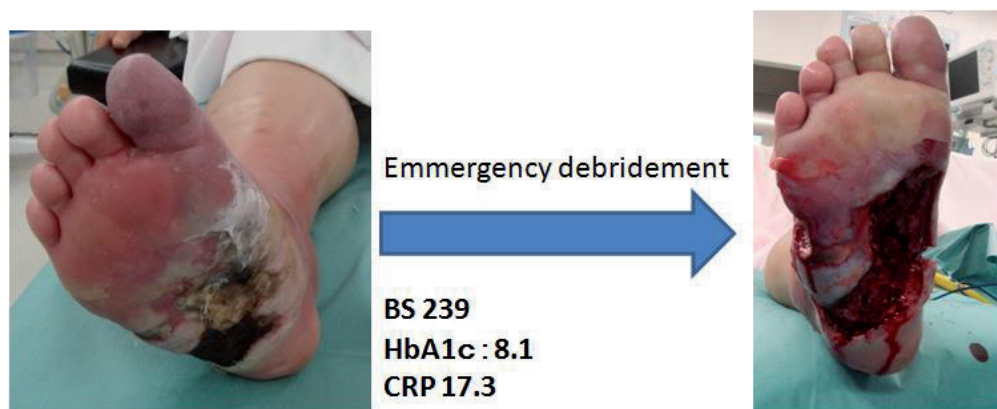


Figure 8.
Views of debridement for necrotizing fasciitis in the diabetic patient's right sole. All necrotizing, contaminated tissue was removed immediately.

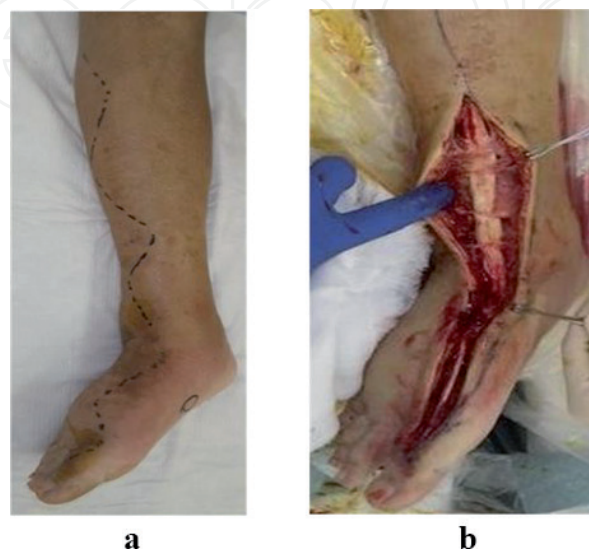


Figure 9.
*(a) A view of necrotizing fasciitis in the right big toe, which spreads upward rapidly.
(b) Intraoperative view showing the contaminated lesion extending along the extensor tendon tract.*

Case presentations

Case 1. A 51-year-old man developed diabetic foot gangrene with osteomyelitis of the fifth toe, which had progressed for 2 weeks (**Figure 10a**). The patient underwent fourth and fifth toe amputation immediately, and cleansing to reduce infection was performed for 2 weeks (**Figure 10b**). As abundant granulation tissue developed on the wound surface, he underwent free skin grafting (**Figure 10c**). The wound had completely resurfaced by 1 month after skin grafting, and the patient could walk without a cane (**Figure 10d**).

4.3.3 Angioplasty for an ischemic foot

Peripheral artery disease (PAD) is observed in up to 50% of patients with a diabetic foot ulcer, and the presence of PAD is an important consideration in their management [34]. PAD affects the distal vessels and results in occlusion, which is one of the major causes of ulcer development and an increased risk of amputation. The treatment for these patients often requires challenging distal revascularization surgery or angioplasty to prevent limb amputation [35]. Revascularization is commonly performed in patients with critical limb ischemia and a diabetic foot ulcer, and the ulcer-healing rate after revascularization ranges from 46 to 91% [36]. Hinchliffe et al. reviewed the effectiveness of revascularization of the ulcerated foot in patients with diabetes and PAD 1 year after surgery and reported that limb salvage rates showed a median of 85% following open surgery, and more than 60% of ulcers had healed following revascularization. They concluded that revascularization improved rates of limb salvage compared with the results of conservatively treated patients [34].

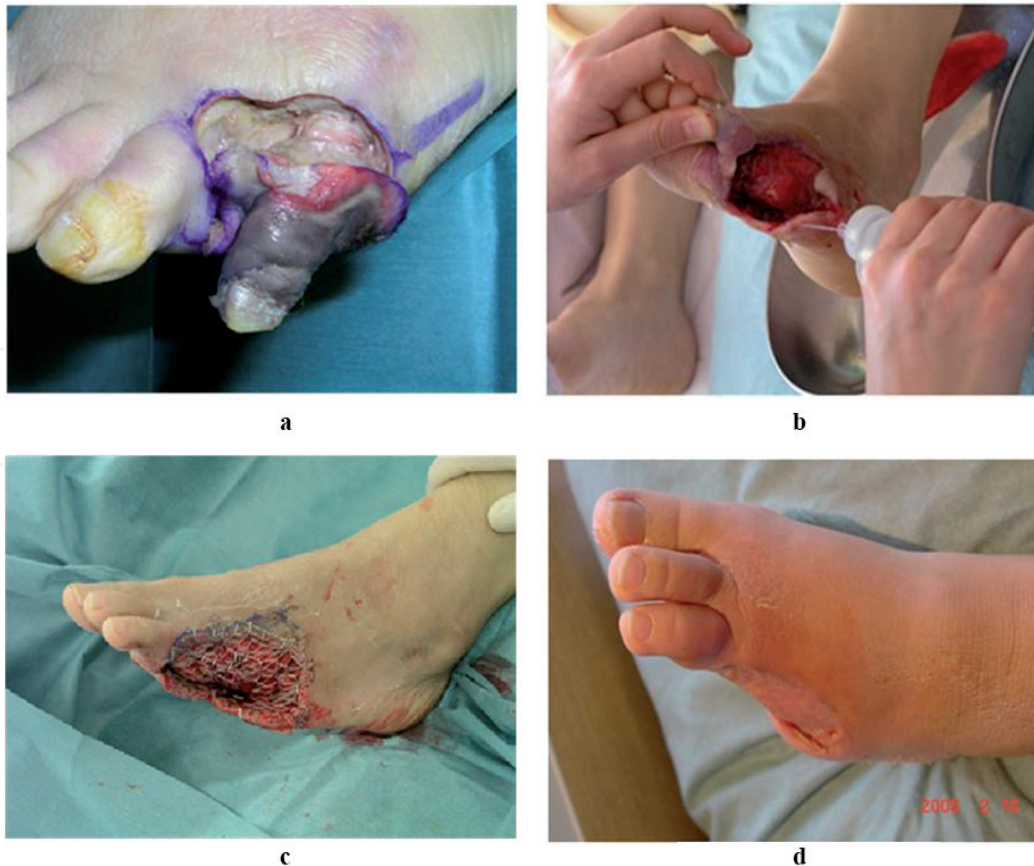


Figure 10. (a) Case 1. A view of diabetic foot gangrene with osteomyelitis of the fifth toe. (b) After fourth and fifth toe amputation, cleansing was performed for 2 weeks. (c) Intraoperative view showing free skin grafting on the wound. (d) A view of the foot 1 month after surgery showing favorable coverage of the wound.

Case presentations

Case 2. A 67-year-old man developed a diabetic foot ulcer of the right heel, which had progressed for 2 months (**Figure 11a**). His posterior tibial artery was not palpable. Enhanced computed tomography (CT) showed that circulation of his right lower leg was poor, with an ankle brachial pressure index (ABI) of only 0.53, which suggested that his leg ulcer might not heal spontaneously. We fashioned femoral-popliteal artery (FP) bypass to increase distal blood flow, and ABI improved to 0.83 (**Figure 11b**). As the patient's foot received sufficient flow, he could safely undergo resurfacing surgery using a reversed sural flap successfully and could walk 3 months after surgery (**Figure 11c-f**).

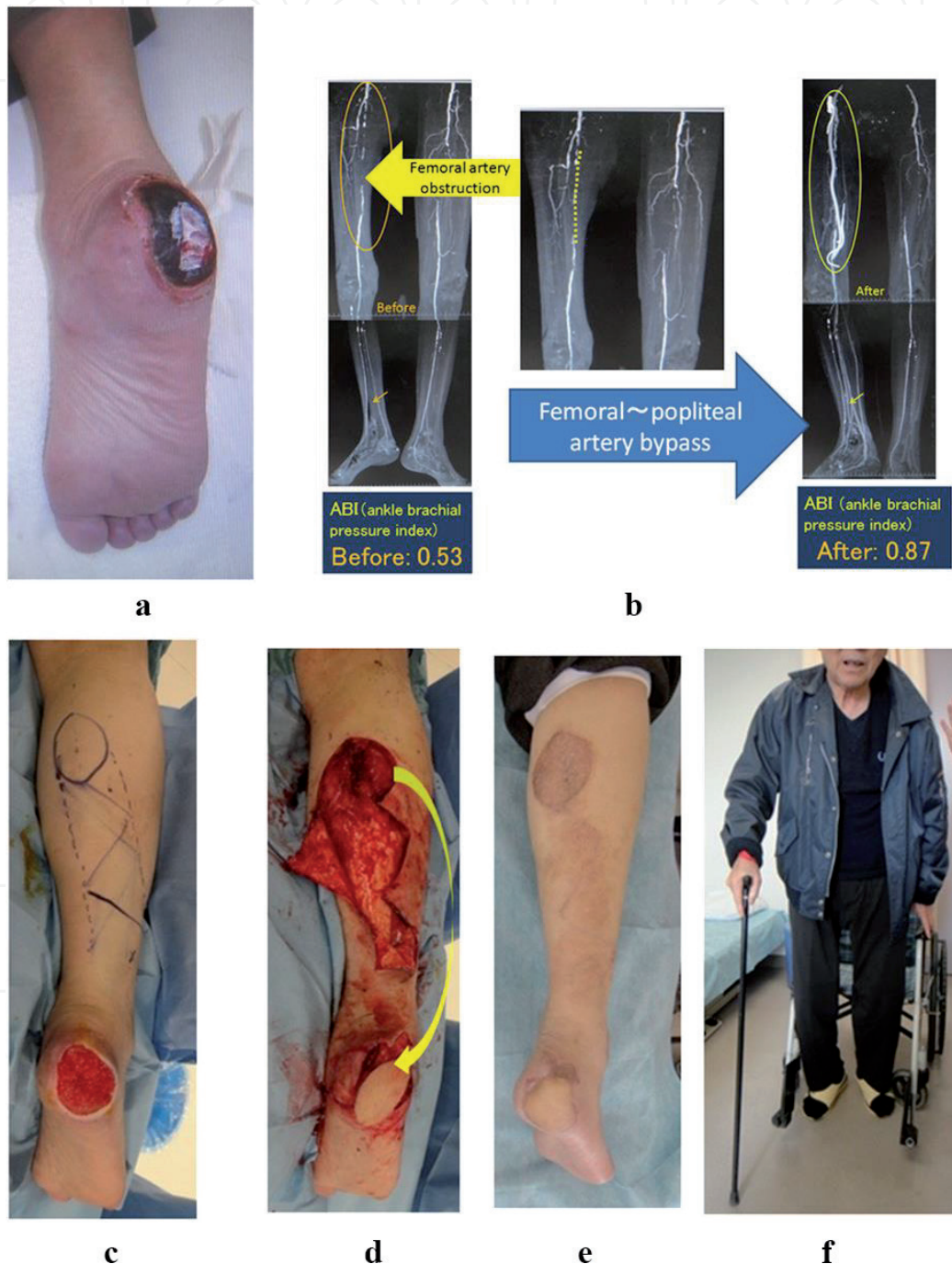

Figure 11.

(a) Case 2. A view of a diabetic foot ulcer of the right heel. (b) Enhanced computed tomography scan image showing the poor circulation of the patient's right lower leg due to obstruction of the right femoral artery (circles). After fashioning the femoral-popliteal artery bypass, increased distal blood flow was seen (small arrows). (c) Intraoperative view showing the debrided heel ulcer and design of the reversed sural flap. (d) Intraoperative view of heel reconstruction showing the transferred reversed sural flap. (e) A view of the reconstructed heel 3 months after surgery revealed favorable coverage of the wound. (f) The patient could walk 3 months after surgery.

Case 3. A 60-year-old man developed a diabetic foot ulcer and osteomyelitis of the calcaneus (**Figure 12a**). Following the removal of a sequester, he underwent FP bypass angioplasty, and ABI improved from 0.67 to 1.01 (**Figure 12b**). The bone-exposing wound was resurfaced using a free superficial circumflex iliac perforator (SCIP) flap (**Figure 12c–e**). One year after the surgery, good circulation had been achieved without infection or ulcer relapse (**Figure 12f**).

4.3.4 Advantages of resurfacing the amputation stump with a free flap

Standard stump plasty requires shortening of the remaining fine and vivid bone end to resurface the bone-exposing amputation stump (**Figure 13a and b**).

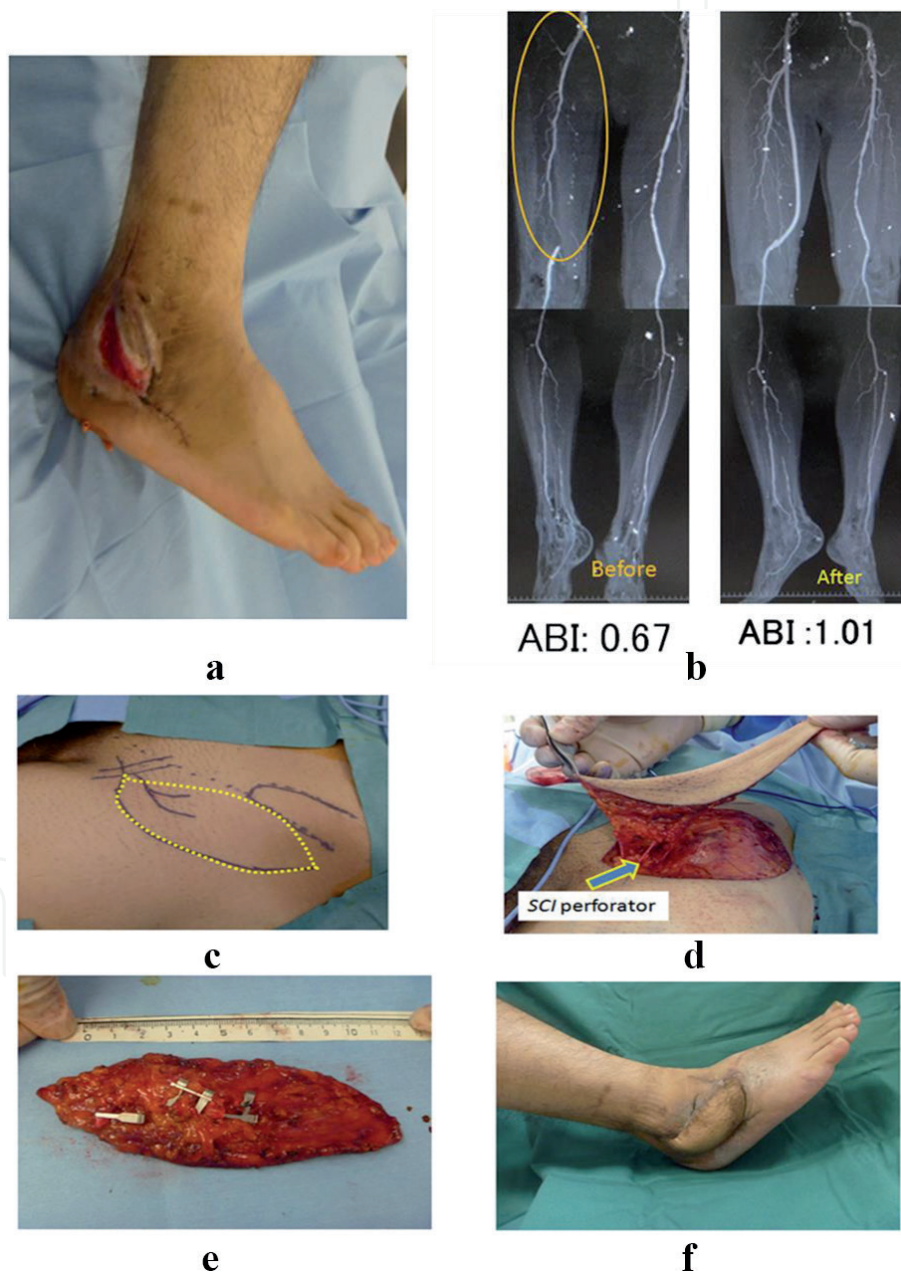


Figure 12. (a) Case 3. A view of a diabetic foot ulcer and osteomyelitis of the calcaneus. (b) Enhanced computed tomography scan image showing poor circulation of the patient's right lower leg due to obstruction of right femoral artery (circle). After fashioning the femoral-popliteal artery bypass, increased distal blood flow was seen. (c) Intraoperative view showing the design of a free superficial circumflex iliac perforator flap. (d) Intraoperative view of the elevated SCIP flap. The arrow indicates the perforator of superficial circumflex iliac vessels. (e) Intraoperative view of the harvested SCIP flap. (f) A view of the reconstructed foot 1 year after surgery showing favorable coverage of the wound.

On the other hand, free flap transfer enables surgeons to maintain the bone length, which is a potential advantage, especially when amputation is performed at the trans-metatarsal lesion (**Figure 14a–c**).

This is because Chopart or transtibial amputation results in more debilitating functional outcomes than transmetatarsal amputation. Furthermore, transmetatarsal amputation preserves maximal foot length, allowing patients to achieve a better quality of life [37, 38].

Regarding the flap choice, the ideal flap is thought to be a good vascularized skin paddle with the same thickness and width as the wound and requiring a single-stage operation [39]. Perforator flaps are defined as flaps consisting of skin and/or subcutaneous fat, with a blood supply from isolated perforating vessels of a stem artery [40]. The development of perforator flaps has increased the number of potential donor sites because a flap can be supplied by any musculocutaneous perforator, and donor-site morbidity can be reduced [41, 42]. Furthermore, the advantage of this skin flap is that it is less invasive, so that the operation can be performed under local anesthesia if the wound is small.

Case presentation

Case 4. A 32-year-old man developed a diabetic foot ulcer on the step (**Figure 15a**). Following debridement, he underwent resurfacing surgery using a free superficial circumflex Iliac artery perforator flap (**Figure 12b and c**). As free SCIP flap transfer is less invasive, the operation can be performed under local anesthesia (**Figure 15d**). One year after the surgery, good circulation had been achieved without infection or ulcer relapse (**Figure 15e**).

The SCIP flap is recommended because it minimizes sacrifice at the donor site, causing no damage to the main vessels or muscles beneath the flap. The only disadvantage is that the pedicle vessel is sometimes short when a suitable recipient vessel cannot

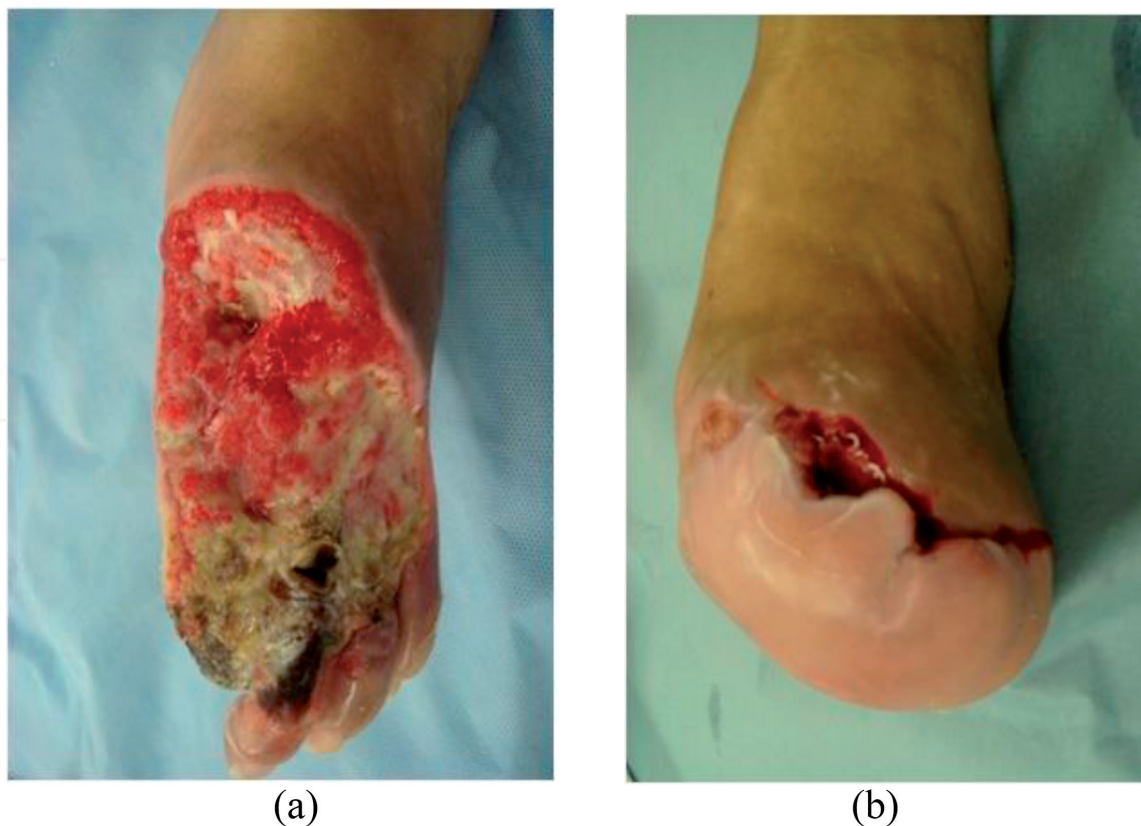


Figure 13.
(a) A view of diabetic gangrene extending the first and second metatarsal bones. After removal of the necrotic bone, the navicular was exposed. (b) Intraoperative view of Chopart amputation followed by resurfacing with a local flap of the sole.

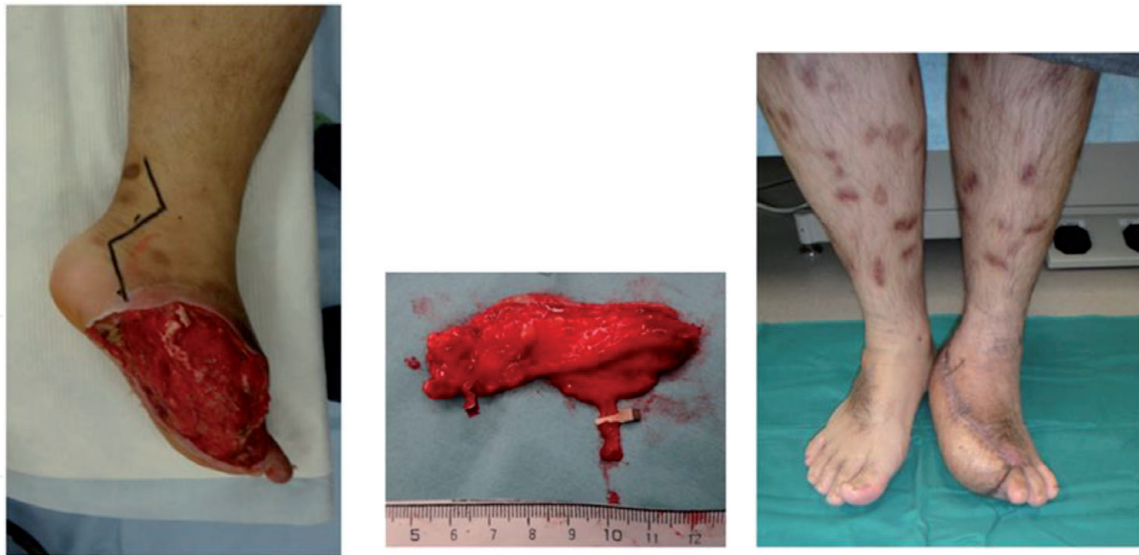


Figure 14.
(a) A view of a diabetic foot ulcer with osteomyelitis of the first and second metatarsal bones.
(b) Intraoperative view of the harvested anterolateral thigh (ALT) flap. (c) A view of the reconstructed foot using a free ALT flap 1 year after surgery, showing favorable coverage, and the patient could walk without a cane.

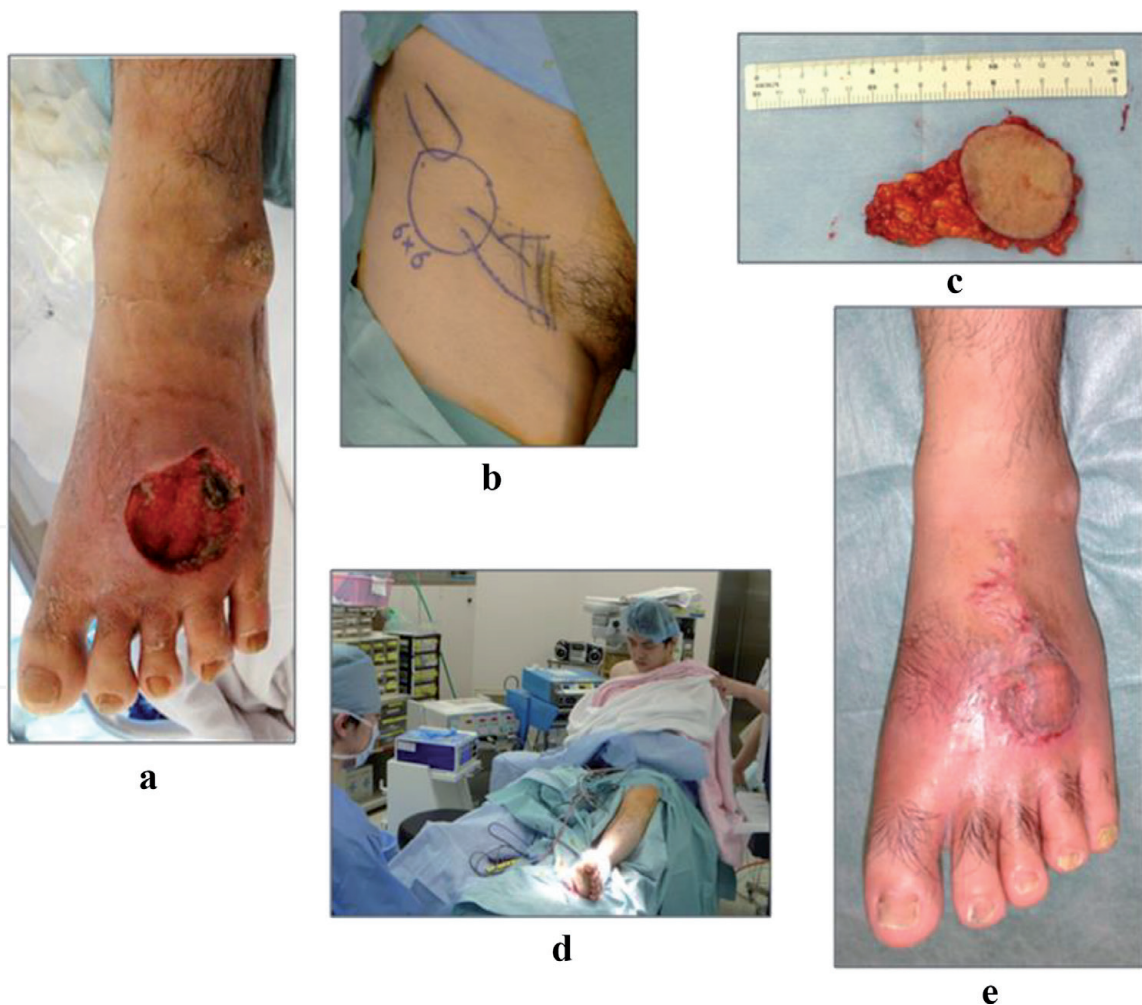

Figure 15.
(a) Case 4. A view of a diabetic foot ulcer of the step. (b) Intraoperative view showing the design of a free superficial circumflex iliac perforator flap. (c) Intraoperative view showing the design of a free SCIP flap. (d) Intraoperative view showing that an SCIP flap transfer is less invasive, so the patient was awake and talking with the surgeon. (e) A view of the reconstructed foot 2 months after surgery revealed favorable wound coverage.

be found near the wound [43]. Identifying an acceptable recipient vessel around the contaminated area is not always easy. Chronic inflammation in recipient vessels caused by infection and fibrosis may be one of the factors leading to thrombosis of the anastomosed vessel [44]. So, it is important to select a flap with a long pedicle, as the suitable recipient vessel may be distant from the wound. The *anterolateral thigh* (ALT) flap is often chosen because it is supplied by the descending branch of the lateral femoral circumflex artery, which has an external diameter of more than 2 mm at the proximal end with a pedicle of more than 8 cm in length [45, 46]. This flap is also a perforator flap, so that a larger cutaneous or fasciocutaneous flap can be harvested from the thigh while avoiding the sacrificing of underlying muscle and large vessels [47, 48].

Case presentation

Case 5. A 66-year-old man developed a diabetic foot ulcer with osteomyelitis of the left fourth and fifth toes (**Figure 16a**). He had already undergone right below

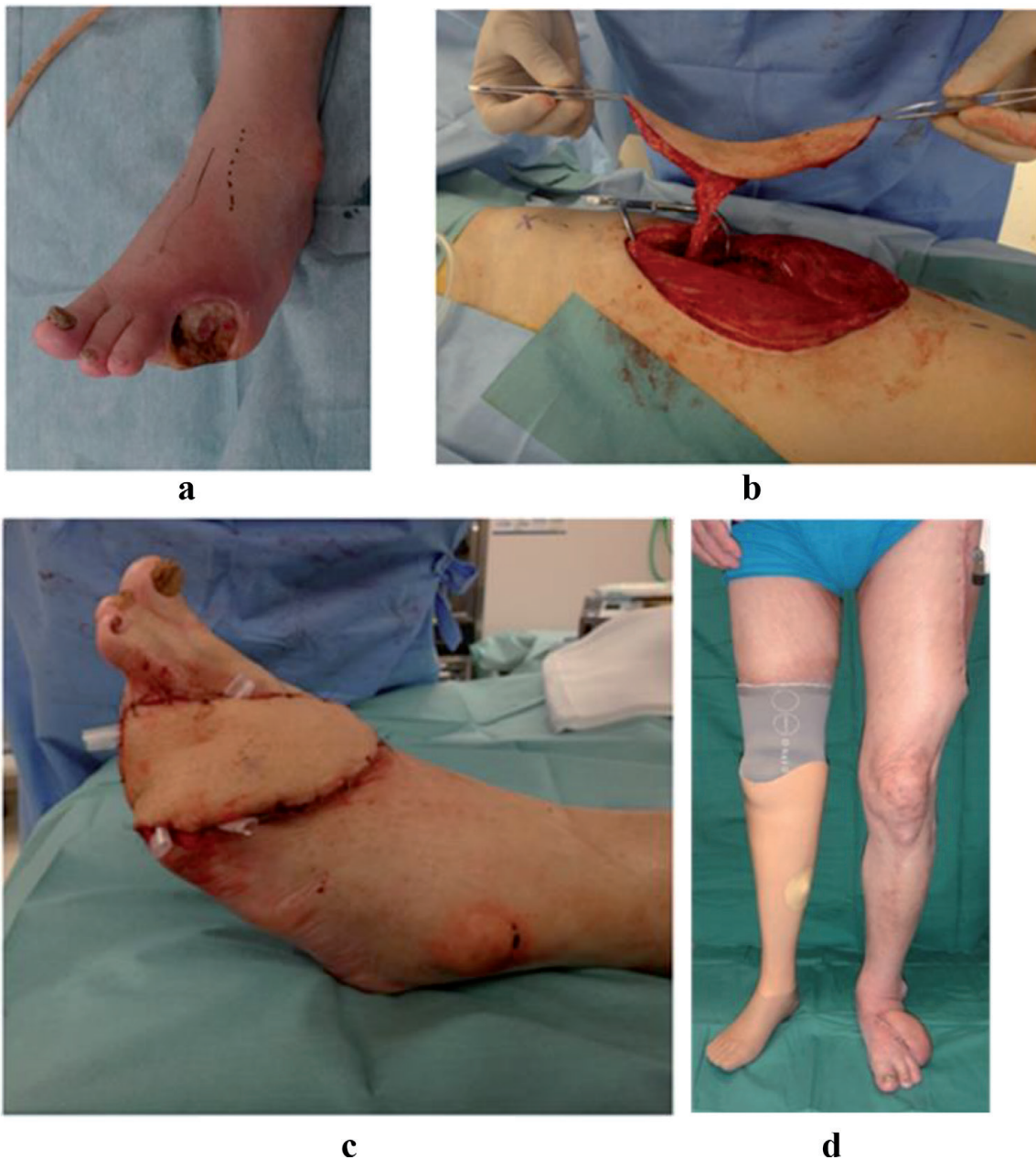

Figure 16.

(a) Case 5. A view of a diabetic foot ulcer. The fourth and fifth toes were amputated due to osteomyelitis. (b) Intraoperative view showing the elevation of an anterolateral thigh (ALT) flap. (c) Intraoperative view showing resurfacing of the bone-exposing wound with an ALT flap. (d) A view of the reconstructed foot 2 months after surgery revealed that favorable resurfacing had been achieved and he could walk without a cane.

the knee amputation due to diabetic gangrene. Thus, he desired to preserve his left leg to walk. Following debridement, he underwent resurfacing surgery using a free ALT flap (**Figure 16b** and **c**). Two months after the surgery, good resurfacing had been achieved, and he could walk with an artificial right leg (**Figure 16d**).

5. Conclusion

I conclude that the risk factors of leg amputation due to a diabetic foot are complications of severe infection and PAD, so diabetic ulcer management should include the immediate removal of necrotic tissue and control of infection. The only way to prevent major amputation of a diabetic ischemic foot is angioplasty of the occluded lower extremity arteries, and reconstruction of the amputation stump using free flap transfers to preserve the foot length is a good option for preserving the walking function.

IntechOpen

Author details

Masaki Fujioka

Department of Plastic and Reconstructive Surgery, National Hospital Organization
Nagasaki Medical Center, Ohmura City, Japan

*Address all correspondence to: inazumahayato7@gmail.com

IntechOpen

© 2019 The Author(s). Licensee IntechOpen. This chapter is distributed under the terms of the Creative Commons Attribution License (<http://creativecommons.org/licenses/by/3.0>), which permits unrestricted use, distribution, and reproduction in any medium, provided the original work is properly cited. 

References

- [1] Vamos EP, Bottle A, Majeed A, Millett C. Trends in lower extremity amputations in people with and without diabetes in England, 1996-2005. *Diabetes Research and Clinical Practice*. 2010;**87**:275-282
- [2] Lombardo FL, Maggini M, De Bellis A, Seghieri G, Anichini R. Lower extremity amputations in persons with and without diabetes in Italy: 2001-2010. *PLoS One*. 2014;**9**:e86405. Herder C, editor
- [3] Lopez-de-Andres A, Jiménez-García R, Aragón-Sánchez J, Jiménez-Trujillo I, Hernández-Barrera V, Méndez-Bailón M, et al. National trends in incidence and outcomes in lower extremity amputations in people with and without diabetes in Spain, 2001-2012. *Diabetes Research and Clinical Practice*. 2015;**108**:499-507
- [4] Watson MJ, Kundu N, Coppa C, Djohan R, Hashimoto K, Eghtesad B, et al. Role of tissue expanders in patients with loss of abdominal domain awaiting intestinal transplantation. *Transplant International*. 2013;**26**(12):1184-1190
- [5] Fard B, Dijkstra PU, Stewart RE, Geertzen JHB. Incidence rates of dysvascular lower extremity amputation changes in Northern Netherlands: A comparison of three cohorts of 1991-1992, 2003-2004 and 2012-2013. *PLoS One*. 2018;**13**(9):e0204623
- [6] Almaraz MC, González-Romero S, Bravo M, Caballero FF, Palomo MJ, Vallejo R, et al. Incidence of lower limb amputations in individuals with and without diabetes mellitus in Andalusia (Spain) from 1998 to 2006. *Diabetes Research and Clinical Practice*. 2012;**95**:399-405
- [7] Qaseem A, Vijan S, Snow V, Cross JT, Weiss KB, Owens DK, et al. Glycemic control and type 2 diabetes mellitus: The optimal hemoglobin A1c targets. A guidance statement from the American College of Physicians. *Annals of Internal Medicine*. 2007;**147**:417-422
- [8] van Houtum WH, Rauwerda JA, Ruwaard D, Schaper NC, Bakker K. Reduction in diabetes-related lower-extremity amputations in the Netherlands: 1991-2000. *Diabetes Care*. 2004;**27**:1042-1046
- [9] Dabkana TM, Nyaku FT, Bwala ST. Current indications for extremity amputations in Maiduguri, North-East Nigeria: A 6-year retrospective review. *Annals of African Medicine*. 2018;**17**(1):22-25
- [10] Yaghi K, Yaghi Y, McDonald AA, Yadegarfar G, Cecil E, Seidl J, et al. Diabetes or war? Incidence of and indications for limb amputation in Lebanon, 2007. *Eastern Mediterranean Health Journal*. 2012;**18**(12):1178-1186
- [11] Sargen MR, Hoffstad O, Margolis DJ. Geographic variation in Medicare spending and mortality for diabetic patients with foot ulcers and amputations. *Journal of Diabetes and its Complications*. 2013;**27**(2):128-133
- [12] Cook KD. Perioperative management of pedal amputations. *Clinics in Podiatric Medicine and Surgery*. 2005;**22**(3):329-341
- [13] Zickler RW, Padberg FT Jr, Lal BK, Pappas PJ. When is a more proximal amputation needed? *Clinics in Podiatric Medicine and Surgery*. 2005;**22**(3):429-446
- [14] Ammendola M, Sacco R, Butrico L, Sammarco G, de Franciscis S, Serra R. The care of transmetatarsal amputation in diabetic foot gangrene. *International Wound Journal*. 2017;**14**(1):9-15

- [15] Pedersen NW, Pedersen D. Nutrition as a prognostic indicator in amputations. *Acta Orthopaedica Scandinavica*. 1992;**63**(6):675-678
- [16] Ploeg AJ, Lardenoye JW, Vrancken Peeters MP, Breslau PJ. Contemporary series of morbidity and mortality after lower limb amputation. *European Journal of Vascular and Endovascular Surgery*. 2005;**29**(6):633-637
- [17] Kay SP, Moreland JR, Schmitter E. Nutritional status and wound healing in lower extremity amputations. *Clinical Orthopaedics and Related Research*. 1987;**217**:253-256
- [18] Luo H, Yang H, Huang B, Yuan D, Zhu J, Zhao J. Geriatric nutritional risk index (GNRI) independently predicts amputation in chronic critical limb ischemia (CLI). *PLoS One*. 2016;**11**(3):e0152111
- [19] Kawamura A, Horie T, Tsuda I, et al. Clinical study of therapeutic angiogenesis by autologous peripheral blood stem cell (PBSC) transplantation in 92 patients with critically ischemic limbs. *Journal of Artificial Organs*. 2006;**9**:226-233
- [20] Iseki K. Pharmacological control of secondary hyperparathyroidism in chronic hemodialysis patients: Cinacalcet is coming to Japan. *Expert Opinion on Pharmacotherapy*. 2008;**9**:601-610
- [21] Kaminski MR, Raspovic A, McMahon LP, Lambert KA, Erbas B, Mount PF, et al. Factors associated with foot ulceration and amputation in adults on dialysis: A cross-sectional observational study. *BMC Nephrology*. 2017;**18**(1):293
- [22] Bencini PL, Montagnino G, Citterio A, Graziani G, Crosti C, Ponticelli C. Cutaneous abnormalities in uremic patients. *Nephron*. 1985;**40**:3163-3121
- [23] Pico MR, Lugo-Somolinos A. Cutaneous alterations in patients with chronic renal failure. *International Journal of Dermatology*. 1992;**31**:860-863
- [24] Wukich DK, Ahn J, Raspovic KM, Gottschalk FA, La Fontaine J, Lavery LA. Comparison of transtibial amputations in diabetic patients with and without end-stage renal disease. *Foot & Ankle International*. 2017;**38**(4):388-396
- [25] Vas PRJ, Edmonds M, Kavarthapu V, Rashid H, Ahluwalia R, Pankhurst C, et al. The diabetic foot attack: "Tis too late to retreat!". *The International Journal of Lower Extremity Wounds*. 2018;**17**(1):7-13
- [26] Fujioka M. More than half of patients receiving hemodialysis with leg ulcer require amputation. In: Suzuki H, editor. *Hemodialysis*. Rijeka: InTech; 2013. pp. P231-P240
- [27] Garimella PS, Wang W, Lin SF, Hymes J, Lacson E Jr. Incident diabetic foot ulcers and mortality in hemodialysis patients. *Hemodialysis International*. 2017;**21**(1):145-147
- [28] Marn Pernat A, Peršič V, Usvyat L, Saunders L, Rogus J, Maddux FW, et al. Implementation of routine foot check in patients with diabetes on hemodialysis: Associations with outcomes. *BMJ Open Diabetes Research & Care*. 2016;**4**(1):e000158
- [29] Mustățea P, Bugă C, Doran H, Mihalache O, Bobîrcă FT, Georgescu DE, et al. Soft tissue infections in diabetic patients. *Chirurgia (Bucharest)*. 2018;**113**(5):651-667
- [30] Lavery LA, Davis KE, Berriman SJ, Braun L, Nichols A, Kim PJ, et al. WHS guidelines update: Diabetic foot ulcer treatment guidelines. *Wound Repair and Regeneration*. 2016;**24**(1):112-126

- [31] Perren S, Gatt A, Papanas N, Formosa C. Hyperbaric oxygen therapy in ischaemic foot ulcers in type 2 diabetes: A clinical trial. *Open Cardiovascular Medicine Journal*. 2018;**12**:80-85
- [32] Erdoğan A, Düzgün AP, Erdoğan K, Özkan MB, Coşkun F. Efficacy of hyperbaric oxygen therapy in diabetic foot ulcers based on Wagner classification. *The Journal of Foot and Ankle Surgery*. 2018;**57**(6):1115-1119
- [33] Tchero H, Kangambega P, Noubou L, Becsangele B, Fluieraru S, Teot L. Antibiotic therapy of diabetic foot infections: A systematic review of randomized controlled trials. *Wound Repair and Regeneration*. Sep 2018;**26**(5):381-391
- [34] Hinchliffe RJ, Brownrigg JR, Andros G, Apelqvist J, Boyko EJ, Fitridge R, et al. International Working Group on the Diabetic Foot. Effectiveness of revascularization of the ulcerated foot in patients with diabetes and peripheral artery disease: A systematic review. *Diabetes/Metabolism Research and Reviews*. 2016;**32**(Suppl 1):136-144
- [35] Forsythe RO, Brownrigg J, Hinchliffe RJ. Peripheral arterial disease and revascularization of the diabetic foot. *Diabetes, Obesity & Metabolism*. 2015;**17**(5):435-444
- [36] Vouillarmet J, Bourron O, Gaudric J, Lermusiaux P, Millon A, Hartemann A. Lower-extremity arterial revascularization: Is there any evidence for diabetic foot ulcer-healing? *Diabetes & Metabolism*. 2016;**42**(1):4-15
- [37] Hahn HM, Jeong KS, Park MC, Park DH, Lee IJ. Free-flap transfer for coverage of transmetatarsal amputation stump to preserve residual foot length. *The International Journal of Lower Extremity Wounds*. 2017;**16**(1):60-65
- [38] Baumfeld D, Baumfeld T, Macedo B, Zambelli R, Lopes F, Nery C. Factors related to amputation level and wound healing in diabetic patients. *Acta Ortopedica Brasileira*. 2018;**26**(5):342-345
- [39] El-Sabbagh AH. Skin perforator flaps: An algorithm for leg reconstruction. *Journal of Reconstructive Microsurgery*. 2011;**27**:511-523
- [40] Parrett BM, Matros E, Pribaz JJ, et al. Lower extremity trauma: Trends in the management of soft-tissue reconstruction of open tibia-fibula fractures. *Plastic and Reconstructive Surgery*. 2006;**117**:1315-1322
- [41] Schaverien M, Saint-Cyr M. Perforators of the lower leg: Analysis of perforator locations and clinical application for pedicled perforator flaps. *Plastic and Reconstructive Surgery*. 2008;**122**:161-170
- [42] Taylor GI, Pan WR. Angiosomes of the leg: Anatomic study and clinical implications. *Plastic and Reconstructive Surgery*. 1998;**102**:599-616
- [43] Suh YC, Hong JP, Suh HP. Elevation technique for medial branch based superficial circumflex iliac artery perforator flap. *Handchirurgie, Mikrochirurgie, Plastische Chirurgie*. 2018;**50**(4):256-258
- [44] Rudolph R, Arganese T, Woodward M. The ultrastructure and etiology of chronic radiotherapy damage in human skin. *Annals of Plastic Surgery*. 1982;**9**(4):282-292
- [45] Wong CH, Wei FC. Anterolateral thigh flap. *Head & Neck*. 2010;**32**(4):529-540
- [46] Wei FC, Jain V, Celik N, Chen HC, Chuang DC, Lin CH. Have we found an ideal soft-tissue flap? An experience with 672 anterolateral thigh flaps. *Plastic and Reconstructive Surgery*. 2002;**109**:2219-2226

[47] Fujioka M. Application of Free Flow-through Anterolateral Thigh Flap for the Reconstruction of an Extremity Soft Tissue Defect Requiring Vascularization. Flap Surgery. Rijeka: InTech; 2018. pp. 51-76. Chapter 4

[48] Gokhan M, Ulusal AE, Atik A, Sargin S, Ulusal B, Sukru Sahin M. Descending branch of the lateral circumflex femoral artery as a recipient vessel for vascularized fibular grafts: Clinical case series. *Microsurgery*. 2014;**34**(8):633-637

IntechOpen