

We are IntechOpen, the world's leading publisher of Open Access books Built by scientists, for scientists

4,800

Open access books available

122,000

International authors and editors

135M

Downloads

Our authors are among the

154

Countries delivered to

TOP 1%

most cited scientists

12.2%

Contributors from top 500 universities



WEB OF SCIENCE™

Selection of our books indexed in the Book Citation Index
in Web of Science™ Core Collection (BKCI)

Interested in publishing with us?
Contact book.department@intechopen.com

Numbers displayed above are based on latest data collected.

For more information visit www.intechopen.com



Intraoperative OCT for Monitoring Corneal Pachymetry during Corneal Collagen Cross-Linking for Keratoconus

Reza Ghaffari, Hassan Hashemi and Soheila Asghari

Abstract

Biomechanical reinforcement of the cornea by collagen cross-linking (CXL) using riboflavin and ultraviolet A (UV-A) irradiation is a well-established treatment for halting the progression of keratoconus. Corneal pachymetry is one of the most important factors with respect to the safety of CXL. In addition to the initial pachymetric changes, significant changes in corneal pachymetry may occur during the different steps of the procedure, highlighting the role of intraoperative pachymetric measurements. Intraoperative optical coherence tomography (OCT) can be used safely and effectively to monitor the corneal pachymetry during CXL. Among the advantages of this technology is its ability to provide a more detailed profile of the corneal thickness in a noncontact manner compared to the ultrasound method. These features are especially advantageous for monitoring corneal pachymetry in the setting of CXL in KCN patients, considering the marked irregularity of the epithelium and stroma in these patients. OCT has also been used for evaluation of other aspects of the CXL procedure like evaluation of in vivo riboflavin penetration in to the corneal stroma.

Keywords: anterior segment OCT, keratoconus, collagen cross-linking, intraoperative OCT, corneal pachymetry

1. Introduction

Keratoconus is a bilateral, progressive, ectatic disease characterized by progressive corneal thinning and irregular astigmatism. Biomechanical instability of the cornea is considered a main feature contributing to disease manifestations and a hallmark of this disease [1].

Biomechanical reinforcement of the cornea by collagen cross-linking (CXL) using riboflavin as a photosensitizer and ultraviolet A (UV-A) irradiation is a well-established treatment for halting the progression of keratoconus [2, 3].

The CXL process is mediated by a photo-oxidation reaction between UV-A (370 nm) and riboflavin (vitamin B2). Reactive oxygen species produced during this reaction, including singlet oxygen, react with the collagen fibril molecules in corneal stroma and enhance the mechanical strength of cornea by forming new chemical bonds between collagen fibril molecules [4].

The original procedure (Dresden protocol) includes removal of the central 7 mm of the corneal epithelium (epithelium-off method), riboflavin saturation of the

stroma with 0.1% riboflavin-20% dextran solution (every 5 minutes until 30 minutes), and then application of UV-A light source (370 nm with irradiance of 3 mW/cm²) on the cornea for 30 minutes [2]. However, there have been other modifications such as preserving the corneal epithelium (epithelial-on method), increasing the intensity of the UV source and decreasing the irradiation time (accelerated method), and using a continuous versus a pulsed light source after the description of the original procedure.

A significant increase up to 71.9 and 328.9% in corneal rigidity has been demonstrated in experimental studies in porcine and human corneas, respectively [4], and long-term studies have demonstrated the safety and efficacy of CXL in halting the progression of keratoconus [5, 6].

2. Significance of corneal pachymetry as a safety criteria for CXL

Corneal thickness (measured by pachymetry) is one of the most important factors with respect to the safety of CXL; a minimum thickness of 400 µm is recommended to ensure the safety of the procedure and avoid the potential toxic effects of UV-A irradiation on the corneal endothelium [7]. Both an adequate corneal thickness and adequate riboflavin saturation of the cornea are necessary to ensure photochemical damage caused by the free radicals to the corneal endothelium.

With the currently used irradiation doses in CXL (UV-A radiant exposure of 5.4 mJ/cm² and the corresponding irradiance of 3 mW/cm²), the estimated level of irradiance at a depth of 400 µm is 0.18 mW/cm² which is by two factors below the damage threshold [7].

CXL in thin corneas with a minimum corneal thickness below 400 µm after epithelial removal has been reported to result in significant endothelial cell loss postoperatively, emphasizing the role of corneal pachymetry as a critical factor for the CXL procedure [8].

3. Pachymetric changes during CXL for KCN and importance of intraoperative pachymetric monitoring

In addition to the initial pachymetric changes, significant changes in corneal pachymetry may occur during the different steps of the procedure [9–11]. Factors contributing to these changes include epithelial removal, dehydration due to corneal stroma due to exposure, osmotic effects of the riboflavin-dextran solution, and UV irradiation. The use of an eyelid speculum during instillation of riboflavin drops and the dextran containing riboflavin formulations (as compared to non-dextran containing riboflavin iso-osmolar formulations) are especially among the potential factors associated with shrinkage of the corneal stroma during the procedure.

Kymionis et al. [10] reported a decrease of 75 µm and Muzzotta et al. [11] reported a 32.07% shrinkage of the corneal stromal thickness after riboflavin saturation of the stroma with the riboflavin-dextran solution. These findings indicate that despite an initial pachymetry value greater than 400 µm, a considerable proportion of patients will end up with a corneal pachymetry value below the critical thickness during the procedure, which may be a factor explaining complications like corneal edema despite an initial adequate pachymetry in some reports [12].

These pachymetric changes all could potentially jeopardize the safety of the procedure, further highlighting the importance of intraoperative pachymetric monitoring during the operation.

4. Current standard method used for intraoperative corneal pachymetry measurements

Currently, ultrasound pachymetry is the most commonly used method for intraoperative pachymetry measurements during CXL. However, pachymetry measurements using this technique are subject to limitations: only single point measurements can be obtained and it is necessary to have contact to obtain the measurements, thus making the results more prone to inter- and intra-observer variability. In addition, vulnerability to infections due to contact with the surface of the eye and inadequate sterilization of the ultrasound tip during the procedure is another concern associated with this method.

5. Application of intraoperative OCT for corneal pachymetry during collagen cross-linking

5.1 Advantages of OCT as a diagnostic tool for corneal imaging

Anterior segment optical coherence tomography (AS-OCT) is a noninvasive imaging modality that can be used to obtain high-resolution, cross-sectional images of the anterior structures of the eye. In comparison with ultrasound pachymetry, AS-OCT has the advantage of providing a more detailed corneal anatomic profile during the procedure with a high degree of intra-observer repeatability and inter-observer reproducibility of the pachymetric measurements.

OCT has been proven to be a useful diagnostic imaging modality for the diagnosis of keratoconus. OCT-derived corneal thickness distribution and asymmetry parameters have been shown to have a good correlation with established Scheimpflug-derived anterior surface irregularity indices and proven useful to detect suspect, early, and clinical keratoconus [13].

The high resolution of the spectral domain OCT which allows for reconstruction of epithelial and stromal thickness profiles is another advantage of OCT to study the altered epithelial thickness pattern in keratoconus due to corneal surface irregularity. OCT-derived epithelial thickness map parameters have shown promising results in early and advanced keratoconus detection [14, 15].

OCT has also been used for detection of demarcation lines after CXL which are considered as a measure of the treatment efficacy [16]. In addition, OCT has been proved to be useful to show changes after CXL including the epithelial remodeling after CXL, resulting in a thinner and more regular thickness profile [7].

5.2 Application of intraoperative OCT in corneal and anterior segment surgery

OCT as a real-time and high-resolution imaging modality provides additional information regarding the angle, corneal thickness, and other structures that are otherwise invisible or difficult to visualize using the normal operating microscope, making it a potential beneficial tool for anterior segment surgery. In addition, it could provide valuable information in the cases like corneal opacity which preclude visualization of the anterior segment structures of the eye.

Intraoperative OCT has also been used as a useful extension of the normal surgical microscope during anterior segment procedures for finding the plane of corneal dissection during anterior lamellar surgery, for assessment of graft-host relationship in penetrating keratoplasty, as a guide during the crucial aspects of posterior lamellar surgery, cataract surgery, and glaucoma procedures like canaloplasty or trabectome surgery [17–22].

As another application of intraoperative OCT, this modality has been used for anterior segment examination of patients under general anesthesia, diagnosis of complex wound apposition problems, with the advantage of providing additional information for understanding corneal wound-related problems [23].

With the adaptation of this technology, intraoperative online OCT provides additional information for anterior segment surgeons providing a real-time dynamic feedback of the various surgical steps during surgery. Nonetheless, shadowing produced by surgical instruments represents the main limitation of this technology [19].

5.3 Application of intraoperative OCT for monitoring corneal pachymetry during corneal collagen cross-linking

Intraoperative OCT has been used to monitor the corneal pachymetry during CXL. The high resolution of OCT is especially advantageous in KCN patients, considering the marked epithelial and stromal irregularity in these patients.

In a study, Mazzotta and Karagiuli reported corneal pachymetric measurements in patients with keratoconus undergoing CXL. Pachymetric measurements were performed before, during, and after instillation of riboflavin using the time-domain Visante OCT (Zeiss, Jena, Germany). They showed significant corneal stromal shrinkage during the instillation of the riboflavin 0.1%-dextran T500 20% solution with 17.61, 25.44, and 32.07% reduction in the corneal thickness after 10, 20, and 30 minutes of riboflavin instillation, respectively [9].

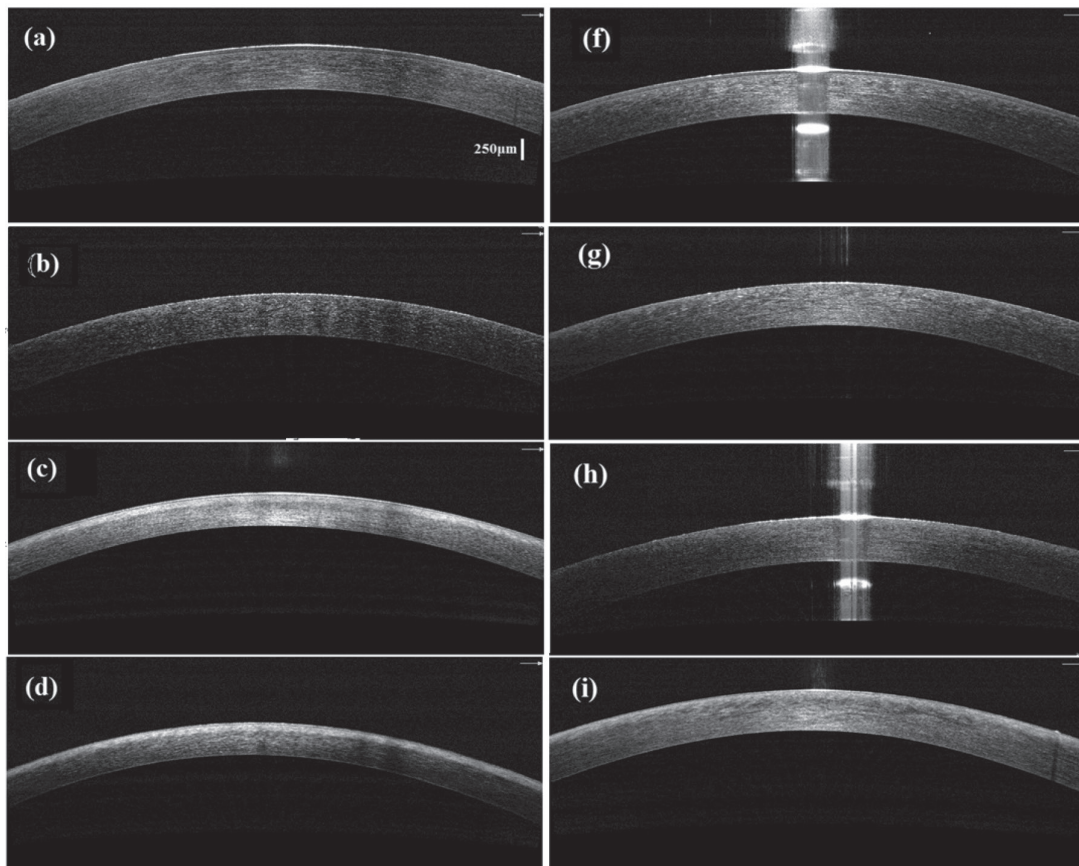


Figure 1. Representative intraoperative OCT images of cases in the speculum-on (a–d) and speculum-off (f–i) groups. The images represent different stages of the procedure: at the baseline (a, f), after epithelial removal (b, g), after riboflavin saturation of the corneal stroma (c, h), and after UV-A irradiation (d, i).

In another study, Rechichi et al. used intraoperative OCT to evaluate corneal pachymetry in keratoconic patients undergoing accelerated corneal collagen cross-linking with a dextran-free 0.1% riboflavin solution plus hydroxyl-propyl methylcellulose (HPMC). Intraoperative corneal thickness was evaluated by corneal optical coherence tomography (iVUE Optovue Inc., Fremont, CA, USA). Their results showed a central corneal thickness of 388.5 ± 36.8 , 385.2 ± 37.8 , and $379.4 \pm 37.2 \mu\text{m}$ after epithelial removal, after 10 minutes of soaking with riboflavin, and after ultraviolet instillation, respectively. Their findings are compatible with those of a stable corneal pachymetry with the dextran-free riboflavin solution, throughout the procedure [24].

In our study, we used intraoperative OCT to compare the effect of eyelid speculum on corneal pachymetric changes using an accelerated (9 mW/cm^2 for 10 minutes) CXL protocol. In 14 patients, the speculum was removed during the riboflavin imbibition time (speculum-off group), while in 11 patients the speculum was retained during this period (speculum-on group). Intraoperative OCT (iVue 100-2; Optovue, Fremont, CA, USA) was used to measure the corneal thickness at baseline, after epithelial removal, after 30 minutes of 0.1% riboflavin in 20% dextran T-500 solution instillation, and after irradiation. The speculum-on group showed a significantly greater decrease in the corneal pachymetry (83.7 vs. $16.4 \mu\text{m}$ decrease in corneal thickness) during riboflavin instillation. As shown in the **Figures 1 and 2**, the speculum-off group had a more stable corneal pachymetry value during riboflavin instillation. On the other hand, the speculum-off group had a greater decrease in the corneal pachymetry value during the irradiation phase, further highlighting the limitations imposed by corneal stromal shrinkage using the isotonic dextran containing riboflavin solution for CXL [25].

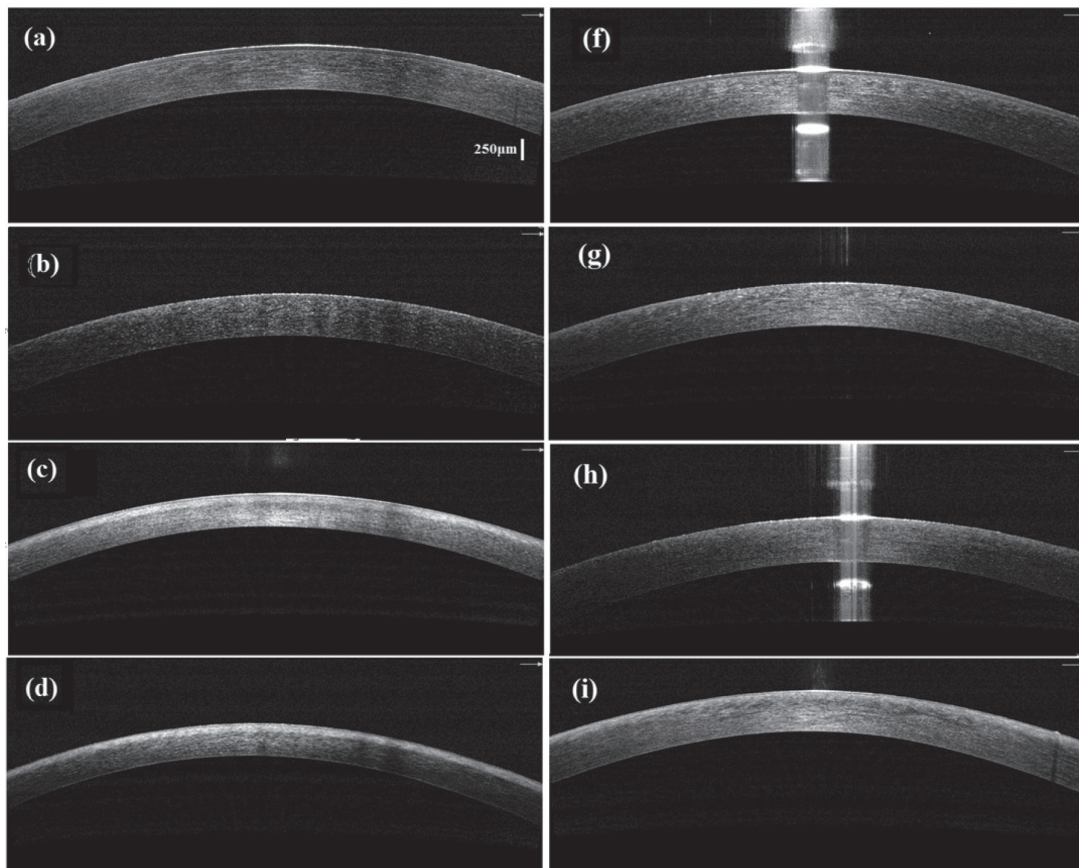


Figure 2. Representative OCT corneal thickness maps in the speculum-on (a–d) and speculum-off (f–i) groups. Note the marked thinning observed in the corneal thickness map during the riboflavin-dextran instillation of the cornea in the speculum-on group (c, h).

6. Other applications of intraoperative OCT for corneal collagen cross-linking

OCT has been used for in vivo evaluation of the riboflavin penetration to the stroma during CXL.

Riboflavin penetration of the cornea is associated with a hyper-reflective signal change in the corneal stroma. Although the correlation between the band's intensity and riboflavin stromal concentration has not been directly investigated, it is speculated that a higher OCT reflectivity should be positively correlated with riboflavin concentration.

Mahotra et al. evaluated the depth of hyper-reflective band (representing penetration of riboflavin) in the anterior corneal stroma after riboflavin saturation of the stroma in 20 patients undergoing CXL with either complete epithelial removal or grid-like epithelial removal (leaving behind intact islands of epithelium) using hand-held spectral domain OCT. In the complete removal group, the hyper-reflective band was homogenous, extending to a mean depth of $54.2 \pm 5.2 \mu\text{m}$ in the stroma. However, the hyper-reflective band was uneven in the grid pattern epithelial removal [26].

Vinciguerra et al. measured the depth of hyper-reflective band after riboflavin saturation of the stroma using two different methods (epithelium-off and iontophoresis method) in six patients. In the conventional epi-off group, after 30 minutes of riboflavin instillation, a homogeneous hyper-reflective band without fading was measured at a mean depth of $80 \mu\text{m}$. In the iontophoresis group, a less homogeneous but deeper hyper-reflective band with a fading effect was observed extending through the anterior $200 \mu\text{m}$ of the cornea [27].

Pahuja et al. used a microscope-integrated real-time spectral domain optical coherence tomography (ZEISS OPMI LUMERA 700 and ZEISS RESCAN 700) to compare the penetration of riboflavin between epithelium-on and epithelium-off methods in keratoconus patients undergoing accelerated CXL. The mean depth of the hyper-reflective stromal band was 149.39 and 191.04 microns in the epithelium-on and epithelium-off groups, respectively. These results are compatible with enhanced riboflavin corneal penetration with the epithelium-off method [28].

7. Conclusions

Intraoperative OCT can be used safely and effectively to monitor corneal pachymetry during CXL. Among the advantages of this technology is its ability to provide a more detailed profile of the corneal thickness in a noncontact manner, which is especially advantageous for monitoring corneal pachymetry in the setting of CXL in KCN patients compared to the conventional ultrasound method. OCT has also been used for evaluation of other aspects of the CXL procedure like evaluation of in vivo riboflavin penetration in to the corneal stroma.

Conflict of interest

The authors declare no conflict of interest regarding any material related to the article.

IntechOpen

Author details

Reza Ghaffari^{1*}, Hassan Hashemi² and Soheila Asghari³

1 Farabi Eye Hospital, Tehran, Iran

2 Noor Research Center for Ophthalmic Epidemiology, Noor Eye Hospital, Tehran, Iran

3 Noor Ophthalmology Research Center, Noor Eye Hospital, Tehran, Iran

*Address all correspondence to: ghaffaryreza@yahoo.com

IntechOpen

© 2019 The Author(s). Licensee IntechOpen. This chapter is distributed under the terms of the Creative Commons Attribution License (<http://creativecommons.org/licenses/by/3.0>), which permits unrestricted use, distribution, and reproduction in any medium, provided the original work is properly cited. 

References

- [1] Rabinowitz YS. Keratoconus. Survey of Ophthalmology. 1998;**42**(4):297-319. DOI: 10.1016/S0039-6257(97)00119-7
- [2] Wollensak G, Spoerl E, Seiler T. Riboflavin/ultraviolet-a induced collagen crosslinking for the treatment of keratoconus. American Journal of Ophthalmology. 2003;**135**(5):620-627. DOI: 10.1016/S0039-6257(97)00119-7
- [3] Wollensak G. Crosslinking treatment of progressive keratoconus: New hope. Current Opinion in Ophthalmology. 2006;**17**(4):356-360. DOI: 10.1097/01.icu.0000233954.86723.25
- [4] Wollensak G, Spoerl E, Seiler T. Stress-strain measurements of human and porcine corneas after riboflavin-ultraviolet-A-induced cross-linking. Journal of Cataract and Refractive Surgery. 2003;**29**(9):1780-1785. DOI: 10.1016/S0886-3350(03)00407-3
- [5] Theuring A, Spoerl E, Pillunat L, Raiskup F. Corneal collagen cross-linking with riboflavin and ultraviolet-a light in progressive keratoconus: Results after 10-year follow-up. Der Ophthalmologe. 2015;**112**(2):140-147. DOI: 10.1007/s00347-014-3114-0
- [6] Hashemi H, Seyedian MA, Miraftab M, Fotouhi A, Asgari S. Corneal collagen cross linking with riboflavin and ultraviolet a irradiation for keratoconus: Long-term results. Ophthalmology. 2013;**120**(8):1515-1520. DOI: 10.1016/j.ophtha.2013.01.012
- [7] Spoerl E, Mrochen M, Sliney D, Trokel S, Seiler T. Safety of UVA-riboflavin cross-linking of the cornea. Cornea. 2007;**26**(4):385-389. DOI: 10.1097/ICO.0b013e3180334f78
- [8] Kymionis GD, Portaliou DM, Diakonou VF, Kounis GA, Panagopoulou SI, Grentzelos MA. Corneal collagen cross-linking with riboflavin and ultraviolet-a irradiation in patients with thin corneas. American Journal of Ophthalmology. 2012;**153**(1):24-28. DOI: 10.1016/j.ajo.2011.05.036
- [9] Mazzotta C, Caragiuli S. Intraoperative corneal thickness measurement by optical coherence tomography in keratoconic patients undergoing corneal collagen cross-linking. American Journal of Ophthalmology. 2014;**157**(6):1156-1162. DOI: 10.1016/j.ajo.2014.02.042
- [10] Kymionis GD, Kounis GA, Portaliou DM, Grentzelos MA, Karavitaki AE, Coskunseven E, et al. Intraoperative pachymetric measurements during corneal collagen crosslinking with riboflavin and ultraviolet a irradiation. Ophthalmology. 2009;**116**(12):2336-2339. DOI: 10.1016/j.ophtha.2009.09.018
- [11] Schmidinger G, Pachala M, Prager F. Pachymetry changes during corneal crosslinking: Effect of closed eyelids and hypotonic riboflavin solution. Journal of Cataract and Refractive Surgery. 2013;**39**(8):1179-1183. DOI: 10.1016/j.jcrs.2013.03.021
- [12] Gokhale NS. Corneal endothelial damage after collagen cross-linking treatment. Cornea. 2011;**30**(12):1495-1498. DOI: 10.1097/ICO.0b013e31820687f7
- [13] Kanellopoulos AJ, Asimellis G. OCT-derived comparison of corneal thickness distribution and asymmetry differences between normal and keratoconic eyes. Cornea. 2014;**33**(12):1274-1281. DOI: 10.1097/ICO.0000000000000275
- [14] Kanellopoulos AJ, Asimellis G. OCT corneal epithelial topographic asymmetry as a sensitive diagnostic tool for early and advancing keratoconus. Clinical Ophthalmology. 2014;**8**:2277-2287. DOI: 10.2147%2FOPHTH.S67902

- [15] Li Y, Tan O, Brass R, Weiss JL, Huang D. Corneal epithelial thickness mapping by Fourier-domain optical coherence tomography in normal and keratoconic eyes. *Ophthalmology*. 2012;**119**(12):2425-2433. DOI: 10.1016/j.ophtha.2012.06.023
- [16] Doors M, Tahzib NG, Eggink FA, Berendschot TT, Webers CA, Nuijts RM. Use of anterior segment optical coherence tomography to study corneal changes after collagen cross-linking. *American Journal of Ophthalmology*. 2009;**148**(6):844-851. DOI: 10.1016/j.ajo.2009.06.031
- [17] Atia R, Jouve L, Sandali O, Laroche L, Borderie V, Bouheraoua N. Early epithelial remodeling after standard and Iontophoresis-assisted corneal cross-linking as evaluated by spectral-domain optical coherence tomography. *Journal of Refractive Surgery*. 2018;**34**(8):551-558. DOI: 10.3928/1081597X-20180702-01
- [18] Siebelmann S, Bachmann B, Lappas A, Dietlein T, Steven P, Cursiefen C. Intraoperative optical coherence tomography for examination of newborns and infants under general anesthesia. *Der Ophthalmologe*. 2016;**113**(8):651-655. DOI: 10.1007/s00347-016-0299-4
- [19] Siebelmann S, Bachmann B, Lappas A, Dietlein T, Hermann M, Roters S, et al. Intraoperative optical coherence tomography in corneal and glaucoma surgical procedures. *Der Ophthalmologe*. 2016;**113**(8):646-650. DOI: 10.1007/s00347-016-0320-y
- [20] Wylegala E, Nowinska AK, Wroblewska-Czajka E, Janiszewska D. Donor disc attachment assessment with intraoperative spectral optical coherence tomography during descemet stripping automated endothelial keratoplasty. *Indian Journal of Ophthalmology*. 2013;**61**(9):511-513. DOI: 10.4103%2F0301-4738.119440
- [21] Steven P, Le Blanc C, Velten K, Lankenau E, Krug M, Oelckers S, et al. Optimizing descemet membrane endothelial keratoplasty using intraoperative optical coherence tomography. *JAMA Ophthalmology*. 2013;**131**(9):1135-1142. DOI: 10.1001/jamaophthalmol.2013.4672
- [22] Titiyal J, Kaur M, Falera R. Intraoperative optical coherence tomography in anterior segment surgeries. *Indian Journal of Ophthalmology*. 2017;**65**:116. DOI: 10.4103%2Fijo.ijo_868_16
- [23] Pujari A, Mukhija R, Urkude J, Singh R, Agarwal D, Sharma N. Intraoperative assessment of corneal injuries using microscope-integrated optical coherence tomography. *Indian Journal of Ophthalmology*. 2018;**66**(11):1614-1615. DOI: 10.4103%2Fijo.ijo_546_18
- [24] Rechichi M, Mazzotta C, Daya S, Mencucci R, Lanza M, Meduri A. Intraoperative OCT Pachymetry in patients undergoing dextran-free riboflavin UVA accelerated corneal collagen crosslinking. *Current Eye Research*. 2016;**41**(10):1310-1315. DOI: 10.3109/02713683.2015.1118130
- [25] Ghaffari R, Mortazavi M, Anvari P, Salamat Rad A, Alipour F, Hafezi F, et al. Intraoperative optical coherence tomography to evaluate the effect of the eyelid speculum on corneal pachymetry during accelerated corneal cross-linking (9 mW/cm²). *Eye*. 2018;**32**(3):579-585. DOI: 10.1038/eye.2017.243
- [26] Malhotra C, Shetty R, Kumar RS, Veluri H, Nagaraj H, Shetty KB. In vivo imaging of riboflavin penetration during collagen cross-linking with hand-held spectral domain optical coherence tomography. *Journal of Refractive Surgery*. 2012;**28**(11):776-780. DOI: 10.3928/1081597X-20121011-05
- [27] Vinciguerra P, Rechichi M, Rosetta P, Romano MR, Mastropasqua L,

Scoria V, et al. *Journal of Refractive Surgery*. 2013;**29**(6):376-377

[28] Pahuja N, Shetty R, Jayadev C, Nuijts R, Hedge B, Arora V. Intraoperative optical coherence tomography using the RESCAN 700: Preliminary results in collagen crosslinking. *BioMed Research International*. 2014;**2015**:572698. DOI: 10.1155/2015/572698

IntechOpen

IntechOpen