

We are IntechOpen, the world's leading publisher of Open Access books Built by scientists, for scientists

4,800

Open access books available

122,000

International authors and editors

135M

Downloads

Our authors are among the

154

Countries delivered to

TOP 1%

most cited scientists

12.2%

Contributors from top 500 universities



WEB OF SCIENCE™

Selection of our books indexed in the Book Citation Index
in Web of Science™ Core Collection (BKCI)

Interested in publishing with us?
Contact book.department@intechopen.com

Numbers displayed above are based on latest data collected.
For more information visit www.intechopen.com



Robotic Liver Surgery

*Ricky Harminder Bhogal, Stephanos Pericleous
and Aamir Z. Khan*

Abstract

Robotic liver surgery is an evolving specialty within liver surgery. The robotic platform allows some of the limitations in both open and laparoscopic surgery to be overcome. Indeed as the technology develops there is scope for the number of robotic liver resections to increase as well as their complexity. In this chapter we discuss the current robotic platform, review the current role of robotics in liver surgery and review the available data in the literature on patient outcome.

Keywords: robotic surgery, liver surgery, liver metastasis, minimally invasive surgery, liver resection

1. Introduction

For many patients with liver tumours, whether benign or malignant, the optimal form of management is liver surgery. In the modern era with advancement anaesthetic techniques, improved understanding of liver pathophysiology and peri-operative patient management liver surgery has become a safe operation with excellent patient outcomes. Concomitant with this advancement in patient care has been a greater understanding of the nature of liver surgery and improving the precision of liver surgery. In particular surgery has followed the trend in other surgical disciplines and moved towards minimal access surgery. Building on the experiences of laparoscopic liver surgery hepatobiliary surgeons have begun to develop robotic liver surgical programs. Many institutes worldwide have performed complex liver procedures using robot-assisted surgery. This chapter summarises the nascent of field of robotic liver surgery and provides an overview of the current robot technology, surgical techniques and patient outcomes.

2. Liver anatomy

The liver is an accessory digestive gland located in the right upper quadrant of the abdomen. The liver's primary function is to produce bile that aids in the emulsification and digestion of dietary fat. The liver also serves many other critical functions including metabolism of drugs and toxins, removing degradation products of normal body metabolism and synthesis of many important proteins (e.g. clotting factors) and enzymes.

The liver is anatomically divided into two major lobes or into eight segments. Cantile line, which runs from the inferior vena cava (IVC) to the gallbladder fossa, marks the division between the left and right hemi-livers. Each hemi-liver can be divided further anatomically; the left liver can be divided into a left lateral section

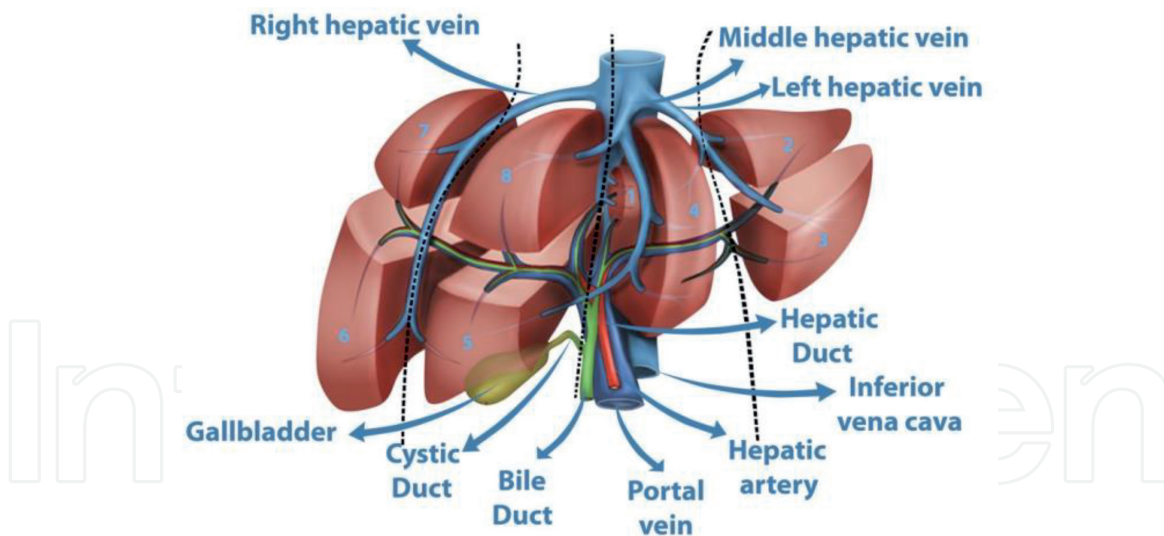


Figure 1.

The segmental anatomy of the liver. The liver derives its blood supply from the hepatic artery and portal vein. Both divide these structures divide into a left and right vessel to supply the respective side of the liver. The hepatic artery and portal veins divide into segmental branches to supply each of the segments within the liver. Correspondingly each segment has its own biliary duct and venous drainage. Importantly segment 1/caudate lobe is a specialised lobe of the liver and receives blood supply from both the left and right hepatic arteries with biliary drainage to both the left and right biliary ducts. Hence the left liver is made up of the segments 2, 3 and 4 and the right liver of segments 5, 6, 7 and 8.

(segments 2 and 3) and a left medial section or segment 4. The right hemi-liver can be divided into the right anterior section (segment 5 and 8) and right posterior section (segment 6 and 7). This segmental liver anatomy was originally described by Couinaud and is based upon the eight major divisions of the hepatic artery, portal vein and the biliary system (**Figure 1**). Segment 1 or caudate lobe is a unique liver lobe and is discussed below. Each Couinaud segment has its own arterial and portal blood supply, venous outflow and biliary drainage.

Blood enters the liver from two separate sources. Twenty percent of total liver blood flow is derived from the hepatic artery that is a branch of the coeliac artery. The remaining 80% is derived from the portal vein that is formed by the union of the Superior Mesenteric Vein and Splenic Vein behind the head of the pancreas. This venous blood brings nutrients and oxygen to liver parenchymal cells (e.g. hepatocytes, sinusoidal endothelial cells and cholangiocytes). Venous outflow of the liver is via the hepatic veins, which drain directly into the IVC and then the heart. This basic structure of the liver is integral to the planning of and performance of liver surgery.

3. Types of liver surgery and indications

3.1 Liver surgical procedures

There are important surgical principles and prerequisites that are mandatory when planning any liver operation. These are relevant for open, laparoscopic and robotic surgery. Most surgical procedures performed upon the liver involve the removal or resection of defined portion(s) of the liver. At the end of liver surgery there must be an adequate volume of liver of suitable quality left in-situ—termed future liver remnant (FLR)—that is generally considered to be 30% of original liver volume. In addition the FLR must have arterial and portal inflow, venous outflow and biliary drainage.

The different types of hepatectomies are illustrated in **Figure 2**. As discussed above as each segment of the liver has its own arterial and venous blood supply,

biliary drainage and venous outflow, a single segment of the liver can be resected without significant risk to the patient (see below). Specifically resections that follow defined anatomical planes are referred to as anatomical resections (e.g. left hepatectomy or segment 7 resection) and those crossing anatomical planes are referred to as non-anatomical resections (NARs).

These liver procedures have traditionally been performed as open surgical operations but during the late 1990s there was a drive to perform these operations via minimally invasive techniques such a laparoscopic surgery and more recently via robotic-assisted surgery. These surgical approaches are discussed in more detail below.

3.2 Indications for liver surgery

Most liver operations are performed for the management of both benign and malignant hepatic tumours. **Table 1** demonstrates the frequency of these liver operations.

The vast majority of liver operations performed for metastatic liver disease are for colorectal liver metastasis, approximately 80% of all liver operations are performed for liver cancer. Other metastatic diseases considered for liver resection include neuroendocrine tumours and sarcoma. The most common primary malignant tumour of the liver is the hepatocellular carcinoma (HCC) and in patients with preserved liver function, hepatectomy can be considered. Importantly in patients where the liver is damaged or cirrhotic, liver surgery cannot be undertaken, as the liver will not regenerate. Cholangiocarcinoma is the other common primary liver tumour and in cases where there is no metastatic/extrahepatic disease hepatectomy as listed in **Figure 2** can be considered. Benign tumours include hepatocellular adenoma, hepatic haemangioma and focal nodular hyperplasia can be considered for liver resection in selected patients particularly if symptomatic. Hepatectomy may also be the procedure of choice to treat intrahepatic gallstones or parasitic

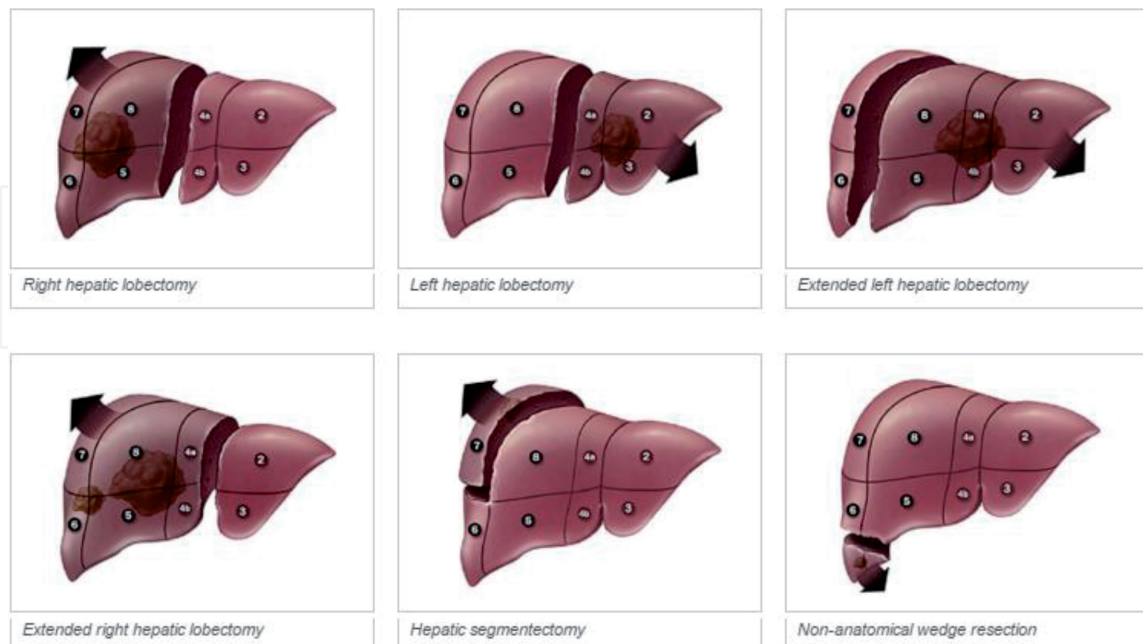


Figure 2.

The different types of hepatectomy. Liver resections are classified based upon the segments of the liver that are resected. A right hepatectomy/lobectomy is surgical resection of segments 5, 6, 7 and 8 whereas a left hepatectomy/lobectomy constitutes resection of segments 2, 3, 4. An extended left hepatectomy involves the further resection of segments 5 and 8. Combining a resection of segment 4 with a right hepatectomy is a classified as an extended right hepatectomy. Resection of a named segment is termed a segmentectomy and two contiguous segments a bi-segmentectomy. Resections crossing anatomical planes irrelevant of size are classified as non-anatomical resections.

Indication for liver surgery	Frequency (%)
Metastatic disease	51–55
Primary liver malignancy	14–16
Benign liver malignancy	8–11
Biliary tract malignancy	3–5
Benign liver disease	2–4
Benign biliary disease	1–4
Trauma	4–8
Other	3–6

Table 1.
Indications for liver resections.

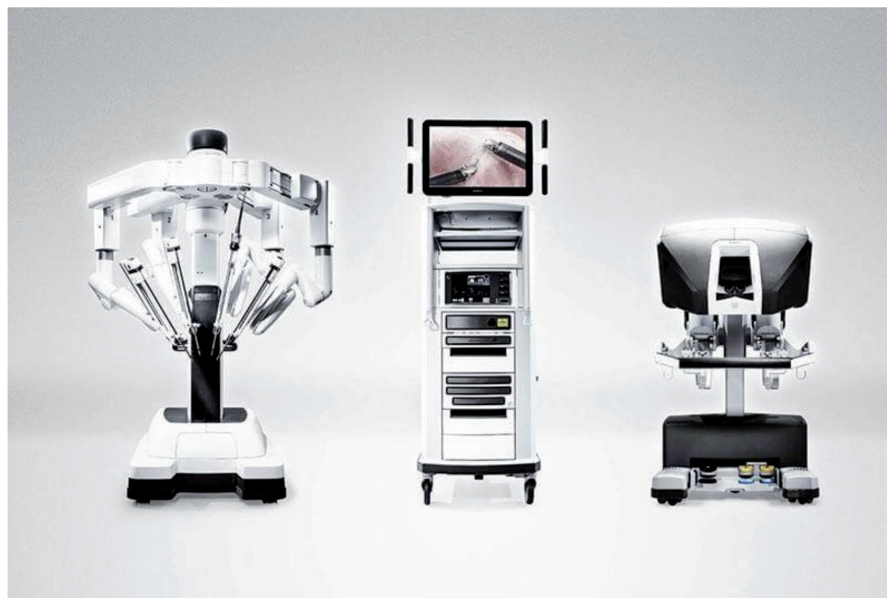cysts of the liver. Some of these pathologies such as HCC are also indications for liver transplantation but these indications and surgical techniques are outside the scope of this chapter. In the modern era liver surgery is safe when performed by experienced surgeons with appropriate technological and institutional support. As with most major surgical procedures, there is a tendency towards improved patient outcomes in high volume centres. Apart from liver surgery for trauma or HCC in cirrhotic patients where the mortality is high [1], the overall operative mortality for liver resections is now reported in the worldwide between 0 and 2% [2, 3]. This is a great advance in comparison to the mortality in liver surgery in early reports, which reached a mortality rate as high as 20% [4].

4. Evolution of robotic liver surgery

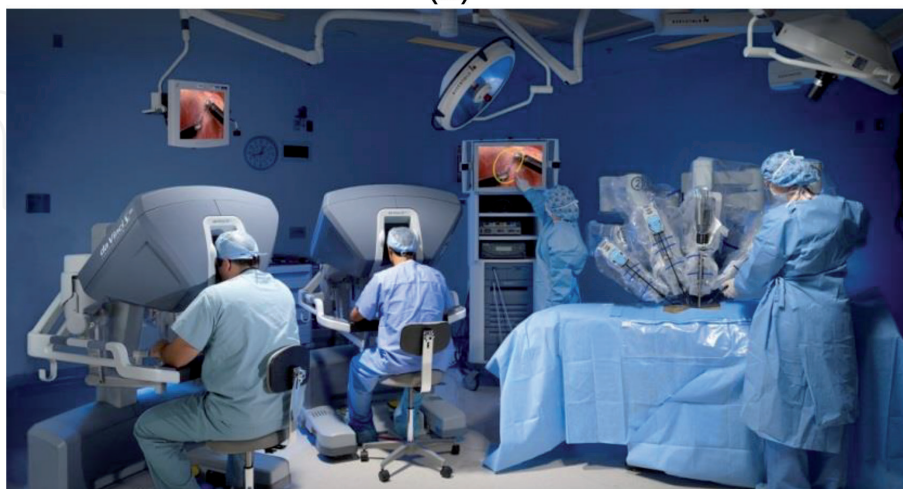
The German surgeon Carl Johann August Langenbuch was the first surgeon to perform a successful hepatic resection in 1888 [5]. The field of liver surgery did not advance significantly until the 1950s at which time liver surgery remained associated with high patient mortality with ill-defined surgical indications [6, 7]. In 1952 Lortat Jacob published his surgical techniques of anatomical liver resection [8] whilst in 1956, Claude Couinaud [9, 10] published his seminal work on the segmental anatomy of the liver which forms the basis of modern liver surgery. The application of these findings was restricted due to the persisting high-risk nature of liver surgery and the inadequate nature of liver imaging. However the advent of intra-operative ultrasound (IOUS) in the early 1980s [11] allowed for the identification of smaller liver lesions that can be resected leading to the rapid expansion of open liver surgery [12]. The technique of IOUS allowed the surgeon to understand liver vasculature and biliary duct anatomy improving the precision and safety of surgery. Within the next decade the first reports of laparoscopic liver wedge resection were published [13] which was followed by laparoscopic major hepatectomy in the mid 1990s [14]. The Second International Consensus Conference in 2014 recommended that laparoscopic resection to be standard of practice for selected anterolateral minor liver resections [15]. This entailed that lesions in segments 2, 3, 4b, 5 and 6 should be considered for laparoscopic liver resection.

There is a common misconception that robotic liver surgery evolved from laparoscopic liver surgery but robotic surgery has developed in tandem with the former. Computer Motion Inc. and Intuitive Surgical Inc. independently developed robotic surgical systems in the 1990s. In 1999, Intuitive Surgical released the da Vinci robot in Europe. The da Vinci robot is made up of three components (**Figure 3**):

a surgeon console, a 4-armed patient cart that is docked against the operating table, and a vision cart. The robot as a high-definition 3-dimensional viewer, a footswitch that conveniently allows the surgeon to seamlessly move between the camera, retractors, and instrument control, and the Endowrist instruments. Importantly the Endowrist instruments are articulated in a manner that allows a greater degree of motion than the human wrist [16] (see below). In 2003, Intuitive Surgical and Computer Motion merged and during this time the first reports of robotic liver resections were published. Marescaux *et al.* reported the first transatlantic robot-assisted telesurgery in 2001, where a robotic cholecystectomy was performed by surgeons in New York, USA, and the patient in Strasbourg, France [17]. The second generation da Vinci S was released in 2006, and in 2014, the fourth generation da Vinci Xi robot was approved by the FDA, with a redesigned surgical arm cart, smaller, longer arms, and new camera system to allow more flexibility in cart position and port placement (**Figure 3**) [18].



(a)



(b)

Figure 3.

The Da Vinci xi system. (a) Illustrates the current 4th generation da Vinci xi[®] robotic system. The system consists of three separate components; the patient cart, vision cart and surgeon console (left to right). (b) Demonstrates the set-up of the robotic system in an operating theatre. Operating surgeons can sit unscrubbed at the surgeon console away from the operating table where the sterile patient cart is docked to the patient. The vision cart allows the other theatre staff to view the surgical field and allow the use of ancillary functions such as visual annotation and video recording.

5. The robotic assisted surgery components

As discussed above a surgical robot consists of three separate components all of which are integral to the safe execution of robotic liver surgery. A summary of each component is given below using the da Vinci Xi[®] system as an example.

5.1 Surgeon console

The surgeon console is the component of the robotic system where the operating surgeon sits and performs liver surgery. It is sometimes also termed the workstation. The surgeon console is located outside the immediate surgical field (**Figure 3**) and with the newer robotic systems there are dual surgeon consoles that also allow training robotic surgeons to be assisted and mentored during their learning curve. Before commencing surgery the operator is able to adjust the physical parameters of the console to ensure appropriate ergonomics. The operator is afforded a three dimensional view of the surgical field using the viewer (**Figure 4A**). The screen also provides details of the instruments that are in use in the patient cart, the type of energy systems that are applied to these instruments and also provide real-time alerts to the operator to pre-empt potential problems and suggest troubleshooting options. There is also an option to adjust the screen view to accommodate several images at the same time such as the surgical field alongside two other displays accommodated by auxiliary inputs. This setup ensures that the manoeuvres made by the surgeon are safer, more precise and steadier. Instruments and the endoscope are manipulated and manoeuvred using the finger controls that replicate tremor free movements within the abdomen (**Figure 4B**). The surgeon is able to control two robotic arms/instruments simultaneous. At base of the console the surgeon has various controls that allow the operator to manoeuvre the 3D endoscope with the camera pedal and the EndoWrist[®] instruments during surgery (**Figure 4C**). The toggle pedal allows the operator to switch between different robotic arms whilst the foot-clutch allows the finger controls to be reset without any movement of the instruments in the abdomen. There are also pedals at the base of the console that allow the application of electrocautery through desired robotic instruments. Using




Figure 4.

The surgeon console. (a) The 3D viewer at the top of the surgeon console allow the operator to obtain an optimal view of the surgical field whilst being provided with contemporaneous information on instruments and energy devices. (b) Finger switches allow the operator to control the 3D endoscope, robotic instruments and allow advanced surgical manoeuvres such as suturing. (c) The base of the console allow the operator to control the endoscope in conjunction with the finger switches, switch between robotic instruments using the toggle pedal and allow electrocautery through the robotic instruments (both monopolar and bipolar).

the surgeon console the operator is able to simultaneously control the endoscope, instruments and energy application.

5.2 Patient cart

The patient cart is the component of the robotic system that is in direct contact with the patient and hence is required to be sterile draped prior to surgery. The patient cart consists of 4 robotic arms and makes up the surgical component of the robotic system. The patient cart has a display panel that allow for selection for the type of surgery to be undertaken (e.g. upper abdominal and pelvic) and needs to be selected prior to surgery. Once robotic ports have been inserted in an satisfactory manner (see below) the patient cart is manoeuvred into position using the handles (**Figure 5A**) and by utilising a spot laser in the helm of the cart the appropriate arm intended for the endoscope is positioned under the laser. This improves the position of the four robotic arms. A second assisting surgeon is stationed at the patient-side cart, in order to aid in the replacement of the robotic instruments and utilising assistant ports.

The 4 robot arms are latched deriving from a remote centre and fixed in space. This connection allows the surgical instruments and the endoscope to move freely reducing the force exerted on the patient's body to a minimum. Once the endoscope is engaged further instruments can be inserted in through other robotic ports after completion of docking (see below) and engaged in the remaining three robotic arms. Each robot arm has a port clutch at the base that allows docking of the robot port and for the instrument to swivel in a circular fashion and an instrument clutch at the base the allows the instrument to in and out of the abdomen to the desired length (**Figure 5B**). Pressing buttons on the instrument and replacing them with the desired instrument accomplish instrument changes—the robotic system allows the new instrument to be moved to within 3 mm of the position of the original instrument.

5.3 Vision cart

The visual cart is the final component of the robotic system (**Figure 3**). It contains an image-processing unit and a 24-inch touch screen monitor that allows live annotation of the screen and also allows other theatre staff to observe surgery.



Figure 5.
The patient cart. (a) The visual pad on the patient cart that allows operator to set the type of surgery to be performed and the handles that allows the patient cart to be moved around theatre. (b) A robotic arm with an instrument in place. The port and instrument clutches can be utilised to move the instrument into the correct position. Setting set-up it must be ensured that the robotic arms are in the correct alignment to avoid unnecessary collisions and clashes between arms.

The cart also contains an electrosurgical unit, the light source for the 3D endoscope and a series of racks for optional auxiliary surgical equipment such as recording facilities.

6. Robotic liver surgery

As experience with major laparoscopic operations such as splenectomy and colectomy has increased the interest in applying minimally invasive techniques to liver resection were developed in tandem. Technical developments such as more sophisticated energy devices and articulated laparoscopic staplers have enabled surgeons to tackle liver resection laparoscopically in line with international recommendations [15]. Specifically, as discussed above, lesions in the antero-medial segments of the liver are particularly favourable for this approach. Some of the major technical challenges in liver surgery include the access to the IVC and major hepatic veins, dissection of a difficult hepatic hilum coupled with the propensity for the liver to bleed during transection. These difficulties are magnified during laparoscopic surgery due to the limitations in depth perception, restricted movement with rigid instruments and fixed fulcrum at the ports, unnatural ergonomics that can compound suturing to the liver particularly in presence of haemorrhage. There is also a steep learning curve with laparoscopic liver surgery making its practice outside high-volume centres difficult although the same situation exists with robotic liver surgery. As a result, the uptake of minimally invasive hepatectomy has been understandably slow and cautious. However with increasing experience, surgeons have gradually increased the difficulty and complexity of liver surgery undertaken. This has developed from staging laparoscopy and de-roofing of simple liver cysts to resecting lesions in accessible parts of the liver such as the left lateral sector and wedge resections from the anteroinferior segments, to major hepatectomies. However, certain liver procedures are considered technically challenging. These include patient who have undergone previous surgery in particular upper abdominal surgery/liver surgery, resections involving the caudate lobe, lesions in the posterior portion of the liver and in patients requiring bile duct resection with reconstruction. In 2008 following a consensus conference experts recommended that laparoscopic resection should be considered in patients with solitary lesions, lesions 5 cm or less and/or those lesions located in segments 2–6 [19]. Furthermore the conference recommended that laparoscopic resection of liver segments 7, 8 and 1 was not standard practice. In part these recommendations were based upon the access to and visualisation of these areas of the liver and resection of these areas of the liver with rigid instruments. Moreover resection of liver lesions in the segments VII and VIII are particularly challenging because of issues with surgical access and the technical challenges in maintaining a curved transection lines throughout surgery thereby maintaining margins and obtaining R0 resection. Hence some evidence suggests that such lesions are more likely to be resected using right hepatectomy. Whilst oncologically this cannot be faulted it does necessitates the loss of a significant amount of normal functioning liver mass [20]. The most recent guidelines however still suggest that laparoscopic and by extension robotic liver surgery should not be considered for extended hepatectomies, when concomitant biliary reconstruction is needed or when lesions involve major vascular structures [15].

In theory, robotic surgery is an ideal platform for telesurgery. The indications for robotic hepatectomy are very similar to those for laparoscopic hepatectomy. Both benign and malignant tumours can be resected robotically. Robotic hepatectomy overcomes many of the problems inherent in laparoscopic surgery. In particular instruments allow curved transection lines and better visualisation of the liver [21].

Thus the greatest theoretical advantage of robotic hepatectomy may lie in sectoral, segmental, or subsegmental resections in difficult to access positions that mitigate against large incisions and extensive mobilisation required in an open approach. On the other hand, major hepatectomies for malignant conditions, such as hilar cholangiocarcinomas, where large incisions are required for specimen extraction may be better served by a traditional open approach although with improving robotic technology these may soon follow under the indications for robotic hepatectomy.

Image guided surgery is an evolving entity in liver surgery. The premise of this approach involves the use of pre-operative imaging being used to precision guide surgery. Some fields in surgery, such as orthopaedic surgery, have built up a significant amount of experience with this approach [22]. Essentially by using fixed bony landmarks on the body pre-operative images can be used as part of computer modelling systems to target organs and potentially lesion in real-time. Clearly the use of a mandatory console as part of robotic surgery means that such image-guided surgery can be made a routine part of surgery. For liver surgeons this would mean pre-emptive appreciation of vascular structures and the ability to carefully plan resection margins. However image-guidance surgery in hepatobiliary surgery remains a nascent field and further technological advances required before its use can be widely applied in robotic liver surgery.

7. Current advantages and disadvantages of robotic liver surgery

The utility of robotic liver surgery in part lies in the fact that it can overcome some of the inherent difficulties associated with laparoscopic liver surgery. For instances both these minimal access approaches to liver surgery entail long operative times and in the case of laparoscopic liver surgery this involves enduring unfavourable ergonomics during surgery primarily because of rigid laparoscopic instruments coupled with the primary operator having to remain scrubbed at the table side for extended periods of time. In the robotic liver surgery the primary operator being unscrubbed at the surgeon cart whilst operating and tailoring the console ergonomics to suit their individual preference overcomes these particular constraints. The benefits to the operating surgeon are clear namely operating in an ergonomically comfortable position with a 3-D view of the surgical field that aids depth perception. In addition the surgeon maintains control of the endoscope mitigating unnecessary camera movements and ensuring stable surgical views throughout the procedure. Robotic-assisted retractors are also controlled by the operating surgeon and maintain their position until further movement/retraction is required further avoiding inappropriate or ineffective retraction. Furthermore the use of articulated instruments that mimic the dexterity of the human hand allows for precise tissue manipulation and suturing in restricted surgical fields at angles not possible with rigid instruments. For instance Intuitive's multi-functional da Vinci instruments incorporate EndoWrist[®] technology (**Figure 6**).

The Endowrist[®] is incorporated into each Intuitive instrument (e.g. graspers, needle drivers and energy devices) and has a greater range of movement than the human hand. In addition robotic systems have in-built tremor reduction enhancing fingertip control. The Endowrist[®] technology also facilitates curved transection lines during liver surgery allowing for more complex liver resections to be performed. The technology also allows for the creation of biliary and enteric anastomoses in restricted surgical fields. During robotic surgery the surgeon's motions are scaled so that small, precise movements are effected at the patient's end which when fashioning a hepaticojejunostomy has significant advantages.

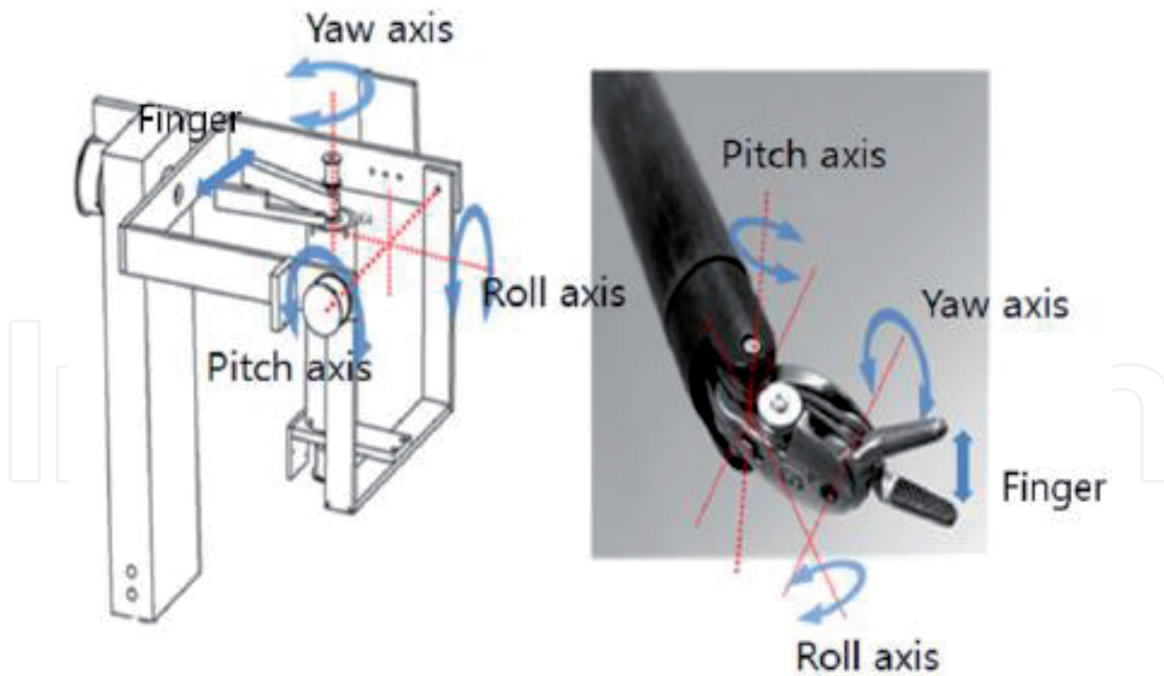


Figure 6. Endowrist robotic instruments. Robotic instruments incorporate Endowrist technology that allows the operator to control various instruments via the fingers switches. The Endowrist allows more degrees of movement than the human hand.

Emerging reports suggest that the learning curve for robotic surgery may be shorter when compared with conventional laparoscopic surgery. However, this may be due to the fact that many surgeons have previously obtained proficiency with laparoscopic surgery before engaging with robotic surgery. Currently, complex laparoscopic liver resections are generally performed by surgeons who are experienced hepatobiliary/laparoscopic surgeons. Open surgical techniques are more readily translated to robotics and thus surgeons who are expert in open hepatobiliary surgery but not necessarily advanced laparoscopy may become proficient quicker with robotic hepatectomy. Robotic surgery lends itself well to computer-based virtual reality training, and as such, trainee robotic surgeons may develop and attain significant competence with the robotic platform prior to operating on real patients. Such training systems have been developed and validated. Studies have found that structured training exercises improved simulator performance, although the translation to actual surgical performance has not been well studied [23]. Although the robotic dual console is also a teaching tool that could help accelerate proficiency. In addition, port placement is more forgiving in robotic surgery as instruments are not completely restricted by a rigid fulcrum and also compensated for by the Endowrist[®]. The details of port placement are discussed further in Section 8 below.

Although the development of robotic surgery is developing quickly, there are a number of disadvantages with the current operating systems. The current generation of robots requires a large amount of space in the theatre to accommodate each of the three components as well as the patient and anaesthetic equipment. In addition, bulky arms can prove difficult to manoeuvre in the space between theatre operating lights. Spacious operating rooms are required, and dexterity is limited by collision of robotic arms (**Figure 3**). Importantly, a skilled assistant is needed for suction, change of instruments, application of argon plasma, and stapling. In addition, if an assistant port is required, this will need the assistant to operate an instrument through it and thus requires some element of laparoscopic skills. However, newer robotic instruments such as robotic suction devices, sealers, and staplers have eliminated the routine need for accessory ports and the necessity of a skilled bedside assistant. Although

the robotic equivalent of CUSA is eagerly awaited which is likely to improve the division of the liver and the scope of liver surgery if and when available. Although there is improved depth perception with the robotic platform there is no tactile feedback and thus retraction force has to be judged and maintained by the operating surgeon. Although not strictly a problem limited to robotic surgery if the patient position requires adjustment this will often necessitate the robotic arms to be undocked, the robot to be moved and the robot arms to be redocked (see below). This will add time to the overall operating procedure and will also mean that an experienced theatre team is needed to carry this out smoothly with no loss of sterility. For similar reasons the ability to convert a robotic surgical procedure to an open procedure for emergencies such as bleeding requires a skilled team that can coordinate undocking of the robot, removal of the robotic instrumentation and conversion to laparotomy. The latest Intuitive Xi robot that allows a greater simplicity in manoeuvring the robotic components without having to move the operating table, patient cart or standard theatre equipment has overcome many of these logistical issues.

Robot and robotic malfunction is a known phenomenon and many of these problems require a replacement of robotic instruments [24]. One of the major disadvantages of robotic surgery is the high cost and this is multifaceted. Aside from the purchase of the platform and equipment there are costs incurred for consumables, surgeon and staff training as well as servicing costs for the robot. Although many of these may be offset by shorter length of ITU stay and shorter hospital stay. One of the limits of robotic HPB surgery is the need for specialised training, not only for the primary surgeon, but also for the assistant surgeon and OR nurses, although in some cases, the learning curve for specific robotic procedures has proven to be shorter than the laparoscopic equivalent [25]. A specific issue for liver surgeons is that at present only a limited number of instruments are available parenchymal transection such as harmonic shears. Although these remain an efficient tool as discussed above the development of a robotic CUSA would improve the mechanical steps of the operation.

8. Technique of robotic liver resection

8.1 General consideration for patients undergoing liver surgery

All patients considered for robotic liver surgery should have the same workup as for patients undergoing any form of liver surgery. Patients must have the physiological reserve to tolerate general anaesthesia and a prolonged pneumoperitoneum. In our institution all patients undergo cardiopulmonary exercise testing and routine haematology, coagulation and biochemistry as part of anaesthetic workup. General contraindications to laparoscopy such as uncorrected coagulopathy and cardio-respiratory compromise should be observed. Furthermore patients should be discussed in an appropriate multidisciplinary team meeting after cross-sectional imaging and staging. In our institution all patients undergo Computed Tomography (CT) of the thorax, abdomen and pelvis. We use MRI liver and CT-PET on a patient-dependent manner. Patients also give informed consent for robotic surgery and we quote a robot to open conversion rate of 10% in our unit based upon our unit prospectively collected data.

8.2 Patient positioning and robot docking

Following general anaesthesia the patient is placed in the supine position and strapped into position on the operating table. Depending upon the type of liver

resection the patient may be kept in reverse-Trendelenburg position whilst supine or placed in this position with legs parted. With the patient in the desired position the optimal position for the ports is marked with a surgical pen. The general recommendation is the robotic ports should be placed 15–20 cm from the target liver segment/lobe. Importantly in laparoscopic surgery ports can be placed at various points within the abdomen however in robotic surgery the ports generally need to be placed in a horizontal line (**Figure 7**). Each port should be placed 7–10 cm apart depending upon the patient's abdominal girth. Additional assistant ports should be placed 7–10 cm caudal to this horizontal plane of robotic ports. Due to the limited degree of freedom of the Harmonic scalpel correct positioning of the instrument through the assistant port is critical in order to follow the transection line particularly for major liver resections. However with availability of the robotic Harmonic scalpel does make this less of an issue. The patient positioning and trocar placement vary depending upon the area of the liver to be resected. Trocars will be positioned very high subcostal and lateral for the posterior superior segments or closer to the transverse umbilical line for the anterior segments shifting towards the left or the right depending on the lesion location. The same basic principle that applies to laparoscopic surgery applies to robotic surgery that is to create adequate triangulation with enough space in between the ports to avoid instrument clashing and aid efficient movement of instruments. Sometimes this might require a switch of the instrument in between the left and right operative arm.

We recommend an open/Hassan technique to inserted the optical robotic port to establish pneumoperitoneum. Robotic ports are specialised metallic ports. Once pneumoperitoneum is satisfactory a diagnostic laparoscopy is performed in order to

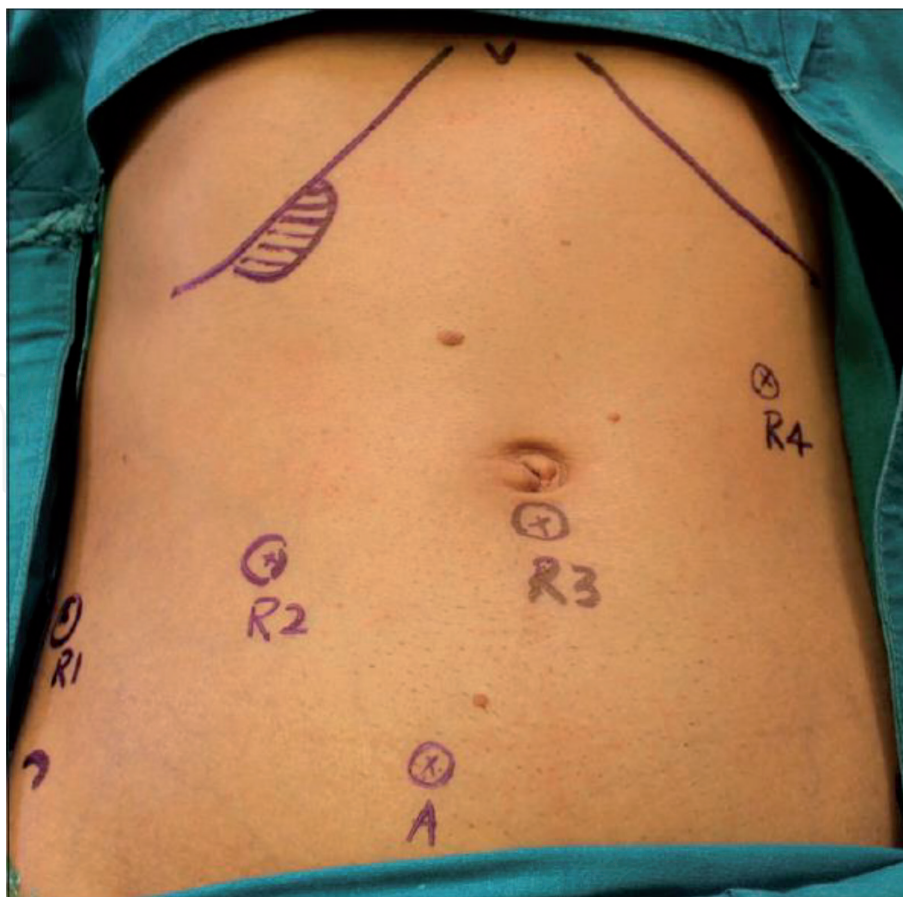


Figure 7. The placement of robotic ports for liver resection. Demonstrates the robotic port placement for liver resection of segment 2, 3, 4, 5, 6 and cholecystectomy. R1–4 represent the robotic arms. Each of these robotic ports can be used as an optical port. Note the assistant port (A) is placed in the caudal position to provide optimal port placement.



Figure 8.
Docking of the robotic ports. All robotic ports require to be docked to the robot arms on the patient cart prior to their use. The metallic extension on the ports is engaged with the robot port using the port clutch in a process known as docking.

exclude the presence of metastases or occult disease. An IOUS is also performed in order to have a better understanding of the size, number and location of the lesions and their relationship to major vascular and biliary structures. Once confirmed that the resection is to proceed the patient cart is brought into the surgical field. A tracker laser is positioned over the optical robotic port to ensure that the robot is in the optimal position. Further robotic ports are then inserted under direct vision in the previously marked position. The metallic extension on the robotic optical port (present on all robotic ports) is then engaged onto the robot arm using the port clutch—this procedure is known as ‘docking’ the robot (**Figure 8**). The endoscope is then placed through the robotic port and engaged onto the top of the robotic arm. By pressing the instrument clutch the endoscope is maneuvered into the peritoneal cavity and is then used to visualise the target anatomy (e.g. liver lesion). The targeting button is then pressed on to endoscope that then automatically places the remaining robotic arms into optimal positions. The remaining robot ports are then docked and the appropriate instruments inserted through the ports and engaged in the robotic arms.

8.3 Surgical procedure

The precise liver procedure to be performed will be dependent upon the type of liver resection to be performed. Below a description of anatomical and non-anatomical liver resections is discussed.

8.3.1 Anatomical/major robotic liver resection

Prior to any form of liver resection the central venous pressure is lowered to less than 5 mmHg in order to reduce blood loss that is used in conjunction with reverse Trendelenburg position for the same reason [26]. For anatomical or major robotic liver resection there are three surgical steps that have been recommended for safe resection outlined in **Table 2** and are similar to open liver surgery.

For major robotic liver resections the falciform ligament is usually divided with a vascular stapler or robotic stapler followed by a retrograde cholecystectomy using the same principles of laparoscopic cholecystectomy. In the case of left hepatectomy the left triangular ligaments can now be divided in order to mobilise

the left lobe of the liver. A Nylon taped maybe passed at this point for future Pringle use although this is not necessary in all cases [27].

Next the relevant hepatic pedicle is then dissected using a combination of robotic monopolar hooks and/or bipolar forceps. For major hepatectomy the right or left hepatic artery is dissected first and clearly identified. IOUS may be utilised after selective clamping of the dissected artery to ensure satisfactory flow within the future liver remnant. Once satisfactory flow is confirmed the desired artery can be divided between prolene sutures, surgical clips or Hem-O-locks[®]. Next the relevant portal vein is completely dissected and selective stitches or ligatures are applied on the small branches if present. The portal vein is then divided between robotic clips/Hem-O-locks or sutured with either 4-0 or 5-0 prolene. Generally an extrahepatic dissection of the bile duct should be performed only when the anatomy is clear and confluence of the biliary ducts is low. In the latter ICG fluorescence can be easily used at any point and can help identify the biliary anatomy and used with the Firefly setting on the robotic system. For right hepatectomy hepatocaval dissection the subsequent step following hilar dissection. Specifically the lateral reflection of the peritoneum is dissected using the hepatocaval plane as a guide. The third arm of the robot can then be used and a retractor deployed to lift the inferior surface of the right liver lobe to expose the IVC in analogous manoeuvre to open surgery. The retrohepatic veins can be divided using either sutures or surgical clips. Clips can also be placed for accessory hepatic veins of minor calibre or to further The liver is progressively dissected off the IVC until the inferior aspect of the right hepatic vein is visible and signals the end of this part of the dissection.

Transection of the liver is the last step of the operation. Parenchymal transection should follow the ischemic demarcation line and start at the anterior aspect of Cantile lines for a right hepatectomy. Many retraction measures can be employed to ensure effective retraction of the liver including stay sutures, rubber rings or surgical instruments. As discussed above many liver surgeons would consider robotic harmonic scalpel as the tool of choice for parenchymal transection. Liver transection is performed layer by layer proceeding in a superficial to deep manner in the same plane to maintain control of vessels and bleeding. Moreover superficial bleeding can be controlled with appropriate energy devices whilst larger vessels may require suturing and/or surgical clips. As the resection proceed deeper into the liver most surgeons would utilise surgical stapling devices to control venous structures such as segment 5 and 8 branches as well as the right/left hepatic vein. The liver is then completely mobilised by sectioning the remaining peritoneal attachments with assistance of the bedside surgeon. In the case of left lateral sectionectomy following left triangular division robotic resection can be completed by remaining lateral to the falciform ligament and completed parenchymal transection with robotic harmonic scalpel and vascular staplers. For segmentectomy the relevant portion of the liver is mobilised and IOUS used to identify selective pedicles prior to transection.

Following transection the raw surface of the remaining liver should then be examined for bleeding and bile leaks. At the end, haemostatic agents such as fibrin glue, Surgicel[®], argon plasma can be applied to the remaining surface as a sealant.

Step 1	Division of the Falciform ligament ± cholecystectomy
Step 2	Portal pedicle dissection and liver mobilisation
Step 3	Liver transection

Table 2.
Suggested steps for major robotic liver resection.

Finally, the specimen is placed in an endoscopic bag and extracted through a small Pfannenstiel incision or through the site of a previous scar. Closed suction drains in the subhepatic and subdiaphragmatic area is used. The robotic cart is removed from the operative field, pneumoperitoneum is stopped and the trocars are extracted under direct laparoscopic vision.

8.3.2 Non-anatomical robotic liver resection

In our experience the Pringle manoeuvre has to be rarely used for NARs but when there is a need to secure more control on the liver inflow, the hepatic pedicle is prepared and a tourniquet is created using an umbilical tape. NARs are generally reserved for liver lesions that are superficial, subcapsular or easily visualised. As discussed above the main tool used for parenchymal transection is the robotic harmonic scalpel and it is ideally suited to perform NARs. Prior to commencing transection the resection line can be marked with diathermy which also allows the robotic harmonic scalpel to be positioned correctly and may mandate the switching of the robotic harmonic scalpel between different robotic arms. As described above transection is recommended to be performed in a layer-by-layer fashion. The fourth robotic arm can be used to aid retraction such that there is minimal traction on the lesion itself. Once the resection is completed haemostasis is achieved with a combination of the robotic energy instruments and topical haemostatic agents.

9. Current results of robotic liver surgery

Early experiences with using a robot in cholecystectomy demonstrated equivalent results to the laparoscopic approach. These early surgical reports served to show that robotic approaches were feasible for liver surgery [28, 29]. In most institutions robotic cholecystectomy is reserved for those surgeons completing approved training pathways/accreditation before commencing upon more complex procedures. Generally for cholecystectomy robotic surgery does not offer any significant advantage over the laparoscopic approach particularly when cost-benefit is considered. Below we discuss the current results for robotic liver resection. On reviewing the available literature it is evident that there are clear contraindications to the robotic liver surgery including invasion of major hepatic vessels and extension into the diaphragm necessitating diaphragmatic resection. There is no predetermined limit regarding the size of lesions that can be resected but very bulky tumours presented a technical challenge.

NAR/segmentectomy	87
Left lateral sectionectomy	51
Left hepatectomy	31
Bisegmentectomy	12
Right hemihepatectomy	51
Right trisectionectomy	3
Other	2
Total	237

Table 3.
Types and frequencies of robotic liver resections.

Authors	Year	n	Age	M:F	Resection type	Operative time (mins)	Blood loss (mins)	Conversion rate (%)	Transfusion rate (%)	Post-op stay (days)	Morbidity (%)	Mortality (%)	R0 (%)
Tsung et al. [31]	2014	57	58	42:58	37% major hepatectomy	253 (180–355)	200 (50–338)	7	4	4 (3–5.5)	20	0	95
Spampinato et al. [32]	2014	25	63	13:12	Major (16 RHH; 17LHH)	430 (240–725)	250 (100–19,000)	4	44	8 (4–22)	16	0	100
Tranchart et al. [27]	2014	28	66	13:15	All minor	210 (45–480)	200 (0–1800)	14	14	6 (1–15)	14	0	NR
Wu et al. [33]	2014	52	61	32:6	67% major hepatectomy	380	325	5	NR	8	8	0	NR
Boggi et al. [34]	2015	12	61	4:8	Superio-posterior segments	260	252	8	25	NR	33	0	100
Montalti R [35]	2016	36	62	21:15	Superio-posterior segments	306 (53–790)	415 (0–1500)	14	NR	6 (2–91)	19	3	89
Lee et al. [36]	2016	70	58	65:35	20% major hepatectomy	252 (97–620)	100 (2–2500)	6	5	5 (2–22)	12	0	98
Lai et al. [37]	2016	100	NR	NR	27% major hepatectomy	207	334	NR	NR	NR	14	0	96
Croner et al. [38]	2016	10	64	2:8	All malignant	321 (138–458)	306	NR	NR	7 (5–13)	10	0	100
Nota et al. [39]	2016	16	69	9:7	All minor (81% malignant)	146 (60–265)	150 (5–600)	6	NR	4 (1–8)	43	0	NR

Authors	Year	n	Age	M:F	Resection type	Operative time (mins)	Blood loss (mins)	Conversion rate (%)	Transfusion rate (%)	Post-op stay (days)	Morbidity (%)	Mortality (%)	RO (%)
Magistri et al. [40]	2017	22	61	18:4	10% major hepatectomy	318	400 (50–1500)	0	5	NR	59	0	96
Morel P [41]	2017	16	60	7:9	69% malignant (all minor)	352	NR	0	6	8	31	0	100
Wang et al. [42]	2018	63	NR	43:20	All HCC, 1 major hepatectomy	296	206	NR	NR	NR	11	NR	94
Ceccarelli et al. [43]	2018	70	NR	NR	26% malignant	NR	NR	10	NR	NR	NR	0	NR
Sucandy et al. [44]	2019	80	63	5:3	46% major hepatectomy	233	150	1	NR	3	14	1	NR

Table 4.
Recent results of robotic liver surgery.

9.1 Results from robot liver resection

Due to the less complex nature of surgery the most common robotic liver procedures performed globally are minor hepatectomy; segmentectomies (29%), left lateral sectionectomies (13%) and bisegmentectomies (9%). **Table 3** demonstrates the types and frequency of robotic hepatectomy.

This table illustrates the frequencies of the different types of robotic liver resections reported in the literature since 2013.

A recent meta-analysis published in 2013 has summarised the results of robotic liver resection up to 2013 [30]. The reader is directed here for the early results of robotic liver resection. In summary the number of major hepatectomies reported in the literature increased as experience with robotic surgery improved. The overall data suggested that robotic assisted liver surgery was comparable to both open and laparoscopic surgery in terms of peri-operative and postoperative outcomes, as well as oncologic efficacy. Complex procedures, such as extended liver resections were suggested to be technically easier due to the intrinsic advantages of the robotic system.

We discuss the results of robotic liver resection from 2013 to the current period. A number of selected studies reporting outcomes for robotic liver surgery since 2014 are shown in **Table 4**. This list is an exhaustive but highlights the progress that has been made worldwide in advancing robotic liver surgery. Achieving complete resection margins in liver surgery is critical for disease- and recurrence-free survival. It is currently still under investigation if minimal invasive techniques with reduced haptic feedback result in the same oncological results as open surgery. Unfortunately some studies still do not report complete resection rates (termed R0) in their data. However reviewing studies from 2014 onwards most report R0 resection rates of over 90% with many reporting 100%. The long-term outcome although is not well reported and many of these studies have not had the necessary follow-up time for this to be reported and this data is eagerly awaited. The limited studies that have been published appear to report equivalent disease-free and overall survival reported for HCC patients undergoing robotic-assisted versus laparoscopic liver surgery [37]. Although as discussed above robotic liver surgery carry increased costs the reported blood loss is in line with open and laparoscopic surgery and there is reassuringly low open conversion rate that is equivalent to laparoscopic surgery.

As the experience with robotic surgery has increased more recent studies have shown that the rate of major hepatectomy completed robotically has increased with low mortality. The morbidity however needs to be carefully interpreted as many studies report overall complications, that include minor complications, whereas as other has reported major complications only.

10. The future of robotic liver surgery

The robotic platform has distinct advantages over open and laparoscopic surgery and in some instances overcomes the limitations associated with these approaches. In particular the 3-D view, improved images and increased dexterity of operating improve the operators ability to carry out surgery without compromising patient safety. As demonstrated in this chapter the safety and feasibility of robotic liver surgery has been shown worldwide.

The future in robot liver surgery may lie in using this platform to perform more complex liver surgery such as extended liver resections or by incorporating digital technology into the operating system but most importantly the for the field to keep evolving there is a real need for randomised clinical trials. This will allow definition

of benefits and demonstrate the real advantage of this approach for both patients and the surgical fraternity. The authors believe that will be the most effective route to the wider dissemination of this technology.

11. Conclusions

The current data suggest that both major and minor robotic hepatectomy is a safe and effective procedure with equivalent patient outcomes in terms of morbidity and mortality and oncological resection. There remain some important limitations to the wider dissemination of this technology principally around cost, some around training and so with the platform itself. It is hoped that collaborations between industry, academia and surgeons will overcome these problems allowing robotic liver surgery to be practiced widely and deliver patient benefit.

Conflict of interest

The authors have no conflict of interests to declare.

IntechOpen

Author details

Ricky Harminder Bhogal*, Stephanos Pericleous and Aamir Z. Khan
The Royal Marsden Hospital, London, United Kingdom

*Address all correspondence to: ricky.bhogal@rmh.nhs.uk

IntechOpen

© 2019 The Author(s). Licensee IntechOpen. This chapter is distributed under the terms of the Creative Commons Attribution License (<http://creativecommons.org/licenses/by/3.0>), which permits unrestricted use, distribution, and reproduction in any medium, provided the original work is properly cited. 

References

- [1] Bismuth H, Eshkenazy R, Arish A. Milestones in the evolution of hepatic surgery. *Rambam Maimonides Medical Journal*. 2011;**2**(1):e0021
- [2] Asiyanbola B, Chang D, Gleisner AL, et al. Operative mortality after hepatic resection: Are literature-based rates broadly applicable? *Journal of Gastrointestinal Surgery*. 2008;**12**:842-851
- [3] Dimick JB, Cowan JA Jr, Knol JA, et al. Hepatic resection in the United States, indications, outcomes, and hospital procedural volumes from a nationally representative database. *Archives of Surgery*. 2003;**138**:185-191
- [4] Almersjö O, Bengmark S, Hafström L. Liver resection for cancer. *Acta Chirurgica Scandinavica*. 1976;**142**:139-144
- [5] Langenbuch C. Ein Fall von Resektion eines linksseitigen Schnurlappens der Leber. *Berliner Klinische Wochenschrift*. 1888;**25**:37
- [6] Quattlebaum JK, Quattlebaum JK Jr. Technique of hepatic lobectomy. *Annals of Surgery*. 1959;**149**:648-651
- [7] Fineberg C, Goldburgh WP, Templeton JY 3rd. Right hepatic lobectomy for primary carcinoma of the liver. *Annals of Surgery*. 1956;**144**:881-892
- [8] Lortat-Jacob JL, Robert HG. Well defined technique for right hepatectomy. *Presse Médicale*. 1952;**60**:549-551
- [9] Couinaud C. Lobes et segments hépatiques. *Presse Médicale*. 1954;**62**:709
- [10] Couinaud C. *Le foie*. Paris: Masson; 1957
- [11] Bismuth H, Castaing D. Preoperative echography in hepatobiliary surgery. *Ann Gastroenterol Hepatol*. 1984;**20**:221-223
- [12] Bismuth H, Houssin D, Castaing D. Major and minor segmentectomies "réglées" in liver surgery. *World Journal of Surgery*. 1982;**6**:10-24
- [13] Reich H, McGlynn F, DeCaprio J, et al. Laparoscopic excision of benign liver lesions. *Obstetrics and Gynecology*. 1991;**78**:956
- [14] Hüscher CG, Lirici MM, Chiodini S, et al. Current position of advanced laparoscopic surgery of the liver. *Journal of the Royal College of Surgeons of Edinburgh*. 1997;**42**:219-225
- [15] Wakabayashi G, Cherqui D, Geller DA, et al. Recommendations for laparoscopic liver resection: A report from the second international consensus conference held in Morioka. *Annals of Surgery*. 2015;**261**(4):619-629
- [16] Lanfranco AR, Castellanos AE, Desai JP, et al. Robotic surgery: A current perspective. *Annals of Surgery*. 2004;**239**:14-21
- [17] Satava RM. Surgical robotics: The early chronicles: A personal historical perspective. *Surgical Laparoscopy, Endoscopy & Percutaneous Techniques*. 2002;**12**:6-16
- [18] Intuitive Surgical. Da Vinci Surgical System. Available from: http://www.intuitivesurgical.com/products/davinci_surgical_system/davinci_surgical_system_si/
- [19] Buell JF, Cherqui D, Geller DA, et al. The international position on laparoscopic liver surgery: The Louisville statement 2008. *Annals of Surgery*. 2009;**250**:825-830
- [20] Cho JY, Han HS, Yoon YS, et al. Feasibility of laparoscopic liver

resection for tumors located in the posterosuperior segments of the liver, with a special reference to overcoming current limitations on tumor location. *Surgery*. 2008;**144**:32-38

[21] Casciola L, Patrìti A, Ceccarelli G, et al. Robot-assisted parenchymal-sparing liver surgery including lesions located in the posterosuperior segments. *Surgical Endoscopy*. 2011;**25**:3815-3824

[22] Kingham TP, Scherer MA, Neese BW, et al. Image-guided liver surgery: Intraoperative projection of computed tomography images utilizing tracked ultrasound. *HPB: The Official Journal of the International Hepato Pancreato Biliary Association*. 2012;**14**:594-603

[23] Hung AJ, Patil MB, Zehnder P, et al. Concurrent and predictive validation of a novel robotic surgery simulator: A prospective, randomized study. *The Journal of Urology*. 2012;**187**:630-637

[24] Agcaoglu O, Aliyev S, Taskin HE, et al. Malfunction and failure of robotic systems during general surgical procedures. *Surgical Endoscopy*. 2012;**26**:3580-3583

[25] Ocuin LM, Tsung A. Robotic liver resection for malignancy: Current status, oncologic outcomes, comparison to laparoscopy, and future applications. *Journal of Surgical Oncology*. 2015;**112**:295-301

[26] Li Z, Sun YM, Wu FX, et al. Controlled low central venous pressure reduces blood loss and transfusion requirements in hepatectomy. *World Journal of Gastroenterology*. 2014;**20**:303-309

[27] Tranchart H, Ceribelli C, Ferretti S, et al. Traditional versus robot-assisted full laparoscopic liver resection: A matched-pair comparative study. *World Journal of Surgery*. 2014;**38**:2904-2909

[28] Gagner M, Begin E, Hurteau R, et al. Robotic interactive

laparoscopic cholecystectomy. *Lancet*. 1994;**343**:596-597

[29] Himpens J, Leman G, Cadiere GB. Telesurgical laparoscopic cholecystectomy. *Surgical Endoscopy*. 1998;**12**:1091

[30] Ho CM, Wakabayashi G, Nitta H, et al. Systematic review of robotic liver resection. *Surgical Endoscopy*. 2013;**27**(3):732-739

[31] Tsung A, Geller DA, Sukato DC, et al. Robotic versus laparoscopic hepatectomy: A matched comparison. *Annals of Surgery*. 2014;**259**:549-555

[32] Spampinato MG, Coratti A, Bianco L, et al. Perioperative outcomes of laparoscopic and robot-assisted major hepatectomies: An Italian multi-institutional comparative study. *Surgical Endoscopy*. 2014;**28**:2973-2979

[33] Wu CY, Chen PD, Lee CY, et al. Robotic-assisted right posterior segmentectomies for liver lesions: Single-center experience of an evolutionary method in left semi-lateral position. *Journal of Robotic Surgery*. 2019;**13**:231-237

[34] Boggi U, Caniglia F, Vistoli F, et al. Laparoscopic robot-assisted resection of tumors located in posterosuperior liver segments. *Updates in Surgery*. 2015;**67**:177-183

[35] Montalti R, Scuderi V, Patrìti A, et al. Robotic versus laparoscopic resections of posterosuperior segments of the liver: A propensity score-matched comparison. *Surgical Endoscopy*. 2016;**30**:1004-1013

[36] Lee KF, Cheung YS, Chong CC, et al. Laparoscopic and robotic hepatectomy: Experience from a single centre. *ANZ Journal of Surgery*. 2016;**286**:122-126

[37] Lai EC, Tang CN. Long-term survival analysis of robotic

versus conventional laparoscopic hepatectomy for hepatocellular carcinoma: A comparative study. *Surgical Laparoscopy, Endoscopy & Percutaneous Techniques*. 2016;**26**:162-166

[38] Croner RS, Perrakis A, Hohenberger W, et al. Robotic liver surgery for minor hepatic resections: A comparison with laparoscopic and open standard procedures. *Langenbeck's Archives of Surgery*. 2016;**401**(5):707-714

[39] Nota CLMA, Molenaar IQ, van Hillegersberg R, et al. Robotic liver resection including the posterosuperior segments: Initial experience. *The Journal of Surgical Research*. 2016;**206**(1):133-138

[40] Magistri P, Tarantino G, Guidetti C, et al. Laparoscopic versus robotic surgery for hepatocellular carcinoma: The first 46 consecutive cases. *The Journal of Surgical Research*. 2017;**217**:92-99

[41] Morel P, Jung M, Cornateanu S, et al. Robotic versus open liver resections: A case-matched comparison. *The International Journal of Medical Robotics*. 2017;**13**. <https://doi.org/10.1002/rcs.1800>

[42] Wang WH, Kuo KK, Wang SN, et al. Oncological and surgical result of hepatoma after robot surgery. *Surgical Endoscopy*. 2018;**32**(9):3918-3924

[43] Ceccarelli G, Andolfi E, Fontani A, et al. Robot-assisted liver surgery in a general surgery unit with a "Referral Centre Hub & Spoke Learning Program". Early outcomes after our first 70 consecutive patients. *Minerva Chirurgica*. 2018;**73**(5):460-468

[44] Sucandy I, Schlosser S, Bourdeau T, et al. Robotic hepatectomy for benign and malignant liver tumors. *Journal of Robotic Surgery*. 2019. DOI: 10.1007/s11701-019-00935-0