

We are IntechOpen, the world's leading publisher of Open Access books Built by scientists, for scientists

4,800

Open access books available

122,000

International authors and editors

135M

Downloads

Our authors are among the

154

Countries delivered to

TOP 1%

most cited scientists

12.2%

Contributors from top 500 universities



WEB OF SCIENCE™

Selection of our books indexed in the Book Citation Index
in Web of Science™ Core Collection (BKCI)

Interested in publishing with us?
Contact book.department@intechopen.com

Numbers displayed above are based on latest data collected.

For more information visit www.intechopen.com



Elastometry Indices of Unchanged Liver in Healthy Children

*Mikhail Pykov, Natalia Kuzmina, Nikolay Rostovtsev
and Alexander Kinzersky*

Abstract

Two hundred healthy children aged 3–18 years were included in the study to determine liver stiffness indices by means of shear wave elastometry. The difference is significant when we compared shear wave velocity in children aged 3–6 years, on the one hand, and in children aged 7–18 years, on the other ($p = 0.001$). Liver stiffness indices in boys and girls were not different. As a result, liver stiffness indices in children in various age groups have been obtained, which can be recommended as normal ones for pediatric patients.

Keywords: ultrasound diagnostics, shear wave elastography, fibrosis, liver, children

1. Relevance

Chronic diffuse liver diseases are an urgent issue in present children gastroenterology. Interest to this group of liver diseases is due to their increasing incidence, frequent severe course, tendency to progression, and unfavorable outcomes. This problem requires great attention as chronic liver diseases are often polyetiological and their course is insufficiently symptomatic because of the great compensatory capacities of the organ. Clinical manifestations and patient presentation often take place when severe morphological changes have already occurred and adaptation and compensatory mechanisms have been wasted. [1]. Regardless of the etiology, cirrhosis is the cause of fatal outcome in patients due to the development of complications, i.e., hemorrhage from the esophageal varices, ascites, encephalopathy, hemorrhagic syndrome, and transformation to hepatocellular carcinoma [2]. In children chronic liver diseases develop as a result of influence of various etiologic factors such as viruses, autoantibodies, cholestasis, metabolic disorders, toxic agents, etc. on the liver parenchyma for a long time. Most often the process evolves due to bile duct disorders (75.6%), alpha-1 antitrypsin insufficiency (63.6%), autoimmune hepatitis (56.9%), chronic hepatitis D (57.4%), and Wilson-Konovalov disease (45.6%) [3].

Diagnosics of early fibrosis changes in the liver is prognostically important in the evaluation of the disease course. Presently, “the gold standard” of diagnostic method in diffuse liver disease is considered transcutaneous puncture biopsy with histologic investigation of tissue sampling, which enables to confirm, specify, and even alter the clinical diagnosis. However, the method is invasive and may cause a number of complications; moreover, in children their number is greater coming up to 4%. There are objective reasons limiting the use of biopsy method, i.e., a small

size of the tissue sampling. As liver fibrosis may have irregular distribution, different locations may show different stages of liver fibrosis and histologic activity [4, 5]. Thus, in pediatric medical practice, specialists are encouraged to search for noninvasive methods enabling not only to reveal liver changes but also to dynamically follow up the fibrosis process.

Ultrasound elastography is a great breakthrough in the evolution of noninvasive methods of visualization of liver conditions in general and ultrasound diagnostics in particular. There are only a few publications describing indices of liver stiffness in children obtained by one-dimensional and two-dimensional shear wave elastography (SWE). While studying stiffness indices in kPa (kilopascal) and m/s, the scientists pay attention to the data on liver stiffness obtained by different ultrasound and elastography techniques which cannot be compared. Normal indices for various age and gender groups are not clearly defined in the literature. Taking all these into account, the purpose of our study is to determine gender-age indices of liver “stiffness” in healthy children.

2. Material and methods

Two hundred healthy children aged 3–18 years were included in the study. Written informed consent was obtained from the legal representatives of all children. The study was approved by the ethics committee of FGBOU DPO, Moscow. All patients were allocated to three age groups according to age periodization of Mazurin and Vorantsov [6]. The first group consisted of 103 children, the second one consisted of 52, and the third one consisted of 45. According to this periodization, extrauterine period (besides the neonatal, infancy, and early childhood periods) includes preschool period (from 3 to 6 years), junior school period (from 7 to 11 years), and senior school period (from 12 to 18 years). There were 103 girls and 97 boys among them. The following criteria were considered allocating children to the control group: height and weight of each child within the interval from 5th to 95th percentile of age norm [7]; absence of liver diseases and (or) congestive heart failure in the anamnesis; absence of inflammatory alterations according to general and biochemical blood analysis (signs of cholestasis, cytolysis); absence of pathology of the liver, bile ducts, pancreas, and spleen according to ultrasound study in the grayscale and Doppler study (chromatic Doppler mapping, impulse-wave Doppler) modes; and a quiet behavior of a child during examination. The examination was performed on Aixplorer device (SuperSonic Imagine, France) by broadband convex sensor acting within frequency range of 1–6 MHz. The study was done when a patient was fasting after standard ultrasound examination of abdominal organs and retroperitoneal space. Finishing the grayscale mode and Doppler ultrasound, elastography shear wave (SWE) mode was started. Tissue stiffness was demonstrated on the screen as a chromatic coded map (qualitative characteristics), and quantitative value of stiffness was evaluated in kilopascal (kPa).

After SWE mode activation, there appeared two images on the screen: the first one, displayed in the real-time mode a scanned area in the B-mode, and the second one, the same image with elastogram (**Figure 1**).

The mapping color depended on the chosen type of chromatic map. The chosen type of chromatic map colored stiffer tissues in red, while softer tissues in blue. The tissues of “mean” stiffness were colored in intermediate colors from light blue and green to yellow.

Elastometry was performed in elder children during breath-holding for not more than 10 s or during shallow breathing in. The patients were in a supine or pronation position. To visualize the liver, subcostal, intercostal, longitudinal, and

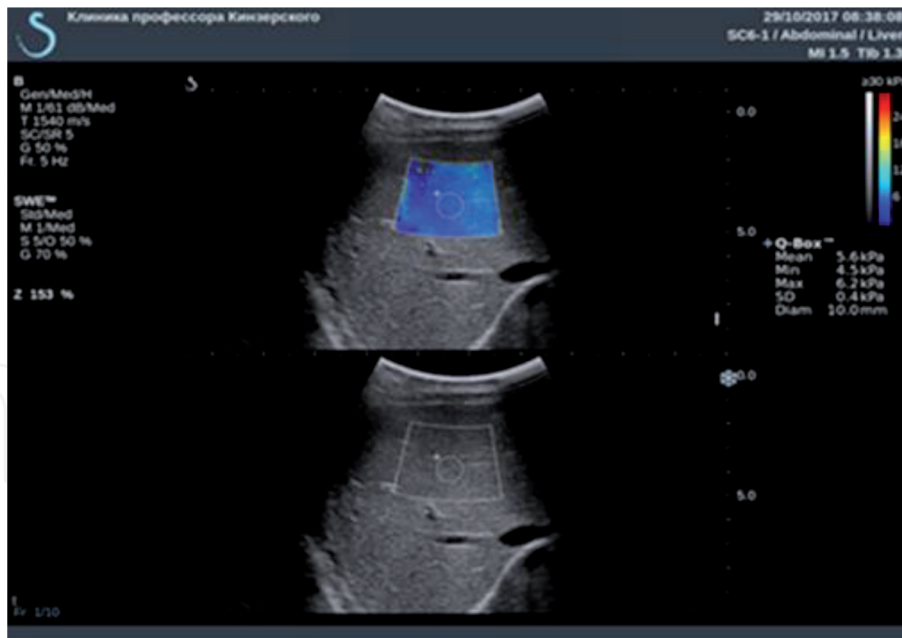


Figure 1.
ESB mode study. Bellow a scanned area in the B-mode, above the same image with elastogram.

transversal epigastric accesses were used. The sensor was placed perpendicularly to the body surface. Measurements were taken in different segments of the right and left hepatic lobes and in the areas free from the vascular structures, fixing the zone of scanning at the depth of 3–5 cm from the capsule. The area of interest (a light window) was chosen with subsequent expectation of image stabilization to get a homogeneous coloring of the light window. The measurement was considered successful when region of interest (ROI) was filled with color by more than 90%. Not <10 measurements were made, which enabled to calculate the mean value of liver stiffness.

3. Statistical analysis of data

Statistical analysis of data was performed by IBM SPSS Statistics 19. If the parameters were normal, Kolmogorov-Smirnov criterion with Liljefors significance adjustment was used. As the distribution of characteristic in one of the groups deviated from normal, Kruskal-Wallis criterion was used with subsequent pairwise comparison by means of nonparametric Mann-Whitney test. All quantitative values were presented as M (mean value), m (standard error of the mean value), σ (standard deviation), median (50th percentile), and 25th–75th percentiles of both minimal and maximal values. Comparison of quantitative parameters was performed using Mann-Whitney test, and qualitative ones were compared by Fisher criterion of accuracy. Differences ($p < 0.05$) were considered significant.

4. Results

Elastography image of the unchanged liver in all patients in the comparison group was characterized by parenchyma coloring of both lobes in homogeneous blue without areas of local stiffness increase (**Figure 2**).

Median of E_{mean} value in the comparison group was 5.00 kPa, E_{max} —6.3 kPa. The obtained data are presented in **Table 1**.

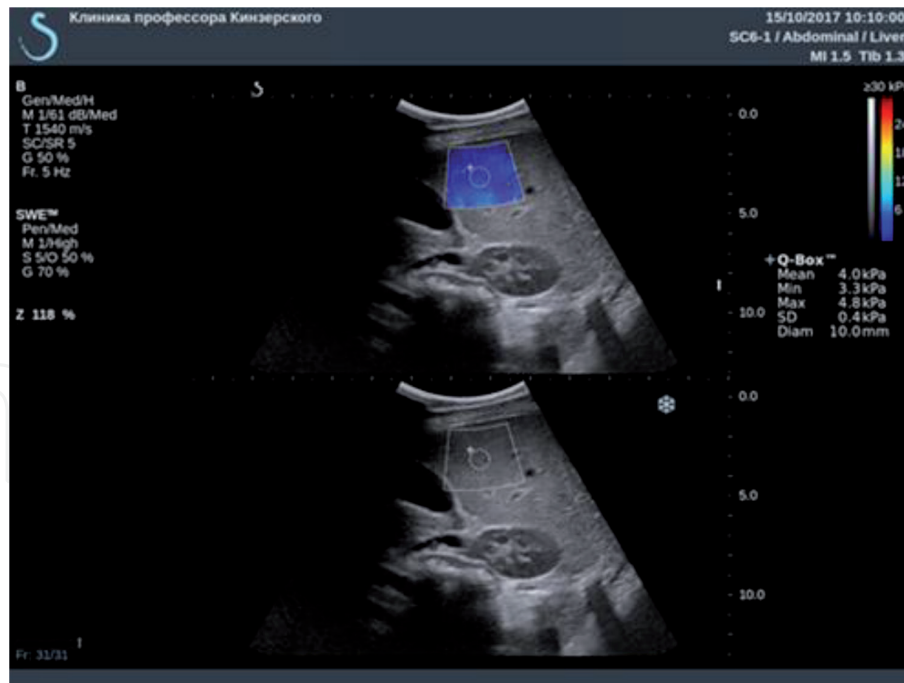


Figure 2. An example of liver stiffness evaluation in a healthy child aged 5 years: B-mode (below) and two-dimensional shear wave elastography mode (above). These are the results of one of 10 measurements. $E_{mean} = 4.0$ kPa. Homogeneous coloring without areas of local stiffness increase.

Group N = 200	Young modulus, kPa				
	$M \pm m$	Median	Maximal-minimal values	25th–75th percentile	σ
3–18 years	5.01 ± 0.03	5.00	3.00–6.30	4.70–5.38	0.49

Table 1. Young modulus value (E_{mean} , kPa) of the unchanged liver parenchyma in the study group of healthy children.

Age groups N = 200	Young modulus, kPa				
	$M \pm m$	Median	Maximal-minimal values	25th–75th percentile	σ
3–6 years (n = 103)	4.89 ± 0.04	4.90	3.48–6.18	4.56–5.22	0.45
7–11 years (n = 52)	5.09 ± 0.07	5.03	3.00–6.00	4.98–5.41	0.48
12–18 years (n = 45)	5.18 ± 0.08	5.24	4.05–6.20	4.77–5.54	0.51

Table 2. Young modulus value (E_{mean} , kPa) of parenchyma of unchanged liver in different age groups.

Median in the age group 3–6 years ($n = 103$) was 4.90 kPa, E_{max} —6.18 kPa. Median in the age group 7–11 years ($n = 52$) was 5.03 kPa, E_{max} —6.00 kPa. Median in the age group 12–18 years ($n = 45$) was 5.24 kPa, E_{max} —6.20 kPa. The obtained data on unchanged liver parenchyma values in different age groups are presented in **Table 2**.

To adjust gender differences in the values of unchanged liver parenchyma, Young modulus analysis in girls ($n = 103$) and in boys ($n = 97$) was performed. E_{mean} median in boys is 5.08 kPa and in girls is 4.99 kPa ($p = 0.345$). The analysis results are presented in **Table 3**.

Group	Young modulus, kPa				
	$M \pm m$	Median	Maximal-minimal values	25th–75th percentile	σ
Boys ($n = 97$)	5.07 ± 0.07	5.08	4.06–6.00	4.82–5.50	0.48
Girls ($n = 103$)	5.03 ± 0.05	4.99	4.26–5.70	4.78–5.33	0.36

Table 3. Young modulus value (E_{mean} , kPa) of parenchyma of unchanged liver in different gender groups of healthy children (aged 3–18 years).

Thus, normal elastography picture of the liver is characterized by homogeneous coloring of parenchyma in the color window without areas of local stiffness increase. Mean value of Young modulus is 5.01 ± 0.03 kPa, and median of E_{mean} value in the comparison group was—5.00 kPa (4.70–5.38). Significant increase of liver stiffness in children older than 6 years was established. Significant gender differences in stiffness were not found.

According to the results of other research groups, the values of the shear wave velocity in the liver parenchyma of the right and left lobes do not have statistically significant differences. Point shear wave elastography (ARFI elastography) was performed by Feoktistova et al. [8] in 100 children aged from 6 months up to 16 years. There were no any significant differences of shear wave speed between the right and left lobes [8]. The authors believed it is possible to measure the stiffness of both the right and left lobes of the liver due to the relatively lesser force of the aortic pulsation, as well as the small thickness of the anterior abdominal wall with a small degree of subcutaneous and preperitoneal fat tissue in the epigastrium. To determine the standard shear wave velocity values [9], 103 children aged from 2 weeks to 17 years were examined. The authors indicate that during statistical processing of data, no significant differences were found in the lobes of the liver [9].

Taking into account literature data testifying the absence of significant differences between the right and left lobe stiffness, measurements were made in both of them. The findings were combined to further analyze the quantitative data. Mean liver stiffness value was calculated in 10 measurements in two lobes of each child.

Interestingly, the mean value of stiffness in the control group (5.01 ± 0.03) kPa coincided more with the study of researchers Huang et al. (509 healthy adult volunteers) [10] and Shin et al. (76 healthy children [11], which were 5.10 ± 1.02 and 5.5 ± 1.3 kPa, respectively) (two-dimensional elastometry). The mean value of stiffness in the study of Engelmann et al. (TE) was 4.7 kPa [12]. The results differed from the findings of Franchi-Abella et al. [13] and Tutar et al. [14] where the mean value of stiffness obtained by convex sensor was higher: 6.94 ± 1.42 and 7.41 kPa, respectively. But one should take into consideration that both studies were performed on control groups consisting of 50 healthy children, which may reduce their statistical power.

To adjust age-specific features of unchanged parenchyma stiffness, all study patients were allocated to three groups according to Mazurin and Vorontsov age periodization. Subgroup 1 consisted of 103 children aged 3–6 years. Subgroup 2 consisted of 52 children aged 7–11 years. Subgroup 3 consisted of 45 children aged 12–18 years. Median in the age group 3–6 years ($n = 103$) was 4.90 kPa, in the age group 7–11 years ($n = 52$) was 5.03 kPa, and in the age group 12–18 years ($n = 45$) was 5.24 kPa (Table 2). Significant differences of stiffness were obtained comparing the values in age groups 3–6 and 7–11 years ($p = 0.001$) and 3–6 and 12–18 years ($p = 0.001$). Statistically significant differences between subgroups 2 and 3 were not established ($p > 0.001$). Thus, liver stiffness values in children older than 6 years

are significantly higher. Probably, in a larger sampling, there will appear a tendency to stiffness increase as patients get older.

The same results of stiffness increase with age were established by Engelmann et al. and Sagir et al. [15] who studied normal indices of stiffness by transient elastography method in groups of 240 and 198 children. Engelmann et al. [12] established the values of stiffness median for age group 0–5 years, 4.40 kPa; for age group 6–11 years, 4.73 kPa; and for age group 11–18 years, 5.10 kPa ($p = 0.001$). Sagir et al. [15] also observed age and stiffness dependence: 4.8 ± 1.4 kPa (0–5 years), 5.6 ± 1.3 kPa (6–11 years), and 5.7 ± 1.7 kPa (12–18 years). Stiffness values in these age groups coincided with the results obtained in our study.

As a result of the study, there were no established statistically significant differences in gender stiffness values: E_{mean} median in boys is 5.08 kPa and in girls is 4.99 kPa ($p = 0.345$). Comparing the two groups, statistically significant differences were considered ($p > 0.001$).

Gender characteristics of parenchyma stiffness were analyzed in the work of Franchi-Abella et al. where any differences in stiffness depending on the gender were also not established [13].

5. Conclusion

Young modulus values obtained from healthy children may be recommended as a standard investigation. The use of shear wave elastometry within a complex ultrasound evaluation will contribute to better early diagnostics of the changed parenchyma. Prospectively, a widespread use of ultrasound elastography will result in decreasing the number of biopsies.

Author details

Mikhail Pykov^{1*}, Natalia Kuzmina², Nikolay Rostovtsev³ and Alexander Kinzersky⁴

¹ Division of Pediatric Radiology, Russian Medical Academy of Postgraduate Education, Moscow, Russia

² Ultrasound Diagnostics Department, Chelyabinsk Regional Children Clinical Hospital, Chelyabinsk, Russia

³ Department of Pediatric Surgery, Federal State Budgetary Institution of Higher Education “South Ural State Medical University”, Chelyabinsk, Russia

⁴ Professor Kinzersky Clinic, Chelyabinsk, Russia

*Address all correspondence to: pykov@yandex.ru

IntechOpen

© 2019 The Author(s). Licensee IntechOpen. This chapter is distributed under the terms of the Creative Commons Attribution License (<http://creativecommons.org/licenses/by/3.0>), which permits unrestricted use, distribution, and reproduction in any medium, provided the original work is properly cited. 

References

- [1] Orlovsky DV, Oshmyanskaya NY, Nedzvetskaya NV. Place of puncture biopsy in diagnosis of chronic diffuse liver diseases. *Gastroenterology*. 2013;**48**(2):47-52
- [2] Gotje SV. Liver transplantation: The current state of the problem. *Almanac of the Vishnevsky Institute of surgery*. 2008;**3**(30):9-17
- [3] Gotje SV, Kaganov BS, Zaynutdinov ZM, Tsirulnikova OM. Criteria of diagnostics and clinical course of liver cirrhosis in children. *Infectious Diseases*. 2008;**6**(3):14-21
- [4] Minuk GY, Sutherland LR, Wiseman DA, MacDonald FR, Ding DL. Prospective study of the incidence of ultrasound-detected intrahepatic and subcapsular hematomas in patients randomized to 6 or 24 hours of bed rest after percutaneous liver biopsy. *Gastroenterology*. 1987;**92**(2):290-293
- [5] Dezsófi A, Baumann U, Dhawan A, Durmaz O, Fischler B, Hadzic N, et al. Liver biopsy in children: Position paper of the ESPGHAN hepatology committee. *Journal of Pediatric Gastroenterology and Nutrition*. 2015;**60**(3):408-420
- [6] Mazurin AV, Vorontsov IM. *Propaedeutics of Children Diseases*. Moscow: Medicine; 1985. p. 432
- [7] Baranov AA, editor. *Pediatrics. National Guidelines*. GEOTAR-Media: Moscow; 2009. p. 1024
- [8] Feoktistova EV, Pykov MI, Amosova AA, Tarasov MA, Dubrovin MM. Application of ARFI—Elastography for liver stiffness evaluation of children of different age groups. *Ultrasound and Functional Diagnostics*. 2013;**6**:46-55
- [9] Hanquinet S, Courvoisier D, Kanavaki A, et al. Acoustic radiation force impulse imaging—Normal values of liver stiffness in healthy children. *Pediatric Radiology*. 2013;**43**(5):539-544
- [10] Huang Z, Zheng J, Zeng J, Wang X, Wu T, Zheng R. Normal liver stiffness in healthy adults assessed by real-time shear wave elastography and factors that influence this method. *Ultrasound in Medicine and Biology*. 2014;**40**(11):2549-2555
- [11] Shin HJ, Kim M-J, Kim HY, Roh YH, Lee M-J. Optimal acquisition number for hepatic shear wave velocity measurements in children. *PLoS One*. 2016;**11**(12). DOI: 10.1371/journal.pone.0168758. [Accessed: 21 December 2016]
- [12] Engelmann G, Gebhardt C, Wenning D, Wühl E, Hoffmann GF, Selmi B, et al. Feasibility study and control values of transient elastography in healthy children. *European Journal of Pediatrics*. 2012;**171**(2):353-360
- [13] Franchi-Abella S, Corno L, Gonzales E, Antoni G, Fabre M, Ducot B, et al. Feasibility and diagnostic accuracy of supersonic shear-wave elastography for the assessment of liver stiffness and liver fibrosis in children: A pilot study of 96 patients. *Radiology*. 2016;**278**(2):554-562
- [14] Tutar O, Beşer ÖF, Adaletli I, Tunc N, Gulcu D, Kantarci F, et al. Shear wave elastography in the evaluation of liver fibrosis in children. *Journal of Pediatric Gastroenterology and Nutrition*. 2014;**58**(6):750-755
- [15] Sagir A, Ney D, Oh J, Pandey S, Kircheis G, Mayatepek E, et al. Evaluation of acoustic radiation force impulse imaging (ARFI) for the determination of liver stiffness using transient elastography as a reference in children. *Ultrasound International Open*. 2015;**1**(1):E2-E7. DOI: 10.1055/s-0035-1554659