

We are IntechOpen, the world's leading publisher of Open Access books Built by scientists, for scientists

4,800

Open access books available

122,000

International authors and editors

135M

Downloads

Our authors are among the

154

Countries delivered to

TOP 1%

most cited scientists

12.2%

Contributors from top 500 universities



WEB OF SCIENCE™

Selection of our books indexed in the Book Citation Index
in Web of Science™ Core Collection (BKCI)

Interested in publishing with us?
Contact book.department@intechopen.com

Numbers displayed above are based on latest data collected.
For more information visit www.intechopen.com



Allograft Structural Interbody Spacers Compared to PEEK Cages in Cervical Fusion: Benchtop and Clinical Evidence

Nigeste Carter, Elena C. Gianulis and Mark A. Moore

Abstract

Cervical degenerative disc disease (CDDD) can lead to radiculopathy and myelopathy, resulting in pain, lack of function, and immobility. Anterior cervical discectomy and fusion (ACDF) is a common surgical treatment modality for advanced CDDD. ACDF involves removal of the affected disc(s) followed by replacement with a bone or synthetic graft. Historically, autograft has been considered the gold standard for interbody fusion. However, it is often associated with limitations, including donor site morbidity and limited quality and supply, prompting surgeons to seek alternatives. Two of the most common alternatives are structural bone allografts and polyetheretherketone (PEEK) synthetic cages. Both, advantageously, have similar mechanical properties to autologous bone, with comparable elastic modulus values. However, a lack of osseointegration of PEEK cages has been reported both pre-clinically and clinically. Reported fusion rates assessed radiographically are higher with the use of structural bone allografts compared to PEEK cages, while having a lower incidence of pseudarthrosis. This book chapter will discuss in detail the pre-clinical and clinical performance of structural allografts in comparison to conventional PEEK cages.

Keywords: polyetheretherketone (PEEK), structural bone allograft, anterior cervical discectomy and fusion (ACDF), cervical degenerative disc disease, synthetic cage, allograft, irradiation

1. Introduction

Cervical degenerative disc disease is one of the most common diagnoses for patients suffering from neck and back pain. These symptoms may present with various conditions, such as radiculopathy or myelopathy, involving compression of the nerve root and spinal cord, respectively [1]. Patients may suffer from pain, lack of function, immobility and sensory loss. Initial treatments often include anti-inflammatory medicine, immobilization, and physical therapy [1]. However, when conservative treatment options fail, a surgical approach such as anterior cervical discectomy and fusion (ACDF) may be warranted. This anterior approach involves excising the affected disc(s), removing osteophytes, and decompressing the nerve root or spinal cord. Following disc removal, the residual vertebral space is typically implanted with a bone or synthetic graft, with or without the additional support of plates and screws.

Robinson and Smith described this technique in 1955 [2]. Their approach involved implantation of a horseshoe-shaped bone graft harvested from iliac crest, followed by immobilization. Patients treated with this technique demonstrated promising clinical outcomes [2]. In 1958, Cloward described a similar technique, however, it included decompression of the neural structures and implantation of a bone dowel in the interbody space [3]. Regardless of the approach, a graft was used as a spacer to restore disc height, provide stability, and help promote bone fusion. Autograft, generally taken from the iliac crest, is often considered to be the gold standard for interbody fusion [4]. The use of autograft has led to high fusion rates and clinical success, although there are several disadvantages, such as extended operating time, donor site pain, limited supply, and variable quality depending upon the patient's health [5–8]. In an effort to avoid the complications seen with autografts, there has been a decades-old shift towards the use of alternative interbody spacers for treatment of degenerative disc disease [9, 10]. Two of the most common choices have been structural allograft bone or synthetic cages manufactured using polyetheretherketone (PEEK) [10]. Here, a comparison of the material properties and clinical performance of structural allografts and conventional PEEK cages is provided.

2. Bone graft substitutes as intervertebral spacers in ACDF

Structural bone allografts have been used successfully in a broad range of clinical applications including ACDF procedures [11–13]. Although lacking direct osteogenic potential, structural allografts have similar osteoconductive properties to autograft while avoiding complications such as donor site morbidity [14]. Furthermore, studies have shown similar clinical outcomes when comparing the use of allograft to autograft in ACDF procedures [15, 16]. Other commonly used implants include interbody cages made of various materials, including metals, ceramics, and polymers. Metal implants have been widely used as spinal cages for ACDF procedures. In particular, titanium implants offer mechanical strength, maintenance of vertebral disc height, and are available in various forms including mesh and box implants [4]. However, there are concerns regarding the use of titanium implants due to their mismatched mechanical properties compared to native bone. The difference in elastic modulus between bone and titanium can cause stress shielding, weakening the surrounding bone and increasing risk of peri-prosthetic fractures [17]. Bioactive ceramics serve as an attractive alternative due to their demonstrated biocompatibility, osteoconductive potential, and availability [9]. Despite these advantages, varying porosity of ceramics can lead to brittleness, thus making them less ideal implants for load-bearing applications [18]. Finally, various polymers are used in biomedical applications due to their biocompatibility, chemical and mechanical stability, and wide ranging compositions. However, some polymers are not ideal for orthopedic implants due to their malleable nature and weak mechanical properties [19]. One polymer with desirable mechanical properties is polyetheretherketone (PEEK). Compared to autograft, PEEK cages offer shorter operating time and reduced donor site morbidity [4]. This chapter will focus on the properties of structural allograft bone compared to conventional PEEK implants due to their similar mechanical properties and common use. Pre-clinical studies examining mechanical properties, osteoconduction and osseointegration, and clinical fusion rates in the cervical spine will be presented.

2.1 Structural allograft

Allograft bone, sourced from deceased human donors, is readily available and commonly used [20]. Allogenic bone grafts come in various forms, shapes, and

sizes, based on clinical need, and can be either structural or non-structural. The bone is typically processed by physical and chemical means to ensure safety, biocompatibility and clinical suitability. Processing steps can include physical shaping and resizing of the graft for a specific clinical purpose (e.g., an intervertebral body spacer), disinfection and sterilization, and preservation to increase shelf life and simplify storage.

Allograft use in bone grafting procedures dates back many decades, as evidenced by a nineteenth century publication from the Scottish surgeon William MacEwen [21, 22]. He successfully reconstructed an infected humerus of a 4 year-old child using allograft tibial segments obtained while treating effects of rickets. Early in the twentieth century, Fred Albee published a book on bone graft applications, laying the foundation for a surge in bone transplantation procedures that is ongoing [23]. Allograft bone is now widely used for spinal, orthopedic, dental, and trauma applications. Notably, allograft usage in the treatment of degenerative cervical disc disease has increased from 14% in 1999 to 59% in 2008 [24]. Of particular interest here, the use of structural allografts in ACDF procedures dates back as early as 1958. Cloward described the use of frozen allograft bone in 46 patients undergoing ACDF [3]. A cylindrical iliac dowel, commonly known as the Cloward dowel, was implanted into the empty interbody space. Forty-four patients demonstrated complete interbody fusion at 3–4 months post-operative. Numerous studies have since been published discussing the use of various structural allografts in ACDF procedures [18]. Structural allografts continue to be used as interbody spacers due to their ability to support mechanical loads and resist failure. Such structural allografts are comprised of either cortical, cancellous or a combination of both cortical and cancellous bone. Cortical bone is more rigid and provides greater structural support, while cancellous bone confers less mechanical strength, but is more porous, providing an osteoconductive scaffold for neovascularization and osseointegration.

Infection due to allograft transplantation remains a risk, albeit rare. A report released by the Centers for Disease Control and Prevention (CDC) in 2005 estimated an overall allograft-associated infection rate of 0.0004%, emphasizing the unlikely event of allograft-associated disease transmission [25]. This number was developed before additional advanced tissue processing methods, including terminal sterilization, were implemented by many tissue providers. Organizations, such as the American Association of Tissue Banks (AATB) and the Food and Drug Administration (FDA), maintain standards for tissue banking, including donor acceptance criteria, tissue procurement and processing methods, and allograft storage [26, 27]. Additionally, FDA published the Current Good Tissue Practice (CGTP) Final Rule, effective in 2005, setting requirements aimed at “preventing the introduction, transmission and spread of communicable diseases” [28]. AATB and FDA guidelines ensure that human allograft tissues are both clinically suitable and safe. Through the combination of rigorous donor screening and tissue processing, risk of disease transmission is virtually eliminated.

2.2 Synthetics: polyetheretherketone (PEEK) cages

Polyetheretherketone (PEEK) is a non-absorbable, semicrystalline polymer processed through a variety of techniques including extrusion, or injection and compression molding [29, 30]. Chemically, PEEK is made up of an aromatic backbone, interconnected by ketone and ether functional groups [30]. The chemical structure of PEEK gives it distinct qualities such as: stability at high temperatures, resistance to chemical and radiation damage, strength and stiffness. PEEK is available in several configurations including neat (unfilled) and carbon-reinforced PEEK (CRPEEK). The addition of composite fillers, such as carbon fiber, provides those forms of PEEK with increased mechanical strength [30].

Developed in 1978, PEEK was initially commercialized for industrial applications such as aircraft and turbine blades due to its high chemical and mechanical resistance [29, 31]. However, in the late 1980s, it emerged as a potential biomaterial for surgical implantation and rapidly gained acceptance as a medical device. In the late 1990s, PEEK was introduced as a spinal cage implant and has also been used for other orthopedic and dental applications [19]. PEEK cages have become a popular choice due to inherent biocompatibility and favorable mechanical properties compared to traditional metal-based cages. PEEK has undergone numerous biocompatibility and cytotoxicity tests in accordance with both FDA and ISO 10993 standards. Morrison et al. evaluated the response from mouse fibroblasts and rat osteoblasts *in vitro* and found PEEK to display excellent biocompatibility [32]. Rivard et al. demonstrated that PEEK particles implanted in New Zealand white rabbits elicited no apparent necrosis or swelling, leading the authors to suggest that it is “harmless” to the spinal cord [33].

Compared to other synthetic implants such as titanium cages, PEEK has an elastic modulus similar to that of native bone, thus reducing the potential impact of stress shielding on the bone healing process [19, 34]. Another advantage of PEEK is radiolucency which allows for radiographic assessment of fusion [35]. Furthermore, due to its ability to resist radiation damage, PEEK is able to be sterilized by electron beam or gamma irradiation. Despite noted advantages, several concerns have been raised due to how PEEK’s inert nature and low-surface energy might affect the body’s biological response. Adsorption of water at the implant surface plays an important role in protein-surface interactions, and thus cell-surface interactions, which can determine the success of an implant [36]. The hydrophobic nature of PEEK can potentially limit cellular adhesion. This undesirable property has been recently reported in studies finding that conventional smooth PEEK implants have limited osteoconductive properties and limited bone fixation at the implant interface [29, 37]. For example, Phan et al. described a case in which a patient underwent anterior lumbar interbody fusion (ALIF) with a PEEK implant [38]. The authors found evidence of poor integration between the implant and surrounding bone causing the “halo-effect” on CT scans.

These issues have led to several modifications in an attempt to increase PEEK’s bioactivity, including surface coating with synthetic osteoconductive material such as titanium, increasing surface roughness and porosity through chemical modifications, and incorporating bioactive particles [34, 39]. Despite these promising modifications, conventional PEEK is still commonly used and is the focus in this chapter.

3. Engineering studies of PEEK and allograft

Interbody spacers require appropriate mechanical properties to be clinically effective. One important property is elastic modulus, the measure of resistance to deformation in response to applied stress. Mismatches in the elastic modulus between the surrounding vertebral bodies and an implant may lead to issues such as subsidence and stress shielding [40]. Clinically, these issues can cause complications such as pseudarthrosis and non-unions. Thus, it is ideal for an implant to have a similar elastic modulus as native bone. Heary et al. measured the elastic modulus and stiffness of various spinal interbody implants including neat and carbon-reinforced PEEK and cancellous and cortical bone [40]. The authors found that the elastic modulus of neat PEEK was similar to cancellous allograft bone, 3.84 and 3.78 GPa, respectively (**Figure 1**). Similarly, carbon-reinforced PEEK demonstrated a comparable elastic modulus to cortical allograft bone, 17.94 and 14.64 GPa, respectively. The study demonstrates the similar elastic modulus of allograft and

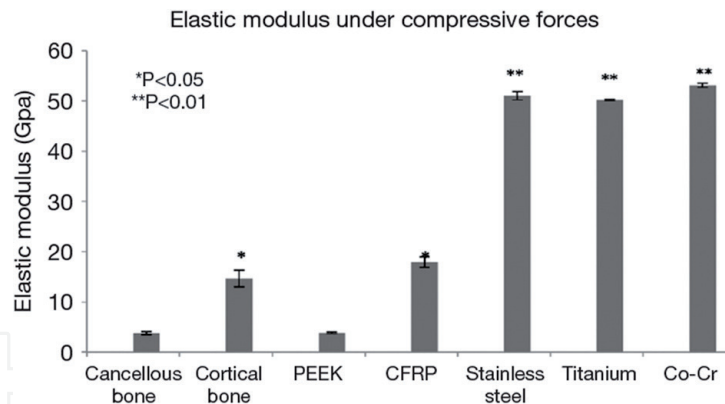


Figure 1. Elastic modulus of all materials (* $p < 0.05$; ** $p < 0.01$). Reprinted with permission from Heary et al. [40].

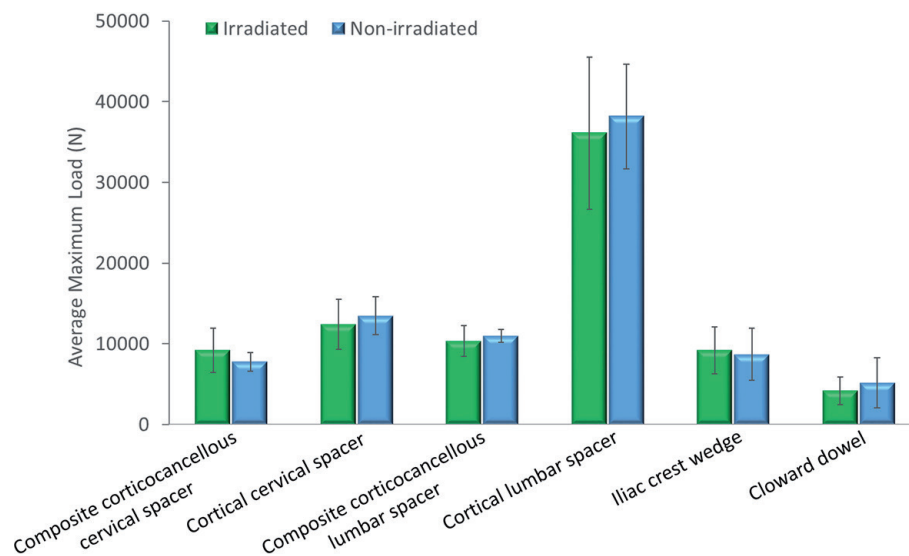


Figure 2. Compressive strength of disinfected and irradiated vs. disinfected only structural bone allografts used in spinal fusion procedures. Compressive strength was defined as the maximum load that the graft could withstand before graft failure. Disinfected structural allografts were divided into either non-irradiated or irradiated groups, with a targeted absorbed dose of 15 kGy. Irradiation did not significantly alter the compressive strength of any of the structural allografts.

PEEK implants and contrasts with the stiffer stainless steel, titanium, and cobalt-chrome materials.

The success of a spinal fusion procedure depends, in part, on the mechanical strength of the interbody spacer. Failure of the spacer can lead to graft subsidence and non-union. Native vertebral bodies have been reported to withstand average compressive strengths up 2400 N for cervical and 8600 N for lumbar joints [41, 42]. It is desirable for interbody spacers to withstand a compressive strength comparable to that of the relevant autologous bone in that surgical procedure (e.g., cervical vs. lumbar). Since structural allografts are typically processed to disinfect or sterilize, and to preserve for storage before use, these methods have the potential to alter clinically relevant properties. The biomechanical strength of several configurations of structural bone allografts was assessed following disinfection using one such method, the proprietary Allowash[®] process (United States Patents 5,556,379; 5,820,581; 5,977,034; 6,024,735). In addition, samples were tested with or without a sterilizing dose of gamma irradiation performed at ultra-low temperatures (Figure 2). The results indicate that bone grafts can be disinfected and retain a strength greater than that of pertinent vertebral bodies, but can also be sterilized under controlled conditions without negative impact on the clinically relevant

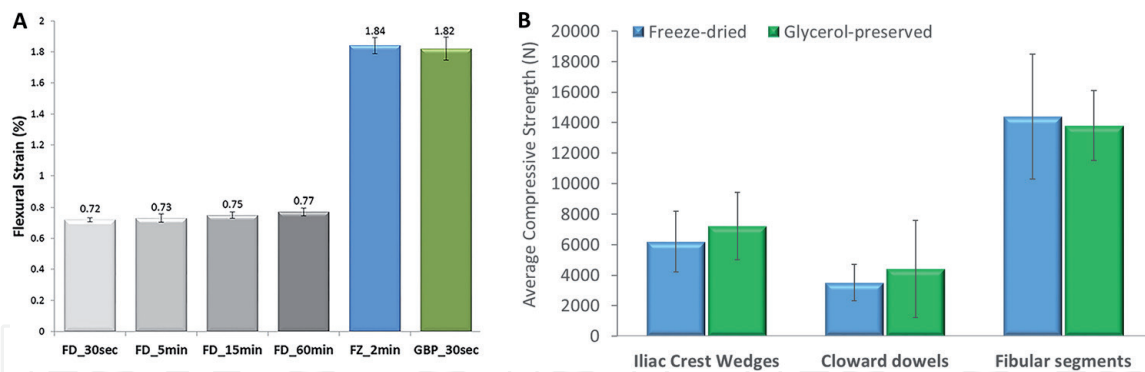


Figure 3.

Biomechanical properties of structural allografts preserved by different methods. Different types of disinfected structural bone allografts were preserved by either freezing, freeze-drying or glycerol preservation, followed by irradiation with a targeted absorbed dose of 15 kGy. Panel (A) shows the average flexural strain of cortical bone allografts preserved by the different approaches. The glycerol-preservation and frozen groups were not significantly different, but both demonstrated significantly greater average maximum flexural strain compared to the freeze-dried group. Modified and reprinted with permission from Samsell et al. [44] according to the Creative Commons Attribution 4.0 International License (<https://creativecommons.org/licenses/by/4.0/legalcode>). (B) Average compressive strength of structural allografts that were either freeze-dried or preserved using a glycerol-based solution. The compressive strength was not different between the freeze-dried and glycerol-preserved groups for all three graft types.

characteristics of the bone. Additionally, it has been separately demonstrated that moderate doses of irradiation (up to 28.5 kGy) performed at ultra-low temperatures do not alter the compressive strength or elastic modulus of structural allografts compared to non-irradiated controls [43].

Likewise, storage conditions can potentially alter properties of structural bone allografts before use. Traditionally, bone grafts have been provided frozen, with storage at -20°C , or freeze-dried, which allows for storage at room temperature. Frozen grafts require special shipping and storage, and must be thawed prior to use. Freeze-dried allografts can be stored at room temperature, but require rehydration, which may not restore the native biomechanical properties of the graft. More recently, a glycerol-based preservation solution was developed to allow storage of grafts at room temperature [44]. The flexural strain (i.e., elasticity) and compressive strength of various structural bone allografts preserved by either freezing, freeze-drying, or glycerol-based preservation were evaluated. The results demonstrate that the frozen and glycerol-preserved groups were not significantly different, but did display significantly greater flexural strain compared to freeze-dried tissue, even after the freeze-dried bone was rehydrated up to 60 minutes (**Figure 3A**). The compressive strengths of different structural allografts that were either freeze-dried or glycerol-preserved (**Figure 3B**) were found to be unaltered by the preservation method for each type of graft. These results demonstrate that the processing of allograft bone, including disinfection, sterilization by irradiation and varying preservation methods, does not significantly impair clinically relevant characteristics, notwithstanding the increased brittle nature of freeze-dried bone.

4. Pre-clinical literature review: *in vivo* models

In addition to testing mechanical properties, it is also important to evaluate the biocompatibility of bone graft substitutes. Animal models are a common and useful tool to evaluate the *in vivo* response to implantable materials prior to clinical application. Animal studies have demonstrated fibrous tissue growth and lack of osseointegration related to the use of PEEK implants.

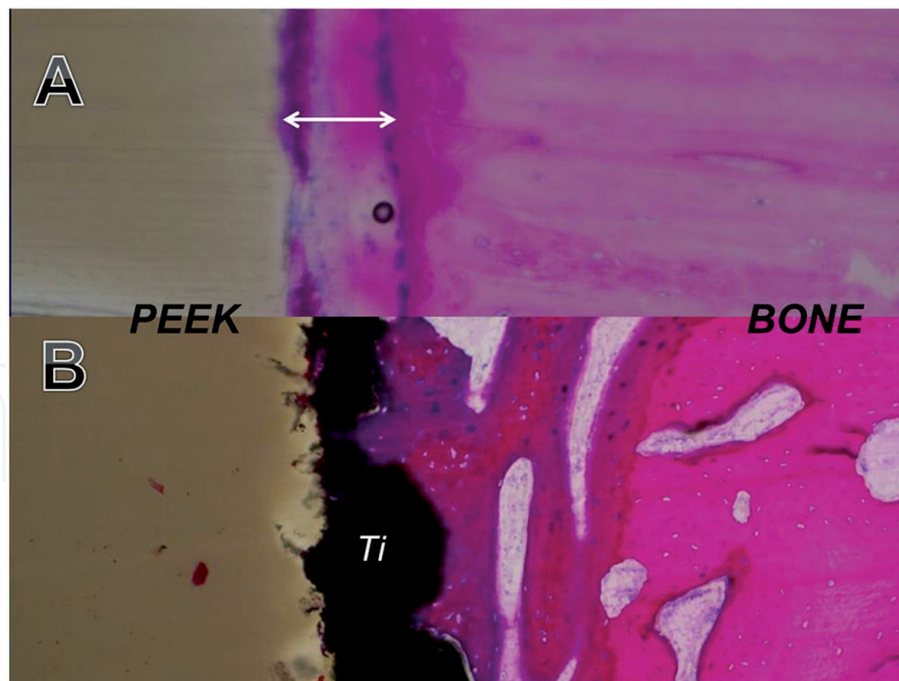


Figure 4. Histology of PEEK/bone interface at 4 weeks post-implantation into a sheep tibia model. (A) Presence of fibrous tissue (white arrow) between the PEEK implant and adjacent bone—the rim of fibrous tissue results in the halo effect seen on CT imaging. (B) Titanium (Ti)-PEEK/bone interface demonstrating on-growth and ingrowth of bone at the Ti-PEEK/bone interface, with no radiolucent rim evident on CT imaging. Reprinted with permission from Phan et al. [38].

In a technical note, Phan et al. described PEEK's poor integration with the surrounding bone, producing a "PEEK-Halo" effect [38]. This phenomenon is represented by a halo appearance between the implant and bone graft on a CT scan. The authors placed conventional PEEK (c-PEEK) and Ti-sprayed PEEK implants in cortical bone and cancellous bone of adult sheep tibia. Histological analysis of the c-PEEK implant showed a fibrous tissue layer and a gap on the PEEK-bone interface (**Figure 4**). The authors suggest this may be due to inflammatory factors and/or the interaction between PEEK and osteoblastic differentiation. In a cervical interbody fusion model in adult sheep, authors compared the bone-implant interface of conventional PEEK (c-PEEK) and Hydroxyapatite coated PEEK (HA-PEEK) [37]. Micro-CT analysis demonstrated less new bone formation in the c-PEEK group at 6 weeks post-implantation. Furthermore, histological analysis showed a fibrous tissue interface between bone and c-PEEK implants at 6 and 12 weeks post-implantation. Walsh et al. likewise compared the mechanical and histologic properties of conventional PEEK and Ti-PEEK at the bone-implant interface in a sheep model [45]. Sites implanted with c-PEEK appeared static with no bone response. While, encouragingly, Ti-PEEK exhibited in-growth of bone, that is not the focus of this chapter. PEEK-bone implant interface contained a fibrous tissue layer and a gap at 4 and 12 weeks. Direct bone contact for the c-PEEK implants in cancellous bone was minimal at 4 weeks (4.8%) and improved at 12 weeks, but only reached 11.5%. This *in vivo* study is yet another example of fibrous tissue seen at the PEEK interface.

The use of structural allografts in ACDF procedures is well documented, with reported fusion rates similar to that of autologous bone [15, 16]. *In vivo* osseointegration of bone was assessed using a calvarial defect model in athymic rats [44]. A portion of the rat's skull was removed to create a critical size defect, which cannot close on its own. Following creation of the defect site, the investigators implanted human cortical and cancellous bone discs that were preserved by either freezing, freeze-drying, or glycerol-based preservation. At 1 week post-implantation, there

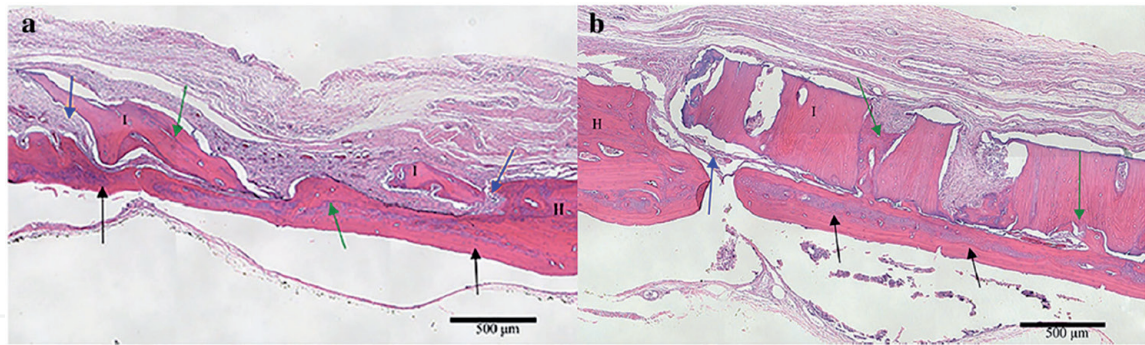


Figure 5. (a) Glycerol-preserved cancellous bone in a tight-fit rat calvarial defect. The scale is 500 μm . (b) Freeze-dried cortical bone in a tight-fit rat calvarial defect at 6 weeks. The scale is 500 μm . Black arrows mark complete bone bridge formation. Blue arrows indicate soft tissue infiltrate. Green arrows mark osseointegration. H, host bone; I, implant bone. Reprinted with permission from Samsell et al. [44] according to the Creative Commons Attribution 4.0 International License (<https://creativecommons.org/licenses/by/4.0/legalcode>).

was apparent soft tissue infiltration in all experimental groups, consistent with an early post-operative response. These findings support the biocompatibility of the bone grafts. Additionally, at 6 weeks post-implantation, the authors observed areas of osseointegration similar to autograft (Figure 5).

5. Clinical data: fusion, nonunion, and pseudarthrosis rates

Both PEEK and allograft spinal implants have a long history of use in ACDF procedures. While mechanical and pre-clinical results can help predict clinical performance, this is ultimately determined through clinical outcomes. Many studies rely upon radiographic fusion to determine clinical success. According to Zdeblick and Phillips, “most published reports use the ‘fusion’ criteria required by the FDA, including motion of less than 5° on flexion-extension radiographs and an absence of lucencies around the cages or cage migration” [46]. Some studies also include pseudarthrosis rates. In the following section, we will compare clinical outcomes for allograft and PEEK implants.

Historically, autograft has been considered the gold standard for spinal fusion procedures, and therefore, it is used as the control to which structural allografts or PEEK implants have been compared. In a retrospective review, investigators evaluated radiographic fusion in 66 patients who underwent one-level ACDF with autograft ($n = 31$) or frozen tricortical iliac crest allograft spacers ($n = 35$), both with anterior plate fixation [16]. Radiographic outcomes were assessed at an average of 12 months follow-up. One hundred percent of patients in the allograft group demonstrated fusion compared to the 90% of patients in the autograft group, although the difference was not statistically significant. Three patients in the autograft group showed evidence of non-union. The authors suggested that the use of allograft can achieve high fusion rates, while avoiding complications associated with autograft, such as donor site pain. In a similar study, radiographic fusion was assessed in 80 patients who underwent multi-level ACDF procedures using autologous ($n = 45$) or allogeneic ($n = 35$) tricortical iliac crest grafts [15]. Radiographic outcomes were assessed in all patients at an average follow-up of 16 months. Successful bone fusion occurred in 100 and 94% of patients in the autograft and allograft group, respectively. Pseudarthrosis occurred in two patients in the allograft group, but was not statistically significant. The authors concluded that allograft can produce solid bone fusion similar to autograft without the associated donor site pain. Finally, in a prospective study, Cho et al. compared the radiographic outcomes of PEEK cages

filled with autologous iliac bone marrow vs. autologous iliac crest graft only in 80 patients who underwent ACDF, with the number of levels ranging from 1 to 3 [47]. The study revealed 93% fusion in the autograft only group and 100% fusion rate in autograft filled PEEK cage group at an average follow-up of 10 months. It should be noted that the high fusion rate demonstrated by the PEEK group could potentially be associated with inherent bone healing properties of autograft within the cage.

Structural allografts have been used for decades to treat degenerative cervical disc disease. Numerous studies have evaluated radiographic fusion rates following use of structural bone allografts in ACDF procedures. Abla et al. prospectively evaluated 74 patients who were diagnosed with clinically significant cervical spinal stenosis or spondylosis and required ACDF surgery [48]. The investigators used a corticocancellous composite interbody spacer allograft (**Figure 6**) combined with cervical plate fixation. One-level fusion was performed in 34 patients, two levels in 23 patients, three levels in six patients, and four levels in one patient. Early fusion (at 1–3 months post-operative) was seen in 53% of the patients and by 12 months, 100% of the patients had fusion (**Figure 6**). The authors reported no graft failures, and an overall patient satisfaction of 90% at 12 months follow-up.

Another study, conducted by Graham et al. prospectively compared fusion rates using either freeze-dried or glycerol-preserved Cloward dowel allografts in ACDF procedures [49]. The study evaluated 86 patients with random assignment to either freeze-dried ($n = 39$) or glycerol-preserved ($n = 47$) groups (82 and 100 levels, respectively). Radiographic assessment at 6 months follow-up confirmed an overall fusion rate of >95% at all levels. Similarly, Rodway and Gander compared the use of glycerol-preserved vs. frozen interbody corticocancellous composite allografts in 67 patients undergoing ACDF procedures, with the number of levels ranging from 1 to 4 and a 1-year minimum follow-up [50]. Radiographic results demonstrated fusion in 38% of glycerol-preserved and 42% of frozen allografts at 3 months follow-up, and 100% fusion in both groups at 12 months (**Table 1**). Of note, the structural allografts used in each of these studies were sterilized by a low dose of gamma irradiation at ultra-low temperatures. Therefore, the combined results demonstrate the clinical effectiveness of structural allografts in ACDF surgery, regardless of method of preservation or treatment with a sterilizing dose of irradiation.

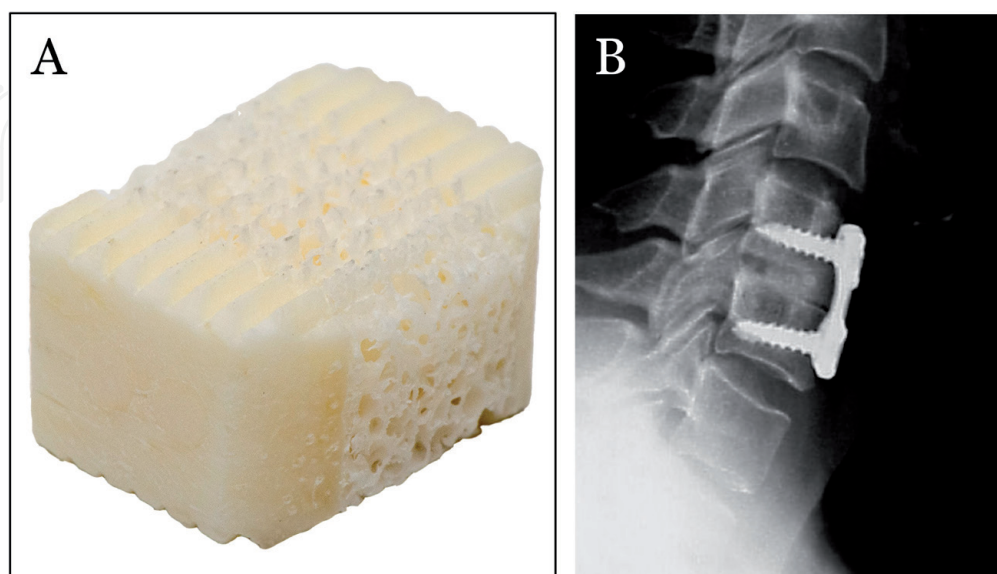


Figure 6. (A) Structural interbody spacer with cancellous bone sandwiched between two plates of cortical bone. (B) Lateral X-ray 6 months after ACDF was performed in a 47-year old woman from C4-C5 using the structural interbody spacer shown. Complete fusion and good alignment were achieved. Modified and reprinted with permission from Abla et al. [48].

	Total patients	Frozen			Total patients	Glycerol-preserved			Frozen versus glycerol statistically similar?
		Fused grafts	Not fused	% of fused patients		Fused grafts	Not fused	% of fused patients	
Three months	38	16	22	42.1%	29	11	18	37.9%	Yes ($P = 0.7343$)
12 months	24.5	24.5	0	100%	17.5	17.5	0	100%	Yes ($P > 0.999$)

*Note that 2 patients had both glycerol-preserved and frozen grafts, 1 level for each type. The results from those patients were counted as 1/2 patients in each group.

Table 1.

Fusion rates by number of patients. Source: "Reprinted with permission from Rodway and Gander [50], according to the Creative Commons Attribution 4.0 International License (<https://creativecommons.org/licenses/by/4.0/legalcode>)".*

In a separate retrospective study, Muzevic et al. evaluated 154 patients who underwent a first-time ACDF surgery for treatment of cervical degenerative disc disease over a 3-year period [51]. One-level fusion was performed in 48 patients, two-level in 56 patients, three-level in 47 patients, and four-level in three patients using either cortical or corticocancellous structural allografts, along with demineralized bone matrix and cervical plating. Solid fusion was achieved in 98% of patients at a mean follow-up of 6 months, with improved overall treatment outcomes in 82% of patients. Finally, Yue et al. reviewed clinical and radiological outcomes in 71 patients who had ACDF surgery performed using structural freeze-dried fibular allografts an average of 7.2 years prior to the review [52]. The authors found that symptoms remained resolved in more than 82% of patients. They observed fusion in 93% of disc spaces, which was comparable to reported fusion rates for autograft [15, 16, 47, 53, 54]. While approximately 17% of the patients required revision surgery, the authors state that this rate is comparable to that following ACDF performed with autograft. Therefore, they attribute this revision rate to be a reflection of "normal" degeneration with age and not to use of allograft.

Several studies have assessed the clinical outcomes of ACDF procedures with the use of PEEK cages. In a prospective study, investigators assessed bone fusion in 52 patients who underwent anterior cervical discectomy with empty PEEK cages. One-level surgery was performed in 44 patients and 2-level surgery in eight patients [55]. Based on radiographic analyses, the authors confirmed bone fusion at 43 treated levels (72%) at an average of 16 months. The authors note the low fusion rates of empty PEEK cages, but stated that the lack of fusion did not affect clinical outcomes. Similarly, Suess et al. evaluated the clinical and radiographic outcomes of 292 patients who received empty PEEK cages for single-level ACDF procedures [56]. PEEK demonstrated radiographic fusion in 126 patients (43%) at 6 months, 214 patients (73%) at 12 months, and 241 patients (83%) at 18 months. The authors noted that slow and incomplete radiographic fusion could be attributed to the use of empty PEEK cages, and therefore did not recommend their use. Furthermore, they suggest this incomplete fusion may lead to reduced improvement in pain and possible disability. Finally, Kim et al. retrospectively evaluated 68 patients who underwent two and three-level ACDF with PEEK packed with demineralized bone matrix [57]. At an average follow-up of 28 months, PEEK demonstrated 81% overall fusion rate, which is less than reported levels for both autograft and structural allograft.

In a retrospective review, Krause et al. looked at 127 patients who underwent one-level ACDF with structural allograft (composite (61/71), cortical (8/71), or cancellous (2/71)) or PEEK cages to examine the incidence of pseudarthrosis as determined by radiography [58]. Fifty six patients (44%) received PEEK implants while 71 (56%) received structural allografts. All PEEK cages were filled with allogeneic demineralized bone matrix (DBM) or local autograft. The PEEK cohort demonstrated a higher rate of radiographic pseudarthrosis at one or more years

after follow-up compared to the allograft cohort, 52 vs. 10% ($p < 0.001$), respectively (**Figure 7**). The investigators concluded that there was a *five-fold higher incidence of pseudarthrosis in patients with PEEK cages*, and almost double the rate of subsequent revision. Furthermore, the investigators suggested PEEK's inability to integrate with organic bone is due to its bio-inertness.

In a similar study, Teton et al. compared pseudarthrosis rates of 62 consecutive patients who underwent multi-level ACDF with structural allograft or PEEK cages, with at least 1 year follow-up [59]. Of 62 patients, 31 received PEEK implants, and 31 received structural allograft. Within the PEEK group, 20 (65%) patients demonstrated radiographic evidence of pseudarthrosis, compared to six (19%) patients implanted with structural allograft ($p < 0.001$), demonstrating *over three-fold higher incidence of pseudarthrosis rates with PEEK*. Furthermore, four patients implanted with PEEK required re-operation due to pseudarthrosis (13%), compared to zero patients with allograft ($p = 0.014$). Additionally, in a retrospective database review, authors analyzed 6130 patients who underwent ACDF with allograft (4063 patients) or intervertebral cages (2067 patients) to compare nonunion rates after

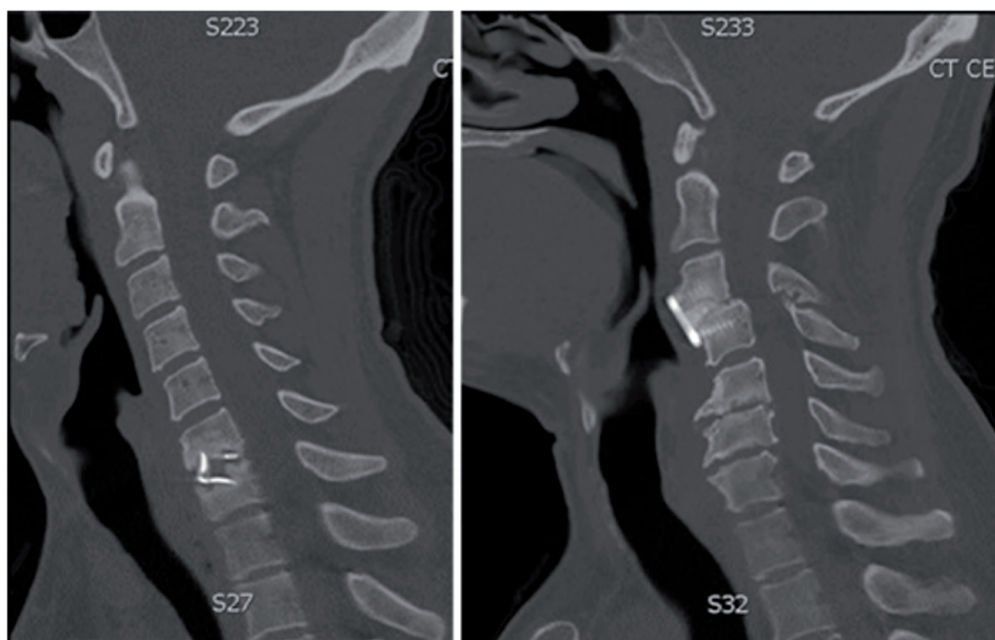


Figure 7. Sagittal X-ray films obtained in a patient with a PEEK interbody graft and pseudarthrosis (left) and a patient with a structural allograft implant (right) healed 1 year after surgery. Reprinted with permission from Krause et al. [58].

Stratified Analysis; Nonunion Rates Between Allograft and Cage, After Controlling for Number of Levels Treated, Diabetes Status, and Tobacco Use			
	Allograft	Cage	P
One-level ACDF	1.9% (35/1835)	4.2% (35/843)	0.0007
Two-level ACDF	1.7% (28/1641)	6.1% (56/921)	<0.0001
3+ level ACDF	2.9% (17/587)	6.3% (19/303)	0.0155
Diabetes +	2.6% (44/1692)	8.3% (61/738)	<0.0001
Diabetes -	1.5% (36/2371)	3.7% (49/1329)	<0.0001
Tobacco +	2.7% (60/2195)	6.7% (69/1034)	<0.0001
Tobacco -	1.1% (20/1868)	4.0% (41/1033)	<0.0001

ACDF indicates anterior cervical discectomy and fusion.

*PEEK, titanium, mesh, or porous (unstratified due to nature of data base).

Table 2. Nonunion Rates Between Structural Allograft and Cages*. Source: Reprinted with permission from Pirkle et al. [60].

Author and year	Number of levels	Graft type	Number of patients	Time of fusion assessment	Fusion rate (%)	Pseudarthrosis rate (%)
Samartzis et al. [16]	2- and 3-level	Autograft	45	16 months	100	N/A
		Structural allograft (tricortical iliac crest)	35		94	
Samartzis et al. [15]	1-level	Autograft	31	12 months	90	N/A
		Structural allograft (tricortical iliac crest)	35		100	
Cho et al. [47]	Multilevel	Autograft	40	Avg. 10 months	93	N/A
		PEEK + autograft	40		100	
Abla et al. [48]	Multilevel	Structural allograft (corticocancellous composite)	74	1–3 months	53	N/A
				12 months	100	
Graham et al. [49]	Multi-level	Allograft (Cloward dowel, freeze-dried)	39	6 months	95	N/A
		Allograft (Cloward dowel, glycerol-preserved)	47		98	
Rodway and Gander [50]	Multi-level	Allograft (corticocancellous composite, glycerol-preserved)	29	3 months	38	N/A
			18	12 months	100	
		Allograft (corticocancellous composite, frozen)	38	3 months	42	
			25	12 months	100	
Muzevic et al. [51]	Multi-level	Allograft (cortical or corticocancellous + DBM)	154	Avg. 6 months	98	N/A
Yue et al. [52]	Multi-level	Allograft (fibular segment, freeze-dried)	71	Avg. 7 years	93	17 (“normal degeneration”)
Pechlivanis et al. [55]	1- and 2-level	PEEK	52	Avg. 16 months	72	28 (nonunion)
Suess et al. [56]	1-level	PEEK	292	6 months	43	N/A
				12 months	73	
				18 months	83	

Author and year	Number of levels	Graft type	Number of patients	Time of fusion assessment	Fusion rate (%)	Pseudarthrosis rate (%)
Kim et al. [57]	2- and 3-level	PEEK + DBM	68	Avg. 28 months	81	N/A
Krause et al., [58]	1-level	PEEK + DBM or autograft	56 (47 DBM; 9 autograft)	Avg. 21 months	N/A	52
		Structural allograft (composite, cortical, or cancellous)	71 (61 composite; 8 cortical; 2 cancellous)	Avg. 16 months	N/A	10
Teton et al. [59]	Multi-level	PEEK	31	1 year	N/A	65
		Structural allograft	31		N/A	19
Pirkle et al. [60]	Multi-level	Intervertebral cages	2067	1 year	N/A	5
		Allograft	4063		N/A	2

Table 3.
Clinical fusion and pseudarthrosis rates following ACFD using autograft, structural allograft, or PEEK cages.

1 year post-operative [60]. Cages were unable to be stratified by type and may have been “PEEK, titanium, mesh, or porous.” Patients were stratified by the number of levels treated, tobacco use, and diabetic conditions. Overall *nonunion rates were significantly higher in the cage group* (5.32%) than in allograft group (1.97%) ($p < 0.0001$). Notably, patients receiving intervertebral cages showed higher rates of nonunion regardless of other factors such as, levels treated, tobacco use, and diabetes (**Table 2**).

6. Summary

While autograft use is common for bone grafting procedures, it is associated with limitations, including donor site morbidity, limited quantities, and unsatisfactory biological activity. For ACDF, autograft use has steadily declined in favor of alternatives, primarily structural bone allografts and PEEK cages [18, 30]. Favorably, each has mechanical properties similar to autograft, with comparable elastic modulus and sufficient strength for intended applications. However, *in vivo* models demonstrate lack of osseointegration for PEEK, as well as fibrous tissue growth. Poor integration can lead to graft subsidence and pseudarthrosis, and ultimately pain, immobility and sensory loss. In contrast, structural allografts act as an osteoconductive scaffold demonstrating osseointegration in a rat model and have a long history of successful clinical use. These differences are reflected in clinical outcomes, as detailed in this chapter and summarized in **Table 3**. As shown, fusion rates when using PEEK cages were generally lower than when structural allografts were used. Moreover, the use of PEEK cages, and cages in general, in ACDF surgery presented a significantly higher rate of pseudarthrosis vs. structural allografts, leading to a greater rate for the need for subsequent revision surgery.

Due to lack of osseointegration of PEEK reported both pre-clinically and clinically, researchers have modified its surface or sought other materials in attempt to improve clinical outcomes. There are promising advances in porous and titanium coatings and clinical efficacy is being assessed.

In conclusion, although conventional PEEK cages have similar elastic modulus as structural allografts and autografts, they display poorer osseointegration characteristics compared to human bone implants. Comparative clinical analyses indicate that structural allografts yield higher fusion rates and lower incidence of pseudarthrosis than conventional PEEK cages in ACDF procedures.

Acknowledgements

We would like to thank Julie B. McLean, PhD, for editorial assistance.

Conflicts of interest

NC, ECG, and MAM are employees of LifeNet Health, a nonprofit organization.

IntechOpen


IntechOpen

Author details

Nigeste Carter, Elena C. Gianulis and Mark A. Moore*
LifeNet Health, Virginia Beach, VA, USA

*Address all correspondence to: mark_moore@lifenethealth.org

IntechOpen

© 2019 The Author(s). Licensee IntechOpen. This chapter is distributed under the terms of the Creative Commons Attribution License (<http://creativecommons.org/licenses/by/3.0>), which permits unrestricted use, distribution, and reproduction in any medium, provided the original work is properly cited. 

References

- [1] Whitecloud TS 3rd. Modern alternatives and techniques for one-level discectomy and fusion. *Clinical Orthopaedics and Related Research*. 1999;**359**:67-76
- [2] Riley LH Jr, Robinson RA, Johnson KA, Walker AE. The results of anterior interbody fusion of the cervical spine. Review of ninety-three consecutive cases. *Journal of Neurosurgery*. 1969;**30**(2):127-133
- [3] Cloward RB. The anterior approach for removal of ruptured cervical disks. *Journal of Neurosurgery*. 1958;**15**(6):602-617
- [4] Song KJ, Choi BY. Current concepts of anterior cervical discectomy and fusion: A review of literature. *Asian Spine Journal*. 2014;**8**(4):531-539
- [5] Bhadra AK, Raman AS, Casey AT, Crawford RJ. Single-level cervical radiculopathy: Clinical outcome and cost-effectiveness of four techniques of anterior cervical discectomy and fusion and disc arthroplasty. *European Spine Journal*. 2009;**18**(2):232-237
- [6] Shen FH, Samartzis D, Khanna N, Goldberg EJ, An HS. Comparison of clinical and radiographic outcome in instrumented anterior cervical discectomy and fusion with or without direct uncovertebral joint decompression. *The Spine Journal*. 2004;**4**(6):629-635
- [7] Suchomel P, Barsa P, Buchvald P, Svobodnik A, Vanickova E. Autologous versus allogenic bone grafts in instrumented anterior cervical discectomy and fusion: A prospective study with respect to bone union pattern. *European Spine Journal: Official Publication of the European Spine Society, the European Spinal Deformity Society, and the European Section of the Cervical Spine Research Society*. 2004;**13**(6):510-515
- [8] Russell JL, Block JE. Surgical harvesting of bone graft from the ilium: Point of view. *Medical Hypotheses*. 2000;**55**(6):474-479
- [9] Chau AM, Mobbs RJ. Bone graft substitutes in anterior cervical discectomy and fusion. *European Spine Journal*. 2009;**18**(4):449-464
- [10] Chen F, He W, Mahaney K, Noeller J, Mhanna N, Viljoen S, et al. Alternative grafts in anterior cervical fusion. *Clinical Neurology and Neurosurgery*. 2013;**115**(10):2049-2055
- [11] McKoy BE, Wingate JK, Poletti SC, Johnson DR 2nd, Stanley MD, Glaser JA. Fibular allograft after anterior cervical corpectomy: Long term follow-up. *The Iowa Orthopaedic Journal*. 2002;**22**:42-46
- [12] Novell J, Novell-Costa F, Ivorra C, Farinas O, Munilla A, Martinez C. Five-year results of implants inserted into freeze-dried block allografts. *Implant Dentistry*. 2012;**21**(2):129-135
- [13] Richards CJ, Garbuz DS, Pugh L, Masri BA. Revision total knee arthroplasty: Clinical outcome comparison with and without the use of femoral head structural allograft. *The Journal of Arthroplasty*. 2011;**26**(8):1299-1304
- [14] Miller LE, Block JE. Safety and effectiveness of bone allografts in anterior cervical discectomy and fusion surgery. *Spine*. 2011;**36**(24):2045-2050
- [15] Samartzis D, Shen FH, Goldberg EJ, An HS. Is autograft the gold standard in achieving radiographic fusion in one-level anterior cervical discectomy and fusion with rigid anterior plate fixation? *Spine*. 2005;**30**(15):1756-1761

- [16] Samartzis D, Shen FH, Matthews DK, Yoon ST, Goldberg EJ, An HS. Comparison of allograft to autograft in multilevel anterior cervical discectomy and fusion with rigid plate fixation. *The Spine Journal*. 2003;**3**(6):451-459
- [17] Piscitelli P, Iolascon G, Innocenti M, Civinini R, Rubinacci A, Muratore M, et al. Painful prosthesis: Approaching the patient with persistent pain following total hip and knee arthroplasty. *Clinical Cases in Mineral and Bone Metabolism*. 2013;**10**(2):97-110
- [18] Anderson DG, Albert TJ. Bone grafting, implants, and plating options for anterior cervical fusions. *The Orthopedic Clinics of North America*. 2002;**33**(2):317-328
- [19] Ramakrishna S, Mayer J, Wintermantel E, Leong KW. Biomedical applications of polymer-composite materials: A review. *Composites Science and Technology*. 2001;**61**(9):1189-1224
- [20] AAOS Comprehensive Orthopaedic Review 2. 2nd ed. Rosemont, IL: American Academy of Orthopedic Surgeons; 2018
- [21] de Boer HH. The history of bone grafts. *Clinical Orthopaedics and Related Research*; **1988**(226):292-298
- [22] James CDT. Sir William Macewen. *Proceedings of the Royal Society of Medicine*. 1974;**67**(4):237-242
- [23] Albee FH. Bone-graft surgery. *Clinical Orthopaedics and Related Research*. 1996;**(324)**:5-12
- [24] McGuire KJ, Harrast J, Herkowitz H, Weinstein JN. Geographic variation in the surgical treatment of degenerative cervical disc disease: American Board of Orthopedic Surgery Quality Improvement Initiative; part II candidates. *Spine*. 2012;**37**(1):57-66
- [25] Center for Disease Control and Prevention (CDC). *Allograft-Transmitted Infection: Priorities for Public Health Intervention*; 2005
- [26] *Standards for Tissue Banking*. 14th ed. American Association of Tissue Banks; 2016
- [27] *Regulatory Considerations for Human Cells, Tissues, and Cellular and Tissue-Based Products: Minimal Manipulation and Homologous Use*. 2017
- [28] US Food and Drug Administration (FDA). *Guidance for Industry Current Good Tissue Practice (CGTP) and Additional Requirements for Manufacturers of Human Cells, Tissues, and Cellular and Tissue-Based Products (HCT/Ps)*; 2011
- [29] Toth JM, Wang M, Estes BT, Scifert JL, Seim HB 3rd, Turner AS. Polyetheretherketone as a biomaterial for spinal applications. *Biomaterials*. 2006;**27**(3):324-334
- [30] Kurtz SM, Devine JN. PEEK biomaterials in trauma, orthopedic, and spinal implants. *Biomaterials*. 2007;**28**(32):4845-4869
- [31] Eschbach L. Nonresorbable polymers in bone surgery. *Injury*. 2000;**31**(Suppl 4):22-27
- [32] Morrison C, Macnair R, MacDonald C, Wykman A, Goldie I, Grant MH. In vitro biocompatibility testing of polymers for orthopaedic implants using cultured fibroblasts and osteoblasts. *Biomaterials*. 1995;**16**(13):987-992
- [33] Rivard CH, Rhalmi S, Coillard C. In vivo biocompatibility testing of peek polymer for a spinal implant system: A study in rabbits. *Journal of Biomedical Materials Research*. 2002;**62**(4):488-498
- [34] Ma R, Tang T. Current strategies to improve the

- bioactivity of PEEK. *International Journal of Molecular Sciences*. 2014;**15**(4):5426-5445
- [35] Rao PJ, Pelletier MH, Walsh WR, Mobbs RJ. Spine interbody implants: Material selection and modification, functionalization and bioactivation of surfaces to improve osseointegration. *Orthopaedic Surgery*. 2014;**6**(2):81-89
- [36] Kasemo B, Lausmaa J. Material-tissue interfaces: The role of surface properties and processes. *Environmental Health Perspectives*. 1994;**102**(Suppl 5):41-45
- [37] Walsh WR, Pelletier MH, Bertollo N, Christou C, Tan C. Does PEEK/HA enhance bone formation compared with PEEK in a sheep cervical fusion model? *Clinical Orthopaedics and Related Research*. 2016;**474**(11):2364-2372
- [38] Phan K, Hogan JA, Assem Y, Mobbs RJ. PEEK-Halo effect in interbody fusion. *Journal of Clinical Neuroscience*. 2016;**24**:138-140
- [39] Almasi D, Iqbal N, Sadeghi M, Sudin I, Abdul Kadir MR, Kamarul T. Preparation methods for improving PEEK's bioactivity for orthopedic and dental application: A review. *International Journal of Biomaterials*. 2016;**2016**:8202653
- [40] Heary RF, Parvathreddy N, Sampath S, Agarwal N. Elastic modulus in the selection of interbody implants. *Journal of Spine Surgery*. 2017;**3**(2):163-167
- [41] Przybyla AS, Skrzypiec D, Pollintine P, Dolan P, Adams MA. Strength of the cervical spine in compression and bending. *Spine*. 2007;**32**(15):1612-1620
- [42] Mosekilde L, Mosekilde L. Iliac crest trabecular bone volume as predictor for vertebral compressive strength, ash density and trabecular bone volume in normal individuals. *Bone*. 1988;**9**(4):195-199
- [43] Balsly CR, Cotter AT, Williams LA, Gaskins BD, Moore MA, Wolfenbarger L Jr. Effect of low dose and moderate dose gamma irradiation on the mechanical properties of bone and soft tissue allografts. *Cell and Tissue Banking*. 2008;**9**(4):289-298
- [44] Samsell B, Softic D, Qin X, McLean J, Sohoni P, Gonzales K, et al. Preservation of allograft bone using a glycerol solution: A compilation of original preclinical research. *Biomaterials Research*. 2019;**23**:5
- [45] Walsh WR, Bertollo N, Christou C, Schaffner D, Mobbs RJ. Plasma-sprayed titanium coating to polyetheretherketone improves the bone-implant interface. *The Spine Journal*. 2015;**15**(5):1041-1049
- [46] Zdeblick TA, Phillips FM. Interbody cage devices. *Spine*. 2003;**28**(15 Suppl):S2-S7
- [47] Cho DY, Liao WR, Lee WY, Liu JT, Chiu CL, Sheu PC. Preliminary experience using a polyetheretherketone (PEEK) cage in the treatment of cervical disc disease. *Neurosurgery*. 2002;**51**(6):1343-1349. Discussion 9-50
- [48] Ablal AA, El Kadi H, Bost J, Maroon JC, Wert M. Allograft composite cortical and cancellous bone graft for anterior cervical fusion. *Contemporary Neurosurgery*. 2005;**27**(8):1-6
- [49] Graham RS, Samsell BJ, Proffer A, Moore MA, Vega RA, Stary JM, et al. Evaluation of glycerol-preserved bone allografts in cervical spine fusion: A prospective, randomized controlled trial. *Journal of Neurosurgery. Spine*. 2015;**22**(1):1-10
- [50] Rodway I, Gander J. Comparison of fusion rates between glycerol-preserved and frozen composite allografts in

cervical fusion. *International Scholarly Research Notices*. 2014;**2014**:960142

[51] Muzevic D, Splavski B, Boop FA, Arnautovic KI. Anterior cervical discectomy with instrumented allograft fusion: Lordosis restoration and comparison of functional outcomes among patients of different age groups. *World Neurosurgery*. 2018;**109**:e233-ee43

[52] Yue WM, Brodner W, Highland TR. Long-term results after anterior cervical discectomy and fusion with allograft and plating: A 5- 1-year radiologic and clinical follow-up study. *Spine*. 2005;**30**(19):2138-2144

[53] Geisler FH, Caspar W, Pitzen T, Johnson TA. Reoperation in patients after anterior cervical plate stabilization in degenerative disease. *Spine*. 1998;**23**(8):911-920

[54] Schneeberger AG, Boos N, Schwarzenbach O, Aebi M. Anterior cervical interbody fusion with plate fixation for chronic spondylotic radiculopathy: A 2- -year follow-up. *Journal of Spinal Disorders*. 1999;**12**(3):215-220. Discussion 21

[55] Pechlivanis I, Thuring T, Brenke C, Seiz M, Thome C, Barth M, et al. Non-fusion rates in anterior cervical discectomy and implantation of empty polyetheretherketone cages. *Spine*. 2011;**36**(1):15-20

[56] Suess O, Schomaker M, Cabraja M, Danne M, Kombos T, Hanna M. Empty polyetheretherketone (PEEK) cages in anterior cervical discectomy and fusion (ACDF) show slow radiographic fusion that reduces clinical improvement: Results from the prospective multicenter "PIERCE-PEEK" study. *Patient Safety in Surgery*. 2017;**11**:12

[57] Kim YS, Park JY, Moon BJ, Kim SD, Lee JK. Is stand alone PEEK cage the gold standard in multilevel anterior

cervical discectomy and fusion (ACDF)? Results of a minimum 1-year follow up. *Journal of Clinical Neuroscience*. 2018;**47**:341-346

[58] Krause KL, Obayashi JT, Bridges KJ, Raslan AM, Than KD. Fivefold higher rate of pseudarthrosis with polyetheretherketone interbody device than with structural allograft used for 1-level anterior cervical discectomy and fusion. *Journal of Neurosurgery*. 2018;**30**(1):46-51

[59] Teton Z, II BC, Ahmed Raslan M, Khoi Than M. Use of Polyetheretherketone Interbody Devices for Multi-Level Anterior Cervical Discectomy and Fusion Results in a Three-Fold Higher Rate of Pseudarthrosis Compared to Structural Allograft. *American Association of Neurological Surgeons*; 2019

[60] Pirkle S, Kaskovich S, Cook DJ, Ho A, Shi LL, Lee MJ. Cages in ACDF are associated with a higher nonunion rate than allograft: A stratified comparative analysis of 6130 patients. *Spine*. 2019;**44**(6):384-388