

We are IntechOpen, the world's leading publisher of Open Access books Built by scientists, for scientists

4,800

Open access books available

122,000

International authors and editors

135M

Downloads

Our authors are among the

154

Countries delivered to

TOP 1%

most cited scientists

12.2%

Contributors from top 500 universities



WEB OF SCIENCE™

Selection of our books indexed in the Book Citation Index
in Web of Science™ Core Collection (BKCI)

Interested in publishing with us?
Contact book.department@intechopen.com

Numbers displayed above are based on latest data collected.
For more information visit www.intechopen.com



Quantification of Liver Steatosis

Ioan Sporea, Roxana Şirli and Alina Popescu

Abstract

The prevalence of non-alcoholic fatty liver disease (NAFLD) and non-alcoholic steatohepatitis (NASH) is increasing in the modern world. Fatty infiltration of the liver can be assessed by standard ultrasound, by controlled attenuation parameter (CAP) using the FibroScan device or, more recently, by ultrasound systems that evaluate the attenuation in the liver. Standard ultrasound (US) for steatosis evaluation was used for a long time as a semi-quantitative method for steatosis assessment in the liver. A “bright liver” with “posterior attenuation” is the typical US sign of liver steatosis. Considering the attenuation severity, steatosis is subjectively graded as mild, moderate or severe. Using the kidney/liver ratio, a more accurate evaluation can be made. Controlled attenuation parameter (CAP) was developed by EchoSens, France, and implemented into the FibroScan device. CAP manages an objective assessment of steatosis severity with rather good accuracy. More recently, ultrasound companies such as Hitachi, General Electric and Canon, implemented in their system algorithms which allow an objective assessment of liver steatosis, using the attenuation of the ultrasound beams.

Keywords: non-alcoholic fatty liver disease, non-alcoholic steatohepatitis, liver steatosis, standard ultrasound, controlled attenuation parameter

1. Introduction

In the last years, the field of hepatology changed regarding the etiology of predominant liver diseases. New treatments with direct acting agents (DAA) for HCV chronic infection, or modern analogues for HBV infection, decreased the importance of the very precise evaluation of liver fibrosis severity in these two diseases. Furthermore, the increasing number of patients with obesity, type 2 diabetes or hypertriglyceridemia in the developed world, increased the prevalence of non-alcoholic fatty liver disease (NAFLD) and non-alcoholic steatohepatitis (NASH), changing the focus of hepatologists on these diseases.

Speaking about the risk factors for NAFLD, overweight and obesity play a central role. Worldwide estimations show that approximately 1.9 billion people are overweight and approximately 650 million are obese [1]. In such patients, fatty infiltration of the liver is quite common, going from simple steatosis to NASH. On the other hand, in adult population (and especially in aging population), the prevalence of type 2 diabetes mellitus can be as high as 1/11 individuals [2]. Thus, in this huge cohort of patients, it became essential to make a confident and non-invasive evaluation of liver disease severity. This assessment must reveal the severity of steatosis, the severity of fibrosis and inflammation.

In this chapter, we will cover only the quantification of liver steatosis using ultrasound methods. They are quite simple, inexpensive, and can be performed as point of care methods, by clinicians or by radiologists.

Fatty infiltration of the liver can be assessed by standard ultrasound, by controlled attenuation parameter (CAP) using the FibroScan device (EchoSens, Paris), or, more recently, by ultrasound systems that evaluate the attenuation in the liver.

2. Standard ultrasound (US) for steatosis evaluation

Standard ultrasound (US) for steatosis evaluation was used for a long time as a semi-quantitative method for steatosis assessment in the liver. A “bright liver” with “posterior attenuation” is the typical US sign of liver steatosis (**Figure 1**). Considering the attenuation severity, steatosis is subjectively graded as mild, moderate or severe. Using the kidney/liver ratio, a more accurate evaluation can be made (knowing that in normal conditions, the liver and right kidney have similar ultrasound appearance) (**Figure 2**).

Some studies were published regarding the value of transabdominal ultrasound for the quantification of steatosis, considering liver biopsy as the “gold standard”. In a study performed by Palmentieri et al. [3] the ultrasound “bright liver” echo pattern was compared to liver biopsy in a cohort of 235 patients. “Bright liver” was found in 67% of patients with steatosis of any degree and in 89% of patients with histologic steatosis $\geq 30\%$. The sensitivity (Se), specificity (Sp), positive predictive value (PPV) and negative predictive value (NPV) of “bright liver” echo pattern and “posterior attenuation” for the presence of any steatosis were 64, 97, 96 and 65%,

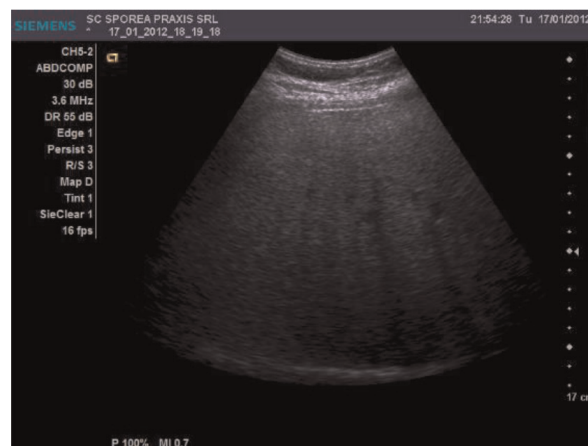

Figure 1.
Moderate steatosis-posterior attenuation.

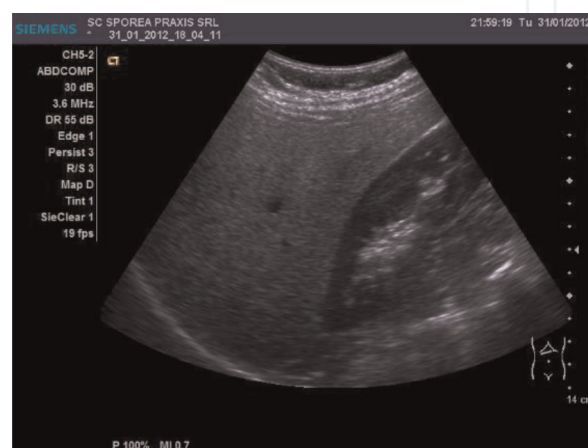

Figure 2.
Increased hepato-renal index.

respectively. However, when only severe steatosis was taken into consideration (a subgroup of patients who had steatosis of $\geq 30\%$) the Se, Sp, PPV and NPV were 91, 93, 89 and 94%, respectively.

In another study performed by Mathiesen et al. [4] liver ultrasound was compared with hepatic histology for steatosis assessment in a series of 165 patients. The steatosis was graded as none, mild, moderate or severe. In patients with increased echogenicity, 86.7% had liver steatosis at least moderate. This study revealed that for the detection of steatosis, standard US had 90% Se, 82% Sp, 87% PPV and 87% NPV.

Some studies tried to use Computer Assisted Diagnosis (CAD) to increase the accuracy of US for the detection and evaluation of steatosis severity [5]. In a study performed in 120 subjects, CAD was able to make a correct classification of steatosis severity with 82.2% accuracy [6].

Similar results were obtained by the group of Xia [7] in a study on 127 subjects. In this study, CAD was used to compare liver attenuation and liver/kidney index by US to magnetic resonance spectroscopy considered as the “gold standard”. A very good correlation of US findings with MRI steatosis quantification ($r = 0.884$) was observed.

Ultrasound hepatic/renal ratio in connection with hepatic attenuation can increase the accuracy of liver fat quantification [8]. In a study performed by Zhang, in a cohort of 170 subjects, where ultrasound was compared with magnetic resonance spectroscopy, an equation of quantitative model for fatty liver prediction was assessed, using ultrasound hepatic/renal ratio and hepatic echo-intensity attenuation rate. In this quantitative ultrasound model, sensitivity and specificity for fatty liver were 94.7 and 100%.

In review paper by Castera et al. [9] it was concluded that liver US has 60–94% sensitivity and 84–95% specificity for detecting hepatic steatosis and that the sensitivity increases with the severity of fatty infiltration.

Probably the most relevant study concerning the performance of US in diagnosing liver steatosis is a large meta-analysis that included 49 studies and 4720 subjects [10]. In this study, the sensitivity of US for moderate and severe steatosis was 84.8%, with 93.6% specificity as compared to liver biopsy, with the area under the summary receiving operating characteristics curve of 0.93. Considering this study as reference, we can say that standard transabdominal US can be used in clinical practice to perform a semi-quantitative evaluation of steatosis, with quite good accuracy. However, if we intend to follow-up these kind of patients, maybe a more objective method is needed, with results expressed as numeric values. On the other hand, the operator’s experience in ultrasound is important for steatosis quantification, and, maybe, the quality of the ultrasound machine should be taken into consideration.

3. Controlled attenuation parameter (CAP)

Controlled attenuation parameter (CAP) was developed by EchoSens, France, and implemented into the FibroScan device. Initially the CAP algorithm was available only on the M probe (for non-obese patients), but more recently it is also available on the XL probe (for obese) (**Figure 3**).

Many studies were published showing the value of CAP for liver steatosis assessment, most of them using liver biopsy as the reference method. CAP measures the total ultrasound attenuation, using vibration controlled Transient Elastography (TE). The measurement results are expressed in dB/m, with values ranging between 100 and 400 dB/m. The first evaluation of CAP was performed in a cohort of 115 patients with liver histology [11]. CAP was very well correlated with steatosis (Spearman $\rho = 0.81$, $p < 0.00001$) and the AUROCs for the detection of >10

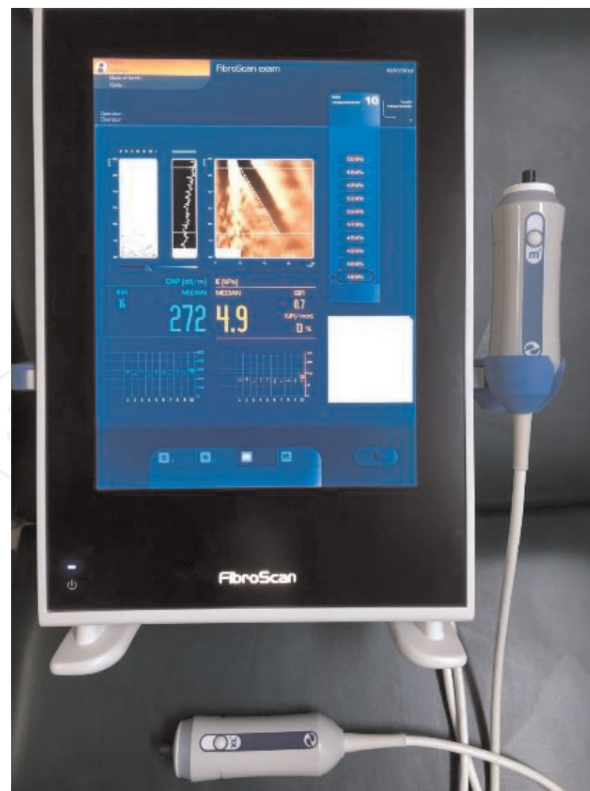

Figure 3. FibroScan with CAP, with M and XL probes. Steatosis values are displayed in light blue and liver stiffness values in yellow.

and >33% steatosis were 91 and 95% respectively. CAP was evaluated also with the XL probe by the same author in a cohort of 59 patients [12]. In this study, the AUROCs for the detection of >2 and >16% liver fat were 83/84% and 92/91% for the M/XL probes, respectively.

Another study performed on 440 patients who had liver biopsy as reference method showed that the AUROCs of CAP for the diagnosis of steatosis >10, >33 and >66% were 79, 84, and 84%, respectively [13]. On multivariate analysis, factors significantly associated with elevated CAP were BMI 25–30 kg/m², BMI > 30 kg/m², metabolic syndrome, alcohol intake more than 14 drinks/week and liver stiffness >6 kPa.

In a study on 201 patients who also had undergone liver biopsy, histologic steatosis was the only factor that independently influenced CAP values [14]. For moderate and severe steatosis, CAP cut-off values of 285 and 294 dB/m had 82.0 and 81.5% accuracy, respectively. However, for mild steatosis, the accuracy was only 76.1% at a cut-off 260 dB/m. These last two studies showed maybe a more realistic value of CAP for liver steatosis assessment, the accuracy being around 80–85% (less for mild steatosis).

In another study in a cohort of 101 NAFLD patients with liver biopsy, CAP was associated in a multivariate analysis with steatosis grade (odds ratio [OR] = 29.16, $p < 0.001$), serum triglycerides (OR = 13.59, $p = 0.037$) and body mass index (BMI; OR = 4.34, $p < 0.001$) [15]. In this study, the optimal CAP cut-offs for estimation of steatosis grades S1 (5–33% of hepatocytes), S2 (>33–66% of hepatocytes), and S3 (>66% of the hepatocytes) were 263dB/m, 281dB/m, and 283dB/m, respectively, and the AUROC's for S1, S2, and S3 were 0.97, 0.86, and 0.75, respectively.

In a very recent multicenter study [16], where FibroScan was compared to liver biopsy in patients with NAFLD, from 450 consecutive patients, 404 patients had valid measurements using M and XL probes. AUROC of CAP for steatosis evaluation was 0.87 for $S \geq S1$, 0.77 for $S \geq S2$, and 0.70 for S3. In the same study, the cut-off values for $S \geq S1$, $S \geq S2$, and $S = S3$ were 302 dB/m, 331 dB/m, and 337 dB/m,

respectively. Two important information came from this study: the AUROCs of CAP are decreasing with the severity of steatosis, and the cut-off values of CAP are higher than in other published studies, for all degrees of steatosis.

In different studies, different cut-off values were proposed for different degrees of steatosis, the first being proposed by the manufacturer: 230 dB/m for mild steatosis, 275 dB/m for moderate steatosis and 300 dB/m for severe steatosis. Other studies obtained different values, but they were correlated with the cohort of patients, with the severity of steatosis, the presence of diabetes and others.

The first meta-analysis evaluating the accuracy of CAP for steatosis quantification showed that the optimal CAP cut-off values for mild, moderate and severe steatosis were 232.5, 255 and 290 dB/m respectively [17]. In this study, the summarized sensitivity and specificity values were 78 and 79% for mild, 85 and 79% for moderate, and 83 and 79% for severe steatosis. However, this meta-analysis calculated a rather low specificity for CAP, being approx. 80%.

Another meta-analysis, comparing CAP with liver biopsy, was performed by Karlas in a cohort of 2735 patients: 37% with chronic hepatitis B, 36% with chronic hepatitis C, 20% with NAFLD/NASH, 7% with other chronic hepatitis. Histologic steatosis distribution was as follows: 51/27/16/6% for S0/S1/S2/S3. In this meta-analysis, the calculated optimal cut-offs were 248 dB/m for S0 vs. S1–S3, 268 dB/m for S0–S1 vs. S2–S3 and 280 dB/m for S0–S2 vs. S3, with AUROCs of 0.82, 0.86 and 0.88 respectively [18].

Other studies compared CAP to MRI quantification of steatosis. Proton density fat fraction (PDFF) by MRI was lately proposed as a sensitive modality of liver fat evaluation. In a cohort of 104 consecutive patients, all with liver biopsy, MRI-PDFF was compared with CAP for diagnosis of steatosis (grades 1–3 vs. 0) [19]. In this study, MRI-PDFF detected any steatosis with an AUROC of 0.99, significantly higher than that of CAP (AUROC 0.85). In the same time, MRI-PDFF identified S2 or S3 with AUROC values of 0.90 and 0.92, while CAP identified S2 or S3 with AUROC values of 0.70 and 0.73.

In another comparative study between CAP and PDFF, performed in Japan in a cohort of 142 patients with NAFLD and liver biopsy, CAP measurements identified patients with $S \geq 2$ with an AUROC of 0.73 and PDFF methods identified them with an AUROC of 0.90 [20].

A comparative study between CAP and PDFF was performed in 119 adults with liver biopsy, evaluating the performance to diagnose 5 and 10% fatty infiltration in PDFF [21]. In this study, using CAP with M or XL probes, AUROC of CAP for the detection of MRI-PDFF $\geq 5\%$ was 0.80 (at the cut-point of 288 dB/m) and of MRI-PDFF $\geq 10\%$ was 0.87 (at the cut-point of 306 dB/m). When the authors considered the IQR (interquartile range) as a qualitative parameter, it was shown that CAP measurements with an IQR (inter quartile range) below 30 dB/m had a more robust AUROC as compared to those with an IQR higher than this (0.92 versus 0.70, $p = 0.0117$).

In the study performed by Wong et al. [22] in a prospective multicenter study, including 754 patients, they found that the IQR of CAP was associated with the accuracy of this method and that the AUROC of CAP was 0.90 in patients with IQR < 40 (and 0.77 if ≥ 40 dB/m, respectively, $p = 0.004$). Finally they proposed like a qualitative criteria for CAP to use IQR < 40 dB/m.

These comparative studies clearly showed a better performance of MRI-PDFF vs. CAP to diagnose steatosis, but we must have in mind that CAP can be a point of care method and that the price of such investigation is much lower than the price of MRI-PDFF. Most published papers concerning the accuracy of CAP for fat quantification calculated accuracies ranging from 0.75 to 0.85, increasing with the severity of steatosis.

4. Ultrasound systems evaluating the attenuation

For a long time the posterior attenuation of ultrasound beams in standard liver evaluation was used as a subjective parameter for steatosis assessment. More recently, ultrasound companies such as Hitachi, General Electric and Canon, implemented in their system algorithms which allows an objective assessment of liver steatosis, using the attenuation of the ultrasound beams.

4.1 Attenuation coefficient (ATT)

Attenuation coefficient (ATT) from Hitachi was evaluated in a prospective multi-center cohort of 351 patients [23], where liver biopsy and ATT measurement were performed in the same day. In this study, the median values of ATT for steatosis grades S0, S1, S2, and S3 were 0.55, 0.63, 0.69 and 0.85 dB/cm/MHz, respectively, increasing with the severity of steatosis ($p < 0.001$). In the same time, the AUROCs for $S \geq 1$, $S \geq 2$, and $S \geq 3$ were 0.79, 0.87, and 0.96, respectively.

The Combi-Elasto algorithm from Hitachi quantifies steatosis (ATT), but in the same time the shear-waves speed is used for estimation of the stiffness or elasticity (E) of the liver expressed in kPa and also to produce some indexes, such as Liver Fibrosis Index (LFI) and Activity Index (AI) (**Figures 4–5**).

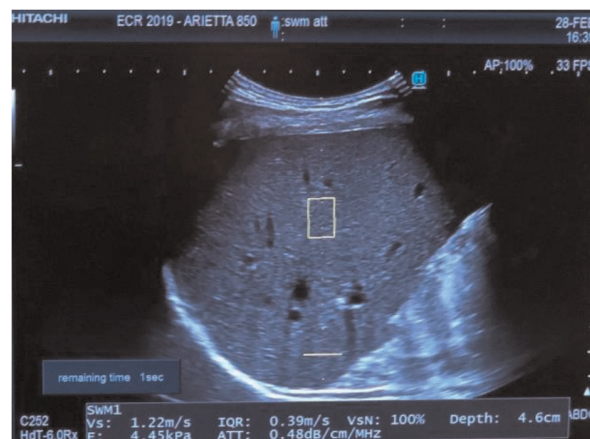


Figure 4.
Attenuation coefficient (ATT).

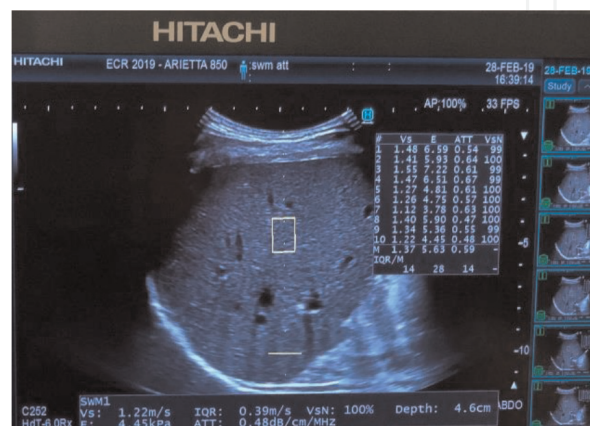


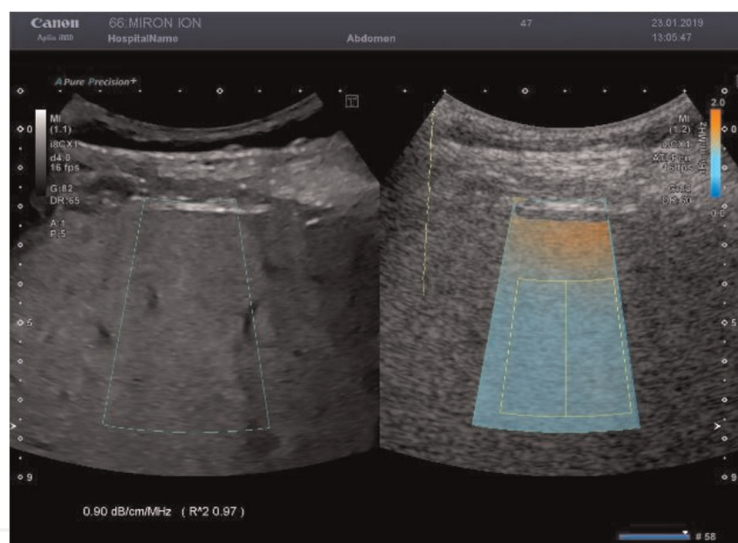
Figure 5.
ATT coefficient with ten measurement values.

4.2 Ultrasound-guided attenuation parameter (UGAP)

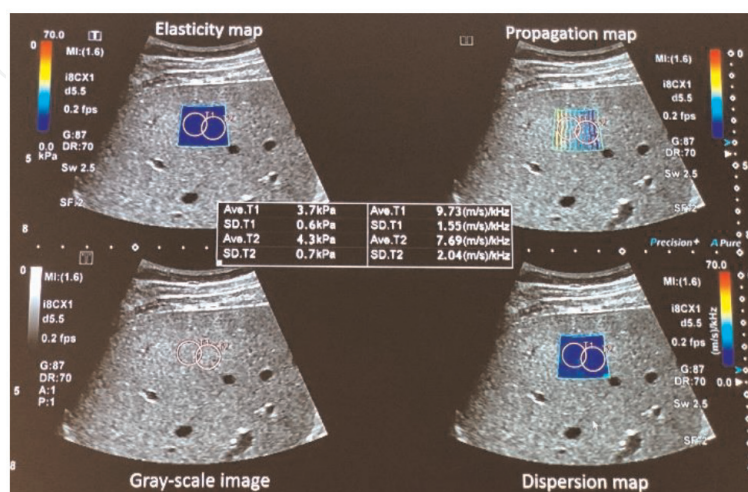
Ultrasound-guided attenuation parameter (UGAP) from General Electric was recently proposed for steatosis quantification. In a paper published by a Japanese group, UGAP was compared with liver biopsy and CAP in a cohort of 163 patients [24]. In this study, the median value of UGAP in patients with S0, S1, S2 and S3 grade steatosis were 0.485, 0.560, 0.660 and 0.720 respectively (increasing with the severity of steatosis), and in the same time, the AUROCs of UGAP for identifying >S1, >S2 and S3 were 0.900, 0.953 and 0.959, respectively, significantly better than the results obtained with CAP.

4.3 Attenuation image (ATI)

Attenuation image (ATI) from Canon was introduced for liver steatosis quantification. This method permit a simple quantification of liver steatosis, by using a region of interest applied on the standard ultrasound image, where the attenuation is evaluated. Values of this parameter are expressed in dB/cm/MHz and it also has a parameter of the quality of acquisition, that must be higher than $R^2 > 0.90$ (Figure 6a).



a



b

Figure 6.

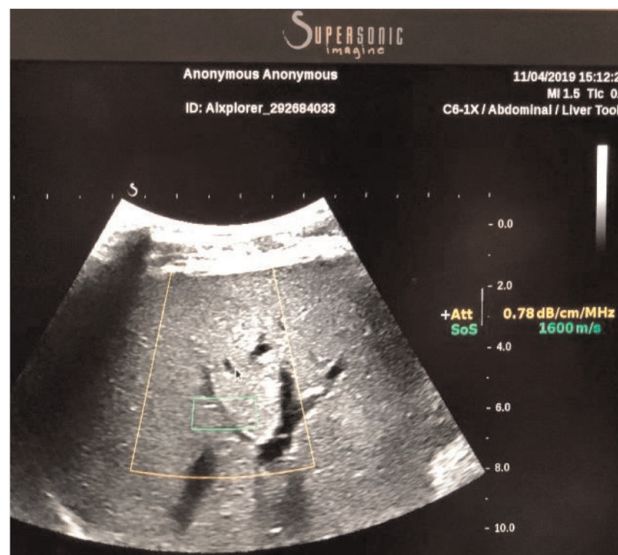
(a) Attenuation image from Canon and (b) evaluation of dispersion with Canon system.

In a preliminary study in which ATI was compared with CAP (FibroScan, EchoSens), in a cohort of 113 consecutive subjects [25], a strong positive correlation was found between the attenuation coefficients of steatosis obtained by the 2 methods, $r = 0.81$, $p < 0.001$. Using CAP as reference, the AUROCs of ATI for $\geq S1$, $\geq S2$ and $\geq S3$ were excellent (0.89, 0.88, respectively 0.95, $p < 0.001$) and the proposed cut-off values for were: $S1 = 0.64$ dB/cm/mHz, $S2 = 0.79$ dB/cm/mHz and $S3 = 0.86$ dB/cm/mHz.

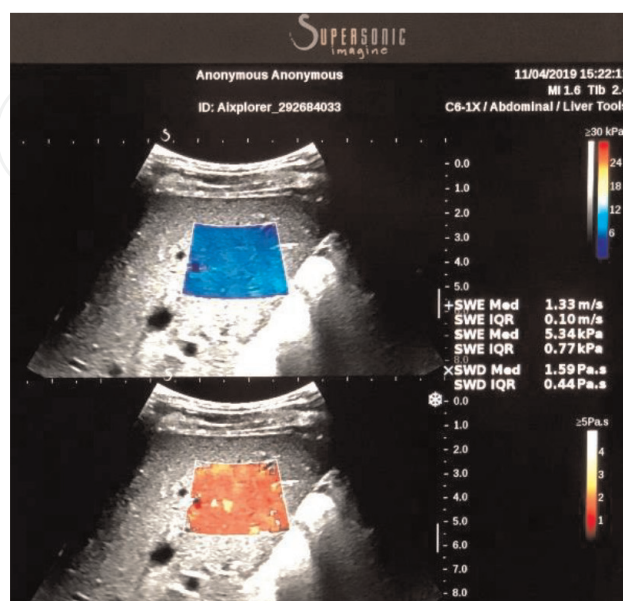
The Canon system can also evaluate dispersion, considering the viscoelastic properties of liver tissue (Figure 6b).

4.4 Attenuation parameter

Attenuation parameter from Aixplorer evaluates attenuation of ultrasound, concomitantly with the display of speed of sound (SoS), used for fatty infiltration estimation. Similar to other modern ultrasound machines, the new system is able to quantify the tissue viscosity, expressed in Pa s (Figure 7a and b).



a



b

Figure 7
(a) Attenuation quantification and (b) viscosity imaging.

Many of the new ultrasound systems are able to estimate with the same machine steatosis severity, liver stiffness and, more recently, inflammation. This is the next step toward a multiparametric approach of liver diseases, using ultrasound machines.

In conclusion, quantification of liver steatosis using ultrasound is a good method for daily practice. The low cost, easy feasibility and accessibility make these methods useful for the large number of potential patients with fatty liver.

IntechOpen

IntechOpen

Author details

Ioan Sporea, Roxana Şirli* and Alina Popescu
Department of Gastroenterology and Hepatology, “Victor Babeş” University of
Medicine and Pharmacy, Timișoara, Romania

*Address all correspondence to: roxanasirli@gmail.com

IntechOpen

© 2019 The Author(s). Licensee IntechOpen. This chapter is distributed under the terms of the Creative Commons Attribution License (<http://creativecommons.org/licenses/by/3.0>), which permits unrestricted use, distribution, and reproduction in any medium, provided the original work is properly cited. 

References

- [1] Loomba R, Sanyal AJ. The global NAFLD epidemic. *Nature Reviews. Gastroenterology & Hepatology*. 2013;**10**:686-690
- [2] International Diabetes Federation. *Diabetes: Facts and Figures*. 2019. Available online: <http://www.idf.org/> [Accessed: 30 June 2019]
- [3] Palmentieri B, de Sio I, La Mura V, et al. The role of bright liver echo pattern on ultrasound B-mode examination in the diagnosis of liver steatosis. *Digestive and Liver Disease*. 2006;**38**:485-489
- [4] Mathiesen UL, Franzen LE, Aselius H, et al. Increased liver echogenicity at ultrasound examination reflects degree of steatosis but not of fibrosis in asymptomatic patients with mild/moderate abnormalities of liver transaminases. *Digestive and Liver Disease*. 2002;**34**:516-522
- [5] Gaitini D, Baruch Y, Ghersin E, et al. Feasibility study of ultrasonic fatty liver biopsy: Texture vs. attenuation and backscatter. *Ultrasound in Medicine & Biology*. 2004;**30**:1321-1327
- [6] Mihăilescu DM, Gui V, Toma CI, et al. Computer aided diagnosis method for steatosis rating in ultrasound images using random forests. *Medical Ultrasonography*. 2013;**15**:184-190
- [7] Xia MF, Yan HM, He WY, et al. Standardized ultrasound hepatic/renal ratio and hepatic attenuation rate to quantify liver fat content: An improvement method. *Obesity*. 2012;**20**:444-452
- [8] Zhang B, Ding F, Chen T, et al. Ultrasound hepatic/renal ratio and hepatic attenuation rate for quantifying liver fat content. *World Journal of Gastroenterology*. 2014;**20**:17985-17992
- [9] Castera L, Vilgrain V, Angulo P. Noninvasive evaluation of NAFLD. *Nature Reviews. Gastroenterology & Hepatology*. 2013;**10**:666-675
- [10] Hernaez R, Lazo M, Bonekamp S, et al. Diagnostic accuracy and reliability of ultrasonography for the detection of fatty liver: A meta-analysis. *Hepatology*. 2011;**54**:1082-1090
- [11] Sasso M, Beaugrand M, de Ledinghen V, et al. Controlled attenuation parameter (CAP): A novel VCTE™ guided ultrasonic attenuation measurement for the evaluation of hepatic steatosis: Preliminary study and validation in a cohort of patients with chronic liver disease from various causes. *Ultrasound in Medicine & Biology*. 2010;**36**:1825-1835
- [12] Sasso M, Audière S, Kemgang A, et al. Liver steatosis assessed by controlled attenuation parameter (CAP) measured with the XL probe of the FibroScan: A pilot study assessing diagnostic accuracy. *Ultrasound in Medicine & Biology*. 2016;**42**:92-103
- [13] de Lédighen V, Vergniol J, Capdepon M, et al. Controlled attenuation parameter (CAP) for the diagnosis of steatosis: A prospective study of 5323 examinations. *Journal of Hepatology*. 2014;**60**:1026-1031
- [14] Lupşor-Platon M, Feier D, Stănescu H, et al. Diagnostic accuracy of controlled attenuation parameter measured by transient elastography for the non-invasive assessment of liver steatosis: A prospective study. *Journal of Gastrointestinal and Liver Diseases*. 2015;**24**:35-42
- [15] Chan WK, Nik Mustapha NR, Mahadeva S. Controlled attenuation parameter for the detection and quantification of hepatic steatosis in

nonalcoholic fatty liver disease. *Journal of Gastroenterology and Hepatology*. 2014;**29**:1470-1476

[16] Eddowes PJ, Sasso M, Allison M, et al. Accuracy of FibroScan controlled attenuation parameter and liver stiffness measurement in assessing steatosis and fibrosis in patients with nonalcoholic fatty liver disease. *Gastroenterology*. 2019;**156**:1717-1730

[17] Shi KQ, Tang JZ, Zhu XL, et al. Controlled attenuation parameter for the detection of steatosis severity in chronic liver disease: A meta-analysis of diagnostic accuracy. *Journal of Gastroenterology and Hepatology*. 2014;**29**:1149-1158

[18] Karlas T, Petroff D, Sasso M, et al. Individual patient data meta-analysis of controlled attenuation parameter (CAP) technology for assessing steatosis. *Journal of Hepatology*. 2017;**66**: 1022-1030

[19] Park CC, Nguyen P, Hernandez C. Magnetic resonance elastography vs transient elastography in detection of fibrosis and noninvasive measurement of steatosis in patients with biopsy-proven nonalcoholic fatty liver disease. *Gastroenterology*. 2017;**152**:598-607

[20] Imajo K, Kessoku T, Honda Y, et al. Magnetic resonance imaging more accurately classifies steatosis and fibrosis in patients with nonalcoholic fatty liver disease than transient elastography. *Gastroenterology*. 2016;**150**:626-637

[21] Caussy C, Alquraish MH, Nguyen P, et al. Optimal threshold of controlled attenuation parameter with MRI-PDFF as the gold standard for the detection of hepatic steatosis. *Hepatology*. 2018;**67**: 1348-1359

[22] Wong VWS, Petta S, Hiriart JB, et al. Validity criteria for the diagnosis

of fatty liver by M probe-based controlled attenuation parameter. *Journal of Hepatology*. 2017;**67**:577-584

[23] Tamaki N, Koizumi Y, Hirooka M, et al. Novel quantitative assessment system of liver steatosis using a newly developed attenuation measurement method. *Hepatology Research*. 2018;**48**: 821-828

[24] Fujiwara Y, Kuroda H, Abe T, et al. The B-mode image-guided US attenuation parameter accurately detect hepatic steatosis in chronic liver disease. *Ultrasound in Medicine and Biology*. 2018;**44**(11):2223-2232

[25] Sporea I, Bâldea V, Lupuşoru R, et al. Value of Viscosity, Viscoelasticity and Attenuation Measurement Using Shear Wave Ultrasound Elastography. Oral Presentation. Granada, Spain: Euroson; 2019