

We are IntechOpen, the world's leading publisher of Open Access books Built by scientists, for scientists

4,800

Open access books available

122,000

International authors and editors

135M

Downloads

Our authors are among the

154

Countries delivered to

TOP 1%

most cited scientists

12.2%

Contributors from top 500 universities



WEB OF SCIENCE™

Selection of our books indexed in the Book Citation Index
in Web of Science™ Core Collection (BKCI)

Interested in publishing with us?
Contact book.department@intechopen.com

Numbers displayed above are based on latest data collected.
For more information visit www.intechopen.com



EUS-Guided Biliary Drainage

Takeshi Ogura and Kazuhide Higuchi

Abstract

Endoscopic ultrasound-guided biliary drainage (EUS-BD) has been developed as an alternative method for failed endoscopic retrograde cholangiopancreatography (ERCP). EUS-BD can be divided into two main approach routes, such as transgastric or transduodenal approach. Also, EUS-guided hepaticogastrostomy, choledochoduodenostomy (CDS), and gallbladder drainage (GBD) have been reported. In this chapter, we described technical tips for each basic technique, including literature review. As advanced technique of EUS-BD, antegrade stone removal has been reported. More recently, electrohydraulic lithotripsy for bile duct stones under transluminal cholangioscopy guidance, hepaticojejunostomy stricture dilation through EUS-hepaticogastrostomy (HGS) route, or EUS-guided gastrojejunostomy has been reported. Although EUS-BD has various potential as treatment technique, treatment method should be selected for each patient's conditions.

Keywords: EUS-guided biliary drainage, EUS-BD, EUS, endoscopic ultrasound-guided biliary drainage, ERCP, endoscopic retrograde cholangiopancreatography, PTBD, percutaneous transhepatic biliary drainage

1. Introduction

Biliary drainage under endoscopic retrograde cholangiopancreatography (ERCP) is the gold standard and is an established technique for malignant biliary obstruction. However, successful selective biliary cannulation is not always obtained. In addition, if the case is complicated by malignant gastroduodenal obstruction or surgically altered anatomy preventing advance of the endoscope into the ampulla of Vater, ERCP itself may not be indicated. As an alternative biliary drainage technique, percutaneous transhepatic biliary drainage (PTBD) is another established technique. However, this alternative may also be contraindicated for patients with massive ascites and shows several disadvantages such as risk of self-tube removal or cosmetic problems. Endoscopic ultrasound (EUS)-guided biliary drainage (BD) has recently been developed as a novel alternative biliary drainage technique. EUS-BD can be divided into two main approach routes: transgastric and transduodenal. In addition, EUS-guided hepaticogastrostomy (HGS), choledochoduodenostomy (CDS), and gallbladder drainage (GBD) have been reported. In this chapter, we provide technical tips for each basic technique and review the associated literature.

2. EUS-guided biliary drainage

2.1 EUS-guided CDS

2.1.1 Indications

EUS-CDS is mainly attempted for patients with failed endoscopic balloon dilation (EBD) excluded prospective clinical trial, as previously described [1, 2]. This procedure can be performed for obstructions in the middle and lower bile duct. This indicates that pancreatobiliary carcinoma is the main indication for EUS-CDS. EUS-CDS is contraindicated in patients with surgically altered anatomy, such as a Roux-en-Y anastomosis or tumor invasion-associated duodenal obstruction through which an endoscope cannot be passed. In such cases, EUS-guided hepaticogastrotomy may be indicated. However, if the duodenal bulb is not involved, EUS-CDS can be performed in combination with duodenal stenting. Optimal indications regarding EUS-CDS versus ERCP for benign disease have not been defined, completely. Prospective randomized controlled studies between ERCP and EUS-CDS are therefore needed to assess the clinical efficacy of the procedure. Indications for EUS-CDS are the following: (1) failed EBD including inaccessibility of the Vater, such as that caused by malignant duodenal obstruction, (2) contraindications for percutaneous transhepatic cholangiography drainage (PTCD), and (3) middle or lower bile duct obstruction. EUS-CDS has recently been attempted as a first-line drainage technique. According to randomized controlled trials [3, 4], EUS-CDS offers similar safety to ERCP. In addition, EUS-CDS may result in fewer cases of tumor ingrowth but may also be associated with greater frequencies of food impaction or stent migration. Further high-quality randomized trials are needed.

2.1.2 Technical tips

The EUS scope is introduced into the duodenum, turned slightly to the left, and angled downward to identify the common bile duct (CBD) on EUS. To avoid any intervening vessels, the CBD should be punctured using a 19-G needle under color Doppler guidance. Then, bile juice is aspirated to ensure the biliary tract, and the contrast medium is injected to obtain image of the CBD. During this step, avoiding puncture of the duodenal mucosa [5, 6] and cystic duct is important. When a double duodenal mucosal line is visualized on EUS, the CBD should not be punctured to avoid puncture and stenting through the double duodenal mucosa. To prevent this adverse event, a water-filling technique may be impactful [5]. After guidewire insertion, to insert the stent delivery system, dilation for the duodenal and CBD wall is sometimes needed. Various devices have been described for dilatation of the fistula after puncturing the CBD. The most common devices for transmural tract dilation are the dilator (6 to 10 Fr), balloon catheter (4–8 mm), and needle knife. Park et al. described that the overall complication rate for EUS-CDS and EUS-HGS was 27% (15/55) [7]. As risk factor for complication associated with EUS-BD ($P = 0.01$, HR 12.4, 95%CI, 1.83–83.5), the use of a needle knife for fistula dilation is identified. Because of the acute angulation of the scope, following deployment of the catheter at the duodenum, the needle knife points tangentially when deployed. This can lead to accidental incision with a chance of pneumoperitoneum or bleeding. Therefore, the author's conclusion is that fistula dilation should be avoided to prevent procedural complication. The next step is stent deployment (**Figures 1–3**).

Endoscopist can select both plastic and metallic stents during EUS-CDS as drainage device. Plastic stents with diameters ranging from 5 to 10 Fr were commonly used according to previous reports. A 7- or 8.5-Fr plastic stent is used,

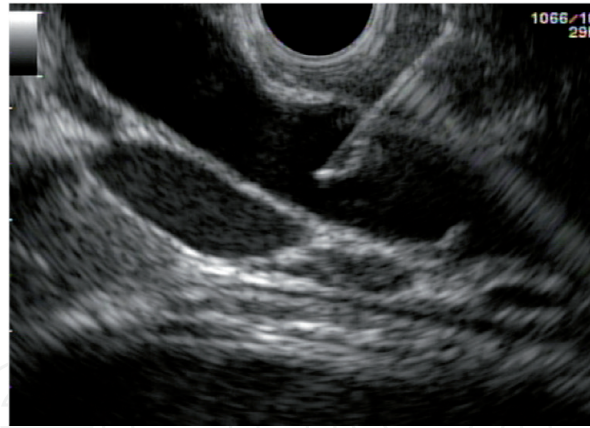

Figure 1.
The common bile duct is punctured using 19-G needle from the duodenal bulb.

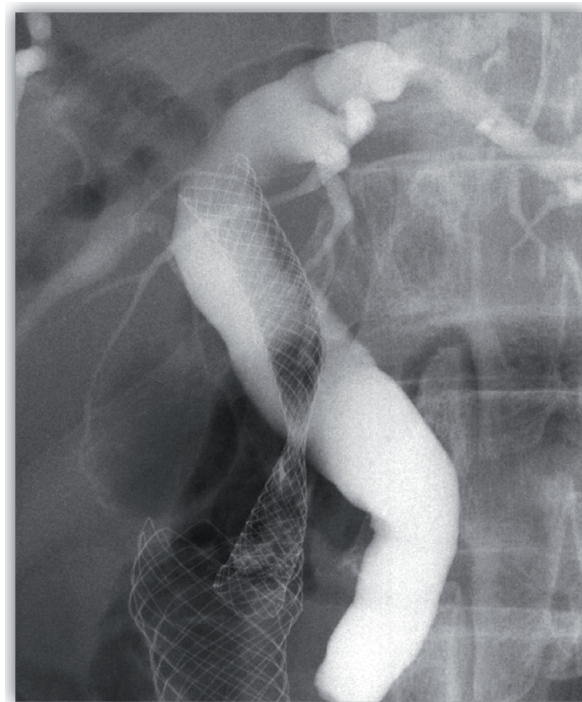


Figure 2.
The covered metal stent deployment is performed from the common bile duct to the duodenum.

because the diameter of the working channel is 3.7 mm. However, bile leakage can occur with plastic stent placement (**Figure 6**). This patient experienced high fever and abdominal pain for up to 3 days after EUS-CDS, and bile leakage was seen according to computed tomography and duodenoscopy. If a large fistula is created before stent deployment, bile leakage from the gap between fistula and the stent is likely to occur because plastic stent is fine gauge compared with metal stent. On the other hand, although no comparative studies appear to have been conducted, metallic stents are expected to offer several clinical benefits. First, because of their large diameter, metallic stents tend to remain in the patent longer than plastic stents.

Second, bile leakage is less likely because of the close proximity between the metallic stent and duodenal and bile duct wall. If an uncovered metallic stent is used, however, bile leakage can easily occur, which sometimes proves fatal. Therefore, covered self-expandable metal stents (SEMSs) should be used. However, although SEMSs can prevent bile leakage, the side branch of biliary tract may be occluded. This suggests that if the distance between the puncture site and hepatic

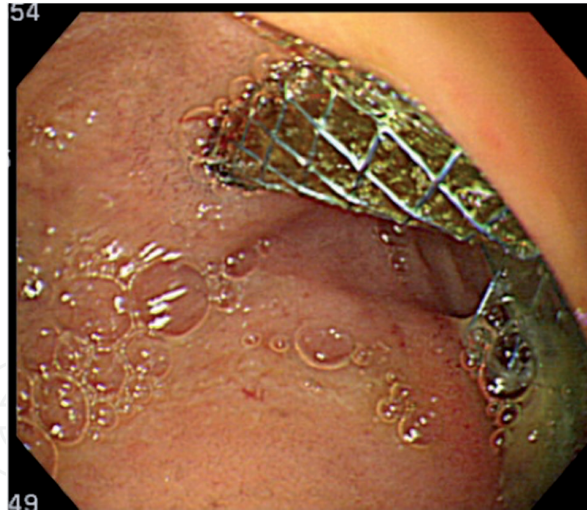


Figure 3.
Metal stent is placed in the duodenum bulb.

hilar portion is short, a partially covered SEMS should be selected to prevent occlusion of the intrahepatic bile duct. However, if EUS-CDS is performed using by a partially covered SEMS, bile leakage can occur from the uncovered site, particularly between the bile duct and duodenum. A challenging complication is stent migration during EUS-BD. In the use of a standard metallic stent in EUS-CDS, some authors have found that a double-pigtail plastic stent should be placed inside the metal stent to prevent stent migration. To prevent stent migration, standard SEMSs with a wide flange should be used, and stent shortening to a length of 60 mm may be preferable. Recently, a novel SEMS has been available. The lumen-apposing metal stent (LAMS) (NAGI Stent; Taewoong Medical Co., Seoul, Korea) is a 10.5-Fr delivery system and consists of a fully covered, 20-mm-long, 16-mm-diameter stent. The hot AXIOS stent (Xlumena, Inc., Mountain View, CA, USA) is a fully covered, 10-mm-diameter delivery system, with 10-mm-long braided stent with bilateral 20-mm-diameter anchor flanges. These novel SEMSs are mainly used for EUS-guided pseudocystic drainage and EUS-guided cholecystogastrostomy [8–10]. These SEMSs also seem useful for EUS-CDS, although clinical trials are needed to confirm their utility.

2.1.3 Clinical results

According to a recent meta-analysis including 572 patients [11], the pooled rate of all adverse events was 0.136 (95% CI, 0.097–0.188; $P = 0.01$) with moderate heterogeneity ($I = 56.9$), and pooled rates were 4.2% for cholangitis, 4.1% for bleeding, 3.7% for bile leakage, and 2.9% for perforation. On subgroup analysis, the pooled rate of adverse events with the use of lumen-apposing metal stents was 9.3% (95%CI, 4.8–17.3%). On the other hand, the rate of adverse events such as cholangitis, bleeding, and bile leakage was 13.4%.

2.2 EUS-guided HGS

2.2.1 Indications

EUS-HGS should be indicated for failed ERCP due to surgical anatomy or inaccessible ampulla of Vater, because adverse events such as stent migration can sometimes prove fatal. However, although EUS-CDS cannot be attempted in patients complicated with surgical anatomy, such as Roux-en-Y anastomosis or

malignant duodenal obstruction, EUS-HGS can be attempted because the access route of EUS-HGS is the stomach. Regarding biliary stricture sites, EUS-HGS may be challenging in case of hepatic hilum stricture because stent deployment is performed from the left intrahepatic bile duct. Therefore, the right hepatic bile duct cannot drain. As expanding indication, EUS-BD for right hepatic bile duct obstruction has been developed [12, 13]. Park et al. [12] reported that EUS-guided biliary access is successfully performed in antegrade bypass stenting (n = 2), antegrade transanastomotic stenting (n = 1), antegrade transanastomotic balloon dilation (n = 1), and the use of the cholangiogram as a roadmap (n = 1) among six patients with isolated right hepatic bile duct obstruction. We also conducted that EUS-BD was successfully performed using bridging method (n = 7) and locking stent method (n = 4) among 11 patients with right hepatic bile duct obstruction [13]. No severe adverse events were identified in either study. EUS-HGS has potential as indication for hepatic hilar stricture. However, because it is technically challenging, the right hepatic approach under EUS guidance should be performed for selected patients. Recently, Khashab et al. [14] reported a comparative evaluation of PTCD and EUS-BD in patients who were complicated with distal malignant biliary obstruction. According to this study, although the technical success rate was higher in the PTCD than in EUS-BD (100% vs. 86.4%, $P = 0.007$), clinical success and stent patency were not different. Rates of adverse event (70.6% vs. 18.2%, $P < 0.001$) and total charges were significantly higher in the PTCD ($\$9.072 \pm 3.817$ vs. $\$18.261 \pm 16.021$, $P = 0.003$). Therefore, their conclusion is that EUS-BD might be preferred if EUS-BD can be performed by experienced endoscopists. However, there are several limitations such as small number of patients, a single-center study, and a single operator. Therefore, to determine whether EUS-HGS or PTCD should be performed in a multicenter, prospective randomized controlled study is needed. The current indications for EUS-HGS are the following: (1) failed ERCP, (2) inaccessibility of the Vater due to surgical anatomy or duodenal obstruction caused by the tumor, and (3) contraindications for PTCD due to massive ascites and risk of self-tube removal. Compared with PTCD, metallic stent placement can be used in EUS-HGS in primary session. Therefore, EUS-HGS may be indicated even if a small amount of ascites is present in the access route. However, if massive ascites is present, preventing the formation of fistula between the stomach and liver, EUS-HGS is not indicated. The contraindications for EUS-HGS are the following: (1) massive ascites between the stomach and liver and (2) unresectable gastric cancer.

2.2.2 *Technical tips*

The EUS device is introduced into the stomach. Then, using counterclockwise rotation, the left hepatic lobe can be identified. A 19-G FNA needle may be better than a 22-G. A stiffer guidewire is inserted into the biliary tract through the EUS-fine needle aspiration (FNA) needle because fistula dilation is an important point to insert the stent delivery system compared with EUS-CDS. If segment 2 (B2) is punctured, because devices can be passed across the mediastinum, when puncturing from the esophagus, severe adverse events such as mediastinitis or pneumomediastinum may occur. Therefore, segment 3 (B3) should be initially punctured. There are two important points regarding the intrahepatic bile duct puncture. The first point is the angle of the bile duct, and the second point is the volume of the liver parenchyma. The bile duct that runs from the upper left to the lower right based on EUS imaging should be punctured to advance the guidewire toward the hepatic hilum. Furthermore, avoiding stent migration into the abdominal cavity requires a sufficient volume of liver parenchyma to obtain anchoring function, like PTCD procedure. Therefore, B3 is better as puncturing site. The next

step is guidewire insertion. During EUS-HGS, one of the most important procedures is the guidewire insertion. If the guidewire is introduced into the peripheral biliary tract, the next step may not be attempted. The biliary tract running from the upper left to the lower right on EUS imaging should be punctured to successfully advance the guidewire toward the hepatic hilum, as described in the above section. If the guidewire is advanced into the periphery of the biliary tract, the guidewire should be pulled, and then advance of the guidewire into the hepatic hilum should be attempted. However, during this procedure, the guidewire is sometimes kinked with the FNA needle. To avoid this adverse event, the liver impaction method appears clinically impactful [15]. Various types of guidewire are available. A 0.025-inch guidewire with a highly flexible tip, sufficient stiffness, and easy seeking ability is preferable for EUS-guided procedures. After the guidewire is inserted along with other devices, continued visualization of the other devices on EUS imaging is important during various EUS-guided procedures to fit the alignment. To perform stent deployment, the bile duct and stomach wall must be dilated. Various techniques for dilating a fistula have been reported to date [16–20]. A graded dilation technique using a dilator or a 4-mm balloon catheter is used by many authors according to previous studies. The mechanical dilator (6 to 10 Fr), balloon catheter (4–8 mm), and needle knife are mainly selected by many authors. Park et al. [16] described that, among the total of 57 patients who underwent EUS-BD, post-procedural adverse events such as bile peritonitis (n = 2), mild bleeding (n = 2), and self-limited pneumoperitoneum (n = 7) were observed. According to multivariate analysis, the use of a needle knife was the only risk factor for post-procedure adverse events of EUS-BD (P = 0.01, HR 12.4, 95%CI, 1.83–83.5). Therefore, their conclusion is that a needle knife should not be selected as a dilation device. To avoid this risk, an electrocautery dilator, which was coaxial with the guidewire, has been developed. Although this device is clinically useful as a dilation device, this device has disadvantages such as burning effect. When the bile duct is punctured while avoiding small vessels using color Doppler, bleeding can occur due to the burning effect of the electrocautery dilator. To reduce burning effects, a novel electrocautery dilator has become available in Japan (Fine 025; Medico's Hirata Inc., Japan, Osaka) [17]. Further study is needed to evaluate this device. On the other hand, a graded dilation technique using a balloon or mechanical dilator may be safe because burning effect does not occur. Park et al. [18] reported that graded dilation using a 4-Fr catheter and 6- or 7-Fr bougie dilator device is safe. In this study, technical success rate of EUS-CDS was high, with a low rate of adverse events. According to our previous report [19], we reported successful EUS-HGS using an ERCP catheter and a 4-mm balloon catheter without using electrocautery devices. This technique may be associated with a lower frequency of bleeding caused by the burning, although bile leakage might easily occur during graded dilation because procedure time is longer. Recently, novel techniques and dilation devices for EUS-BD have been reported. Paik et al. [20] reported a simplified fistula dilation technique. After the biliary tract was punctured using a 19-G FNA needle, direct insertion using a 4-mm balloon catheter was performed. In 28 patients, the technical success rate was 96% (27/28). In addition, early adverse events were not seen in any patients. We also described a simplified fistula dilation technique using a fine-gauge balloon catheter [21, 22]. As an even more novel technique, a one-step stent placement technique has been described [23]. According to this study, 32 patients, who were complicated with malignant biliary stricture, were enrolled. EUS-BD was performed using a novel metallic stent. The introducer for this novel stent has only a 3-Fr-tip-4-Fr tapered. The technical success rate of one-step stent deployment was 88% (14/16). In addition, the procedure time was short in the one-step stent placement group. The risk of bile

leakage may be increased, if procedure time is longer. In fact, in their reports, although significant differences were not seen, early adverse events were uncommon in the one-step dilation group compared with the graded dilation group (31.3% vs. 6.3%, $P = 0.172$). Although randomized, clinical trials and additional cases are needed to clarify which dilation technique or devices are more suitable in EUS-HGS, these techniques have potentials of decreasing the frequency of adverse events such as bile leakage. The final step is stent deployment. A fully covered self-expanding metal stent (FCSEMS) with strong radial force may be suitable for EUS-HGS compared with a plastic stent for the following reasons: (1) if a large fistula is created before inserting the stent delivery system, bile leakage from the gap between the stent and fistula is less likely; (2) longer stent patency may be obtained due to large diameter compared with plastic stent; and (3) a tamponade effect of stent expansion may occur if bleeding from the stomach wall is present. However, the following disadvantages are seen for FCSEMS: (1) the stent is expensive; (2) stent shortening must be considered during stent deployment, especially in the luminal portion to prevent stent migration into the abdominal cavity; and (3) side branches may be obstructed by covered site of the metal stent [24]. A novel metallic stent and several efforts to prevent stent migration have been recently reported. Some authors have described that a double-pigtail plastic stent can be placed inside the metal stent, when standard metallic stents are used. Prevention of stent dislocation requires sufficient stent length. We have also described that EUS-HGS can be safely performed using a partially covered metallic stent with long length [25]. More recently, Song et al. [26] described a preliminary study on a newly hybrid metal stent in EUS-BD procedure. The distal portion of this stent, which is 3.5-mm long, comprises silicone-covered nitinol wire to prevent bile leakage through the mesh. Also, anti-migration flaps are present proximal and distal to the covered site to prevent stent migration into the abdominal cavity. This novel stent, on the proximal site, has the uncovered site. This uncovered site is 1.5- to 5.5-mm long. This fact can prevent bile duct branch obstruction. In their study using this novel hybrid stent, EUS-HGS was successfully attempted for all 10 patients. In addition, no bile leakage or stent migration was seen in any patients. On the other hand, EUS-HGS using a newly designed plastic stent has been described by Umeda and Itoi et al. [27] that report using an 8-Fr single-pigtail plastic stent, which is a push-type stent that is usually not possible to retract (total length, 20 cm; effective length, 15 cm; four flanges). Also, the proximal end has a pigtail structure, and the distal end is strongly tapered. EUS-HGS using this plastic stent was successfully attempted in all 23 patients. Although bleeding or abdominal pain was seen in four patients (17.4%), no severe adverse events such as stent migration into the abdominal cavity or stent dislocation were observed during follow-up (median 5.0 months). Median stent patency was 4.0 months, and therefore, this result was clinically encouraging. However, as the author described in this report, additional long-term studies with a larger number of cases are needed to clarify the clinical benefit of using this stent for EUS-HGS. To prevent stent migration, technical tips for stent deployment are also extremely important. One of the consensus techniques in Japan is the intra-scope channel release technique [28]. The following steps were followed for stent release under the intra-scope channel technique. The stent delivery system was inserted into the confluence of B2 and B3. Next, stent release was performed from the intrahepatic bile duct to the hepatic parenchyma. Thereafter, the EUS scope was stabilized until the stent was deployed up to 1 cm within the EUS scope. The EUS scope was then withdrawn slightly while simultaneously pushing the stent delivery system. In that procedure, stent release was performed completely under endoscopic guidance (Figures 4–6).

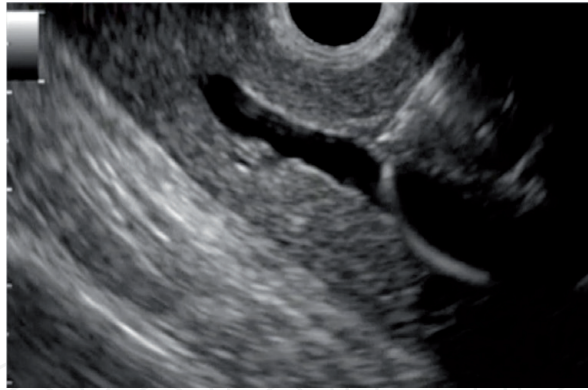


Figure 4.
The intrahepatic bile duct is punctured using 19-G needle from the stomach.

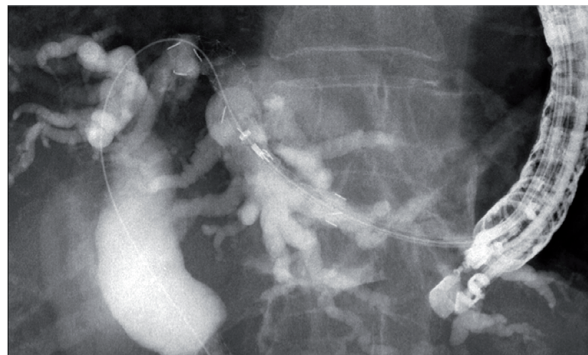


Figure 5.
The covered metal stent deployment is performed from the intrahepatic bile duct to the stomach.

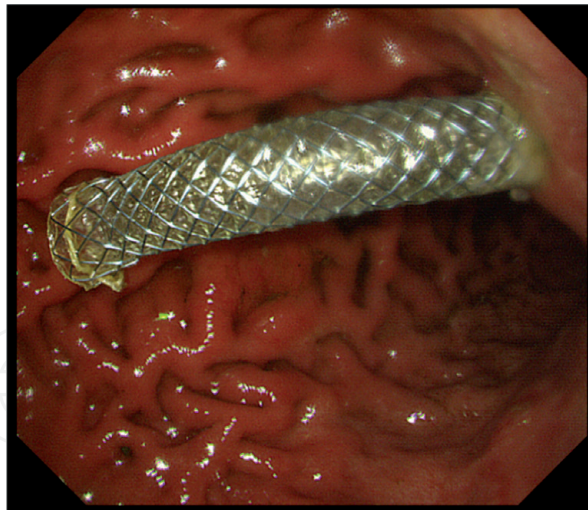


Figure 6.
The metal stent is placed in the stomach.

2.2.3 Clinical results

According to a recent meta-analysis of 686 patients [29], overall clinical success and technical success rates were, respectively, 84% (95%CI 80–88%) and 96% (95%CI, 93–98%) for EUS-HGS. On the other hand, in terms of technical results for EUS-HGS conducted by non-expert hands, the technical success rate was only 64.7% (22/34) [30]. This technique should therefore be performed in expert-assisted situations, and improvement of devices is warranted. The rate of adverse events including bile leakage, stent migration, bleeding, and peritonitis was relatively high (29%).

2.3 EUS-guided gallbladder drainage (GBD)

2.3.1 Indications

Compared with percutaneous transhepatic gallbladder drainage (PTGBD), one of the advantages of EUS-GBD is internal drainage. In addition, the procedure is technically simple compared with endoscopic retrograde gallbladder drainage (ETGBD). However, the results of long-term follow-up remain unclear, and there is still insufficient evidence on the performance of EUS-GBD as the first-line drainage technique. Current indications for EUS-GBD are thus as follows: (1) nonsurgical candidates with/without stone extraction, (2) as a bridge to surgical cholecystectomy, (3) conversion from PTGBD to EUS-GBD, (4) alternative to failed PTGBD/ETGBD, and (5) alternative to failed EUS-guided biliary drainage such as EUS-CDS or HGS [31].

2.3.2 Technical tips

The EUS probe is advanced into the stomach or duodenum to identify the gallbladder. The gallbladder neck is normally detected from the duodenal bulb, and the body or tail of the gallbladder is also detected via the stomach. No evidence of clinical differences between the use of these two sites has been found in previous reports. Tyberg et al. conducted a clinical study of differences between transgastric and transduodenal approaches regarding EUS-GBD [32]. In this study including a total of 42 patients, technical success was achieved in 92.6% (25/27) in transgastric approach group and in 100% in the transduodenal approach group. Adverse events were observed in four patients in the transgastric approach group (14.8%) and in five patients in the transduodenal approach group (33%). Therefore, they concluded that stent location was not a significant predictor of clinical failure ($P = 0.432$) or adverse events ($P = 0.289$). Also, Teoh et al. performed a comparative analysis of EUS-GBD from the antrum route or duodenum route [31]. Among a total of 59 patients, technical and clinical success rates were 94.4% (34/36) and 91.2% (31/34), respectively, among patients who underwent EUS-GBD from the antrum and 100% (23/23) and 95.7% (22/23) among patients who underwent EUS-GBD from the duodenum ($P = 0.52$ and 0.39). Overall adverse events also showed no significant difference between the two groups ($P = 0.64$). Endoscopists are thus free to select the site preferred for puncture. However, the duodenum may have less mobility compared with the stomach. This may result in less technically challenging and lower risks of both early and late stent migration with the transduodenal route. In addition, the frequency of food reflux into the gallbladder through the EUS-GBD stent may be lower when puncture is attempted via the duodenum compared with the stomach [33, 34]. On the other hand, EUS-GBD from the stomach may have several benefits. First, because the lumen is normally larger in the gallbladder body than in the gallbladder neck, puncturing the gallbladder through the stomach may be easy. In particular, the gallbladder body allows a greater lumen area to accommodate the internal flanges of the LAMS. Second, if serious complications such as perforation or stent migration occur, the consequences may be less serious because subsequent surgery is easier in patients who have undergone EUS-GBD from the stomach compared with from the duodenum. Endoscopists should thus be mindful of the characteristics of each site before performing EUS-GBD (**Figures 7 and 8**).

The next step is fistula dilation. According to previous reports [33, 35–42], a 6- or 7-Fr bougie, tapered catheter, and 4-mm balloon were the most commonly used devices for dilatation prior to insertion of drainage devices. If some resistance to passage of the stent delivery system is present, electrocautery dilation may be useful

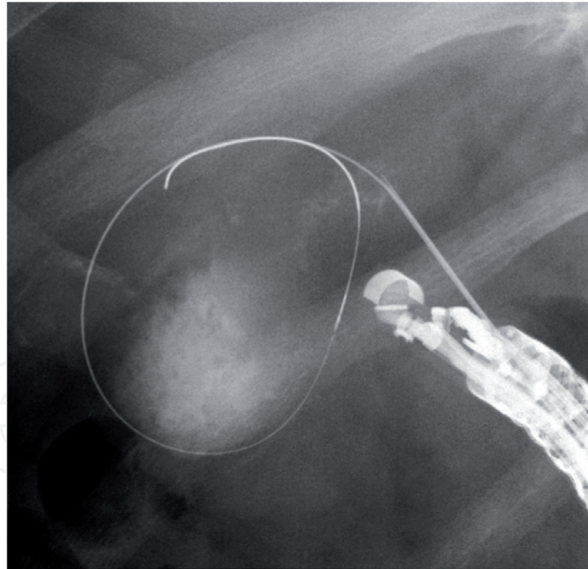


Figure 7.
The gallbladder is punctured using 19-G needle from the duodenum.

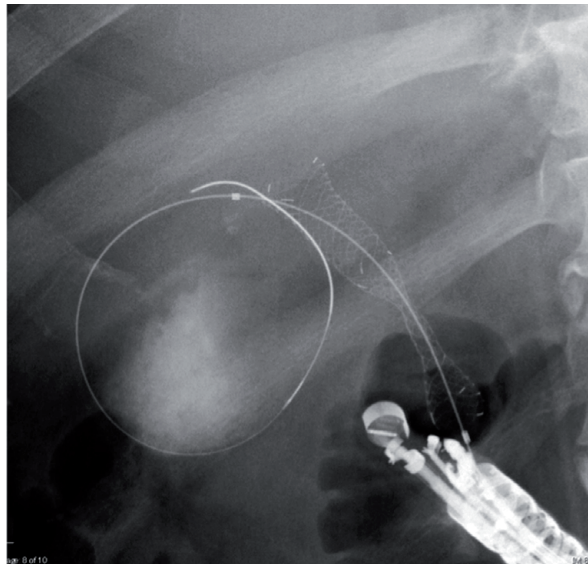


Figure 8.
The covered metal stent deployment is performed from the gallbladder to the duodenum.

according to previous reports. Bile leakage may occur as with other EUS-BD procedures, after this step and prior to stent deployment. In fact, the risk of bile leakage is frequently observed compared with EUS-HGS, because of the lack of a tamponade effect from the liver. As a result, dilation with one-step process may be preferred. Electrocautery dilation can certainly be performed regarding dilation of the fistula; however, it carries a risk of burns, which can in turn lead to bleeding. A dilation technique using a fine-gauge balloon catheter may be suitable from the perspective of preventing adverse events. However, since no evidence suggests which dilation devices should be used, a randomized controlled study among various dilation devices should be attempted.

Recently, the hot AXIOS stent with electrocautery-enhanced delivery system (Boston Scientific, Marlborough, MA, USA) has been developed. This stent is a through-the-scope LAMS mounted on a stent delivery system with an electrocautery wire at the distal tip. The electrocautery tip allows passage of the catheter into the gallbladder without the need for prior dilation of the tract by application of a pure cutting current. This fact may have clinical benefits, such as shortening of

the procedure time, reduced bile leakage during fistula dilation, and an improved technical success rate due to the single-step nature of the procedure. However, a previous retrospective study [31] showed no significant differences in technical success rates between hot and cold AXIOS [100% (10/10) vs. 95.9% (47/49), respectively; $P = 1.00$]. In addition, rates of adverse events were not significantly different [20% (2/10) vs. 34.7% (17/49), respectively; $P = 0.48$]. Since electrocautery dilation procedures may carry a risk of bleeding due to the potential for burns, a randomized controlled trial is needed to determine the superiority of hot AXIOS.

The next step is stent deployment. EUS-GBD has been performed using plastic stents. However, because stent deployment in EUS-GBD is performed from the gallbladder to the stomach or duodenum through the abdominal cavity, no tamponade effect arises such as due to the hepatic parenchyma, as seen with EUS-HGS. Bile leakage can therefore occur due to the gap between the fistula and plastic stent. In addition, stent patency is shorter compared with the covered SEMS (cSEMS). Jang et al. reported a comparative trial between EUS-GBD and PTGBD for acute cholecystitis [38]. In a study including 29 patients, who underwent EUS-GBD, laparoscopic cholecystectomy was performed in 23 patients (79.3%). None of the patients initially underwent open cholecystectomy, although 2 of the 23 patients (8.7%) in the EUS-GBD group and 3 of 26 patients (11.5%) in the PTGBD group required conversion to open cholecystectomy ($P = 0.99$). They also described that EUS-GBD did not cause severe inflammation or adhesions to the tissues surrounding the gallbladder and laparoscopic cholecystectomy could be safely attempted following EUS-GBD using plastic stents or endoscopic naso-gallbladder drainage (ENGBD) without an increase in technical difficulty as compared with PTGBD. Therefore, the use of a plastic stent should first be considered, if the patient is likely to undergo cholecystectomy in the future. Recently, cSEMS has been used as the drainage device for EUS-GBD instead of plastic stents in patients who are not good candidates for surgery due to other severe organ failure or the presence of advanced malignancy. The cSEMS is useful as compared with plastic stents, since self-expanding stents prevent bile leakage and are associated with longer stent patency. However, because of weak flanges, the standard tubular cSEMS has a risk of stent migration after stent deployment. As a method to prevent stent migration, several authors have described combination usage of a double-pigtail plastic stent or ENGBD and cSEMS [33, 39, 40, 42]. Indeed, stent migration has not been observed in EUS-GBD cases using this technique. And if the cSEMS migrates, the pigtail plastic stent remains in place from the gallbladder to the gastrointestinal lumen. This maintains fistula patency, allowing re-intervention.

Khan et al. undertook a systematic review of endoscopic gallbladder drainage [43]. In this review, subgroup analysis was attempted regarding the kinds of stent in the EUS-GBD. According to their results, EUS-GBD using SEMS is less likely to cause adverse events than EUS-GBD using a plastic stent or ENGBD. Therefore, if the patient is unlikely to undergo future cholecystectomy, EUS-GBD using SEMS might be preferable to prevent adverse events.

LAMS deployment has been reported in EUS-guided transluminal interventions, including EUS-guided pancreatic fluid collection [44], EUS-guided bile duct drainage [45], and EUS-guided gastroenterostomy [46]. LAMS has several benefits compared with SEMS. LAMS has a larger inner diameter, allowing better drainage. Also, the unique design such as the form of anchoring flanges may play an important role in preventing stent migration into both abdominal and luminal portions. Finally, a standard endoscope can be passed into the gallbladder lumen through the LAMS after LAMS deployment. In cases requiring EUS-guided intervention for walled-off necrosis [47], the use of SEMS or LAMS is superior to plastic stents in terms of overall treatment efficacy. The number of procedures required was

significantly lower with LAMS compared with SEMS or plastic stent placement. However, since high-quality evidence is lacking regarding the use of LAMS in EUS-GBD procedures, comparative studies between LAMS and other drainage devices for EUS-GBD are needed.

Finally, this chapter referred to our previous papers [48–50].

3. Conclusions

EUS-guided biliary drainage has clinical impact as alternative drainage technique. If more evidences are available, indications of this technique will be spread.

Conflict of interest

The authors declare no conflict of interest.

Author details

Takeshi Ogura* and Kazuhide Higuchi
2nd Department of Internal Medicine, Osaka Medical College, Osaka, Japan

*Address all correspondence to: oguratakeshi0411@yahoo.co.jp

IntechOpen

© 2019 The Author(s). Licensee IntechOpen. This chapter is distributed under the terms of the Creative Commons Attribution License (<http://creativecommons.org/licenses/by/3.0>), which permits unrestricted use, distribution, and reproduction in any medium, provided the original work is properly cited. 

References

- [1] Rai P, Lokesh CR, Goel A, et al. Endoscopic ultrasound-guided choledochoduodenostomy using partially-covered self-expandable metal stent in patients with malignant distal biliary obstruction and unsuccessful ERCP. *Endoscopy International Open*. 2018;**6**:E67-E72
- [2] Hara K, Yamao K, Niwa Y, et al. Prospective clinical study of EUS-guided choledochoduodenostomy for malignant lower biliary obstruction. *The American Journal of Gastroenterology*. 2011;**106**:1239-1245
- [3] Park JK, Woo YS, Noh DH, et al. Efficacy of EUS-guided and ERCP-guided biliary drainage for malignant biliary obstruction: Prospective randomized controlled study. *Gastrointestinal Endoscopy*. 2018;**88**:277-282
- [4] Bang JY, Navaneethan U, Hasan M, et al. Stent placement by EUS or ERCP for primary biliary decompression in pancreatic cancer: A randomized trial (with videos). *Gastrointestinal Endoscopy*. 2018;**88**:9-17
- [5] Ogura T, Masuda D, Takeuchi T, et al. Intraluminal water filling technique to prevent double mucosal puncture during EUS-guided choledochoduodenostomy. *Gastrointestinal Endoscopy*. 2016;**83**:834-845
- [6] Kawakami H, Kuwatani M, Sakamoto N. Double penetrated double wall during endoscopic ultrasound-guided choledochoduodenostomy. *Gut and Liver*. 2016;**10**:318-319
- [7] Park DH, Jang JW, Lee SS, et al. EUS-guided biliary drainage with transluminal stenting after failed ERCP: Predictors of adverse events and long-term results. *Gastrointestinal Endoscopy*. 2011;**74**:1276-1284
- [8] Itoi T, Binmoeller KF, Shah J, et al. Clinical evaluation of a novel lumen-apposing metal stent for endosonography-guided pancreatic pseudocyst and gallbladder drainage (with videos). *Gastrointestinal Endoscopy*. 2012;**75**:870-876
- [9] Fabbri C, Fugazza A, Binda C, et al. Beyond palliation: Using EUS-guided choledochoduodenostomy with a lumen-apposing metal stent as a bridge to surgery. A case series. *Journal of Gastrointestinal and Liver Diseases*. 2019;**28**:125-128
- [10] Anderloni A, Fugazza A, Troncone E, et al. Single-step EUS-guided choledochoduodenostomy using a lumen-apposing metal stent for malignant biliary obstruction. *Gastrointestinal Endoscopy*. 2019;**89**:69-76
- [11] Mohan BP, Shakhathreh M, Garg R, et al. Efficacy and safety of endoscopic ultrasound-guided choledochoduodenostomy: A systematic review and meta-analysis. *Journal of Clinical Gastroenterology*. 2019;**53**:243-2250
- [12] Park SJ, Choi JH, Park do H, et al. Expanding indication: EUS-guided hepaticoduodenostomy for isolated right intrahepatic bile duct obstruction (with video). *Gastrointestinal Endoscopy*. 2013;**78**:374-380
- [13] Ogura T, Sno T, Onda S, et al. Endoscopic ultrasound-guided biliary drainage for right intrahepatic bile duct obstruction (with video). *Endoscopy*. 2015;**47**:72-75
- [14] Khashab MA, Valeshabad AK, Kalloo AN, et al. A comparative evaluation of EUS-guided biliary drainage and percutaneous drainage in patients with distal malignant biliary obstruction and failed ERCP. *Digestive Diseases and Sciences*. 2015;**60**:557-565

- [15] Ogura T, Masuda D, Takeuchi T, et al. Liver impaction technique to prevent sharing of the guidewire during endoscopic ultrasound-guided hepaticogastrostomy. *Endoscopy*. 2015;**47**:E583-E584
- [16] Park do H, Jang JW, Lee SS, et al. EUS-guided biliary drainage with transluminal stenting after failed ERCP: Predictors of adverse events and long-term results. *Gastrointestinal Endoscopy*. 2011;**74**:1276-1284
- [17] Ogura T, Nakai Y, Itoi T. Novel fine gauge electrocautery dilator for endoscopic ultrasound-guided hepaticogastrostomy (with video). *Journal of Hepato-Biliary-Pancreatic Sciences*. 2019;**26**:E3-E4
- [18] Park do H, Jeong SU, Lee BU, et al. Prospective evaluation of a treatment algorithm with enhanced guidewire manipulation protocol for EUS-guided biliary drainage after failed ERCP (with video). *Gastrointestinal Endoscopy*. 2013;**78**:91-101
- [19] Ogura T, Kurisu Y, Masuda D, et al. Novel method of endoscopic ultrasound-guided hepaticogastrostomy to prevent stent dysfunction. *Journal of Gastroenterology and Hepatology*. 2014;**29**:1815-1821
- [20] Paik WH, Park Do H, Choi JH, et al. Simplified fistula dilation technique and modified stent deployment maneuver for EUS-guided hepaticogastrostomy. *World Journal of Gastroenterology*. 2014;**20**:5051-5059
- [21] Ogura T, Takagi W, Onda S, Masuda D, Takeuchi T, Fukunishi S, et al. Endoscopic ultrasound-guided biliary drainage with a novel fine-gauge balloon catheter: Simplified technique using a coaxial guidewire. *Endoscopy*. 2015;**47**:573-574
- [22] Ogura T, Sano S, Onda S, Masuda D, Imoto A, Higuchi K. Endoscopic ultrasound-guided biliary drainage with a novel fine-gauge balloon catheter: One-step placement technique. *Endoscopy*. 2015;**47**:245-246
- [23] Park do H, Lee TH, Paik WH, et al. Feasibility and safety of a novel dedicated device for one-step EUS-guided biliary drainage: A randomized trial. *Journal of Gastroenterology and Hepatology*. 2015;**30**:1461-1466
- [24] Itoi T, Isayama H, Sofuni A, et al. Stent selection and tips on placement technique of EUS-guided biliary drainage: Transduodenal and transgastric stenting. *Journal of Hepato-Biliary-Pancreatic Sciences*. 2011;**18**:664-672
- [25] Ogura T, Yamamoto K, Sano T, et al. Stent length is impact factor associated with stent patency in endoscopic ultrasound-guided hepaticogastrostomy. *Journal of Gastroenterology and Hepatology*. 2015;**30**:1748-1752
- [26] Song TJ, Lee SS, Park do H, Seo DW, Lee SK, Kin MH. Preliminary report on a new hybrid metal stent for EUS-guided biliary drainage (with videos). *Gastrointestinal Endoscopy*. 2014;**80**:707-711
- [27] Umeda J, Itoi T, Tsuchiya T, et al. A newly designed plastic stent for EUS-guided hepaticogastrostomy: A prospective preliminary feasibility study (with videos). *Gastrointestinal Endoscopy*. 2015;**82**:390-396.e2
- [28] Miyano A, Ogura T, Yamamoto K, et al. Clinical impact of the intra-scope channel stent release technique in preventing stent migration during EUS-guided hepaticogastrostomy. *Journal of Gastrointestinal Surgery*. 2018;**22**:1312-1318
- [29] Hedjoudje A, Sportes A, Grabar S, et al. Outcomes of endoscopic ultrasound-guided biliary drainage: A

systematic review and meta-analysis. *United European Gastroenterology Journal*. 2019;7:60-68

[30] Vila JJ, Perez-Miranda M, Vazquez-Sequerios E, et al. Initial experience with EUS-guided cholangiopancreatography for biliary and pancreatic duct drainage: A Spanish national survey. *Gastrointestinal Endoscopy*. 2012;76:1133-1141

[31] Teoh AYB, Sema C, Penas I, et al. Endoscopic ultrasound-guided gallbladder drainage reduces adverse events compared with percutaneous cholecystectomy in patients who are unfit for cholecystectomy. *Endoscopy*. 2017;49:130-138

[32] Tyberg A, Saumoy M, Sequeiros EV, et al. EUS-guided versus percutaneous gallbladder drainage: Isn't time to covert? *Journal of Clinical Gastroenterology*. 2018;52:79-84

[33] Takagi W, Ogura T, Sano T, et al. EUS-guided cholecystoduodenostomy for acute cholecystitis with an anti-stent migration and anti-food impaction system; a pilot study. *Therapeutic Advances in Gastroenterology*. 2016;9:19-25

[34] Perez-Miranda M. Technical considerations in EUS-guided gallbladder drainage. *Endoscopic Ultrasound*. 2018;7:79-82

[35] Lee SS, Park DH, Hwang CY, et al. EUS-guided transluminal cholecystectomy as rescue management for acute cholecystitis in elderly or high-risk patients: A prospective feasibility study. *Gastrointestinal Endoscopy*. 2007;66:1008-1012

[36] Song TJ, Park DH, Eum JB, et al. EUS-guided cholecystoenterostomy with single-step placement of a 7Fr double-pigtail plastic stent in patients who are unsuitable for cholecystectomy: A pilot study (with

video). *Gastrointestinal Endoscopy*. 2010;71:634-640

[37] Jang JW, Lee SS, Park DH, et al. Feasibility and safety of EUS-guided transgastric/transduodenal gallbladder drainage with single-step placement of a modified covered self-expandable metal stent in patients unsuitable for cholecystectomy. *Gastrointestinal Endoscopy*. 2011;74:176-181

[38] Jang JW, Lee SS, Song TJ, et al. Endoscopic ultrasound-guided transmural and percutaneous transhepatic gallbladder drainage are comparable for acute cholecystitis. *Gastroenterology*. 2012;142:805-811

[39] Choi JH, Lee SS, Choi JH, et al. Long-term outcomes after endoscopic ultrasonography-guided gallbladder drainage for acute cholecystitis. *Endoscopy*. 2014;46:656-661

[40] Keida P, Sharaiha RZ, Kumta NA, et al. Endoscopic gallbladder drainage compared with percutaneous drainage. *Gastrointestinal Endoscopy*. 2015;82:1031-1036

[41] Kamata K, Takenaka M, Kitano M, et al. Endoscopic ultrasound-guided gallbladder drainage for acute cholecystitis: Long-term outcomes after removal of a self-expandable metal stent. *World Journal of Gastroenterology*. 2017;23:661-667

[42] Kahaleh M, Perez-Miranda M, Artifon EL, et al. International collaborative study on EUS-guided gallbladder drainage: Are we ready for prime time? *Digestive and Liver Disease*. 2016;48:1054-1059

[43] Khan MA, Atiq O, Kubiliam N, et al. Efficacy and safety of endoscopic gallbladder drainage in acute cholecystitis: Is it better than percutaneous gallbladder drainage? *Gastrointestinal Endoscopy*. 2017;85:76-87

[44] Chen YI, Barkun AN, Adam V, et al. Cost-effectiveness analysis comparing lumen-apposing metal stents with plastic stents in the management of pancreatic walled-off necrosis. *Gastrointestinal Endoscopy*. 2018;**88**:267-276

[45] Kunda R, Perez-Miranda M, Will U, et al. EUS-guided choledochoduodenostomy for malignant distal biliary obstruction using a lumen-apposing fully covered metal stent after failed ERCP. *Surgical Endoscopy*. 2016;**30**:5002-5008

[46] Itoi T, Baron TH, Khashab MA, et al. Technical review of endoscopic ultrasonography-guided gastroenterostomy in 2017. *Digestive Endoscopy*. 2017;**29**:495-502

[47] Siddiqui AA, Kowalski TE, Loren DE, et al. Fully covered self-expandable metal stents versus lumen-apposing fully covered self-expandable metal stent versus plastic stents for endoscopic drainage of pancreatic walled-off necrosis: Clinical outcomes and success. *Gastrointestinal Endoscopy*. 2017;**85**:758-765

[48] Ogura T, Higuchi K. Technical tips for endoscopic ultrasound-guided hepaticogastrostomy. *World Journal of Gastroenterology*. 2016;**22**:3945-3951

[49] Ogura T, Higuchi K. Technical tips of endoscopic ultrasound-guided choledochoduodenostomy. *World Journal of Gastroenterology*. 2015;**21**:820-828

[50] Ogura T, Higuchi K. Endoscopic ultrasound-guided gallbladder drainage: Current status and future prospects. *Digestive Endoscopy*. 2019;**31**(Suppl 1): 55-64