

We are IntechOpen, the world's leading publisher of Open Access books Built by scientists, for scientists

4,800

Open access books available

122,000

International authors and editors

135M

Downloads

Our authors are among the

154

Countries delivered to

TOP 1%

most cited scientists

12.2%

Contributors from top 500 universities



WEB OF SCIENCE™

Selection of our books indexed in the Book Citation Index
in Web of Science™ Core Collection (BKCI)

Interested in publishing with us?
Contact book.department@intechopen.com

Numbers displayed above are based on latest data collected.

For more information visit www.intechopen.com



Utility of ERCP in the Diagnosis and Management of Biliary Complications of Hepatic Hydatid Disease

Pedro Pinto, Sergio Gaete and Patricia Vega

Abstract

To report the experience with endoscopic retrograde cholangiopancreatography (ERCP) in the pre- and postoperative management of complicated liver hydatidosis. Case series retrospective of 14 patients who underwent ERCP in the Department of Surgery and Endoscopy Regional Hospital of Coyhaique, from January 2005 to December 2014. In this report, patients are separated into two groups: those in whom ERCP was used as diagnosis and those in which it was used for handling the external biliary fistula. Five patients consulting for jaundice and pain were subjected to ERCP in the preoperative period. Hydatid membranes were found and extracted in all. A sphincterotomy was performed in all, and an endoprosthesis was placed in one. Four patients were operated posteriorly, and only one did not require surgery. On nine patients with an external biliary fistula draining more than 200 ml/day, a postoperative ERCP was carried out. The surgical procedure was a partial cystectomy, and in four it was laparoscopic. The ERCP was carried out in the 20th postoperative day, performing a sphincterotomy and placing an endoprosthesis in all. Fistulae are closed at 28 days. Patients were followed up for 6 years and none died.

Keywords: hepatic hydatid cyst, complications, biliary fistula, endoscopic pancreatography

1. Introduction

The liver is compromised in 50–70% of patients with hydatid disease. The most frequent hepatic hydatid cyst (HCH) complication is intrabiliary rupture, which occurs in 5–25% of patients. This rupture can lead to the obstruction of the Bile duct cholangitis and sepsis which can reach 50% of mortality. Surgery has been the traditional treatment for these patients, which has been associated with a high morbidity ranging 21.3–53.8% according to several series [1], the external biliary fistula (EBF) being the most frequent complication with 4–28% of the total [2].

Since the first communication in 1987 about the endoscopic retrograde cholangiopancreatography (ERPC) utility in the study and treatment of patients with complicated hepatic hydatidosis (CHH) [3, 4], more than 1000 patients had undergone this procedure, with a complication rate of 7.9% and a mortality of 0.6% [5].

The ERPC is mainly used in the preoperative period to solve acute complications such as cholangitis and the obstruction of the bile duct cystic material and in the postoperative management of the EBF and benign strictures of the biliary duct [6].

The aim of this presentation is to report the surgery and endoscopy service experience in the use of ERPC, in both pre- and postoperative stages of CHH patients.

2. Material and method

Retrospective case series from 14 patients are submitted to ERPC in the Department of Surgery and Endoscopy Regional Hospital of Coyhaique, from January 2005 to December 2014. Such procedure was used in the pre- and postoperative handling of patients with CHH.

During this period, 218 CHH carrying patients were treated, and 9 (4.1%) of them presented EBF high drainage complications; therefore they will be the reason for this presentation. In turn, the endoscopy service realized 832 ERPC during the same period, and only 14 (1.7%) presented CHH as an indication.

In this presentation, patients are separated into two groups: those in whom ERCP was used as diagnosis (**Table 1**) and those in which it was used for managing the external biliary fistula (**Table 2**).

In a previous post [7], it is established that biliary fistula refers to a bile flow which extends for more than 10 days. The draining qualifies as low when the flow is less than 200 ml per day and high when it is greater than that quantity. The ERPC indication was an average biliary draining greater than 200 cc per day.

The ERPC was performed by the endoscopy unit team at the Imaging Service of the Coyhaique Regional Hospital. All patients underwent antibioprophyllaxis with 1 g of intravenous cefazolin, they were sedated with midazolam and fentanyl, and the peristalsis duodenal was suppressed with hyoscine butylbromide

Patient no.	Age	Sex	Clinic	Ultrasound	ERPC findings	ERPC technique	Monitoring
1	76	F	Jaundice	SVI-SVII, MV, 12 × 7 cm, communicated to BD	Cholangiohydatisidosis	Membrane extraction sphincterotomy	Operated the following month
2	55	M	Jaundice	SV-SVI, UV, 11 × 6 cm	Communication BD cyst	Sphincterotomy	Operated 2 months later
3	51	M	Jaundice	Caudate lobe, MV 48 × 37 × 47 mm	Cholangiohydatisidosis	Membrane extraction sphincterotomy	Not operated Medical examinations ok
4	35	M	Jaundice, pain	SII-SIII, MV, 13 cm	Cholangiohydatisidosis	Membrane extraction sphincterotomy endoprosthesis 7.5 F	Operated the following month
5	55	M	Jaundice, pain	RHL, 17 × 13 × 13 cm communicated to BD, hepatic hilum	Cholangiohydatisidosis communication right hepatic	Membrane extraction sphincterotomy	Operated 20 days later

Table 1.
Diagnosis.

Patient no.	Age	Sex	Hepatic hydatid cyst (intraoperative) location-size-characteristic	Surgical technique	Lapse ERPC/surgery days (bile flow)	ERPC technique	Monitoring
1	49	M	SIV: 6 x 5 cm, MV bilis 5 x 4 cm, MV	Indirect marsupialization	13 days (300 ml)	Endoprosthesis 7 F papillotomy	30/50
2	63	M	SVII-SVIII, 11 x 11 x 10 cm, MV bilis output can be seen	LC partial cystectomy	15 days (250 ml)	Endoprosthesis 7 F papillotomy (2 ERPC)	11/48
3	33	F	SII-III, 15 x 20 cm bilobulated	LC partial cystectomy LC	27 days (400 ml)	2 endoprosthesis 7 F	14/39
4	70	M	3: SV, 19 x 17cm, UV SVIII, 15 x 13 cm, MV bilis SII, 8 x 9 cm, MV bilis	Partial cystectomy capitonage partial resection	10 days (250 ml)	Endoprosthesis 8.5 F papillotomy	34/42
5	11	M	SVIII (2), 10 and 4 cm, MV	Partial cystectomy	25 days (800 ml)	Endoprosthesis 7 F papillotomy	9/126
6	45	M	SII-SIII, 15 x 13 cm, UV frank bilis	Partial cystectomy	11 days (1000 ml)	Endoprosthesis 7 F papillotomy	37/129
7	54	M	Between LHL and RHL, 12 x 10 x 11 cm, UV, frank bilis	LC	7 days (200 ml)	Endoprosthesis 7 F papillotomy	31/71
8	10	M	LHL, 10 x 12 cm, MV, ruptured peritoneum	Partial cystectomy	41 days (300 ml)	Endoprosthesis 7 F, 2 ERPC performed	57/120
9	13	M	RHL 17 x 9.5 x 11.8 cm, UV, bilis	Partial cystectomy	27 days (990 ml)	Endoprosthesis 8.5 F papillotomy	28/18

ERPC, endoscopic pancreatography; F, frank; F, female ("sex" column); RHL, right hepatic lobe; LHL, left hepatic lobe; M, male; MV, multivesicular; LC, laparoscopic cystectomy; S, segment; UV, univesicular.

Table 2.
 External biliary fistula management.

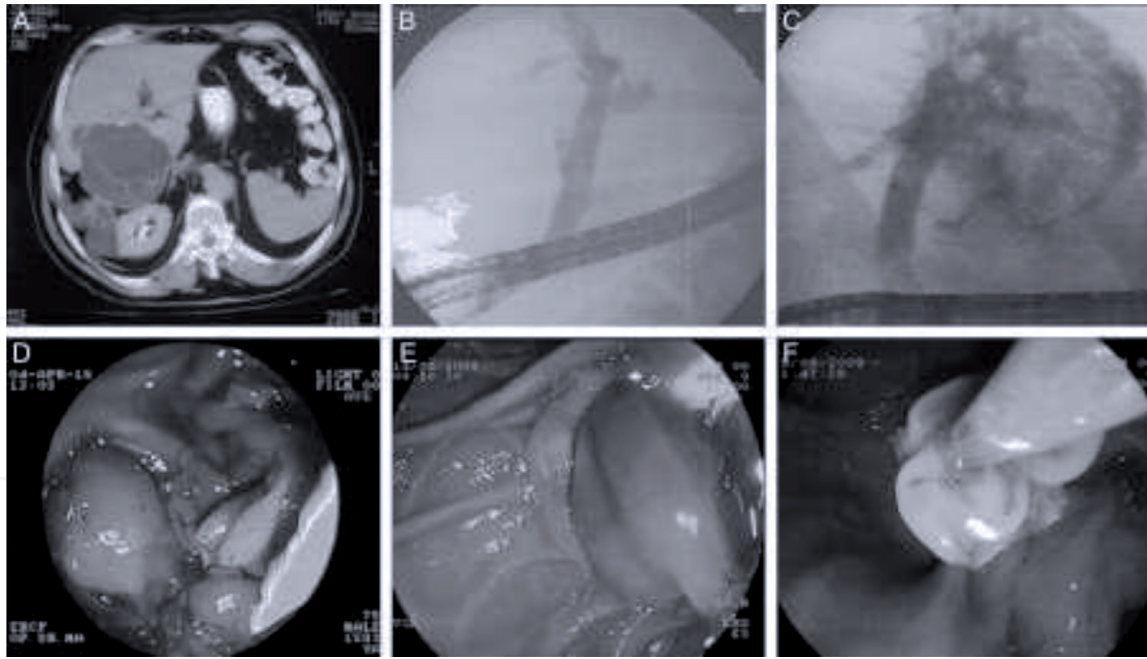


Figure 1.
 (A) HHC CAT image. (B) Hydatid material in the common biliary duct. (C) Extravasation of contrast media from the biliary ducts to the cystic cavity. (D) Hydatid material infected post-papillotomy draining. (E) Hydatid material extraction through an endoscopic balloon. (F) Way out of germinative from the choledochal.

of scopolamine. The procedure was performed with the patient in the left lateral decubitus position using the EXERA TJF-160VF OLYMPUS videodenoscope. The sphincterotomy was performed in the classic way with a TRI-20M papillotome (TR-TOME PC triple lumen COOK) guided with HYB-48015. After the sphincterotomy was done, a Dormia MSN COOK canister or a TXR COOK balloon was used to extract the daughter vesicles and to allow a fluid biliary drainage.

ERPC, endoscopic pancreatography; F, frank; F, female (“sex” column); RHL, right hepatic lobe; M, male; MV, multivesicular; S, segment; BD, biliary duct.

If stenting was required, an Oasis set of prosthesis introduction (OACL, 7.5–10 F) was used (**Figure 1**).

After discharge, patients were followed a month later, 3 and 6 months later, and then 1 year later.

3. Results

There were five patients submitted to ERPC in the preoperative period (**Table 1**). Male sex predominated and the average age was 54 ± 15 years old. The average cyst size was 12 ± 4.4 cm and all of them were multivesicular.

The main consultation motive was jaundice and pain, only one of them had as an antecedent having undergone a CHH surgery. In all of them, a passage of hydatid membranes to the main bile duct was found and endoscopically extracted. Sphincterotomy was performed in all, and only one case required an endoprosthesis installation which was subsequently removed (**Figure 1**).

Four patients were stabilized and operated according to schedule before a month, and only the one who had the minor-sized cyst ($48 \times 37 \times 47$ mm) located in the caudate lobe did not require surgery, and his examinations are normal until now.

Due to the EBF presence with sustained high output (>200 ml) bile flow, ERPC was performed in nine patients aiming to close it (**Table 2**). As in the preoperative

therapeutic use, male sex predominates, and the average age was 39 ± 22 years. The cyst size was 12 ± 5 cm, and two thirds of them were multivesicular.

The surgical technique employed in all was non-resective (partial cystectomy), and in four patients (4/9) it was performed through a videolaparoscopy. ERPC indication took place 20 days (7–41) after the intervention, and the average EBF output was 498 ml per day (200–1000). Sphincterotomy was performed in all with endoprosthesis installation, mostly 7F (7/9). The fistula closure happened on average at 28 ± 15 days. The prosthesis was extracted from five patients between week 6 and 8 after the EBF.

The patients' monitoring reached 71.4 ± 42 months (6 years), with a minimum of 18 and a maximum of 129 months (10.7 years).

4. Discussion

So far we have only found one work in literature published by national authors related to the utility of ERPC in CHH [8] and hence the interest in making it known.

The communication among CHH and the biliary tree is the most frequent and severe complication, and it explains 60% of the complications. When this communication is greater than 5 mm, it is called frank rupture, and in 65% of the cases, it is possible to see cystic content in the main biliary duct [9]. The classic treatment for these patients was surgery; however, since Al Karawi et al. in 1987 [3] reported the use of ERPC with sphincterotomy in the handling of daughter vesicles retained in the biliary duct, this procedure has been considered as a safe and effective choice.

ERPC is used in the preoperative period with the following objectives [10]:

- Surgery planning by defining the cystobiliar relationship.
- Resolution of acute conditions such as cholangitis and obstruction of the main bile duct, allowing elective surgery (cases 1, 2, 4, and 5).
- In 25% of cases, it allows for a permanent cure [3, 11], which is confirmed in our series (case 3).
- Complementing the procedure with sphincterotomy reduces the incidence of EBF.

In the postoperative period, its main indications are [10]:

- Solving the obstruction and the cholangitis caused by the presence of hydatid material in the bile ducts.
- Enabling the best handling of EBF (1–9 cases).
- Solving the secondary biliary stenosis to the CHH.

It is essential to bear in mind that the ERPC indication must be precocious, ideally within 10 days after the EBF has been established [12].

The main problem is in low output fistula. According to Zeybek et al. when the flow is 102 ml per day, this closes spontaneously [13], and the end of the flow occurs 34.7 days [7] later; therefore, there is a tendency to have an expectant behavior due to the inherent risks of the procedure.

The fistula high output case is different, in which aggressive behavior is required, since the stay of these patients is even longer (41.6 days) [7] and the risk

of complications increases. The average output in our patients reached 498 ml per day, and the ERPC indication was performed when the flow was persistently greater than 200 ml and the latency of the procedure reached 20 days, a situation that we have tried to correct in the last patients.

When reviewing the worldwide experience up to 2002 in the endoscopic management of CHH, the Turkish gastroenterologists Ersan Özaslan and Yusuf Bayraktar mention that optimal management of EBF remains unanswered. In their opinion of sphincterotomy, stent and nasobiliar drainage are not exclusive but complementary, and each should be used according to the individual characteristic of each patient [6].

The therapy performed in the service to patients with EBF consisted of a combination of sphincterotomy plus stent installation. In the first patients a 7 F was used to subsequently use a thicker 8.5 F. This was done to reduce the probability of being obstructed with the content of the residual cavity and having to change and reinstall it, as occurred in two patients.

All this was subsequently endorsed by the publication of Adas et al. [14], who in a retrospective multicenter study concluded that sphincterotomy is the treatment of choice in low debit EBFs, but in high debit EBFs (flow greater than 200 ml per day), the gold standard is the insertion of a 10 F stent whenever possible.

It is worth mentioning that the removal of the prosthesis should not be performed beyond 4–6 weeks after the cessation of EBF [12]. In our patients this was performed in 5 of 9, those in which choledocholithiasis was not favored, thus requiring a new ERCP (patient 7), in another there was persistence of infection of the residual cavity (patient 2), in a third the stent had to be removed due to persistent pain (patient 3), and in another there was migration of the prosthesis to the residual cavity (patient 9). Therefore, at this time, as a rule, the stent is removed no later than 4–6 weeks after the cessation of bile flow.

According to the different series, the objective of the cessation of EBF is achieved by 83.3–100%, and the closing time varies between 2 and 4 weeks [12]. When reviewing our series, the target was 100%, and the average closing time of the EBF was 28 days. This is far from the spontaneous evolution that reached 42 days in a previous publication [7].

It is worth mentioning that the monitoring of patients in this series of cases reached 100%, the average being 6 years. This occurs because the disease mainly affects patients who are beneficiaries of the public system, and since there is no private clinic in the region, in most cases they must be controlled in the regional hospital.

In this series of cases, there was no mortality.

5. Conclusions

This study confirms that ERPC is a useful and safe procedure in the diagnosis and treatment of bile complications of liver hydatidosis.

Conflict of interest

The authors declare no conflict of interest.

Notes/thanks/other declarations

None.

IntechOpen

IntechOpen

Author details

Pedro Pinto^{1*}, Sergio Gaete² and Patricia Vega²

1 Surgery Service, Coyhaique Regional Hospital, Coyhaique, Chile

2 Endoscopy Unit, Coyhaique Regional Hospital, Coyhaique, Chile

*Address all correspondence to: pedropablopatricio@gmail.com

IntechOpen

© 2019 The Author(s). Licensee IntechOpen. This chapter is distributed under the terms of the Creative Commons Attribution License (<http://creativecommons.org/licenses/by/3.0>), which permits unrestricted use, distribution, and reproduction in any medium, provided the original work is properly cited. 

References

- [1] Manterola C, Urrutia S. Morbilidad postoperatoria en pacientes con hidatidosis hepática complicada. *Revista Chilena de Infectología*. 2015;**32**(1):43-49
- [2] Singh V, Reddy DC, Verma GR, Singh G. Endoscopic management of intrabiliary-ruptured hepatic hydatid cyst. *Liver International*. 2006;**26**(5):621-624
- [3] Al Karawi MA, Mohamed AE, Yasawy I, Haleem A. Non-surgical endoscopic trans-papillary treatment of ruptured echinococcosis liver cyst obstructing the biliary tree. *Endoscopy*. 1987;**19**(2):81-83
- [4] Al Karawi MA, Yazawy MI, El Sheikh FS, Mohamed AR. Endoscopic management of biliary hydatid disease. Report on six cases. *Endoscopy*. 1991;**23**(5):278-281
- [5] Rabenstein T, Schneider HT, Hahn EG, Ell C. 25 years of endoscopic sphincterotomy in Erlangen: Assessment of the experience in 3.498 patients. *Endoscopy*. 1998;**30**(2):194-201
- [6] Ozaslan E, Bayraktar Y. Endoscopic therapy in the management of hepatobiliary hydatid disease. *Journal of Clinical Gastroenterology*. 2002;**35**(2):160-174
- [7] Pinto P, López R. Evolución natural de la fístula biliar externa post cirugía del quiste hidatídico hepático. *Revista Chilena de Cirugía*. 2010;**62**(5):476-479
- [8] De Aretxabala X, Pérez OL. The use of endoprótesis in biliary fistula of hydatid cyst. *Gastrointestinal Endoscopy*. 1999;**49**(6):797-799
- [9] Zaouche A, Haouet K, Jovini M, El Hachaichi A, Dziri C. Management of liver hydatid cyst with a large biliocystic fistula: Multicenter retrospective study. *World Journal of Surgery*. 2001;**25**(1):28-39
- [10] Ozaslan E. Therapeutic endoscopic retrograde cholangiopancreatography and related modalities have many roles in hepatobiliary hydatid disease. *World Journal of Gastroenterology*. 2006;**12**(30):4930-4931
- [11] Dolay K, Akbulut S. Role of endoscopic retrograde cholangiopancreatography in the management of hepatic hydatid disease. *World Journal of Gastroenterology*. 2014;**20**(41):15253-15261
- [12] Akcakaya A, Sahin M, Karakelleoglu A, Okan I. Endoscopic stenting for selected cases of biliary fistula after hepatic hydatid surgery. *Surgical Endoscopy*. 2006;**20**(9):1415-1418
- [13] Zeybek N, Dede H, Balci D, Coskun AK, Ozerhan IH, Peker S, et al. Biliary fistula after treatment for hydatid disease of the liver: When to intervene. *World Journal of Gastroenterology*. 2013;**19**(3):355-361
- [14] Adas G, Arikan S, Gurbuz E, Karahan S, Eryasar B, Karatepe O, et al. Comparison of endoscopic therapeutic modalities for postoperative biliary fistula of liver hydatid cyst: A retrospective multicentric study. *Surgical Laparoscopy, Endoscopy & Percutaneous Techniques*. 2010;**20**(49):223-227