

# We are IntechOpen, the world's leading publisher of Open Access books Built by scientists, for scientists

**4,800**

Open access books available

**122,000**

International authors and editors

**135M**

Downloads

Our authors are among the

**154**

Countries delivered to

**TOP 1%**

most cited scientists

**12.2%**

Contributors from top 500 universities



**WEB OF SCIENCE™**

Selection of our books indexed in the Book Citation Index  
in Web of Science™ Core Collection (BKCI)

Interested in publishing with us?  
Contact [book.department@intechopen.com](mailto:book.department@intechopen.com)

Numbers displayed above are based on latest data collected.

For more information visit [www.intechopen.com](http://www.intechopen.com)



# Acute Diarrhea as a Manifestation of Abdominal Epilepsy

*Tomohiko Murai and Masako Kinoshita*

## Abstract

Medical doctors are very frequently confronted with gastrointestinal complaints in daily clinical practice. Most of them are ascribed to gastrointestinal disease in general. There exist, however, cases who complain with abdominal signs and symptoms whose causes are unable to be found, in spite of various examinations related to the abdomen. Epilepsy is a chronic disorder of the central nervous system manifesting with recurrent unprovoked seizures. Abnormal abdominal sensation often heralds the onset of epileptic seizures. Among them, there is a rare syndrome called abdominal epilepsy in which episodic gastrointestinal complaints like abdominal pain, abdominal discomfort, nausea, vomit, and diarrhea are the primary or the sole manifestation of epileptic seizures. It is important for clinicians to know that abdominal epilepsy is one of the differential diagnoses of acute gastrointestinal signs and that these symptoms can be treated with antiepileptic medications. Here we review abdominal epilepsy as one of the causes in acute diarrhea.

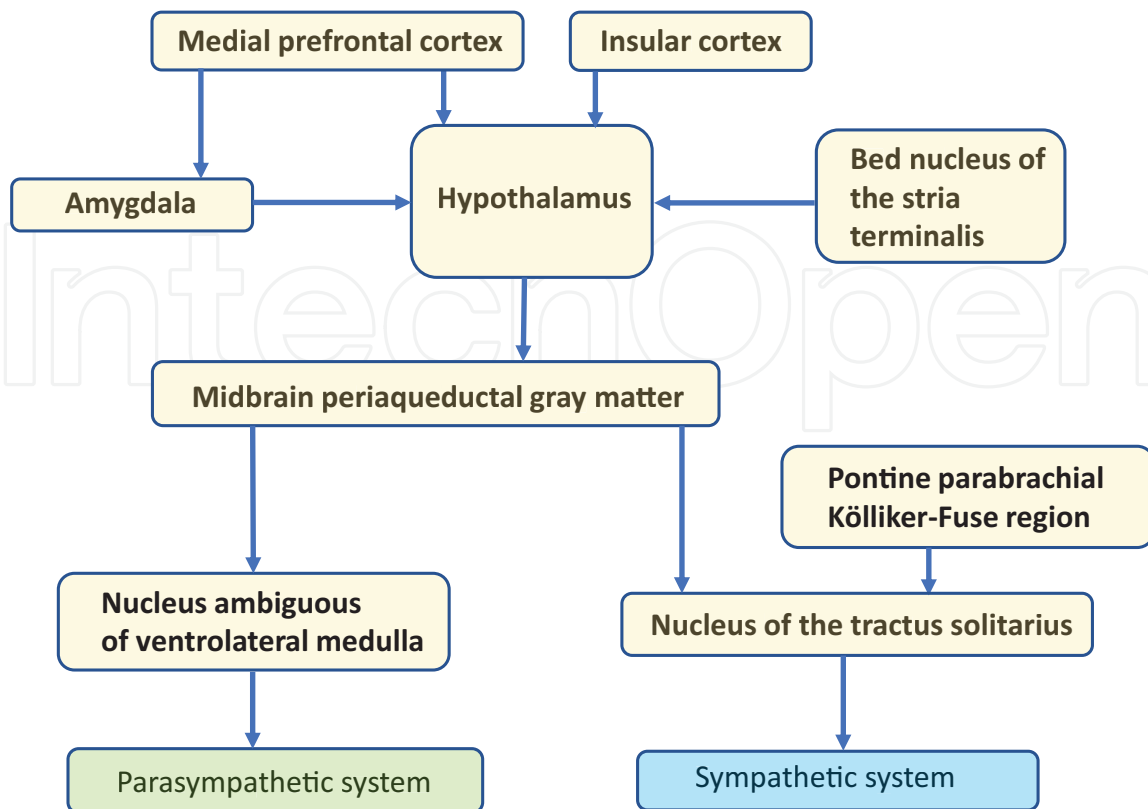
**Keywords:** acute diarrhea, recurrent diarrhea, semiology, epileptic seizures

## 1. Introduction

We clinicians often have to deal with gastrointestinal complaints in daily medical practice. Most of the abnormal abdominal signs and symptoms are ascribed to gastrointestinal disease in general. Meanwhile, the autonomic nervous system is a part of the central nervous system (CNS) and innervates all organs of the body including the gastrointestinal system (**Figure 1**). Autonomic dysfunction manifests with gastrointestinal symptoms like constipation, diarrhea, and oropharyngeal dysphagia. Neurodegenerative disorders as multiple systemic atrophy, allied parkinsonian disorders, and pure autonomic failure can show autonomic manifestations including gastrointestinal signs. Diabetes mellitus and alcoholic enteropathy also cause neurogenic diarrhea along with anxiety neurosis [1]. Their symptoms are usually chronic.

There are, however, rare cases with gastrointestinal manifestations whose causes cannot be found, though various examinations related to the abdomen are performed. Their symptoms are acute and recurrent episodically. Epileptic seizures are a “transient occurrence of signs and/or symptoms due to abnormal excessive or synchronous neuronal activity in the brain” [2]. Epileptic seizures have to be distinguished from nonepileptic seizures and acute provoked seizures that occurs in the context of an acute brain damage or systemic disorder, such as, but not limited to, stroke, head trauma, a toxic or metabolic insult, or an intracranial infection [3].

Simplified diagram of central autonomic network (CAN)



**Figure 1.**  
Simplified diagram of central autonomic network (CAN).

In the widely accepted operational definition of epilepsy, it requires that an individual has at least two provoked seizures on separate days, generally 24 hours apart. There are various seizure types in accord with the cortical function of the epileptic foci and propagated areas in epilepsy. Abnormal abdominal sensation often heralds the onset of epileptic seizures. Among them, there is a rare syndrome called abdominal epilepsy in which episodic gastrointestinal complaints like abdominal pain, abdominal discomfort, nausea, vomit, and diarrhea are the primary or the sole manifestation of epileptic seizures. It is important for clinicians to know that abdominal epilepsy is one of the differential diagnoses of gastrointestinal signs, especially when they are acute onset and recurrent, and that it is treatable with antiepileptic medications.

Here we review abdominal epilepsy as one of the causes in acute diarrhea.

## 2. Definition

Abdominal epilepsy is characterized by paroxysmal gastrointestinal signs and symptoms resulting from epileptic activity of the neurons in the brain. Epileptic seizures of several patients with abdominal epilepsy are accompanied with impairment of the CNS like loss of consciousness and headache. There is no authorized diagnosis criterion for abdominal epilepsy at present. Zinkin and Peppercorn propose the following criteria for diagnosis of abdominal epilepsy. That is to say, (1) paroxysmal gastrointestinal manifestations of undetermined origin after thorough evaluation including laboratory, radiographic, and endoscopy testing, (2) symptoms originated from the CNS, (3) an abnormal electroencephalogram (EEG)

findings relatively specific for epileptic seizures, and (4) a sustained improvement of symptoms by antiepileptic medication [4].

Though many authors cite this criterion in their case reports published hitherto, there are several points at issue in this definition as follows. The gastrointestinal symptoms as acute symptomatic seizures should be ruled out; i.e., unprovoked chronic recurrence or more than 60% probability to recur is needed to diagnose epilepsy [5]. It is difficult to certify the diagnosis by EEG findings (difficulty to record in ictal state, difficulty to record EEG activities via scalp electrodes in cases with epileptogenic foci on mesial temporal area or insular cortex especially in small areas, and low rate of detecting the epileptogenic discharge on patient with epilepsy in general). In case of refractory epilepsy, symptoms could not be improved by antiepileptic drug. Therefore new definition is expected to capture the real entity of this disease.

### 3. Epidemiology

Hitherto, publications concerning abdominal epilepsy are quite limited in number. Accurate prevalence rate of abdominal epilepsy has not been evaluated. There are 36 cases reported in literature, in the review of abdominal epilepsy by Zinkin and Peppercorn [4]. We found other 15 cases of abdominal epilepsy in

author	published year	Age	Gender	gastrointestinal symptoms	CNS symptoms	MRI/CT	SPECT	EEG	laterality on EEG	abnormal location on EEG	treatment
Scotinotis	2000	66	M	nausea	none	unremarkable	NA	sharp wave	right	temporal	CBZ
Topno	2005	38	F	abdominal pain	LOC, post-ictal amnesia	unremarkable	NA	sharp wave	right	fronto-temporal	PHE
Shihabuddin	2007	72	F	abdominal pain, nausea	none	NA	NA	ictal discharge	right	temporal	LTG
Dutta	2007	50	M	abdominal discomfort, vomit	NA	unremarkable	NA	dysrhythmia in the form slowing	left	temporal	OXC
		52	F	abdominal discomfort, vomit	headache, drowsiness	unremarkable	NA	focal discharge with generalization	right	frontal	OXC
Sekimoto	2007	32	M	nausea, vomit	palpitation	unremarkable	NA	low voltage spikes	bilateral	occipital, parietal	CBZ
		23	F	nausea, vomit	vaguely unpleasant feeling	unremarkable	NA	low voltage spikes	bilateral	occipital, parietal	CBZ
Tiamkao	2011	20	F	abdominal pain, nausea	GTCS	NA	NA	sharp wave	NA	NA	PHE, DIA
		46	M	epigastric pain, vomit	none	NA	NA	spike	NA	NA	PHE
		21	F	abdominal discomfort, vomit	none	NA	NA	spike	NA	NA	PHE
Murai	2014	63	F	abdominal discomfort, diarrhea	LOC, palpitation	unremarkable	decreased blood flow in the left frontal and temporal	sharp transients, delta waves	left	anterior-mid temporal	CBZ
Harshe	2016	45	F	abdominal pain, vomit	none	NA	NA	spike and slow wave complexes	bilateral	NA	VPA
Hayashida	2016	71	F	nausea, vomit	headache	unremarkable	perfusion defects in the frontotemporo parietal	sharp wave	left	temporal	LEV, CZP
Mpondo	2016	38	M	abdominal pain	none	NA	NA	spikes	bilateral	temporal	CBZ
Al-Hail	2018	26	F	abdominal pain	none	left mesial temporal sclerosis	NA	sharp wave	left	anterior temporal	LTG

Abbreviations: LOC, loss of consciousness; GTCS, generalized tonic-clonic seizure; NA, not available; CBZ, carbamazepine; PHE, phenytoin; LTG, lamotrigine; OXC, oxcarbazepine; DIA, diazepam; VPA, sodium valproate; CZP, clonazepam

**Table 1.**  
 Summary of case reports by literature.

English literature after Zinkin's review paper [6–16]. In the reported cases, there is no racial specificity nor regional specificity. The number of patients with abdominal epilepsy could be more than reported cases because the entity of abdominal epilepsy has still not been recognized and because nonmotor seizure manifestations are often underdiagnosed. **Table 1** shows the patient profile of 15 case reports that was published after his review. Elderly patients of more than 60 years old are only 1 case (2%) out of his 36 cases and 4 cases (26%) out of 15 cases. Recently there is increasing evidence that elderly with dementia have greater risk of epilepsy. Hayashida et al. reported that the cumulative incidence of at least one unprovoked seizure in individuals with Alzheimer's disease is in the range of 10–20% [14]. From now on, the number of abdominal epilepsy could be increased along with the increase of elderly patients with epilepsy.

#### **4. Clinical features**

Abdominal epilepsy is quite uncommon. Zinkin and Peppercorn found only 36 reported cases in the English literature since Douglas and White laid the groundwork in the reporting of cases of abdominal epilepsy in 1971, and they reviewed 36 patients with abdominal epilepsy in the past 34 years [4]. After their report, we found other 15 adult cases in English literature (**Table 1**). Age of patients varies a great deal from 1 to 71 years, and female is 57% (29/51), without any significant predisposition. Gastrointestinal manifestations of epilepsy include abdominal pain in 76% (39/51), nausea and/or vomit in 43% (22/51), and diarrhea in 6% (3/51); in abdominal epilepsy, rate of occurrence of diarrhea is quite rare as a gastrointestinal symptom. All three patients with diarrhea had the abnormal findings on EEG in temporal area. Antiepileptic drugs were prescribed (phenobarbital, valproic acid, and carbamazepine). The outcome was complete resolution or well-controlled.

#### **5. Examination**

General physical examination is unremarkable. The examination directly related with gastrointestinal signs and symptoms, for example, abdominal computed tomography (CT) scan, abdominal ultrasound, and gastrointestinal endoscopy, is normal. Blood tests and cerebrospinal fluid examination are usually normal.

Neuroimaging like magnetic resonance (MR) imaging and/or CT scan or single-photon emission computed tomography (SPECT) sometimes shows local lesion, especially in temporal areas. Two cases have no remarkable MR imaging and/or CT but abnormal findings in temporal lobe or areas including temporal lobe on brain SPECT (one, decreased blood flow in the left frontal and temporal; the other, perfusion defects in the frontotemporal-parietal area) [12, 14]. There is one patient who has abnormal lesion in temporal lobe on MR imaging (left mesial temporal sclerosis) [16]. No specific finding is relevant to diagnosis of abdominal epilepsy.

As is the case with any type of epilepsy, EEG is one of the most important examinations for abdominal epilepsy. EEG is a record of the electrical potentials generated in neurons from electrodes attached to the human scalp. One estimate is that approximately 6 cm<sup>2</sup> of cortical surface must be synchronously activated in order for there to be a potential recorded at the surface [17]. Abnormal EEG activity can be classified into two types: epileptiform and non-epileptiform. The two most important types of abnormal activity are slowing and epileptiform activity. Slow waves indicate disordered function of the neuron, whereas epileptiform activities indicate abnormal synchronous activity [17]. EEG is of diagnostic power when

significant epileptiform discharges are detected. Spikes and sharp waves are epileptiform discharges that reflect the paroxysmal depolarization shifts in the epileptic neurons. They are basically surface negative but in rare occasions surface positive. Patients with epilepsy has abnormal EEG findings even though they are in interictal state. Interictal epileptic discharge like spikes and sharp waves is recognized on EEG of abdominal epilepsy patients; however, less specific EEG changes can be a clue for diagnosis.

In patients with epilepsy, generally speaking, the initial EEG examination shows interictal epileptiform discharges in only about 50%; therefore, normal EEG does not exclude the presence of epileptic disorder. It is hard to capture the abnormal signals in case of deeper lesion and/or small foci in the brain. As for enhancement of sensitivity, the detection rate is increased by performing repeated EEG at different times or by physiological activation procedures like hyperventilation, sleep recording, and photic stimulation. Long-term video EEG monitoring is one of the useful tools for diagnosis of epilepsy. Video EEG monitoring is an EEG record with video recording continuously for several days including sleep in the night and performed for direct correlation of clinical symptoms with EEG findings. When the gastrointestinal signs and symptoms occur and abnormal EEG findings (epileptiform discharge) are recognized at the same time, the diagnosis of epilepsy is determined. In most of the reports in the past, abnormal findings on EEG are interictal, but only one case report has ictal EEG recording showing left anterior temporal onset [16].

## 6. Pathophysiology

Seizure semiology of abdominal epilepsy is usually categorized as partial seizures (simple partial seizures with preserved consciousness, complex partial seizures with impaired consciousness, and secondarily generalized seizures with loss of consciousness and generalized convulsion) [4]. Based on the operational classification of seizure types by the International League Against Epilepsy (ILAE) (2017), epileptic seizures with onset of autonomic features are classified into autonomic (onset) seizures. According to the “ILAE classification of the epilepsies: Position paper of the ILAE Commission for Classification and Terminology,” [18] abdominal epilepsy is categorized as a focal epilepsy, whatever the etiology may be.

In history, many cases have been described, and many terms have been used for paroxysmal autonomic symptoms including gastrointestinal ones classified as epilepsy from the times of Armand Trousseau [19]. Moore used the term abdominal epilepsy for the first time for patients with abdominal pain or abdominal pain with nausea and vomit caused by epileptic seizures [20]. Because sensory symptoms are related to loss of consciousness or any other impairment of central nervous system, the sensory symptoms are regarded as an aura [21].

The mechanism that abdominal epilepsy occurs is still unclear, but several studies indicate that temporal lobe structures including the amygdala and hippocampus, insular cortex, and limbic systems could be related with inducing abdominal sign and symptoms known as abdominal epilepsy [4]. Ictal autonomic changes are probably due to direct excitation or inhibition of neocortex and limbic systems involved in seizure onset and their propagation to structures that constitute the central autonomic network (**Figure 1**) [21]. The brain controls widespread autonomic responses through the central autonomic network ranging from the cerebral hemisphere to the brain stem. The insular and medial prefrontal cortices, the hippocampus, and the amygdala are the major inputs to transmit cortical activity to the central nervous network. Certain autonomic symptoms and signs (vomiting, nausea, and alterations in heart rate and respiration, flushing,

sweating, piloerection, pupil dilatation) indicate specific localization and lateralization of the seizure-onset zone [21–24].

## **7. Diagnosis**

Gastrointestinal disease should be ruled out at first. The detail of history as recurrent paroxysmal episodes of gastrointestinal symptoms is needed for the diagnosis of abdominal epilepsy. The duration of symptoms is usually within a few minutes. It is important to distinguish abdominal epilepsy itself from abdominal auras preceding to other major seizure manifestations of temporal or parieto-occipital epilepsies [23].

On the contrary, information of subjective findings related to epileptic auras should be carefully obtained. Especially, epigastric rising sensation, déjà vu, jamais vu, olfactory sensation, and sudden emergence of certain memory are related to temporal lobe epilepsy. When gastrointestinal symptoms and signs are the sole seizure manifestation, nonepileptic disease could be included in the differential diagnosis since gastrointestinal signs may often be wrongly diagnosed. Ictal autonomic symptoms are most often associated with epileptiform discharges in limbic portions of the temporal and frontal lobes on EEG [25].

## **8. Treatment**

There has been no controlled trial that provides evidence-based medication on treatment of abdominal epilepsy so far. Treatment is the same as other types of epilepsy, and antiepileptic drug is usually used. Epileptic seizures of abdominal epilepsy are recognized as one of the partial seizures; therefore, carbamazepine or phenytoin is selected as the first line in medication. If the first drug is not effective enough, the certain drug would be increased to the maximum tolerable dose, or other types of medication can be added on, based on the patient's response.

## **9. Prognosis**

The prognosis of abdominal epilepsy is generally good. In most patients, antiepileptic drug is effective, and only antiepileptic medication brings relief in gastrointestinal symptoms. In cases who are drug-resistant to single medication, polytherapy is needed by using a couple of antiepileptic drugs in combination. Other kinds of autonomic signs and symptoms, and seizure manifestations other than autonomic features, might also reflect a reaction to the occurrence of epileptic seizures [23]. Therefore, it is necessary to check subjective/objective findings by thorough medical history taking and to schedule follow-up examinations including EEG evaluation.

## **10. Conclusions**

Patients with focal epilepsy often exhibit a variety of autonomic symptoms including abdominal sensations as auras (simple partial seizures, or focal seizures with retained awareness). When gastrointestinal complaints, usually abdominal pain and nausea, are the most prominent manifestation of epileptic seizures, they are called as abdominal epilepsy. Abdominal epilepsy should be suspected as one of

the possible diagnoses in patients with diarrhea and other autonomic symptoms, even though they do not exhibit convulsions or other typical motor manifestations. Unless a careful and detailed history taking reveals the subjective and objective findings by patients and witnesses, a possible diagnosis of epilepsy and a therapeutic trial of antiepileptic therapy are never considered. Detection of significant epileptiform discharges in EEG is the cardinal method for diagnosis; however, normal EEG does not exclude the possibility of epileptic disorders because only half of patients with clinical diagnosis of epileptic seizures or epilepsy show overt abnormality. Subtle EEG findings, especially reproducible ones whose distribution is in concordance with clinical manifestations, should not be neglected. Acute diarrhea as one of the manifestations of focal epilepsy, especially temporal lobe epilepsy, is quite uncommon, but it is important to recognize the clinical entity.

## Acknowledgements

No funding for this paper.

## Conflict of interest

The authors have no conflict of interests to disclose.

## Author details


Tomohiko Murai<sup>1</sup> and Masako Kinoshita<sup>2\*</sup>

<sup>1</sup> Department of Neurology, Kyoto City Hospital, Kyoto, Japan

<sup>2</sup> Department of Neurology, Utano National Hospital, National Hospital Organization, Kyoto, Japan

\*Address all correspondence to: [machak@kuhp.kyoto-u.ac.jp](mailto:machak@kuhp.kyoto-u.ac.jp)

## IntechOpen

© 2019 The Author(s). Licensee IntechOpen. This chapter is distributed under the terms of the Creative Commons Attribution License (<http://creativecommons.org/licenses/by/3.0>), which permits unrestricted use, distribution, and reproduction in any medium, provided the original work is properly cited. 



## References

- [1] Mathias CJ, Freeman R. Autonomic dysfunction. In: *Neurological Disorders: Course and Treatment*. 2nd ed. Cambridge: Academic Press; 2003
- [2] Fisher RS, Boas W, et al. Epileptic seizures and epilepsy: Definition proposed by the International League against Epilepsy (ILAE) and the International Bureau for Epilepsy (IBE). *Epilepsia*. 2005;**46**:470. DOI: 10.1111/j.0013-9580.2005.66104.x
- [3] Guideline for epidemiologic studies on epilepsy. Commission on Epidemiology and Prognosis, International League Against Epilepsy. *Epilepsia*. 1993;**34**:592-596
- [4] Zinkin NT, Peppercorn MA. Abdominal epilepsy. *Best Practice & Research Clinical Gastroenterology*. 2005;**19**:263-274. DOI: 10.1016/j.bpg.2004.10.001
- [5] Fisher RS, Acevedo C, et al. ILAE official report: A practical clinical definition of epilepsy. *Epilepsia*. 2014;**55**:475-482. DOI: 10.1111/epi.12550
- [6] Scotiniotis I, Stecker M, et al. Recurrent nausea as part of the spectrum of abdominal epilepsy. *Digestive Diseases and Sciences*. 2000;**45**:1238-1240
- [7] Topno N, Gopasetty MS, et al. Abdominal epilepsy and foreign body in the abdominal dilemma in diagnosis of abdominal pain. *Yonsei Medical Journal*. 2005;**46**:870-873. DOI: 10.3349/ymj.2005.46.6.870
- [8] Shihabuddin BS, Harik SI. Episodic nausea and abdominal sensations as sole manifestations of simple partial seizures. *Neurosciences*. 2007;**12**:327-329
- [9] Dutta SR, Hazarika I, Chakravarty BP. Abdominal epilepsy, an uncommon cause of recurrent abdominal pain: A brief report. *Gut*. 2007;**56**:439-441. DOI: 10.1136/gut.2006.094250
- [10] Sekimoto M, kato M, et al. Ictal nausea with vomiting as the major symptom of simple partial seizures: Electroencephalographic and magnetoencephalographic analysis. *Epilepsy and Behavior*. 2007;**11**:582-587. DOI: 10.1016/j.yebeh.2007.08.023
- [11] Tiamkao S, Pratipanawatr T, et al. Abdominal epilepsy: An uncommon of non-convulsive status epilepticus. *Journal of the Medical Association of Thailand*. 2011;**94**:998-1001
- [12] Murai T, Tohyama T, Kinoshita M. Recurrent diarrhea as a manifestation of temporal lobe epilepsy. *Epilepsy and Behavior Case Reports*. 2014;**2**:57-59. DOI: 10.1016/j.ebcr.2014.03.007
- [13] Harshe DG, Harshe SD, et al. Abdominal epilepsy in an adult: A diagnosis often missed. *Journal of Clinical and Diagnostic Research*. 2016;**10**:VD01-VD02. DOI: 10.7860/JCDR/2016/19873.8600
- [14] Hayashida A, Tomizawa Y, et al. Abdominal epilepsy associated with Alzheimer's disease. *Journal of the American Geriatrics Society*. 2016;**64**(5):1146-1147. DOI: 10.1111/jgs.14125
- [15] Mpondo BC, Mwasada G, et al. Abdominal epilepsy, an uncommon cause of chronic and recurrent abdominal pain: A case report. *Clinical Case Reports*. 2016;**4**:1117-1119. DOI: 10.1002.ccr3.711
- [16] Al-Hail H, Wilkins SS, et al. Temporal epilepsy causing recurrent abdominal pain in adults. *World Journal of Neuroscience*. 2018;**8**:270-276. DOI: 10.4236/wjns.2018.82021
- [17] Misulis KE. *Atlas of EEG, Seizure Semiology, and Management*. 2nd ed.

Oxford: Oxford University Press; 2014.  
pp. 26-29. DOI: 10.1093/med/  
97801999985906.001.0001

[18] Fisher RS, Cross JH, et al.  
Operational classification of seizure  
types by the International League  
Against Epilepsy: Position Paper of the  
ILAE Commission for Classification and  
Terminology. *Epilepsia*. 2017;**58**:  
522-530. DOI: 10.1111/epi.13670

[19] Moseley B, Bateman L, et al.  
Autonomic epileptic seizures,  
autonomic effects of seizures and  
SUDEP. *Epilepsy and Behavior*. 2013;**26**:  
375-385. DOI: 10.1016/j.2012.08.020

[20] Moore MT. Abdominal epilepsy.  
*The Review of Gastroenterology*. 1948;  
**15**:381-395

[21] Peppercorn MA, Herzog AG. The  
spectrum of abdominal epilepsy in  
adults. *The American Journal of  
Gastroenterology*. 1989;**84**:1294-1296

[22] Tufenkjian K, Luders HO. Seizure  
semiology: Its value and limitations in  
localizing the epileptogenic zone.  
*Journal of Clinical Neurology*. 2012;**8**:  
243-250. DOI: 10.3988/jcn.2012.8.4.243

[23] Foldvary-Schaefer N, Unnwongse  
K. Localizing and lateralizing features of  
auras and seizures. *Epilepsy and  
Behavior*. 2011;**20**:160-166. DOI:  
10.1016/j.yebeh.2010.08.034

[24] Freeman R, Schachter SC.  
Autonomic epilepsy. *Seminars in  
Neurology*. 1995;**15**:158-166. DOI:  
10.1055/s-2008-1041019

[25] Engel JJR. *Seizures and Epilepsy*.  
Oxford: Oxford University Press;  
2013. p. 210. DOI: 10.1093/med/  
9780195328547.001.0001