

We are IntechOpen, the world's leading publisher of Open Access books Built by scientists, for scientists

4,800

Open access books available

122,000

International authors and editors

135M

Downloads

Our authors are among the

154

Countries delivered to

TOP 1%

most cited scientists

12.2%

Contributors from top 500 universities



WEB OF SCIENCE™

Selection of our books indexed in the Book Citation Index
in Web of Science™ Core Collection (BKCI)

Interested in publishing with us?
Contact book.department@intechopen.com

Numbers displayed above are based on latest data collected.

For more information visit www.intechopen.com



Chapter

Cerebral Arteriovenous Malformation from Classification to the Management

Nissar Shaikh, Aisha Al-Kubaisi, Muhammad Mohsin Khan, Adnan Khan, Zia Mahmood, Arshad Chanda, Adel Ganaw, Gamal Al-Ameri, Mostafa Rezk, Moad Ehfeda, Muhammad Zubair, Jazib Hassan and AR Raju Vegesna

Abstract

Cerebral arteriovenous malformations (cAVMs) are the rare neurosurgical emergency. cAVM is an abnormal vascular web, composed of nidus, feeding artery and draining veins. It commonly occurs in the supratentorial area of the brain. The common grading system used in cAVM is Spetzler-Martin grading, which takes into consideration the size of nidus, the location of cAVM and the venous drainage. The cAVMs may develop flow and pressure-related aneurysms, which will increase the morbidity and mortality in these patients. cAVMs vary in size and undergo growth, remodeling and rarely regression. Most of the cAVMs are asymptomatic, but the common presentation are headache, seizure, intracerebral hemorrhage or focal neurological deficit. The cerebral angiography remains the gold standard for the diagnosis of cAVM. Management of the cAVM includes medical therapy, surgical excision, radiosurgery and embolization.

Keywords: cerebral angiography, headache, embolization, focal neurological deficit, intracerebral hemorrhage, medical therapy, radiosurgery, seizures, surgical excision, Spetzler-Martin grading

1. Introduction

1.1 Definition

Cerebral arteriovenous malformations (cAVMs) are the vascular abnormality composed of a complex, tangled web of afferent arteries and draining veins linked by an abnormal dysplastic intervening capillary bed or no capillary bed (**Figure 1**). The ruptured cAVM is a neurosurgical emergency requiring team management approach including neurosurgeons, neuro-interventional radiologist, neuro-anaesthesiologist and an intensivist.

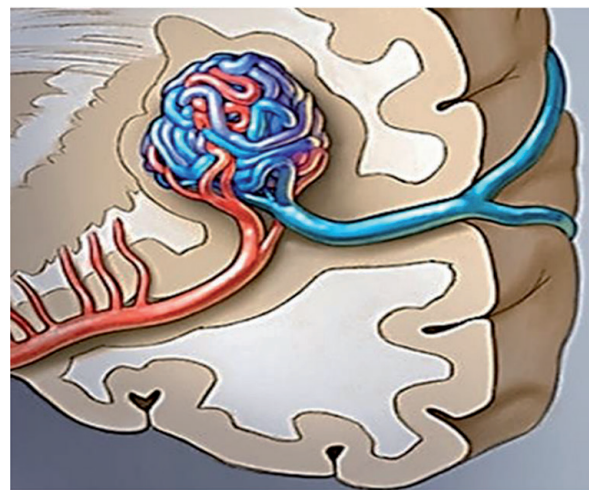
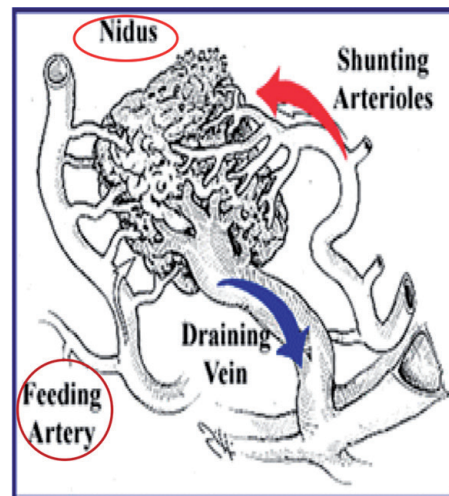


Figure 1.
Cerebral arteriovenous malformation.

2. Epidemiology

Cerebral arteriovenous malformations are rare, found in around 0.1% of the population and one-tenth (1/10th) of the incidence of the brain aneurysms. About 15% of cAVMs remain asymptomatic based on autopsy series. The majority (90%) of cAVMs are found in the supratentorial region, the remaining 10% occur in the posterior fossa. cAVMs commonly occur as single lesions, and in 9% of the patients, there are multiple AVMs [1, 2]. cAVM has no gender preference.

cAVM causes subarachnoid hemorrhages in 9% of the patients. The mean age of presentation is 30–40 years; 3% of young patients had stroke due to cAVM. It also causes primary intracerebral hemorrhage in 33% of young adults [3].

3. Classifications

cAVM is classified as follows:

1. Luessenhop-Gennarelli anatomical grading
2. Spetzler-Martin grading (**Table 1**)/supplementary Spetzler-Martin grading (**Table 2**)

3. Nataf grading (**Table 3**)

4. Vienna classification (**Table 4**).

Size of cAVM	
0–3 cm	1
3.1–6.0 cm	2
>6 cm	3
Location of cAVM: eloquent areas (sensorimotor, language, visual, thalamus, hypothalamus, internal capsule, brain stem, cerebellar peduncles and deep cerebellar nuclei)	
Non-eloquent brain area	0
Eloquent brain area	1
Deep venous drainage	
Absent	0
Present	1
AVM grade = size + eloquence + deep component	

Table 1.
 Spetzler-Martin grading scale for cAVM.

Size of cAVM		Patient's age (years)
0–3 cm	1	<20
3.1–6.0 cm	2	20–40
>6 cm	3	>40
Location of cAVM (eloquence area)		Compactness
No	0	Yes
Yes	1	No
Venous drainage		Bleeding
Superficial	0	Yes
Deep	1	No

Table 2.
 Supplementary Spetzler-Martin or Lawton-Young cAVM grading scale.

Grade I	No risk factor for bleeding
Grade Ia	With venous recruitment
Grade Ib	Without venous recruitment grade
Grade II	Venous stenosis or venous reflux
Grade III	Deep venous drainage only
Grade IV	Intra- or juxta-nidal aneurysm

According to this grading system, there is 13% of hemorrhage in grade Ia, in grade Ib 38%, in grade II 48% and in grade III and IV risk of hemorrhage 90% [7].

Table 3.
 Nataf grading.

	Gr 0	Gr I	Gr II	Gr III
Feeders		Pial	Pial + perforators	Perforator
Number of feeders	1–2	>2		
Nidus (cm)	<2	2–4	>4	

Table 4.
Vienna classification.

3.1 Luessenhop-Gennarelli grading

This is the anatomical grading of supratentorial cAVM described in 1977, according to the degrees of surgical difficulty for total obliteration, graded into I–IV. Luessenhop-Gennarelli grading of cAVM is based upon the number of directly participating arteries for which there is a standardized nomenclature [4].

3.2 Spetzler-Martin (S-M) grading

In 1986 Spetzler and Martin graded cAVMs according to location, size and deep venous drainage, into the following five grades [5]:

1. Low-grade AVM: Grade I, grade II and grade III
2. High-grade AVM: Grade IV and grade V
3. Inoperable lesions: Grade VI (supplementary Spetzler-Martin (S-M Supp)).

The disadvantages of S-M grading of cAVM are definition of eloquence, lack of consideration for nidus compactness, not useful for posterior fossa AVM, only applicable for surgical outcome and grade III in homogeneity.

Supplementary Spetzler-Martin or Lawton-Young grading scale for cAVM was described in 2010, apart from the risk factors included in S-M grading; this S-M Supp grading system includes factors affecting the patient's outcome, namely, age, bleeding or compactness of the cAVMs (**Table 2**) [6]. Kim et al. from their cohort multicentre study concluded that S-M Supp grading system works better than the S-M grading for operability decisions and cut-off value for operability is S-M Supp scale of 6. S-M Supp also gives better post-operative neurological outcome predictability than the S-M score.

3.3 Nataf grading

In this 4-point grading, five angiographic parameters are used for the determinants of the bleeding risk.

3.4 Vienna classification

This classification is helpful in choosing the mode of treatment.

4. Morphology and type cAVM

Depending on the type and morphology, cAVM (**Figure 2**) is divided into the following (**Tables 5 and 6**):

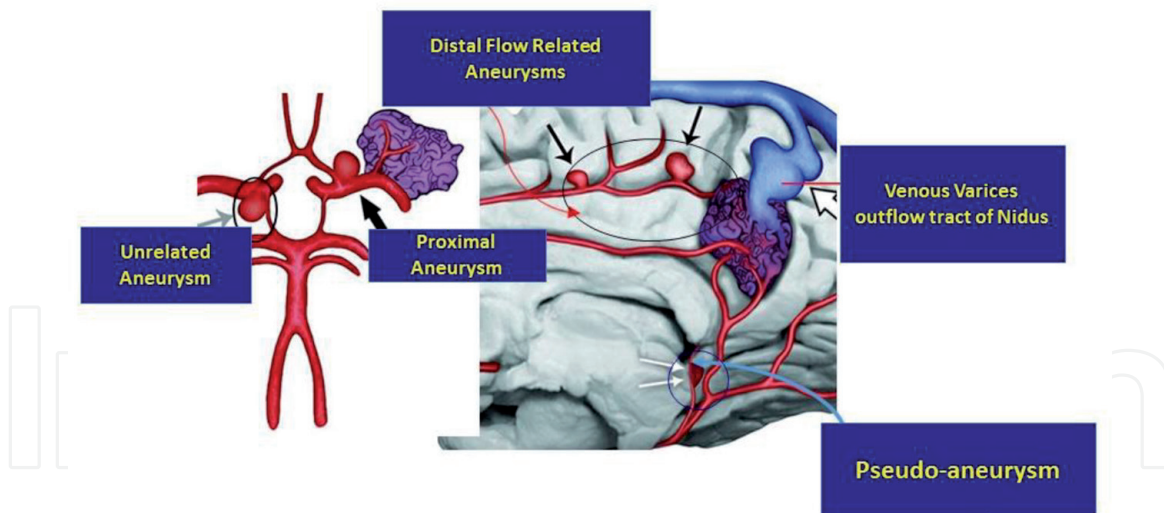


Figure 2.
 Details of cAVM and associated aneurysms.

Cryptic	Absent on angiogram/surgery/pathology
Occult	Absent on angiogram/surgery/seen only in pathology examination
According to the size of cAVM	
Micro-AVM	<1 cm
Small AVM	<2.5 cm
Moderate AVM	2.5–5 cm
Large AVM	>5 cm

Table 5.
 Morphology of cAVM.

Type	Nature	Pathological features of the vessel wall	Treatment modality
Intranidal	Pseudo-aneurysm	Disruption of internal elastic lamina (IEL)	Embolization
Distal flow-related	Saccular aneurysm, arising from the arterial trunk	Disruption of IEL, deficiency in the smooth muscle layer	The aneurysm and the parent artery were occluded with Onyx at the same sitting
Proximal flow-related	Segmental ectasia	Stretched/fragmented IEL: no luminal thrombus	Coiling for symptomatic lesion
Unrelated	Saccular, arising from the Willis circle or a site of bifurcation	Disruption of the IEL	Simply coiling or stent-assisted coiling

Table 6.
 Classification of aneurysm with cAVM [8].

5. Pathophysiology

The pathogenesis of cAVMs is not well understood; they are considered congenital and can undergo growth, remodeling or regression over the period. The

size of cAVMs varies widely, and cAVM can remain clinically silent for decades. In cAVM blood flows directly between them without capillary bed and not intervening neural parenchyma in nidus. cAVMs is a high-flow and high-pressure system. Particularly the small AVMs are having significantly higher pressure in the feeding arteries; hence the small AVMs are more lethal than the larger ones and bleed more frequently.

Familial cAVMs have been reported, but it is not clear whether these are coincidental or indicate a familial occurrence. Angio-architecture of cAVMs is direct arterial to venous connections without an intervening capillary network. Both the arterial supply and the venous drainage may be by single or multiple vessels. The high-flow arteriovenous communication potentiates a variety of flow-related phenomena such as the development of afferent and efferent pedicle aneurysms, which occur in 20–25% of patients, and arterialization of the venous limb. Aneurysms can be a source of bleeding with cAVMs and may indicate a grave prognosis [9]. Abnormal flow and a vascular steal phenomenon have been suggested to underlie some clinical symptoms associated with cAVMs [10]. Histopathological studies demonstrate areas of chronic ischemia and gliosis in the region of the cAVM malformation. Angio-structure of cAVM is typically composed of arterial feeder, nidus, draining vein and intervening gliotic neural parenchyma. The arterial feeder can be single or multiple originating from pial or perforating or dural arteries, and it can be a direct feeder supply as terminal branch or indirect feeder supply en-passage. Nidus is a compact tangle of dysplastic, thin-walled vessels of varied length connecting feeding arteries to draining veins. cAVM nidus can either be globular or conical in shape and may be compact or diffuse. Within the nidus, arterial blood is shunted directly into draining veins without passage through a normal, high-resistance arteriolar-capillary network.

6. Clinical presentation

cAVMs commonly present in younger age group ranging from 10 to 40 years. The clinical presentation of cAVM depends on the patient's age, size, location and vascular features of the cAVM. These patients commonly present with headache or neurological deficit or convulsions or intracerebral hemorrhage.

6.1 Headache

Around 0.2% of patients with headache and normal neurologic examinations were associated with cAVM [11]. Usually headache associated with cAVM is incidental, without any specifications. Headaches are the presenting symptom in approximately 15% of patients without evidence of rupture. Headache can be characterized as similar to migraines with lateralization to one side.

6.2 Focal neurologic deficit

This is quite an unusual presentation of cAVM. A vascular steal syndrome is hypothesized to be the cause for focal neurologic deficit [1].

6.3 Seizure (convulsions)

About 11–33% of cAVM patients present with convulsions, and patients with cortical-located, large, multiple and superficial-draining cAVMs present with convulsions [12]. Convulsions are focal, simple or partial complex with secondary

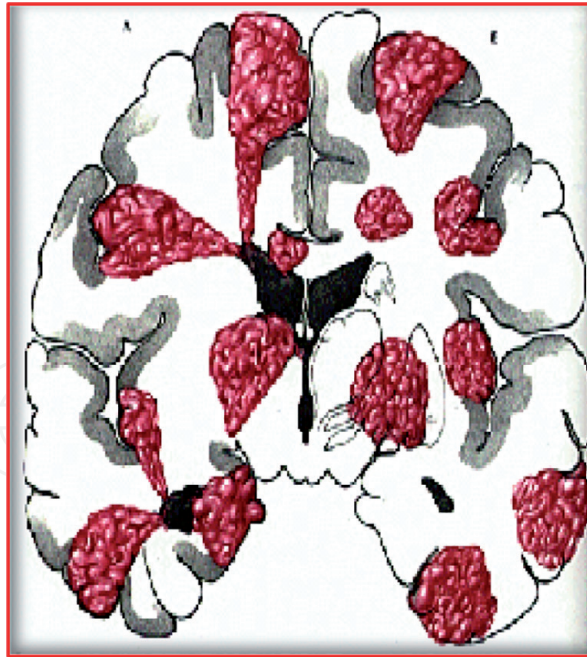


Figure 3.
Graphic representation of intracerebral hemorrhage.

generalization. cAVM-related seizures may occur due to the overt intracranial hemorrhage, from the hemosiderin deposition, or secondary to venous hypertension, ischemia following steal. The cAVM location influences the seizure type and semiology. The 5-year seizure risk for cAVMs is found to be 8% [13].

6.4 Intracerebral hemorrhage

About 41–79% of cAVM patients present with intracerebral hemorrhage (ICH) (**Figure 3**). Children more frequently present with intracerebral hemorrhage than adults [14]; 23% of patients with ICH or focal neurologic deficits had a 5-year risk of seizures. Hemorrhage can be parenchymal, intraventricular or subarachnoid.

Patients with cAVMs can have ICH on initial presentation. The deep venous drainage and deep brain location of cAVM had higher incidence of ICH, a recurrent AVM hemorrhage of 12% over an average with an average rebleeding rate of 7% annually [15]. Pregnancy is not a risk factor for hemorrhage from a cAVM, but the data are not definitive [16]; cAVM hemorrhage rate in pregnant women was not significantly different compared with the rate for non-pregnant women [17].

7. Diagnosis

Imaging studies are essential for the establishment of the diagnosis of cAVM, to make a pre-therapeutic evaluation of the cAVM to help in decision-making, to treat the AVM as a sole therapy or a multidisciplinary approach. It also helps in post-therapeutic evaluation of cAVM.

7.1 Computerized tomography (CT) of the brain

The CT of the brain is the first imaging procedure used to rule out hemorrhage. cAVM is suspected in young patients with lobar hematoma without significant oedema and calcifications. The parenchymal calcifications are found in 20% of cases, related to intravascular thrombosis or evolution of an old hematoma.

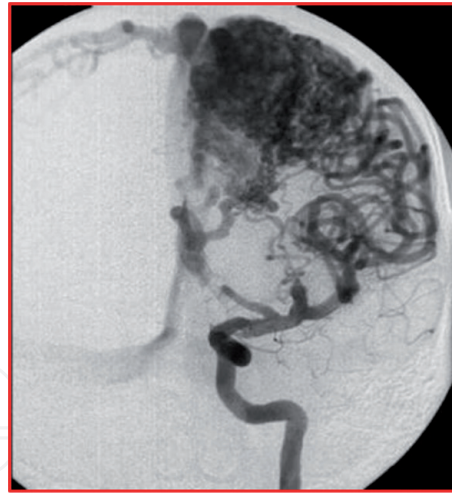


Figure 4.
Cerebral angiogram showing cAVM.

The compression of the nidus by hematoma precludes CT diagnosis of cAVM in patients with acute intracerebral hemorrhage; in these patients CT angiography and magnetic resonance angiography are essential.

7.2 Magnetic resonance imaging (MRI) of the brain

MRI of the brain is highly sensitive for the location of the cAVM nidus and an associated draining vein; it also has a unique sensitivity in demonstrating remote bleeding related to these lesions. MRI of the brain is particularly valuable in follow-up patients after treatment. After radiosurgery MRI is important for the regression of the nidal volume. Whereas the MR angiography techniques can characterize the venous drainage and other vascular features, the surrounding tissue that is subjected to the radiation field can be accurately monitored for post-therapy oedema or radiation necrosis [18].

7.3 Cerebral angiography

It is the gold standard for the diagnosis, treatment planning and follow-up after treatment of cAVMs. The anatomical and physiological information of the cAVM nidus, its relationship to surrounding vessels and localization of the draining or efferent portion of the cAVM are readily obtained with this cerebral angiography. It will also help in demonstration of associated aneurysm suggesting a lesion at higher risk for subsequent hemorrhage. The contrast transit times provide additional useful information regarding (Figure 4).

8. Treatment

The treatment plans of cAVM are most appropriately made by a multidisciplinary team of experienced clinicians with the consideration of size, location and vascular features of the AVM [19]. While making the decision, whether a patient should undergo AVM treatment, several factors have to be considered including the short- and long-term risk of hemorrhage, feasibility, associated aneurysm, patient's age, risks of intervention, availability of interventional radiologist and size and compactness of the nidus. The short-term and long-term hemorrhage risk is associated with a history of ruptured cAVM, patient age, AVM location, size and vascular morphological features.

The three types of modalities of treatment are microsurgery and excision of cAVM, embolization and stereotactic radiosurgery. It's frequent that these modalities are used in combination to achieve the complete treatment. In a systemic review, it was found that available treatment modalities were associated with risks including 5.1–7.4% of the median rate of permanent neurologic complications or death and incomplete efficacy of 13–96% [20]. Medical management of cAVM is considered when the patient has suffered a devastating neurological deficit; cAVM is very extensive, located deep in the brain, with blood supply primarily from deep perforating vessels, which are not amenable to endovascular or radiosurgical therapy, advanced age and poorly controlled comorbidities. We will discuss these modalities in the following subheadings.

8.1 Microsurgical cAVM excision

Microsurgical AVM excision is the most effective treatment of cAVM; it has the longest history of use for the definitive treatment of cAVMs and offers the best chance of immediate cure in patients at high risk of hemorrhage [19]. Factors associated with increased surgical risk are large size, deep venous drainage, deep location, diffuse nidus and feeders from deep perforating system. Surgeons should follow few basic surgical principles, cAVM excision should be an elective procedure, irrespective of the ruptured or unruptured cAVMs, preoperative steroids, anticonvulsants and antibiotics to be started, a wider craniotomy and dural opening, if the nidus is below the surface, an arterialized draining vein (red vein) can be followed to the AVM, localization may be assisted with ultrasound or frameless stereotaxic, dura should be open carefully, circumferential dissection of the nidus layer by layer, at least one major draining vein should be preserved till end of dissection, at end of dissection this vein becomes bluish proving that feeders have been eliminated, securing the individual vessels can be done with low power bipolar coagulation, but care should be taken as the excessive bipolar coagulation usage can cause retraction into eloquent tissue leading to the significant neurological morbidity. The complete AVM excision should be documented by post-op angiogram. Excision of the whole nidus is necessary to protect against rebleeding. If cAVM are high-flow, preoperative embolization should be considered, and cAVM supplies with multiple vascular territories may require a surgical staging. If cAVM are ectatic, high blood flow and irregular vessels will help in the identification. The feeding arteries (**Table 7**) can be distinguished from draining veins not by sight or look, as the veins will have arterial blood but by noting if the distal vessel collapses with gentle occlusion of the vein. The surgeon should always secure the feeding artery as close to the nidus as possible to ensure that this is not a passage artery feeding the normal brain, unless there is definite evidence on an angiogram that an artery is a direct nidus feeder.

Size	Vein dilates considerably, the vessel >4 mm is a vein unless proven otherwise
Color	Due to oxygenated blood, both appear red, but on careful view under illuminating microscopy, the vein appears bright red due to thin muscular layer, and the artery appears light pink
Flow on occlusion	Upon gentle compression of the vein, it will collapse distally unlike the artery
Vascular course	Arteries dive into sulci and fissure when veins rise to the surface towards sinuses

Table 7.
Differentiation of the artery from the vein in cAVM.

8.2 The morbidity and mortality of microsurgical excision of cAVMs

According to *Castel and Kantor*, morbidity and mortality after microsurgical excision of cAVM vary from 1.5 to 18.7% and from 0 to 15%, respectively [21]. Morbidity is high (20%) in deep-seated cAVM compared to the smaller cAVM with morbidity of up to 9% (**Tables 8 and 9**).

8.3 Stereotactic radiosurgery for cAVMs

High-energy beams of photons or protons to a defined volume containing cAVM nidus are stereotactically focused, and it induces progressive thrombosis of lesions by fibrointimal hyperplasia and subsequent luminal obliteration (**Figure 5**). The time between treatment and obliteration is referred to as the latency period, and it varies from 1 to 3 years. One has to wait for radiosurgery till the hematoma resolves. The factors influencing the obliteration rate of cAVM are cAVM size, target determination, angio-architecture and haemodynamics, cAVM location (hemispheric better) and radiation dosage. Stereotactic radiosurgery for cAVMs has disadvantages of the risk of hemorrhage in latency period and individual variability to radiosensitivity and neurological deficit.

The neurological deficit after radiosurgery is observed in 5.37% of the cases, and it was permanent in 1.46%. The mortality was 1.6%, and it is mainly due to the bleeding in the latency period [24].

The other complications after radiosurgery are radiation necrosis, which causes new neurologic deficits and seizures, and around 8% of the patients develop the parenchymal lesions, cranial nerve deficits, seizures, headaches and cyst formation [25]. The incidence of complications is related to cAVM location and the volume treated. Thalamic, basal ganglionic and brainstem locations are prone to development of deficits after radiosurgery [26]. The risk of complications is also related to

Intraoperative rupture
Post-retraction oedema
Seizures
Retrograde thrombosis of feeding vessels
Resection of eloquent brain
Normal perfusion pressure breakthrough (haemorrhage in normal brain tissue surrounding the lesion)

Table 8.
Complication of microvascular surgery.

S-M grading	Patient's outcome
Grade I	92–100%
Grade II	95%
Grade III	88%
Grade IV	73%
Grade V	57%

(*Heros RC, Korusure K, Diebuild PM. Surgical excision of cerebral arteriovenous malformations. Neurosurgery. 1990;26:570-577*).

Table 9.
Spetzler-Martin grading and patient's outcome after microsurgery [22, 23].

cAVM Obliteration rate (%) According to Patients Age (Years)

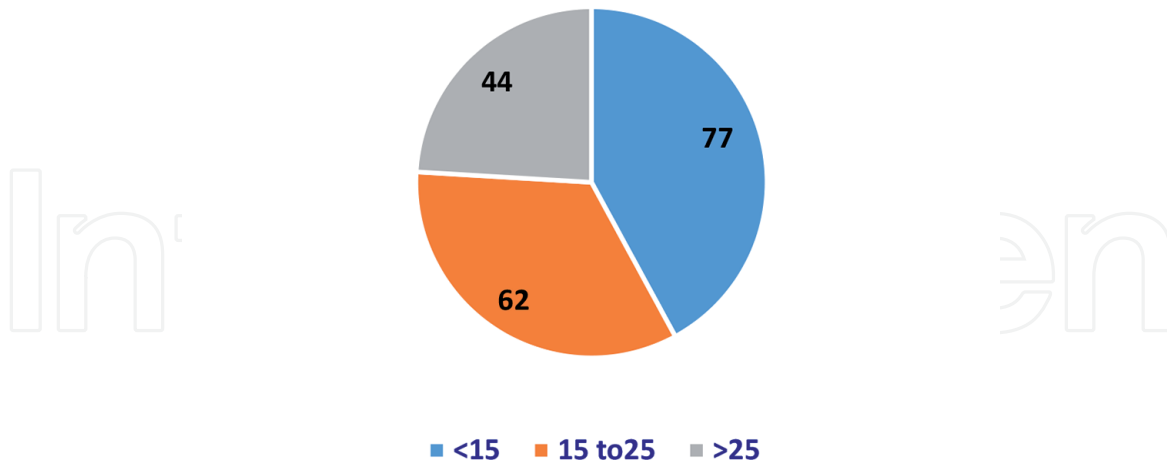


Figure 5.
Percentage of cAVM obliteration according to the nidus size (mm) by radiosurgery [25].

the radiation dose directed to the surrounding tissue and is increased in large brain AVMs that require larger treatment volumes [27]. Repeated radiosurgery is associated with increased complications [28].

8.4 Embolization

A rapidly evolving technique uses embolic agents such as silk, Histoacryl with Lipiodol and Onyx and delivery systems such as balloons with calibrated leaks, flow-guided micro-catheters and over-the-wire micro-catheters (**Figure 6**). It was used initially as an adjunct to microsurgery or radiosurgery; nowadays in selected cases, embolization is a sole treatment modality. By embolization less than 5% of cAVMs are cured.

Embolization can be an effective adjunct to radiosurgery and surgery. Embolization prior to radiosurgery is used to reduce the nidus size of large brain AVMs as the large AVMs have a lower cure rate with radiosurgery alone. Embolization prior to surgery is employed to reduce blood loss and to occlude

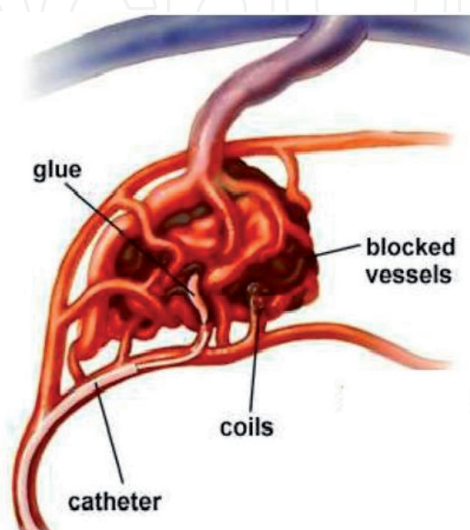


Figure 6.
Embolization process.

vessels that may be difficult to control during surgery [29]. Pre-embolization steroids and anti-epileptic medications should be started; the procedure is done under general anesthesia. The aims of cAVM embolization could be curative or palliative, and it could be partial prior to the radio- or microscopic surgery. Careful analyses of angiographic information including size, eloquent location, deep versus superficial venous drainage and vascular anatomy/number of feeders are considered for the suitability for embolization of cAVMs.

The cAVM embolization can be complicated into partial occlusion, intracranial hemorrhage, brain ischemia, glueing of micro-catheter or perfusion pressure breakthrough syndrome. Perfusion pressure breakthrough syndrome occurs in approximately 5% of the patients, thought to be related to the loss of autoregulation causing oedema or hemorrhages in the surrounding normal brain tissues [30]. The successful cAVM embolization occurs in 10–40% of the patients and may have to be done in the multiple settings.

To summarize the treatment of cAVMs, the following factors have to be considered: the patient's age and anatomic and vascular morphology of the cAVM.

8.5 Patient's age

It is an important factor in the decision to treat cAVMs. Those with a longer life expectancy will accrue a higher lifetime risk of hemorrhage. Accordingly therapy is recommended for children and young adults, whereas the older cAVM patients with shorter life expectancies may be managed more conservatively. The cumulative risk of hemorrhage in cAVM patients can be calculated by the formula [31]: Lifetime risk of hemorrhage = $1 - (1 - P) \times N$ (N is the expected years of life remaining, and P is the annual probability of hemorrhage). Another simpler formula is as follows: [32] Lifetime risk of hemorrhage = 105 - patient's age in years.

8.6 cAVM location

cAVM in eloquent brain territories presents a challenge for risk assessment. Significant clinical morbidity is likely to result if a surgical complication occurs as well as if the cAVM ruptures. Such patients may be more likely to be considered for radiosurgery.

8.7 Deep venous drainage

Deep venous drainage is a risk factor for surgical complications as well as for AVM rupture. If the lesion is otherwise amenable for treatment, radiosurgery may be the best option.

8.8 The cAVM size

Larger lesions are more difficult to treat but are not clearly at higher risk of bleeding than smaller lesions. cAVMs greater than 6 cm are managed conservatively. In patients with large lesions, the endovascular treatments may be useful to reduce the size of the aneurysm, if the vascular anatomy is determined to be amenable to this approach.

8.9 Associated aneurysm

The treatment of aneurysms associated with AVMs varies depending on aneurysm location and diameter [33]. When believed to be the source of hemorrhage,

	Microsurgery	Radiosurgery	Embolization
Low procedural invasivity	1	3	2
Occlusion capacity	3	2	1-2
Speed of efficacy	3	1	2-3
Long-term reliability	3	3	2-3
Independent from size	2	1	3
Independent from brain functionality	1	2	3
Independent from angio-architecture	2	3	
Independent from flow	3	2	1

1: no/low, 2: medium, and 3: yes/high.

Table 10.
 Factors for selecting the modalities of therapy in cAVM patients [34].

aneurysms are generally treated with surgery or endovascular therapy, depending on their location and size, according to the expertise of the available experienced clinicians. Aneurysms associated with unruptured cAVMs do not necessarily require treatment, depending on their size and other anatomic features.

Spetzler-Martin grading scale: Spetzler-Martin grading scale classifies surgical risk of removing cAVM according to its size, location and the presence of deep venous drainage. According to S-M grading, surgery is the modality of choice for grade I and II lesions, with radiosurgery as an alternative for small lesions based on location or other vascular anatomic features, while grade IV and V lesions are generally managed conservatively. S-M Supp grading gives a cut-off scale of 6 for operability of cAVM, and it is also a better predictor for post-cAVM excision neurological outcome. Hafez et al. [34] nicely described that apart from the S-M Supp grading, perforates play an important role in cAVM patient's outcome (**Table 10**) [35].

9. Conclusion

Cerebral arteriovenous malformations are rare and 10 times less frequent than the cerebral aneurysms. cAVMs are rare in the posterior fossa and account for 33% of intracerebral hemorrhage in young patients. They are classified by four different ways, but the commonly used classifications are Spetzler-Martin grading and supplementary Spetzler-Martin grading, as they also help in deciding the therapeutic approach. But it is not much useful in dealing the posterior fossa cAVMs. cAVMs can complicate into the formation of flow-related aneurysms and, according to their locations in relation to the cAVM, are classified into intranidal, distal, proximal or unrelated aneurysms. Angio-structure of cAVM is the direct connection between arterial and venous circulations without any intervening capillary network, and this makes cAVM high in flow and pressure structure at the risk of rupture.

The common presentation of cAVM is with intracerebral hemorrhage, with convulsions and rarely with focal neurological deficit. The most commonly used imaging modality for the diagnosis of cAVMs is computerized tomography. MRI scan has a unique sensitivity for the detection of remote hemorrhage, and conventional catheter cerebral angiography remained a gold standard in diagnosis of cAVMs. Multidisciplinary team approach is the best for management of cAVM patients. The surgical excision of cAVM gives definitive therapy in cAVM patients, radiosurgery is curative in selected cAVM patients and cerebral angiographic embolization is

rarely a sole therapy and usually in combination with surgical therapy. The medical therapies of cAVMs are anticonvulsants and steroids. While taking a therapeutic decision for cAVMs, it is of vital importance to consider the patient's age, location, deep venous drainage, size of cAVMs and the presence of the associated aneurysms. The associated aneurysms must be secured before the interventions for cAVMs.

IntechOpen

Author details

Nissar Shaikh^{1*}, Aisha Al-Kubaisi², Muhammad Mohsin Khan², Adnan Khan², Zia Mahmood¹, Arshad Chanda¹, Adel Ganaw¹, Gamal Al-Ameri¹, Mostafa Rezk¹, Moad Ehfeda¹, Muhammad Zubair¹, Jazib Hassan¹ and AR Raju Vegesna¹

1 Surgical Intensive Care, Hamad Medical Corporation, Doha, Qatar

2 Department of Neurosciences, Hamad Medical Corporation, Doha, Qatar

*Address all correspondence to: nissatfirdous99@gmail.com

IntechOpen

© 2019 The Author(s). Licensee IntechOpen. This chapter is distributed under the terms of the Creative Commons Attribution License (<http://creativecommons.org/licenses/by/3.0>), which permits unrestricted use, distribution, and reproduction in any medium, provided the original work is properly cited. 

References

- [1] Mohr JP, Kejda-Scharler J, Pile-Spellman J. Diagnosis and treatment of arteriovenous malformations. *Current Neurology and Neuroscience Reports*. 2013;**13**(2):324
- [2] Willinsky RA, Lasjaunias P, Terbrugge K, Burrows P. Multiple cerebral arteriovenous malformations (AVMs). Review of our experience from 203 patients with cerebral vascular lesions. *Neuroradiology*. 1990;**32**:207
- [3] Diringer MN, Bleck TP, Claude Hemphill J 3rd, et al. Critical care management of patients following aneurysmal subarachnoid hemorrhage: Recommendations from the Neurocritical Care Society's Multidisciplinary Consensus Conference. *Neurocritical Care*. 2011;**15**:211
- [4] Luessenhop AJ, Gennarelli TA. Anatomical grading of supratentorial arteriovenous malformations for determining operability. *Neurosurgery*. 1977;**1**(1):30-35
- [5] Spetzler RF, Martin NA. A proposed grading system for arteriovenous malformations. *Journal of Neurosurgery*. 1986;**65**(4):476-483
- [6] Kim H, Abla AA, Nelson J, McCulloch CE, Bervini D, Morgan MK, et al. Validation of the supplemented Spetzler-Martin grading system for brain arteriovenous malformations in a multicentre cohort of 1009 surgical patients. *Neurosurgery*. 2015;**76**(1):25-33
- [7] Nataf F, Schlienger M, Bayram M, Ghossoub M, George B, Roux FX. Microsurgery or radiosurgery for cerebral arteriovenous malformations? A study of two paired series. *Neurosurgery*. 2007;**61**:39-49
- [8] Lv X, Wu Z, He H, Ge H, Li Y. Proposal of classification of aneurysms coexisting with AVM and possible treatment strategies. *Turk Neurosurgical*. 2016;**26**(2):229-233. DOI: 10.5137/1019-5149.JTN.8600-13.1
- [9] Perata HJ, Tomsick TA, Tew JM Jr. Feeding artery pedicle aneurysms: Association with parenchymal hemorrhage and arteriovenous malformation in the brain. *Journal of Neurosurgery*. 1994;**80**:631
- [10] Moftakhar P, Hauptman JS, Malkasian D, Martin NA. Cerebral arteriovenous malformations. Part 2: Physiology. *Neurosurgical Focus*. 2009;**26**:E11
- [11] Evans RW. Diagnostic testing for the evaluation of headaches. *Neurologic Clinics*. 1996;**14**:1
- [12] Garcin B, Houdart E, Porcher R, et al. Epileptic seizures at initial presentation in patients with brain arteriovenous malformation. *Neurology*. 2012;**78**:626
- [13] Josephson CB, Leach JP, Duncan R, et al. Seizure risk from cavernous or arteriovenous malformations: Prospective population-based study. *Neurology*. 2011;**76**:1548
- [14] Fullerton HJ, Achrol AS, Johnston SC, et al. Long-term hemorrhage risk in children versus adults with brain arteriovenous malformations. *Stroke*. 2005;**36**:209
- [15] Choi JH, Mast H, Sciacca RR, et al. Clinical outcome after first and recurrent haemorrhage in patients with untreated brain arteriovenous malformation. *Stroke*. 2006;**37**:1243
- [16] Brown RD Jr, Flemming KD, Meyer FB, et al. Natural history, evaluation, and management of intracranial vascular malformations. *Mayo Clinic Proceedings*. 2005;**80**:269

- [17] Horton JC, Chambers WA, Lyons SL, et al. Pregnancy and the risk of hemorrhage from cerebral arteriovenous malformations. *Neurosurgery*. 1990;**27**:867
- [18] Saleh RS, Singhal A, Lohan D, et al. Assessment of cerebral arteriovenous malformations with high temporal and spatial resolution contrast-enhanced magnetic resonance angiography: A review from protocol to clinical application. *Topics in Magnetic Resonance Imaging*. 2008;**19**:251
- [19] Barr JC, Ogilvy CS. Selection of treatment modalities or observation of arteriovenous malformations. *Neurosurgery Clinics of North America*. 2012;**23**:63
- [20] van Beijnum J, van der Worp HB, Buis DR, et al. Treatment of brain arteriovenous malformations: A systematic review and meta-analysis. *Journal of the American Medical Association*. 2011;**2011**:306
- [21] Castel JP, Kantor G. Postoperative morbidity and mortality after microsurgical exclusion of cerebral arteriovenous malformations. Current data and analysis of recent literature. *Neuro-Chirurgie*. 2001;**47**:369-383
- [22] Sasaki T, Kurita H, Saito I, Kawamoto S, Nemoto S, Terahara A, et al. Arteriovenous malformations in the basal ganglia and thalamus: Management and results in 101 cases. *Journal of Neurosurgery*. 1998;**88**(2):285-292
- [23] Schaller C, Schramm J, Haun D. Significance of factors contributing to surgical complications and to late outcome after elective surgery of cerebral arteriovenous malformations. *Journal of Neurology, Neurosurgery and Psychiatry*. 1998;**65**:547-554
- [24] Nataf F et al. Results of series of 705 AVM treated by radiosurgery. *Neuro-Chirurgie*. 2001;**47**:268-282
- [25] Flickinger JC, Kondziolka D, Lunsford LD, et al. A multi-institutional analysis of complication outcomes after arteriovenous malformation radiosurgery. *International Journal of Radiation Oncology, Biology, Physics*. 1999;**44**:67
- [26] Pollock BE, Gorman DA, Brown PD. Radiosurgery for arteriovenous malformations of the basal ganglia, thalamus, and brainstem. *Journal of Neurosurgery*. 2004;**100**:210
- [27] Miyawaki L, Dowd C, Wara W, et al. Five year results of LINAC radiosurgery for arteriovenous malformations: Outcome for large AVMS. *International Journal of Radiation Oncology, Biology, Physics*. 1999;**44**:1089
- [28] Buis DR, Meijer OW, van den Berg R, et al. Clinical outcome after repeated radiosurgery for brain arteriovenous malformations. *Radiotherapy and Oncology*. 2010;**95**:250
- [29] Krings T, Hans FJ, Geibprasert S, Terbrugge K. Partial "targeted" embolization of brain arteriovenous malformations. *European Radiology*. 2010;**20**:2723
- [30] Young WL, Kader A, et al. Pressure autoregulation is intact after arteriovenous malformation resection. *Neurosurgery*. 1993;**32**:491-497
- [31] Kondziolka D, McLaughlin MR, Kestle JR. Simple risk predictions for arteriovenous malformation hemorrhage. *Neurosurgery*. 1995;**37**:851
- [32] Brown RD Jr. Simple risk predictions for arteriovenous malformation hemorrhage. *Neurosurgery*. 2000;**46**:1024
- [33] Friedlander RM. Clinical practice. Arteriovenous malformations of the brain. *The New England Journal of Medicine*. 2007;**356**:2704

[34] Hafez A, Koroknay-Pál P, Oulasvirta E, Elseoud AA, Lawton MT, Niemelä M, et al. The application of the novel grading scale (Lawton-Young Grading System) to predict the outcome of brain arteriovenous malformation. *Neurosurgery*. 2019;**84**(2):529-536

[35] Ogilvy CS, Stieg PE, Awad I, et al. AHA Scientific Statement: Recommendations for the management of intracranial arteriovenous malformations: A statement for healthcare professionals from a special writing group of the Stroke Council, American Stroke Association. *Stroke*. 2001;**32**:1458

IntechOpen