

We are IntechOpen, the world's leading publisher of Open Access books Built by scientists, for scientists

4,800

Open access books available

122,000

International authors and editors

135M

Downloads

Our authors are among the

154

Countries delivered to

TOP 1%

most cited scientists

12.2%

Contributors from top 500 universities



WEB OF SCIENCE™

Selection of our books indexed in the Book Citation Index
in Web of Science™ Core Collection (BKCI)

Interested in publishing with us?
Contact book.department@intechopen.com

Numbers displayed above are based on latest data collected.
For more information visit www.intechopen.com



Chapter

HCC in Cirrhotic and Non-cirrhotic Liver: Timing to Surgery and Outcome - State of the Art

Stefania Brozzetti, Simone Bini, Chiara D'Alterio, Chiara De Lucia, Leonardo Luca Chiarella, Katia Fazzi and Michele Di Martino

Abstract

In this chapter we aim at presenting the state of the art in liver surgery. After a brief introduction about natural evolution of hepatocellular carcinoma (HCC) either in cirrhotic or non-cirrhotic patients, this manuscript will focus on planning and timing surgery: CT evaluation of the remnant liver; biopsy and ultrasonography (US) evaluation of liver disease; intraoperative US; surgical techniques, such as major and limited hepatectomies and two-stage hepatectomies, each of them in open or mini-invasive approach; and their possible complications. Follow-up and further interventions during expected recurrences will be highlighted. Our chapter will also treat topics such as patient's quality of life, importance of multidisciplinary evaluation and the role of surgeon in it.

Keywords: HCC, liver cirrhosis, liver surgery, open surgery, laparoscopic liver surgery, robotic liver surgery, HCC management, HCC follow up, staged hepatectomy, ALPSS

1. Introduction

Hepatocellular carcinoma (HCC) accounts for about 75–85% of primary liver malignancy. Being the most common histotype of liver cancer, it contributes significantly to global disease and mortality. Liver cancer ranks sixth for worldwide incidence and third for worldwide mortality. In Europe it ranks 14th for incidence and 8th for mortality [1]. In cirrhotic patients it remains one of the major causes of death [2, 3].

HCC incidence is worldwide heterogeneous because of the distribution of its main risk factors: hepatitis B, hepatitis C, alcoholic hepatitis, non-alcoholic fatty liver disease (NAFLD) and steatohepatitis (NASH) (**Table 1**) [4] chronic liver disease is the main background in which HCC arises (70–90% of all patients) [2]. It usually develops in cirrhotic liver, even if 10–20% of cases involve patients not yet cirrhotic [3]. These ones tend to receive a late diagnosis, due to the lack of symptomatology in early stage and/or inadequate surveillance [3].

Parameter	Mean incidence in cirrhotic liver	Mean incidence in non-cirrhotic liver
HBV	41.65%	30.60%
HCV	44.18%	14.36%
Alcoholic hepatitis	30%	21.77%
NAFLD-NASH	6.48% from a single study	6.45% from a single study

Desai et al. [3].

Table 1.
HCC incidence in cirrhotic and non-cirrhotic patients per risk factor.

Clinical evaluation and multidisciplinary approach are fundamental to submit patients to the most appropriate treatment. Assessment must consider patients' characteristics (general conditions, performance status, physiological age, life expectancy, treatment tolerability), HCC stage, oncological principles and liver status [4].

Several approaches, both surgical and non-surgical, are available for HCC treatment. Surgery is the first-line treatment in terms of overall survival and disease-free survival [5].

Surgical approaches include liver resections (LRs) and liver transplantation (LT).

LR is the gold standard in non-cirrhotic liver, whereas cirrhotic patients should be properly selected because of higher risk of complications [5].

LT allows radical tumor removal (R0) combined with the cure of underlying liver disease [6]. It is the treatment of choice in patients unsuitable for resective surgery that fall within the Milan criteria [5]. LT is indicated in patients ≤ 65 years (extended to 70 and 70+ patients, in some cases) [7] with severe cirrhosis (MELD > 15). According to the Milan criteria, patients should have a single nodule ≤ 5 cm or up to three nodules measuring ≤ 3 cm [8, 9], with no macroscopic vascular invasion nor extrahepatic metastases [5, 9]. After some years of experience, the Milan criteria were extended, developing up-to-seven criteria, in which patients are considered eligible for liver transplant when the sum of the size (in cm) of the largest tumor and the number of lesions is ≤ 7 , in the absence of microscopic vascular invasion [10]. Up-to-seven criteria should be used carefully because overall survival decreases as the number and size of tumor grows [11]. This principle is called "Metro ticket" [12]. Because of organs' low availability, lower recurrence risk patients shall be selected for transplantation in order to optimize organ allocation [12]. Resection and noninvasive therapies could be performed to control lesion progression during waiting period (bridging) or in order to downstage HCC [5, 6]. Liver function in waiting list is commonly evaluated through Child-Pugh (CTP), MELD and MELD-Na scores [13]. The latter is a good predictor of waitlist mortality in cirrhotic patients, so it shall be taken into account to improve organ allocation system [14]. Pretransplant mortality rate in liver malignancy accounts for about 10 deaths per 100 patient years of waiting [15].

Non-surgical approaches include percutaneous radiofrequency thermoablation (RFA), microwave thermoablation (MWA), drug-eluting bead transarterial chemoembolization (DEB-TACE), transarterial radioembolization (TARE), percutaneous ethanol injection (PEI), cryoablation and laser ablation (LA). Except from thermoablations, which are considered curative in small lesion (≤ 2 cm), non-surgical approaches are commonly palliative [16]. Elderly, very elderly and frail patients, either at presentation or in the case of recurrences, may benefit from these techniques in terms of survival and quality of life [4].

RFA and MWA are the most appropriate treatment in patients with BCLC 0 and A tumors not eligible for surgery [5, 17]. RFA induces coagulative necrosis in tumor

cells and in a “safety ring” of peritumoural tissue using frictional heat generated by high-frequency alternating current. Lesions adjacent to the vessels and biliary tree or in subcapsular positions could compromise RFA effectiveness and safety [5, 18, 19]. However, microwave ablation has been recognized as effective in this kind of lesions, due to damage concentration and less heat dispersion [17, 20]. MWA uses electromagnetic energy to induce a larger necrotic area than RFA thanks to faster heating and higher temperature [17]. Overall, RFA and MWA provide similar results in terms of local control and survival rates [17].

DEB-TACE induces tumor necrosis through intraarterial delivery of microspheres fulfilled with chemotherapeutic drug that may vary in size and chemotherapeutic agent to treat different types of HCC [21]. This technique profits from the presence of a singular artery feeding the tumor. TACE is a palliative treatment indicated in patients not eligible for surgery or percutaneous ablation, with tumor at stage BCLC B (Child-Pugh \leq B8; PS $<$ 2). HCC nodule $>$ 10 cm, macroscopic vascular invasion, extrahepatic disease, untreatable ascites, jaundice and kidney dysfunction strongly contraindicate TACE [4, 5]. Potential adverse effects are liver enzyme abnormalities (18.1%), fever (17.2%), hematological/bone marrow toxicity (13.5%), pain (11%), vomiting (6%) and even death (0.6%) for liver failure [5].

RFA can be used as a complementary technique with TACE, to treat residual neoplastic tissue [22]. Patients with bigger nodules ($>$ 3 cm) and with capillary vascularization receive higher benefit from this combination [5, 23].

TARE is also called selective internal radiation therapy (SIRT). It is a palliative brachytherapy that uses radioactive substances (Y^{90} -microspheres) injected into tumor-feeding arteries. This complex procedure is indicated in patients with conserved liver function (Child-Pugh \leq 8, bilirubin \leq 2.0 mg/dl, no ascites) and locally advanced HCC, not eligible for surgery or TACE (portal system invasion or unencapsulated large lesions). Pulmonary shunt and other vascular anomalies contraindicate to this technique [4, 5].

PEI induces tumor cell necrosis through dehydration, protein denaturation and small tumor vessel disruption. It is indicated in patients not eligible neither for resection nor for other forms of ablation, especially in HCC nodules \leq 3 cm in the hepatic hilum area. The application of this procedure is restricted because it allows only an incomplete necrosis in lesions $>$ 3 cm and leads to high recurrence rate [5, 24].

Cryoablation induces tumor cell necrosis using recurring applications of freezing temperature. Despite its good efficacy, this procedure is barely used because it is associated with high risk of life-threatening complications such as cryoshock, cold injury to adjacent organs and massive bleeding [25].

LA induces tissue necrosis through conversion of absorbed light (usually infrared) into heat. It can be used to treat up to five lesions, measuring \leq 5 cm, located in the deep parenchyma and distant from the vessels, biliary ducts, bowel or diaphragm, when patients are not eligible for resection [26]. It is rarely used because of difficulties in the technique's management [5].

Surgical and non-surgical treatments, and the possibility of combined approach, should be carefully evaluated aiming for a tailored therapy.

Follow-up is fundamental in HCC patients, both in cirrhotic and non-cirrhotic ones, in order to promptly identify possible recurrences and to treat them in the best way. Intrahepatic recurrences, far from previously treated lesions, are always possible and generated by chronic hepatopathy; therefore, lifelong surveillance is necessary [4, 27].

The aim of this chapter is to illustrate the state of the art in liver surgery to achieve the best treatment for patients suffering from hepatocellular carcinoma.

2. Planning and timing surgery

2.1 Multidisciplinary evaluation

The multidisciplinary unit is a highly specialized and dedicated team, composed of hepatobiliary and transplants surgeons, hepatologists, radiologists, pathologists, oncologists, interventional radiologists and supportive care specialists (**Figure 1**) [28]. The aim of the unit is to discuss complex patients, developing the best possible care plan for every different case. First of all, liver status and disease shall always be evaluated and taken into account, assessing them according to Child-Pugh (CTP), MELD or MELD-Na scores [5, 14, 29]. CTP score seems to have a higher specificity than MELD in patients undergoing resective surgery (**Table 2**) [13]. Other important factors are preoperative platelet count, INR and hepatic venous pressure gradient (HVPG) [5, 30]. Cirrhotic patients eligible for hepatic resection should have ideally HVPG < 10 mmHg and platelet count $\geq 100,000/\text{ml}$ [5].

In addition to Child-Pugh and MELD scores, in borderline liver function, indocyanine green kinetics and cholinesterase/bilirubin ratio are useful to improve patients selection [5].

Thanks to multidisciplinary discussions in international meetings, many HCC staging systems have been proposed during the years [31]. The Cancer of the Liver Italian Program (CLIP) score and Barcelona Clinic Liver Cancer (BCLC) staging classification are the most comprehensive and commonly used systems to stage HCC patients. They consider the liver status and function, physical status, cancer-related symptoms and number and extension of lesions. Patients are classified in six stages (CLIP score) or five stages (BCLC), each linked with a specific survival rate and treatment algorithm (**Table 3, Figure 2**) [32].

According to BCLC criteria, liver resection is indicated in BCLC stage A patients only, but several studies show that it could provide long-term survival with reduced intraoperative mortality in selected BCLC stage B patients (**Figure 3**) [33–36]. Patients having singular large nodule (>5 cm) and/or lateralized multinodular tumor and a very well-preserved liver function are considered

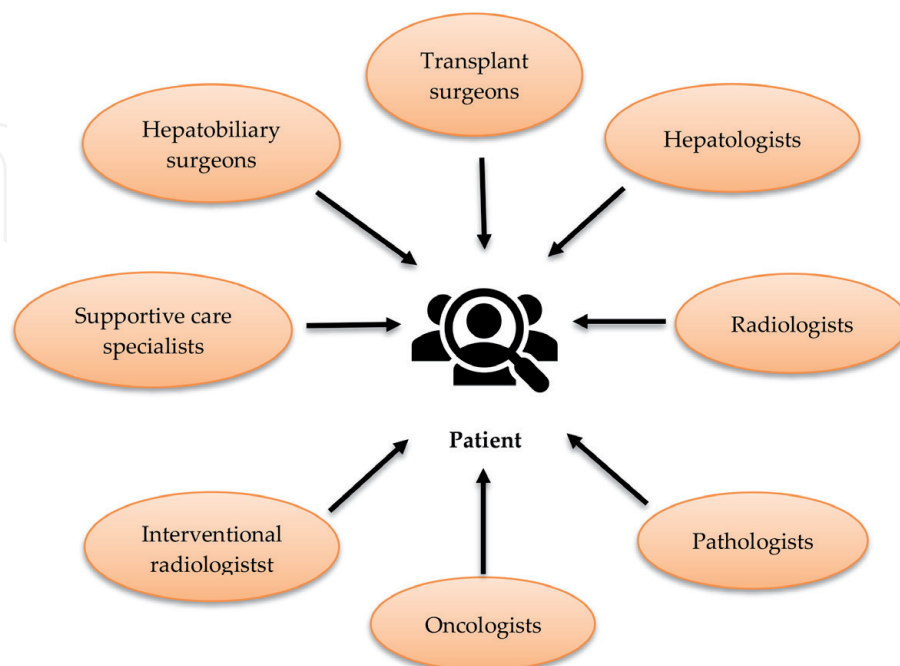


Figure 1. Composition of liver multidisciplinary units. Source: Siddique et al. [28].

Child-Pugh score Parameters	Points		
	1	2	3
Serum bilirubin (mg/dl)	2.0	2-3	>3.0
Serum albumin (g/dl)	>3.5	2.8-3.5	<2.8
Prothrombin time Seconds prolonged	1-4	4-6	>6
Hepatic encephalopathy	None	Mild to moderate (grade 1 or 2)	Severe (grade 3 or 4)
Ascites	None	Mild to moderate (diuretic responsive)	Severe (grade 3 or 4)
5-6 points Child-Pugh A			
7-9 points Child-Pugh B			
10-15 points Child-Pugh C			

Table 2.
 Child-Pugh scoring system.

resectable stage B patients [38]. In order to achieve a parenchyma-sparing surgery, these patients may benefit from combining surgery with intraoperative ablation (RF/MW) [39, 40].

2.2 US evaluation of liver disease

Ultrasonography (US) has a primary role in HCC screening. US sensitivity ranges from 63 (for small lesions) to 94%, whereas specificity from 52 to 98% [41–43].

US is highly operator-dependent. Machine quality, tumor size and localization, liver echotexture and abdomen characteristic influence the diagnostic accuracy of the exam [44].

Six-month US is relevant in detecting early-stage HCC in high-risk patients [45]. US detection of small HCC nodules in cirrhotic livers is arduous due to altered echotexture [46].

If combined with serum marker alpha-fetoprotein (AFP), it allows further unidentified lesions' detection in 6–8% of the cases [47]. AFP alone is a weak screening test (Se 39–64%, Sp 76–91%, cut-off 20 mg/ml) [41], since high AFP levels could be also related to inflammatory status (exacerbation of underlying chronic liver disease or hepatitis), and it is not increased in about 20% of HCC

CLIP score Parameters	Points		
	0	1	2
Tumor morphology	Uninodular and extension ≤ 50%	Multinodular and extension ≤ 50%	Massive or extension > 50%
Child-Pugh score	A	B	C
Alpha-fetoprotein	<400 ng/ml	≥400 ng/ml	—
Portal vein thrombosis	Absent	Present	—

Maida et al. [31].

Table 3.
 CLIP score evaluation system.

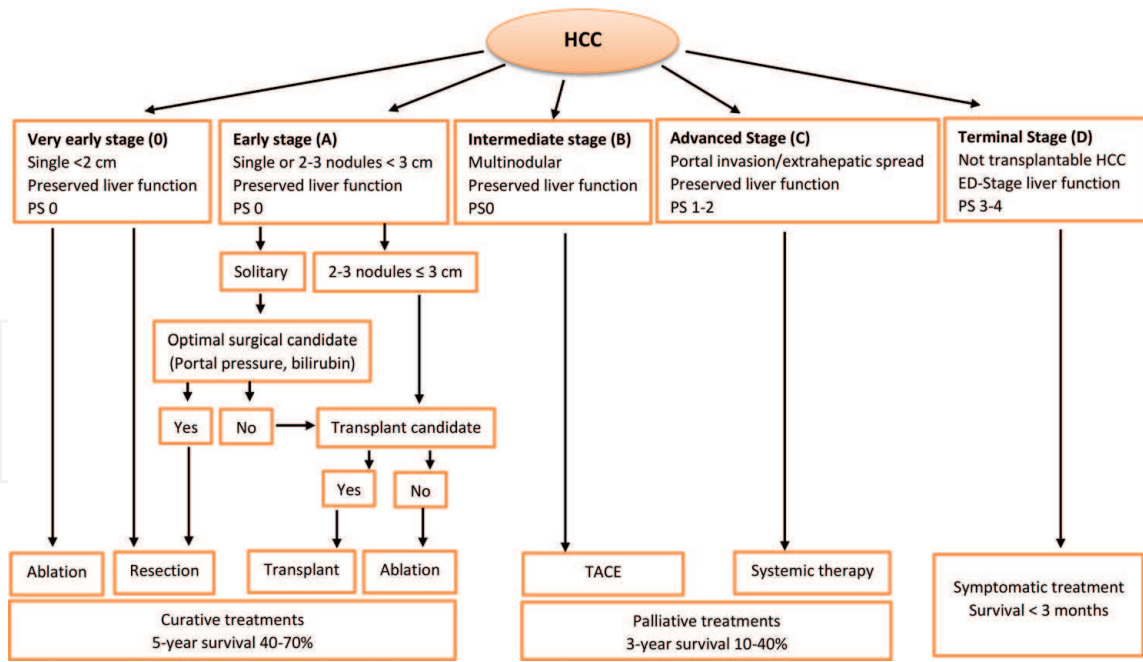


Figure 2.
BCLC staging. Galle et al. [5].

cases, especially in early stages [41]. PIVKA-II is another serum marker still under evaluation in combination with US for screening purposes, even if not enough evidences have been published yet to justify its use [48].

US is useful to evaluate liver status while planning treatment and to identify possible contraindication to surgery, such as portal vein thrombosis [5].

Contrast-enhanced ultrasound (CEUS) uses gas microbubbles as a contrast agent that highlights lesions with well-represented vasculature. Due to pulmonary clearance, it is suitable for patients with reduced renal function or renal failure. It is repeatable, noninvasive and without risks [49].

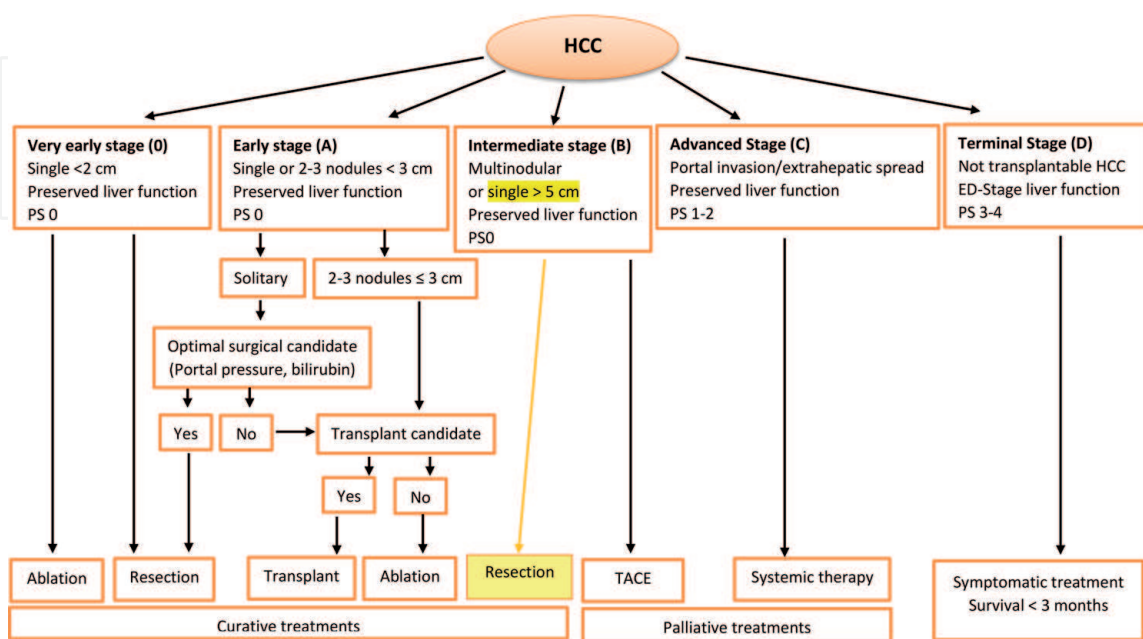


Figure 3.
Modified indications in BCLC staging. Source: Torzilli et al. [35] and Bolondi et al. [37].

Differently from US, CEUS is not indicated for screening but for characterizing known nodules. HCC is characterized by arterial-phase enhancement and low and later wash-out (after at least 60 seconds) on CEUS [50, 51]. It may differentiate HCC from other nodules in cirrhotic liver and distinguish neoplastic portal vein thrombosis from a benign one [49]. However CEUS does not detect small (<20 mm) and deep-located lesions, and it hardly discriminates between HCC and cholangiocarcinoma (CCC) [5, 45].

CEUS alone is not enough neither for diagnosis nor for staging of HCC, so it shall be considered as a second-line method in patients unfit either for contrast CT (due to chronic kidney disease) or MRI (due to possible vascular metallic devices or claustrophobia) [50].

2.3 CT evaluation

CT is a second-line imaging technique that enables a high diagnostic accuracy, if proper technique and contrast administration are applied. The CT appearance of HCC is extremely variable and depends on growth pattern (solitary, multifocal masses of infiltrating neoplasm), size and histologic composition [52].

Hepatocellular carcinoma (HCC) is most often hypoattenuating on unenhanced scan. After contrast agent injection, HCC is typically hypervascular during the arterial phase: small lesions show more homogeneous enhancement than larger neoplasms that are heterogeneous. During the portal venous phase, HCC becomes iso- to hypoattenuating to the surrounding liver. On delayed phase the tumors wash out more rapidly than the hepatic parenchyma [45].

Based on the guidelines, these diagnostic criteria are sufficient for a noninvasive diagnosis of HCC [5].

HCC could also present atypical findings such as hypervascular lesion without wash-out or hypovascular tumor: hypovascular nodules are not uncommon, and they usually represent early stages like dysplastic nodules with focal HCC or well-differentiated small HCCs [53].

Perfusion CT (PCT) allows quantitative evaluation of tumor-related angiogenesis, tissue perfusion and segmental hepatic function. Higher radiation dose and lower resolution are the main limitations of this method [45].

CT with higher spatial resolution is fundamental in preoperative management: firstly, in detection of vascular or bile ducts anatomical variants and also in calculation of the future remnant liver (FRL) if a major resection is considered [54].

Evaluation of anatomical variation is critic while planning hepatic resections. Hepatic arterial anatomy variations are common (approximately 45%), and different hepatic venous anomalies, such as drainage of segment VIII into the middle hepatic vein, of segments V and VI directly into the inferior vena cava and of accessory middle hepatic vein directly into the inferior vena cava, can impact surgery. Also portal vein variants and biliary anatomy variations should be carefully investigated [55].

The FRL is calculated by dedicated software that analysed the total liver volume, the tumour volume and the liver volume after surgical procedure. The FRL volume of 20–30% is the lowest limit for a safe resection in healthy livers, 40% in elderly, whereas in patients with diffuse liver disease, a volumetric evaluation shall be associated with FRL function assessment (e.g. indocyanine green retention test or liver maximum capacity test) [54, 56, 57].

2.4 MRI

MRI is superior to CT for the diagnosis of HCC [53].

At MR imaging small HCCs have variable signal intensity on T1-weighted pre-contrast imaging: they commonly appear hypointense, but high signal intensity has been reported with a frequency ranging between 34 and 61%. On T2-weighted images, HCC is iso- to hyperintense to the surrounding liver parenchyma. Generally, hyperintense lesions on T1 and isointense in T2 are well-differentiated, due to the presence of fat and or glycoprotein; on the contrary lesions hypointense on T1 and hyper on T2 are moderately/poorly differentiated. After contrast agent injection, HCC shows the same imaging patterns described on CT examination [45, 58].

The introduction in clinical practice of liver-specific contrast agents, superparamagnetic as well as paramagnetic, significantly improves the detection and characterization of HCC, in particular for lesions between 1 and 2 cm. With paramagnetic contrast agents, the absence of functional hepatocytes, which is considered a sign of malignancy, is represented as a loss of signal intensity during the hepatobiliary phase. Nevertheless, fewer than 20% of well-differentiated and moderately differentiated HCCs appear iso- or hyperintense on hepatobiliary phase images [45, 58].

HCC can rarely invade biliary ducts, both microscopically and macroscopically [59]. Incidence of biliary duct invasion ranges from 1.2 to 9%. It shall be carefully evaluated while staging patients, in order to choose the best treatment and to assess prognosis. Biliary invasion, in fact, is an independent adverse prognostic factor and is often linked to higher biological aggressiveness and portal vein invasion which make prognosis worse [60].

MR cholangiopancreatography (MRCP) is a noninvasive procedure aimed for evaluating the hepatobiliary and pancreatic systems. This method is helpful in assessing biliary invasion. Biliary duct tumor thrombus appears as an intraluminal soft tissue with arterial-phase enhancement on MRCP, and biliary ducts could be seen dilated because of obstructing tumor fragments [60].

Several studies have shown that biliary ducts invasion in HCC is not a contraindication to surgical resection, even in patients with obstructive jaundice caused by biliary tumor thrombus, as long as R0 resection can be achieved. If jaundice is present, biliary drainage should be performed preoperatively [59, 61–63].

MRI also enables the estimation of fat storage in the liver parenchyma: proton density fat fraction (PDFF) technique is a fast, accurate and easy-to-use MR modality that allows liver fat quantification [52].

2.5 Bioptic evaluation

Biopsy of hepatic lesions is an invasive procedure. Its use is restricted, as a typical pattern in one second-line imaging technique is enough to make an HCC diagnosis, according to the guidelines [64]. In performing liver biopsy, indeed, there is a high risk of bleeding, even higher if the patient has a bleeding disorder due to cirrhosis, and an established possibility of seeding along the needle tract. However, haemorrhagic risk can be reduced with infusion of fresh frozen plasma and platelets before the procedure [51]. Subcapsular and extended tumor and ascites could compromise safe needle insertion too [46].

The procedure allows histological analysis, so it may be used when HCC has atypical growing pattern, so that there is a high suspicion of cholangiocarcinoma (CCC), considering that in such cases bioptic results will impact on therapeutic choice, changing it completely [51].

Furthermore liver parenchyma biopsy is currently the reference procedure for assessing and staging fibrosis and cirrhosis. Stages are classified according to METAVIR score, a histopathologic grading system. Hepatic biopsy has some important limitations: it allows the evaluation of a sample, and not of the entire liver, and, above all, it is an invasive method that could cause minor (temporary pain in 20%

of cases) or major (bleeding, sepsis, pneumothorax and even death in 1.1% of cases) complications [65].

2.6 Intraoperative US

Intraoperative ultrasonography (IOUS) is fundamental while performing hepatic resections. It can give further information about lesions and parenchyma and can determine modifications both in tumor staging and in surgical management as well [66].

IOUS and contrast-enhanced intraoperative ultrasound (CE-IOUS) have higher sensitivity compared to preoperative US and CEUS and allow better detection and characterization of small nodules [66].

Without these intraoperative procedures, surgical inspection and palpation can overlook up to 50% of preoperatively undetected lesions, especially those located in deep parenchyma and in cirrhotic liver [67].

Furthermore, IOUS became a mandatory tool in major hepatic surgery, as it allows visualizing of major vessels, assessing their location in relation to HCC lesion and delimiting resection area. It is also important to identify correct dissection planes and accurately define tumor extension, thus to achieve higher rates of R0 resections [67].

3. Surgical treatment

Surgical resection is the first-line treatment in non-cirrhotic and compensated cirrhotic livers [5]. The aim of surgery is to achieve R0 resection while preserving enough future remnant liver, in order to avoid postoperative liver failure [68]. Therefore, the most appropriate surgical technique is chosen according to principles of oncological radicality, safety and the least invasiveness [69], considering that HCC tends to be a recurrent disease (recurrence rate 40–70%), and so re-resection or noninvasive treatments are often needed [70].

Large nodules, major intrahepatic vessels invasion, portal branches and hepatic vein thrombosis do not contraindicate to surgery as soon as R0 resection can be achieved [71], keeping in mind that a well-preserved liver function is necessary to perform radical hepatic resections [72]. Surgery can be even performed in case of HCV and HBV hepatitis as long as there is metabolic syndrome-related hepatopathy or cirrhosis is compensated. (Child-Pugh ≤ 8 ; MELD ≤ 9) [73].

Patient performance status is also a factor that has to be considered while planning a surgical resection of the liver. Advanced age is not a contraindication, as long as these patients are carefully selected, according to their general condition, performance status, life expectancy and treatment tolerability [56].

In some cases, surgery may be a *bridging* treatment to liver transplant in patients with advanced cirrhosis and HCC, when waiting time exceeds 6–8 months [74].

Impaired liver function, insufficient future remnant liver, advanced tumor stage and poor performance status are absolute contraindications to surgical resection [73]. Liver resection could not be performed in the case of Child-Pugh > 8 , MELD ≥ 9 , bilirubin ≥ 3 mg/dl associated with INR ≥ 1.7 or PT $< 50\%$, platelet count $< 50,000/\mu\text{l}$, indocyanine green retention at 15 minutes $> 22\%$ and portal vein pressure gradient > 10 mmHg without possible TIPS [72, 73]. Extended portal or vena caval thrombosis and extrahepatic disease reveal an advanced HCC stage and contraindicate surgical resection [73]. Patients not eligible for surgery are those with ECOG performance status 4, ASA index > 3 , Charlson's index $> 3-4$ and older than 70 years with comprehensive geriatric assessment (CGA) = 3 or systemic diseases with severe prognosis (life expectancy < 12 months) [56].

Intrahepatic recurrence after surgical treatment is often linked to portal venous invasion, both macroscopic (MPVI) and microscopic (mPVI). MPVI can be preoperatively detected by CT, MRI and US, whereas mPVI is very difficult to diagnose preoperatively. In order to reduce recurrence rates due to mPVI, in young and fit patients, anatomic liver resection (ALR) should be preferred to nonanatomic liver resection (NALR) [75]. ALR should be taken into account especially in patients who have solitary PVI (in a single portal vein branch) or a higher risk of mPVI linked to α -fetoprotein ≥ 20 ng/ml, PIVKA-II ≥ 100 mAU/ml, tumor size ≥ 5 cm and a confluent lesion morphology [76, 77]. Some authors suggest that during anatomic resection, it is better to avoid excessive rotation of the liver, perform an early extrahepatic ligation of the portal pedicle of the resected segment(s) before parenchymal transection and obtain an adequate surgical margin to decrease the risk of recurrences [71].

On the other hand, NALR allows *parenchyma-sparing* surgery that, though associated to higher recurrence rates, is indicated in elderly and cirrhotic patients suffering from early HCC, where an anatomic resection would sacrifice an excessive amount of the parenchyma (**Figure 4**) [75].

Surgery is proved to be superior to RF in terms of local recurrences for nodules >2 cm [19, 78], but in the case of multinodular HCC, in selected patients, they can be combined together to achieve a better outcome, compared to TACE or TARE, whose role remains palliative (**Figure 5**) [35, 64, 78].

3.1 Major hepatectomies

All liver resections involving three or more liver segments of Couinaud are considered major hepatectomies. Most commonly performed resections are right hepatectomy, left hepatectomy, right-extended hepatectomy, left-extended hepatectomy and median hepatectomy [69]. Major hepatectomy is frequently required to achieve a complete tumor removal (**Figure 6**) [79].

Healthy livers may be resected as much as 70% without major complications; cirrhotic or hepatopathic patients shall be cautiously submitted to resection after precise FRL analysis in terms of future remnant liver function (FRLF) and volume [54]. Liver resections for HCC related to NAFLD and metabolic syndrome are encumbered by important rates of complications (13–20%) and mortality (2%); procedure risk profile in this condition is closer to that burdening cirrhotic livers rather than non-cirrhotic ones [5].

Age is not a contraindication to major hepatectomy, because elderly patients' liver, when healthy, have comparable regeneration rates to younger ones, while patients' performance status and liver residual function are more important [80].

Major hepatectomies can be performed safely in either open or mini-invasive approaches [81].

Open approach is more invasive, but it offers great advantages in a better view on the operative field, allowing a complete administration in organ mobilization and a prompt control of bleeding (**Figure 7**). Open approach is indicated in the case of upper abdominal adhesions, respiratory impairment and advanced liver fibrosis. In severe respiratory disease, pneumoperitoneum worsens gas exchange; therefore, laparoscopic- and robot-assisted resection are contraindicated [82]. In the case of upper abdominal adhesions, it is hard to induce an adequate pneumoperitoneum to insert trocars and instrument safely, and open approach is the one indicated [83]. Advanced liver fibrosis makes the organ stiffer and difficult to mobilize with laparoscopic graspers [84]. The *liver hanging manoeuvre (LHM)*, which is a technique of passing a tape along the retrohepatic avascular space and suspending the liver during parenchymal transection, facilitates anterior approach of major hepatectomy and minimizes bleeding by elevation of the liver along its deeper parenchymal plane [85, 86].

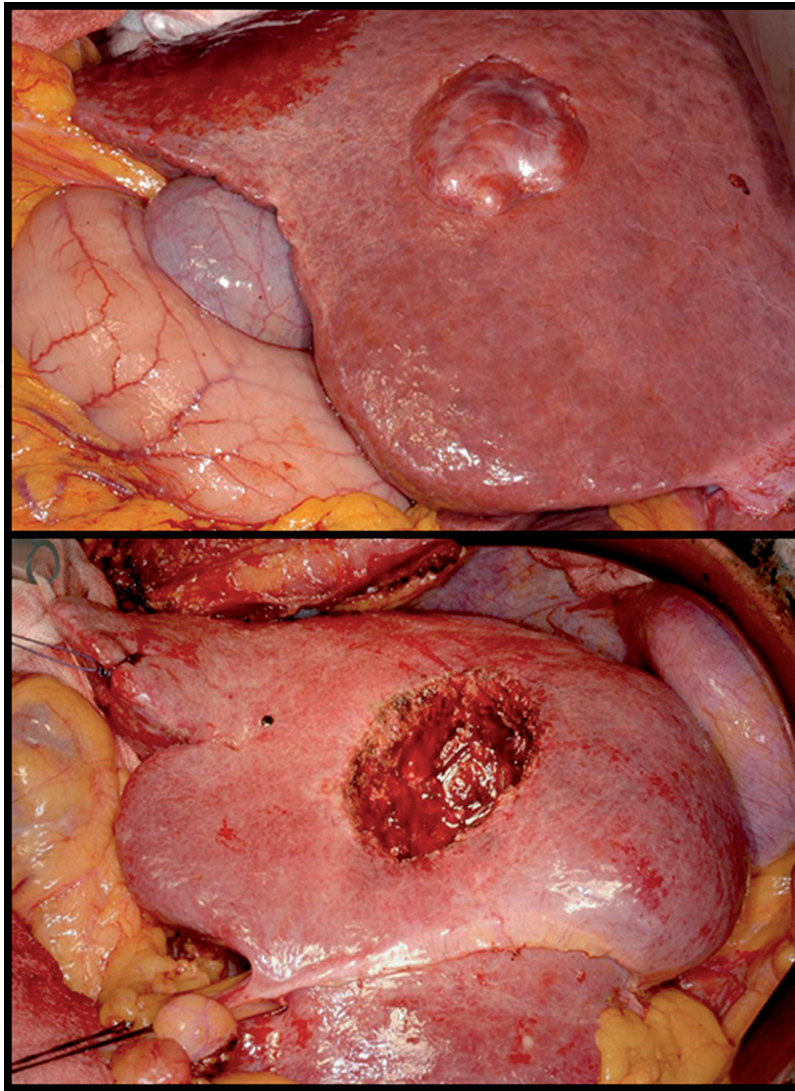


Figure 4.
Wedge resection (NALR) in the NAFLD liver. HHC located in V/VIII segment.

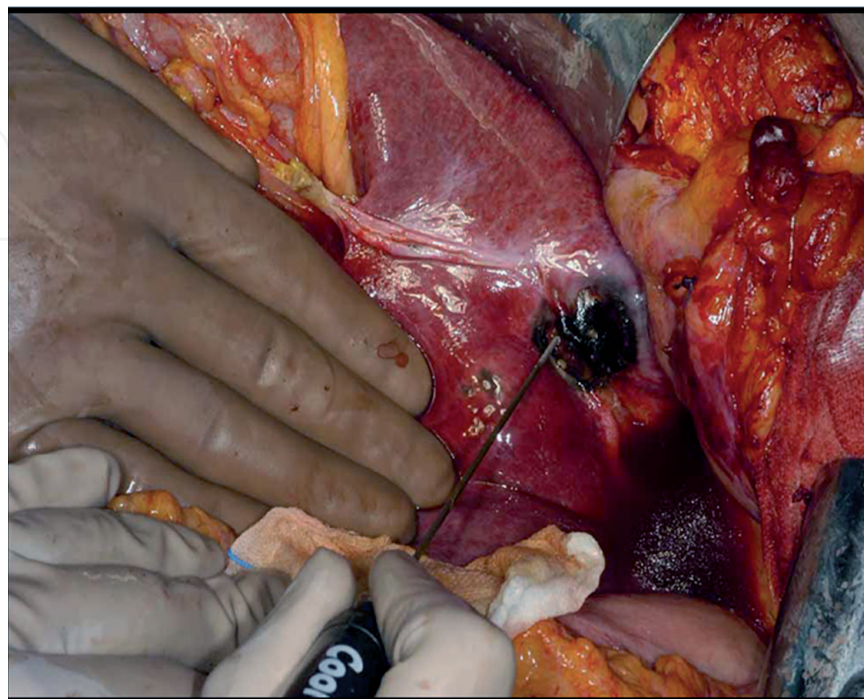


Figure 5.
Intraoperative RF in HCC nodule of II segment.

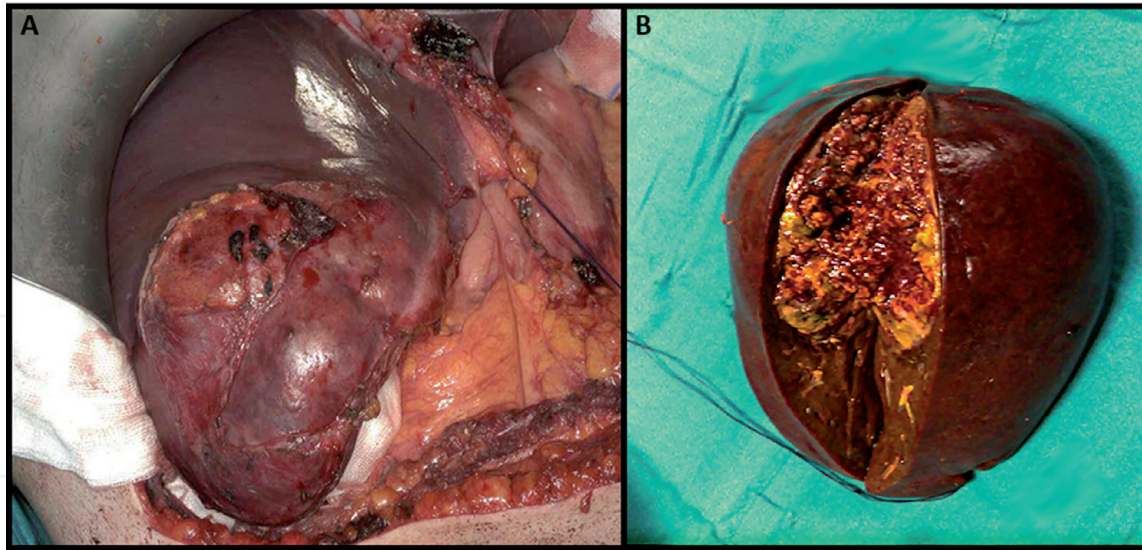


Figure 6. (A) Large HCC in non-cirrhotic liver requiring right hepatectomy. (B) Extended right hepatectomy in NAFLD, surgical sample showing a 11-cm HCC.

Minimally invasive liver surgery has strongly progressed during the last 20 years [87].

Laparoscopic approach is proven as being safe and presents good outcomes in terms of hospitalization and morbidity. However, the main disadvantage of this approach is the lack of control when a huge bleeding occurs, but the LHM reducing bleeding risk makes the procedure safer.

Robotic-assisted resection is the newest technology in hepatobiliary surgery. Compared to laparoscopy, robotic instruments allow wide-angle rotation; therefore, it is easier and faster to perform sutures and ligatures. Four-arm *da Vinci Si* enables the surgeon to perform safer resections, reduced bleeding and major dexterity, particularly in hilar time and in vena cava detachment time. One of the major disadvantages of the robot is its cost [88, 89].

HCC is a fast-spreading tumor, particularly in the vascular system; therefore, major resections in large or multinodular tumors allow the most radical removal; however, consistent volume of the functioning liver is also resected, increasing risks of liver impairment in cirrhotic and hepatopathic patients [90].

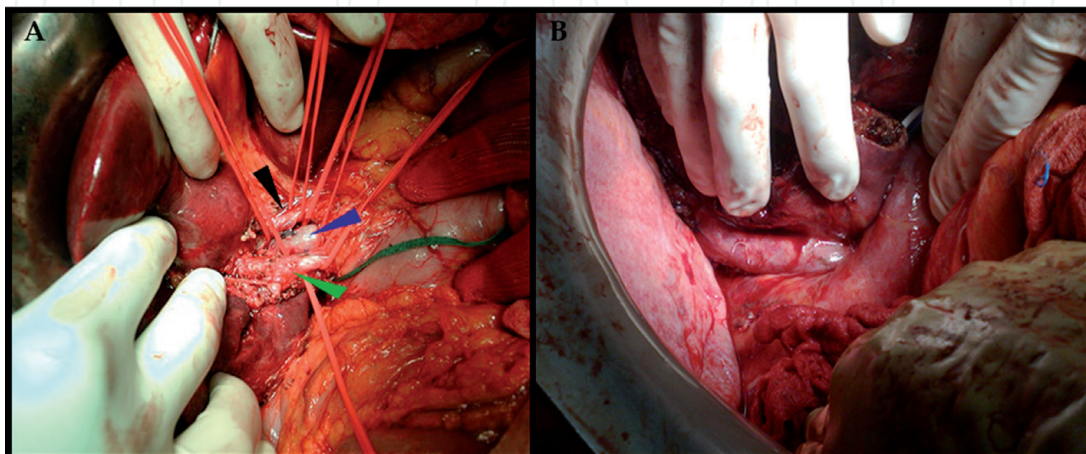


Figure 7. (A) Dissection of liver hilum. Elements are indicated by arrows: choledocus (green), portal vein (blue), hepatic artery (black). (B) Caval detachment in bisegmentectomy (VI-VII).

3.2 Limited hepatectomies

Limited hepatectomy means resection of two or less segments of Couinaud, like left lobectomy, involving segments II and III, and bisegmentectomy of VI–VII and VI–V, that are the most common (**Figure 8**). Limited hepatectomies are indicated in the case of single or multiple HCC nodules located in one or two adjacent liver segments [69], especially when early diagnosed. Otherwise non-followed up patients are often diagnosed with advanced or multinodular HCC, which are eligible to more extended hepatectomies only.

Limited hepatectomies tend to preserve liver function, so analysis of FRLF and FRLV is often unnecessary in healthy patients, while it is mandatory in compensated cirrhosis due to higher resection risk and distorted liver anatomy [73].

Limited resection is often performed with mini-invasive surgical technique, such as laparoscopic- or robot-assisted surgery. Although expert surgeons are able to resect safely even posterior and subdiaphragmatic lesions, these techniques have some limits. Laparoscopy, in fact, has prolonged surgical times for liver mobilization due to difficulties in parenchyma manipulation, arduous bleeding control and necessity of a major experience of the surgeon.

Robotic liver resection (RLR) allows to go beyond laparoscopic disadvantages, thanks to superior flexibility of its arms. For this reason, RLRs are considered safe, even in deep parenchyma or posterior segment [89]. It is comparable to open approach considering the oncological radicality, but it presents the same advantages of laparoscopy in terms of length of hospital stay and postoperative complications. Conversion rate from robotic to open approach ranges from 0 to 8.8% [87].

Open surgery shall be chosen in the case of contraindications to other approaches such as respiratory impairment that is worsened by pneumoperitoneum or excessive difficulties in liver manipulation; the surgeon's experience remains an important variable in surgical indications, and safety of intervention shall always drive the choice [82, 84].

Nonanatomic liver resection, or wedge resection, is reserved for early HCC (BCLC 0 or A), particularly in the elderly, suffering from advanced cirrhosis or exophytic lesions in hypertrophic segments, where anatomic resection would determine too extensive healthy parenchyma loss [75].

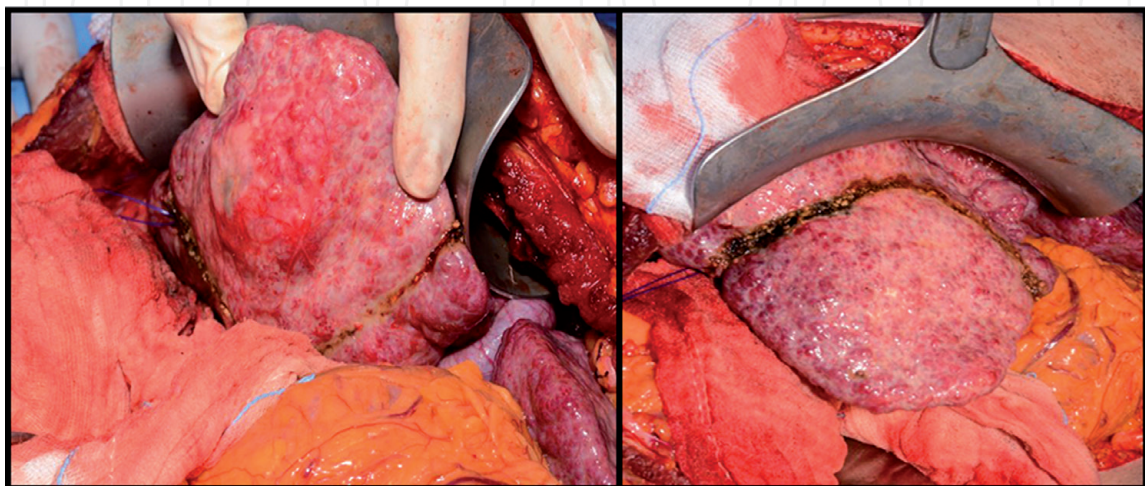


Figure 8.
Anatomic resection of segment VI in cirrhotic live. HCC diameter 2.5 cm.

3.3 Staged hepatectomies

Staged hepatectomies in HCC treatment are the most recent innovation, first introduced to treat multiple colorectal metastases, now under evaluation for extended hepatectomies in advanced HCC patients [91]. The main issue related to this technique is that most HCC patients are cirrhotic or hepatopathics, and cirrhosis limits parenchyma regeneration in a significant way [91, 92].

Extended resection is feasible when the future remnant liver is $\geq 40\%$ for cirrhotic patients, $\geq 30\%$ in patients with severe steatosis or fibrosis without cirrhosis and $\geq 20\%$ in those with normal liver function [93].

Several strategies can be carried out in order to increase future remnant liver volume (FRLV), improve resectability and reduce postoperative risk of liver failure (PLF) in patients with inadequate FRLV. These techniques include preoperative portal vein embolization (PVE) or ligation (PVL), sequential transarterial chemoembolization and PVE, two-stage hepatectomy (TSH), preoperative Yttrium-90 (^{90}Y) radioembolization (RE) and associated liver partition and portal vein ligation for staged hepatectomy (ALPPS) [93]. Parenchyma hypertrophy shall be assessed using CT volumetry before performing second-stage hepatectomy [94].

ALPPS is indicated in non-cirrhotic patients with insufficient remnant liver or in the case of PVE failure [93, 95, 96]. This procedure allows higher and faster hypertrophy rates compared to other strategies, due to parenchyma transection and collateral portal branches ligation, especially in hepatopathics; such advantages have been seen also in cirrhotic patients [92]. Moreover, it reduces risk of HCC progression thanks to the shorter time interval between operations. On the other hand, it is associated with high risk of PLF (27%) probably due to portal hyperperfusion, major perioperative complications and mortality [97]. Some authors suggest that the use of anterior approach combined with hanging manoeuvre allows higher control and safety during ALPPS procedure [92]. Only few case series have been published about staged hepatectomy for HCC, more perspective research is still necessary, even if this technique is proving effective and beneficial in selected patients [98].

3.4 Complication

Postoperative complications have higher incidence and severity in cirrhotic patients [99].

Postoperative liver failure (PLF) is the most life-threatening complication following hepatic resection, especially in cirrhotics [93]. It is defined as the decrease in liver synthetic, excretory and/or detoxifying functions after resection [100]. It can be associated with insufficient future liver volume, prolonged operative time, prolonged ischemia, massive intra- and postoperative bleeding, hemodynamic instability, bile duct obstruction, drug-induced injury, viral reactivation and sepsis [90]. It occurs after the fifth day in 4–19% of cases, and it is characterized by various symptoms and signs, such as ascites, pleural effusion, prolonged cholestasis, coagulation disorders, elevated serum lactate levels, hyperbilirubinemia, hypoalbuminemia, hypoglycaemia and hepatic encephalopathy [90, 93].

Bile leakage is another severe postoperative complication. It occurs in 4–17% of cases with comparable incidences in laparoscopic and open approaches [101]. It can induce further complications, such as extrahepatic abscess, requiring reoperation; otherwise it is usually managed with interventional radiology [100].

Postoperative ascites is common, and it may be caused by portal flow resistance increase and serum albumin loss. It can be treated with diuretics, sodium restriction or albumin infusion [100]. Persistent ascites is associated to higher risks of spontaneous bacterial peritonitis (SBP) and mortality.

Clotting disorders are frequent after extended hepatectomies and in cirrhotic patients, who may already have preoperative low platelet count. They can manifest as PT and aPTT prolongation, increase in levels of fibrinogen degradation products and platelet levels reduction [100].

Surgical site infection may occur within 30 days after resection [100].

Postoperative pneumonia and respiratory disturbs (acute lung injury, acute respiratory distress syndrome) rarely occur after liver resection, especially in the elderly [100].

Resected patients shall be rapidly mobilized postoperatively; feeding shall start early, together with intravenous liquid restriction. Nonadequately selected patients may also suffer from postoperative acute renal failure or hepatorenal syndrome [100].

Mini-invasive surgical approaches allow lower postoperative complications, such as ascites, pleural effusion and hospital-acquired infections [87, 99, 102].

4. Follow-up

HCC recurrence within 5 years after hepatic resection occurs in 40–70% of patients [70, 103, 104]. Several recurrence risk factors should be carefully considered while planning postoperative surveillance (**Table 4**) [70].

Intrahepatic recurrent HCC can develop from an intrahepatic metastasis (IM type) or arise from de novo multicentric carcinogenesis (MO type) due to the underlying chronic liver disease. These two HCC types can be distinguished according to their clinic-pathological characteristics and recurrence-free interval [70].

Early recurrence occurs within 2 years from primary resection, and they seem associated with intrahepatic metastasis, whereas late recurrences can show up more than 2 years after surgery, and they are linked to multicentric occurrence [105].

Differentiating them is important because MO, compared to IM, is associated with higher survival rate after repeated resection and better prognosis [106].

RHCCs have the same imaging features of primary HCC, so they shall be detected and diagnosed using the same methods of primary HCC diagnosis.

US, CT or MRI and AFP determination should be performed after surgical resection.

Surgical factors	Non-anatomical resection Positive histologic margin (R1 or R2) Necessity of transfusion due to significant bleeding Iatrogenic tumor escape or rupture
Clinicopathological factors	Low tumor differentiation Advanced tumor stage Tumor rupture, damaged capsule Tumor diameter > 5 cm Tumor number ≥ 3 Vascular tumor thrombus Lymph node invasion Adjacent organ invasion satellite lesion High level of AFP before operation Increased AFP level 2 months after operation
Patient's factor	Underlying chronic liver disease: active hepatitis infection or cirrhosis

Wen et al. [70].

Table 4.
 Risk factors of postoperative recurrence.

US should be performed every 6 months within the first 5 years after surgical treatment; a second level imaging study is requested at the first year and repeated after 12–18 months according to the underlying liver status [5]. Resected patients for HCC, who received direct-acting antiviral (DAA) therapy for HCV negativization, are commonly kept in a less intensive follow-up with US every 12–18 months, for a persistent recurrence risk is maintained [107].

Once detected, RHCC shall be carefully assessed in order to plan the best therapy. Re-resection is the treatment of choice if nodule is resectable and patient is eligible for surgery; so, disease-free time, performance status, future remnant liver volume and function, cirrhosis, portal hypertension and other aspects should be evaluated again before repeating operation. Only about 20% of patients with recurrent HCC receive surgical treatment [105]. Multiple resections could be performed after major or limited primary hepatectomy [70, 108].

Both open and laparoscopic resections can be carried out, but laparotomy is generally preferred, since intra-abdominal adhesions limit laparoscopic approach [109]. Five-year survival rate higher than 70% can be achieved in well-selected patients, despite repeated treatments [103, 104].

Prognosis after repeated resections is linked to clinic-pathological characteristics of primary HCC and recurrence interval. Particularly a disease-free period longer than 1 year after primary resection, single primary HCC and negative portal invasion are positive prognostic factors after second resection [105, 108].

Other possible locoregional therapies for recurrent illness are RFA, MWA and TACE. Liver transplantation could be taken into account in selected patients with worsened liver function and falling within transplant criteria [70, 103].

Incidence of extrahepatic metastases (EHM) after hepatectomy is low (range 5–20%) [108, 110]. High-serum alpha-fetoprotein levels, after liver resection or transplant, is suspicious for extrahepatic recurrence; thus serial cross-sectional total body imaging is mandatory to identify them, and palliative R0 resection may be performed in fit patients with quality of life and survival benefits [27].

5. Conclusion

HCC is a deadly malignancy either in cirrhotic and non-cirrhotic patients. A well-timed follow-up and detection of patients at risk are fundamental, since diagnosis at early stage allows more aggressive and effective treatments. HCC in non-cirrhotic liver will be more often diagnosed, particularly in the case of NASH and NAFLD, because they are followed up more strictly.

In recent years, indications to surgery have not changed substantially, while a lot has been introduced in terms of imaging, which is nowadays an essential support in preoperative planning, intraoperative guide and postoperative follow-up. Staged hepatectomy techniques have shown interesting results and will become part of clinical practice in the future, especially in treatment of non-cirrhotic patients. Surgery remains the most effective treatment against HCC, since complete resections allow important survival benefits at 3, 5 and 10 years.

IntechOpen

Author details

Stefania Brozzetti^{1*}, Simone Bini¹, Chiara D'Alterio¹, Chiara De Lucia¹,
Leonardo Luca Chiarella¹, Katia Fazzi¹ and Michele Di Martino²

1 Department of Surgery "Pietro Valdoni", Policlinico Umberto I, University of Rome La Sapienza, Rome, Italy

2 Department of Radiological Sciences, Policlinico Umberto I, University of Rome La Sapienza, Rome, Italy

*Address all correspondence to: stefania.brozzetti@uniroma1.it

IntechOpen

© 2019 The Author(s). Licensee IntechOpen. This chapter is distributed under the terms of the Creative Commons Attribution License (<http://creativecommons.org/licenses/by/3.0>), which permits unrestricted use, distribution, and reproduction in any medium, provided the original work is properly cited. 

References

- [1] Bray F, Ferlay J, Soerjomataram I, Siegel RL, Torre LA, Jemal A. Global cancer statistics 2018: GLOBOCAN estimates of incidence and mortality worldwide for 36 cancers in 185 countries. *CA: A Cancer Journal for Clinicians*. 2018;**68**(6):394-424. DOI: 10.3322/caac.21492
- [2] Forner A, Reig M, Bruix J. Hepatocellular carcinoma. *Lancet*. 2018;**391**(10127):1301-1314. DOI: 10.1016/S0140-6736(18)30010-2
- [3] Desai A, Sandhu S, Lai J-P, Sandhu DS. Hepatocellular carcinoma in non-cirrhotic liver: A comprehensive review. *World Journal of Hepatology*. 2019;**11**(1):1-18. DOI: 10.4254/wjh.v11.i1.1
- [4] Brozzetti S, Bini S, Luca Chiarella L, Fazzi K, Di Martino M, Bezzi M. HCC in elderly patients. Curative intraoperative strategies and management in recurrences. *Liver Cancer*. InTechOpen; 2018. DOI: 10.5772/intechopen.79748
- [5] Galle PR, Forner A, Llovet JM, et al. EASL clinical practice guidelines: Management of hepatocellular carcinoma. *Journal of Hepatology*. 2018;**69**(1):182-236. DOI: 10.1016/j.jhep.2018.03.019
- [6] Hackl C, Schlitt HJ, Kirchner GI, Knoppke B, Loss M. Liver transplantation for malignancy: Current treatment strategies and future perspectives. *World Journal of Gastroenterology*. 2014;**20**(18):5331-5344. DOI: 10.3748/wjg.v20.i18.5331
- [7] Durand F, Levitsky J, Cauchy F, Gilgenkrantz H, Soubrane O, Francoz C. Age and liver transplantation. *Journal of Hepatology*. 2019;**70**(4):745-758. DOI: 10.1016/j.jhep.2018.12.009
- [8] Mazzaferro V, Regalia E, Doci R, et al. Carcinomas in patients with cirrhosis. *The New England Journal of Medicine*. 1996;**334**(11):693-699. DOI: 10.1056/NEJM199603143341104
- [9] Sposito C, Mazzaferro V, Bhoori S, et al. Milan criteria in liver transplantation for hepatocellular carcinoma: An evidence-based analysis of 15 years of experience. *Liver Transplantation*. 2011;**17**(S2):S44-S57. DOI: 10.1002/lt.22365
- [10] Mazzaferro V, Llovet JM, Miceli R, et al. Predicting survival after liver transplantation in patients with hepatocellular carcinoma beyond the Milan criteria: A retrospective, exploratory analysis. *The Lancet Oncology*. 2009;**10**(1):35-43. DOI: 10.1016/S1470-2045(08)70284-5
- [11] Lei JY, Wang WT, Yan LN. Up-to-seven criteria for hepatocellular carcinoma liver transplantation: A single center analysis. *World Journal of Gastroenterology*. 2013;**19**(36):6077-6083. DOI: 10.3748/wjg.v19.i36.6077
- [12] Belghiti J, Durand F. Criteria for liver transplantation for hepatocellular carcinoma: What is an acceptable outcome? *Liver International*. 2011;**31**(Suppl. 1):161-163. DOI: 10.1111/j.1478-3231.2010.02413.x
- [13] Peng Y, Qi XGX. Child-Pugh versus MELD score for the assessment of prognosis in liver cirrhosis. *Medicine*. 2016;**95**(8):1-29. DOI: 10.1097/MD.0000000000002877
- [14] Marroni CP, de Mello Brandão AB, Hennigen AW, et al. MELD scores with incorporation of serum sodium and death prediction in cirrhotic patients on the waiting list for liver transplantation: A single center experience in southern Brazil. *Clinical Transplantation*. 2012;**26**(4):E395-E401. DOI: 10.1111/j.1399-0012.2012.01688.x

- [15] Valapour M, Skeans MA, Smith JM, et al. OPTN/SRTR 2015 annual data report: Lung. *American Journal of Transplantation*. 2017;**17**:357-424. DOI: 10.1111/ajt.14129
- [16] Changyong E, Wang D, Yu Y, Liu H, Ren HJT. Efficacy comparison of radiofrequency ablation and hepatic resection for hepatocellular carcinoma: A meta-analysis. *Journal of Cancer Research and Therapeutics*. 2017;**13**(4):625-630. DOI: 10.4103/jcrt.JCRT_406_17
- [17] Vogl TJ, Nour-Eldin NEA, Hammerstingl RM, Panahi B, Naguib NNN. Microwave ablation (MWA): Basics, technique and results in primary and metastatic liver neoplasms—Review article. *RöFo - Fortschritte auf dem Gebiet der Röntgenstrahlen und der bildgebenden Verfahren*. 2017;**189**(11):1055-1066. DOI: 10.1055/s-0043-117410
- [18] Jiang Y-Q, Wang Z-X, Deng Y-N, Yang Y, Wang G-Y, Chen G-H. Efficacy of hepatic resection vs. radiofrequency ablation for patients with very-early-stage or early-stage hepatocellular carcinoma: A population-based study with stratification by age and tumor size. *Frontiers in Oncology*. 2019;**9**(February):1-10. DOI: 10.3389/fonc.2019.00113
- [19] Cucchetti A, Piscaglia F, Cescon M, Ercolani G, Pinna AD. Systematic review of surgical resection vs radiofrequency ablation for hepatocellular carcinoma. *World Journal of Gastroenterology*. 2013;**19**(26):4106-4118. DOI: 10.3748/wjg.v19.i26.4106
- [20] Tan W, Deng Q, Lin S, Wang Y, Xu G. Comparison of microwave ablation and radiofrequency ablation for hepatocellular carcinoma: A systematic review and meta-analysis. *International Journal of Hyperthermia*. 2019;**36**(1):264-272. DOI: 10.1080/02656736.2018.1562571
- [21] Wu B, Zhou J, Ling G, Zhu D, Long Q. CalliSpheres drug-eluting beads versus lipiodol transarterial chemoembolization in the treatment of hepatocellular carcinoma: A short-term efficacy and safety study. *World Journal of Surgical Oncology*. 2018;**16**(1):1-8. DOI: 10.1186/s12957-018-1368-8
- [22] Hyun D, Cho SK, Shin SW, et al. Early stage hepatocellular carcinomas not feasible for ultrasound-guided radiofrequency ablation: Comparison of transarterial chemoembolization alone and combined therapy with transarterial chemoembolization and radiofrequency ablation. *Cardiovascular and Interventional Radiology*. 2016;**39**(3):417-425. DOI: 10.1007/s00270-015-1194-0
- [23] Qian J, Feng GS, Vogl T. Combined interventional therapies of hepatocellular carcinoma. *World Journal of Gastroenterology*. 2003;**9**(9):1885-1891. DOI: 10.3748/wjg.v9.i9.1885
- [24] Vilana R, Bruix J, Bru C, Ayuso C, Solé MRJ. Tumor size determines the efficacy of percutaneous ethanol injection for the treatment of small hepatocellular carcinoma. *Hepatology*. 1992;**16**(2):353-357
- [25] Facciorusso A, Serviddio G, Muscatiello N. Local ablative treatments for hepatocellular carcinoma: An updated review. *World Journal of Gastrointestinal Pharmacology and Therapeutics*. 2016;**7**(4):477-489. DOI: 10.4292/wjgpt.v7.i4.477
- [26] Gough-palmer AL, Michal W, Gedroyc W, Gough-palmer AL, Witold WM. Laser ablation of hepatocellular carcinoma—A review. *World Journal of Gastroenterology*. 2008;**14**(47):7170-7174. DOI: 10.3748/wjg.14.7170
- [27] Brozzetti S, Bini S, Fazzi K, et al. Case-report: Metastases in a low-stage middle-graded HCC in cleared HCV

infection, non-cirrhotic liver: Surgical therapy. Case Report—Open Access. *International Journal of Surgery Case Reports*. 2018;**47**:19-21. DOI: 10.1016/j.ijscr.2018.04.013

[28] Siddique O, Yoo ER, Perumpail RB, et al. The importance of a multidisciplinary approach to hepatocellular carcinoma. *Journal of Multidisciplinary Healthcare*. 2017;**10**:95-100. DOI: 10.2147/JMDH.S128629

[29] Subramanian KKK, Tandon M, Pandey CK, Jain P. Patients with cirrhosis of liver operated for non-transplant surgery: A retrospective analysis. *Journal of Clinical and Translational Hepatology*. 2019;**7**(X): 1-6. DOI: 10.14218/jct.2018.00043

[30] Maithel SK, Kneuert PJ, Kooby DA, Scoggins CR, Weber SM, Martin RCG, et al. Importance of low preoperative platelet count in selecting patients for resection of hepatocellular carcinoma: A multi-institutional analysis. *Journal of the American College of Surgeons*. 2011;**212**(4):638-648. DOI: 10.1016/j.jamcollsurg.2011.01.004

[31] Maida M, Orlando E, Cammà CCG. Staging systems of hepatocellular carcinoma: A review of literature. *World Journal of Gastroenterology*. 2014;**20**(15):4141-4150. DOI: 10.3748/wjg.v20.i15.4141

[32] Barone C, Koeberle D, Metselaar H, Parisi G, Sansonno D, Spinzi G. Multidisciplinary approach for HCC patients: Hepatology for the oncologists. *Annals of Oncology*. 2013;**24**(Supplement 2):ii15-ii23. DOI: 10.1093/annonc/mdt053

[33] Chawla A, Ferrone C. Hepatocellular carcinoma surgical therapy: Perspectives on the current limits to resection. *Chinese Clinical Oncology*. 2018;**7**(5):48-48. DOI: 10.21037/cco.2018.08.12

[34] Guglielmi A, Ruzzenente A, Conci S, et al. Hepatocellular carcinoma: Surgical perspectives beyond the Barcelona clinic liver cancer recommendations. *World Journal of Gastroenterology*. 2014;**20**(24):7525-7533. DOI: 10.3748/wjg.v20.i24.7525

[35] Torzilli G, Belghiti J, Kokudo N, Takayama T, Capussotti L, Nuzzo G, et al. A snapshot of the effective indications and results of surgery for hepatocellular carcinoma in tertiary referral centers. *Annals of Surgery*. 2013;**257**(5):929-937. DOI: 10.1097/sla.0b013e31828329b8

[36] Vitale A, Saracino E, Boccagni P, et al. Validation of the BCLC prognostic system in surgical hepatocellular cancer patients. *Transplantation Proceedings*. 2009;**41**(4):1260-1263. DOI: 10.1016/j.transproceed.2009.03.054

[37] Bolondi L, Burroughs A, Dufour JF, Galle PR, Mazzaferro V, Piscaglia F, et al. Heterogeneity of patients with intermediate (BCLC B) hepatocellular carcinoma: Proposal for a subclassification to facilitate treatment decisions. *Seminars in Liver Disease*. 2012;**1**(212):348-359. DOI: 10.1055/s-0032-1329906

[38] Yang X, Pan L, Wang L, et al. Systematic review of single large and/or multinodular hepatocellular carcinoma: Surgical resection improves survival. *Asian Pacific Journal of Cancer Prevention*. 2015;**16**(13):5541-5547. DOI: 10.7314/APJCP.2015.16.13.5541

[39] Cheung TT, Ng KK, Chok KS, et al. Combined resection and radiofrequency ablation for multifocal hepatocellular carcinoma: Prognosis and outcomes. *World Journal of Gastroenterology*. 2010;**16**(24):3056-3062. DOI: 10.3748/wjg.v16.i24.3056

[40] Simon CJ, Dupuy DE, Iannitti DA, et al. Intraoperative triple antenna hepatic microwave ablation.

American Journal of Roentgenology. 2006;**187**(4):333-340. DOI: 10.2214/AJR.05.0804

[41] Aghoram R, Cai P, Dickinson JA. Alpha-fetoprotein and/or liver ultrasonography for screening of hepatocellular carcinoma in patients with chronic hepatitis B. Cochrane Database of Systematic Reviews. 2012;**9**:1-24. DOI: 10.1002/14651858.CD002799.pub2

[42] Singal A, Volk ML, Waljee A, et al. Meta-analysis: Surveillance with ultrasound for early-stage hepatocellular carcinoma in patients with cirrhosis. Alimentary Pharmacology & Therapeutics. 2009;**30**(1):37-47. DOI: 10.1111/j.1365-2036.2009.04014.x

[43] Bolondi L. Screening for hepatocellular carcinoma in cirrhosis. Journal of Hepatology. 2003;**39**(6):1076-1084. DOI: 10.1016/s0168-8278(03)00349-0

[44] Kee KM, Lu SN. Diagnostic efficacy of ultrasound in hepatocellular carcinoma diagnosis. Expert Review of Gastroenterology & Hepatology. 2017;**11**(4):277-279. DOI: 10.1080/17474124.2017.1292126

[45] Henedige T, Kundapur S. Imaging of hepatocellular carcinoma: Diagnosis, staging and treatment monitoring. Cancer Imaging. 2012;**12**:530-547. DOI: 10.1102/1470-7330.2012.0044

[46] Ayuso C, Rimola J, García-Criado Á. Imaging of HCC. Abdominal Imaging. 2012;**37**(2):215-230. DOI: 10.1007/s00261-011-9794-x

[47] Zhang BYB. Combined alpha fetoprotein testing and ultrasonography as a screening test for primary liver cancer. Journal of Medical Screening. 1999;**6**:108-110. DOI: 10.1136/jms.6.2.108

[48] Saitta C, Raffa G, Alibrandi A, et al. PIVKA-II is a useful tool for

diagnostic characterization of ultrasound-detected liver nodules in cirrhotic patients. Medicine (United States). 2017;**96**(26):1-5. DOI: 10.1097/MD.00000000000007266

[49] Kim TK, Jang H. Contrast-enhanced ultrasound in the diagnosis of nodules in liver cirrhosis. World Journal of Gastroenterology. 2014;**20**(13):3590-3596. DOI: 10.3748/wjg.v20.i13.3590

[50] Cantisani V, David E, Meloni FM, et al. Recall strategies for patients found to have a nodule in cirrhosis: Is there still a role for CEUS?. Medical Ultrasonography. 2015;**17**(4):515-520. DOI: 10.11152/mu.2013.2066.174.rsp

[51] Russo FP, Imondi A, Lynch EN, Farinati F. When and how should we perform a biopsy for HCC in patients with liver cirrhosis in 2018? A review. Digestive and Liver Disease. 2018;**50**(7):640-646. DOI: 10.1016/j.dld.2018.03.014

[52] Zhang Y, Fowler K, Hamilton G, et al. Liver fat imaging—A clinical overview of ultrasound, CT, and MR imaging. The British Journal of Radiology. 2018;**91**(March):1-12. DOI: 10.1259/bjr.20170959

[53] Bolog N, Andreisek G, Oancea IMA. CT and MR imaging of hepatocellular carcinoma. Journal of Gastrointestinal and Liver Diseases. 2011;**20**(2):181-189

[54] Guglielmi A, Ruzzenente A, Conci S, Valdegamberi A, Iacono C. How much remnant is enough in liver resection? Digestive Surgery. 2012;**29**(1):6-17. DOI: 10.1159/000335713

[55] Wile G, Gorden L, Caserta MP, Sakala M, Shen P. Presurgical planning for hepatobiliary malignancies. Magnetic Resonance Imaging Clinics of North America. 2014;**22**(3):447-465. DOI: 10.1016/j.mric.2014.04.003

- [56] Brozzetti S, Bezzi M, de Sanctis GM, et al. Elderly and very elderly patients with hepatocellular carcinoma: Strategy for a first line treatment. *Annali Italiani di Chirurgia*. 2014;**85**(2):120-128
- [57] Christ B, Dahmen U, Herrmann KH, et al. Computational modeling in liver surgery. *Frontiers in Physiology*. 2017;**8**(Nov). DOI: 10.3389/fphys.2017.00906
- [58] Willatt JM, Hussain HK, Adusumilli S, Marrero JA. MR imaging of hepatocellular carcinoma in the cirrhotic liver: Challenges and controversies. *Radiology*. 2008;**247**(2):311-330. DOI: 10.1148/radiol.2472061331
- [59] Yang X, Qiu Z, Ran R, et al. Prognostic importance of bile duct invasion in surgical resection with curative intent for hepatocellular carcinoma using PSM analysis. *Oncology Letters*. 2018;**16**(3):3593-3602. DOI: 10.3892/ol.2018.9108
- [60] Park DH, Lee KS, Lee D, et al. Clinical features and outcomes of patients with hepatocellular carcinoma complicated with bile duct invasion. *Clinical and Molecular Hepatology*. 2017;**23**(2):160-169. DOI: 10.3350/cmh.2016.0088
- [61] Orimo T, Kamiyama T, Yokoo H, et al. Hepatectomy for hepatocellular carcinoma with bile duct tumor thrombus, including cases with obstructive jaundice. *Annals of Surgical Oncology*. 2016;**23**(8):2627-2634. DOI: 10.1245/s10434-016-5174-7
- [62] Qiao W, Yu F, Wu L, Li B, Zhou Y. Surgical outcomes of hepatocellular carcinoma with biliary tumor thrombus: A systematic review. *BMC Gastroenterology*. 2016;**16**(1):4-10. DOI: 10.1186/s12876-016-0427-2
- [63] Yeh CN, Jan YY, Lee WC, Chen MF. Hepatic resection for hepatocellular carcinoma with obstructive jaundice due to biliary tumor thrombi. *World Journal of Surgery*. 2004;**28**(5):471-474. DOI: 10.1007/s00268-004-7185-y
- [64] Heimbach JK, Kulik LM, Finn RS, et al. AASLD guidelines for the treatment of hepatocellular carcinoma. *Hepatology*. 2018;**67**(1):358-380. DOI: 10.1002/hep.29086
- [65] Sigrist RMS, Liao J, El Kaffas A, Chammas MC, Willmann JK. Ultrasound elastography: Review of techniques and clinical applications. *Theranostics*. 2017;**7**(5):1303-1329. DOI: 10.7150/thno.18650
- [66] Gong N-M. Intraoperative US and contrast-enhanced intraoperative US during hepatic resection for patients with hepatocellular carcinoma in liver cirrhosis. *Clinical Hemorheology and Microcirculation*. 2018:1-16. DOI: 10.3233/ch-180431
- [67] Fan MH, Chang AE. Resection of liver tumors: Technical aspects. *Surgical Oncology*. 2002;**10**(4):139-152. DOI: 10.1016/S0960-7404(02)00002-6
- [68] Pulitano C, Crawford M, Joseph D, Aldrighetti L, Sandroussi C. Preoperative assessment of postoperative liver function: The importance of residual liver volume. *Journal of Surgical Oncology*. 2014;**110**(4):445-450. DOI: 10.1002/jso.23671
- [69] Pang YY, Strasberg SM. The Brisbane 2000 terminology of liver anatomy and resections (HPB 2000;2:333-339). *HPB Journal*. 2002;**4**(2):99. author reply 99-100. DOI: 10.1080/136518202760378489
- [70] Wen T, Jin C, Facciorusso A, et al. Multidisciplinary management of recurrent and metastatic hepatocellular carcinoma after resection: An international expert consensus. *HepatoBiliary Surgery and Nutrition*.

2018;7(5):353-371. DOI: 10.21037/hbsn.2018.08.01

[71] Tsai TJ, Chau GY, Lui WY, et al. Clinical significance of microscopic tumor venous invasion in patients with resectable hepatocellular carcinoma. *Surgery*. 2000;127(6):603-608. DOI: 10.1067/msy.2000.105498

[72] Hackl C, Schlitt HJ, Renner P, Lang SA. Liver surgery in cirrhosis and portal hypertension. *World Journal of Gastroenterology*. 2016;22(9):2725-2735. DOI: 10.3748/wjg.v22.i9.2725

[73] Zamora-Valdes D, Taner TND. Surgical treatment of hepatocellular carcinoma. *Cancer Control*. 2017;24(3):1-15. DOI: 10.1177/1073274817729258

[74] Belghiti J, Cortes A, Abdalla EK, et al. Resection prior to liver transplantation for hepatocellular carcinoma. *Annals of Surgery*. 2003;238(6):885-893. DOI: 10.1097/01.sla.0000098621.74851.65

[75] Zhou Y, Xu D, Wu L, Li B. Meta-analysis of anatomic resection versus non-anatomic resection for hepatocellular carcinoma. *Langenbeck's Archives of Surgery*. 2011;396(7):1109-1117. DOI: 10.1007/s00423-011-0784-9

[76] Shimada S, Kamiyama T, Yokoo H, et al. Clinicopathological characteristics of hepatocellular carcinoma with microscopic portal venous invasion and the role of anatomical liver resection in these cases. *World Journal of Surgery*. 2017;41(8):2087-2094. DOI: 10.1007/s00268-017-3964-0

[77] Kajiyama K, Maehara Y, Shirabe K, et al. Prognosis of hepatocellular carcinoma accompanied by microscopic portal vein invasion. *World Journal of Gastroenterology*. 2009;15(21):2632. DOI: 10.3748/wjg.15.2632

[78] Tsang Y-M, Huang G-T, Lee P-H, et al. Liver resection improves the

survival of patients with multiple hepatocellular carcinomas. *Annals of Surgical Oncology*. 2009;16(4):848-855. DOI: 10.1245/s10434-008-0282-7

[79] Strasberg SM, Belghiti J, Clavien P-A, et al. The Brisbane 2000 terminology of liver anatomy and resections. *HPB Journal*. 2000;2(3):333-339. DOI: 10.1016/S1365-182X(17)30755-4

[80] Yasuda S, Nomi T, Hokuto D, Yoshikawa T, Matsuo Y, Sho M. Liver regeneration after major liver resection for hepatocellular carcinoma in the elderly. *Journal of Investigative Surgery*. 2018:1-7. DOI: 10.1080/08941939.2018.1517839. [E-pub ahead of print]

[81] Fruscione M, Pickens R, Baker EH, et al. Robotic-assisted versus laparoscopic major liver resection: analysis of outcomes from a single center. *HPB Journal*. 2019. DOI: 10.1016/j.hpb.2018.11.011. [E-pub ahead of print]

[82] Cavalcante AN, Gurrieri C, Sprung J, Schroeder DR, Weingarten TN. Isoflurane and postoperative respiratory depression following laparoscopic surgery: A retrospective propensity-matched analysis. *Bosnian Journal of Basic Medical Sciences*. 2018;18(1):95-100. DOI: 10.17305/bjbm.2017.2478

[83] Leoni S, Piscaglia F, Serio I, et al. Adherence to AASLD guidelines for the treatment of hepatocellular carcinoma in clinical practice: Experience of the bologna liver oncology group. *Digestive and Liver Disease*. 2014;46(6):549-555. DOI: 10.1016/j.dld.2014.02.012

[84] Giovanardi F, Lai Q, Bertacco A, Vitale A. Resection for hepatocellular cancer: overpassing old barriers. *Translational Gastroenterology and Hepatology*. 2018;3(1):64-64. DOI: 10.21037/tgh.2018.09.13

- [85] Ogata S, Belghiti J, Varma D, et al. Two hundred liver hanging maneuvers for major hepatectomy. *Annals of Surgery*. 2007;**245**(1):31-35. DOI: 10.1097/01.sla.0000224725.40979.0a
- [86] J. B. Editorial perspective: Resection of large hepatocellular carcinoma using the combination of liver hanging maneuver and anterior approach. *World Journal of Surgery*. 2010;**34**:1879-1880. DOI: 10.1007/s00268-010-0593-2
- [87] Machairas N, Papaconstantinou D, Tsilimigras DI, et al. Comparison between robotic and open liver resection: A systematic review and meta-analysis of short-term outcomes. *Updates in Surgery*. 2019;**71**(1):39-48. DOI: 10.1007/s13304-019-00629-0
- [88] Liu R, Wakabayashi G, Kim H-J, et al. International consensus statement on robotic hepatectomy surgery in 2018. *World Journal of Gastroenterology*. 2019;**25**(12):1432-1444. DOI: 10.3748/wjg.v25.i12.1432
- [89] Fahrner R, Rauchfuß F, Bauschke A, Kissler H, Settmacher U, Zanow J. Robotic hepatic surgery in malignancy: Review of the current literature. *Journal of Robotic Surgery*. 2019. DOI: 10.1007/s11701-019-00939-w. [E-pub ahead of print]
- [90] Khan AS, Garcia-Aroz S, Ansari MA, et al. Assessment and optimization of liver volume before major hepatic resection: Current guidelines and a narrative review. *International Journal of Surgery*. 2018;**52**:74-81. DOI: 10.1016/j.ijso.2018.01.042
- [91] Cai X, Tong Y, Yu H, et al. The ALPPS in the Treatment of Hepatitis B – Related Hepatocellular Carcinoma With Cirrhosis : A Single-Center Study and Literature Review. *Surgical Innovation*. 2017:1-7. DOI: 10.1177/1553350617697187
- [92] Vennarecci G, Levi Sandri GBEG. Performing the ALPPS procedure by anterior approach and liver hanging maneuver. *Annals of Surgery*. 2016;**263**(1):e11. DOI: 10.1097/SLA.0000000000001007
- [93] Tustumi F, Ernani L, Coelho FF, et al. Preoperative strategies to improve respectability for hepatocellular carcinoma: A systematic review and meta-analysis. *HPB Journal*. 2018;**20**(12):1109-1118. DOI: 10.1016/j.hpb.2018.06.1798
- [94] Sparrelid E, Jonas E, Tzortzakakis A, et al. Dynamic Evaluation of Liver Volume and Function in Associating Liver Partition and Portal Vein Ligation for Staged Hepatectomy. *Journal of Gastrointestinal Surgery*. 2017:967-974. DOI: 10.1007/s11605-017-3389-y
- [95] De Santibañes E, Alvarez FA, Ardiles V. How to avoid postoperative liver failure: A novel method. *World Journal of Surgery*. 2012;**36**(1):125-128. DOI: 10.1007/s00268-011-1331-0
- [96] Schnitzbauer AA, Lang SA, Goessmann H, et al. Right portal vein ligation combined with in situ splitting induces rapid left lateral liver lobe hypertrophy enabling 2-staged extended right hepatic resection in small-for-size settings. *Annals of Surgery*. 2012;**255**(3):405-414. DOI: 10.1097/SLA.0b013e31824856f5
- [97] Zhou Z, Xu M, Lin N, et al. Associating liver partition and portal vein ligation for staged hepatectomy versus conventional two-stage hepatectomy: A systematic review and meta-analysis. *World Journal of Surgical Oncology*. 2017;**15**(1):1-10. DOI: 10.1186/s12957-017-1295-0
- [98] Vennarecci G, Ferraro D, Tudisco A, et al. The ALPPS procedure: Hepatocellular carcinoma as a main indication. An Italian single-center experience. *Updates in Surgery*. 2018;**71**(1):67-75. DOI: 10.1007/s13304-018-0596-3

- [99] Chen K, Pan Y, Zhang B, Liu X, Maher H, Zheng X. Laparoscopic versus open surgery for hepatocellular carcinoma: A meta-analysis of high-quality case-matched studies. *Canadian Journal of Gastroenterology and Hepatology*. 2018;**2018**:1-15. DOI: 10.1155/2018/1746895
- [100] Ishii M, Mizuguchi T, Harada K, et al. Comprehensive review of post-liver resection surgical complications and a new universal classification and grading system. *World Journal of Hepatology*. 2014;**6**(10):745-751. DOI: 10.4254/wjh.v6.i10.745
- [101] Xiong JJ, Altaf K, Javed MA, Huang W, Mukherjee R, Mai G, et al. Meta-analysis of laparoscopic vs open liver resection for hepatocellular carcinoma. *Hepatology Research*. 2012;**18**(45):6657-6668. DOI: 10.3748/wjg.v18.i45.6657
- [102] Swaid F, Geller DA. Minimally invasive primary liver cancer surgery. *Surgical Oncology Clinics of North America*. 2019;**28**(2):215-227. DOI: 10.1016/j.soc.2018.11.002
- [103] Faber W, Seehofer D, Neuhaus P, et al. Repeated liver resection for recurrent hepatocellular carcinoma. *Journal of Gastroenterology and Hepatology*. 2011;**26**(7):1189-1194. DOI: 10.1111/j.1440-1746.2011.06721.x
- [104] Joliat GR, Allemann P, Labgaa I, Demartines N, Halkic N. Treatment and outcomes of recurrent hepatocellular carcinomas. *Langenbeck's Archives of Surgery*. 2017;**402**(5):737-744. DOI: 10.1007/s00423-017-1582-9
- [105] Lacaze L, Scotté M, Nicolle C. Surgical treatment of intra hepatic recurrence of hepatocellular carcinoma. *World Journal of Hepatology*. 2015;**7**(13):1755-1760. DOI: 10.4254/wjh.v7.i13.1755
- [106] Yang SL, Luo YY, Chen M, et al. A systematic review and meta-analysis comparing the prognosis of multicentric occurrence and vs. intrahepatic metastasis in patients with recurrent hepatocellular carcinoma after hepatectomy. *HPB Journal*. 2017;**19**(10):835-842. DOI: 10.1016/j.hpb.2017.06.002
- [107] Schietroma I, Scheri GC, Pinacchio C, Stazu M, Pascale FG. Hepatitis C Virus and Hepatocellular Carcinoma-Pathogenetic Mechanisms and Impact of Direct-Acting Antivirals. *Open Virology Journal*. 2018;(12):16-25. DOI: 10.2174/1874357901812010016
- [108] Minagawa M, Makuuchi M, Takayama T, Kokudo N. Selection criteria for repeat hepatectomy in patients with recurrent hepatocellular carcinoma. *Annals of Surgery*. 2003;**238**(5):703-710. DOI: 10.1097/01.sla.0000094549.11754.e6
- [109] Song KD, Lim HK, Rhim H, et al. Repeated hepatic resection versus radiofrequency ablation for recurrent hepatocellular carcinoma after hepatic resection: A propensity score matching study. *Radiology*. 2015;**275**(2):599-608. DOI: 10.1148/radiol.14141568
- [110] Hatzaras I, Bischof DA, Fahy B, Cosgrove D, Pawlik TM. Treatment options and surveillance strategies after therapy for hepatocellular carcinoma. *Annals of Surgical Oncology*. 2014;**21**(3):758-766. DOI: 10.1245/s10434-013-3254-5