

We are IntechOpen, the world's leading publisher of Open Access books Built by scientists, for scientists

4,800

Open access books available

122,000

International authors and editors

135M

Downloads

Our authors are among the

154

Countries delivered to

TOP 1%

most cited scientists

12.2%

Contributors from top 500 universities



WEB OF SCIENCE™

Selection of our books indexed in the Book Citation Index
in Web of Science™ Core Collection (BKCI)

Interested in publishing with us?
Contact book.department@intechopen.com

Numbers displayed above are based on latest data collected.

For more information visit www.intechopen.com



How to Treat Bilobar Liver Metastases: New Surgical Challenges

Fabio Uggeri, Enrico Pinotti, Mattia Garancini, Mauro Scotti, Marco Braga and Fabrizio Romano

Abstract

To date, the improvements in survival of patients with liver metastases and advances in technology allowed the surgical indications to be extended. In complex cases, however, the possibility of performing a curative hepatic resection collides with the need to preserve a sufficient liver volume to avoid a postoperative hepatic failure. Currently postoperative liver failure is the major cause of death for these patients. In the attempt to overcome this limit in the last decades, we tried to introduce new measures and develop new surgical techniques. From the introduction by Makuuchi in the 1980s of the preoperative portal embolization, many surgical techniques have been proposed and perfected. The aim of this chapter is to describe the new surgical techniques for the approach of complex hepatic metastases.

Keywords: hepatic liver metastases, hepatectomy, liver failure, two-stage hepatectomy, ALPPS

1. Introduction

In the recent decades, the improvement of technology associated with a refinement of preoperative imaging allowed to expand surgical indications, leading to treat patients until a few years ago judged unresectable. These improvements have made major liver surgery more feasible and sure with a clean reduction of morbidity and mortality rate. Today after major hepatectomy, mortality ranges from 0.5 and 4%, making surgery a therapeutic option even in case of advanced disease.

Beyond the extension of surgical indications, the pivotal point remains the possibility to perform a curative resection (R0). Unfortunately, situations such as chronic liver diseases or an extensive disease do not let to achieve a radical resection for the inability to maintain a suitable remnant liver after resection for an adequate postoperative function. Nowadays this is the limits to overcome.

At the current state of knowledge, the future liver remnant (FLR) estimated before surgical resection should be more of 25% of the total liver volume in patients without hepatic disease and of around 40% in the patients with history of liver pathologies (viral chronic hepatitis, alcoholic, nonalcoholic steatohepatitis (NASH), chemotherapeutic damage).

An effective and safe surgery can only be achieved with a perfect knowledge of the surgical anatomy. This anatomy corresponds to a functional liver vascular distribution based on the concept of the anatomical division of the liver proposed by Claude Couinaud, Ton That Tung, and Henri Bismuth, which divides the liver into independent portions that can be handled separately without compromising the function of the remnant liver.

Unfortunately, today it is not uncommon to evaluate patients at the first instance inoperable due to the disseminated hepatic spread. The research of new surgical strategies to effectively extend the number of liver resections and the concept of “resectability” were one of the biggest challenges in oncologic surgery over the last 30 years.

To overcome this limit, new surgical techniques have been proposed with the clear intention of promoting liver regeneration by modifying the procedures first performed in a single procedure in more steps. Moreover in the case of large and complex surgical resections, an accurate study of the liver is recommended to evaluate the postoperative functional reserve with a volumetric and functional assessment (clearance of indocyanine green, scintigraphy, CT, MR).

Laboratory tests on animals and clinical data showed that the closure of portal flow toward a hemiliver induces contralateral lobe hypertrophy. Portal flow redistribution can be achieved with surgical ligation (PVL) or percutaneous embolization (portal vein embolization (PVE)). The purpose of PVE is to increase preoperatively the volume of the future remnant liver to allow the surgery and reduce postoperative morbidity, when the only contraindication to surgery is represented by the initial insufficient remnant liver. The first to propose this technique in the 1980s was Makuuchi, and since then huge progress has been made. Makuuchi and his group [1] first used this technique in 14 patients with cholangiocarcinoma to minimize the possibility of postoperative hepatic dysfunction. The results obtained were encouraging without showing major complications and being able to perform surgical resection in 85% of patients in a timing from 4 to 41 days after embolization.

The experience of Makuuchi marked a crossroad for the birth of a new surgical attitude to approach extended right-side hepatectomy, in fact the procedure was shortly adopted by several surgeons [2–4].

Once the new technique was universally accepted, some surgeons proposed during the next decade a technical progress describing a sequential surgical procedure called “two-stage hepatectomy (TSH)” [5]. To achieve the goal of radical resection in patients with colorectal hepatic metastases, the authors outline a previously therapeutic approach [6]. A procedure includes a first surgical step in which the removal of the lesions of the left lobe associated with the closure of the right portal branch is performed. Liver hypertrophy associated with chemotherapy limits the growth and spread of residual lesions and then allows the patients to undergo surgery in the absence of disease progression and in the presence of a residual volume adequate to prevent postoperative hepatic failure. The feasibility of the procedure was 81% with a mortality rate of 15% for the second stage. At the beginning the technique did not provide for all patients portal embolization, and then the routine use of the latter led to a higher rate of hypertrophy and therefore with a greater rate of patient treated with curative intent [7]. Although the first results were encouraging, the drawback of TSH led to the impossibility of achieving sufficient hypertrophy in an acceptable time to avoid a progression of the disease that in some studies did not allow up to 28% of treated patients to undergo second surgical phase [8]. The reasons of technique failure were due to disease progression

inherent to long time to reach the proper hypertrophy or the impossibility to achieve the desired liver hypertrophy in consideration of the unsuitable size of the remnant liver.

In the attempt to overcome these limits, in 2012 Schnitzbauer [9] proposed a new surgical approach, named subsequently by Santibanes [10] “*associating liver partition and portal vein ligation for staged hepatectomy* (ALPPS).” The procedure involves the separation of the future remnant liver from diseased liver through “split” in situ of the hepatic parenchyma in combination with ligation of the portal vein during the first phase. Schnitzbauer [9] reported a hypertrophy of the remnant liver achieved in a very short time (average future remnant liver hypertrophy of 74% in about 9 days). The mechanism by which ALPPS leads to such a dramatic increase in hepatic hypertrophy compared to PVE still needs to be fully clarified. Initially it was thought that the stimulus to hypertrophy was related to the cessation of blood flow between the diseased segments and the FLR, but some authors have subsequently reported how step I in ALPPS leads to an increase in levels of interleukin-6 and tumor necrosis factor- α in liver tissue 1 hour after the procedure compared to PVL [11]. Therefore, rapid hypertrophy could be associated with a systemic increase in circulating growth factors as an inflammatory reaction to parenchymal split.

Beyond the first promising results, the high complication rate (44%) with a mortality of 12% described by Schnitzbauer led to several questions about the role and indications of the technique in the surgical community. The subsequent expedients to the original technique and the proposal of more restrictive indications based on practice have led to a significant reduction of the postoperative morbidity and mortality rate. In fact the results of the most recent ALPPS register report more encouraging data, with a 90-day mortality of 9% and serious complications of 27% [12].

Since its introduction until today, under the term ALPPS, many variations and adaptations of the original technique are grouped. The common thread of all these variants is to try to reduce morbidity and mortality while maintaining an adequate hypertrophy response from the liver.

The purpose of the chapter is to analyze which surgical techniques, to date, can be performed in the presence of diffuse liver metastases.

2. Liver failure

Within this context of extended resection, postoperative liver failure remains a real concern. The term “small for size syndrome” (SFSS) has been first used in liver transplantation to describe the development of acute liver failure, situation in which the donor’s liver was too small for the given recipient. Few years later, Dahm [13] proposed a systematic definition of SFSS. Small for size syndrome was defined as the presence of two of the following criteria in the first three postoperative days: serum bilirubin >6 mg/dL, international normalized ratio (INR) > 2 , and the presence of encephalopathy grade III/IV.

As in liver transplantation, the extension of surgical indications in the presence of bilobar metastases led to the concept of post-hepatectomy liver failure (PHLF). PHLF is a clinical manifestation that occurs when the remnant liver is not sufficient to provide for metabolic demand. To predict early mortality after extensive hepatectomy in 2005, Balzan [14] proposed that the persistence of either PT $< 50\%$ or a serum bilirubin >3 mg/dL on 5 postoperative days is to be considered a predictive mortality index and indicates PHLF. The result of the study demonstrated that the

conjunction of these two values on 5 postoperative days could predict nearly 100% morbidity rate and 50% mortality rate.

Recently the International Study Group for Liver Surgery (ISGLS) [15] has proposed to define PHLF as a “postoperatively acquired deterioration in the ability of the liver to maintain its synthetic, excretory, and detoxifying functions, characterized by an increased INR and concomitant hyperbilirubinemia on or after postoperative five days.”

PHLF incidence ranges from 0 to 2% after resection of a healthy liver but can reach 7% after major hepatectomy. Cirrhotic liver may exceed 30% [16]. PHLF is the main cause of mortality after extensive hepatic resection, and it may occur even after the 30th postoperative days [17]. In the last decades, surgical techniques in the field of hepatic surgery have focus their attention to develop and implement a series of tools to induce hypertrophy in the future remnant liver to overcome this long-standing problem.

2.1 Two-stage hepatectomy (TSH)

Patients with disseminated and large liver cancers are one of the major surgical challenges; two-stage hepatectomy with PVE or PVL, associated by subsequent hepatectomy, can represent a solution to this dilemma [7].

In the late 1990s, the studies of Bismuth [6] and Azoulay [18] had highlighted how patients with initially unresectable colorectal liver metastases could benefit by the use of PVE associated with neoadjuvant chemotherapy. Preoperative treatment led patients to surgery with survival benefits comparable to those obtained with primary liver resection (40% patients alive at 5 years).

Whereas not all patients with intrahepatic multinodular liver disease undergoing portal vein embolization were able to achieve curative surgery, approximately 20 years ago, Adam et al. [5] proposed a new surgical strategy with a possible curative intent: two-stage hepatectomy “TSH.” They modified this practice by introducing an initial stage in which in addition to the ligation or portal embolization were surgically removed the highest number of metastases but not all of them. The hepatic hypertrophy and chemotherapy limiting the metastatic diffusion allowed to perform a second stage for curative purposes reducing the risk of postoperative hepatic failure (**Figure 1**). They were the first to report the results of TSH in terms of feasibility, risks, and patient outcome. The rate of completion of the procedure was 81% with a survival of 35% at 3 years. The risks related to the procedure were inherent in the possible tumor progression between the two stages. But the survival benefit of treated versus untreated patients exceeded methodical risks. The authors reported a mortality rate of 15% comparable to that of patients undergoing primary resection during the same period.

Currently TSH is indicated for multiple colorectal liver lesions judged unresectable in the first instance. As mentioned above the technique provides a first

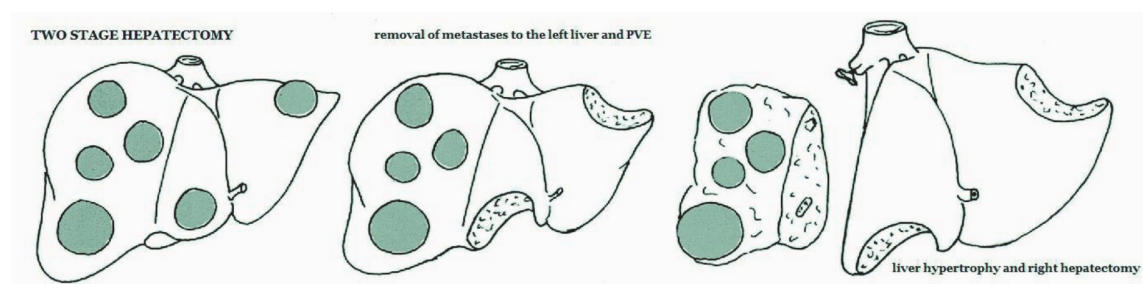


Figure 1.
Two-stage hepatectomy (surgical steps).

stage in which the future remnant liver (usually the left lobe) is surgically or by ablation reclaimed. The first step also provides the execution of PVL or PVE. Portal occlusion stimulates liver regeneration as the possible growth of occult metastases in the remnant liver. In fact the possible progression of disease is the main cause that can prevent the completion of the second surgical phase.

The success of the surgical procedure is closely related to liver regeneration between the two procedures, which avoids the possible risk of postoperative liver failure. The rate of liver regeneration is normally assessed through the execution of a CT scan between 30 and 50 days after the portal occlusion. Although portal occlusion leads to a higher rate than 40% of liver regeneration, it is not always possible to reach the second stage of treatment [19]. Disease progression and insufficient liver regeneration are the main causes leading to a failure of the treatment that ranges from 22–28% [20]. Patients who do not undergo the second stage have an extreme unfavorable prognosis compared to patients who complete the treatment. Three and five survival rates were 68% and 49%, respectively, for patients who underwent second-stage resection and 6 and 0%, respectively, for patients who did not [21, 22]. Patients enrolled to the second surgery have a median overall survival of 36 months [23]; these outcomes are comparable with those patients with resectable colorectal liver metastases at the diagnosis [24–26]. With regard to morbidity and mortality after the first and second stage, in a recent study, Passot [21] reported a morbidity rate of 26% for the second stage compared to 6% of the first. Instead the postoperative mortality at 90 days after the second surgery is around 7%, which is halved compared to the data reported by the first studies.

Considering the technique feasible in selected patients with acceptable morbidity and mortality rates, are there selection criteria to select patients? Interesting in this regard is the paper of Narita [27] which stated that the presence of three or more metastases in the FLR can be considered a negative prognostic factor. A high number of metastases in the remnant liver is correlated to an increased possibility of disease progression during the two surgical stages and may encourage the appearance of “de novo” metastases.

A possible explanation of disease progression, which manifests itself from 13 to 35% of patients [27, 28], is given by numerous experimental studies which suggested that a hypoxia-induced alteration of tumor microenvironment leads to an increased production of vascular endothelial growth factors (VEGF), which can stimulate beyond liver regeneration the growth of dormant micrometastases [22, 29].

The technique, today, should be considered in selected patients with bilobar colorectal liver metastases in whom a right hepatectomy would leave more than three metastases or any metastases of >3 cm in the FLR [30].

Chemotherapy has a key role in the success of sequential treatment. The objective response to preoperative chemotherapy has been shown to be a strong predictor of survival after resection for colorectal liver metastases [31]. Modern chemotherapy regimens using a combination of multiple drugs (5-fluorouracil, oxaliplatin, irinotecan) have achieved really satisfactory results. Some new biological agents such as bevacizumab and cetuximab promise to lead to better results [32]. Although the effectiveness of chemotherapy and its execution should be considered as mandatory for a successful surgical treatment, its use is not without risk. Hepatic chemotherapy damage expressed in terms of liver steatosis and increased postoperative bleeding should be considered when planning an extensive hepatic resection [27, 33]. In fact, several studies have shown an increase in mortality in patients undergoing preoperative chemotherapy.

In conclusion TSH can be considered in selected patients a standard surgical procedure in the treatment of diffuse liver metastases with an acceptable mortality

rate. In this regard in fact, a recent study of Baumgart [34] reported a postoperative 30th mortality rate of 0% after the TSH second stage. On the contrary the rate of completion of the procedure expected at best to be about 80% associated with an insufficient liver regeneration reported in some studies [35, 36] can be considered a technical limit. In combination with failure to achieve an adequate residual liver volume, disease progression related to the long time needed to achieve liver regeneration may be considered the additional limitations of the surgical procedure.

2.2 Associating liver partition and portal vein ligation for two-staged hepatectomy (ALPPS)

Associating liver partition and portal vein ligation for two-staged hepatectomy (ALPPS) is a surgical procedure recently introduced in hepatobiliary surgery [9, 10] which consists of the association, during an initial surgical time, of ligation of the right portal vein and transection of the hepatic parenchyma in order to induce a rate of residual liver hypertrophy more marked in a shorter time interval than the standard techniques (PVE, TSH), and it represented a novel concept and one of the most promising advances in oncological liver surgery.

The technique, initially described in a single patient with perihilar cholangiocarcinoma and subsequently tested in a series of patients with diffuse colorectal liver metastases, involves two separate surgical stages. The new approach described by Schnitzbauer [9] in 2012 combines in situ split of the liver usually between the left lateral sector and segment IV^o with ligation of the right portal branch followed by a right or extended right hepatectomy. The removal of the liver metastases in the left lateral sector can be included in the first surgical stage (**Figure 2a, b**).

A significant increase in FLR was obtained about 1 week after the first operation, and in 2 weeks in healthy livers the maximum peak of regeneration is achieved [37]. Schnitzbauer [9] observed features of hepatocyte apoptosis in the diseased liver and enhanced markers of hepatocyte proliferation in the remnant liver. Although the precise pathophysiologic mechanism by which this spectacular liver regenerative response occurs has not yet been clarified in detail, it is thought that the inflammatory response due to the portal ligation associated with the complete hepatic transection, which does not allow cross portal circulation between the two parts of the liver, is the basis of this regenerative response. The benefits of rapid liver regeneration are clear enough to allow the surgeon to complete the procedure in a shorter time than previous techniques, reducing the risk of possible progression of disease. Furthermore the advantages are expressed in a shorter period of postoperative hospital stay for the patient, and from the technical point of view, the surgeons may be faced with a lower number of postoperative adhesions performing less complicated operations [10].

From the first description of the ALPPS some technical measures have been introduced. To minimize the possibility of biliary leaks on the surface of the diseased liver, due to ischemia, surgeons placed the latter in a plastic bag with a drain inside; a catheter was also placed inside the cystic duct to perform a hydraulic test to highlight any biliary leak in the FLR. They performed, moreover, a portal pedicle lymphadenectomy, not only for oncological reasons but also for a better identification of the hilar structures and portal vein ligation. To facilitate the identification of hepatic veins, hepatic artery, and portal pedicle at the time of the second operation, they routinely encircled them with a strong black silk [10]. This new approach allowed to lead to surgical treatment patients with widespread disease judged unresectable with the previous techniques.

Beyond the initial enthusiasm for the new surgical procedure, to the detriment of the latter, the high mortality rate reported in the paper of Schnitzbauer [9]

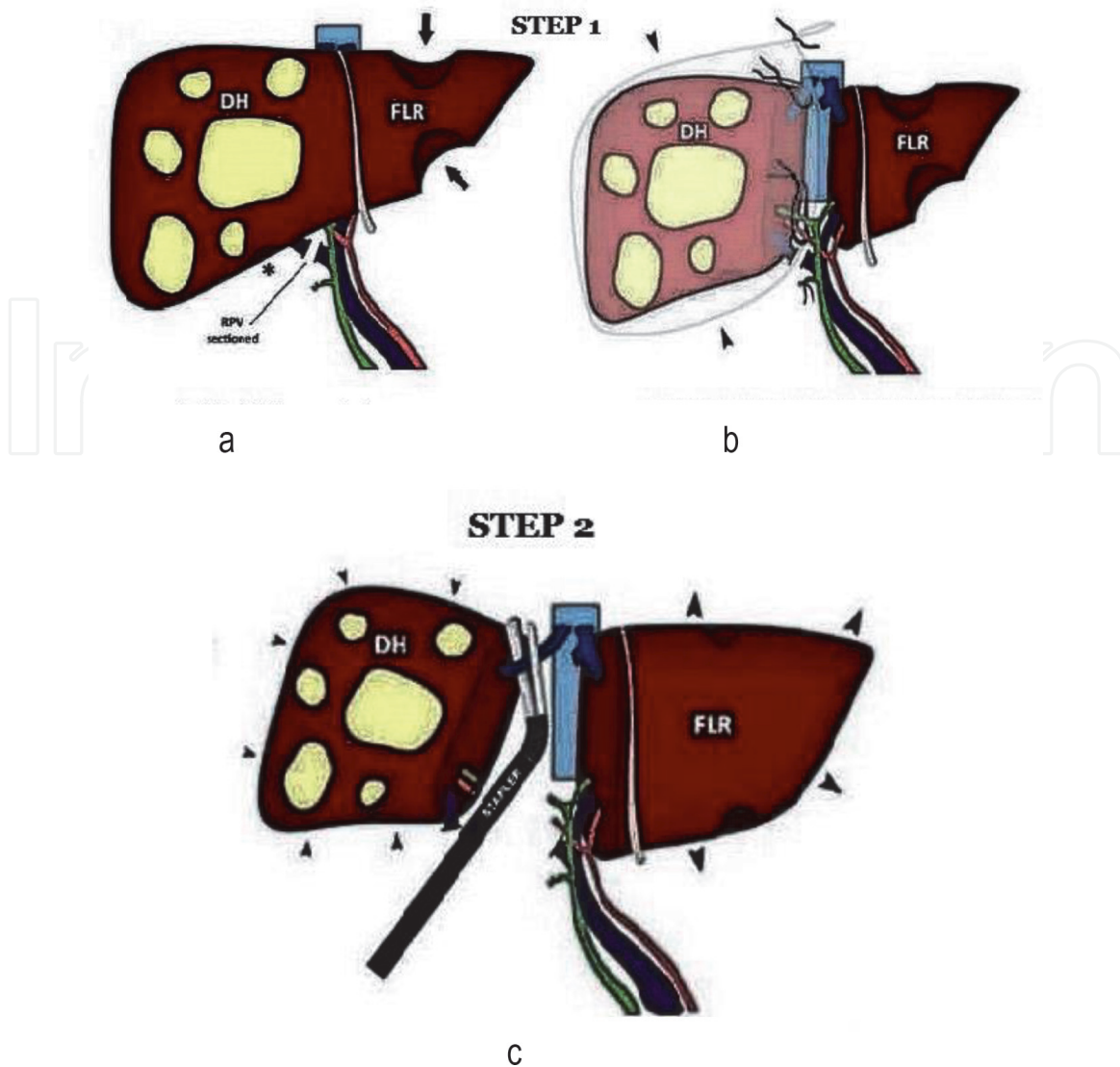


Figure 2.
ALPPS surgical technique ((a) Removal of the left liver metastases, (b) Parenchymal transection and right portal branch ligation, step 1; (c) Liver hypertrophy and parenchymal transection, step 2).

generated several controversies in the surgical community. In fact Schnitzbauer reported a mortality rate of 12% and a morbidity rate of close to 50%.

Over the following years, the technique has been refined trying to better clarify the indications and the various clinical scenarios, leading to steady improvements in safety.

During the 12th Biennial Congress of the European-African Hepato-Pancreato-Biliary Association, in the 10th ALPPS anniversary, some experts discussed indications, management, mechanisms of regeneration, and the pitfalls of the new technique [38].

First of all surgeons emphasized how an accurate knowledge of the vascular liver anatomy (especially that pertaining to the IV^o segment [39]) was fundamental to avoid iatrogenic vascular damage resulting in failure of the procedure. It is necessary to assess liver function in addition to volume to avoid liver postoperative failure that occurred in 14 and 30% after stages 1 and 2, respectively [40]. The discrepancy between liver volume increases (up to 200%), and the high rate of liver failure may be attributed to a lack of maturity of the regenerating hepatocytes [41].

To obtain a proper functional study providing quantitative and visual information of the various regional hepatic districts, scintigraphy using ^{99m}Tc-labeled iminodiacetic acid derivatives should be performed. It provides a regional measure of the function of FLR. The use of scintigraphy for timing of stage 2 in ALPPS was

compared with CT volumetry in 60 patients completing ALPPS in six centers. The results showed that often volumetry overestimated liver function [42].

Some technical aspects to improve ALPPS morbidity have been investigated in the last years. Interesting are the results of some studies on animal models that have evidenced as the reduction up to a minimum of 50% of the hepatic transection led to a rate of regeneration comparable to the complete transection of the parenchyma [43]. Partial transection offers comparable FLR hypertrophy but significantly lower morbidity, when compared with total transection (38.1 vs. 88.9%) and near-zero mortality [44].

Recent studies indicated that the presence of complications after phase 1 is to be considered predictive of mortality after phase 2 [40]. So during the interstage, the occurrence of complications is to be decisive for the outcome after ALPPS. In this respect some limitations in patient selection should be considered: in patients over 65 years of age or with biliary primary disease with associated cholestasis, the procedure should be contraindicated [43]. International ALPPS registry counts only 11 patients in whom the procedure has been performed for perihilar cholangiocarcinoma without obtaining encouraging results (90th mortality of 27%) [45]. Most recently, biliary tumors and elevated serum bilirubin (pre-stage 2) were identified as predictors of futile outcome after ALPPS [43].

With regard to the possible indication of ALPPS for hepatocellular carcinoma, although the liver's regenerative capacity is certainly less than a healthy liver [12], some group experience showed that ALPPS remains a possible approach to achieving an adequate FLR in patients with hepatitis-related hepatocellular carcinoma [46].

Colorectal liver metastases represent the main indications of ALPPS. Currently the mortality of the procedure in patients with colorectal liver metastases stands at 5% with a survival rate at 3 years around 50% [34, 47]. Although the recurrence rate compared to traditional surgery for colorectal liver metastases is high (only 13% of 3-year-old patients are disease-free), ALPPS is a surgical option for these patients otherwise unresectable.

As already mentioned the technique has undergone several modifications since its introduction focused on an attempt to reduce the complications and mortality of the "classic" ALPPS.

The proposed new technical variations have focused their attention on first-stage spitting of the liver parenchyma, on the use of ALPPS for salvage or rescue after TSH, as regard to prevent ischemia of segment IV°, on specific operative maneuvers (Pringle, hanging, anterior approach), on the use of laparoscopic approach at either stage, and on the methods to prevent and identify biliary complications and in the number and position of segments resected [48].

With the term "partial" ALPPS (**Figure 3a–d**), some authors [44, 49] described modification, which provided for the partial transection of the entire transection surface. The latter was carried out from 50–80% of the surface area. The authors reported no difference in liver hypertrophy between partial and full parenchymal splitting (60% vs. 61% median FLR hypertrophy), but a much greater morbidity after the first stage was reported when a full parenchymal split was used.

Associating liver tourniquet and portal ligation for staged hepatectomy (ALTPS). This technique reported in three studies [50–52] provided the positioning of a tourniquet around the future line of transection to ensure a parenchymal compression without having to perform the parenchyma splitting. The authors reported a median FLR growth of 61% over 7 days and a morbidity of 27 and 36% for stage 1 and stage 2, respectively. But a mortality rate of 9% in their series did not reflect a real improvement in terms of the patient's safety. An additional variation indicated with the name of "sequential" ALTPS was proposed by Robles Campos [50]. Unlike

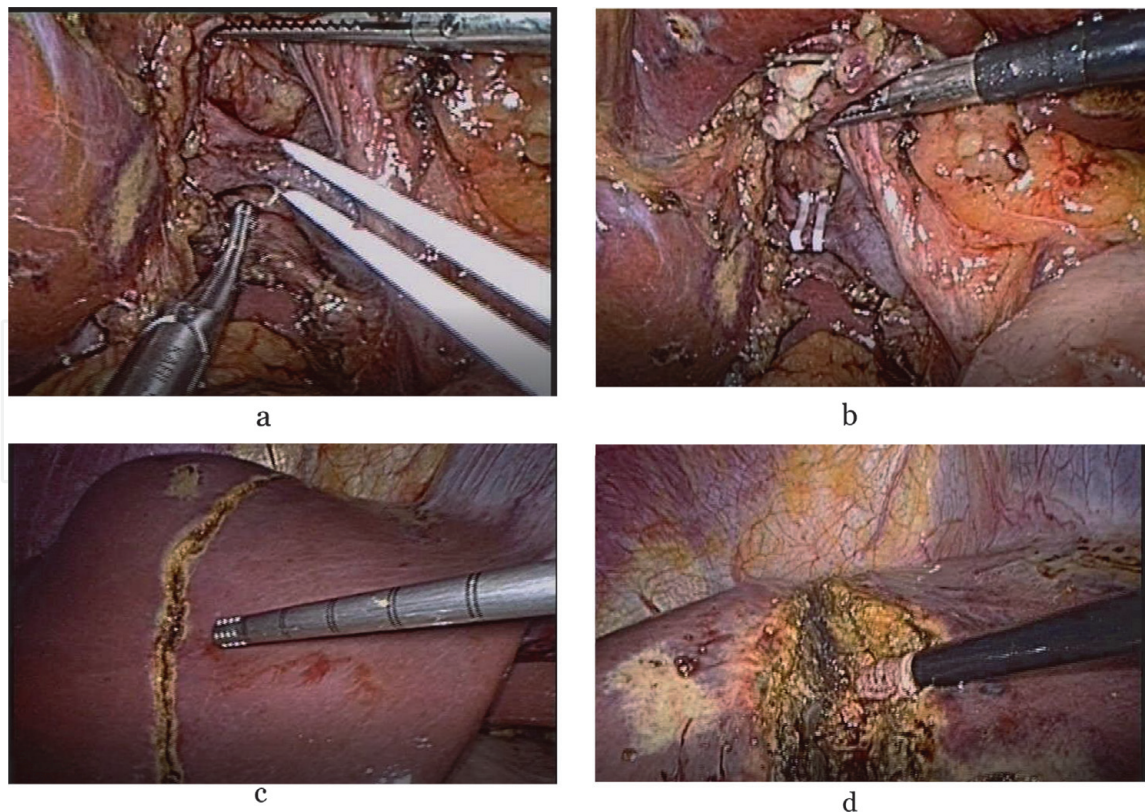


Figure 3.
Surgical steps of laparoscopic “partial ALLPS.” (a) Isolation of the right portal branch. (b) Closing of the right portal branch with Hem-o-lock. (c) Demarcation of the section line. (d) Parenchymal transection.

the previous, they did not provide the portal ligature but the execution of portal embolization in the fourth postoperative days. The authors hypothesized that the delayed cessation of blood flow may be related to a decreased impact and severity of venous congestion in the FLR, possibly attenuating the risk of postoperative liver failure.

Conversion to ALPPS appears successful after both PVE and PVL with acceptable clinical outcomes. No differences in major complications showed by Truant [53] in patients who had no PVE before an in situ split.

There are also various technical measures proposed to avoid ischemia and the possible infectious risk at the level of IV^o segment, recognized as one of the main causes of morbidity and mortality during the execution of ALPPS. Systematic use of antibiotic therapy has been proposed, partial transection was indicated with the role of generating less ischemic damage [54], and in addition, segment IV^o has been resected [55]. Moreover some authors advise to minimize the surgical manipulation of the hepatic hilum to avoid hard surgical adhesions and to minimize the tumor progression during the second phase by means of an anterior approach or Pringle maneuver [46].

Laparoscopic ALPPS has been successfully performed both for two stages. At the expense of an increase in technical difficulty, fewer surgical adhesions were described during the second phase [56]. Although the number of patients treated is very limited, some series report 0% of mortality rate with no major complications and with postoperative hospital stay shorter than the open technique [57]. These results indicate that laparoscopic ALPPS is feasible and it is not inferior to the open approach.

“Hybrid” ALPPS. The technique consists of three main steps [58]: a surgical exploration with the parenchymal split in situ using the anterior approach, the execution of portal embolization using interventional radiology techniques, and

right hepatectomy during the second surgical phase. Special care should be taken not to dissect the right hepatoduodenal ligament, and right liver mobilization should not be performed. The technique involves less manipulation to allow more accurate dissection and a greater oncological effectiveness during the second phase of the procedure. This approach was proposed for tumors involving biliary confluence, but although the technique is considered feasible, long-term survival data are still lacking.

Minimally invasive laparoscopic microwave ablation and portal vein ligation for staged hepatectomy (LAPS). On the basis that treatment with microwave thermal ablation/coagulation (MWA) represents a safe and effective treatment option for primary and metastatic liver malignancy, Gringeri [59] developed a novel ALPPS variation associating minimally invasive laparoscopic PVL and MWA on the future transection plane without in situ splitting. This allowed complete and satisfactory hypertrophy of the nonoccluded FLR (avoiding the development of porto-portal shunts) and an easier second step (liver resection) in a patient with hepatocellular carcinoma. With the use of intraoperative laparoscopic ultrasound guidance, the future transection plane was identified and marked with monopolar cautery. MWA antenna was then infixed into the parenchyma, positioning it at the right of the transection plane, applying a 5-minute ablation cycle. This maneuver was repeated step by step every 3 cm, proceeding from the inferior liver margin to the suprahepatic veins. This technique creates an avascular separation and a necrotic groove between the cancer and the FRL in the future transection plane.

Radiofrequency-assisted liver partition with portal vein ligation (RALPP). This technique first described by Gall [60] uses a radiofrequency ablation device to create a line of coagulative necrosis in the hepatic parenchyma instead of physical transection. In experimental study in animals, the procedure has also been performed percutaneously (*percutaneous radiofrequency-assisted liver partition with portal vein ligation (PRALPPS)*) [61].

Although there are still no data on the long-term outcome, as all surgical techniques developed in recent years, they appear to be feasible, inducing a sufficient hepatic hypertrophy with a lower rate of complications. Their execution, however, remains limited to highly specialized centers in liver surgery.

3. Conclusion

The improvement of surgical techniques made resectable, in selected cases, patients with disseminated liver disease, but the treatment of bilobar liver metastases still remains a surgical challenge. The achievement of an adequate residual liver volume to avoid postoperative liver failure was a key point of the procedures developed in recent decades. Since their birth TSH and ALLPS have undergone several changes in the attempt to reduce the rate of morbidity and mortality, and giant steps have been taken. The future of this surgery will be surely full of further innovations and encouraging for hepatobiliary surgeons, never forgetting that a justified nonoperative approach will always be less invasive than the least invasive surgical approach.

Conflict of interest

All authors declare no conflict of interest.

IntechOpen

Author details

Fabio Uggeri^{1,2*}, Enrico Pinotti^{1,2}, Mattia Garancini², Mauro Scotti², Marco Braga^{1,2}
and Fabrizio Romano^{1,2}

1 School of Medicine and Surgery, University of Milan-Bicocca, Monza, Italy

2 Department of Surgery, San Gerardo Hospital, Monza, Italy

*Address all correspondence to: fabio.uggeri@unimib.it

IntechOpen

© 2019 The Author(s). Licensee IntechOpen. This chapter is distributed under the terms of the Creative Commons Attribution License (<http://creativecommons.org/licenses/by/3.0>), which permits unrestricted use, distribution, and reproduction in any medium, provided the original work is properly cited. 

References

- [1] Makuuchi M, Thai BL, Takayasu K, Takayama T, Kosuge T, Gunven P, et al. Preoperative portal embolization to increase safety of major hepatectomy for hilar bile duct carcinoma: A preliminary report. *Surgery*. 1990; **107**(5):521-527. PMID: 2333592
- [2] de Baere T, Roche A, Elias D, Lasser P, Lagrange C, Bousson V. Preoperative portal vein embolization for extension of hepatectomy indications. *Hepatology*. 1996; **24**(6):1386-1391. DOI: 10.1053/jhep.1996.v24.pm0008938166
- [3] Tanaka H, Hirohashi K, Kubo S, Shuto T, Higaki I, Kinoshita H. Preoperative portal vein embolization improves prognosis after right hepatectomy for hepatocellular carcinoma in patients with impaired hepatic function. *The British Journal of Surgery*. 2000; **87**(7):879-882. DOI: 10.1046/j1365-2168.2000.01439.x
- [4] Wakabayashi H, Okada S, Maeba T, Maeta H. Effect of preoperative portal vein embolization on major hepatectomy for advanced-stage hepatocellular carcinomas in injured livers: A preliminary report. *Surgery Today*. 1997; **27**(5):403-410. DOI: 10.1007/BF02385702
- [5] Adam R, Laurent A, Azoulay D, Castaing D, Bismuth H. Two-stage hepatectomy: A planned strategy to treat irresectable liver tumors. *Annals of Surgery*. 2000; **232**(6):777. PMID: 11088072
- [6] Bismuth H, Adam R, Levi F, et al. Resection of nonresectable liver metastases from colorectal cancer after neoadjuvant chemotherapy. *Annals of Surgery*. 1996; **224**:509-522. PMID: 8857855
- [7] Jaeck D, Oussoultzoglou E, Rosso E, Greget M, Weber JC, Bachellier P. A two-stage hepatectomy procedure combined with portal vein embolization to achieve curative resection for initially unresectable multiple and bilobar colorectal liver metastases. *Annals of Surgery*. 2004; **240**(6):1037. DOI: 10.1097/01.sla.0000145965.86383.89
- [8] Shindoh J, Vauthey JN, Zimmitti G, Curley SA, Huang SY, Mahvash A, et al. Analysis of the efficacy of portal vein embolization for patients with extensive liver malignancy and very low future liver remnant volume, including a comparison with the associating liver partition with portal vein ligation for staged hepatectomy approach. *Journal of the American College of Surgeons*. 2013; **217**(1):126-133. DOI: 10.1012/j.jamcollsurg.2013.03.004
- [9] Schnitzbauer AA, Lang SA, Goessmann H, Nadalin S, Baumgart J, Farkas SA, et al. Right portal vein ligation combined with in situ splitting induces rapid left lateral liver lobe hypertrophy enabling 2-staged extended right hepatic resection in small-for-size settings. *Annals of Surgery*. 2012; **255**(3):405-414. DOI: 10.1097/SLA.0b013e31824856f5
- [10] de Santibanes E, Clavien PA. Playing play-Doh to prevent postoperative liver failure: The "ALPPS" approach. *Annals of Surgery*. 2012; **255**:415-417. DOI: 10.1097/SLA.0b013e318248577d
- [11] Schlegel A, Lesurtel M, Melloul E, Limani P, Tschuor C, Graf R, et al. ALPPS: From human to mice highlighting accelerated and novel mechanisms of liver regeneration. *Annals of Surgery*. 2014; **260**:839-846. discussion 46-7. DOI: 10.1097/SLA.0000000000000949
- [12] Schadde E, Ardiles V, Robles-Campos R, Malago M, Machado M, Hernandez-Alejandro R, et al. Early

survival and safety of ALPPS: First report of the international ALPPS registry. *Annals of Surgery*. 2014;**260**: 829-838. DOI: 0.1097/SLA.0000000000000947

[13] Dahm F, Georgiev P, Clavien PA. Small for size syndrome after partial liver transplantation: Definition, mechanisms of disease and clinical implications. *American Journal of Transplantation*. 2005;**5**(11): 2605-2610. DOI: 10.1111/j.1600-6143.2005.01081.x

[14] Balzan S, Belghiti J, Farges O, Ogata S, Sauvanet A, Delefosse D, et al. The "50-50 criteria" on postoperative day 5: An accurate predictor of liver failure and death after hepatectomy. *Annals of Surgery*. 2005;**242**(6):824. DOI: 10.1097/01.sla.0000189131.90876.9e

[15] Rahbari NN, Garden OJ, Padbury R, Brooke-Smith M, Crawford M, Adam R, et al. Posthepatectomy liver failure: A definition and grading by the international study Group of Liver Surgery (ISGLS). *Surgery*. 2011;**49**(5): 713-724. DOI: 10.1016/j.surg.2010.10.001

[16] Golse N, Bucur PO, Adam R, Castaing D, Cunha AS, Vibert E. New paradigms in post-hepatectomy liver failure. *Journal of Gastrointestinal Surgery*. 2013;**17**(3):593-605. DOI: 10.1007/s11605-012-2048-6

[17] Mullen JT, Ribero D, Reddy SK, Donadon M, Zorzi D, Gautam S, et al. Hepatic insufficiency and mortality in 1,059 noncirrhotic patients undergoing major hepatectomy. *Journal of the American College of Surgeons*. 2007;**204**(5):854-862. DOI: 10.1016/j.jamcollsurg.2006.12.032

[18] Azoulay D, Castaing D, Smail A, Adam R, Cailliez V, Laurent A, et al. Resection of nonresectable liver metastases from colorectal cancer after percutaneous portal vein embolization.

Annals of Surgery. 2000;**231**(4):480. DOI: 10.1097/00000658-200004000-00005

[19] Homayounfar K, Liersch T, Schuetze G, Niessner M, Goralczyk A, Meller J, et al. Two-stage hepatectomy (R0) with portal vein ligation-towards curing patients with extended bilobar colorectal liver metastases. *International Journal of Colorectal Disease*. 2009;**24**(4):409-418. DOI: 10.1007/s00384-008-0620-z

[20] Viganò L, Procopio F, Cimino MM, Donadon M, Gatti A, Costa G, et al. Is tumor detachment from vascular structures equivalent to R0 resection in surgery for colorectal liver metastases? An observational cohort. *Annals of Surgical Oncology*. 2016;**23**(4): 1352-1360. DOI: 10.1245/s10434-015-5009-y

[21] Passot G, Chun YS, Kopetz SE, Zorzi D, Brudvik KW, Kim BJ, et al. Predictors of safety and efficacy of 2-stage hepatectomy for bilateral colorectal liver metastases. *Journal of the American College of Surgeons*. 2016;**223**(1):99-108. DOI: 10.1016/j.jamcollsurg.2015.12.057

[22] Naumov GN, Akslen LA, Folkman J. Role of angiogenesis in human tumor dormancy: Animal models of the angiogenic switch. *Cell Cycle*. 2006;**5**(16):1779-1787. DOI: 10.4161/cc.516.3018

[23] Lam VW, Laurence JM, Johnston E, Hollands MJ, Pleass HC, Richardson AJ. A systematic review of two stage hepatectomy in patients with initially unresectable colorectal liver metastases. *HPB: The Official Journal of the International Hepato Pancreato Biliary Association*. 2013;**15**(7):483-491. DOI: 10.1111/j.1477-2574.2012.00607.x

[24] Rees M, Tekkis PP, Welsh FKS, O'Rourke T, John TG. Evaluation of long term survival after hepatic resection for

metastatic colorectal cancer: A multifactorial model of 929 patients. *Annals of Surgery*. 2008;**247**:125-135. DOI: 10.1097/SLA.0b013e31815aa2c2

[25] Minagawa M, Makuuchi M, Torzilli G, Takayama T, Kawasaki S, Kosuge T, et al. Extension of the frontiers of surgical indications in the treatment of liver metastases from colorectal cancer: Longterm results. *Annals of Surgery*. 2000;**231**:487-499. PMID: 10749608

[26] Abdalla EK, Vauthey JN, Ellis LM, Ellis V, Pollock R, Broglio KR, et al. Recurrence and outcomes following hepatic resection, radiofrequency ablation, and combined resection/ablation for colorectal liver metastases. *Annals of Surgery*. 2004;**239**:818-825. DOI: 10.1097/01.sla.0000128305.90650.71

[27] Narita M, Oussoultzoglou E, Jaeck D, Fuchschuber P, Rosso E, Pessaux P, et al. Two-stage hepatectomy for multiple bilobar colorectal liver metastases. *The British Journal of Surgery*. 2011;**98**(10):1463-1475. DOI: 10.1002/bjs.7580

[28] Wicherts DA, Miller R, de Haas RJ, Bitsakou G, Vibert E, Veilhan LA, et al. Long-term results of two-stage hepatectomy for irresectable colorectal cancer liver metastases. *Annals of Surgery*. 2008;**248**(6):994-1005. DOI: 10.1097/SLA.0b013e3181907fd9

[29] Yokoyama Y, Nagino M, Nimura Y. Mechanisms of hepatic regeneration following portal vein embolization and partial hepatectomy: A review. *World Journal of Surgery*. 2007;**31**(2):367-374. DOI: 10.1007/s00268-006-0526-2

[30] Adam R, Miller R, Pitombo M, Wicherts DA, de Haas RJ, Bitsakou G, et al. Two-stage hepatectomy approach for initially unresectable colorectal hepatic metastases. *Surgical Oncology*

Clinics of North America. 2007;**16**(3): 525-536. DOI: 10.1016/j.soc.2007.04.016

[31] Blazer DG III, Kishi Y, Maru DM, Kopetz S, Chun YS, Overman MJ, et al. Pathologic response to preoperative chemotherapy: A new outcome end point after resection of hepatic colorectal metastases. *Journal of Clinical Oncology*. 2008;**26**(33):5344-5351. DOI: 10.1200/JCO.2008.17.5299

[32] Masi G, Loupakis F, Salvatore L, Fornaro L, Cremolini C, Cupini S, et al. Bevacizumab with FOLFOXIRI (irinotecan, oxaliplatin, fluorouracil, and folinate) as first-line treatment for metastatic colorectal cancer: A phase 2 trial. *The Lancet Oncology*. 2010;**11**(9): 845-852. DOI: 10.1016/S1470-2045(10)70175-3

[33] Tsim N, Healey AJ, Frampton AE, Habib NA, Bansal DS, Wasan H, et al. Two-stage resection for bilobar colorectal liver metastases: R0 resection is the key. *Annals of Surgical Oncology*. 2011;**18**(7):1939-1946. DOI: 10.1245/s10434-010-1533-y

[34] Baumgart J, Jungmann F, Bartsch F, Kloth M, Mittler J, Heinrich S, et al. Two-stage hepatectomy and ALPPS for advanced bilateral liver metastases: A tailored approach balancing risk and outcome. *Journal of Gastrointestinal Surgery*. 2019;**28**:1-10. DOI: 10.1007/s11605-019-04145-9

[35] Simoneau E, Hassanain M, Shaheen M, Aljiffry M, Molla N, Chaudhury P, et al. Portal vein embolization and its effect on tumour progression for colorectal cancer liver metastases. *The British Journal of Surgery*. 2015;**102**(10): 1240-1249. DOI: 10.1002/bjs.9872

[36] Giuliante F, Ardito F, Ferrero A, Aldrighetti L, Ercolani G, Grande G, et al. Tumor progression during preoperative chemotherapy predicts failure to complete 2-stage hepatectomy for colorectal liver metastases: Results of

an Italian multicenter analysis of 130 patients. *Journal of the American College of Surgeons*. 2014;**219**(2): 285-294. DOI: 10.1016/j.jamcollsurg.2014.01.063

[37] Madoff DC, Hicks ME, Abdalla EK, Morris JS, Vauthey JN. Portal vein embolization with polyvinyl alcohol particles and coils in preparation for major liver resection for hepatobiliary malignancy: Safety and effectiveness—Study in 26 patients. *Radiology*. 2003; **227**:251-260. DOI: 10.1148/radiol.2271012010

[38] Lang H, de Santibañes E, Schlitt HJ, Malagó M, van Gulik T, Machado MA, et al. 10th anniversary of ALPPS—Lessons learned and quo Vadis. *Annals of Surgery*. 2019;**269**(1):114-119. DOI: 10.1097/SLA.0000000000002797

[39] Jin GY, Yu HC, Lim HS, Moon JI, Lee JH, Chung JW, et al. Anatomical variations of the origin of the segment 4 hepatic artery and their clinical implications. *Liver Transplantation*. 2008;**14**(8):1180-1184. DOI: 10.1002/lt.21494

[40] Schadde E, Raptis DA, Schnitzbauer AA, Ardiles V, Tschuor C, Lesurtel M, et al. Prediction of mortality after ALPPS Stage-1: An analysis of 340 patients from the international ALPPS registry. *Annals of Surgery*. 2015; **262**(5):780-786. DOI: 10.1097/SLA.0000000000001450

[41] Matsuo K, Murakami T, Kawaguchi D, Hiroshima Y, Koda K, Yamazaki K, et al. Histologic features after surgery associating liver partition and portal vein ligation for staged hepatectomy versus those after hepatectomy with portal vein embolization. *Surgery*. 2016; **159**(5):1289-1298. DOI: 10.1016/j.surg.2015.12.004

[42] Olthof PB, Tomassini F, Huespe PE, Truant S, Pruvot FR, Troisi RI, et al. Hepatobiliary scintigraphy to evaluate

liver function in associating liver partition and portal vein ligation for staged hepatectomy: Liver volume overestimates liver function. *Surgery*. 2017;**162**:775-783. DOI: 10.1016/j.surg.2017.05.022

[43] Linecker M, Kambakamba P, Reiner CS, Nguyen-Kim TDL, Stavrou GA, Jenner RM, et al. How much liver needs to be transected in ALPPS? A translational study investigating the concept of less invasiveness. *Surgery*. 2017;**161**:453-464. DOI: 10.1016/j.surg.2016.08.004

[44] Petrowsky H, Gyori G, de Oliveira M, Lesurtel M, Clavien PA, et al. Is partial-ALPPS safer than ALPPS? A single-center experience. *Annals of Surgery*. 2015;**261**:e90-e92. DOI: 10.1097/SLA.0000000000001087

[45] Serenari M, Zanello M, Schadde E, Toschi E, Ratti F, Gringeri E, et al. Importance of primary indication and liver function between stages: Results of a multicenter Italian audit of ALPPS 2012–2014. *HPB: The Official Journal of the International Hepato Pancreato Biliary Association*. 2016;**18**:419-427. DOI: 10.1016/j.hpb.2016.02.003

[46] Chan AC, Poon RT, Chan C, Lo CM. Safety of ALPPS procedure by the anterior approach for hepatocellular carcinoma. *Annals of Surgery*. 2016;**263**:e14e16. DOI: 10.1097/SLA.0000000000001272

[47] Wanis KN, Ardiles V, Alvarez FA, Tun-Abraham ME, Linehan D, de Santibañes E, et al. Intermediate-term survival and quality of life outcomes in patients with advanced colorectal liver metastases undergoing associating liver partition and portal vein ligation for staged hepatectomy. *Surgery*. 2018;**163**:691-697. DOI: 10.1016/j.surg.2017.09.044

[48] Edmondson MJ, Sodergren MH, Pucher PH, Darzi A, Li J, Petrowsky H,

et al. Variations and adaptations of associated liver partition and portal vein ligation for staged hepatectomy (ALPPS): Many routes to the summit. *Surgery*. 2016;**159**(4):1058-1072. DOI: 10.1016/j.surg.2015.11.013

[49] Alvarez FA, Ardiles V, de Santibanes M, Pekolj J, de Santibanes E. Associating liver partition and portal vein ligation for staged hepatectomy offers high oncological feasibility with adequate patient safety: A prospective study at a single center. *Annals of Surgery*. 2015;**261**:723-732. DOI: 10.1097/SLA.0000000000001046

[50] Robles Campos R, Brusadin R, Lopez Conesa A, Parrilla Paricio P. Staged liver resection for perihilar liver tumors using a tourniquet in the umbilical fissure and sequential portal vein embolization on the fourth postoperative day (a modified ALTPS). *Cirugía Española*. 2014;**92**:682-686. DOI: 10.1016/j.ciresp.2014.07.006

[51] Robles R, Parrilla P, Lopez-Conesa A, Brusadin R, de la Pena J, Fuster M, et al. Tourniquet modification of the associating liver partition and portal ligation for staged hepatectomy procedure. *The British Journal of Surgery*. 2014;**101**:1129-1134. discussion 34. DOI: 10.1002/bjs.9547

[52] Cai X, Peng S, Duan L, Wang Y, Yu H, Li Z. Completely laparoscopic ALPPS using round-the-liver ligation to replace parenchymal transection for a patient with multiple right liver cancers complicated with liver cirrhosis. *Journal of Laparoendoscopic & Advanced Surgical Techniques. Part A*. 2014;**24**: 883-886. DOI: 10.1089/lap.2014.0455

[53] Truant S, Scatton O, Dokmak S, Regimbeau JM, Lucidi V, Laurent A, et al. Associating liver partition and portal vein ligation for staged hepatectomy (ALPPS): Impact of the inter-stages course on morbi-mortality and implications for management.

European Journal of Surgical Oncology. 2015;**41**:674-682. DOI: 10.1016/j.ejso.2015.01.004

[54] Alvarez FA, Ardiles V, Sanchez Claria R, Pekolj J, de Santibanes E. Associating liver partition and portal vein ligation for staged hepatectomy (ALPPS): Tips and tricks. *Journal of Gastrointestinal Surgery*. 2013;**17**: 814-821. DOI: 10.1007/s11605-012-2092-2

[55] Andriani OC. Long-term results with associating liver partition and portal vein ligation for staged hepatectomy (ALPPS). *Annals of Surgery*. 2012;**256**:e5. author reply e16-9. DOI: 10.1097/SLA.0b013e318265fbb

[56] Cillo U, Gringeri E, Feltracco P, Bassi D, D'Amico FE, Polacco M, et al. Totally laparoscopic microwave ablation and portal vein ligation for staged hepatectomy: A new minimally invasive two-stage hepatectomy. *Annals of Surgical Oncology*. 2015;**22**:2787-2788. DOI: 10.1245/s10434-014-4353-7

[57] Machado MA, Makdissi FF, Surjan RC, Basseres T, Schadde E. Transition from open to laparoscopic ALPPS for patients with very small FLR: The initial experience. *HPB: The Official Journal of the International Hepato Pancreato Biliary Association*. 2017;**19**:59-66. DOI: 10.1016/j.hpb.2016.10.004

[58] Li J, Kantas A, Ittrich H, Koops A, Achilles EG, Fischer L, et al. Avoid "all-touch" by hybrid ALPPS to achieve oncological efficacy. *Annals of Surgery*. 2016;**263**(1):e6-e7. DOI: 10.1097/SLA.0000000000000845

[59] Gringeri E, Boetto R, D'Amico FE, Bassi D, Cillo U. Laparoscopic microwave ablation and portal vein ligation for staged hepatectomy (LAPS): A minimally invasive first-step approach. *Annals of Surgery*. 2015;**261**: e42-e43. DOI: 10.1097/SLA.0000000000000606

[60] Gall TM, Sodergren MH, Frampton AE, Fan R, Spalding DR, Habib NA, et al. Radio-frequency-assisted liver partition with portal vein ligation (RALPP) for liver regeneration. *Annals of Surgery*. 2015;**261**:e45-e46. DOI: 10.1097/SLA.0000000000000607

[61] Gimenez ME, Houghton EJ, Davrieux CF, Serra E, Pessaux P, Palermo M, et al. Percutaneous radiofrequency assisted liver partition with portal vein embolization for staged hepatectomy (pralpps). *ABCD: Arquivos Brasileiros de Cirurgia Digestiva (São Paulo)*. 2018;**31**(1):e1346. DOI: 10.1590/0102-672020180001e1346

IntechOpen