

We are IntechOpen, the world's leading publisher of Open Access books Built by scientists, for scientists

4,800

Open access books available

122,000

International authors and editors

135M

Downloads

Our authors are among the

154

Countries delivered to

TOP 1%

most cited scientists

12.2%

Contributors from top 500 universities



WEB OF SCIENCE™

Selection of our books indexed in the Book Citation Index
in Web of Science™ Core Collection (BKCI)

Interested in publishing with us?
Contact book.department@intechopen.com

Numbers displayed above are based on latest data collected.
For more information visit www.intechopen.com



Root Canal Morphology and Anatomy

Esra Pamukcu Guven

Abstract

Success in root canal treatment depends on the proper application of all procedures of root canal treatment. This wholistic approach includes leakproof crown restoration, following ideal instrumentation, irrigation and hermetic obturation. Therefore, the first step of root canal treatment begins with understanding the tooth morphology in detail. The teeth vary according to their localization at the jaws and the gender and race of people. Detection of the extra canals, canal curvatures, isthmuses and lateral and accessory canals plays an important role in the success of root canal treatment. With all this, the academic knowledge and proficiency of the dentist and/or endodontist enable tooth morphology to be more clearly understandable.

Keywords: tooth morphology, root canal morphology, dental anatomy, technologic devices, illumination and magnification systems

1. Introduction

Understanding the anatomy of the root canal system is essential for a successful root canal treatment. Complexity of root canals depends on reasons such as ethnicity, gender, age, the existence of lateral/accessory canals, isthmuses, the location of the teeth at the jaws and anomalies of the teeth (dens invaginatus, dens evaginatus, fusion, gemination, dens in dente). Besides all of these, some physiological alterations occur in enamel and dentin with age. Mineralization of dentin results in calcification of dentinal tubules; thus, dentin becomes sclerotic. Several difficulties occur during root canal treatment in such cases. The utilization of novel technologic equipments for magnification and lightning of the root canal system like dental microscope, loupe, radiographic visualization systems and cone beam computed tomography (CBCT) in dentistry enlightens endodontic treatment [1].

2. Maxillary incisor teeth

Maxillary central teeth have one root and one main canal [2]. Rarely, at 6% rate one canal of maxillary central teeth is divided into two parts at the apical foramina which can be classified as Vertucci type V (**Figure 1**). Apical root canal anatomy should be regarded because of its main effect on the success of root canal treatment (**Figure 2**). In the study of Adorno et al. [3], accessory canals in the apical 3 mm at Japanese population were found in 46% of the specimens.

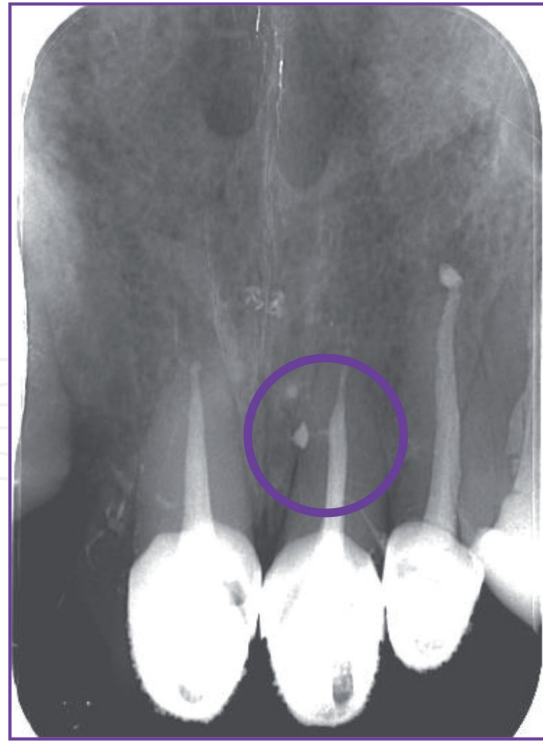


Figure 1.
Endodontic treatment of a maxillary left first incisor tooth with lateral canal.

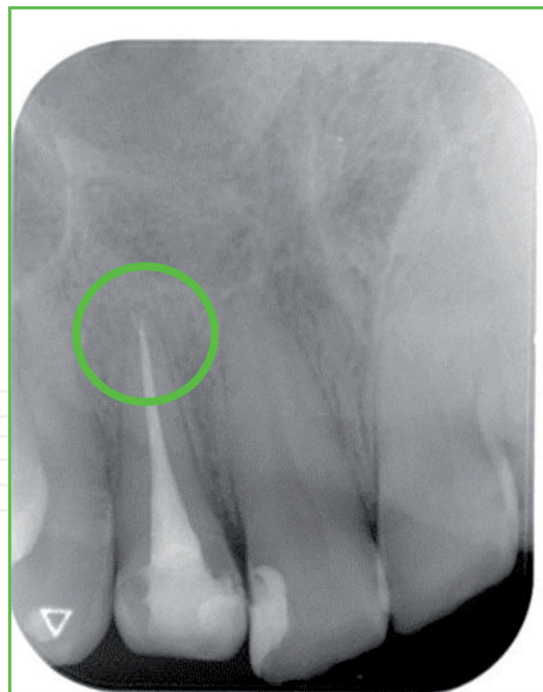


Figure 2.
Accessory canals in the apical 3 mm of the root.

According to Vertucci's classification, maxillary lateral incisor teeth have one main canal (100%) [2]. Generally, maxillary lateral incisor teeth are single-rooted with a single canal [4]. The apex of the maxillary lateral teeth is positioned at the palatal side. In the study of Adorno et al. [3], among Japanese population, accessory canals in the apical 3 mm were found in 29% of the specimens.

3. Maxillary canine teeth

According to Vertucci's classification, maxillary canine teeth have one main canal (100%) [2]. In the study of Adorno et al. [3], among Japanese population, accessory canals in the apical 3 mm related with the maxillary canine teeth were found in 38% of the specimens. The endodontic cavity should be prepared at the palatal side of the tooth in oval shape in these teeth.

4. Maxillary premolar teeth

In the study of Tian et al. [5], it was found that in Chinese population, 66% of the premolar teeth had one root, 33% had two roots and 1% had three roots. According to Vertucci's classification, root canal morphology is classified into eight types:

Type I: One canal extending to the apex.

Type II: One canal beginning from the pulp chamber, dividing into two parts at the 1/3 middle of the root and then ending in one part at the apex.

Type III: One canal leaving the pulp chamber, dividing into two and ending as one canal by merging.

Type IV: Two canals leaving the pulp chamber and ending as two separate canals.

Type V: One canal leaving the pulp chamber and dividing into two distinct canals with separate apical foramina.

Type VI: Two separate canals leaving the pulp chamber, merging in the 1/3 of the root canal and then separating to exist as two distinct canals.

Type VII: One canal leaving the pulp chamber, merging in the 1/3 of the root canal and then separating to exist as two distinct canals.

Type VIII: Three separate, distinct canals extend from the pulp chamber to the apex.

According to Weine (1976), the classifications are divided into four groups as:

Type I: One canal extending as one canal to the apex.

Type II: Two separate canals leaving from the pulp chamber and merging at the 1/3 of the apex.

Type III: Two canals leaving the pulp chamber and extending as two canals to the foramen.

Type IV: One canal leaving from the pulp chamber, dividing into two parts at the 1/3 middle of the root and extending as two canals to the apex.

In the study of Pan et al. [6], the prevalence of maxillary first premolar teeth with one main root canal was 67.8%, with two roots was 31.9% and with two canals was 88.2%. In Malaysian population, according to Vertucci's classification, second premolars were detected to be single-rooted with type I in the 58.2% incidence [2]. Based on the detection of premolars in molar shape, the endodontic cavity of the maxillary premolar teeth should begin to be prepared as "T-shaped" on the occlusal surface instead of oval shape. In these teeth, two root canal orifices are at the buccal side, and one is at the palatal side [7].

5. Maxillary molar teeth

The upper first molar teeth have three roots and three or four canals (palatal, mesiobuccal 1 (MB1), mesiobuccal 2 (MB2) and disto-buccal (DB)). In the study of Kumar et al. [8], the upper molar teeth were shown to have seven canals. At Burmese population, the prevalence of two canals in mesiobuccal roots of the upper first molar teeth decreases towards the upper third molar teeth. Around 85.2% of

270 roots of the upper molar teeth have one canal in one root at the apex, 14% have two canals at the apex and 0.8% have three canals at the apex [9]. According to Pan et al. [6], a second palatal canal was detected in 0.9% in the maxillary first molar teeth in Malaysian population. Ninety-one percent of mesiobuccal roots of maxillary first molars was detected to have accessory canals [10, 11]. Accessory canals with 85% of incidence were found to be located in the apical third of the roots [10]. According to micro-computed tomography analysis of the mesiobuccal root canal anatomy referring to second mesiobuccal canals of maxillary first molar tooth, the results were in 60% in accordance with Weine et al.'s (1969) classification and in 70% with Vertucci's (1984) classification [10].

Mikrogeorgis et al. [12] determined two root canals in conjunction with the apex. In addition, as the morphological differences determined related with the mesiobuccal root of upper molar teeth, distal root has also been detected to have two separate canals; distobuccal 1 (DB1) & distobuccal 2 (DB2) as shown in **Figure 3**.

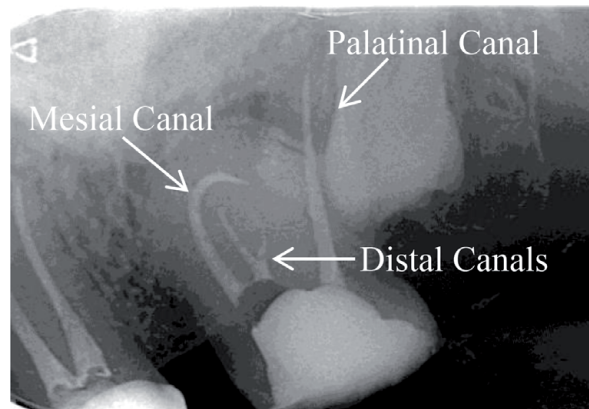


Figure 3.
The radiograph of a maxillary second molar tooth with two distal canals.

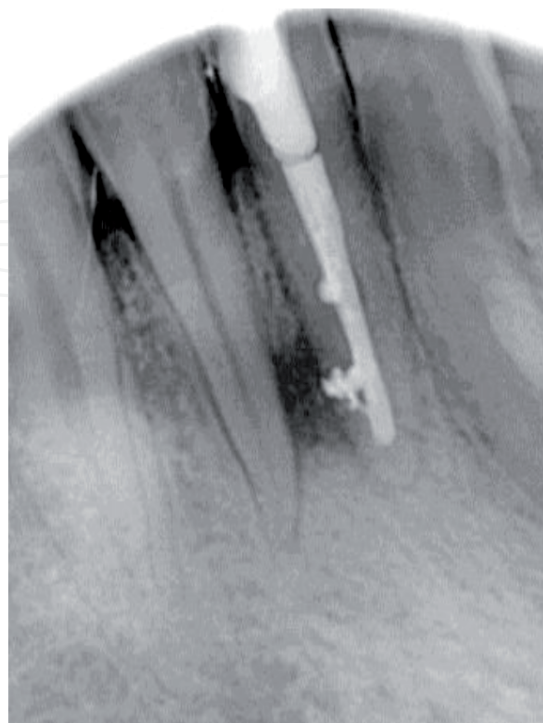


Figure 4.
Endodontic treatment of a mandibular right first incisor tooth with a lateral canal.

6. Mandibular incisors

In the study of Sert et al. [17], in Turkish population, it was pointed out that 68% of mandibular central incisors have two canals and 6.5% have lateral canals. In addition, in the same study, it was pointed out that 63% of mandibular lateral incisors had two canals and the prevalence of lateral canals was 13% in Turkish population. Mandibular first incisor tooth with a lateral canal is seen in **Figure 4**.

7. Mandibular canine teeth

According to a morphological study of Soleymani et al. [18], in the Iranian population, 89.7% of the mandibular canine teeth were found to have type I, 5.7% had type III, 3.7% had type II and 1% had type V morphology.

8. Mandibular premolar teeth

The endodontic cavity has to be prepared in oval shape on the occlusal surface of the premolar teeth regarding the localization of root canal orifices. In Turkish population, 62% of the mandibular premolar teeth have one main root canal [17]. Vertucci found out a second canal in 26% of the mandibular first premolars and 3% at the second premolars [2]. In Turkish population, 71% of the mandibular second premolars have one main root canal [17].

9. Mandibular Molar teeth

According to Vertucci's classification, 44% of the mesial roots of the mandibular first molar teeth were found to be type I, whilst 54% were type II. Al-Qudah et al. [16] reported that in Jordanian population, the mandibular first molar teeth had three canals (48%) and four canals (46%). The frequency of the mesial root canals' combination in the first (56, 34%) and second (67, 41%) mandibular molars is more common in three-rooted teeth than four-rooted teeth [19]. Huang et al. [20] pointed out that the incidence of mandibular first molars with two, three and four roots was 55.5, 26.5 and 18.0%, respectively. They also added that double-rooted distal root was associated with two mesial canals. In a CBCT assessment study of mandibular molars, the distance from the apex to the canal orifice is found to be 13.15 mm [21]. The existence of isthmus is a type of morphological difference seen in mandibular molar teeth. Endodontic treatment of a mandibular right first molar tooth with an isthmus located between the mesiobuccal and the mesiolingual canals is seen in **Figure 5**.

The results of a study evaluating the root canals of the mandibular second molar teeth showed that 76% of the two-rooted mandibular second molars had a single distal canal and 87.5% had two mesial canals that combined apically with the prevalence of 53% [17]. In South Asian Pakistani population, the mesial roots of the mandibular molar teeth were found to have two canals (97%), whereas the distal roots had single canals (50%) [22]. In the study of Al-Qudah et al. [16], the incidence of three canals in Jordanian mandibular second molars was reported as 58%, two canals as 19% and four canals as 17%. Gulabivala et al. [23] reported that 68% of Thai mandibular molars had two distinct roots and 20% had fused roots.

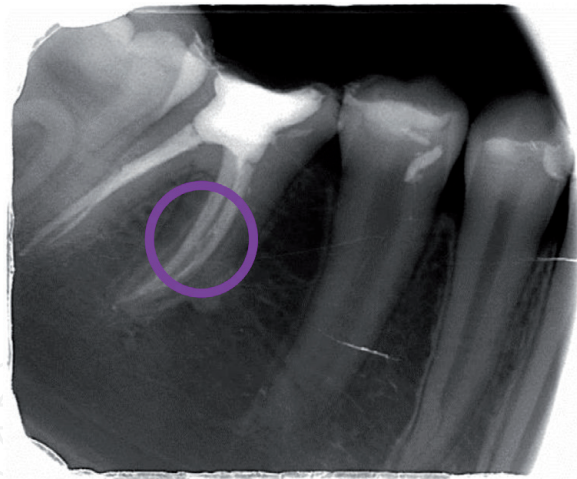


Figure 5.
Endodontic treatment of a mandibular right first molar tooth with an isthmus located between the mesiobuccal and the mesiolingual canals.

10. C-shaped root Canals

C-shaped root canals' anatomy is defined as the connection of two distal roots internally and C-shaped appearance panoramically. C-shaped root canals can be observed in the upper and lower first and second molar teeth. They are seen at high rates in the mandibular second molar teeth in Asian population. The treatment of C-shaped root canals needs more care because of their wide, oval and complex anatomy and the bleeding potential of wide pulpal tissue. In the study of Kim et al. [13], the problems with the treatment of C-shaped root canals were found as unsuccessful sealing ability of the canal (45.2%), overlooked canal (9.5%), overfilling (7.1%) and iatrogenic problems (7.1%).

Irrigation protocols have significant importance for removing pulpal remnants and hard tissue debris, especially for the unreachable points in the root canals [4]. The morphology of C-shaped root canals may result in elbows during root canal shaping in curved canals. The percentages of elbow formation were reported as 42.1% in C form canals, 40.0% in J form canals and 19.3% in straight form canals. Zip formation was observed in 83.5% of C form canals [14]. Eighty percent of C-shaped root canals were found to have 1–3 apical foramina [15]. In Malaysian population, the C-shaped root canals were found to have 48.7% of incidence [6]. In Jordanian population the mandibular second molar teeth had C-shaped roots in 10% of incidence [16].

11. Dental anomalies

Dental morphological anomalies accompany some growth and developmental abnormalities. Dens invaginatus, dens evaginatus, dens in dente, fusion and gemination are among the often seen dental anomalies. Dental anomalies could also be associated with syndromes, such as Down syndrome.

Dens invaginatus is determined as an infolding of dentin and enamel extending into the pulp chamber. In a case report of Kottoor et al. [24], a maxillary lateral incisor was found to have four main canals called distal, labial, mesial and lingual in a dens invaginatus case. Dens invaginatus is more often characterized with an immature tooth with a periapical lesion. The decision on treatment type depends on the tooth's morphological situation. This pathology is treated by regenerative procedures in which root dentin thickness and newly developed apical foramina are expected.

In a morphology study conducted among individuals with Down syndrome, it was reported that all teeth, except mandibular first premolars, showed significantly shorter crown and root lengths [25]. This information is valuable during making a decision of the crown restoration type regarding the crown-root proportions.

12. Conclusion

Focusing on the tooth morphology considering root canal complexity allows dentists to perform successful root canal treatment. Besides the dentists' knowledge and interest in root canal morphology and anatomy, proficiency on root canal treatment and the tendency to use novel technological devices enable prosperous endodontic treatment. The novel tooth morphology classification presented by Ahmed and Dummer, based on the simplicity and clarity respecting tooth number, number of roots and root canal configuration types, is the prominent leading literature for dentistry [26].

IntechOpen

Author details

Esra Pamukcu Guven
Faculty of Dentistry, Department of Endodontics, Istanbul Okan University,
Istanbul, Turkey

*Address all correspondence to: esra.pamukcu@okan.edu.tr

IntechOpen

© 2019 The Author(s). Licensee IntechOpen. This chapter is distributed under the terms of the Creative Commons Attribution License (<http://creativecommons.org/licenses/by/3.0>), which permits unrestricted use, distribution, and reproduction in any medium, provided the original work is properly cited. 

References

- [1] Peters OA, Laib A, Göhring TN, Barbakow F. Changes in root canal geometry after preparation assessed by high resolution computed tomography. *Journal of Endodontia*. 2001;27:1-6
- [2] Vertucci FJ. Root canal anatomy of the human permanent teeth. *Oral Surgery, Oral Medicine, and Oral Pathology*. 1984;58:589-599
- [3] Adorno CG, Yoshioka T, Suda H. Incidence of accessory canals in Japanese anterior maxillary teeth following root canal filling *ex vivo*. *International Endodontic Journal*. 2010;43:370-376
- [4] Konstantinidi E, Psimma Z, Chavez de Paz LE, Boutsoukis C. Apical negative pressure irrigation versus syringe irrigation: A systematic review of cleaning and disinfection of the root canal system. *International Endodontic Journal*. 2017;50:1034-1054
- [5] Tian Y-Y, Guo B, Zhang R, Yu X, Wang H, Hu T, et al. Root and canal morphology of maxillary first premolars in a Chinese subpopulation evaluated using cone-beam computed tomography. *International Endodontic Journal*. 2012;45:996-1003
- [6] Pan JYY, Parolia A, Chuah SR, Bhatia S, Mutalik S, Pau A. Root canal morphology of permanent teeth in a Malaysian subpopulation using cone beam computed tomography. *BMC Oral Health*. 2019;14:1-15
- [7] Sieraski SM, Taylor GT, Kohn RA. Identification and endodontic management of three-canal maxillary premolars. *Journal of Endodontia*. 1989;15:29-32
- [8] Kumar R. Report of a rare case: A maxillary first molar with seven canals confirmed with cone-beam computed tomography. *Iranian Endodontic Journal*. 2014;9(2):153-157
- [9] Ng Y-L, Aung TH, Alavi A, Gulabivala K. Root and canal morphology of Burmese maxillary molars. *International Endodontic Journal*. 2001;34:620-630
- [10] Verma P, Love RM. A micro CT study of the mesiobuccal root canal morphology of the maxillary first molar tooth. *International Endodontic Journal*. 2011;44:210-217
- [11] Gu Y, Lee JK, Spangberg LS, Lee Y, Park CM, Seo DG, et al. Minimum-intensity projection for in depth morphology study of mesiobuccal root. *Oral Surgery, Oral Medicine, Oral Pathology, Oral Radiology, and Endodontics*. 2011;112:671-677
- [12] Mikrogeorgis G, Lyroudia KL, Nikopoulos N, Pitas I, Molyvdas I, Lambrianidis TH. 3D computer-aided reconstruction of six teeth with morphological abnormalities. *International Endodontic Journal*. 1999;32:88-93
- [13] Kim Y, Lee D, Kim DV, Kim SY. Analysis of cause of endodontic failure of C-shaped root canals. *Scanning*. 2018:1-7. DOI: 10.1155/2018/2516832
- [14] Nagy CD, Bartha K, Berna M, Verdes E, Szabo J. The effect of root canal morphology on canal shape following instrumentation using different techniques. *International Endodontic Journal*. 1997;30:133-140
- [15] Cheung GSP, Yang J, Fan B. Morphometric study of the apical anatomy of C-shaped root canal systems in mandibular second molars. *International Endodontic Journal*. 2007;40:239-246
- [16] Al-Qudah AA, Awawdeh LA. Root and canal morphology of mandibular first and second molar teeth in a Jordanian population. *International Endodontic Journal*. 2009;42:775-784

- [17] Sert S, Aslanalp V, Tanalp J. Investigation of the root canal configurations of mandibular permanent teeth in the Turkish population. *International Endodontic Journal*. 2004;**37**:494-499
- [18] Soleymani A, Namaryan N, Moudi E, Gholinia A. Root canal morphology of mandibular canine in an Iranian population: A CBCT assessment. *Iranian Endodontic Journal*. 2017;**12**(1):78-82
- [19] Furri M. Differences in the confluence of mesial canals in mandibular molar teeth with three or four root canals. *International Endodontic Journal*. 2008;**41**:777-780
- [20] Huang R-Y, Cheng W-C, Chen C-J, Lin C-D, Lai T-M, Shen E-C, et al. Three-dimensional analysis of the root morphology of mandibular first molars with Disto-lingual roots. *International Endodontic Journal*. 2010;**43**:478-484
- [21] Gambarini G, Ropini P, Piasecki L, Costantini R, Carneiro E, Testarelli L, et al. A preliminary assessment of a new dedicated endodontic software for use with CBCT images to evaluate the canal complexity of mandibular molars. *International Endodontic Journal*. 2018;**51**:259-268
- [22] Wasti F, Shearer AC, Wilson NHF. Root canal systems of the mandibular and maxillary first permanent molar teeth of south Asian Pakistanis. *International Endodontic Journal*. 2001;**34**:263-266
- [23] Gulabivala K, Opasanon A, Ng Y-L, Alavi A. Root and canal morphology of Thai mandibular molars. *International Endodontic Journal*. 2002;**35**:56-62
- [24] Kottoor J, Murugesan R, Albuquerque DV. A maxillary lateral incisor with four root canals. *International Endodontic Journal*. 2012;**45**:393-397
- [25] Kelsen AE, Love RM, Kieser JA, Herbison P. Root canal anatomy of anterior and premolar teeth in Down's syndrome. *International Endodontic Journal*. 1999;**32**:211-216
- [26] Ahmed HMA, Dummer PMH. A new system for classifying tooth, root and canal anomalies. *International Endodontic Journal*. 2018;**51**:389-404