

# We are IntechOpen, the world's leading publisher of Open Access books Built by scientists, for scientists

**4,800**

Open access books available

**122,000**

International authors and editors

**135M**

Downloads

Our authors are among the

**154**

Countries delivered to

**TOP 1%**

most cited scientists

**12.2%**

Contributors from top 500 universities



**WEB OF SCIENCE™**

Selection of our books indexed in the Book Citation Index  
in Web of Science™ Core Collection (BKCI)

Interested in publishing with us?  
Contact [book.department@intechopen.com](mailto:book.department@intechopen.com)

Numbers displayed above are based on latest data collected.

For more information visit [www.intechopen.com](http://www.intechopen.com)



# Paraneoplastic Pemphigus Is a Life-Threatening Disease

*Richard Lucas Konichi-Dias*

## Abstract

Paraneoplastic pemphigus is a multiorgan autoimmune disease, usually triggered by neoplasias, mainly of lymphoproliferative origin such as chronic lymphocytic leukemia, multiple myeloma, non-Hodgkin's lymphoma, Castleman disease, and thymoma. This disorder is characterized by the presence of auto-antibodies that react against proteins, such as desmoplakins, desmocollins, and others existing in cell junctions. The prognosis is reserved, and the mortality rate of the disease is very high, thus proving to be an additional challenge in the therapeutic management of onco-hematological diseases. The objective of this chapter is to solve the main clinical aspects of paraneoplastic pemphigus in lymphoproliferative hematological diseases, anatomopathological and immunofluorescence characteristics, as well as associations with the main differential diagnoses and therapeutic management. We will also describe the main differential diagnoses of paraneoplastic pemphigus, such as various types of pemphigus including induced drug, bullous pemphigoid, drug eruption, lichen planus, graft versus host disease, erythema multiforme, Stevens-Johnson syndrome, and toxic epidermal necrolysis. In addition, the prognosis and quality of life will be mentioned.

**Keywords:** paraneoplastic pemphigus, neoplasms disease, autoimmune disease

## 1. Introduction

Paraneoplastic pemphigus (PNP) was first described in 1990 by Anhalt et al. as a rare autoimmune disease that causes ulcerated lesions and vesicular eruptions in the mucocutaneous regions [1]. In 2001, the researcher Nguyen et al. introduced the term multiorgan autoimmunity paraneoplastic syndrome, since it is a systemic disease that can affect the kidneys, bladder, and smooth and striated muscles [2]. PNP is a disease triggered mainly by B-cell lymphomas and malignant hematological diseases [3]. Other neoplasms also demonstrate the onset of this disease, as well as carcinoma of the stomach, lung, and colon [3]. The patients with PNP present high mortality rates, being around 90% of the cases, besides presenting an extremely complex and difficult diagnosis, since it resembles several other diseases [4, 5]. The treatment and management of this disease are often ineffective, as it is an extremely aggressive and lethal disease.

In this chapter, we will address the epidemiological aspects, the main triggers, pathophysiology, main manifestations, diagnosis, differential diagnoses, treatments used, prognosis, and the quality of life of patients affected by PNP.

## 2. Epidemiology

Because PNP is an extremely rare disease, there is still no data on the incidence of this disease in the world population [3]. To date, about 500 cases have been reported in the literature, with PNP representing 3–5% of all cases of pemphigus in the population [6–8]. The vast majority of affected patients demonstrate lymphoproliferative disorders (LPD) [9]. Although this disease can affect children and adolescents, the most common age group is between 45 and 70 years of age and is not correlated with place of origin, race, and sex [7, 10–14].

## 3. Association with malignancy and genetic background

PNP can be triggered by several types of neoplasias; however, about 84% of all patients present neoplasias or hematological disorders [3, 7, 15]. Non-Hodgkin's lymphoma is the most common disorder with 38.6% of cases, followed by chronic lymphocytic leukemia and Castleman disease with 18.4% each (**Table 1**). Among the non-hematological neoplasms, sarcomas present approximately 8.6% of the cases, such as leiomyosarcoma, malignant nerve sheath tumor, poorly differentiated sarcoma, reticular cell sarcoma, dendritic cell sarcoma, liposarcoma, and inflammatory myofibroblastoma [15–17]. Other less common diseases described in the literature that provide PNP are malignant thymoma, squamous cell carcinoma of the esophagus, colon carcinoma, CD8+ T-cell lymphoma, retroperitoneal Kaposi's sarcoma, and lymphoepithelioma-like carcinoma [18–23]. Although the PNP is triggered by several neoplasias, the manifestations of this disease may precede the hematological disorders and other malignancies, thus requiring the frequent and continuous follow-up of these patients [15]. In addition, there are reports of the occurrence of PNP without a detecting the cause [24, 25].

It is known that the major histocompatibility complex (MHC) has important relationships in increasing the susceptibility of autoimmune diseases. Although there are few papers that analyze the relationship between PNP and genetics, some studies in the Caucasian and Chinese population showed the relationships of the HLA class II alleles DRB1\*03 and HLA-Cw\*14 in the PNP's trigger [26, 27]. HLA-Cw\* 14 proved to be a more specific allele type of PNP. Its importance has been associated with PNP, regardless of whether it is a Castleman disease or other tumors, in addition to Castleman disease. [26]. However, to date, these studies are preliminary studies that suggest the association between genetic factors and PNP. To better understand this relationship, it is important to conduct studies with larger numbers of patients and that are affected by different tumors, as well as the realization of this association in different populations.

Neoplasms	Frequencies (%)
Non-Hodgkin's lymphoma	38.6
Chronic lymphocytic leukemia	18.4
Castleman disease	18.4
Sarcoma	8.6
Others	16

**Table 1.**  
*Paraneoplastic pemphigus associated with neoplasms.*

## 4. Pathogenesis

PNP even being a disease not yet known at the present time, it is known that both autoantibodies, as cell-mediated immunity, are involved [28]. Certainly, it deduces that the immune system is paramount in the pathophysiology of this disease.

### 4.1 Autoantibodies

PNP triggers immune changes with the production of autoantibodies capable of acting on various proteins in the body. The major target proteins of the autoantibodies are desmoglein 1 (DSG-1) and desmoglein 3 (DSG-3); desmocollins 1, 2, and 3; desmoplakins 1 and 2; BP230; BP130; and envoplakin, in addition to several other epitopes affected by autoantigens found in the individual [29]. These characteristics demonstrate the immunological complexity of the disease.

Proteins of the plakin family, such as desmoplakins 1 and 2, envoplakin, periplakin, plectin and BP230, demonstrate the major targets of autoantibodies [30]. In contrast, the proteins of the cadherin family are the second most affected, with proteins such as DSG-1 and DSG-3 and desmocollin [31]. It is known that the presence of autoantibodies to some proteins are not related to the clinical practice of the patients, although there is a study that has mentioned DSG-3 relation with genital involvement [32].

Other autoantibodies such as alpha-2 macroglobulin-like 1 (A2ML1), a broad-range protease inhibitor, have been shown to be important in some patients. This protein has been shown to increase in the oral mucosa, intestine, esophagus, and muscles. However, its true function in the epithelium is unknown [33, 34].

PNP studies with tumor resection demonstrate that tumors have the capacity to secrete autoantibodies capable of affecting the proteins of the epidermal region [35]. While knowing that most PNPs are involved in neoplastic and LPD diseases, triggering by solid tumors is still poorly understood and demonstrates other mechanisms involved in the production of autoantibodies to plakin proteins.

The involvement of the humoral immunity of PNP presents the desmoplakins 1 and 2, envoplakin, periplakin, BP230, A2ML1, and DSG-1 and DSG-3 as the main proteins of concern [1]. However, 16% of all affected do not demonstrate the presence of these autoantibodies, and this makes, in some cases, the accomplishment of the early diagnosis difficult. A study conducted in patients with PNP and who developed muscle weakness demonstrated autoantibodies against neuromuscular junction proteins and muscle tissue. These muscle-associated proteins were autoantibodies to anti-acetylcholinesterase receptors and anti-titin and anti-ryanodine receptor [36].

### 4.2 Cellular immunity

Cellular immunity has evidenced important roles in the immunophenotyping of PNP. Pathological analyses have demonstrated inflammatory infiltrates with the presence of CD8+ T cells, CD68+ monocytes, and non-major histocompatibility complex-restricted CD56+ in the subepidermal region [2, 37]. Besides that, in the places of affection, the increase in tumor necrosis factor, as well as interferon gamma, was evidenced [38]. These findings show the importance of cellular immunity in the pathogenesis of the disease, since they present abundantly in the sites of PNP involvement.

## 5. Clinical features

PNP presents several symptoms and clinical evolutions. The first symptoms as well as the progression of the disease are very varied from one patient to another. However, there are more frequent clinical features of these individuals.

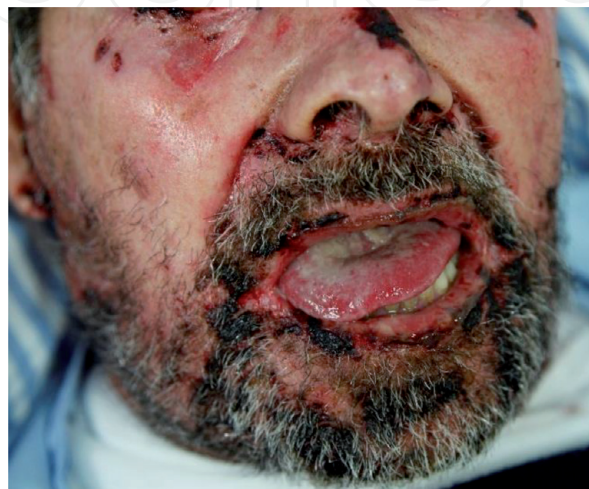### 5.1 Oral lesions

The oral mucosa is often affected in patients with PNP [3, 39, 40]. Oral symptoms may be the first symptoms in these patients, even before skin lesions [41]. The most common symptoms are oral and labial erosions with bleeding that may be associated with blisters, macules, papules, vesicles, and erythema (**Figure 1**). In addition, these patients may present a positive Nikolsky sign [41].

PNP lesions may be similar to oral manifestations of other diseases. Pemphigus vulgaris is a disease that initially triggers blisters and ulcers in the oral mucosa (especially on the cheeks) and may even reach the body. Erythema multiforme also affects the region of the oral mucosa with the appearance of erythema, edema, and some superficial erosions with formation of pseudomembrane. Lichen planus causes erythematous lesions where Wickham striae are present and may in rare cases develop erosions. In most cases of oral lichen planus, these are asymptomatic manifestations with few complications. Even though these diseases show some similarity to PNP, they are less aggressive, lethal, painful, and incapacitating, with less ability to spread to all mucosal and other body sites when compared to PNP [28, 42, 43].

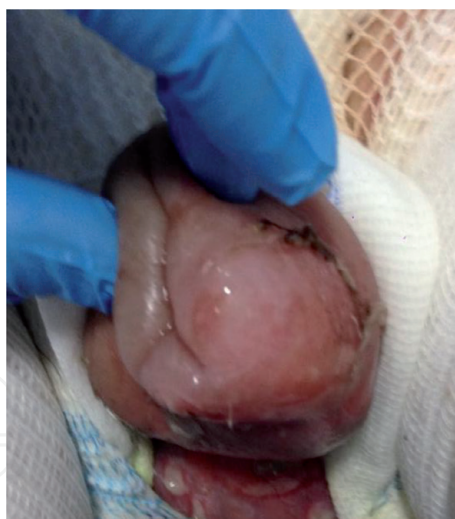### 5.2 Secondary mucosal lesions

Lesions can also affect regions such as the oropharynx, esophagus, stomach, duodenum, large intestine, conjunctiva, and anogenital region [2, 3, 7, 39, 41, 44, 45]. The involvement of the oropharynx and esophagus commonly triggers painful sensations and dysphagia [4]. The anogenital lesions demonstrate red-violet erythema in the glans or its surroundings (**Figure 2**). In some cases, lichen planus presents a possible differential diagnosis. However, unlike red-violet lesions, lichen planus forms linear white streaks that may arise in the glans, scrotum, and vulva, in addition to the presence of dyspareunia and pruritus [43]. In these patients, both necrosis and loss of epidermis are absent, unlike patients with PNP who present this clinical [43].

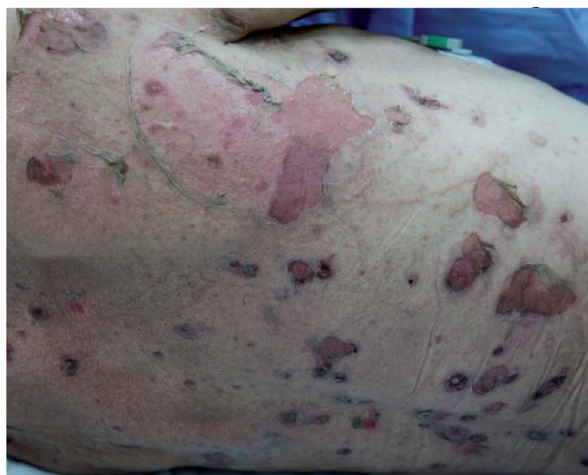

**Figure 1.**  
*Severe erosive mucositis with hematic crusting on the lips and oral mucosa.*





**Figure 2.**  
*Red-violet lesion in the genital organ.*



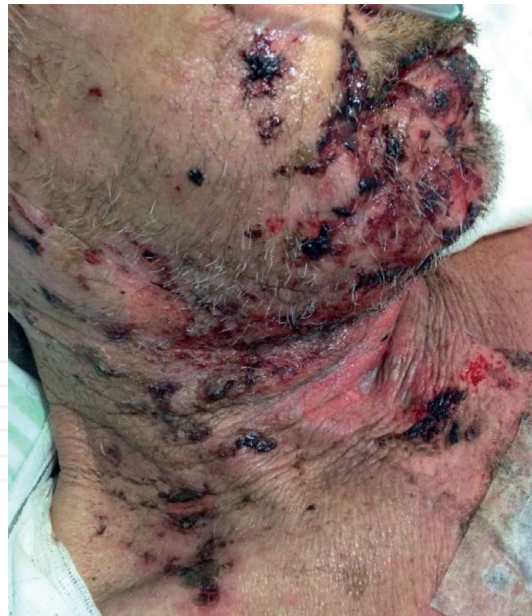**Figure 3.**  
*Extensive erosions and blisters in the dorsal region.*

About 70% of the patients present conjunctival lesions such as bilateral bulbar conjunctival hyperemia, diffuse papillary tarsal conjunctival reactions, conjunctival epithelium desquamation, forniceal shortening, painful ocular irritation, poor vision, conjunctival and corneal erosions, and pseudomembranous conjunctivitis [2, 46, 47].

### 5.3 Skin lesions

Skin lesions usually appear soon after the onset of mucosal involvement [48]. The most affected sites are the dorsal region (**Figure 3**), head, and neck (**Figure 4**), in addition to the nearby extremities [4, 39, 49]. Patients with PNP started the study in very different ways, with the first signs being erythema, bullous and vesicular lesions, papules, skin scaling with Nikolsky sign, exfoliative erythema, and ulcers with hematic crust. Often, the first clinical sign on the skin is erythema that may progress with bullous and ulcerated lesions [24, 50]. Unlike adults, PNP in the skin of children appears in the form of lichenoid lesions, rather than bullous lesions.

Similar to PNP, bullous pemphigoid (BP) provides blistering with erythematous base or normal skin. However, BP lesions occur more frequently in the lower abdomen and lower limbs, and in most individuals, mucosal lesions are not affected [51]. In addition, pruritus is present in the vast majority of these patients, unlike PNP, which show painful and disseminated lesions mainly in the upper body and mucosal regions [28, 51].



**Figure 4.**  
*Confluent erosions with hematic crusts in the head and neck region.*

Already erythema multiforme shows prodromal symptoms such as fever and myalgia before the appearance of lesions on the mucosal and skin. Their skin lesions change in feature according to the course of the disease and resemble insect bites or hives that result in the well-known targetoid lesions that are common in this disease. Although cases of necrosis and blisters occur in the center of the lesions, this disease shows less aggression and fewer blisters and ulcers with hematic crusts than the patients affected by PNP [42].

Lichen planus affects flexor surfaces of the wrists, forearm, and legs. These lesions have round reticular white lines such as Wickham striae. They may arise in places that suffer trauma (Koebner's phenomenon), in addition to making the site pigmented after inflation, thus demonstrating clinical differences in cutaneous erosions seen in the course of PNP progression [43].

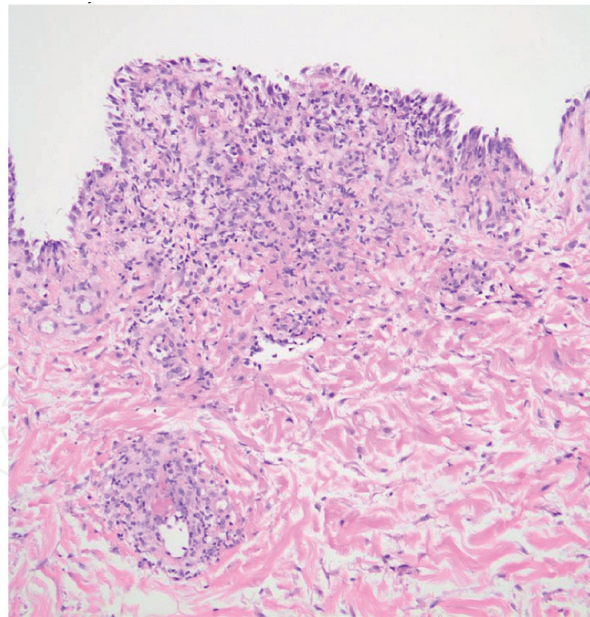
The graft versus host disease causes rash and maculopapular rash that present itching and can spread to the entire body, less in the scalp. In very severe cases, there may be some sites with necrosis at the base of epidermal rete pegs [52]. Generally, these severe cases are differentiated from the PNP both by the patient's clinical history and by skin biopsy that demonstrate distinct histopathological characteristics.

#### **5.4 Pulmonary manifestations**

Approximately 92.8% of the cases described in the literature show pulmonary involvement [3]. The pulmonary clinical signs of PNP are dyspnea, obstructive pulmonary disease, and bronchiolitis obliterans. The resolution of pulmonary problems is of extreme importance, since it is the main cause of death in individuals with PNP [53]. The patients with the greatest pulmonary involvement are Chinese children and patients with Castleman disease [53]. Studies show that 71% of the patients had bronchiolitis obliterans organizing pneumonia, and they give worse prognosis even if treatment of the neoplasia occurs [12, 54].

### **6. Histopathological examination**

The pathological analyses demonstrate many varied aspects, since they show them peculiar characteristics according to the evaluated lesions [55]. When



**Figure 5.**  
*Histopathological examination of the biopsy specimen showing keratinocyte apoptosis and acantholysis (hematoxylin and eosin, original magnification  $\times 100$ ).*

analyzing the biopsy of blisters, we found acantholysis with inflammatory infiltrates (**Figure 5**) [55]. However, when it presents inflammatory maculopapular lesions, the most common findings are lichenoid interface dermatitis [55]. In the presence of lesions with the presence of blisters and maculopapular lesions, mixed characteristics of each type of lesion may occur in the pathology. The findings with dyskeratosis and suprabasal acantholysis are one of the most important characteristics that lead to the definitive diagnosis of PNP [6]. Dyskeratosis is an abnormal formation of epidermal keratinization, whereas acantholysis is the loss of adhesion between skin cells [28]. These findings may help in the diagnosis even when there is no possibility of performing direct immunofluorescence (DIF) or when they are negative [39, 55]. DIF is a laboratory technique capable of detecting the deposition of autoantibodies and immune cells in the sites affected by the disease. The use of DIF demonstrates an extremely important technique for the diagnosis of PNP, since it can analyze both specific autoantibodies and cytotoxic cells of the human immune system, such as CD8<sup>+</sup> T cells that act by attacking several layers with keratin and demonstrating intracellular staining of cementum and/or marking of epidermal dermal junctions in band [28, 55].

## 7. Immunological studies

The use of DIF demonstrates great importance in the diagnosis of PNP even though approximately 50% of the cases show negative [3]. This technique shows a staining in IgG deposition intracellular chicken wire pattern (linear formation of autoantibodies deposition) along the dermoepidermal junction in both the linear form, as granulate [15]. The presence of IgG deposition in the dermoepidermal region is very characteristic of the PNP; however, only 25% presents this pattern [56].

The use of indirect immunofluorescence (IIF) shows involvement of the epidermis by the deposition of IgG in the intercellular regions. Other techniques used as cytoplasmic fluorescence (intracellular staining) demonstrate a prominent basal staining. IIF marking is extremely strong in the layers of the epithelium, and this, alerting to PNP investigation, since it shows high specificity [56].



Other serological methods may also be used, such as immunoprecipitation, immunoblot and anti-EP enzyme-linked immunosorbent assay (ELISA) [57–59]. Studies evidenced 95 and 100% sensitivity in radioactive and nonradioactive immunoprecipitation techniques, respectively, and this demonstrates that immunoprecipitation is the most serologically sensitive test for PNP diagnosis [57, 60, 61]. Currently the immunoprecipitation is considered gold standard in the diagnosis of PNP, that is, the main criterion to diagnose [62, 63].

## 8. Diagnosis

The criteria for diagnosis according to Anhalt et al. in 1990 are based on five criteria, such as clinical characteristics, histopathological analysis, direct and indirect immunofluorescence, and immunoprecipitation [1]. These criteria have been modified and adapted. In 1993, researchers included to perform the diagnosis the presence of three main criteria or two major and two minor [63]. Already in 2002, Mimouni et al. reviewed the Anhalt criteria and considered four minimum criteria of high confidence in diagnosis (**Table 2**) [12]. DIF is a nonessential criterion because of its low sensitivity. As for IIF on rat bladder epithelia and monkey esophagus, they were considered useful for tracking and detecting PNP [57, 64]. Negative IIF cannot exclude PNP, and other techniques such as immunoblotting and immunoprecipitation should be used to confirm or rule out a diagnosis.

1. Clinical features of severe and protracted mucosal involvement and polymorphic cutaneous eruptions
2. Histologic features of acantholysis or lichenoid or interface dermatitis
3. Demonstration of antiplakin autoantibodies
4. The presence of an underlying neoplasm, especially lymphoproliferative tumors

**Table 2.**  
*Minimum criteria for diagnosis.*

## 9. Differential diagnosis

The diagnosis of PNP can be complex and difficult to perform because there are several similar diseases (**Table 3**). PNP and pemphigus vulgaris (PV) are very similar clinically, but some details differentiate them. PNP develops with inflammatory papules or macules that progress to blisters, while PV presents bullous lesions with a reddish background. Molecularly, the PNP presents some antibodies specific for this disease, such as the presence of anti-A2ML1, anti-envoplakin, and anti-periplakin, and demonstrates patterns of IgG deposition on cell surfaces with accumulation in the basement membrane zone [57, 64–66]. Even though bullous autoimmune diseases resemble each other, PNP differentiates it by the presence of antibody that stains the mouse bladder. In bullous pemphigoid (PB), BP230 and BP180 can be found, as well as in PNP. However, the use of DIF differentiates them by the IgG deposition patterns found in the PNP. The involvement by morbilliform-like erythema, toxic epidermal necrolysis, and Stevens-Johnson syndrome can also be confused with PNP. However, the detection of antibodies, pathological analysis of the lesions, and the patient's clinic can differentiate these diseases [1, 10, 39, 57, 64–66].

Despite some cases that both clinically and histologically resemble each other, it is important to perform other techniques to rule out differential diagnoses. The use of otorhinolaryngological examination is very important to differentiate the diseases

Disease	Causers	Pathophysiology
Pemphigus vulgaris	Autoimmune reaction	Autoantigens anti-desmoglein 1,3
Bullous pemphigoid	Autoimmune reaction	Autoantigens anti-BP180 and anti-BP230
Lichen planus	Autoimmune reaction	Autoantigens anti-keratinocyte and antinuclear
Erythema multiforme	hypersensitivity by infection, viruses and drugs	Infiltration of cytotoxic T cell and increased tumor necrosis factor- $\alpha$
Toxic epidermal necrolysis	Drug reaction that affects more than 30% of the body	Infiltration of cytotoxic T cell, natural killer, and increased granulysin
Stevens-Johnson syndrome	Drug reaction that affects less than 10% of the body	Infiltration of cytotoxic T cell, natural killer, and increased granulysin
Drug eruption	Drug reaction	Perivascular infiltration by lymphocytes, eosinophils, and increased histamine and leukotrienes

**Table 3.**  
*Differential diagnosis.*

that affect the mucous membranes. Well-done physical examination of the oral cavity, histopathological analysis characteristics, cutaneous involvement, and the presence of IIF strongly suggest for the diagnosis of PNP [40, 44, 67].

## 10. Treatment

Effective treatment for PNP is still a major puzzle because of its rarity. Although several drugs are used in the literature, PNP has shown great resistance when compared to other forms of pemphigus [50, 68]. When there is suspicion or evidence of PNP, the performance of the six steps described on 2011 by Frew et al. may provide better management of individuals (**Table 4**) [69]. Stabilization of patients, according to the first step, is the most important step, since it is the major cause of death in patients [69].

Currently, the first-line treatment for PNP is still high doses of corticosteroids [70]. This treatment improves the cutaneous lesions, but the mucosal involvement is little altered. The use of other drugs also shows little efficacy in the lesions of the mucosa, this resistance being the characteristic of the disease [69, 71].

Several studies have shown that the combination of drugs has been effective and safe. These associations were prednisolone used with other therapies, such as mycophenolate mofetil, cyclosporine A, azathioprine, plasmapheresis, and intravenous immunoglobulin [72–77]. Even though treatment is more effective, mucosal involvement is still resistant to such combined therapies [71].

The use of monoclonal antibody has been effective in the treatment of PNP in some case reports described in the literature. Administration of rituximab, an anti-CD20, has shown good PNP therapy due to B-cell lymphoma [78, 79]. This therapy is based on an infusion of 375 mg/m<sup>2</sup> weekly for 4 weeks followed by eight weekly infusions for 4 weeks of corticosteroid and administration of other immunosuppressive drugs such as cyclosporine A [69].

The use of alemtuzumab, a humanized monoclonal antibody that binds to CD52, has been reported. Reported in the treatment of PNP remission in patients whose presence of chronic lymphoid leukemia [80]. Alemtuzumab has been used in a patient with resistance to other drugs such as corticosteroids, intravenous immunoglobulin,

1. Stabilization of vital parameters
2. Assessment of any underlying malignancy
3. Diagnosis of PNP
4. Removal and therapy for the triggering tumor
5. Treatment of PNP

**Table 4.**  
*Management of the patient with suspected PNP.*

and cyclosporine A. In this patient, intravenous 30 mg was infused three times a week for 3 months. Even though there was improvement in both skin and mucosal lesions, the patient continued maintenance treatment with 500 mg of mycophenolate mofetil and 5 mg of prednisone [80]. Although there are several treatment alternatives, new therapies that reduce the resistance of PNP to drugs are still fundamental. Daclizumab, a monoclonal antibody against T-cell interleukin-2, has been shown to be a promising therapy [81].

It is known that in order to avoid large amounts of autoantibodies released into the bloodstream during tumor excision surgery, it is necessary to block blood flow and prevent compression of neoplastic tissue. In addition, the use of intravenous immunoglobulin before and during operations has demonstrated a significant reduction in mortality caused by bronchiolitis obliterans. Even after complete tumor resolution, immunoglobulin administration is required until 2 years to provide remission of autoimmunity triggered by PNP [82, 83].

In addition to the treatment of neoplasia and PNP, other ducts must be performed. When there is loss of skin integrity or immunosuppression, antimicrobial therapy is recommended early to prevent sepsis. Medications for pain control are also useful, since patients have pain in regions with ulceration and erosions [50].

Although there are several treatments stipulated in the literature, there are still no known drugs that reduce the mortality of patients, since the PNP proves highly resistant to more aggressive therapies. However, it is known that management, diagnosis, and early treatment are indispensable methods for a better response of the patients in the prescribed procedures.

## 11. Prognosis

The prognosis of PNP is extremely poor. Mortality can reach 90% of the cases in the first year, 41% of mortality in the second year, and 38% of death in the third year with the disease [84]. Commonly, death is triggered by systemic complications such as bronchiolitis obliterans, sepsis, and bleeding in the gastrointestinal tract [6, 50]. It is known that regardless of the cure or control of the neoplasia, the PNP progresses, demonstrating itself autonomous to the triggering factor [6, 10, 11, 13, 50]. Patients who exhibit morbilliform erythema and necrosis of skin biopsy keratinocytes demonstrate a worse overall survival [84]. In some cases, the removal of Castleman disease and benign thymoma has shown better results than other underlying diseases [84, 85].

Even with a high mortality rate, the prognosis depends very much on the proper management of the patient, such as monitoring of vital signs, control of oral and skin lesions, treatment of the triggering disease, and prevention of sepsis and bronchitis obliterans. For this, it is essential to follow the patient closely and treat the disease aggressively [50].

## 12. Quality of life

Studies have mentioned severe losses in the quality of life of patients with pemphigus. The main criteria that impair the quality of life were the greater severity of the disease, anxiety, and depression. However, there was no clear measurement of gender, age, type of pemphigus, duration of disease, skin involvement, disease activity, itching, burning sensation in the skin, or treatment in use [86]. There is still a great need in the standardization and validation of PNP-specific questionnaires, as this proves to be extremely important in order to know and enable actions at key points by multidisciplinary teams.

## 13. Conclusions

PNP demonstrates a great challenge for physicians, since it presents several clinical aspects and varied degrees of bodily involvement. Early diagnosis, management of the patient, treatment of the underlying neoplasia, and aggressive treatment for PNP are of paramount importance for the best prognosis of the patient, since it is an extremely lethal disease. For this, more studies are needed to better understand the disease and cooperation between multidisciplinary teams involving dermatologists, oncologists, hematologists, otorhinolaryngologists, surgeons, ophthalmologists, immunologists, psychologists, nurses, and social workers.

## Acknowledgements

The author would like to acknowledge the help of Dr. Paulo Prata and the School of Health Sciences Barretos, São Paulo, Brazil.

## Conflict of interest

The author has declared no conflicts of interest.

## Appendices and nomenclature

A2ML1	alpha-2 macroglobulin-like 1
BP	bullous pemphigoid
DIF	direct immunofluorescence
DSG	desmoglein
IIF	indirect immunofluorescence
LPD	lymphoproliferative disorders
PNP	paraneoplastic pemphigus



IntechOpen

IntechOpen

### **Author details**

Richard Lucas Konichi-Dias

School of Health Sciences, Dr. Paulo Prata-FACISB, Barretos, Sao Paulo, Brazil

\*Address all correspondence to: richardkonichi95@gmail.com

### **IntechOpen**

---

© 2019 The Author(s). Licensee IntechOpen. This chapter is distributed under the terms of the Creative Commons Attribution License (<http://creativecommons.org/licenses/by/3.0>), which permits unrestricted use, distribution, and reproduction in any medium, provided the original work is properly cited. 

## References

- [1] Anhalt GJ, Kim SC, Stanley JR, et al. Paraneoplastic pemphigus. An autoimmune mucocutaneous disease associated with neoplasia. *The New England Journal of Medicine*. 1990;**323**:1729-1735
- [2] Nguyen VT, Ndoye A, Bassler KD, et al. Classification, clinical manifestations, and immunopathological mechanisms of the epithelial variant of paraneoplastic autoimmune multiorgan syndrome: A reappraisal of paraneoplastic pemphigus. *Archives of Dermatology*. 2001;**137**:193-206
- [3] Paolino G, Didona D, Magliulo G, et al. Paraneoplastic pemphigus: Insight into the autoimmune pathogenesis, clinical features and therapy. *International Journal of Molecular Sciences*. 2017;**18**:2532. DOI: 10.3390/ijms18122532
- [4] Anhalt GJ. Paraneoplastic pemphigus. *The Journal of Investigative Dermatology. Symposium Proceedings*. 2004;**9**:29-33
- [5] Sinha AA. Paraneoplastic pemphigus: Autoimmune-cancer nexus in the skin. *Anti-Cancer Agents in Medicinal Chemistry*. 2015;**15**:1215-1223
- [6] Vassileva S, Drenovska K, Manuelyan K. Autoimmune blistering dermatoses as systemic diseases. *Clinics in Dermatology*. 2014;**32**:364-375
- [7] Czernik A, Camilleri M, Pittelkow MR, et al. Paraneoplastic autoimmune multiorgan syndrome: 20 years after. *International Journal of Dermatology*. 2011;**50**:905-914
- [8] Sticherling M, Erfurt-Berge C. Autoimmune blistering diseases of the skin. *Autoimmunity Reviews*. 2012;**11**:226-230
- [9] Pollmann R, Schmidt T, Eming R, et al. Pemphigus: A comprehensive review on pathogenesis, clinical presentation and novel therapeutic approaches. *Clinical Reviews in Allergy and Immunology*. 2018;**54**:1-25
- [10] Sehgal VN, Srivastava G. Paraneoplastic pemphigus/ paraneoplastic autoimmune multiorgan syndrome. *International Journal of Dermatology*. 2009;**48**:162-169
- [11] Cervini AB, Tosi V, Kim SH, et al. Paraneoplastic pemphigus or paraneoplastic autoimmune multiorgan syndrome. Report of 2 cases in children and a review of the literature. *Actas Dermo-Sifiliográficas*. 2010;**101**:879-886
- [12] Mimouni D, Anhalt GJ, Lazarova Z, et al. Paraneoplastic pemphigus in children and adolescents. *British Journal of Dermatology*. 2002;**147**:725-732
- [13] Lane JE, Woody C, Davis LS, et al. Paraneoplastic autoimmune multiorgan syndrome (paraneoplastic pemphigus) in a child: Case report and review of the literature. *Pediatrics*. 2004;**114**:e513-e516
- [14] Geller S, Gat A, Harel A, et al. Childhood pemphigus foliaceus with exclusive immunoglobulin G autoantibodies to desmocollins. *Pediatric Dermatology*. 2016;**33**:e10-e13
- [15] Amber KT, Valdebran M, Grando SA. Paraneoplastic autoimmune multiorgan syndrome (PAMS): Beyond the single phenotype of paraneoplastic pemphigus. *Autoimmunity Reviews*. 2018;**17**:1002-1010
- [16] Kaplan I, Hodak E, Ackerman L, et al. Neoplasms associated with paraneoplastic pemphigus: A review with emphasis on non-hematologic malignancy and oral mucosal manifestations. *Oral Oncology*. 2004;**40**:553-562

- [17] Shahidi-Dadras M, Abdollahimajd F, Barzkar N, et al. Paraneoplastic pemphigus with underlying retroperitoneal inflammatory myofibroblastic tumor: A case report and review of the literature. *Indian Dermatology Online Journal*. 2017;**8**:478-481
- [18] Lim JM, Lee SE, Seo J, et al. Paraneoplastic pemphigus associated with a malignant thymoma: A case of persistent and refractory oral ulcerations following thymectomy. *Annals of Dermatology*. 2017;**29**:219-222
- [19] Cho JH, Kim NJ, Ko SM, et al. A case report of paraneoplastic pemphigus associated with esophageal squamous cell carcinoma. *Cancer Research and Treatment*. 2013;**45**:70-73
- [20] Wang Y-Z, Gao Z-Y, Lei F-M, et al. A case report on paraneoplastic pemphigus associated colonic carcinoma. *Chinese Medical Journal*. 2016;**129**:1501-1502
- [21] Gill H, Trendell-Smith NJ, Loong F, et al. Paraneoplastic pemphigus due to CD8-positive cytotoxic T-cell lymphoma. *British Journal of Haematology*. 2010;**149**:464
- [22] Ghigliotti G, Di Zenzo G, Cozzani E, et al. Paraneoplastic autoimmune multi-organ syndrome: Association with retroperitoneal Kaposi's sarcoma. *Acta Dermato-Venereologica*. 2016;**96**:261-262
- [23] Hong WJ, Lee SE, Chang S-E, et al. Paraneoplastic pemphigus associated with metastatic lymphoepithelioma-like carcinoma originating from the thyroid gland. *The British Journal of Dermatology*. 2015;**172**:831-834
- [24] Ohzono A, Sogame R, Li X, et al. Clinical and immunological findings in 104 cases of paraneoplastic pemphigus. *The British Journal of Dermatology*. 2015;**173**:1447-1452
- [25] Verrini A, Cannata G, Cozzani E, et al. A patient with immunological features of paraneoplastic pemphigus in the absence of a detectable malignancy. *Acta Dermato-Venereologica*. 2002;**82**:382-384
- [26] Liu Q, Bu D-F, Li D, et al. Genotyping of HLA-I and HLA-II alleles in Chinese patients with paraneoplastic pemphigus. *The British Journal of Dermatology*. 2008;**158**:587-591
- [27] Martel P, Loiseau P, Joly P, et al. Paraneoplastic pemphigus is associated with the DRB1\*03 allele. *Journal of Autoimmunity*. 2003;**20**:91-95
- [28] Kasperkiewicz M, Ellebrecht CT, Takahashi H, et al. Pemphigus. *Nature Reviews Disease Primers*. 2017;**3**:17026
- [29] Okahashi K, Oiso N, Ishii N, et al. Paraneoplastic pemphigus associated with Castleman disease: Progression from mucous to mucocutaneous lesions with epitope-spreading phenomena. *The British Journal of Dermatology*. 2017;**176**:1406-1409
- [30] Gloghini A, Colombatti A, Bressan G, et al. Basement membrane components in lymphoid follicles: Immunohistochemical demonstration and relationship to the follicular dendritic cell network. *Human Pathology*. 1989;**20**:1001-1007
- [31] Futei Y, Amagai M, Hashimoto T, et al. Conformational epitope mapping and IgG subclass distribution of desmoglein 3 in paraneoplastic pemphigus. *Journal of the American Academy of Dermatology*. 2003;**49**:1023-1028
- [32] Ohyama M, Amagai M, Hashimoto T, et al. Clinical phenotype and anti-desmoglein autoantibody profile in paraneoplastic pemphigus. *Journal of the American Academy of Dermatology*. 2001;**44**:593-598

- [33] Schepens I, Jaunin F, Begre N, et al. The protease inhibitor alpha-2-macroglobulin-like-1 is the p170 antigen recognized by paraneoplastic pemphigus autoantibodies in human. *PLoS One*. 2010;5:e12250
- [34] Galliano M-F, Toulza E, Gallinaro H, et al. A novel protease inhibitor of the alpha2-macroglobulin family expressed in the human epidermis. *The Journal of Biological Chemistry*. 2006;281:5780-5789
- [35] Wang L, Bu D, Yang Y, et al. Castleman's tumours and production of autoantibody in paraneoplastic pemphigus. *Lancet*. 2004;363:525-531
- [36] Wang R, Li J, Wang M, et al. Prevalence of myasthenia gravis and associated autoantibodies in paraneoplastic pemphigus and their correlations with symptoms and prognosis. *The British Journal of Dermatology*. 2015;172:968-975
- [37] Wade MS, Black MM. Paraneoplastic pemphigus: A brief update. *The Australasian Journal of Dermatology*. 2005;46:1-8. Quiz 9-10
- [38] Reich K, Brinck U, Letschert M, et al. Graft-versus-host disease-like immunophenotype and apoptotic keratinocyte death in paraneoplastic pemphigus. *The British Journal of Dermatology*. 1999;141:739-746
- [39] Konichi-Dias RL, Ramos AF, de Almeida Santos Yamashita ME, et al. Paraneoplastic pemphigus associated with chronic lymphocytic leukemia: A case report. *Journal of Medical Case Reports*. 2018;12:252
- [40] Kelly S, Schifter M, Fulcher DA, et al. Paraneoplastic pemphigus: Two cases of intra-abdominal malignancy presenting solely as treatment refractory oral ulceration. *The Journal of Dermatology*. 2015;42:300-304
- [41] Wieczorek M, Czernik A. Paraneoplastic pemphigus: A short review. *Clinical, Cosmetic and Investigational Dermatology*. 2016;9:291-295
- [42] Sokumbi O, Wetter DA. Clinical features, diagnosis, and treatment of erythema multiforme: A review for the practicing dermatologist. *International Journal of Dermatology*. 2012;51:889-902
- [43] Usatine RP, Tinitigan M. Diagnosis and treatment of lichen planus. *American Family Physician*. 2011;84:53-60
- [44] Healy WJ, Peters S, Nana-Sinkam SP. A middle-aged man presenting with unexplained mucosal erosions and progressive dyspnoea. *Case Reports*. 2015;2015:bcr2014208677
- [45] Yokokura H, Demitsu T, Kakurai M, et al. Paraneoplastic pemphigus mimicking erosive mucosal lichen planus associated with primary hepatocellular carcinoma. *The Journal of Dermatology*. 2006;33:842-845
- [46] Meyers SJ, Varley GA, Meisler DM, et al. Conjunctival involvement in paraneoplastic pemphigus. *American Journal of Ophthalmology*. 1992;114:621-624
- [47] Broussard KC, Leung TG, Moradi A, et al. Autoimmune bullous diseases with skin and eye involvement: Cicatricial pemphigoid, pemphigus vulgaris, and pemphigus paraneoplastica. *Clinics in Dermatology*. 2016;34:205-213
- [48] Bialy-Golan A, Brenner S, Anhalt GJ. Paraneoplastic pemphigus: Oral involvement as the sole manifestation. *Acta Dermato-Venereologica*. 1996;76:253-254
- [49] Mutasim DF, Pelc NJ, Anhalt GJ. Paraneoplastic pemphigus. *Dermatologic Clinics*. 1993;11:473-481



- [50] Yong AA, Tey HL. Paraneoplastic pemphigus. *The Australasian Journal of Dermatology*. 2013;**54**:241-250
- [51] Khandpur S, Verma P. Bullous pemphigoid. *Indian Journal of Dermatology, Venereology and Leprology*. 2011;**77**:450
- [52] Ferrara JLM, Levine JE, Reddy P, et al. Graft-versus-host disease. *Lancet*. 2009;**373**:1550-1561
- [53] Maldonado F, Pittelkow MR, Ryu JH. Constrictive bronchiolitis associated with paraneoplastic autoimmune multi-organ syndrome. *Respirology*. 2009;**14**:129-133
- [54] Mar WA, Glaesser R, Struble K, et al. Paraneoplastic pemphigus with bronchiolitis obliterans in a child. *Pediatric Dermatology*. 2003;**20**:238-242
- [55] Zimmermann J, Bahmer F, Rose C, et al. Clinical and immunopathological spectrum of paraneoplastic pemphigus. *Journal der Deutschen Dermatologischen Gesellschaft*. 2010;**8**:598-606
- [56] Poot AM, Siland J, Jonkman MF, et al. Direct and indirect immunofluorescence staining patterns in the diagnosis of paraneoplastic pemphigus. *The British Journal of Dermatology*. 2016;**174**:912-915
- [57] Joly P, Richard C, Gilbert D, et al. Sensitivity and specificity of clinical, histologic, and immunologic features in the diagnosis of paraneoplastic pemphigus. *Journal of the American Academy of Dermatology*. 2000;**43**:619-626
- [58] Hashimoto T, Amagai M, Ning W, et al. Novel non-radioisotope immunoprecipitation studies indicate involvement of pemphigus vulgaris antigen in paraneoplastic pemphigus. *Journal of Dermatological Science*. 1998;**17**:132-139
- [59] Probst C, Schlumberger W, Stöcker W, et al. Development of ELISA for the specific determination of autoantibodies against envoplakin and periplakin in paraneoplastic pemphigus. *Clinica Chimica Acta*. 2009;**410**:13-18
- [60] Poot AM, Diercks GFH, Kramer D, et al. Laboratory diagnosis of paraneoplastic pemphigus. *The British Journal of Dermatology*. 2013;**169**:1016-1024
- [61] Kelly S, Culican S, Silvestrini RA, et al. Comparative study of five serological assays for the diagnosis of paraneoplastic pemphigus. *Pathology*. 2015;**47**:58-61
- [62] Hashimoto T, Amagai M, Watanabe K, et al. Characterization of paraneoplastic pemphigus autoantigens by immunoblot analysis. *The Journal of Investigative Dermatology*. 1995;**104**:829-834
- [63] Camisa C, Helm TN. Paraneoplastic pemphigus is a distinct neoplasia-induced autoimmune disease. *Archives of Dermatology*. 1993;**129**:883-886
- [64] Helou J, Allbritton J, Anhalt GJ. Accuracy of indirect immunofluorescence testing in the diagnosis of paraneoplastic pemphigus. *Journal of the American Academy of Dermatology*. 1995;**32**:441-447
- [65] Cozzani E, Dal Bello MG, Mastrogiovanni A, et al. Antidesmoplakin antibodies in pemphigus vulgaris. *The British Journal of Dermatology*. 2006;**154**:624-628
- [66] Kazerounian S, Mahoney MG, Uitto J, et al. Envoplakin and periplakin, the paraneoplastic pemphigus antigens, are also recognized by pemphigus foliaceus autoantibodies. *The Journal of Investigative Dermatology*. 2000;**115**:505-507
- [67] van der Waal RI, Pas HH, Anhalt GJ, et al. Paraneoplastic pemphigus as the

presenting symptom of a lymphoma of the tongue. *Oral Oncology*. 1998;**34**:567-570

[68] Lee SE, Hashimoto T, Kim S-C. No mucosal involvement in a patient with paraneoplastic pemphigus associated with thymoma and myasthenia gravis. *The British Journal of Dermatology*. 2008;**159**:986-988

[69] Frew JW, Murrell DF. Current management strategies in paraneoplastic pemphigus (paraneoplastic autoimmune multiorgan syndrome). *Dermatologic Clinics*. 2011;**29**:607-612

[70] Martínez De Pablo MI, Iranzo P, Mascaró JM, et al. Paraneoplastic pemphigus associated with non-Hodgkin B-cell lymphoma and good response to prednisone. *Acta Dermatovenereologica*. 2005;**85**:233-235

[71] Vezzoli P, Berti E, Marzano AV. Rationale and efficacy for the use of rituximab in paraneoplastic pemphigus. *Expert Review of Clinical Immunology*. 2008;**4**:351-363

[72] Gergely L, Váróczy L, Vadász G, et al. Successful treatment of B cell chronic lymphocytic leukemia-associated severe paraneoplastic pemphigus with cyclosporin A. *Acta Haematologica*. 2003;**109**:202-205

[73] Williams JV, Marks JG, Billingsley EM. Use of mycophenolate mofetil in the treatment of paraneoplastic pemphigus. *The British Journal of Dermatology*. 2000;**142**:506-508

[74] Hertzberg MS, Schifter M, Sullivan J, et al. Paraneoplastic pemphigus in two patients with B-cell non-Hodgkin's lymphoma: Significant responses to cyclophosphamide and prednisolone. *American Journal of Hematology*. 2000;**63**:105-106

[75] Tan-Lim R, Bystryn JC. Effect of plasmapheresis therapy on circulating

levels of pemphigus antibodies. *Journal of the American Academy of Dermatology*. 1990;**22**:35-40

[76] Izaki S, Yoshizawa Y, Kitamura K, et al. Paraneoplastic pemphigus: Potential therapeutic effect of plasmapheresis. *The British Journal of Dermatology*. 1996;**134**:987-989

[77] Granata G, Greco A, Iannella G, et al. Posterior reversible encephalopathy syndrome—Insight into pathogenesis, clinical variants and treatment approaches. *Autoimmunity Reviews*. 2015;**14**:830-836

[78] Hertl M, Zillikens D, Borradori L, et al. Recommendations for the use of rituximab (anti-CD20 antibody) in the treatment of autoimmune bullous skin diseases. *Journal der Deutschen Dermatologischen Gesellschaft*. 2008;**6**:366-373

[79] Hainsworth JD, Burris HA, Morrissey LH, et al. Rituximab monoclonal antibody as initial systemic therapy for patients with low-grade non-Hodgkin lymphoma. *Blood*. 2000;**95**:3052-3056

[80] Hohwy T, Bang K, Steiniche T, et al. Alemtuzumab-induced remission of both severe paraneoplastic pemphigus and leukaemic bone marrow infiltration in a case of treatment-resistant B-cell chronic lymphocytic leukaemia. *European Journal of Haematology*. 2004;**73**:206-209

[81] Lee SE, Kim S-C. Paraneoplastic pemphigus. *Dermatologica Sinica*. 2010;**28**:1-14

[82] Zhu X, Zhang B. Paraneoplastic pemphigus. *The Journal of Dermatology*. 2007;**34**:503-511

[83] Anhalt GJ. Paraneoplastic pemphigus. *Advances in Dermatology*. 1997;**12**:77-96. Discussion 97

[84] Leger S, Picard D, Ingen-Housz-Oro S, et al. Prognostic factors of paraneoplastic pemphigus. *Archives of Dermatology*. 2012;**148**:1165-1172

[85] Wang J, Zhu X, Li R, et al. Paraneoplastic pemphigus associated with castleman tumor: A commonly reported subtype of paraneoplastic pemphigus in China. *Archives of Dermatology*. 2005;**141**:1285-1293

[86] Rencz F, Gulácsi L, Tamási B, et al. Health-related quality of life and its determinants in pemphigus: A systematic review and meta-analysis. *The British Journal of Dermatology*. 2015;**173**:1076-1080

IntechOpen