

We are IntechOpen, the world's leading publisher of Open Access books Built by scientists, for scientists

4,800

Open access books available

122,000

International authors and editors

135M

Downloads

Our authors are among the

154

Countries delivered to

TOP 1%

most cited scientists

12.2%

Contributors from top 500 universities



WEB OF SCIENCE™

Selection of our books indexed in the Book Citation Index
in Web of Science™ Core Collection (BKCI)

Interested in publishing with us?
Contact book.department@intechopen.com

Numbers displayed above are based on latest data collected.
For more information visit www.intechopen.com



Cannulation for Cardiopulmonary Bypass

Emily Bond, Crystal Valadon and Mark Slaughter

Abstract

Cardiac surgery has made significant progress since the advent of cardiopulmonary bypass. Arterial cannulation for bypass is a cornerstone to most cardiac procedures. Choosing an ideal cannulation site, employing peri- and intraoperative imaging, selecting an appropriate cannula, and avoiding complications are vital to success. These, along with the steps to arterial cannulation, are discussed in this chapter.

Keywords: cardiopulmonary bypass, arterial cannulation, aortic cannulation, femoral cannulation, axillary cannulation

1. Introduction

Cardiopulmonary bypass serves the purpose of acting in place of the patient's heart and lungs during a cardiac operative procedure. The mechanism allows for blood to become reoxygenated in order to ensure sufficient perfusion throughout the patient's body. The application of this novel concept is attributed to John Gibbon Jr., and its first successful clinical use was reported in 1953 [1]. However, it did not become more practically available until in 1955 when both John Kirklin at the Mayo Clinic and C. Walton Lillehei at the University of Minnesota introduced its routine use in open heart surgery [1].

The utilization of cardiopulmonary bypass increased significantly between the years 1960 and 1969 due to the increased demand brought on by advances in the field of cardiothoracic surgery. Prior to this era, the majority of cardiac surgeries being performed addressed congenital heart disease in an expeditious fashion. Bypass allowed more complex problems to be repaired by allowing more time for the surgeon to operate while the patient maintained perfusion. Additionally, the need for reliable extracorporeal circulation was expanded with the introduction of coronary artery bypass grafting, the development of artificial heart valves, the utilization of deep hypothermia to facilitate circulatory arrest, and heart transplantation [1].

With the use of cardiopulmonary bypass increasing so dramatically, research into further understanding and improvement of the process was initiated, particularly in the 1980s. Special investigative attention was given to the inflammatory reaction induced by cardiopulmonary bypass, the development of drugs to reduce adverse neurologic events, and flow pulsatility [1–3]. The field of cardiothoracic surgery and the advancement of cardiopulmonary bypass have continued to be refined and improved.

2. Arterial cannulation sites

Arterial cannulation is necessary in order to provide oxygenated blood systemically during cardiopulmonary bypass. Currently, there are three different sites that can be utilized to achieve this function:

- Distal ascending aorta
- Femoral artery
- Axillary artery

The most commonly utilized site is the distal ascending aorta. In this instance, cannulation is performed near the origin of the brachiocephalic trunk [4]. In the event this site is not a viable option, the femoral artery is the standard peripheral site. Femoral arterial cannulation can be accessed both by open cutdown technique and percutaneous techniques. If a percutaneous approach is taken, the arteriotomy will need to be closed using a percutaneous vessel closure device or an open repair. If both the distal ascending aorta and femoral artery prove to be high-risk options due to complications, the axillary artery is the next alternative, preferably on the right side. This vessel is accessed via the deltopectoral groove via a standard infraclavicular cutdown.

3. How to choose the appropriate arterial cannulation site

Determining which arterial cannulation site to use depends on factors such as the procedure being performed, patient body habitus, and the degree of atherosclerotic disease present [5]. Therefore, each case should be evaluated individually to decide upon the best course of action. Based on the surgical procedure, it must be determined if the distal ascending aorta is an appropriate cannulation site. Instances where this may not be the case include repeat sternotomy, emergency surgery, minimally invasive surgery, anatomic anomalies, prohibitive atherosclerotic disease, and robotic cardiac surgery, among others [4]. The benefits of antegrade versus retrograde flow must also be weighed. Both the distal ascending aorta and the axillary artery have the advantage of antegrade flow, whereas the femoral artery exhibits retrograde flow [5]. This is especially important in cases involving aortic dissection. When contemplating using femoral access, excessive arterial calcification, previous groin operations, and body habitus must be considered.

4. Preoperative imaging

Obtaining the appropriate imaging studies prior to conducting cardiopulmonary bypass is essential, as the information gathered can influence the surgical approach. There are several different imaging options that can be utilized. The most routine preoperative imaging study performed is chest radiography. Chest x-ray (anteroposterior and lateral) can provide information such as the size and shape of the cardiac silhouette, traces of previous thoracic interventions or hardware, severe atherosclerotic disease, and significant pulmonary disorders, in addition to other pertinent information [6]. In the current era, nearly every patient who presents with chest pain has CT imaging ordered by a provider during

the work-up. Chest CT can provide an abundance of information regarding the patient's anatomy and quality of vasculature, as well as many anomalies and abnormalities. Certain findings such as porcelain aorta, dissections, and subclavian stenosis can alter the operative treatment plan. Recent data has suggested that CT should be the standard preoperative imaging for patients with prior sternotomy, as doing so has been associated with a lower risk of perioperative complication [7]. This type of imaging allows for the surgeon to visualize and analyze the sternum more effectively, providing information that will ultimately optimize planning of the surgical procedure [7].

Additional imaging modalities that can be utilized preoperatively include transesophageal echocardiogram (TEE) and transthoracic echocardiogram (TTE). Echocardiography has the ability to provide critical information in order to optimize hemodynamics and identify conditions that had not been appreciated on static imaging [8]. In regard to determining which form of echocardiography (TEE vs. TTE) is most appropriate, several factors should be considered. The imaging quality of TTE is limited by the structures the signal must traverse. TEE has shown to provide superior imaging, particularly for posterior structures that are closer in association to the esophagus including the aorta and both atria [9]. The disadvantages of TEE in comparison to TTE include its invasive nature, requirement for sedation, and increased time to perform. Despite these factors, TEE's improved ability to visualize critical structures suggests that it should be the echocardiography imaging of choice for procedures requiring cardiopulmonary bypass. In our practice, TEE is regularly performed in the operating room after induction and prior to incision to verify and support the other preoperative cardiac function tests.

5. Types of cannulas

Aortic cannulas come in a variety of commercially available options. Cannula size should be selected in conjunction with the perfusionist team so as to utilize the appropriate cannula for adequate flow within the circuit. Too large of a cannula may require an aortotomy that is difficult to close in a standard fashion, while too small of a cannula will not allow sufficient flows. A narrower cannula can cause high pressure gradients, cavitation, or jets of flow which can increase the likelihood of dissection. Diffusion-tip cannulas are available which provide multidirectional flow to reduce jets. The tip of the cannula may be straight, tapered, or angled, as well as made from metal or plastic. Various tip modifications, such as flanges or adjustable rings, are available to prevent the cannula from being inserted too far into the aorta and impeding flow to the head vessels. When using an alternate arterial cannulation site, certain adjustments must be made. Adequate bypass support via femoral cannulation is best achieved with a long, wire-reinforced cannula, whereas the diameter of the axillary artery must be taken into account when selecting an appropriate cannula [10].

6. Steps to cannulation

Arterial cannulation is almost always completed prior to venous cannulation during the setup for cardiopulmonary bypass. The steps below outline the appropriate manner in which arterial cannulation can be achieved.

1. Identify the appropriate cannulation site through the use of preoperative imaging, surgical history, and operator preference (**Figure 1**).

2. Utilize additional intraoperative imaging, such as TEE and epi-aortic ultrasound (discussed below), and surgical palpation to ensure avoidance of atherosclerotic regions to minimize risk of embolization. Adequate surgical exposure should be obtained through tedious dissection of the desired vessel. When using the axillary or femoral artery, proximal and distal control should be obtained in the form of vessel loops. Ascending aortic exposure should include the origin identification and isolation of the brachiocephalic trunk and the main pulmonary artery, at a minimum.
3. Two purse string sutures should be placed at the intended access site, typically with monofilament (Prolene™) or braided (Ethibond™) nonabsorbable suture, at a distance that can accommodate an average 20–22F cannula (**Figure 2**).

These should be snared in the standard fashion, as they will be tightened and tied after the cannula has been removed to close the aortotomy. The adventitia within the sutures is then gently divided to prepare for aortotomy (**Figure 3**).

4. Close attention should be paid to the systemic blood pressure, which should be below 100 mmHg prior to aortotomy to decrease the incidence of dissection. A #11 or #15 blade is used to make the aortotomy within the purse string sutures, while the adventitia superior to the incision is pulled gently inferiorly to cover the defect in order to prevent excessive bleeding (**Figure 4**). The incision should be adequate to accommodate the selected cannula but not excessively wide so as to cause difficulty snaring the cannula in place while on bypass. The selected cannula is then inserted into the aorta, and the sutures snared down (**Figure 5**). As previously mentioned, the cannula tip should not be inserted any further than necessary so as to provide optimal systemic flow.
5. Appropriate placement of the cannula is then verified by checking for adequate back-bleeding, which is an opportunity to de-air the cannula as well. Alternatively, the perfusionist may check the arterial waveform for flow verification after the line has been de-aired and connected to the circuit.
6. The arterial cannula and snares are then tied together with silk ties to provide additional stability [11] (**Figure 6**).

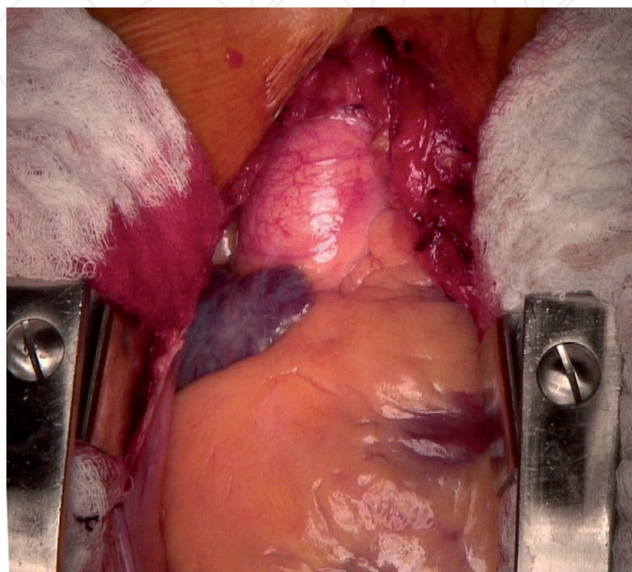


Figure 1.
Ascending aortic exposure prior to cannulation.

Closing the aortic cannulation site is rather straightforward. The purse string sutures that were placed prior to the cannula insertion are utilized to close the incision once the tubing has been removed. If needed, an additional mattress

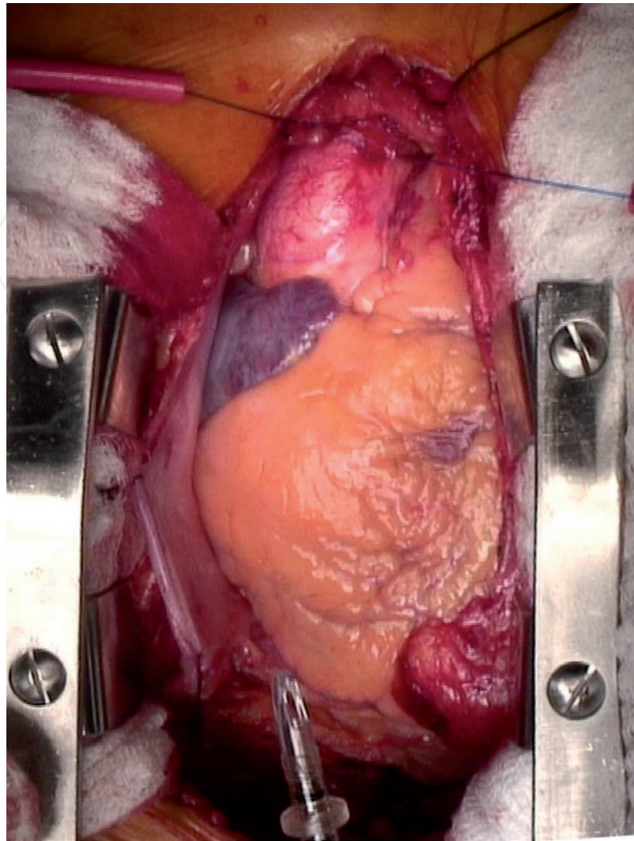


Figure 2.
Cannulation site opposite brachiocephalic artery with purse string sutures placed. Note the cannula at the lower border of the image with a flange marking the maximum length of desired insertion.

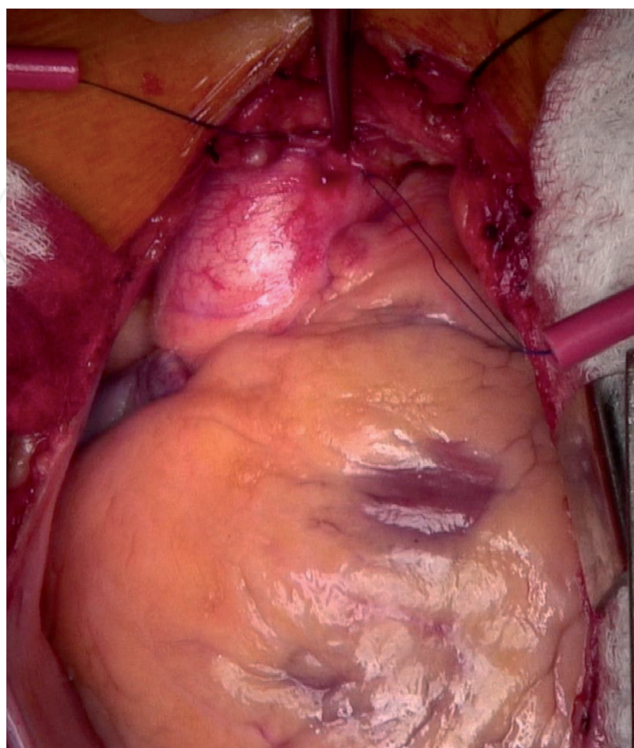


Figure 3.
The adventitia is gently removed from the cannulation site within the purse string sutures.

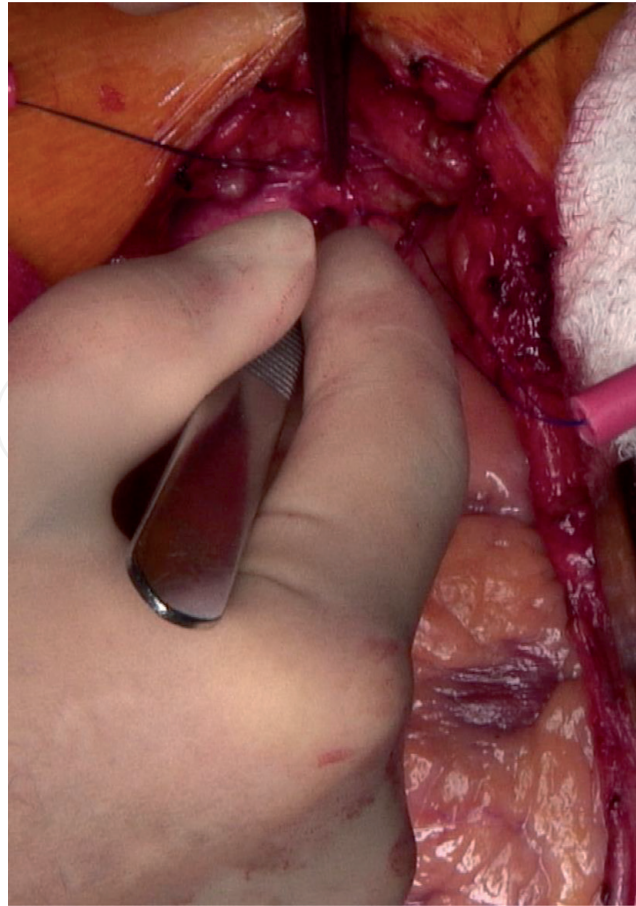


Figure 4.
A scalpel is used to make the aortotomy at the cannulation site, while gentle inferior traction is placed with the adventitia to prevent excessive bleeding.

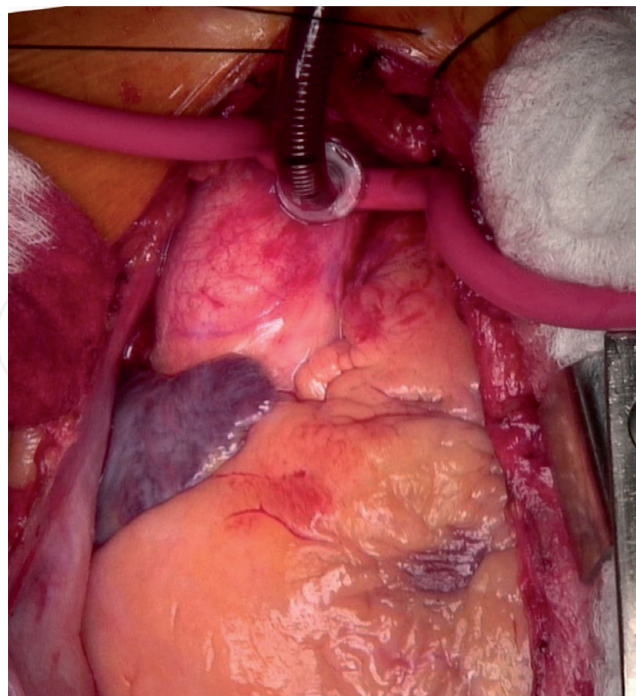


Figure 5.
The aortic cannula has been inserted, and the purse string sutures snared down.

or figure-of-eight suture can be placed to reinforce the aortotomy [12]. The use of felt pledges is left to the discretion of the surgeon. These are composed of prosthetic material such as polytetrafluorethylene and are used to achieve a greater level of hemostasis, especially in patients with fragile tissue such as the

elderly [12]. There is, however, a theoretically increased risk of bacterial infection with their use [12]. When closing femoral or axillary cannulation sites, a bovine pericardial patch is frequently used so as not to narrow the arterial diameter significantly.

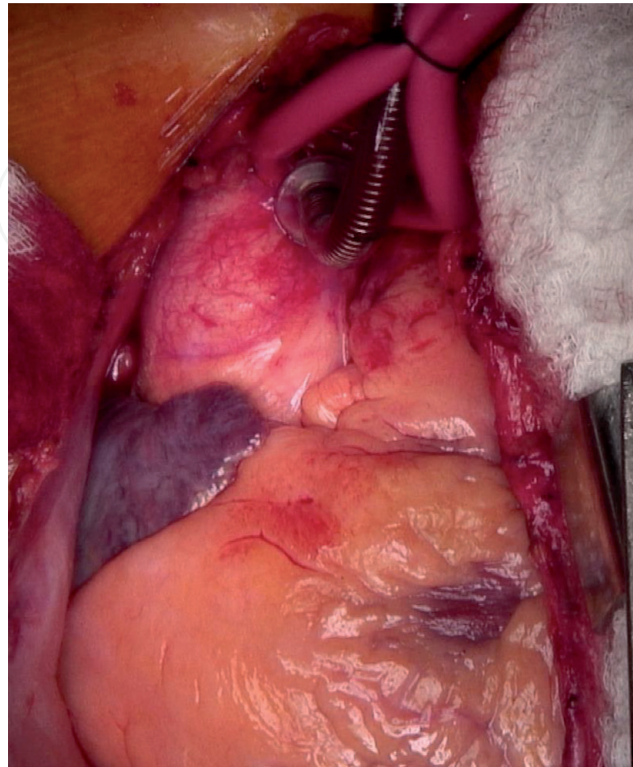


Figure 6.
The aortic cannula and snared purse string sutures are secured together with a heavy silk suture.

7. Axillary artery cannulation

If the axillary artery is selected as the cannulation site, the exposure should be completed prior to median sternotomy. The right side is preferred. To isolate the artery, an incision is made 2 fingerbreadths inferiorly at the middle 1/3 of the clavicle. The incision may be extended laterally. The subcutaneous tissue is dissected down to the level of the pectoralis major. The pectoralis major is then split in the direction of its fibers, and the pectoralis minor is retracted laterally. The axillary vein is the first vascular structure encountered. It is dissected out and retracted inferiorly. Care should be taken to ligate small venous branches. The brachial plexus is superior to the artery and should be avoided if possible. Once the axillary artery is dissected from the surrounding tissue and isolated, the decision must be made to cannulate the artery directly or use an extension graft, such as Dacron. If the artery is to be cannulated directly, open transverse arteriotomy may be made or Seldinger technique employed for cannula placement. A graft is most helpful for small arteries where there is concern that the size of the cannula will completely occlude distal flow or if there is concern that the artery will be significantly narrowed when the arteriotomy is closed. If a graft is to be used, proximal and distal clamps should be placed on the artery, followed by a longitudinal arteriotomy. Graft anastomosis is typically completed with a 6-0 polypropylene suture. After the anastomosis is complete, the graft can be cannulated and blood flow to the arm restored. At the completion of cardiopulmonary bypass, the graft may be ligated and oversewn. If a graft is not used, the arteriotomy can be closed in the standard fashion after decannulation. Standard cannulation strategies should be used, as discussed above. After

decannulation, the pectoralis major should be reapproximated so as to cover the arteriotomy, and the incision should be closed in layers [13, 14].

8. Femoral artery cannulation

The femoral artery has long been used for cardiopulmonary bypass since the advent of cardiac surgery. As mentioned above, the femoral artery is a good alternative to direct aortic cannulation in the setting of porcelain aorta, type A aortic dissection, and re-operative cardiac surgery, as well as minimally invasive cardiac procedures [15–17]. The femoral artery can be cannulated percutaneously or directly. An extension graft is almost never needed for femoral cannulation, as opposed to axillary artery cannulation.

Several commercial sets are available to assist in percutaneous cannulation. A percutaneous cannulation is unlikely to be successful in patients who do not have a palpable femoral pulse. To start, the femoral artery should be identified by palpation or ultrasound guidance. The common femoral artery should be punctured well above the superficial/profunda femoral artery bifurcation so as to decrease the incidence of limb malperfusion. Seldinger technique is then employed to completed cannulation. When using femoral artery cannulation for aortic dissection, it is vital to identify the guide wire in the true lumen by TEE prior to cannula placement. Closure preferences for the arteriotomy vary. Several commercial closure devices are available, such as Perclose Proglide Vascular Closure Device (Abbott Inc., Santa Clara, CA) [18]. The field of endovascular closure devices is rapidly growing due to the popularity of endovascular procedures such as abdominal aortic aneurysm repair and transcatheter valve replacement. If the arteriotomy is not hemostatic after attempted endovascular closure and prolonged pressure, a femoral cutdown may be necessary for direct surgical closure of the artery.

For open surgical femoral artery cannulation, an incision should be made parallel to the inguinal crease. The subcutaneous tissues should be dissected down until the femoral artery can be identified and isolated. Proximal and distal control is obtained, and the common femoral artery can be directly cannulated. At the termination of cardiopulmonary bypass, the artery is repaired directly, typically with 4-0 or 5-0 polypropylene suture. Femoral approach, both percutaneous and via cutdown, can be significantly more difficult to successfully perform on obese patients and patients with severe peripheral vascular disease.

9. Intraoperative techniques and imaging

Patients undergoing cardiopulmonary bypass are at risk for developing neurological deficits due to the dislodgement of atheroma from the aorta and proximal arch during the procedure [19]. Therefore, it is imperative that these atheromas are identified accurately to avoid the development of such complications. The standard method for detecting atherosclerotic disease of the aorta intraoperatively is manual palpation performed by the surgeon [20]. However, it has been noted that this traditional technique is unable to detect approximately 50% of atheroma lesions due to the presence of soft calcifications that the surgeon cannot appropriately identify [21].

An imaging modality that is routinely utilized in cardiac procedures is intraoperative transesophageal echocardiogram (TEE). TEE has shown to be effective in identifying areas of the aorta that are affected by atherosclerotic disease [10].

However, this method is not comprehensive as the bronchus creates a blind spot due to its position between the aorta and esophagus [19].

The best approach to identifying the presence of atheroma lesions in the aorta and proximal arch is epi-aortic scanning. This method involves directly imaging the aortic root and arch via ultrasound. An investigation conducted by Sylviris and colleagues [21] found that epi-aortic scanning was superior to both palpation and TEE in both identifying areas of atherosclerosis and grading the lesions.

Once the locations of atheroma lesions have been identified, modifications to the surgical approach can be made in order to ensure appropriate cannulation and clamping sites. Avoidance of these diseased locations will help to decrease the likelihood of neurologic complications due to disruption of the atherosclerotic regions.

10. Arterial cannulation site complications

10.1 Bleeding

Intraoperative bleeding can be a painful complication for both the surgeon and the patient. Bleeding from the aortic cannulation site is most commonly from too large of an aortotomy or inadequate snaring of the purse string sutures. To prevent this, careful attention should be paid to the diameter of the purse string “circle” that is created to ensure that it is 3–5 mm wider than the cannula diameter, typically 1.5–2 cm in total diameter. It can be challenging to place an additional circumferential suture after the aortotomy has been made. Additionally, care should be taken when making the aortotomy that the scalpel is not inserted too deeply so as to injure the posterior wall of the ascending aorta.

10.2 Malposition of cannula tip

Monitor circuit and peripheral arterial line mean arterial pressures to ensure adequate systemic circulation. Unequal mean arterial pressures suggests cannula malposition, which can typically be corrected by slightly withdrawing the cannula while taking care not to withdraw the cannula completely. Circuit flow rates should be maintained around 2.4 L/min/m² to ensure cerebral perfusion. If the flow rates are decreased, cannula position should be verified both visually and with intraoperative TEE.

10.3 Embolic events

Visual inspection and palpation of the distal ascending aorta prior to cannulation is of utmost importance in preventing embolic events. A calcified aortic wall is more likely to cause not only difficulty in successfully inserting an aortic cannula but also showering of plaque to the systemic circulation. In addition, intraoperative TEE and epi-aortic ultrasound can be employed to help select an adequate cannulation site for complex aortic walls. If a heavy calcified porcelain aorta is present but not appreciated on preoperative imaging (which would be rare), alternate cannulation sites should be considered. A caveat to this is that atherosclerotic disease that majorly affects the aorta is also likely to affect femoral or axillary vessels.

10.4 Aortic dissection

Aortic dissection is the most feared complication related to aortic cannulation. If not promptly recognized and addressed, the effects can be devastating. Placement

of the cannula into the true aortic lumen, as detailed above using adequate pressure gradient monitoring in the bypass circuit, sufficient blood return in the cannula after placement, and verification of placement with TEE significantly decrease the risk of dissection. Atherosclerotic plaques can tear between the medial and intimal layers causing dissection if a cannula is attempted to be forced through a calcified area on the aortic wall. In addition, severe hypertension after decannulation when the aortic purse string sutures are being tied down can lead to tears in the aortic wall layers [3, 22, 23].

11. Conclusion

Cardiac surgery has undergone significant progress over the last 65 years that would not have been possible without the evolution of cardiopulmonary bypass. Several strategies, tips, and pitfalls have been presented above to provide the greatest opportunity for successful arterial cannulation for bypass.

Author details

Emily Bond, Crystal Valadon and Mark Slaughter*
University of Louisville Department of Cardiothoracic Surgery, Louisville,
Kentucky, United States

*Address all correspondence to: mark.slaughter@louisville.edu

IntechOpen

© 2019 The Author(s). Licensee IntechOpen. This chapter is distributed under the terms of the Creative Commons Attribution License (<http://creativecommons.org/licenses/by/3.0>), which permits unrestricted use, distribution, and reproduction in any medium, provided the original work is properly cited. 

References

- [1] Hessel EA. A brief history of cardiopulmonary bypass. *Seminars in Cardiothoracic and Vascular Anesthesia*. 2014;**18**(2):87-100. DOI: 10.1177/1089253214530045
- [2] Hickey P, Buckley M, Philbin D. Pulsatile and nonpulsatile cardiopulmonary bypass: Review of a counterproductive controversy. *The Annals of Thoracic Surgery*. 1983;**36**(6):720-737
- [3] Kincaid EH, Hammon JW. Cardiopulmonary bypass. In: Yuh DD, Vricella LA, Yang SC, Doty JR, editors. *Johns Hopkins Textbook of Cardiothoracic Surgery*. 2nd ed. New York, NY: McGraw-Hill; 2014
- [4] El-Sherief AH, Wu CC, Schoenhagen P, Little BP, Cheng A, Abbara S, et al. Basics of cardiopulmonary bypass: Normal and abnormal postoperative CT appearances. *Radiographics*. 2013;**33**:63-72. DOI: 10.1148/rg.331115747
- [5] Ramchandani M, Al Jabbari O, Abu Saleh WK, Ramlawi B. Cannulation strategies and pitfalls in minimally invasive cardiac surgery. *Methodist DeBakey Cardiovascular Journal*. 2016;**12**(1):10-13
- [6] Cantinotti, M. The importance and ways of exploring the entire chest before and after cardiac surgery: Chest radiography, lung ultrasonography, and computed tomography. *The Journal of Thoracic and Cardiovascular Surgery*. 2018;**155**(5):2041-2042
- [7] LaPar DJ, Ailawadi G, et al. Preoperative computed tomography is associated with lower risk of perioperative stroke in reoperative cardiac surgery. *Interactive Cardiovascular and Thoracic Surgery*. 2011;**12**(6):919-923. DOI: 10.1510/icvts.2010.265165
- [8] Qizilbash B, Couture P, Denault A. Impact of perioperative transesophageal echocardiography in aortic valve replacement. *Seminars in Cardiothoracic and Vascular Anesthesia*. 2017;**11**(4):288-300. DOI: 10.1177/1089253207311789
- [9] Patel A, Kannam J. Transesophageal Echocardiography: Indications, Complications, and Normal Views. UpToDate. Retrieved from: <https://www.uptodate.com/contents/transesophageal-echocardiography-indications-complications-and-normal-views>
- [10] Hessel EA, Hill AG. Circuitry and cannulation techniques. In: Gravlee GP, Davis RF, Kursz M, Utley JR, editors. *Cardiopulmonary Bypass: Principles and Practice*. 2nd ed. Philadelphia, PA: LWW; 2000
- [11] Kwon MH, Tollis G, Sundt TM. Myocardial revascularization with cardiopulmonary bypass. In: Cohn LH, Adams DH, editors. *Cardiac Surgery in the Adult*. 5th ed. New York, NY: McGraw-Hill; 2018
- [12] Tappainer E. A stitch in time saves nine: Closing the hole after removal of the aortic root cannula. *Journal of Cardiothoracic Surgery*. 2009;**4**:2. DOI: 10.1186/1749-8090-4-2
- [13] Valentine RJ. Surgical treatment of the subclavian and axillary artery. In: Chaikof EL, Cambria RP, editors. *Atlas of Vascular Surgery and Endovascular Therapy*. 1st ed. Philadelphia: Saunders; 2014. pp. 157-170
- [14] Sinclair MC, Singer RL, Manley NJ, Montesano CCP. Cannulation of the axillary artery for cardiopulmonary bypass: Safeguards and pitfalls. *The Annals of Thoracic Surgery*. 2003;**75**:931-934. DOI: 10.1016/S0003-4975(02)04497-1

- [15] Ayyash B, Tranquilli M, Elefteriades JA. Femoral artery cannulation for thoracic aortic surgery: Safe under transesophageal echocardiographic control. *The Journal of Thoracic and Cardiovascular Surgery*. 2011;**142**:1478-1481
- [16] Schwarz B, Mair P, Margreiter J, et al. Experience with percutaneous venoarterial cardiopulmonary bypass for emergency circulatory support. *Critical Care Medicine*. 2003;**31**:758-764
- [17] Fusco DS, Shaw RK, Tranquilli M, Kopf GS, Eleteriades JA. Femoral cannulation is safe for type A dissection repair. *The Annals of Thoracic Surgery*. 2004;**78**:1285-1289
- [18] Yang L, Liu J, Li Y. Femoral artery closure versus surgical cutdown for endovascular aortic repair: A single-center experience. *Medical Science Monitor*. 2018;**24**:92-99. DOI: 10.12659/MSM.905350
- [19] Joo H-C, Youn Y-N, Kwak Y-L, Yi G-J, Yoo K-J. Intraoperative epiaortic scanning for preventing early stroke after off-pump coronary artery bypass. *BJA: British Journal of Anaesthesia*. 2013;**111**(3):374-381. DOI: 10.1093/bja/aet113
- [20] Katz E, Tunick P, Facc H, et al. Protruding aortic atheromas predict stroke in elderly patients undergoing cardiopulmonary bypass: Experience with intraoperative transesophageal echocardiography. *Journal of the American College of Cardiology*. 1992;**20**(1):70-77
- [21] Sylivris S, Calafiore P, Matalanis G, et al. The intraoperative assessment of ascending aortic atheroma: Epiaortic imaging is superior to both transesophageal echocardiography and direct palpation. *Journal of Cardiothoracic and Vascular Anesthesia*. 1997;**11**:704-707. DOI: 10.1016/S1053-0770(97)90161-0
- [22] Williams C, Suwansirikul S, Engelman R. Thoracic aortic dissection following cannulation for perfusion. *The Annals of Thoracic Surgery*. 1974;**18**(3):300-304
- [23] Still R, Hilgenber A, Akins C, et al. Intraoperative aortic dissection. *Annals of Thoracic Surgery*. 1992;**53**:374-380