

# We are IntechOpen, the world's leading publisher of Open Access books Built by scientists, for scientists

**4,800**

Open access books available

**122,000**

International authors and editors

**135M**

Downloads

Our authors are among the

**154**

Countries delivered to

**TOP 1%**

most cited scientists

**12.2%**

Contributors from top 500 universities



**WEB OF SCIENCE™**

Selection of our books indexed in the Book Citation Index  
in Web of Science™ Core Collection (BKCI)

Interested in publishing with us?  
Contact [book.department@intechopen.com](mailto:book.department@intechopen.com)

Numbers displayed above are based on latest data collected.

For more information visit [www.intechopen.com](http://www.intechopen.com)



# Pathogenesis of Periodontal Disease

*José Luis Muñoz-Carrillo, Viridiana Elizabeth Hernández-Reyes, Oscar Eduardo García-Huerta, Francisca Chávez-Ruvalcaba, María Isabel Chávez-Ruvalcaba, Karla Mariana Chávez-Ruvalcaba and Lizbeth Díaz-Alfaro*

## Abstract

Inflammation is a physiological response of the innate immune system against several endogenous or exogenous stimuli. Inflammation begins with an acute pattern; however, it can become chronic by activating the adaptive immune response through cellular and noncellular mechanisms. The main etiologic factor of periodontal disease is bacteria which substantially harbor the human oral cavity. The most common periodontal diseases are gingivitis and periodontitis, whose main characteristic is inflammation. The knowledge of how immune mechanisms and inflammatory responses are regulated is fundamental to understanding the pathogenesis of periodontal disease. The purpose of this chapter is to show the current panorama of the immunological mechanisms involved in the pathogenesis of periodontal disease.

**Keywords:** periodontal tissues, biofilm, inflammatory response, innate and adaptive immunity, periodontitis

## 1. Introduction

Periodontitis is a globally widespread pathology of the human oral cavity. Approximately 10% of the global adult population is highly vulnerable to severe periodontitis, and 10–15% appears to be completely resistant to it, while the remainder varies between these two situations [1]. Periodontitis is a major public health problem due to its high prevalence, as well as because it may lead to tooth loss and disability, negatively affect chewing function and aesthetics, be a source of social inequality, and impair the quality of life. Periodontitis accounts for a substantial proportion of edentulism and masticatory dysfunction, results in significant dental care costs, and has a plausible negative impact on general health [2].

## 2. Periodontal support tissues

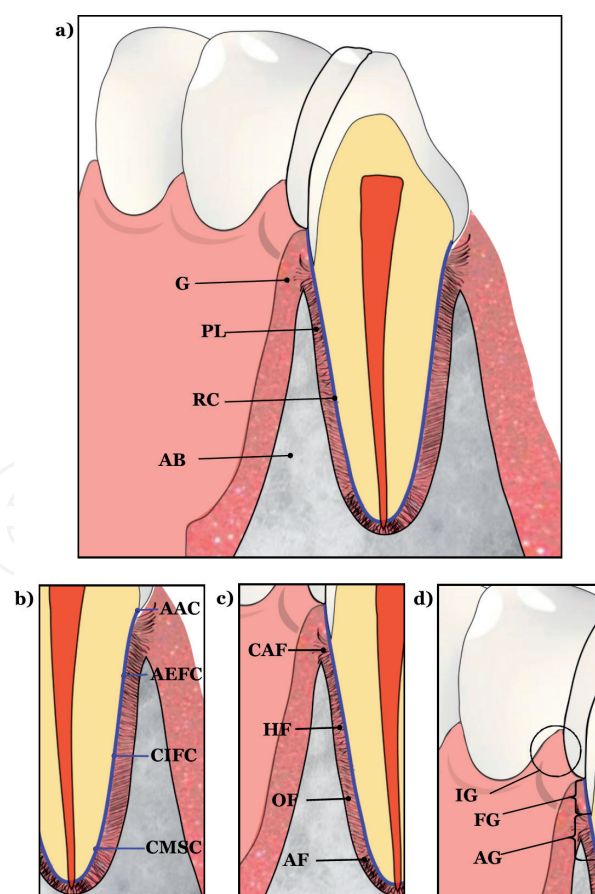
The periodontium is a complex of tissues with blood vessels, nerves, and bundles of fibers, which provide nutrition and sensibility, supporting and investing the tooth. The periodontium has the potential for regeneration and remodeling throughout life, which allows the primary dentition to be transient and to be

replaced by the permanent dentition [3, 4]. It is important to understand that each of the periodontal tissues has a very specialized structure and that these structural characteristics directly define the function. In fact, the proper functioning of the periodontium is only achieved through the structural integrity and interaction between its components [4].

The periodontium is one of the morphofunctional components of the stomatognathic system, and its “design” not only responds to intrinsic functions related to nutrition or the subjection of the tooth but also to functions integrated within the physiology of the stomatognathic system [5]. The main function of the periodontium is to join the tooth to the bone tissue and maintain integrity on the surface of the masticatory mucosa of the oral cavity [6]. The periodontium includes four tissues located near the teeth: (1) the alveolar bone (AB), (2) root cementum (CR), (3) periodontal ligament (PL), and (4) gingiva (G) (e.g., **Figure 1a**) [4, 7, 8].

## 2.1 Alveolar bone

The alveolar bone, together with the root cementum and the periodontal ligament, constitutes the tooth insertion apparatus, whose main function is to distribute the forces generated by chewing and other contacts [6]. The maxilla and mandible of the adult human can be subdivided into two parts: (a) the alveolar process that involves in housing the roots of the erupted teeth and (b) the basal body that does not involve in housing the roots [8].



**Figure 1.** Periodontal tissues. (a) Tissues that support the tooth include the alveolar bone (AB), root cementum (RC), periodontal ligament (PL), and gingiva (G). (b) Forms of cementum: acellular afibrillar cementum (AAC), acellular extrinsic fibers cementum (AEFC), cellular mixed stratified cementum (CMSC), and cellular intrinsic fibers cementum (CIFC). (c) Bundles of collagen fibers: crestal alveolar fibers (CAF), horizontal fibers (HF), oblique fibers (OF), and apical fibers (AF). (d) Parts of the gingiva: free gingiva (FG), interdental gingiva (IG), and attached gingiva (AG).

The alveolar process is the bone of the jaws that contain the sockets (alveoli) of the teeth. It consists of outer cortical plates (buccal, lingual, and palatal) of the compact bone, a central spongiosa, and bone lining the alveolus (alveolar bone) [4]. The alveolar process is dependent on the teeth as they develop and remodel with their formation and eruption. Therefore, the shape, location, and function of the teeth determine its morphology [8]. The periodontal ligament contains progenitor cells that can differentiate into osteoblasts for the maintenance and repair of the alveolar bone. However, in the absence of the tooth, it is lost. These characteristics suggest that the regulatory mechanisms are important for the alveolar bone, so there is an interdependence of the periodontal tissues, which work together as a unit [4].

## 2.2 Root cementum

The root cementum is an avascular mineralized connective tissue covering the entire root surface, forming the interface between the root dentine and the periodontal ligament [6, 7]. In addition, the root cementum plays important roles in nourishing the tooth as well as in stabilizing the tooth via the attachment to the periodontal ligament. This enables the tooth to maintain its relationship to adjacent and opposing teeth [3]. Unlike the bone, the root cementum does not contain blood or lymphatic vessels, lacks innervation, and does not undergo remodeling or physiological resorption, but it is characterized by the fact that continues to be deposited throughout life [6]. The composition of cementum contains about 50% mineral (substituted apatite) and 50% organic matrix. Type I collagen is the predominant organic component, constituting up to 90% of the organic matrix. Other collagens associated with cementum include type I, III, V, VI, XII, and XIV [4].

Cementum performs different functions: it fixes the main fibers of the periodontal ligament to the root and contributes in the repair process when the root surface has been damaged [6]. Cementum has been classified as cellular and acellular cementum depending on the presence and absence of cementocytes, further grouped into intrinsic and extrinsic fiber cementum depending on the presence of collagen fibers formed by cementoblasts or by fibroblasts, respectively [8]. There are different forms of cementum (e.g., **Figure 1b**): (1) acellular afibrillar cementum (AAC), (2) acellular extrinsic fiber cementum (AEFC), (3) cellular mixed stratified cementum (CMSC), and (4) cellular intrinsic fibers cementum (CIFC) [4, 6].

## 2.3 Periodontal ligament

The periodontal ligament is the soft and specialized connective tissue situated between the cementum covering the root of the tooth and the bone forming the socket wall (alveolodental ligament) [4]. The periodontal ligament consists of cells and an extracellular compartment comprising collagenous and noncollagenous matrix constituents. The cells include osteoblasts and osteoclasts, fibroblasts, epithelial cell rests of Malassez, monocytes and macrophages, undifferentiated mesenchymal cells, and cementoblasts and odontoclasts. The extracellular compartment consists mainly of well-defined collagen fiber bundles embedded in an amorphous background material, known as ground substance [4, 8]. These bundles of collagen fibers can be classified into the following groups, according to their disposition (e.g., **Figure 1c**): crestal alveolar fibers (CAF), horizontal fibers (HF), oblique fibers (OF), and apical fibers (AF) [6].

The main function of the periodontal ligament is to support the teeth in their sockets and at the same time allow them to withstand the considerable forces of

mastication. In addition, the periodontal ligament has the capacity to act as a sensory receptor necessary for the proper positioning of the jaws during mastication, and, very importantly, it is a cell reservoir for tissue homeostasis, regeneration, and repair [4].

## **2.4 Gingiva**

Gingiva is a portion of the oral mucosa covering the tooth-carrying part of the alveolar bone and the cervical neck of the tooth. Three parts of the gingiva can be distinguished (e.g., **Figure 1d**): (1) free gingiva (FG), (2) interdental gingiva (IG), and (3) attached or inserted gingiva (AG) [6]. Histologically, the epithelial component of the gingiva shows regional morphological variations that reflect the adaptation of the tissue to the tooth and alveolar bone. These include the epithelium that covers a connective tissue, chorion, or lamina propria. A keratinized stratified squamous epithelium protects the lamina propria of the gingiva on its masticatory surfaces and a nonkeratinized epithelium protects the lamina propria on its crevicular and junctional surfaces [6, 9]. The junctional epithelium plays a crucial role since it essentially seals off periodontal tissues from the oral environment. Its integrity is thus essential for maintaining a healthy periodontium. Periodontal disease sets in when the structure of the junctional epithelium starts to fail, an excellent example of how structure determines function [4].

During pathological conditions, such as inflammation, the periodontal connective tissues, including the gingiva, undergo many changes. Clinically detected gingival overgrowth is one of the alterations that occurs in chronic periodontitis. It is caused by a variety of etiological factors and is exacerbated by local bacterial biofilm accumulation, because the periodontopathogen products act on the gingival tissues activating cellular events that induce the alteration of connective tissue homeostasis and the destruction of the alveolar bone [9]. Likewise, junctional epithelial cells differ considerably from those of the gingival epithelium. There are polymorphonuclear leukocytes and monocytes that pass from the subepithelial connective tissue through the junctional epithelium and into the gingival sulcus. The mononuclear cells, together with molecules they secrete and others originating from junctional epithelial cells, blood and tissue fluid, represent the first line of defense in the control of the perpetual microbial challenge [4].

## **3. Periodontal pathogenesis**

Periodontitis is a chronic multifactorial disease characterized by an inflammation of the periodontal tissue mediated by the host, which is associated with dysbiotic plaque biofilms, resulting in the progressive destruction of the tooth-supporting apparatus and loss of periodontal attachment [1, 10]. The bacterial biofilm formation initiates gingival inflammation; however, periodontitis initiation and progression depend on dysbiotic ecological changes in the microbiome in response to nutrients from gingival inflammatory and tissue breakdown products and anti-bacterial mechanisms that attempt to contain the microbial challenge within the gingival sulcus area once inflammation has initiated. This leads to the activation of several key molecular pathways, which ultimately activate host-derived proteinases that enable loss of marginal periodontal ligament fibers, apical migration of the junctional epithelium, and allows apical spread of the bacterial biofilm along the root surface [1]. Therefore, the primary features of periodontitis include the loss of periodontal tissue support, manifested through clinical attachment loss and radiographically assessed alveolar bone loss, presence of periodontal pocketing, and gingival bleeding [10].

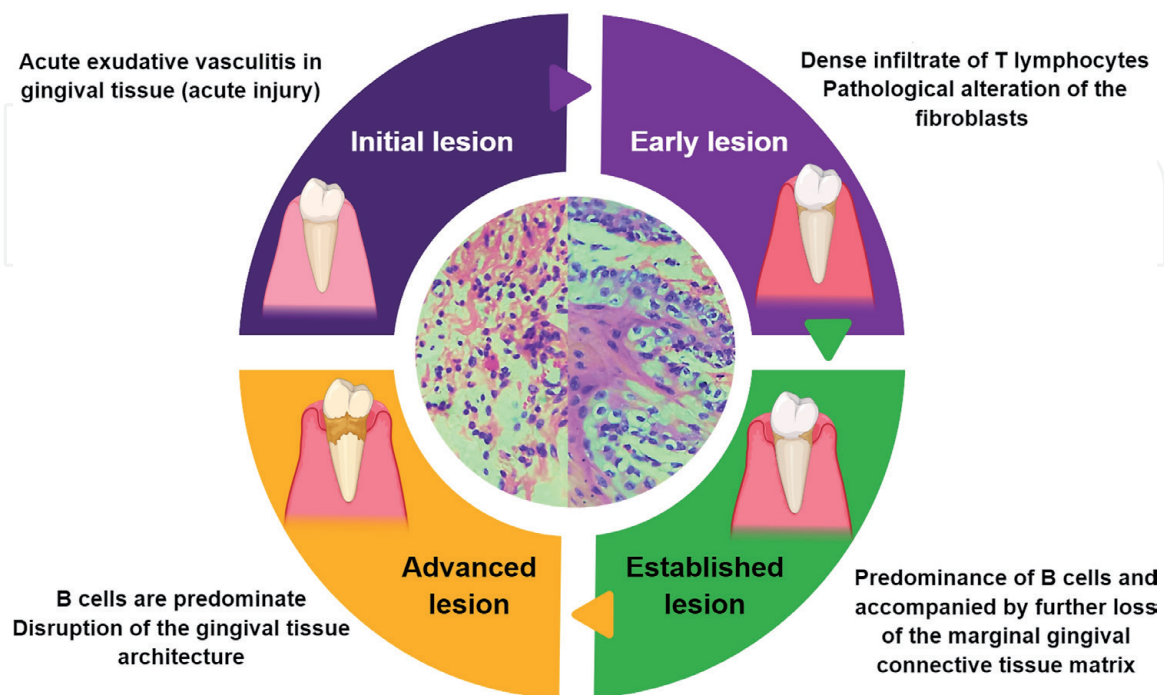
### 3.1 Periodontal histopathology

The development of gingivitis and periodontitis can be divided into a series of stages: initial, early, established, and advanced lesions (e.g., **Figure 2**) [11, 12]. The initial lesion begins 2–4 days after the accumulation of the microbial plaque. During the initial lesion, an acute exudative vasculitis in the plexus of the venules lateral to the junctional epithelium, migration of polymorphonuclear (PMN) cells through the junctional epithelium into the gingival sulcus, co-exudation of fluid from the sulcus, and the loss of perivascular collagen were observed. The early injury develops within 4–10 days. This lesion is characterized by a dense infiltrate of T lymphocytes and other mononuclear cells, as well as by the pathological alteration of the fibroblasts [6, 11–13].

Subsequently, the established lesion develops within 2–3 weeks. This lesion is dominated by activated B cells (plasma cells) and accompanied by further loss of the marginal gingival connective tissue matrix, but no bone loss is yet detectable. Several PMN continue to migrate through the junctional epithelium, and the gingival pocket is gradually established. Finally, in the advanced lesion, plasma cells continue to predominate as the architecture of the gingival tissue is disturbed, together with the destruction of the alveolar bone and periodontal ligament. It is characterized by a conversion of junctional epithelium to the pocket epithelium, formation of denser inflammatory infiltrate composed of plasma cells and macrophages, loss of collagen attachment to the root surface, and resorption of the alveolar bone [6, 11–13].

### 3.2 Immune responses in the pathogenesis of periodontal disease

In normal health conditions, periodontal tissues are capable of coping with the presence of bacteria through several mechanisms of the host immune system (e.g., **Figure 3**) [14]. However, when the balance between the infection control mechanisms and the subgingival biofilm is lost [15], which includes *Porphyromonas*

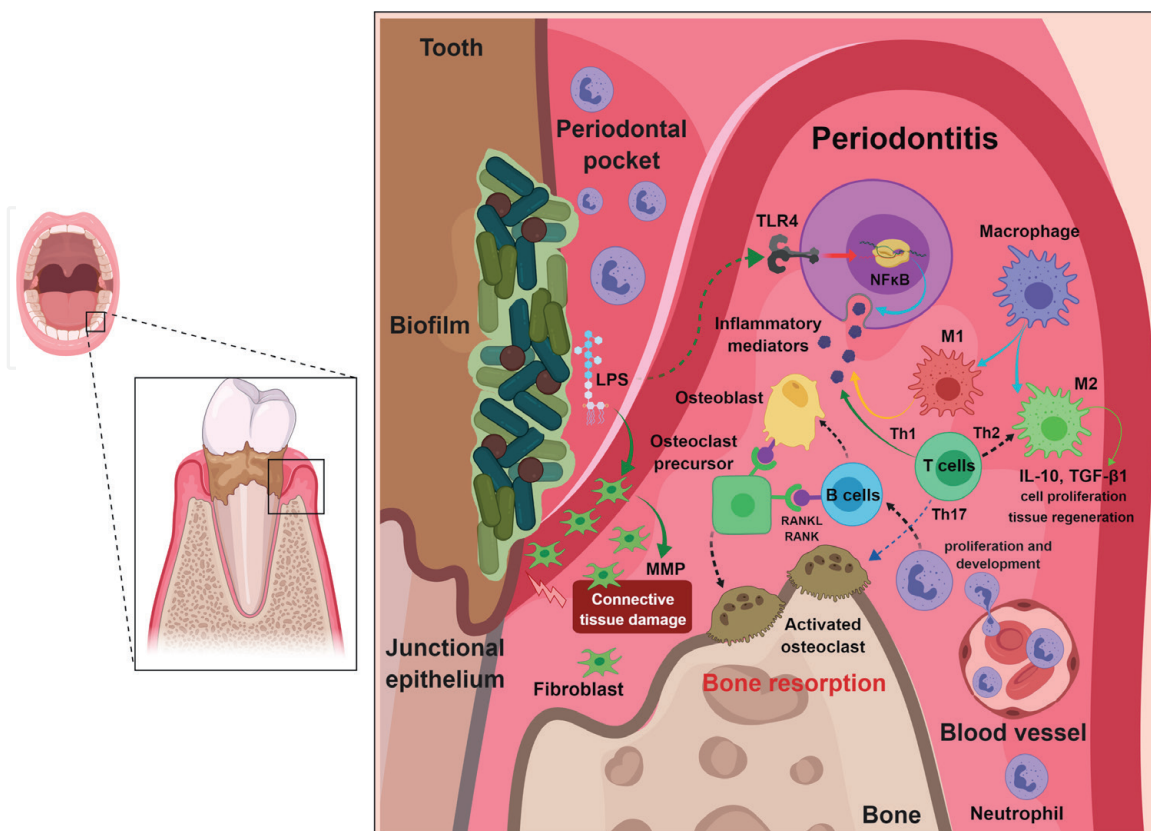


**Figure 2.** Histopathological lesions of periodontal pathogenesis. Initial, early, established, and advanced lesions of the development of gingivitis and periodontitis.

*gingivalis*, *Aggregatibacter actinomycetemcomitans*, *Tannerella forsythia*, and *Treponema denticola* [16], innate, inflammatory, and adaptive reactions are triggered. These processes result in the destruction of the tissues that surround and support the teeth, and eventually in the loss of tissues, bones and finally, of the teeth [17].

### 3.2.1 Innate immune response in periodontal disease

The most important characteristic of periodontitis is the inflammatory reabsorption of the tooth-supporting alveolar bone due to the uncontrolled host immune response against periodontal infection, since the destructive events, which lead to the irreversible phenotype of periodontal disease, are the result of the persistence of a chronic and exacerbated inflammatory immune response [18]. Inflammation is a process of the innate immune system activation, in response to exogenous and endogenous factors, such as infection by microorganisms, tissue stress, and injuries. Inflammation is a protective response, characterized by its cardinal signs, such as redness, swelling, heat, pain, and disrupted function [19]. The inflammatory response consists of four main components: (1) endogenous or exogenous factors, such as molecular patterns associated with pathogens (PAMP) and damage (DAMP), which are derived from bacteria, viruses, fungi, parasites, and cell damage, as well as toxic cellular components or any other harmful condition; (2) cellular receptors that recognize these molecular patterns (PRR), for example, Toll-like receptors (TLR); (3) proinflammatory mediators, such as cytokines, chemokines, the complement system, etc.; and (4) target cells and tissues, where these proinflammatory mediators act [20, 21]. The inflammatory response is mainly characterized by four successive phases: (1) silent phase, where the cells synthesize and release the first proinflammatory mediators; (2) vascular phase, characterized by an increase in vascular permeability and dilatation; (3) cellular



**Figure 3.** Innate and adaptive immune response during periodontal disease (description in the text).

phase, characterized by the infiltration of inflammatory cells at the site of injury; and (4) the resolution of the inflammatory response [22].

The inflammatory immune response is triggered by the interaction of resident cells with the bacterial biofilm attached to the tooth surface. Bacterial biofilm attaches to the tooth surface, making it impossible for the immune system to eradicate the infecting microorganisms efficiently, perpetuating the insult to the periodontal tissues [18]. The junctional epithelium is the first periodontal structure to face the bacterial challenge [23]. Bacteria are capable to cross the junctional epithelium and pass to the gingival conjunctive tissue, where they stimulate the gingival epithelial cells and fibroblasts to trigger the initial inflammatory responses [24]. These resident periodontal cells detect bacterial PAMP, such as lipopolysaccharide (LPS) [25], which binds to the Toll-like receptors (TLR4/2), triggering the recruitment of several protein kinases in the cytoplasmic end of the receptors, ultimately causing the activation of proinflammatory transcription factors, such as nuclear factor kappa B (NF $\kappa$ B) and activator protein 1 (AP-1) [26], which induces the synthesis and release of mediators to trigger the inflammatory response. Likewise, the gingival fibroblasts and the periodontal ligament are responsible for the destruction and disorganization of the fibrous component of the extracellular matrix of the periodontal tissue by increasing the local production and the activity of the matrix metalloproteinases (MMPs) [27, 28].

The periodontal lesion is initiated as acute inflammation characterized by increased numbers of neutrophils migrating into the gingival crevice through the junctional epithelium, which have the de novo biosynthetic capacity for chemokines and cytokines with proinflammatory, anti-inflammatory, or immunoregulatory properties. Neutrophils, through the release of chemokines, can induce the recruitment of interleukin-17-producing CD4-positive T-helper 17 cells to sites of infection or inflammation. In addition, they can promote the survival, proliferation, and development of B cells into antibody-secreting plasma cells. Likewise, it was shown that activated neutrophils express membrane-bound receptor activator of nuclear factor kappa B ligand (RANKL), a key osteoclastogenic cytokine and, thereby able of inducing osteoclastic bone resorption [29]. These recent concepts suggest that neutrophils could contribute to periodontitis not only by initiating the lesion but also by participating in its progression, by recruiting T-helper 17 cells or promoting the accumulation of B cells and plasma cells in the established and advanced lesions.

Macrophages are an important source of proinflammatory and potentially destructive molecules for tissues, such as interleukin-1 (IL-1), tumor necrosis factor alpha (TNF- $\alpha$ ), MMP, and prostaglandin E<sub>2</sub> [30], which play an important role and are elevated in the gingival tissue and in the gingival crevicular fluid of patients with chronic periodontitis [28]. Therefore, studies have shown a direct correlation of macrophage infiltration with the severity of periodontal disease [31], contributing greatly to the intensification of the degradation of the collagen matrix in the connective periodontal tissue [32, 33]. These macrophages may undergo a classical (M1) or alternative (M2) activation. M1 macrophages are induced by microbial agents (e.g., LPS) or by Th1 cytokines and show high phagocytic capacity and an increased expression of proinflammatory cytokines, costimulatory, and antimicrobial molecules. In contrast, M2 macrophages are induced by Th2 cytokines and secrete high levels of IL-10 and transforming growth factor beta 1 (TGF- $\beta$ 1). Therefore, they have immunoregulatory properties and promote cell proliferation and tissue regeneration [29, 34]. In periodontal inflammation models, macrophages share properties of both M1 and M2. However, M1 macrophages show a predominance over M2 macrophages, suggesting that M1 macrophages probably represent a subset associated with periodontitis [35–37].



### *3.2.2 Adaptive immune response in periodontal disease*

When the inflammatory response becomes chronic, the lymphocytes of the adaptive immune system invade the periodontal tissues releasing inflammatory and immune molecular mediators, which alter the balance of bone metabolism, marking the transition from gingivitis to periodontitis [29]. The activation of lymphocytes requires two types of signals: a signal induced by the antigen receptor itself when recognizing its related antigen and a costimulatory signal by professional antigen-presenting cells (APCs) [22]. In gingivitis, the predominant APCs are CD14<sup>+</sup> and CD83<sup>+</sup> dendritic cells. While in the periodontitis, the predominant APCs are CD19<sup>+</sup> and CD83<sup>+</sup> B lymphocytes [38]. Therefore, the activation of adaptive immunity has a great influence on the bone loss in periodontitis, associated with B and T lymphocytes, since several studies have shown that these cells are the main cellular sources of activator of the  $\kappa$ B ligand receptor of the nuclear factor (RANKL) during periodontal inflammation [39].

RANKL is a cytokine member of the TNF family that can be bound or secreted to the membrane and stimulates the differentiation of osteoclasts, cell fusion, and activation that leads to bone resorption [40, 41]. Osteoblasts and stromal cells of the bone marrow predominantly express RANKL bound to the membrane, which induces osteoclastogenesis through cell contact with osteoclast precursors. Likewise, activated T and B cells produce both the membrane-bound and soluble RANKL forms. Soluble RANKL can induce osteoclastogenesis independently of direct contact between infiltrating lymphocytes and osteoclast precursors on the bone surface. However, 17 T-helper cells expressing RANKL, but not T-helper 1 cells, activate osteoclasts also by direct cell-cell contact [42]. In the alveolar bone, the RANKL/OPG/RANK system controls the balance of the bone metabolism [43]. RANKL is the osteoclasts activator and the molecular signal directly responsible for the bone resorption, which interacts with its associated receptor RANK on the surface of osteoclast and osteoclast precursors, which triggers its recruitment on the bone surface and cell fusion and activation [44]. Osteoprotegerin (OPG) is a soluble protein that has the ability to block the biological functions of RANKL by competitive inhibition [45]. In periodontitis, the increase in RANKL/OPG promotes the recruitment of osteoclast precursors, their fusion, and subsequent activation, leading to bone resorption [46].

On the other hand, Th1 lymphocytes have a fundamental role in the establishment and progression of periodontitis, through the increase of IFN- $\gamma$  levels [18]. Studies have shown that mice IFN- $\gamma$ -deficient showed low levels of inflammatory cytokines and chemokines, as well as macrophages infiltrated in periodontal tissue, developing a less severe phenotype of alveolar bone destruction [47]. IL-1 $\beta$  and TNF- $\alpha$  are cytokines secreted by Th1 lymphocytes. TNF- $\alpha$  and IL-1 $\beta$  produce vasodilation, stimulate the activation of endothelial cells to increase the recruitment of immune cells, increase the chemokines production in most cell types, participate in the activation of neutrophils, and stimulate secretion and tissue activation of MMPs, among other functions. Although neither IL-1 $\beta$  nor TNF- $\alpha$  is directly involved in the stimulation of bone resorption, they indirectly promote bone destruction by stimulating sustained inflammation of the periodontal tissue [48]. Th2 lymphocytes are the main cellular source of IL-4, which promotes the change of class to the secretion of IgE in B cells and favors the alternative activation of macrophages in an IFN- $\gamma$ -independent pathway. These effector functions of the Th2 lymphocytes negatively regulate the inflammatory and Th1 lymphocyte responses, so that the polarization of a Th2-type immune response in periodontitis may represent a damaged adaptive immune response [18, 49]. Finally, RANKL can also be secreted by Th17 lymphocytes, which in cooperation with inflammatory cytokines derived from Th1 lymphocytes are capable to tilt bone metabolism favoring bone resorption [50].

#### **4. Conclusion**

The main etiological factor of periodontal disease is the bacteria, which are capable of activating the innate immune response of the host inducing an inflammatory response. The evolution of this inflammatory response culminates in the destruction of periodontal tissues. For this reason, it is important to understand the different molecular and cellular mechanisms of the pathogenesis of periodontal disease, with the purpose of making an opportune diagnosis and appropriate treatment and prognosis.

#### **Acknowledgements**

Thanks to the authors who collaborated in the writing of this chapter: Dr. en C. José Luis Muñoz-Carrillo, Dra. Viridiana Elizabeth Hernández-Reyes, Dr. Oscar Eduardo García-Huerta, Dra. Karla Mariana Chávez-Ruvalcaba, Dra. en C. Francisca Chávez-Ruvalcaba, Dra. en C. María Isabel Chávez-Ruvalcaba, and Dra. Lizbeth Díaz-Alfaro, as well as the Universities involved, Cuauhtémoc University Aguascalientes, Autonomous University of Zacatecas, and Autonomous University of Aguascalientes for financial support for chapter publication.

#### **Conflict of interest**

We have no conflict of interest related to this work.

IntechOpen

## **Author details**

José Luis Muñoz-Carrillo<sup>1\*</sup>, Viridiana Elizabeth Hernández-Reyes<sup>1</sup>, Oscar Eduardo García-Huerta<sup>1</sup>, Francisca Chávez-Ruvalcaba<sup>2</sup>, María Isabel Chávez-Ruvalcaba<sup>3</sup>, Karla Mariana Chávez-Ruvalcaba<sup>4</sup> and Lizbeth Díaz-Alfaro<sup>5</sup>

1 Faculty of Odontology, School of Biomedical Sciences, Cuauhtémoc University Aguascalientes, Aguascalientes, Mexico

2 Nutrition Degree, Health Sciences Area, Autonomous University of Zacatecas, Zacatecas, Mexico

3 Laboratory of Immunoparasitology, Academic Unit of Biological Sciences, Autonomous University of Zacatecas, Zacatecas, Mexico

4 Academic Unit of Odontology, Autonomous University of Zacatecas, Guadalupe, Zacatecas, Mexico

5 Department of Stomatology, Autonomous University of Aguascalientes, Aguascalientes, Mexico

\*Address all correspondence to: [mcbjlm@gmail.com](mailto:mcbjlm@gmail.com)

## **IntechOpen**

© 2019 The Author(s). Licensee IntechOpen. This chapter is distributed under the terms of the Creative Commons Attribution License (<http://creativecommons.org/licenses/by/3.0>), which permits unrestricted use, distribution, and reproduction in any medium, provided the original work is properly cited. 

## References

- [1] Papapanou PN, Sanz M, Buduneli N, Dietrich T, Feres M, Fine DH, et al. Periodontitis: Consensus report of workgroup 2 of the 2017 world workshop on the classification of periodontal and peri-implant diseases and conditions. *Journal of Periodontology*. 2018;**89**(Suppl. 1): S173-S182. DOI: 10.1002/JPER.17-0721
- [2] Kassebaum NJ, Bernabe E, Dahiya M, Bhandari B, Murray CJ, Marcenes W. Global burden of severe periodontitis in 1990-2010: A systematic review and meta-regression. *Journal of Dental Research*. 2014;**93**(11):1045-1053
- [3] Ansari G, Golpayegani MV, Welbury R. Histology and embryology of the teeth and periodontium. In: Ansari G, Golpayegani MV, Welbury R, editors. *Atlas of Pediatric Oral and Dental Developmental Anomalies*. Chichester: Wiley; 2018. pp. 13-16. DOI: 10.1002/9781119380894.ch2
- [4] Nanci A, Bosshardt DD. Structure of periodontal tissues in health and disease. *Periodontology* 2000. 2006;**40**(1):11-28. DOI: 10.1111/j.1600-0757.2005.00141.x
- [5] Ramos MJ. Biomecánica de los tejidos periodontales. *Kiru*. 2013;**10**(1):75-82
- [6] Lindhe J, Lang NP. *Periodontología clínica e implantología odontológica*. 6a Edición ed. Madrid, España: Editorial Medica Panamericana S. A de C.V; 2017. pp. 3-37
- [7] Hassell TM. Tissues and cells of the periodontium. *Periodontology* 2000. 1993;**3**(1):9-38. DOI: 10.1111/j.1600-0757.1993.tb00230.x
- [8] Cho MI, Garant PR. Development and general structure of the periodontium. *Periodontology* 2000. 2000;**24**(1):9-27. DOI: 10.1034/j.1600-0757.2000.2240102.x
- [9] Pisoschi C, Stanciulescu C, Banita M. Growth factors and connective tissue homeostasis in periodontal disease. In: Buduneli N, editor. *Pathogenesis and Treatment of Periodontitis*. London: InTechOpen; 2012. pp. 55-80. DOI: 10.5772/33669
- [10] Tonetti MS, Greenwell H, Kornman KS. Staging and grading of periodontitis: Framework and proposal of a new classification and case definition. *Journal of Periodontology*. 2018;**89**(Suppl. 1):S159-S172. DOI: 10.1002/JPER.18-0006
- [11] Page RC, Schroeder HE. Pathogenesis of inflammatory periodontal disease. A summary of current work. *Laboratory Investigation*. 1976;**34**(3):235-249
- [12] Kinane DF. Causation and pathogenesis of periodontal disease. *Periodontology* 2000. 2001;**25**(1):8-20. DOI: 10.1034/j.1600-0757.2001.22250102.x
- [13] Bostanci N, Belibasakis GN. Periodontal pathogenesis: Definitions and historical perspectives. In: Bostanci N, Belibasakis G, editors. *Pathogenesis of Periodontal Diseases*. Cham: Springer; 2018. pp. 1-7. DOI: 10.1007/978-3-319-53737-5\_1
- [14] Cavalla F, Araujo-Pires AC, Biguetti CC, Garlet GP. Cytokine networks regulating inflammation and immune defense in the oral cavity. *Current Oral Health Reports*. 2014;**1**(2):104-113. DOI: 10.1007/s40496-014-0016-9
- [15] Kornman KS, Page RC, Tonetti MS. The host response to the microbial challenge in periodontitis: Assembling the players. *Periodontology* 2000. 1997;**14**(1):33-53. DOI: 10.1111/j.1600-0757.1997.tb00191.x
- [16] Mira A, Simon-Soro A, Curtis MA. Role of microbial communities in the pathogenesis of periodontal

diseases and caries. *Journal of Clinical Periodontology*. 2017;**44**(Suppl. 18): S23-S38. DOI: 10.1111/jcpe.12671

[17] Silva N, Abusleme L, Bravo D, Dutzan N, Garcia-Sesnich J, Vernal R, et al. Host response mechanisms in periodontal diseases. *Journal of Applied Oral Science*. 2015;**23**(3):329-355. DOI: 10.1590/1678-775720140259

[18] Cavalla F, Bigueti CC, Garlet TP, Trombone APF, Garlet GP. Inflammatory pathways of bone resorption in periodontitis. In: Bostanci N, Belibasakis G, editors. *Pathogenesis of Periodontal Diseases*. Cham: Springer; 2018. pp. 59-85. DOI: 10.1007/978-3-319-53737-5\_6

[19] Muñoz Carrillo JL, Castro García FP, Gutiérrez Coronado O, Moreno García MA, Contreras Cordero JF. Physiology and pathology of innate immune response against pathogens. In: Rezaei N, editor. *Physiology and Pathology of Immunology*. London: InTechOpen; 2017. pp. 99-134. DOI: 10.5772/intechopen.70556

[20] Muñoz-Carrillo JL, Ortega-Martín Del Campo J, Gutiérrez-Coronado O, Villalobos-Gutiérrez PT, Contreras-Cordero JF, Ventura-Juárez J. Adipose tissue and inflammation. In: Szablewski L, editor. *Adipose Tissue*. London: InTechOpen; 2018. pp. 93-121. DOI: 10.5772/intechopen.74227

[21] Muñoz-Carrillo JL, Contreras-Cordero JF, Gutiérrez-Coronado O, Villalobos-Gutiérrez PT, Ramos-Gracia LG, Hernández-Reyes VE. Cytokine Profiling Plays a Crucial Role in Activating Immune System to Clear Infectious Pathogens. London: IntechOpen. DOI: 10.5772/intechopen.80843

[22] Muñoz-Carrillo JL, Castro-García FP, Chávez-Rubalcaba F, Chávez-Rubalcaba I, Martínez-Rodríguez JL, Hernández-Ruiz ME. Immune

system disorders: Hypersensitivity and autoimmunity. In: Athari SS, editor. *Immunoregulatory Aspects of Immunotherapy*. London: InTechOpen. pp. 1-30. DOI: 10.5772/intechopen.75794

[23] Noguchi S, Ukai T, Kuramoto A, Yoshinaga Y, Nakamura H, Takamori Y, et al. The histopathological comparison on the destruction of the periodontal tissue between normal junctional epithelium and long junctional epithelium. *Journal of Periodontal Research*. 2017;**52**(1):74-82. DOI: 10.1111/jre.12370

[24] Cavalla F, Osorio C, Paredes R, Valenzuela MA, García-Sesnich J, Sorsa T, et al. Matrix metalloproteinases regulate extracellular levels of SDF-1/CXCL12, IL-6 and VEGF in hydrogen peroxide-stimulated human periodontal ligament fibroblasts. *Cytokine*. 2015;**73**(1):114-121. DOI: 10.1016/j.cyto.2015.02.001

[25] Han MX, Ding C, Kyung HM. Genetic polymorphisms in pattern recognition receptors and risk of periodontitis: Evidence based on 12,793 subjects. *Human Immunology*. 2015;**76**(7):496-504. DOI: 10.1016/j.humimm.2015.06.006

[26] Song B, Zhang YL, Chen LJ, Zhou T, Huang WK, Zhou X, et al. The role of Toll-like receptors in periodontitis. *Oral Diseases*. 2017;**23**(2):168-180. DOI: 10.1111/odi.12468

[27] Pöllänen MT, Laine MA, Ihalin R, Uitto VJ. Host-bacteria crosstalk at the dentogingival junction. *International Journal of Dentistry*. 2012;**2012**(821383):1-14. DOI: 10.1155/2012/821383

[28] Kang W, Hu Z, Ge S. Healthy and inflamed gingival fibroblasts differ in their inflammatory response to Porphyromonas gingivalis lipopolysaccharide. *Inflammation*.

2016;**39**(5):1842-1852. DOI: 10.1007/s10753-016-0421-4

[29] Hajishengallis G, Korostoff JM. Revisiting the Page & Schroeder model: The good, the bad and the unknowns in the periodontal host response 40 years later. *Periodontology* 2000. 2017;**75**(1):116-151. DOI: 10.1111/prd.12181

[30] Cekici A, Kantarci A, Hasturk H, Van Dyke TE. Inflammatory and immune pathways in the pathogenesis of periodontal disease. *Periodontology* 2000. 2014;**64**(1):57-80. DOI: 10.1111/prd.12002

[31] Gupta M, Chaturvedi R, Jain A. Role of monocyte chemoattractant protein-1 (MCP-1) as an immune-diagnostic biomarker in the pathogenesis of chronic periodontal disease. *Cytokine*. 2013;**61**(3):892-897. DOI: 10.1016/j.cyto.2012.12.012

[32] Bodet C, Chandad F, Grenier D. Inflammatory responses of a macrophage/epithelial cell co-culture model to mono and mixed infections with *Porphyromonas gingivalis*, *Treponema denticola*, and *Tannerella forsythia*. *Microbes and Infection*. 2006;**8**(1):27-35. DOI: 10.1016/j.micinf.2005.05.015

[33] Kiili M, Cox SW, Chen HY, Wahlgren J, Maisi P, Eley BM, et al. Collagenase-2 (MMP-8) and collagenase-3 (MMP-13) in adult periodontitis: Molecular forms and levels in gingival crevicular fluid and immunolocalisation in gingival tissue. *Journal of Clinical Periodontology*. 2002;**29**(3):224-232. DOI: 10.1034/j.1600-051x.2002.290308.x

[34] Braga TT, Agudelo JS, Camara NO. Macrophages during the fibrotic process: M2 as friend and foe. *Frontiers in Immunology*. 2015;**6**:602. DOI: 10.3389/fimmu.2015.00602

[35] Gonzalez OA, Novak MJ, Kirakodu S, Stromberg A, Nagarajan R, Huang CB, et al. Differential gene expression profiles reflecting macrophage polarization in aging and periodontitis gingival tissues. *Immunological Investigations*. 2015;**44**(7):643-664. DOI: 10.3109/08820139.2015.107026

[36] Yu T, Zhao L, Huang X, Ma C, Wang Y, Zhang J, et al. Enhanced activity of the macrophage M1/M2 phenotypes and phenotypic switch to M1 in periodontal infection. *Journal of Periodontology*. 2016;**87**(9):1092-1102. DOI: 10.1902/jop.2016.160081

[37] Lam RS, O'Brien-Simpson NM, Lenzo JC, Holden JA, Brammar GC, Walsh KA, et al. Macrophage depletion abates *Porphyromonas gingivalis*-induced alveolar bone resorption in mice. *Journal of Immunology*. 2014;**193**(5):2349-2362. DOI: 10.4049/jimmunol.1400853

[38] Gemmell E, Seymour GJ. Cytokine profiles of cells extracted from humans with periodontal diseases. *Journal of Dental Research*. 1998;**77**(1):16-26. DOI: 10.1177/00220345980770010101

[39] Dutzan N, Gamonal J, Silva A, Sanz M, Vernal R. Over-expression of forkhead box P3 and its association with receptor activator of nuclear factor-kappa B ligand, interleukin (IL)-17, IL-10 and transforming growth factor-beta during the progression of chronic periodontitis. *Journal of Clinical Periodontology*. 2009;**36**(5):396-403. DOI: 10.1111/j.1600-051X.2009.01390.x

[40] Nakashima T, Hayashi M, Takayanagi H. New insights into osteoclastogenic signaling mechanisms. *Trends in Endocrinology and Metabolism*. 2012;**23**(11):582-590. DOI: 10.1016/j.tem.2012.05.005

[41] Kim JH, Kim N. Regulation of NFATc1 in osteoclast differentiation. *Journal of Bone Metabolism*.

2014;**21**(4):233-241. DOI: 10.11005/jbm.2014.21.4.233

[42] Kikuta J, Wada Y, Kowada T, Wang Z, Sun-Wada GH, Nishiyama I, et al. Dynamic visualization of RANKL and Th17-mediated osteoclast function. *The Journal of Clinical Investigation*. 2013;**123**(2):866-873. DOI: 10.1172/JCI65054

[43] Belibasakis GN, Bostanci N. The RANKL-OPG system in clinical periodontology. *Journal of Clinical Periodontology*. 2012;**39**(3):239-248. DOI: 10.1111/j.1600-051X.2011.01810.x

[44] Lee JW, Kobayashi Y, Nakamichi Y, Udagawa N, Takahashi N, Im NK, et al. Alisol-B, a novel phyto-steroid, suppresses the RANKL-induced osteoclast formation and prevents bone loss in mice. *Biochemical Pharmacology*. 2010;**80**(3):352-361. DOI: 10.1016/j.bcp.2010.04.014

[45] Hofbauer LC, Neubauer A, Heufelder AE. Receptor activator of nuclear factor-kappaB ligand and osteoprotegerin: Potential implications for the pathogenesis and treatment of malignant bone diseases. *Cancer*. 2001;**92**(3):460-470. DOI: 10.1002/1097-0142(20010801)92:3<460::AID-CNCR1344>3.0.CO;2-D

[46] Menezes R, Garlet TP, Letra A, Bramante CM, Campanelli AP, Figueira Rde C, et al. Differential patterns of receptor activator of nuclear factor kappa B ligand/osteoprotegerin expression in human periapical granulomas: Possible association with progressive or stable nature of the lesions. *Journal of Endodontia*. 2008;**34**(8):932-938. DOI: 10.1016/j.joen.2008.05.002

[47] Garlet GP, Cardoso CR, Campanelli AP, Garlet TP, Avila-Campos MJ, Cunha FQ, et al. The essential role of IFN-gamma in the control of lethal *Aggregatibacter actinomycetemcomitans*

infection in mice. *Microbes and Infection*. 2008;**10**(5):489-496. DOI: 10.1016/j.micinf.2008.01.010

[48] Preshaw PM, Taylor JJ. How has research into cytokine interactions and their role in driving immune responses impacted our understanding of periodontitis? *Journal of Clinical Periodontology*. 2011;**38**(Suppl. 11):60-84. DOI: 10.1111/j.1600-051X.2010.01671.x

[49] Gemmell E, Yamazaki K, Seymour GJ. The role of T cells in periodontal disease: Homeostasis and autoimmunity. *Periodontology 2000*. 2007;**43**:14-40. DOI: 10.1111/j.1600-0757.2006.00173.x

[50] Cardoso CR, Garlet GP, Crippa GE, Rosa AL, Júnior WM, Rossi MA, et al. Evidence of the presence of T helper type 17 cells in chronic lesions of human periodontal disease. *Oral Microbiology and Immunology*. 2009;**24**(1):1-6. DOI: 10.1111/j.1399-302X.2008.00463.x