

We are IntechOpen, the world's leading publisher of Open Access books Built by scientists, for scientists

4,800

Open access books available

122,000

International authors and editors

135M

Downloads

Our authors are among the

154

Countries delivered to

TOP 1%

most cited scientists

12.2%

Contributors from top 500 universities



WEB OF SCIENCE™

Selection of our books indexed in the Book Citation Index
in Web of Science™ Core Collection (BKCI)

Interested in publishing with us?
Contact book.department@intechopen.com

Numbers displayed above are based on latest data collected.

For more information visit www.intechopen.com



Principles of Fetal Surgery

Ahmed Abdelghaffar Helal

Abstract

Fetal therapy (in utero therapy) is a type of special therapy which aims to prevent or correct congenital anomalies in fetus, and prevents their severe consequences on later fetal development. It includes the use of in utero human fetal stem cell transplantation, fetal gene therapy and gene-editing technology as a new treatment for fetal genetic disorders. It started with open fetal surgery and then significantly advancing with innovations, toward minimally invasive fetal procedures, which are undoubtedly the future of fetal surgery, with the goal of providing the best possible fetal outcome, while minimizing the morbidity and mortality to the mother. The goal of fetal treatments is to decrease both fetal and maternal risks and prevent premature rupture of membranes. Fetal ultrasound and MRI are crucial for successful fetal interventions. Moreover, multidisciplinary fetal teams, including fetal surgeon, ultrasonographer, perinatologist, and anesthesiologist, are essential for optimum care to both mother and fetus. Finally, any new modality of fetal therapy must be thoroughly evaluated in animal models before clinical practice. In this chapter, we discuss the basic principles of fetal surgery, milestones of fetal surgery, specific fetal anomalies that are amenable for fetal surgery, successful fetal surgery criteria and future of fetal surgery.

Keywords: fetal therapy, in utero therapy, fetal team, minimally invasive fetal procedures

1. Introduction

Fetal surgery or in utero therapy tries to prevent or correct multiple congenital anomalies in the fetus to prevent their severe consequences on later fetal development. It started with open fetal surgery then innovations toward minimally invasive procedures have occurred. In this chapter, we discuss the basic principles of fetal surgery, the general history of its development, important specific conditions and procedures used to treat them, and the future of the field.

2. Key points

- The goal of fetal treatments is to decrease both fetal and maternal risk and prevent premature rupture of membranes.
- Real-time ultrasound and fetal MRI is crucial to the implementation and success of fetal procedures.

- Multidisciplinary fetal teams, including a fetal surgeon, ultrasonographer, perinatologist, and anesthesiologist, are critical to the delivery of optimum care.

3. History and general principles of fetal surgery

In 1963 first fetal intervention was performed (**Table 1**), the first fetal transfusion was reported by Liley. He used Tuohy needle (size 16-G) into the fetal peritoneal space. He injected a contrast material into the amniotic cavity to localize the fetal abdomen and the swallowed contrast opacify the fetal bowel. In the 1970s, endoscopy was used for direct visualization of the fetus, and the first fetal blood sampling or biopsy tissue was reported, however because of the limited technical skill, the therapeutic uses were not applicable [1, 2]. After that, with more use of ultrasound as non-invasive diagnostic tool, the use of diagnostic fetoscopy was replaced with percutaneous needle-based techniques under ultrasound guidance. In the 1980s open fetal surgery was started (direct exposure of the fetus by maternal laparotomy and hysterostomy), then open fetal surgery was replaced with a less invasive fetoscopy, where video camera was inserted inside the uterus under ultrasound guides. At first, fetoscopy was performed in amniotic fluid medium, using a single port to enter the uterine cavity and with a side way working channel. However, amniotic fluid medium poses many limitations for many fetal surgeries especially that require dissection and suture. Low quality images in the fluid medium, and any bleeding will prevent an adequate imaging, and it can end the procedure. Moreover, the “fluctuation” of the fetus during the intervention prevent maintenance of the ideal accessible position. In 2010 Kohl et al. use low insufflation pressure carbon dioxide of amniotic cavity which was left with some amount of amniotic fluid [3–6].

First fetal intervention	1963
Direct visualization of the fetus	1970
Start of open fetal surgery	1982
Thoraco-amniotic fetal shunt placement	1987
Treatment of twin–twin transfusion syndrome by laser ablation	1990
Closure of fetal myelomeningocele using fetoscopy	1997
Treatment of fetal congenital diaphragmatic hernia by tracheal clipping (Fetendo technique)	1997
Excision of fetal amniotic band using fetoscopy	1997
Treatment of fetal congenital diaphragmatic hernia by fetoscopic balloon tracheal occlusion technique	2001

Table 1.
Time scales for important fetal surgeries.

4. Milestones in development of fetal surgery

Criteria for fetal surgery are summarized in **Table 2**.

4.1 Ethical considerations

The ethical issues in the field of fetal surgery are complex because the medical intervention is always invasive, often experimental, involves at least two patients the mother and fetus, and the success rate is difficult to measure. On the

I.	Prompt diagnosis of the pathology and associated anomalies.
II.	Pathophysiology of the disease is documented, and overall prognosis is promising
III.	No curative postnatal treatment.
IV.	Animal models prove feasibility of the in utero technique, preventing serious effects of the pathology.
V.	Fetal therapy performed in specialized multi-disciplinary fetal care centers within clear procedure with local ethics committee approval and signed informed maternal or parent consent.

Table 2.
Successful fetal surgery criteria.

other hand, strong evidence on the benefits of fetal surgery are not present, with many centers considered fetal surgery as an experimental technique to correct fetal anomalies. Controlled randomized studies to evaluate the effects of fetal surgeries on both mother and fetus are still needed. More often, doctors attempt fetal surgery in clinical settings without reporting post-operative outcomes in medical journals. The overall goal of fetal interventions is clear: to improve the health of fetus by intervening before birth to correct or treat prenatally diagnosed abnormalities. Mother and fetus that undergo these interventions must have the same protection afforded to other study participants, with detailed explanation of both short and long-term risks and benefits of these interventions on both the mother and the fetus. Therefore, diagnostic or therapeutic fetal intervention, cannot be performed without mother explicit informed consent (Table 2) [7–10].

4.2 Surgical techniques and procedures

4.2.1 Surgical team

In fetal surgery, there are complex diseases and two patients, so careful planning and open communication before, during, and after surgery between the members of the multidisciplinary care team are essential. The team must include pediatric surgery, obstetrics, pediatric anesthesia, obstetric anesthesia, cardiology, radiology, otolaryngology, neonatology, neonatal nursing, and operative room nursing [11, 12].

During any fetal procedures, the use of ultrasound will guide the pediatric surgeon and/or obstetrician and allow for monitor the fetus during surgery. The surgeon should actively communicate with the anesthesia team, as well as nursing and scrub staff, throughout the procedure. Also, the presence of knowledgeable technical support staff familiar with the specialized equipment and instrument is essential [13, 14].

4.2.2 Surgical approach

Currently, fetal surgery can be classified into three broader areas; open fetal surgery, minimally invasive fetal surgery and EXIT procedures. Each procedure is subdivided into several subdivisions, in an attempt to treat a wide number of severe pathologies that would compromise the fetus. During minimally invasive fetal surgeries a small skin incision on the mother's abdomen was done. The location of the placenta, as well as the intrauterine pathology will guide the site of the planned incision. 1–2 mm instruments were used to access the fetus are to minimize maternal morbidity. Also, curved instruments may be used to avoid injury to anteriorly placed placenta. During fetal access, any present fluid (ascites, pleural effusions,

cystic structures, or the bladder) are aspirated or shunted into the amniotic space. During fetal cardiac valvuloplasty and radiofrequency ablation for treatment of complicated twin gestation, needle-based access is very helpful [15–20].

4.3 Fetoscopic procedures

Usually all patients submitted for a fetoscopic procedure are often pre-medicated with a tocolytic agent. Local or regional anesthesia are usually used. The surgery can be performed in the surgical theater, labor or delivery unit, or in the ultrasound department (depends on gestational age of the fetus). The used instruments, particularly, endoscopes have undergone numerous evolution, based on prototypes developed in animal models. Fetoscopes diameters are between 1.0 and 2.0 mm. Sharp trocars have been developed to accommodate the wide range of diameters used for different operations. Operative fetoscopy is a sonoendoscopic enterprise that has evolved so that the surgical team can see the ultrasound and fetoscopic images simultaneously. Basically, the ultrasound is used to identify an appropriate entry point to direct the trocar into the amniotic cavity, avoiding the placenta and the fetus as well as maternal organs, such as the bowel and bladder. However, some operators have documented the safety, in their hands, of a transplacental approach. Despite this experience, most operators still attempt to avoid the placenta. Nowadays, fetoscopic technique is indicated when direct visualization of the fetus (more than ultrasonography) is needed, as in treatment of cases of twin to twin transfusion syndrome, posterior urethral valves, constricting amniotic bands, and tracheal balloon occlusion for treatment of congenital diaphragmatic hernia. Fetoscopic procedures are performed using 1.2- to 3.0-mm endoscopes. Pictured is a 3 mm 0° endoscope, adjustable length, with a 1-mm working channel (**Figure 1**) [21–29].

4.4 EXIT procedures

EXIT procedures principles is to perform controlled delivery to allow for fetal intervention and establishment of airway prior to cord clamping/cutting. Indications of EXIT procedures includes severe airway obstruction or likelihood of cardiopulmonary insufficiency at birth. Cervical masses, congenital lung malformations (CLM), congenital high airway obstruction (CHAOS), pulmonary agenesis, transition to ECMO. It performed under general anesthesia (fetal anesthesia, uterine relaxation), with maintenance of placental circulation and dorsal supine leftward tilt. Steps includes; Pfannenstiel incision, then customized hysterotomy based on placental location, partial delivery of fetus, and placement of

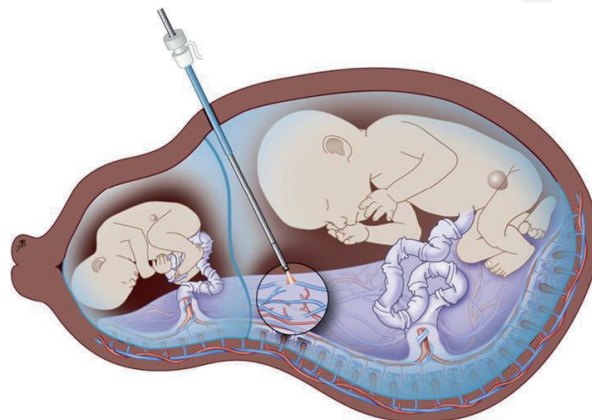


Figure 1.
Fetoscopic laser ablation of abnormal chorionic vessels for TTTS.

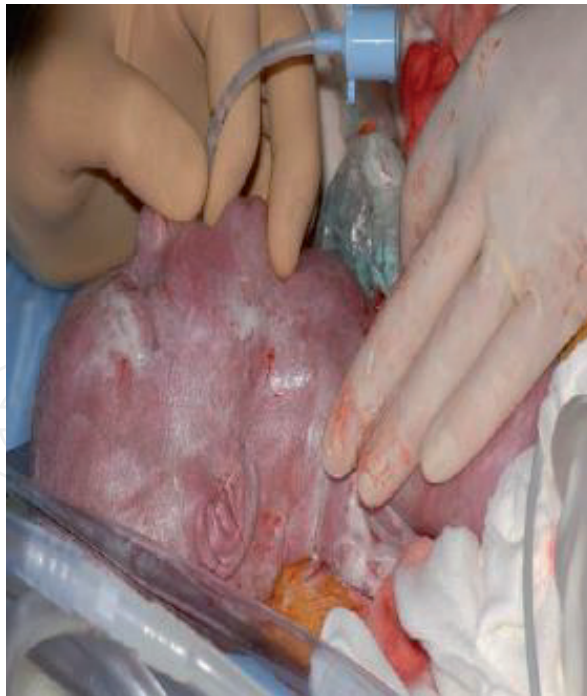

Figure 2.
Successful oro-tracheal intubation during the EXIT procedure.

monitors, fetal airway establishment during surgical intervention then delivery was completed with, transition of the baby to postnatal care, and finally completion of cesarean section (**Figure 2**) [30, 31].

4.4.1 Anesthetic care

Before anesthesia, all physiological changes associated with pregnancy must be considered. The effects of pregnancy on mother pulmonary and cardiovascular function must be considered. Adequate precautions should be taken to prevent hypoxemia and aspiration. The magnesium sulfate used in tocolysis may decrease capillary oncotic pressure and increase capillary permeability with increased risk of pulmonary edema. Aorto-caval compression must be prevented by using left uterine displacement. The doses of anesthetic drugs must be adjusted. Maternal local anesthesia can be effectively used for most needle-based and single port fetoscopic procedures. When multiple ports or caesarian section could be necessary, regional anesthesia; epidural or combined spinal epidural can be added. On the other hand, fetal anesthesia is indicated only for endoscopic procedures performed directly on the fetus. All fetal anesthetic drugs are typically administered through intramuscular route and consists of opiates and non-depolarizing muscle relaxants. Atropine is usually given to avoid fetal bradycardia. For placental or cord procedures with no direct fetal contact, the risk-benefit of fetal anesthesia should be weighed [32–35].

5. Drawbacks of fetal surgery

The drawbacks of fetal surgery, includes bleeding, amniotic fluid leak, chorioamniotic separation, chorioamnionitis, premature rupture of membranes, preterm labor, preterm birth, and fetal loss. Premature rupture of membranes, preterm labor is the most common complication of minimally invasive fetal surgery, with high morbidity, including oligohydramnios, chorioamnionitis, and preterm delivery. However, accurate analysis of the frequency of these complications are difficult

due to variations in both the assessment of the complication as well as reporting methods. Factors increasing the risk during minimally invasive fetal procedures include the number of ports and the diameter of the used instruments. A systematic review of 1376 minimally invasive fetal procedures for lower urinary tract obstruction, and twin reversed arterial perfusion reported that increased diameter of the instrument and increased number of ports are major predictors of iatrogenic premature rupture of membranes [36–38].

Following open fetal procedure, risk of hysterotomy scar weakness may interrupt both current and future labor. Some cases of uterine scar rupture after open fetal procedure was reported, starting from the second trimester, may be caused only by the uterine distension (with no uterine contractions) which form significant risk to both mother and fetus. Moreover, maternal counseling about the risk of delivery complications must be considered. On the other hand, minimally invasive fetal procedures do not preclude vaginal delivery. However, long-term follow-up of subsequent pregnancies after these procedures is not available, beside the complications of repeat caesarian section, significant advantage of minimally invasive fetal procedures should be considered [39, 40].

6. Certain problems amenable for fetal surgery

Some important indications for fetal interventions are summarized in **Table 3**.

6.1 Twin gestations

6.1.1 Twin–twin transfusion syndrome (TTTS)

Monochorionic (shared) placenta with A-V, V-V, A-A connections and unbalanced flow between two twins

- Donor – low flow, oligohydramnios, high output heart failure, brain ischemia, small
- Recipient – fluid overload, polyhydramnios, congestive heart failure, hydrops fetalis, large

Prognosis: 80–90% mortality for both if untreated.

Fetal Surgery

- High-volume amnioreduction historically (survival of at least one twin 60%)
- Fetoscopic laser ablation of vascular connections

Offered to Stage II or greater

Selective A-V or nonselective

76% single survivor, 36% dual survivors.

The donor twin usually develops hypovolemia, leading to oliguria and oligohydramnios from reduced renal perfusion, and the recipient twin suffers the consequences of hypervolemia, including polyuria and polyhydramnios. Both twins are at risk for significant morbidity [41, 42].

Basic principles for TTTS interventions are to prevent preterm delivery caused by polyhydramnios, through removing the excess amniotic fluid surrounding

Fetal surgery	Why to interfere?
I-Surgery on the fetus	
Congenital diaphragmatic hernia	Avoidance of pulmonary hypoplasia and pulmonary hypertension
Sacrococcygeal teratoma	Stop of steal phenomenon, avoid cardiac failure and polyhydramnios
Thoracic space-occupying lesions	Avoid pulmonary hypoplasia and cardiac failure
Lower urinary tract obstruction	Avoid renal failure and pulmonary hypoplasia
Cardiac malformations	Avoid hypoplasia or progressing damage to developing heart
Myelomeningocele	Repair of exposed spinal nerves, stop cerebrospinal fluid leakage, prevent hydrocephaly and hindbrain herniation
II- Placenta, cord or membranes surgery	
Complicated monochorionic pregnancies:	Arrest of fetto-fetal transfusion and its consequences
Twin-twin transfusion syndrome (TTTS)	Avoid preterm delivery
Twin-reversed-arterial-perfusion sequence (TRAP) and other discordant anomalies	Avoid damage to co-twin
Twin-anemia polycythaemia sequence	In some conditions (TTTS/TRAP) reversal of cardiac failure and polyhydramnios
III- Selective intra-uterine growth restriction	
Amniotic band syndrome	Avoid deformities and functional loss
Chorioangioma	Avoid of cardiac failure, hydrops fetoplacental and polyhydramnios

Table 3.
Some important indications for fetal surgery.

the recipient twin, with improved fetal circulation by decreasing pressure on the chorionic plate. In 1990, fetoscopic laser was used to coagulate the crossing superficial blood vessels separating the 2 fetal circulations and destroying the inter-twin vessels that cause discordant twin-twin transfusion. Nowadays, laser ablation is the preferred treatment for TTTS between 16 and 26 weeks of gestation. The procedure is performed through a single uterine access site using a fetoscope and thin laser (Table 4) [43–45].

6.1.2 Twin reversed arterial perfusion

One normal twin acts as a “pump” for a cardiac, a cephalic twin via A-A anastomoses

I	Presence of Poly and oligohydramnios
II	Stage I plus non-visualized bladder in donor twin
III	Stage II plus seriously abnormal Doppler (umbilical artery absent or reversed end-diastolic velocity, ductus venosus reversed flow, pulsatile umbilical venous flow)
IV	Stage III plus evidence of hydrops in either twin
V	Fetal death

Table 4.
Staging of TTTS.

Normal twin much like donor twin in TTTS with R/O high output heart failure, hydrops fetalis, 50% mortality

Fetal Surgery

- Open hysterotomy/delivery
- Fetoscopic ligation
- Bipolar cautery/harmonic scalpel division
- Thermal/laser coagulation
- RFA of acardiac/acephalic cord insertion

6.1.3 Selective fetal reduction

In addition to TTTS, other serious problem that can affect monochorionic twin pregnancies, includes severe intrauterine growth restriction, structural anomalies, twin anemia polycythemia sequence, and TRAP sequence, or a cardiac twinning. In some complicated monochorionic pregnancies, elective fetal reduction is recommended especially for high risk of hemodynamic compromise or intrauterine fetal death, aimed to prevent neurologic injury or demise to the co-twin. Fetal intra-cardiac potassium chloride injection is contraindicated in these pregnancies, because of risk of transmission between twins and selective termination must be performed with interruption of blood flow to the fetus. This interruption usually performed through ligation of the umbilical cord, fetoscopic laser coagulation, ultrasound-guided and bipolar cord coagulation. Selective fetal reduction was seriously indicated in complicated twin pregnancies what is TRAP sequence. In TRAP sequence, one twin is incompatible with life due to absent or rudimentary heart, as well as absence of other vital structures, as head (anencephaly). This twin usually has no placental blood supply, and it receives its blood supply directly through vascular connections from the second normal twin (acts as pump twin). Therefore, the normal twin will rapidly develop high-output heart failure, with more than 50% mortality rate. Selective fetal reduction aims to stop blood flow to incompatible with life twin, and save the life of normal (pump) twin. In the largest review from 12 fetal centers from the North American Fetal Therapy Network registry data, identified 98 patients who underwent percutaneous radio frequency ablation of a cardiac twin. In this series, the overall survival of the normal (pump) twin to 30 days was 80% [46–50].

6.2 Lower urinary tract obstruction (LUTO)

LUTO can be caused by stenosis of the urethral meatus, valves, urethral atresia, ectopic insertion of a ureter or peri-vesical tumors. Bladder shunts are effective for urine diversion, restoring amniotic fluid and thereby preventing pulmonary hypoplasia. Whether shunting effectively salvages renal function is uncertain. For that, prior accurate assessment of renal function is required. The actual anatomical cause of LUTO proved to be an important predictor. Posterior urethral valves do much better in the long run, while babies with urethral atresias or the Prune Belly phenotype do less well. At the moment, the two commonly used techniques, are percutaneous vesico-amniotic shunting, under ultrasound guide, where double pigtail stent is inserted, usually combined with amnio-infusion. The second procedure is fetal cystoscopy, where fetoscope is inserted into the fetal bladder, to diagnose the

source of obstruction and to ablate PUV. The commonly used methods to ablate the valve, includes guide wires, hydro-ablation and laser-ablation. The first open clinical fetal surgical intervention for a case of lower urinary tract obstruction (LUTO), not eligible for shunt placement. Instead, fetal ureterostomies were successfully created. There were no maternal complications, but unfortunately the fetus never produced any urine. On the other hand, main complications of shunting include; failure to insert the catheter, occlusion of the catheter, dislocation, and sometimes fistula formation. In order to conclude and evaluate the results of in-utero VAS, and its long-term outcomes, randomized, controlled trial, “Percutaneous vesico-amniotic shunting versus conservative management for fetal Lower Urinary Tract Obstruction” (PLUTO), was performed in the United Kingdom, Ireland, and the Netherlands from 2006 to 2012. The study performed on 31 cases (16 submitted to VAS, 15 undergo conservative treatment). Study reported that fetal cystoscopy, although it is more invasive than VAS, it has the advantage of confirming the diagnosis of PUV, and more accurate in selection of patients who will benefit from valve ablation. In other multi-centric retrospective study includes 50 cases submitted to fetal cystoscopies for treatment of LUTO, 30 fetuses were diagnosed with PUV and were treated with laser-ablation. Other 13 fetuses were diagnosed with urethral atresia, 5 fetus diagnosed with urethral stenosis, and 2 fetuses diagnosed with trisomy 18 (not treated). The results of the 54 fetuses with normal karyotype were, 32.4 weeks mean delivery gestational age, and 34.8% overall 2 years’ survival. For PUV patients treated with laser-ablation, 53.6% 2 years’ survival. Although 20% (6 of the 30) developed recurrence of LUTO symptoms, and further fetal procedure was performed in 10% (3 patients). Postnatal ablation of PUV was needed in 10 of the 17 survivors. Normal renal function at 2 years of age, was achieved in 75% of infants with PUV (12 of the 16), which considered more promising than the 29% reported in the PLUTO trial with VAS. Reports up to date indicate that, minimally invasive fetal procedure (in selected cases of LUTO), can improve the survival when compared to expectant treatment. However, studies of long term renal function are less encouraging [51–56].

6.3 Intrauterine myelo-meningocele (IMM)

IMM, or Spina bifida, is defined as failure of complete closure of the neural tube with exposure of the spinal canal structures. Lumbar or cervical vertebral levels are the most commonly affected sites, however IMM can occur anywhere along the spine. Neurologic deficits with motor and somato-sensory abnormalities are the most feared complications. In addition, bowel and bladder function may be affected due to injury of autonomic nervous system. Moreover, mostly all patients with IMM will develop Arnold-Chiari II malformation affecting hindbrain, with non-communicating hydrocephalus, which requires ventriculo-peritoneal shunting. Although mortality of IMM was low in the perinatal period, its long-term neurologic morbidity may be fatal, and up to 30% of patients may die before adulthood [57–60].

6.3.1 IMM repair

At the moment, the compared outcomes of pre-natal versus post-natal repair of IMM showed that; although prenatal surgery has an increased risk of preterm delivery, pre-natal repair had significantly better outcomes than the post-natal repair. Pre-natal repair for IMM decrease the risk of death and subsequent needs for shunting (nearly at age of 12 months). Also, pre-natal repair improves scores of mental and motor function (at 30 months). However, pre-natal repair was associated with an increased risk of preterm delivery and uterine dehiscence at labor. Therefore, the potential benefits of pre-natal repair must be balanced against the risks of

prematurity and maternal morbidity [61–65]. In a retrospective review of 54 children evaluated for lower extremity neuro-motor function and short-term ambulatory function following fetal myelomeningocele closure, they concluded that fetal myelomeningocele repair results in better than predicted lower extremity neuro-motor function at birth and short-term ambulatory status. However, these children continue to demonstrate movement incoordination which is characteristic for children with Spina-bifida. In retrospective study evaluated the incidence and clinical implications of the development of cutaneously derived intradural inclusion cysts (ICs) following fetal myelomeningocele closure through parental questionnaire. They concluded that intradural ICs can develop following fetal myelomeningocele repair. ICs long-term complications in these children may include deterioration of bladder function, and loss of lower-extremity function after fetal myelomeningocele closure. Koh et al. 2006 compared urodynamic findings in patients who underwent pre-natal closure of IMM with those of patients who underwent post-natal closure. All pre-natally treated patients had lower lumbo-sacral lesions on neurological examination. In comparison, 39% of post-natally treated patients showed lack of sphincter activity at newborn examination, with similar findings noted at 1-year evaluation. Regarding bladder function, all pre-natally treated patients showed detrusor over-activity, compared to 38% of post-natally treated patients, up to 1-year evaluation. They concluded that fetal closure of IMM is associated with a higher incidence of complete denervation of the external urethral sphincter and detrusor over-activity compared to post-natal repair. Open fetal IMM closure has been extensively studied and its benefits to the fetus have been proven. Minimally invasive fetoscopic repair is technically difficult, with high risk of membrane separation and premature rupture of membrane, and its benefits to the fetus have not been proved. Therefore, minimally invasive IMM repair still needs further more studies to confirm its validity for clinical applications [66–70].

6.4 Congenital diaphragmatic hernia (CDH)

One in 2500 live infant births may be affected with CDH. It consists of abnormal defect in the fetal diaphragm, resulting in herniation of all or part of abdominal viscera into the thoracic cavity (according to the defect size). Pulmonary hypoplasia and pulmonary hypertension, usually present as a result of abnormal development of the lungs and pulmonary vasculature, this may cause persistent fetal circulation and respiratory failure with increased mortality rate. Despite great improvement in its diagnosis and treatment, infant mortality from isolated CDH still about 20–30%. Poor prognostic indicators by ultrasonography include low lung-to-head ratio, liver herniation into the thoracic cavity, and low total lung volume detected by fetal MRI. Initial experimental studies using sheep models demonstrated that prenatal repair of the diaphragmatic hernia could reverse the pulmonary hypoplasia caused by a surgically created CDH. The first clinical experience in humans likewise involved open fetal surgery. High fetal mortality rate is associated with this approach, because of umbilical vein kinking during reduction of the herniated liver into the fetal abdomen. Therefore, all recent studies consider that minimally invasive methods, taking the upper hand for treatment of CDH, as it stimulates lung growth in utero, while open fetal repair of the diaphragmatic defect was abandoned from the clinical use. Preliminary experimental studies in fetal lambs were promising, demonstrating that fetal tracheal occlusion improved fetal lung growth and reducing the severity of pulmonary hypoplasia. In cases of severe CDH, postnatal mortality appears to be significantly lower with in utero surgical intervention. Studies of fetal endoscopic tracheal occlusion (FETO) performed in cases of severe CDH have demonstrated a significantly higher survival rate compared with control fetuses that did not undergo

FETO. Severe PAH occurred in 47% of fetuses that underwent FETO, but in 89% of patients in the prenatal expectant management group (**Figure 3**) [58, 71, 72].

So, fetal surgeons prefer minimally invasive procedures to avoid large hysterotomy and adequately visualize and access the fetal trachea. In 1997 the first fetal endoscopic (Fetendo) tracheal clipping, was done in human fetus, where maternal laparotomy was done, then 4 trocars was inserted through uterus to access and clip the fetal trachea. For the fear of serious complications of tracheal damage and vocal cord paralysis during clipping, fetoscopic balloon tracheal occlusion technique was introduced, in which no fetal neck dissection and only single uterine port was needed. Fetal endoscopic tracheal occlusion (FETO) is usually performed between 26 and 30 weeks of gestation., A trocar is placed through the maternal abdomen into the amniotic cavity guided by ultrasound, and fetoscope is inserted through the fetal mouth, then advanced into the fetal trachea. Once the carina has been retched, the balloon is inflating with physiologic solution and left just above the carina. The correct position is then checked by ultrasound imaging. In some studies, the tracheal balloon was removed at the time of delivery through ex utero intrapartum therapy. However, balloon removal before birth not only allows for the possibility of vaginal birth, but also was shown to increase pneumocyte cells differentiation type II, with increasing surfactant production. Currently, tracheal occlusion can be reversed in utero, by performing second fetoscopic procedure (typically at 34 weeks of gestation) [73, 74]. A multicenter European series including 210 cases of FETO with severe CDH (liver up and lung-to-head ratio ≤ 1) they reported 48.0% rate of survival to discharge, with 47.1% incidence of premature rupture of membrane. Up to date meta-analysis comparing survival outcome between FETO and a contemporary control group, reported that FETO improves survival compared with standard perinatal care in fetuses with isolated CDH and severe pulmonary hypoplasia (lung-to-head ratio ≤ 1). 46.3% of fetuses (Fifty-one of 110) who had undergone FETO survived to discharge, compared with 5.9% (6 of 101) in the control group, giving the FETO group more significant survival chance. However, the true benefits of FETO are difficult to determine because the severity of CDH was not measured uniformly and there was great variability in the postnatal care of these infants. International, randomized controlled studies to evaluate the role of intrauterine fetal surgery in CDH cases with moderate and severe pulmonary hypoplasia is still needed [75].

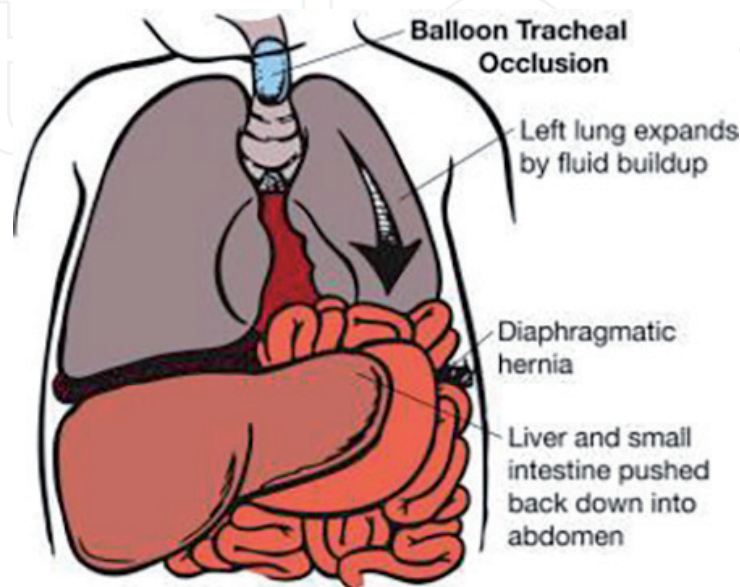


Figure 3.

Tracheal occlusion in fetus with congenital diaphragmatic hernia (CDH) to increases lung volume, decreases herniation of abdominal viscera, and improves postnatal lung function.

6.5 Amniotic band syndrome (ABS)

Amniotic band syndrome can lead to fetal death from umbilical cord strangulation and/or congenital limb deformity or loss, presumed to result from ischemia caused by constriction bands that interfere with vascular perfusion. There is increasing experience with intrauterine release of congenital constrictions and evidence is mounting that this therapy may help save/restore some limb function and morphology. The location of the bands and timing of fetal damage will affect the presentation, severity, and outcome of the condition. For example, pseudosyndactyly or limb amputation can be the results of constriction bands at the extremities, whereas more midline bands can result in craniofacial, thoracic, or abdominal defects, and may be fatal. The etiology of this syndrome is unknown, and theories range from a genetic basis or early disruption of the germinal disc to traumatic disruption of the membranes later in fetal development. Fetoscopic release of amniotic bands using minimally invasive surgery, can help in preservation of life and or limb saving in cases of ABS. The present acceptable functional outcome in 50% of cases is promising, although, clear selection criteria are needed to justify the risk of this in-utero invasive procedure, through increased experience and larger studies on this type of therapy for ABS (**Figure 4**).

In cases of extremity involvement by amniotic band syndrome, the band must be released using fetoscope to save the normal development of the limb and allow for normal limb function. Ultrasound imaging can easily diagnose the problem, showing; distal limb edema and interrupted blood flow by Doppler, with or without visualization of the constricting band. Although, the available reports include small case series, its results suggest that fetuses must have distal arterial limb flow detected by Doppler in order to benefit from intervention. Moreover, data from recent studies reported that fetuses with single limb involvement tend to do better than those with multiple involved limbs. Surprising, the incidence of PROM with this procedure seem to be higher than for other fetoscopic procedures, (reported rates up to 78%). Although, small number of cases were reported in all available studies, and considering the learning curve in this studies, it could also be related to inherent membrane problems in these fetuses [76, 77].

6.6 Sacrococcygeal teratoma (SCT)

Although the mortality rate is 5% for SCT diagnosed in the newborn, the mortality rate is about 50% for fetal SCT. Rupture of the tumor, or hemorrhage inside, or high output heart failure, and premature labor, form the main causes of fetal loss. Every attempt at interventions, to prevent this high prenatal mortality are the target of study of several fetal centers. Resection of the tumor (in utero) should be consider for treatment of pre-mature patients with early signs of heart failure or placentomegaly.

- Removal of the external part of the tumor is usually preferred, followed by later removal of its pelvic extension.
- Alternatively, radio-frequency, or thermal ablation can be used to occlude supplying arteries to the tumor.

It is important to note the related morbidity of all mentioned procedures, like risk of preterm delivery, beside procedure failure rate. The related morbidity can be reduced with minimally invasive procedures, however, the fear from decreased efficacy in local control, still a significant problem. Moreover, these less invasive

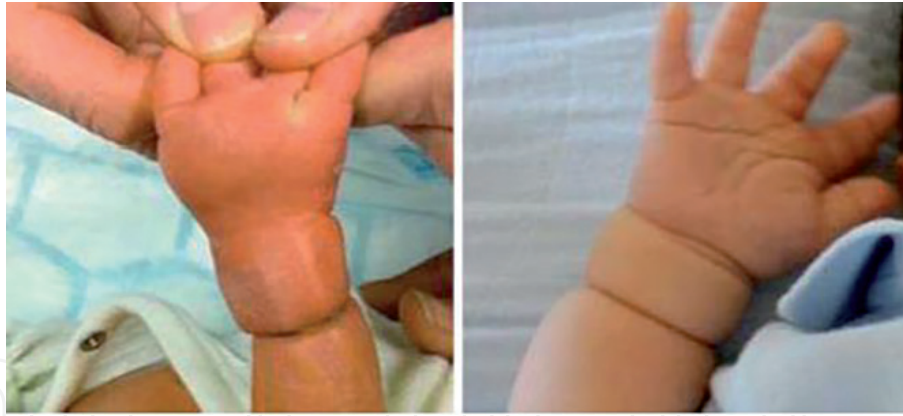

Figure 4.
Some amniotic bands may constrict fetal limbs, and may be serious to cause limb amputation.

procedures should be used as early as possible, preferably before early signs of heart failure, to prevent IUFD. Certainly the best option is complete tumor resection, if possible. A systematic review on 34 cases of SCT from 1980 to 2013, using minimally invasive fetal procedures, they reported 44% (14/32) overall survival with 29.7 ± 4.0 weeks, as mean gestational delivery age. They considered heart failure as a bad prognostic indicator, (30% survival rate (6/20)). Another review compares two minimally invasive procedures, direct tumor control, and vascular occlusion of the tumor feeding vessels. Study included 33 cases, 11 cases submitted to vascular occlusion (group A) and 22 submitted to direct tumor control (group B). They reported 63.6% (7/11) survival in vascular ablation (group A) compared to 40.9% (9/22) in direct tumor control (group B). They claimed that reduction of the tumor blood supply slowly appears safer than rapid tumor necrosis which may lead to hemorrhage inside the tumor. Regarding outcomes of fetuses with large SCTs and fetal hydrops before viability, due to rarity of the tumor the available small case series suggest that fetal intervention does confer a survival advantage. However, randomized trials are needed to make a valuable conclusion, also long-term outcomes data are needed. Because these procedures are associated with significant risks, so to get the best benefit these patients must be performed only in specialized centers, and must be limited to cases presented with both high-output heart failure and fetal hydrops [78].

6.7 Cystic pulmonary airway malformations (CPAM)

Most prenatally detected lung lesions are cystic pulmonary airway malformations (CPAM), broncho-pulmonary sequestrations or so called 'hybrid' lesions, containing features of both. The outcome of most lesions are favorable even without pre-natal intervention, despite often impressive appearance at mid-gestation. During pregnancy many lesions may regress, or disappear completely. Therefore, non-operative treatment (watchful waiting) is preferred by most fetal surgeons. Surprisingly, pressure effect or hemo-dynamic changes may cause sudden physiologic derangements, which may end with progressive heart failure and intra-uterine demise. Therefore, pre-natal intervention may be warranted to improve outcome. Pre-natal interventions for fetal lung lesions aim to alleviate the pressure effect of the mass by partial or complete removal of the lesion. Many surgical and non-surgical options have been reported.

- In macrocystic lesions, needle thoraco-centesis or thoraco-amniotic shunt drainage under ultrasound guided may be used for decompression.

- In microcystic lesions, cysts are too small for drainage. In these cases, open fetal surgery has been performed.
- When a systemic feeding vessel is found, percutaneous laser coagulation or injection of a sclerosing agent can be successful.

Routine ultrasound used as screening method for detection of congenital lung lesions and require referral to a specialist center. Other co-existing problems of the fetus should be carefully evaluated to determine, the magnitude of related complications, delivery place, time and type, and if intra-uterine intervention is needed. Minimally invasive intra-uterine fetal intervention for severe lesions can greatly improve the prognosis of these fetuses. In a large study of thoraco-amniotic shunt placement for congenital lung mass or pleural effusion, performed on 75 fetuses at Children's Hospital of Philadelphia, they showed 55% decrease in congenital cystic adenomatoid malformation volume and 27% of cases showed complete drainage of pleural effusion (73% showed partial drainage of effusions) with hydrops resolution in 83% of fetuses (43/53), which was greatly correlated with survival. Survival to delivery was 93% (70/75), median gestational age was 36 weeks, with 68% (51/75) long-term survival rate. Fifty-six percent of fetuses were delivered at an average of 10 weeks after shunt placement. Duration of stay in the neonatal intensive care unit of 21 days, with for greater than 24 hours. This series affirms the survival benefit risk patients, but underscores the risks inherent to in utero intensive neonatal therapy required [79, 80].

7. Future of fetal surgery

Minimally invasive treatment is undoubtedly the future of fetal surgery, with the goal of providing the best possible outcome for the fetus, while minimizing the morbidity or mortality to the mother. So the concept of treating two patients at the same time is the challenging goal. To this end, significant efforts are being made toward safest methods for fetal intervention, particularly premature rupture of membranes. Currently a collaboration between University of California San Francisco, the University of California Berkeley, and Caltech is focusing on the development of a biocompatible adhesive (methyldihydroxyphenylalanine-based polymers) to preseal amniotic membranes before fetal surgery to prevent PPROM. This formula is currently under development and called "Amnioseal" which can be delivered just below the uterus to preseal the fetal membrane before amniotic access. At the moment, prenatal stem cell transplantation and gene therapy is under extensive research to treat a wide range of genetic conditions, and to extend the current application of fetal surgical intervention for only correction of structural fetal anomalies. The in utero stem cell transplantation will prevent the process of abnormal immune development before the fetus cellular differentiations. Two types of fetal stem cell therapy are currently under investigations for potential clinical use the in utero hematopoietic stem cell transplantation and mesenchymal stem cell transplantation. Many recent clinical trials of in utero hematopoietic stem cell transplantation reported that it has had a limited success in recipients without underlying immunodeficiency, however, some experimental data in a large animal model of intrauterine hematopoietic stem cell transplantation have demonstrated clinically relevant levels of chimerism, may be supporting its role for inherited hematologic disorders. On the other hand, the use of in utero human fetal mesenchymal stem cell transplantation has been reported for osteogenesis imperfect, although the preliminary results are promising, it temporally

results. Finally, the studies of fetal gene therapy and gene-editing technology as a new treatment lines for fetal genetic disorders, are significantly advancing in the field of fetal therapy. However, the safety and long-term effect of these new types of treatment must be thoroughly evaluated in animal models before its applications in clinical practice.

IntechOpen

IntechOpen

Author details

Ahmed Abdelghaffar Helal
Pediatric Surgery Department, Faculty of Medicine, Al-Azhar University, Cairo,
Egypt

*Address all correspondence to: helalhmada@azhar.edu.eg

IntechOpen

© 2019 The Author(s). Licensee IntechOpen. This chapter is distributed under the terms of the Creative Commons Attribution License (<http://creativecommons.org/licenses/by/3.0>), which permits unrestricted use, distribution, and reproduction in any medium, provided the original work is properly cited. 

References

- [1] Adzick NS. Fetal surgery for spina bifida: Past, present, future. *Seminars in Pediatric Surgery*. 2013;**22**:10-17
- [2] Adzick NS, Thom EA, Spong CY, et al. A randomized trial of prenatal versus postnatal repair of myelomeningocele. *The New England Journal of Medicine*. 2011;**364**:993e1004
- [3] American College of Obstetricians and Gynecologists. Committee on ethics; American Academy of Pediatrics, committee on bioethics. Committee opinion no. 501: Maternalefetal intervention and fetal care centers. *Obstetrics and Gynecology*. 2011;**118**(Pt 1):405e10
- [4] Bamforth JS. Amniotic band sequence: Streeter's hypothesis reexamined. *American Journal of Medical Genetics*. 1992;**44**:280-287
- [5] Biffl WL, Spain DA, Rietsma AM, et al. Responsible development and application of surgical innovations: A position statement of the Society of University Surgeons. *Journal of the American College of Surgeons*. 2008;**206**:1204e9
- [6] Chan JK, Gotherstrom C. Prenatal transplantation of mesenchymal stem cells to treat osteogenesis imperfecta. *Frontiers in Pharmacology*. 2014;**5**:223
- [7] Chervenak FA, McCullough LB. An ethically justified framework for clinical investigation to benefit pregnant and fetal patients. *The American Journal of Bioethics*. 2011;**11**:39e49
- [8] Chervenak FA, McCullough LB. *The Professional Responsibility Model of Perinatal Ethics*. Berlin: Walter de Gruyter; 2014
- [9] Cignini P, Giorlandino C, Padula F, et al. Epidemiology and risk factors of amniotic band syndrome, or ADAM sequence. *Journal of Prenatal Medicine*. 2012;**6**:59-63
- [10] Deprest JA, Flake AW, Gratacos E, et al. The making of fetal surgery. *Prenatal Diagnosis*. 2010;**30**:653-667
- [11] Ehrenberg-Buchner S, Stapf AM, Berman DR, et al. Fetal lung lesions: Can we start to breathe easier? *American Journal of Obstetrics and Gynecology*. 2013;**208**:151.e1-151.e7
- [12] Graves EC, Harrison RM, Padilla EB. Minimally invasive fetal surgery. *Clinics in Perinatology*. 2017;**44**(4):729-751
- [13] Harrison MR, Adzick NS, Bullard KM, et al. Correction of congenital diaphragmatic hernia in utero VII: A prospective trial. *Journal of Pediatric Surgery*. 1997;**32**:1637-1642
- [14] Harrison MR, Adzick NS, Flake AW, et al. Correction of congenital diaphragmatic hernia in utero: VI. Hard-earned lessons. *Journal of Pediatric Surgery*. 1993;**28**:1411-1417
- [15] Jani J, Cannie M, Done E, et al. Relationship between lung area at ultrasound examination and lung volume assessment with magnetic resonance imaging in isolated congenital diaphragmatic hernia. *Ultrasound in Obstetrics & Gynecology*. 2007b;**30**:855-860
- [16] Jani J, Nicolaidis KH, Gratacos E, et al. Fetal lung-to-head ratio in the prediction of survival in severe left-sided diaphragmatic hernia treated by fetal endoscopic tracheal occlusion (FETO). *American Journal of Obstetrics and Gynecology*. 2006b;**195**:1646-1650
- [17] Jani J, Nicolaidis KH, Keller RL, et al. Observed to expected lung

area to head circumference ratio in the prediction of survival in fetuses with isolated diaphragmatic hernia. *Ultrasound in Obstetrics & Gynecology*. 2007a;**30**:67-71

[18] Jani JC, Nicolaidis KH, Gratacos E, et al. Severe diaphragmatic hernia treated by fetal endoscopic tracheal occlusion. *Ultrasound in Obstetrics & Gynecology*. 2009;**34**:304-310

[19] Javid P, Jaksic T, Skarsgard E, Lee S. Survival rate in congenital diaphragmatic hernia: The experience of the Canadian neonatal network. *Journal of Pediatric Surgery*. 2004;**39**:657-660

[20] Johnson MP, Corsi P, Badfield W, et al. Sequential urinalysis improves evaluation of fetal renal function in obstructive uropathy. *American Journal of Obstetrics and Gynecology*. 1995;**173**:59-65

[21] Johnson MP, on behalf of NAFTANet. The north American fetal therapy network (NAFTNet): A new approach to collaborative research in fetal diagnosis and therapy. *Seminars in Fetal & Neonatal Medicine*. 2009;**15**:52-57

[22] Keller BA, Hirose S, Farmer DL. Fetal therapy. In: Milunsky A, editor. *Genetic Disorders and the Fetus: Diagnosis, Prevention, and Treatment*. 7th ed. Hoboken (NJ): John Wiley & Sons, Inc.; 2016. pp. 989-1011

[23] Kunisaki S, Barnewolt C, Estroff J, et al. Ex utero intrapartum treatment with extracorporeal membrane oxygenation for severe congenital diaphragmatic hernia. *Journal of Pediatric Surgery*. 2007;**42**:98-106

[24] Kunisaki SM, Fuchs JR, Kaviani A, et al. Diaphragmatic repair through fetal tissue engineering: A comparison between mesenchymal amniocyte- and myoblast-based constructs. *Journal of Pediatric Surgery*. 2006;**41**:34-39

[25] Lam YH, Tang MHY, Shek TWH. Thermocoagulation of fetal sacrococcygeal teratoma. *Prenatal Diagnosis*. 2002;**22**:99-101

[26] Lee H, Wagner AJ, Sy E, et al. Efficacy of radiofrequency ablation for twin-reversed arterial perfusion sequence. *American Journal of Obstetrics and Gynecology*. 2007;**196**:459.e1-459.e4

[27] Lenclen R, Ciarlo G, Paupe A, et al. Neurodevelopmental outcome at 2 years in children born preterm treated by amnioreduction or fetoscopic laser surgery for twin-to-twin transfusion syndrome: Comparison with dichorionic twins. *American Journal of Obstetrics and Gynecology*. 2009;**201**:291.e1-291.e5

[28] Lewi L, Jani J, Blickstein I, et al. The outcome of monochorionic diamniotic twin gestations in the era of invasive fetal therapy: A prospective cohort study. *American Journal of Obstetrics and Gynecology*. 2008;**199**:514.e1-514.e8

[29] Lewi L, Jani J, Cannie M, et al. Intertwin anastomoses in monochorionic placentas after fetoscopic laser coagulation for severe twin-to-twin transfusion syndrome: Is there more than meets the eye? *American Journal of Obstetrics and Gynecology*. 2006;**194**:790-795

[30] Liechty K. Ex utero intrapartum therapy. *Seminars in Fetal & Neonatal Medicine*. 2010;**15**:34-39

[31] Taghavi K, Beasley S. The ex utero intrapartum treatment (EXIT) procedure: Application of a new therapeutic paradigm. *Journal of Paediatrics and Child Health*. 2013;**49**:E420-7

[32] Liggins GC, Howie RN. A controlled trial of antepartum glucocorticoid treatment for prevention of the respiratory distress syndrome in

- premature infants. *Pediatrics*. 1972;**50**:515-525
- [33] Liley AW. Intrauterine transfusion of fetus in haemolytic disease. *British Medical Journal*. 1963;**2**:1107-1109
- [34] Louw JH, Barnard CN. Congenital intestinal atresia; observations on its origin. *Lancet*. 1955;**269**:1065-1067
- [35] Luks FI, Deprest JA, Vandenberghe K, et al. Fetoscopy-guided fetal endoscopy in a sheep model. *Journal of the American College of Surgeons*. 1994;**178**(6):609-612
- [36] Luks FI, Deprest JA. Endoscopic fetal surgery: A new alternative? *European Journal of Obstetrics, Gynecology, and Reproductive Biology*. 1993;**52**:1-3
- [37] Luks FI, Gilchrist BF, Jackson BT, Piasecki GJ. Endoscopic tracheal obstruction with an expanding device in a fetal lamb model: Preliminary considerations. *Fetal Diagnosis and Therapy*. 1996b;**11**:67-71
- [38] Luks FI, Peers KH, Deprest JA, et al. The effect of open and endoscopic fetal surgery on uteroplacental oxygen delivery in the sheep. *Journal of Pediatric Surgery*. 1996a;**31**:310-314
- [39] Luks FI, Wild YK, Piasecki GJ, De Paepe ME. Short-term tracheal occlusion corrects pulmonary vascular anomalies in the fetal lamb with diaphragmatic hernia. *Surgery*. 2000;**128**:266-272
- [40] MacKenzie TC, David AL, Flake AW, et al. Consensus statement from the first international conference for in utero stem cell transplantation and gene therapy. *Frontiers in Pharmacology*. 2015;**6**:15
- [41] MacKenzie TC. Fetal surgical conditions and the unraveling of maternal-fetal tolerance. *Journal of Pediatric Surgery*. 2016;**51**:197-199
- [42] Makin EC, Hyett J, Ade-Ajayi N, et al. Outcome of antenatally diagnosed sacrococcygeal teratomas: Single-center experience (1993-2004). *Journal of Pediatric Surgery*. 2006;**41**:388-393
- [43] Mallik AS, Fichter MA, Rieder S, et al. Fetoscopic closure of punctured fetal membranes with a cellular human amnion plugs in a rabbit model. *Obstetrics and Gynecology*. 2007;**110**:1121-1129
- [44] Mann S, Johnson MP, Wilson RD. Fetal thoracic and bladder shunts. *Seminars in Fetal & Neonatal Medicine*. 2010;**15**:28-33
- [45] Manning FA, Harrison MR, Rodeck C. Catheter shunts for fetal hydronephrosis and hydrocephalus. Report of the international Fetal surgery registry. *The New England Journal of Medicine*. 1986;**315**:336-340
- [46] McClain LE, Flake AW. In utero stem cell transplantation and gene therapy: Recent progress and the potential for clinical application. *Best Practice & Research. Clinical Obstetrics & Gynaecology*. 2016;**31**:88-98
- [47] McCurdy CM, Childers JM, Seeds JW. Ligation of the umbilical cord of an acardiac-acephalus twin with an endoscopic intrauterine technique. *Obstetrics and Gynecology*. 1993;**82**:708-711
- [48] McHugh K, Afaq A, Broderick N, et al. Tracheomegaly: A complication of fetal endoscopic tracheal occlusion in the treatment of congenital diaphragmatic hernia. *Pediatric Radiology*. 2010;**40**:674-680
- [49] Mettauer NL, Pierce CM, Cassidy JV, et al. One year survival in congenital diaphragmatic hernia, 1995-2006. *Archives of Disease in Childhood*. 2009;**94**:407
- [50] Meuli M, Meuli-Simmen C, Yingling CD, et al. In utero repair of

experimental myelomeningocele saves neurological function at birth. *Journal of Pediatric Surgery*. 1996;**31**:397-402

[51] Moise K. The history of fetal therapy. *American Journal of Perinatology*. 2014;**31**:557e66

[52] Senat MV, Deprest J, Boulvain M, et al. A randomized trial of endoscopic laser surgery versus serial amnioreduction for severe twin-to-twin transfusion syndrome at midgestation. *The New England Journal of Medicine*. 2004;**351**:136-144

[53] Peranteau WH, Adzick NS, Boelig MM, et al. Thoracoamniotic shunts for the management of fetal lung lesions and pleural effusions: A single-institution review and predictors of survival in 75 cases. *Journal of Pediatric Surgery*. 2015;**50**:301-305

[54] Peranteau WH, Boelig MM, Khalek N, et al. Effect of single and multiple courses of maternal betamethasone on prenatal congenital lung lesion growth and fetal survival. *Journal of Pediatric Surgery*. 2016;**51**:28-32

[55] Roelofs LA, Eggink AJ, Hulsbergen-van de Kaa CA, et al. Fetal abdominal wall repair with a collagen biomatrix in an experimental sheep model for gastroschisis. *Tissue Engineering. Part A*. 2008a;**14**:2033-2040

[56] Roelofs LA, Eggink AJ, Hulsbergen-van de Kaa CA, et al. Fetal bladder wall regeneration with a collagen biomatrix and histological evaluation of bladder exstrophy in a fetal sheep model. *Fetal Diagnosis and Therapy*. 2008b;**24**:7-14

[57] Rosenkrantz JG, Simon RC, Carlisle JH. Fetal surgery in the pig with a review of other mammalian fetal techniques. *Journal of Pediatric Surgery*. 1968;**3**:392-397

[58] Roybal JL, Santore MT, Flake AW. Stem cell and genetic therapies for

the fetus. *Seminars in Fetal & Neonatal Medicine*. 2010;**15**:46-51

[59] Ruano R, Aubry MC, Barthe B, et al. Quantitative analysis of pulmonary vasculature by 3D-power Doppler ultrasonography in isolated congenital diaphragmatic hernia. *American Journal of Obstetrics and Gynecology*. 2006;**195**:1720-1728

[60] Ruano R, Duarte S, Bunduki V, et al. Fetal cystoscopy for severe lower urinary tract obstruction—Initial experience of a single Centre. *Prenatal Diagnosis*. 2010;**30**:30-39

[61] Ruano R, Sananes N, Sangi-Haghpeykar H, et al. Fetal intervention for severe lower urinary tract obstruction: A multicenter case-control study comparing fetal cystoscopy with vesicoamniotic shunting. *Ultrasound in Obstetrics & Gynecology*. 2015;**45**:452-458

[62] Rychik J, Tian Z, Bebbington M, et al. The twin-twin transfusion syndrome: Spectrum of cardiovascular abnormality and development of a cardiovascular score to assess severity of disease. *American Journal of Obstetrics and Gynecology*. 2007;**197**:392.e1-392.e8

[63] Sala P, Prefumo F, Pastorino D, Buffi D, Gaggero CR, Foppiano M, et al. Fetal surgery: An overview. *Obstetrical & Gynecological Survey*. 2014;**69**:218e28

[64] Sartoris J, Varnholt V, Dahlheim D, Schaible T. CDH in Mannheim—Algorithm and results. *Monatschr Kinderheilkd*. 2006;**153**:717

[65] Sokol J, Shimizu Bohn D, et al. Fetal pulmonary artery diameter measurements as a predictor of morbidity in antenatally diagnosed congenital diaphragmatic hernia: A prospective study. *American Journal of Obstetrics and Gynecology*. 2006;**195**:470-477

- [66] Sroka M, Swiatokowska-Freund M, Golebiewski A, et al. Fetal surgery: Future or way leading to nowhere. First experiences. *Przegląd Pediatryczny*. 2007;**37**:7-9
- [67] Stege G, Fenton A, Jaffray B. Nihilism in the 1990s. The true mortality of CDH. *Pediatrics*. 2003;**112**:532-535
- [68] Stirnemann JJ, Nasr B, Quarello E, et al. A definition of selectivity in laser coagulation of chorionic plate anastomoses in twin-to-twin transfusion syndrome and its relationship to perinatal outcome. *American Journal of Obstetrics and Gynecology*. 2008;**198**:62.e1-62.e6
- [69] Sviggum HP, Kodali BS. Maternal anesthesia for fetal surgery. *Clinics in Perinatology*. 2013;**40**:413-427
- [70] Tsao K, Hawgood S, Vu L, et al. Resolution of hydrops fetalis in congenital cystic adenomatoid malformation after prenatal steroid therapy. *Journal of Pediatric Surgery*. 2003;**38**:508-510
- [71] van der Wildt B, Luks FI, Steegers EA, et al. Absence of electrical uterine activity after endoscopic access for fetal surgery in the rhesus monkey. *European Journal of Obstetrics, Gynecology, and Reproductive Biology*. 1995;**58**:213-214
- [72] Van Mieghem T, Klaritsch P, Doñe E, et al. Assessment of fetal cardiac function before and after therapy for twin-to-twin transfusion syndrome. *American Journal of Obstetrics and Gynecology*. 2009;**200**:400.e1-400.e7
- [73] Van Peborgh P, Rambaud C, Ville Y. Effect of laser coagulation on placental vessels: Histological aspects. *Fetal Diagnosis and Therapy*. 1997;**12**:32-35
- [74] Ville Y, Hyett J, Hecher K, Nicolaides K. Preliminary experience with endoscopic laser surgery for severe twin-twin transfusion syndrome. *The New England Journal of Medicine*. 1995;**332**:224-227
- [75] Ville Y, Hyett JA, Vandenbussche F, Nicolaides KH. Endoscopic laser coagulation of umbilical cord vessels in twin reversed arterial perfusion sequence. *Ultrasound in Obstetrics & Gynecology*. 1994;**4**:396-398
- [76] Ville Y. Twin-to-twin transfusion syndrome: Time to forget the Quintero staging system? *Ultrasound in Obstetrics & Gynecology*. 2007;**30**:924-927
- [77] Welsh A, Agarwal S, Kumar S, et al. Fetal cystoscopy in the management of fetal obstructive uropathy: Experience in a single European Centre. *Prenatal Diagnosis*. 2003;**23**:1033-1041
- [78] Westerburg B, Feldstein V, Sandberg P, et al. Sonographic prognostic factors in fetuses with sacrococcygeal teratoma. *Journal of Pediatric Surgery*. 2000;**35**:322-326
- [79] Clewell WH, Johnson ML, Meier PR, Newkirk JB, Zide SL, Hendee RW, et al. *The New England Journal of Medicine*. 1982;**306**:1320-1325
- [80] Kohl T, Herin R, Heep A, et al. Percutaneous fetoscopic patch coverage of spina bifida aperta in the human—Early clinical experience and potential. *Fetal Diagnosis and Therapy*. 2006;**21**:185-193