

# We are IntechOpen, the world's leading publisher of Open Access books Built by scientists, for scientists

**4,800**

Open access books available

**122,000**

International authors and editors

**135M**

Downloads

Our authors are among the

**154**

Countries delivered to

**TOP 1%**

most cited scientists

**12.2%**

Contributors from top 500 universities



**WEB OF SCIENCE™**

Selection of our books indexed in the Book Citation Index  
in Web of Science™ Core Collection (BKCI)

Interested in publishing with us?  
Contact [book.department@intechopen.com](mailto:book.department@intechopen.com)

Numbers displayed above are based on latest data collected.

For more information visit [www.intechopen.com](http://www.intechopen.com)



# Extracorporeal Carbon Dioxide Removal for the Exacerbation of Chronic Hypercapnic Respiratory Diseases

*Luis Morales-Quinteros and Antonio Artigas*

## Abstract

In the past, treatment of acute exacerbations of obstructive disease refractory to medical treatment was invasive mechanical ventilation. As a result of technical improvements, extracorporeal techniques for carbon dioxide removal have aroused as an attractive option to avoid worsening respiratory failure and respiratory acidosis and potentially prevent, shorten the duration of invasive mechanical ventilation (IMV), and serve as rescue therapy in patients with exacerbation of COPD and asthma. In this review, we will present a comprehensive summary of the pathophysiological rationale and evidence of ECCO<sub>2</sub>R in patients with severe exacerbations of these pathologies.

**Keywords:** COPD, asthma, ECCO<sub>2</sub>R, invasive mechanical ventilation, noninvasive mechanical ventilation

## 1. Introduction

Patients with obstructive lung diseases, such as asthma and chronic obstructive pulmonary disease (COPD), may experience acute exacerbations with severe hypercapnic respiratory failure. Hypercapnia results from acute worsening of expiratory flow limitation caused by the increased small airway resistance with consequent development of dynamic alveolar hyperinflation and intrinsic PEEP. In the most severe cases, these may be refractory to conventional therapies and mechanical ventilation, becoming life-threatening.

Extracorporeal carbon dioxide removal (ECCO<sub>2</sub>R) represents an attractive approach in this setting.

The last decade has seen an increasing interest in the provision of extracorporeal support for respiratory failure, as demonstrated by the progressively increasing number of scientific publications on this topic. In particular, remarkable interest has been focused on ECCO<sub>2</sub>R, due to the relative ease and efficiency in blood CO<sub>2</sub> clearance granted by extracorporeal gas exchangers as compared to oxygen delivery (**Table 1**).

In recent years, new-generation ECCO<sub>2</sub>R devices have been developed. More efficient veno-venous (VV-ECCO<sub>2</sub>R) devices have become available and have replaced the arteriovenous approach, having the advantage of not requiring arterial puncture.

They offer lower resistance to blood flow, have small priming volumes, and have a much more efficient gas exchange [1] with relatively low extracorporeal blood flows

|                         | ECMO   | ECCO <sub>2</sub> R                                 |
|-------------------------|--|---|
| Cannulas                | Large cannulas                                 | Double lumen catheter                               |
| Blood flow              | High extracorporeal flow<br>(2000→5000 ml/min) | Low flow, respiratory dialysis<br>(250–1000 ml/min) |
| Membrane oxygenator     | Large membrane oxygenator                      | Medium size oxygenator                              |
| Oxygenation             | Full blood oxygenation                         | No blood oxygenation                                |
| CO <sub>2</sub> removal | Full blood decarboxylation                     | Partial blood decarboxylation                       |
| Heparin requirements    | High   | Higher than ECMO                                    |
| Setting                 | High technicity, ECMO center                   | Regular ICU   |

**Table 1.**  
*ECMO and ECCO<sub>2</sub>R differences.*

(0.4–1 L/min). With ECCO<sub>2</sub>R the patient’s PaCO<sub>2</sub> is principally determined by the rate of fresh gas flow through the membrane lung [2]. These devices are now comparable to renal dialysis equipment, which is routinely used safely as standard care in ICU.

This approach has been the subject of many animal experiments and human case series demonstrating improved arterial CO<sub>2</sub> and work of breathing [3–6].

## 2. Pathophysiological rationale for ECCO<sub>2</sub>R

Both in asthma and COPD exacerbations, diffuse narrowing of the airways results in profound physiologic consequences. Airway narrowing prevents the lungs from completely emptying (“air trapping”) due to resistance to expiratory flow and bronchial closure at higher than average lung volumes. Air trapping results in dynamic hyperinflation (DHI) [7] which is the excessive increase in end-expiratory lung volume above the relaxation volume of the respiratory system, generating intrinsic positive end-expiratory pressure (auto-PEEP) [8]. As a result, the patient breathes at higher total lung volumes, depending on increased residual volume [9] which reduces tidal ventilation. The net effect is that the work of breathing increases significantly. The diaphragm, intercostal muscles, and even the abdominal muscles are overloaded causing respiratory muscle fatigue and dyspnea.

Pharmacotherapy with bronchodilators and systemic corticosteroids are the cornerstones of medical therapy, designed to reduce this pathophysiological airflow obstruction and improve symptoms.

Patients suffering from a combination of persistent or worsening hypercapnia, respiratory muscle fatigue, and a decline in mental status require mechanical ventilation (MV) along with lung-protective ventilator strategies (e.g., low-tidal-volume ventilation, relatively short inspiratory time and longer expiratory times) [10, 11].

The goal of mechanical ventilation is to provide adequate gas exchange while waiting for airflow obstruction to respond to bronchodilator therapy. However, mechanical ventilation may aggravate alveolar hyperinflation by worsening DHI, which may lead to worsened hypercapnia, barotrauma, and alveolar rupture leading to pneumothorax and further hemodynamic deterioration [12].

Furthermore, during mechanical ventilation, these patients receive sedatives or neuromuscular blockade to facilitate ventilatory support [13]. Sedation and paralysis preclude mobilization, promoting muscular deconditioning and potentially contributing to the long-term cognitive sequelae of critical illness [14].

When conventional therapeutic options are not successful, novel therapies such as extracorporeal membrane oxygenation are entertained as a possible salvage therapeutic modality.

During exacerbation relieving the native lung from at least part of the CO<sub>2</sub> elimination with ECCO<sub>2</sub>R could potentially improve the acid–base balance, reduce patient’s work of breathing with a consequent reduction in respiratory rate and ventilatory drive, and lower alveolar ventilation. The application of ECCO<sub>2</sub>R may allow lower tidal volumes and respiratory rate, resulting in the extension of the expiratory time, suiting better the high expiratory time constant of the respiratory system with expiratory flow limitation. By these physiological mechanisms, ECCO<sub>2</sub>R can counteract the vicious circle of dynamic hyperinflation and its detrimental respiratory and cardiovascular consequences. The derived beneficial effects on respiratory mechanics, ventilatory muscle efficiency, work of breathing, and cardiovascular function may improve gas exchanges and relieve dyspnea, thus potentially preventing NIV failure or facilitate weaning from IMV, and, also by rapidly decreasing and weaning off sedation, reduce the rates of delirium, reduce feeding problems, and allow social contacts with friends and family, as well as allow sufficient physiotherapy to reduce myopathy and critical care illness [14].

### 3. ECCO<sub>2</sub>R technical aspects and principle

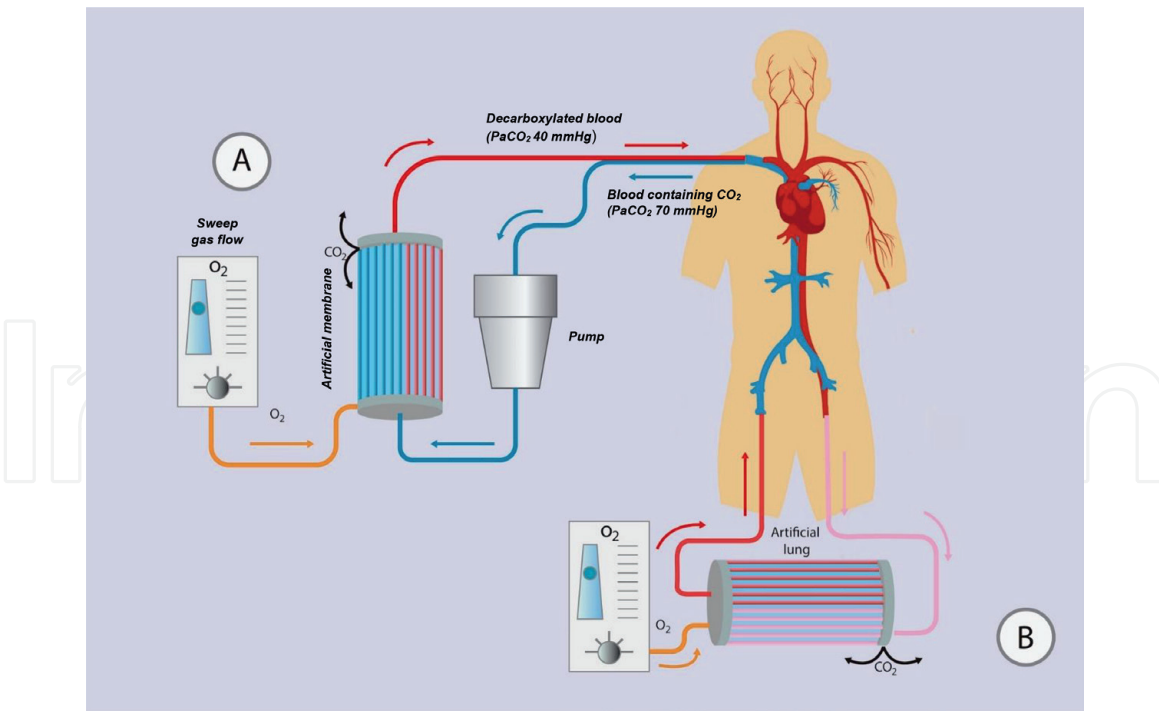
ECCO<sub>2</sub>R is designed to remove carbon dioxide (CO<sub>2</sub>) and, unlike extracorporeal membrane oxygen (ECMO), does not provide significant oxygenation.

The device consists of a drainage cannula placed in a large central vein or artery, a membrane lung, and a return cannula into the venous system (**Figure 1**). Blood is pumped through the membrane lung, and CO<sub>2</sub> is removed by diffusion. A flowing gas known as “sweep gas” containing little or no CO<sub>2</sub> runs along the other side of the membrane, ensuring a diffusion gradient from blood to another side, allowing CO<sub>2</sub> removal.

In contrast to ECMO, where the need for oxygenation requires high blood flow rates, ECCO<sub>2</sub>R allows much lower blood flow rates, a result of significant differences in CO<sub>2</sub> and oxygen (O<sub>2</sub>) kinetics. Almost all the O<sub>2</sub> in blood is carried by hemoglobin, which displays sigmoidal saturation kinetics. Assuming normal hemoglobin and venous O<sub>2</sub>, each liter of venous blood can only carry an extra 40–60 ml of O<sub>2</sub> before the hemoglobin is fully saturated. Blood flows of 5–7 L/min are therefore required to supply enough O<sub>2</sub> for an average adult. Conversely, most CO<sub>2</sub> is transported as dissolved bicarbonate, displaying linear kinetics without saturation. Considering that 1 L of blood is transported around 500 mL of CO<sub>2</sub>, a perfectly efficient system flow of 0.5 L/min would be enough to remove all of the CO<sub>2</sub> produced [1, 15, 16]. Also, CO<sub>2</sub> diffuses more readily than O<sub>2</sub> across extracorporeal membranes because of higher solubility. However, in practice, ECCO<sub>2</sub>R is usually able to remove up to 25% of carbon dioxide production given the limitations of blood flow, blood CO<sub>2</sub> content, hemoglobin, and membrane efficiency [17].

#### 3.1 VV-ECCO<sub>2</sub>R

In the veno-venous configuration, blood is drawn from a central vein by a draining cannula, using a centrifugal or roller pump to generate flow across the membrane. CO<sub>2</sub> diffuses into the “sweep gas” and is returned into the venous circulation (**Figure 1A**). Single site cannulation is possible using a double lumen cannula. This approach allows low flow through the use of smaller cannulas (15–19F), commonly introduced via the right internal jugular vein. The setup is very similar to renal



**Figure 1.** ECCO<sub>2</sub>R common configurations. (A) Minimally invasive veno-venous ECCO<sub>2</sub>R system with a single venous vascular access through a double lumen cannula that can be inserted in the internal jugular or femoral vein (B) Pumpless arteriovenous ECCO<sub>2</sub>R system with the placement of the membrane in the circuit connecting the femoral artery with the contralateral vein.

replacement therapy, and in fact, some systems are trying to combine the two in one [18, 19] (NCT02590575). One of the advantages of VV-ECCO<sub>2</sub>R compared to the AV approach is the less invasiveness by the omission of the arterial cannulation and facilitates early mobilization of patients. It is also possible to set up an ECCO<sub>2</sub>R system through cannulation of two central veins, one for drainage and the other for reinfusion (femoral-femoral configuration).

### 3.2 AV-ECCO<sub>2</sub>R

One ECCO<sub>2</sub>R configuration is through percutaneous cannulation of the femoral artery to the contralateral femoral vein and creating an arteriovenous (AV) bypass, equipped with an artificial gas exchanger membrane across the AV shunt which acts as a “sweep gas” to remove CO<sub>2</sub> that has diffused out of the patient’s blood (Figure 1B). In this configuration, pumpless systems require an arteriovenous pressure gradient  $\geq 60$  mmHg and a cardiac index  $> 3$  L/min/m<sup>2</sup>, which is unsuitable for hemodynamically unstable patients [16, 20]. Further, cannulation of a major artery can result in distal ischemia [21], although measuring the artery diameter with ultrasound and selecting a cannula that occupies no more than 70% of the lumen reduce this risk [22].

## 4. Indications and evidence

### 4.1 Chronic obstructive pulmonary disease

Chronic obstructive pulmonary disease (COPD) is a significant worldwide health burden. Currently, it is the fourth leading cause of death worldwide, is the only leading cause of death that is rising, and will likely become the third cause of

death by 2020 [23, 24]. COPD is characterized by progressive destruction in the elastic tissue within the lung, causing respiratory failure.

Acute exacerbations of COPD (aeCOPD) constitute a significant cause of morbidity and mortality among these patients. Patients with moderate to severe acute exacerbations develop alveolar hyperinflation that may lead to increased work of breathing, muscle fatigue, and hypercapnia, creating a vicious loop refractory to medical treatment [25–27]. The standard respiratory support in this setting in order to break this cycle is noninvasive ventilation (NIV). However, despite the significantly decreased mortality with the emergence of NIV, up to 30% of patients with aeCOPD will “fail” and require intubation and invasive mechanical ventilation (IMV) [28–30]. For patients requiring respiratory support with IMV, in-hospital mortality in recent meta-analysis and observational studies has been reported to be as high as 25–39% [31–34].

Patients with COPD requiring IMV develop a considerable reduction in respiratory muscle strength, having a higher risk of prolonged weaning and failure to wean compared to other causes of acute hypercapnic respiratory failure. Up to 60% of the ventilatory time is devoted to these patients to the process of weaning [35], and they are very likely to require a tracheotomy. Having a prolonged time spent under IMV is not surprising an increase in the incidence of ventilator-associated pneumonia and complications associated with the use of invasive mechanical ventilation such ventilator-induced lung injury (VILI), ventilator-associated pneumonia (VAP), ventilator-associated diaphragmatic dysfunction (VIDD), and a range of neurological disorders associated with prolonged sedation and immobilization.

#### *4.1.1 Evidence and clinical trials of ECCO<sub>2</sub>R in aeCOPD to date*

One of the first reports on the application of ECCO<sub>2</sub>R to support respiratory function of a COPD patient was published in 1990 by Pesenti et al. [36]. However, the technique was abandoned due to technical complications.

As the medical community regained interest in ECCO<sub>2</sub>R, investigators began applying the technique to prevent intubation or to assist weaning from the ventilator in patients with hypercapnic aeCOPD. Several studies in both VV and AV configurations were published, including a meta-analysis (**Table 2**).

#### *4.1.2 ECCO<sub>2</sub>R to avoid IMV*

Brederlau et al. [37] described their experience in three patients that failed NIV for severe aeCOPD. They applied a pumpless AV ECCO<sub>2</sub>R device with the goal of avoiding endotracheal intubation. Shortly after beginning ECCO<sub>2</sub>R, PaCO<sub>2</sub> fell significantly (from 91, 109, and 142 mmHg to 52, 59, and 83 mmHg, respectively), while pH rose (from 7.2, 7.19, and 7.06 to 7.41, 7.43, and 7.34, respectively). Simultaneously, the respiratory rate dropped from 38, 45, and 37 breaths/min to 15, 25, and 18 breaths/min, respectively. The ECCO<sub>2</sub>R flow ranged between 1.1 and 1.6 L/min, with the sweep gas flow varying from 3 to 10 L/min.

Kluge et al. [5] in the same year evaluated the safety and efficacy of using AV pumpless extracorporeal lung assist (PECLA) in 21 COPD patients who did not respond to NIV compared to 21 matched controls. The use of PECLA was associated with a decrease in PaCO<sub>2</sub> levels and improved pH after 24 h and obviated the need for intubation and IMV in 90% of the experimental arm. Although the experimental group demonstrated a shorter length of stay, a retrospective analysis with the control group showed no significant difference in mortality at 28 days (19% with ECCO<sub>2</sub>R vs. 24% without ECCO<sub>2</sub>R) or 6 months (both groups 33%).

| Study  | No of patients | ECCO <sub>2</sub> R characteristics   |                     |                    | Time on ECCO <sub>2</sub> R       | Major results |   |
|--|----------------|---|---------------------|--------------------|-----------------------------------|---------------|---|
|  |                | Configuration   | Blood flow (mL/min) | Sweep flow (L/min) |                                   |               | Membrane (material); surface in m <sup>2</sup>  |
| <b>ECCO<sub>2</sub>R to avoid mechanical ventilation</b> |                |   |                     |                    |                                   |               |   |
| Kluge et al. [5]   | 21             | Femoral AV with 13- to 15-Fr arterial cannula and 13- to 17-Fr venous cannula                                 | 1100                | Not reported       | PMP*; 1.3 (iLA®)                  | 9 days        | <p>19 (90%) PECLA patients did not require intubation</p> <p>Two major and seven minor bleeding complications during PECLA</p> <p>No significant difference in 28-day (24 vs. 19%, <math>p = 0.85</math>), 6-month mortality (33 vs. 33%), or hospital length of stay (23 vs. 42 days, <math>p = 0.06</math>)</p> <p>Significantly fewer tracheostomies in PECLA group (10 vs. 67%, <math>p = 0.004</math>)</p> |
| Del Sorbo et al. [4]                                     | 25             | Modified continuous VV hemofiltration system with membrane lung via 14-Fr single dual-lumen cannula (femoral) | 255                 | 8                  | PLP**; 1.35 (Hemodec DecapSmart®) | 1–2 days      | <p>Significantly higher risk of intubation in NIV-only group (HR 0.27; 95% CI 0.07–0.98)</p> <p>13 patients experienced adverse events: 3 had bleeding, 1 had vein perforation, and 9 had device malfunction</p>  |
| Braune et al. [39]                                       | 25             | VV configuration via a 22 or 24-Fr single dual-lumen cannula (femoral or jugular)                             | 1300                | Not reported       | PMP; 1.3 (Novalung iLA Active)    | 8.5 days      | <p>Intubation was avoided in 14 out of all 25 ECCO<sub>2</sub>R patients (56%)</p> <p>Seven ECCO<sub>2</sub>R patients were intubated because of progressive hypoxemia and four due to ventilatory failure despite ECCO<sub>2</sub>R and NIV</p> <p>Nine ECCO<sub>2</sub>R patients (36%) suffered from major bleeding complications</p> <p>90-day mortality rates were 28 vs. 28%</p>                          |

| Study  | No of patients | ECCO <sub>2</sub> R characteristics  |                     |                    | Time on ECCO <sub>2</sub> R                                  | Major results   |
|--|----------------|--|---------------------|--------------------|--|---|
|  |                | Configuration  | Blood flow (mL/min) | Sweep flow (L/min) |  |   |
| <b>ECCO<sub>2</sub>R to wean from mechanical ventilation</b> |                |  |                     |                    |  |   |
| Abrams et al. [3]  | 5              | VV configuration via a 20- to 24-Fr single dual-lumen jugular catheter using lower flow on ECMO system | 1700                | 1–7                | PMP; 0.98 (Maquet PALP CardioHelp)                           | 8 days<br>Mean (SD) time to ambulation after ECCO <sub>2</sub> R initiation was 29.4 ± 12.6 h<br>Four patients were discharged home, and one underwent planned lung transplantation<br>Only two minor bleeding complications  |
| Cardenas et al. [42]   | 1              | VV configuration with pediatric dual-lumen jugular cannula   | 800                 | 10                 | PMP; 1.8 (Quadrox-d, Maquet)                                 | 3.6 days<br>Patient extubated 48 h after decannulation.<br>No complications reported  |
| Roncon et al. [43]   |                |  |                     |                    |  |   |
| <b>ECCO<sub>2</sub>R with mixed indications</b>              |                |  |                     |                    |  |   |
| Burki [38]   | 20             | VV configuration via a 15.5-Fr single dual-lumen catheter (femoral or jugular)                         | 430                 | Not reported       | PLP with a base of siloxane layer; 0.59 (ALung Hemolung RAS) | 2–192 h<br>20 hypercapnic COPD patients received ECCO <sub>2</sub> R in three distinct groups: group 1 ( <i>n</i> = 7) NIV patients with high risk of IMV; group 2 ( <i>n</i> = 2) could not be weaned from NIV; and group 3 ( <i>n</i> = 11) on IMV and failed to wean<br>IMV avoided in all patient in group 1<br>Both patients in group 2 weaned from NIV<br>In group 3, three patients weaned, and IMV was reduced in two patients<br>One patient died due to a retroperitoneal hemorrhage (during cannulation) |

\*PMP: poly-4-methyl-1-pentene.

\*\*PLP: polypropylene.

**Table 2.**  
 Relevant clinical studies of ECCO<sub>2</sub>R in COPD.



In the study by Burki et al. [38], 20 hypercapnic patients with COPD were treated with ECCO<sub>2</sub>R using a 15.5-Fr dual-lumen cannula allowing a mean blood flow of 430 mL/min. Of the 20 patients recruited into the trial, 7 were at risk of MV despite NIV, 2 were difficult to wean from NIV, and 11 had failed liberation from MV. None of the patients failing NIV required endotracheal intubation, and both patients with difficult weaning from NIV were weaned. However, only 3 of the 11 IMV patients were liberated successfully. Moreover, significant complications arose in a number of patients: bleeding requiring blood transfusion was reported in three patients, deep vein thrombosis was diagnosed in one patient after removal of the ECCO<sub>2</sub>R catheter, one patient experienced pneumothorax due to catheter insertion, and one died from hemorrhage when the iliac vein was perforated during ECCO<sub>2</sub>R catheter placement.

Del Sorbo et al. [4] examined 25 patients with NIV + ECCO<sub>2</sub>R versus NIV alone (historical controls n = 21) for prevention of intubation in aeCOPD. They reported that ECCO<sub>2</sub>R with a 14-Fr dual-lumen catheter and blood flow rates of 177–333 mL/min not only improved respiratory acidosis but also reduced the need for intubation by 75% (12 vs. 33%; p = 0.047) and significantly reduced the in-hospital mortality (8 vs. 35%; p = 0.035). However, this came with a cost of 52% prevalence of ECCO<sub>2</sub>R-related side effects and led the authors to suggest the end point of future studies should be long-term mortality.

In the ECLAIR study, Braune et al. [39] showed that IMV was avoided in 56% of cases treated with ECCO<sub>2</sub>R but was associated with a higher incidence of complications. However, several significant differences must be taken into account. In the latter study, there was an inclusion of patients with relative contraindications to NIV, and there was an unexpectedly high incidence of hypoxemic patients [40].

Finally, Morelli et al. [41] and colleagues confirmed the efficacy of ECCO<sub>2</sub>R (with a flow rate of 250–450 mL/min through a 13-Fr dual-lumen cannula) in reducing the PaCO<sub>2</sub> in a series of 30 patients with acute hypercapnic respiratory failure due to aeCOPD, who refused endotracheal intubation after failing NIV. The duration of ECCO<sub>2</sub>R was 2–16 days, and it was possible to prevent endotracheal intubation in 27 patients.

#### *4.1.3 ECCO<sub>2</sub>R to facilitate weaning from IMV*

Cardenas et al. [42] made the first attempt to use modern ECLS components for VV ECCO<sub>2</sub>R in a patient with aeCOPD. They demonstrated a successful reduction in PaCO<sub>2</sub>, minute ventilation, and ventilator pressures.

Burki et al. [38] showed that in a subgroup of 11 patients receiving IMV, ECCO<sub>2</sub>R allowed the weaning from mechanical ventilator in only 3 patients.

Abrams and colleagues [3] reported five older patients (age 73 ± 8.7 years) with aeCOPD who failed NIV, requiring IMV. After an average of 16.5 ± 5.9 h of IMV, ECCO<sub>2</sub>R was initiated. By using a dual-lumen cannula (20–23 Fr) with blood flow rates of 1–1.7 L/min and with a sweep gas flow from 1 to 7 L/min, they were able to extubate all five patients within 24 h of treatment (median duration of MV post ECCO<sub>2</sub>R = 4 h, range 1.5–21.5 h). Once extubated, patients were rehabilitated while on ECCO<sub>2</sub>R, with a mean time to ambulation of 29.4 ± 12.6 h after ECCO<sub>2</sub>R. Moreover, all patients survived to hospital discharge.

Using a pediatric VV ECMO system (with blood flow rates of 0.9 L/min through a 19 Fr dual-lumen cannula placed in the right jugular vein) in two patients with aeCOPD, Roncon-Albuquerque Jr. et al. reported early extubation after 72 h and patient mobilization out of bed at day 6 [43].

#### 4.1.4 Reviews of ECCO<sub>2</sub>R in COPD

Sklar et al. [44] reviewed 10 studies of ECCO<sub>2</sub>R for aeCOPD and a total of 87 patients, to examine cumulative safety and efficacy. They reported that ECCO<sub>2</sub>R was able to prevent intubation in 65 (93%) of 70 patients and assist in successful extubation of 9 (53%) of 17 patients. There were a total of 11 major complications and 30 minor complications. Half of all patients experienced complications related to ECCO<sub>2</sub>R, and half of those complications were related to bleeding (21/41). No study showed any evidence of increased mortality or increased length of intensive care unit (ICU) or hospital stay with ECCO<sub>2</sub>R.

In a recent publication, Taccone et al. [45] performed a systematic review of ECCO<sub>2</sub>R in adult critically ill patients. Three of the six studies included in the review evaluated patients with COPD that developed hypercapnic respiratory failure [4, 5, 39]. In all the three studies, the reduction of PaCO<sub>2</sub> was reported within a few hours following the initiation of ECCO<sub>2</sub>R. Median values decreased from 73 to 88 mmHg to 34–66 mmHg. Regarding the duration of mechanical ventilation, only one described no significant difference between ECCO<sub>2</sub>R and the controlled group [4]. The need for endotracheal intubation was significantly reduced from 53/67 (79%) to 16/71 (22%  $p < 0.001$ ). However, neither ICU nor hospital length of stay was statistically significantly reduced.

Based on the existing data, we believe that the ideal trial for ECCO<sub>2</sub>R should be a randomized controlled trial designed such ECCO<sub>2</sub>R should be implemented within 12 h of intubation after failing to show improvement (i.e., pH < 7.25 for persistent acidosis) with conventional therapy. Given the risks associated with the technique, it should be instituted once patients fail conventional treatment and require IMV. Patients should be randomized to ECCO<sub>2</sub>R plus IMV or standard IMV. Given the high rate of mortality associated with invasive mechanical ventilation, the study should be powered to demonstrate a mortality benefit, and secondary endpoints include ventilator-free days, transfusion requirements, and rates of ventilator-associated events.

More data will be forthcoming on the application of ECCO<sub>2</sub>R in the management of patients with COPD exacerbations from a number of ongoing or planned clinical trials (**Table 3**).

## 4.2 Severe acute asthma

Asthma is an inflammatory disorder of the airways characterized by airway hyperactivity with bronchospasm, mucosal swelling, and mucus production.

The standard treatment of severe acute asthma consists of measures to reverse airflow obstruction.  $\beta_2$  agonists and steroids are the mainstays of treatment causing bronchodilation and anti-inflammatory effects, respectively [10]. Other available adjunct therapies including anticholinergics, magnesium sulfate, methylxanthines, ketamine, and heliox have been utilized with varying results [46].

Despite advances in asthma therapy, asthma mortality has remained stable in recent years. One reason is status asthmaticus, which can be unresponsive to initial treatment and may lead to hypercapnic respiratory failure despite maximal therapy.

Status asthmaticus, also known as severe acute asthma or near-fatal asthma, is a condition of progressively worsening bronchospasm and respiratory dysfunction due to asthma, which is unresponsive to standard conventional therapy and may progress to respiratory failure and the need for mechanical ventilation. The current indication of mechanical ventilation in a patient presenting with status asthmaticus is a clinical one and does not require a blood gas assessment. These include certain specific situations including alteration of consciousness, respiratory fatigue, or impending cardiopulmonary arrest.

| ClinicalTrials.gov number   | Title   | Type of study                                       | Hypothesis/primary outcome   | Estimated enrollment | Device          |
|---|---|---|--|----------------------|-----------------|
| <b>ECCO<sub>2</sub>R to avoid mechanical ventilation</b>                      |   |   |  |                      |                 |
| NCT02086084   | Extracorporeal CO <sub>2</sub> removal as an adjunct to noninvasive ventilation in acute severe exacerbations of COPD | Randomized, controlled trial                        | Addition of ECCO <sub>2</sub> R to NIV will shorten the duration of NIV and reduce the likelihood of intubation<br>Primary outcome: time to cessation of NIV defined as from NIV commencement to 6 h without NIV   | 24 patients          | Hemolung RAS    |
| NCT03584295   | Early extubation by ECCO <sub>2</sub> R compared to IMV in patients with severe acute exacerbation of COPD (X-COPD)   | Interventional, randomized with parallel assignment | Advantage of VV-ECCO <sub>2</sub> R in severe acute exacerbation of COPD requiring invasive mechanical ventilation (IMV) to facilitate early extubation in terms of reducing mortality or severe disability<br>Primary outcome: death or severe disability   | 202 patients         | Not specified   |
| NCT02564406   | Extracorporeal CO <sub>2</sub> removal in hypercapnic patients  | Interventional single-group trial                   | Retrospectively assess the efficacy and safety of noninvasive ventilation-plus-extracorporeal CO <sub>2</sub> removal in patients who fail NIV and refuse endotracheal intubation<br>Primary outcome: number of patients who avoided endotracheal intubation | 35 patients          | ProLUNG [Estor] |
| NCT03692117   | Extracorporeal carbon dioxide removal in severe chronic obstructive pulmonary disease exacerbation                    | Prospective cohort study                            | Primary outcome: incidence of avoiding endotracheal intubation   | 30 patients          | Not specified   |
| <b>ECCO<sub>2</sub>R to facilitate liberation from mechanical ventilation</b> |   |   |  |                      |                 |
| NCT02259335   | Weaning from mechanical ventilation using extracorporeal CO <sub>2</sub> removal (WeanPRO)                            | Interventional single-group trial                   | Weaning success avoiding reintubation after removal of ECCO <sub>2</sub> R   | 12 patients          | ProLUNG [Estor] |
| NCT02107222   | The PALP™-COPD trial (low flow CO <sub>2</sub> -removal (ECCO <sub>2</sub> -R) in exacerbated COPD) (PALP-COPD)       | Multicenter, randomized, controlled trial           | To evaluate the clinical effect of PALP in reducing the time on invasive ventilation in patients with an exacerbation of COPD requiring invasive mechanical ventilation  | 120 patients         | PALP            |

| ClinicalTrials.gov number  | Title   | Type of study                           | Hypothesis/primary outcome  | Estimated enrollment | Device     |
|--|---|---|---|----------------------|------------|
| <b>ECCO<sub>2</sub>R as an alternative or adjunct to invasive mechanical ventilation</b> |   |   |   |                      |            |
| NCT03255057  | Extracorporeal CO <sub>2</sub> removal for mechanical ventilation avoidance during acute exacerbation of COPD (VENT-AVOID)                | Multicenter randomized controlled trial | ECCO <sub>2</sub> R can be safely used to avoid or reduce time on invasive mechanical ventilation compared to COPD patients treated with standard-of-care mechanical ventilation alone<br>Primary outcome: ventilator-free days at day 60 from randomization  | 500 patients         | Hemolung   |
| <b>ECCO<sub>2</sub>R physiological studies</b>   |   |   |   |                      |            |
| NCT02586948  | Physiological study of minimally invasive ECCO <sub>2</sub> R in exacerbations of COPD requiring invasive mechanical ventilation (EPHEBE) | Interventional single-group trial       | The addition of minimally invasive ECCO <sub>2</sub> R is likely to limit dynamic hyperinflation in COPD patients requiring invasive mechanical ventilation for an acute exacerbation while improving gas exchange<br>Primary outcome: PEEP <sub>i</sub> at baseline and after ECCO <sub>2</sub> R by the device and adjustment of ventilator settings, expressed in cmH <sub>2</sub> O | 12 patients          | Hemolung   |
| NCT02590575  | “Low Flow” CO <sub>2</sub> removal on RRT   | Interventional single-group trial       | Test the effectiveness of a membrane gas exchange device in the veno-venous circulation of continuous renal replacement therapy for the purpose of CO <sub>2</sub> elimination and pH compensation<br>The primary outcome is the modification of the PaCO <sub>2</sub> and/or the ventilator settings (tidal volume VT and plateau pressure Pplat)                                      | 20 patients          | Prismalung |

**Table 3.**  
*Ongoing clinical studies of ECCO<sub>2</sub>R in COPD.*

Approximately, 4% of all patients hospitalized for acute asthma require mechanical ventilation, which is associated with increased in-hospital mortality compared with patients who do not require mechanical ventilation (7 vs. 0.2%) [47].

Furthermore, mechanical ventilation may aggravate alveolar hyperinflation as it was described above. To prevent the potential side effects caused by mechanical ventilation, ECCO<sub>2</sub>R has been applied as rescue therapy.

Extracorporeal carbon dioxide removal as an adjunct to the ventilator for refractory asthma was first reported in 1981 [48]. Subsequently, there have been several case reports (Table 4). In the international Extracorporeal Life Support Organization (ELSO) registry, ECMO was used for asthma in 24 out of 1257 adult patients between 1986 and 2006. Before ECMO was started, the average pH was

7.17 ± 0.16, PaCO<sub>2</sub> 119.7 ± 58 mmHg, and PaO<sub>2</sub>/FiO<sub>2</sub> 244 ± 180 despite mechanical ventilation. Complications were described in 19 of 24 patients (79.2%) with a remarkable number of hemodynamic, hemorrhagic, and mechanical complications [49]. These data show that in patients treated with ECMO for status asthmaticus, hypercapnia, rather than hypoxemia, was the central exchange derangement, suggesting that a less invasive technique like ECCO<sub>2</sub>R will be suitable, with fewer complications. Although most of the clinical applications of ECCO<sub>2</sub>R for the treatment of obstructive lung diseases have been reported in patients with COPD, several cases describe ECCO<sub>2</sub>R in patients with near-fatal asthma [50–54] (Table 4).

The first cases reported were by using a pumpless extracorporeal life assist (pECLA) device. Although no complications were described in these case series, a possible major complication may arise as a consequence of the arterial cannulation, such as lower limb ischemia [53]. Brenner et al. reported two cases using a venous double lumen catheter with successful survival results.

| Study                 | ECCO <sub>2</sub> R technique   | Major findings   |
|-----------------------|---|--|
| Sakai et al. [53]     | Extracorporeal lung assist (ECLA); 22-Fr drainage and 18-Fr return femoro-femoral cannula with a median blood flow rate of 1.7–2 L/min                        | 23-year old<br>Gas exchange with IMV before ECCO <sub>2</sub> R: pH 7.02, paCO <sub>2</sub> 100 mmHg, PaO <sub>2</sub> 50 mmHg (FiO <sub>2</sub> 100%)<br>Weaning achieved after 20 h of ECLA was commenced<br>Extubation 2 days after ECLA<br>No complications reported   |
| Elliot et al. [52]    | Femoral AV pumpless extracorporeal lung assist (PECLA)<br>15-Fr arterial cannula and 17-Fr venous cannula with a mean extracorporeal blood flow of 1.5 L/min  | Case 1: 74-year old. Gas exchange with IMV before ECCO <sub>2</sub> R: pH 6.87, paCO <sub>2</sub> 147 mmHg. Extubation after 48 h of ECLA. Complications: Coagulation of membrane that needed changing. Bleeding through femoral artery<br>Case 2: 52-year old. Gas exchange with IMV before ECCO <sub>2</sub> R: pH 7.2, paCO <sub>2</sub> 130 mmHg. ECCO <sub>2</sub> R duration: 5 days<br>Extubated on intensive care day 11. No complications reported  |
| Jung et al. [54]      | Femoral AV pumpless extracorporeal lung assist (PECLA)<br>15-Fr arterial cannula and 17-Fr venous cannula with a mean extracorporeal blood flow of >1.5 L/min | 42-year old<br>No gas exchange before IMV reported. Patient successfully extubated and transferred from the ICU on day 14 of admission<br>No complications reported  |
| Brenner et al. [50]   | Dual-lumen catheter 20–23 Fr bicaval, inserted into the right internal jugular vein with blood flow of 1.3–1.8 L/min  | Case 1: 48-year old. Gas exchange with IMV before ECCO <sub>2</sub> R: pH 6.94, paCO <sub>2</sub> 147 mmHg, PaO <sub>2</sub> 416 mmHg (FiO <sub>2</sub> 100%). Successfully extubated while on ECCO <sub>2</sub> R and discharged from ICU. No complications reported<br>Case 2: 59-year old. Gas exchange with IMV before ECCO <sub>2</sub> R: pH 7.12, paCO <sub>2</sub> 78 mmHg, PaO <sub>2</sub> 112 mmHg (FiO <sub>2</sub> 100%). ECCO <sub>2</sub> R duration: 9 days. Ventilator support discontinued on day 28 due to critical illness neuromyopathy |
| Schneider et al. [51] | Awake dual-lumen catheter 22 Fr bicaval, inserted into the right internal jugular vein with blood flow of 0.6–1.5 L/min                                       | 67-year old<br>Gas exchange before ECCO <sub>2</sub> R (on NIV): pH 7.24, paCO <sub>2</sub> 61 mmHg, PaO <sub>2</sub> 289 mmHg (FiO <sub>2</sub> 100%)<br>Thirty-four hours after initiating ECCO <sub>2</sub> R, the patient was weaned entirely from NIV, and the cannula could be removed without any complication. On day 4, the patient was discharged from the ICU without the need for supplemental oxygen and 6 days later, discharged from hospital without any impairment  |

IMV, invasive mechanical ventilation; NIV, noninvasive mechanical ventilation.

**Table 4.**  
Case series of ECCO<sub>2</sub>R for near-fatal asthma.

Taking into account the deleterious effects of mechanical ventilation and sedation, and the advantages of keeping the patient awake, recently, an awake approach using a double lumen cannula has been described [51]. NIV was used as ventilatory support. Thirty-four hours after starting the ECCO<sub>2</sub>R system, the patient was weaned entirely from NIV, and the cannula was removed without complications. The patient was discharged from the ICU on day 4 without supplemental oxygen and left the hospital on day 10. Although this is a tempting approach, several issues should be taken into account. Unexpected cannula displacement may be provoked by an interactive patient, resulting in significant hemorrhage and lethal shock, as a time to react is short. Patient discomfort, pain, and anxiety in the “awake” approach might be in such extent that starting deep sedation and mechanical ventilation is inevitable, losing all the advantages described before.

## 5. Complications

Although ECCO<sub>2</sub>R seems to be effective in improving or mitigating hypercapnic acidosis and possibly in reducing the rate of endotracheal intubation, its use is associated with a range of vascular, hematological, and other complications.

Arterial cannulation is associated with higher risk than venous catheterization, with specific complications including distal limb ischemia, compartment syndrome of the lower limb requiring fasciotomy, or limb amputation as devastating consequences [16].

The occurrence of bleeding events is the most frequent complications of ECCO<sub>2</sub>R. The low flow renders systemic anticoagulation mandatory, increasing the risk of significant bleeding including cerebral, gastrointestinal, and nasopharyngeal bleeds. In the studies of ECCO<sub>2</sub>R to date, the rate of clinically significant hemorrhagic complications ranges between 2 and 50% [44].

Thrombocytopenia and heparin-induced thrombocytopenia are also commonly observed.

Conversely, thrombus formation is higher at lower blood flow rates because of increased exposure time to the membrane lung and circuit. Clots may detach and enter the patient’s bloodstream, plugging the membrane or obstructing the cannula if anticoagulation is not achieved.

## 6. Conclusions

In the past, ECCO<sub>2</sub>R was a complex technique requiring intensive monitoring and surgical expertise. Due to a high rate of complications, it was avoided by all but a few high expertise centers. With newer simplified system, devices are placed like temporary dialysis catheters and can be inserted by most intensivists.

In summary, minimally invasive ECCO<sub>2</sub>R appears very promising for patients with acute exacerbation of obstructive diseases refractory to conventional treatment, but systemic evaluation is needed to prove its efficacy and determine the actual risks.

## Acknowledgements

We want to acknowledge Eduardo Radicy for creating the figure for this manuscript. He was not compensated for this work.

## Conflict of interest

The authors declare that they do not have conflicting interests.

## Nomenclature

|                        |   |
|------------------------|---|
| AV-ECCO <sub>2</sub> R | arteriovenous extracorporeal carbon dioxide removal |
| COPD                   | chronic obstructive pulmonary disease               |
| CO <sub>2</sub>        | carbon dioxide                                      |
| DHI                    | dynamic hyperinflation                              |
| ECCO <sub>2</sub> R    | extracorporeal carbon dioxide removal               |
| ECMO                   | extracorporeal membrane oxygenation                 |
| IMV                    | invasive mechanical ventilation                     |
| NIV                    | noninvasive ventilation                             |
| PECLA                  | pumpless extracorporeal lung assist                 |
| PEEP                   | positive end-expiratory pressure                    |
| PLP                    | polypropylene                                       |
| PMP                    | poly-4-methyl-1-pentene                             |
| VV-ECCO <sub>2</sub> R | veno-venous extracorporeal carbon dioxide removal   |

## Author details

Luis Morales-Quinteros<sup>1\*</sup> and Antonio Artigas<sup>1,2,3</sup>

1 Intensive Care Unit, Hospital Universitario Sagrado Corazón, Barcelona, Spain

2 Critical Care Center, Parc Taulí Hospital Universitari, Institut d'Investigació i Innovació Parc Taulí I3PT, Universitat Autònoma de Barcelona, Sabadell, Spain

3 CIBER Enfermedades Respiratorias, Instituto de Salud Carlos III, Madrid, Spain

\*Address all correspondence to: luchomq2077@gmail.com

## IntechOpen

© 2019 The Author(s). Licensee IntechOpen. This chapter is distributed under the terms of the Creative Commons Attribution License (<http://creativecommons.org/licenses/by/3.0>), which permits unrestricted use, distribution, and reproduction in any medium, provided the original work is properly cited. 

## References

- [1] MacLaren G, Combes A, Bartlett R. Contemporary extracorporeal membrane oxygenation for adult respiratory failure: Life support in the new era. *Intensive Care Medicine*. 2012;**38**(2):210-220. DOI: 10.1007/s00134-011-2439-2
- [2] Schmidt M, Tachon G, Devilliers C, Muller G, Hekimian G, Bréchet N, et al. Blood oxygenation and decarboxylation determinants during venovenous ECMO for respiratory failure in adults. *Intensive Care Medicine*. 2013;**39**(5):838-846. DOI: 10.1007/s00134-012-2785-8
- [3] Abrams DC, Brenner K, Burkart KM, Agerstrand CL, Thomashow BM, Brodie D. Pilot study of extracorporeal carbon dioxide removal to facilitate extubation and ambulation in exacerbations of chronic obstructive pulmonary disease. *Annals of the American Thoracic Society*. 2013;**10**:307-314
- [4] Del Sorbo L, Pisani L, Filippini C, Fanelli V, Fasano L, Terragni P, et al. Extracorporeal CO<sub>2</sub> removal in hypercapnic patients at risk of noninvasive ventilation failure: A matched cohort study with historical control. *Critical Care Medicine*. 2015;**43**:120-127. DOI: 10.1097/CCM.0000000000000607
- [5] Kluge S, Braune SA, Engel M, Nierhaus A, Frings D, Ebel H, et al. Avoiding invasive mechanical ventilation by extracorporeal carbon dioxide removal in patients failing noninvasive ventilation. *Intensive Care Medicine*. 2012:1632-1639. DOI: 10.1007/s00134-012-2649-2
- [6] Diehl JL, Piquilloud L, Richard JC, Mancebo J, Mercat A. Effects of extracorporeal carbon dioxide removal on work of breathing in patients with chronic obstructive pulmonary disease. *Intensive Care Medicine*. 2016;**42**(5):951-952. DOI: 10.1007/s00134-015-4166-6
- [7] Pellegrino R, Violante B, Nava S, Rampulla C, Brusasco V, Rodarte J. Expiratory airflow limitation and hyperinflation during methacholine-induced bronchoconstriction. *Journal of Applied Physiology*. 1993;**75**:1720-1727. DOI: 10.1152/jappl.1993.75.4.1720
- [8] Laghi F, Goyal A. Auto-PEEP in respiratory failure. *Minerva Anestesiologica*. 2012;**78**:201-221
- [9] Wagers SS, Jaffe EF, Irving CG. Development structure and physiology in normal and asthmatic lung. In: *Middleton's Allergy: Principles and Practice*. St Louis: Mosby; 2003
- [10] National Heart, Lung and Blood Institute. Expert Panel Report 3: Guidelines for the Diagnosis and Management of Asthma: Full Report 2007. 2017. Available from: <http://nhlbi.nih.gov/guidelines/asthma/asthgdln.pdf>
- [11] Sethi JM, Siegel MD. Mechanical ventilation in chronic obstructive lung disease. *Clinics in Chest Medicine*. 2000;**21**:799-818. DOI: 10.1016/S0272-5231(05)70185-4
- [12] Blanch L, Bernabé F, Lucangelo U. Measurement of air trapping, intrinsic positive end-expiratory pressure, and dynamic hyperinflation in mechanically ventilated patients. *Respiratory Care*. 2005;**50**:110-123
- [13] Marhong JD, Telesnicki T, Munshi L, Del Sorbo L, Detsky M, Fan E. Mechanical ventilation during extracorporeal membrane oxygenation. *Annals of the American Thoracic Society*. 2014;**11**:956-961. DOI: 10.1513/AnnalsATS.201403-100BC
- [14] Langer T, Santini A, Bottino N, Crotti S, Batckinsky AI, Pesenti A, et al.



- “Awake” extracorporeal membrane oxygenation (ECMO): Pathophysiology, technical considerations, and clinical pioneering. *Critical Care*. 2016;**20**:150. DOI: 10.1186/s13054-016-1329-y
- [15] Gattinoni L, Pesenti A, Kolobow T, Damia G. A new look at therapy of the adult respiratory distress syndrome: Motionless lungs. *International Anesthesiology Clinics*. 1983;**21**:97-117
- [16] Cove ME, MacLaren G, Federspiel WJ, Kellum JA. Bench to bedside review: Extracorporeal carbon dioxide removal, past present and future. *Critical Care*. 2012;**16**(5):232
- [17] Terragni P, Maiolo G, Ranieri VM. Role and potentials of low-flow CO<sub>2</sub> removal system in mechanical ventilation. *Current Opinion in Critical Care*. 2012;**18**:93-98. DOI: 10.1097/MCC.0b013e32834f17ef
- [18] Winiszewski H, Aptel F, Belon F, Belin N, Chaignat C, Patry C, et al. Daily use of extracorporeal CO<sub>2</sub> removal in a critical care unit: Indications and results. *Journal of Intensive Care*. 2018;**6**:36. DOI: 10.1186/s40560-018-0304-x
- [19] May AG, Sen A, Cove ME, Kellum JA, Federspiel WJ. Extracorporeal CO<sub>2</sub> removal by hemodialysis: In vitro model and feasibility. *Intensive Care Medicine Experimental*. 2017;**5**:20. DOI: 10.1186/s40635-017-0132-7
- [20] Flörchinger B, Philipp A, Klose A, Hilker M, Kobuch R, Rupperecht L, et al. Pumpless extracorporeal lung assist: A 10-year institutional experience. *The Annals of Thoracic Surgery*. 2008;**86**:410-417. DOI: 10.1016/j.athoracsur.2008.04.045
- [21] Bein T, Weber F, Philipp A, Prasser C, Pfeifer M, Schmid FX, et al. A new pumpless extracorporeal interventional lung assist in critical hypoxemia/hypercapnia. *Critical Care Medicine*. 2006;**34**:1372-1377
- [22] Zimmermann M, Bein T, Arlt M, Philipp A, Rupperecht L, Mueller T, et al. Pumpless extracorporeal interventional lung assist in patients with acute respiratory distress syndrome: A prospective pilot study. *Critical Care*. 2009;**13**:R10. DOI: 10.1186/cc7703
- [23] Calverley PM, Walker P. Chronic obstructive pulmonary disease. *Lancet*. 2003;**362**(9389):1053-1061. DOI: 10.1016/S0140-6736(03)14416-9
- [24] Chapman KR, Mannino DM, Soriano JB, Vermeire PA, Buist AS, Thun MJ, et al. Epidemiology and costs of chronic obstructive pulmonary disease. *The European Respiratory Journal*. 2006;**27**(1):188-207. DOI: 10.1183/09031936.06.00024505
- [25] Barberà JA, Roca J, Ferrer A, Féllez MA, Díaz O, Roger N, et al. Mechanisms of worsening gas exchange during acute exacerbations of chronic obstructive pulmonary disease. *The European Respiratory Journal*. 1997;**10**(6):1285-1291
- [26] Roberts CM, Stone RA, Buckingham RJ, Pursey NA, Lowe D. Acidosis, non-invasive ventilation and mortality in hospitalised COPD exacerbations. *Thorax*. 2011;**66**(1):43-48. DOI: 10.1136/thx.2010.153114
- [27] Oliven A, Kelsen SG, Deal EC, Cherniak NS. Mechanisms underlying CO<sub>2</sub> retention during flow-resistive loading in patients with chronic obstructive pulmonary disease. *The Journal of Clinical Investigation*. 1983;**71**(5):1442-1449. DOI: 10.1172/JCI110897
- [28] Phua J, Kong K, Lee KH, Shen L, Lim TK. Noninvasive ventilation in hypercapnic acute respiratory failure due to chronic obstructive pulmonary disease vs. other conditions: Effectiveness and predictors of failure. *Intensive Care Medicine*. 2005;**31**(4):533-539. DOI: 10.1007/s00134-005-2582-8

- [29] Confalonieri M, Garuti G, Cattaruzza MS, Osborn JF, Antonelli M, Conti G, et al. A chart of failure risk for noninvasive ventilation in patients with COPD exacerbation. *The European Respiratory Journal*. 2005;**25**(2):348-355
- [30] Quinnell TG, Pilsworth S, Shneerson JM, Smith IE. Prolonged invasive ventilation following acute ventilatory failure in COPD: Weaning results, survival, and the role of noninvasive ventilation. *Chest*. 2006;**129**(1):133-139. DOI: 10.1378/chest.129.1.133
- [31] Chandra D, Stamm JA, Taylor B, Ramos RM, Satterwhite L, Krishnan JA, et al. Outcomes of noninvasive ventilation for acute exacerbations of chronic obstructive pulmonary disease in the United States, 1998-2008. *American Journal of Respiratory and Critical Care Medicine*. 2012;**185**(2):152-159. DOI: 10.1164/rccm.201106-1094OC
- [32] Tabak YP, Sun X, Johannes RS, Gupta V, Shorr AF. Mortality and need for mechanical ventilation in acute exacerbations of chronic obstructive pulmonary disease: Development and validation of a simple risk score. *Archives of Internal Medicine*. 2009;**169**(17):1595-1602. DOI: 10.1001/archinternmed.2009.270
- [33] Patil SP, Krishnan JA, Lechtzin N, Diette GB. In-hospital mortality following acute exacerbations of chronic obstructive pulmonary disease. *Archives of Internal Medicine*. 2003;**163**(10):1180-1186. DOI: 10.1001/archinte.163.10.1180
- [34] Demoule A, Girou E, Richard JC, Taille S, Brochard L. Benefits and risks of success or failure of noninvasive ventilation. *Intensive Care Medicine*. 2006;**32**(11):1756-1765. DOI: 10.1007/s00134-006-0324-1
- [35] Nava S, Ambrosino N, Clini E, Prato M, Orlando G, Vitacca M, et al. Noninvasive mechanical ventilation in the weaning of patients with respiratory failure due to chronic obstructive pulmonary disease. A randomized, controlled trial. *Annals of Internal Medicine*. 1998;**128**(9):721-728
- [36] Pesenti A, Rossi GP, Pelosi P, Brazzi L, Gattinoni L. Percutaneous extracorporeal CO<sub>2</sub> removal in a patient with bullous emphysema with recurrent bilateral pneumothoraces and respiratory failure. *Anesthesiology*. 1990;**72**(3):307-314
- [37] Brederlau J, Wurmb T, Wilczek S, Will K, Maier S, Kredel M, et al. Extracorporeal lung assist might avoid invasive ventilation in exacerbation of COPD. *The European Respiratory Journal*. 2012;**40**(3):783-785. DOI: 10.1183/09031936.00006012
- [38] Burki NK, Mani RK, Herth FJF, Schmidt W, Teschler H, Bonin F, et al. A novel extracorporeal CO<sub>2</sub> removal results of a pilot study of hypercapnic respiratory failure in patients with COPD. *Chest*. 2013;**143**(3):678-686. DOI: 10.1378/chest.12-0228
- [39] Braune S, Sieweke A, Brettner F, Staudinger T, Joannidis M, Verbrugge S, et al. The feasibility and safety of extracorporeal carbon dioxide removal to avoid intubation in patients with COPD unresponsive to noninvasive ventilation for acute hypercapnic respiratory failure (ECLAIR study): Multicentre case-control study. *Intensive Care Medicine*. 2016;**42**(9):1437-1444
- [40] Del Sorbo L, Fan E, Nava S, Ranieri VM. ECCO<sub>2</sub>R in COPD exacerbation only for the right patients and with the right strategy. *Intensive Care Medicine*. 2016;**42**(11):1830-1831. DOI: 10.1007/s00134-016-4493-2
- [41] Morelli A, D'Egidio A, Orecchioni A, Alessandri F, Mascia L, Ranieri VM. Extracorporeal CO<sub>2</sub> removal

in hypercapnic patients who fail noninvasive ventilation and refuse endotracheal intubation: A case series. *Intensive Care Medicine Experimental*. 2015;3(Suppl 1):A824. DOI: 10.1186/2197-425X-3-S1-A824

[42] Cardenas VJ Jr, Lynch JE, Ates R, Miller L, Zwischenberger JB. Venovenous carbon dioxide removal in chronic obstructive pulmonary disease: Experience in one patient. *ASAIO Journal*. 2009;55(4):420-422. DOI: 10.1097/MAT.0b013e3181a7b55d

[43] Roncon-Albuquerque R Jr, Carona G, Neves A, Miranda F, Castelo-Branco S, Oliveira T, et al. Venovenous extracorporeal CO<sub>2</sub> removal for early extubation in COPD exacerbations requiring invasive mechanical ventilation. *Intensive Care Medicine*. 2014;40(12):1969-1970. DOI: 10.1007/s00134-014-3503-5

[44] Sklar MC, Beloncle F, Katsios CM, Brochard L, Friedrich JO. Extracorporeal carbon dioxide removal in patients with chronic obstructive pulmonary disease: A systematic review. *Intensive Care Medicine*. 2015;41:1752-1762. DOI: 10.1007/s00134-015-3921-z

[45] Taccone FS, Malfertheiner MV, Ferrari F, Di Nardo M, Swol J, Broman LM, et al. *Minerva Anestesiologica*. 2017;83(7):762-772

[46] Wong JJ, Lee JH, Turner DA, Rehder KJ. A review of the use of adjunctive therapies in severe acute asthma exacerbation in critically ill children. *Expert Review of Respiratory Medicine*. 2014;8:423-441. DOI: 10.1586/17476348.2014.915752

[47] Krishnan V, Diettte GN, Rand CS, Bilderback AL, Merriman B, Hansel NN, et al. Mortality in patients hospitalized for asthma exacerbations in the United States. *American Journal of Respiratory and Critical Care Medicine*.

2006;174:633-655. DOI: 10.1164/rccm.200601-0070C

[48] MacDonnell KF, Moon HS, Sekar TS, Ahluwalia MP. Extracorporeal membrane oxygenator support in a case of severe status asthmaticus. *The Annals of Thoracic Surgery*. 1981;31:171-175

[49] Mikkelsen ME, Woo YJ, Sager JS, Fuchs BD, Christie JD. Outcomes using extracorporeal life support for adult respiratory failure due to status asthmaticus. *ASAIO Journal*. 2009;55:47-52. DOI: 10.1097/MAT.0b013e3181901ea5

[50] Brenner K, Abrams DC, Agerstrand CL, Brodie D. Extracorporeal carbon dioxide removal for refractory status asthmaticus: Experience in distinct exacerbation phenotypes. *Perfusion*. 2014;29:26-28. DOI: 10.1177/0267659113494964

[51] Schneider TM, Bence T, Brettner F. "Awake" ECCO<sub>2</sub>R superseded intubation in a near-fatal asthma attack. *Journal of Intensive Care*. 2017;5:53. DOI: 10.1186/s40560-017-0247-7

[52] Elliot SC, Paramasivam K, Oram J, Bodenham AR, Howell SJ, Mallick A. Pumpless extracorporeal carbon dioxide removal for life-threatening asthma. *Critical Care Medicine*. 2007;35(3):945-948. DOI:10.1097/01.CCM.0000257462.04514.15

[53] Sakai M, Ohteki H, Doi K, Narita Y. Clinical use of extracorporeal lung assist for a patient in status asthmaticus. *Annals of Thoracic Surgery*. 1996;62(3):885-887

[54] Jung C, Lauten A, Pfeifer R, Bahrman P, Figulla HR, Ferrari M. Pumpless extracorporeal lung assist for the treatment of severe, refractory status asthmaticus. *Journal of Asthma*. 2011;48(1):111-113. DOI: 10.3109/02770903.2010.528500