

We are IntechOpen, the world's leading publisher of Open Access books Built by scientists, for scientists

4,800

Open access books available

122,000

International authors and editors

135M

Downloads

Our authors are among the

154

Countries delivered to

TOP 1%

most cited scientists

12.2%

Contributors from top 500 universities



WEB OF SCIENCE™

Selection of our books indexed in the Book Citation Index
in Web of Science™ Core Collection (BKCI)

Interested in publishing with us?
Contact book.department@intechopen.com

Numbers displayed above are based on latest data collected.

For more information visit www.intechopen.com



Vogt-Koyanagi-Harada Disease

Cristhian A. Urzua

Abstract

Vogt-Koyanagi-Harada (VKH) disease is an autoimmune disorder characterized by bilateral intraocular inflammation, exudative retinal detachments, and extraocular manifestations in the auditory, integumentary, and central nervous systems (CNS). This condition is driven by T-cell-mediated autoimmunity directed against melanocytes present in the uveal tissue, in a specific genetic context. The diagnosis is based on clinical presentation, accounting with a set of standardized diagnostic criteria. Studies have reported that patients who have a significant delay in the diagnosis and/or clinical signs of the chronic stage of the disorder have a poorer prognosis and thus special efforts have to be performed in order to have an early diagnosis, together with an appropriate treatment. In that sense, the development of tools that allow us to detect this disease and its degree of severity is extremely important. In this line, novel candidate biomarkers—such as quantification of mRNA levels of NOD and glucocorticoid receptor—have been recently reported, and they represent significant advances that can help the clinician to improve patient categorization and outcomes.

Keywords: Vogt-Koyanagi-Harada disease, VKH, vitiligo, treatment response, biomarkers

1. Introduction

Vogt-Koyanagi-Harada (VKH) disease is an inflammatory and autoimmune condition characterized by intraocular inflammation, serous retinal detachments, and extraocular manifestations at the level of the auditory, integumentary, and central nervous systems (CNS) [1–3].

No epidemiological studies have been carried out on this condition. However, it has been related to certain geographical areas, such as Latin America and Asia, with a significant contribution of native origin. In this regard, its frequency has been reported up to 22.4% of uveitis causes in referral centers around the world [4–8].

Recently, significant advances have been reported regarding treatment options and novel approaches to evaluate and categorize this group of patients, in order to personalize follow-up and management in each subject and thus achieve better functional and anatomic outcomes [9].

2. Pathogenesis

The main disease mechanism would be driven by cell-mediated autoimmunity directed against melanocyte-related proteins, which are located mainly in the uveal tissue, skin, and CNS. A significant body of evidence has been published regarding the role of genetic associations. The human leukocyte antigen (HLA) appears as a

risk factor for VKH, and particularly HLA-DR alleles have shown more consistent data [10, 11]. Moreover, several associations with certain polymorphisms have been reported in Chinese population. In this regard, important advances regarding the role of genetic background in VKH have been introduced by Yang et al. This group has been extensively studying different polymorphisms in VKH in Chinese population [12].

Regarding the role of the immune system in VKH pathogenesis, CD4 + lymphocytes and key cytokines—such as interleukin-2 and interferon gamma—appear to play central roles in the development of autoimmunity against melanocyte-associated proteins [13–15].

3. Clinical findings

A prodromal stage may precede the ocular involvement. This stage is characterized by tinnitus and meningismus, which may include nausea, vomiting, stiffness of the neck and back, as well as headache as a frequent symptom. However, despite its high frequency, headache cannot be considered as a sufficient criterion for the definition of meningismus. By this stage, if lumbar puncture is performed, it may be returned with pleocytosis [3, 16].

After this prodromal phase of neurological findings, the disease continues toward ocular involvement, presenting bilateral acute panuveitis, with a low grade of anterior chamber cells and vitreous haze, and diffuse choroiditis, associated with exudative retinal detachments and optic disc swelling [1, 16–18] (**Figure 1**).

Following this initial uveitic phase, a significant group of patients may develop chronic granulomatous inflammation, and progressive depigmentation of the fundus resulting in “sunset glow fundus” appearance and/or chorioretinal atrophy (**Figure 2**). These clinical findings frequently result from insufficiently treated or from a late diagnosis, and they have been associated with poorer functional outcomes [19–21].

Experimental studies have reported choroidal infiltration of activated lymphocytes in patients with “sunset glow fundus,” suggesting a persistent low grade of subclinical inflammation, which may be implicated in the mechanism of autoimmune-mediated ocular depigmentation and atrophy [22, 23].

In addition, integumentary findings may be seen in some patients. In this regard, alopecia, poliosis, and vitiligo are classic signs related to pathological autoimmune response directed to pigmented tissues (**Figure 3**).

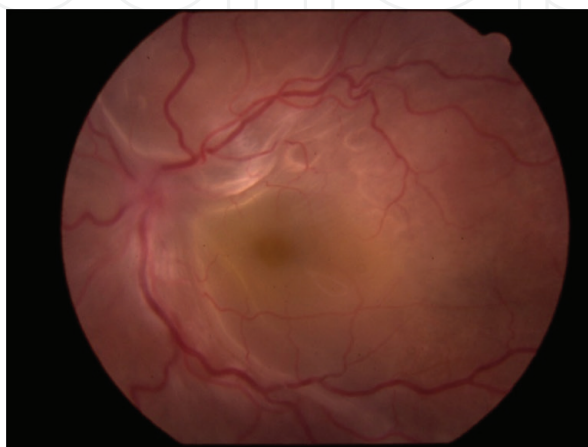

Figure 1.
Color fundus photo showing extensive areas of subretinal fluid and bullous serous retinal detachment in a 37-year-old female with VKH.

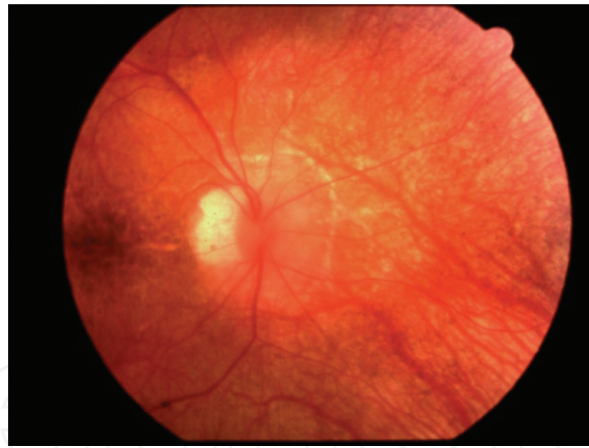

Figure 2.
Extensive fundus depigmentation in a VKH patient after 1 year of disease onset. Note the characteristic “sunset glow” appearance of the fundus.

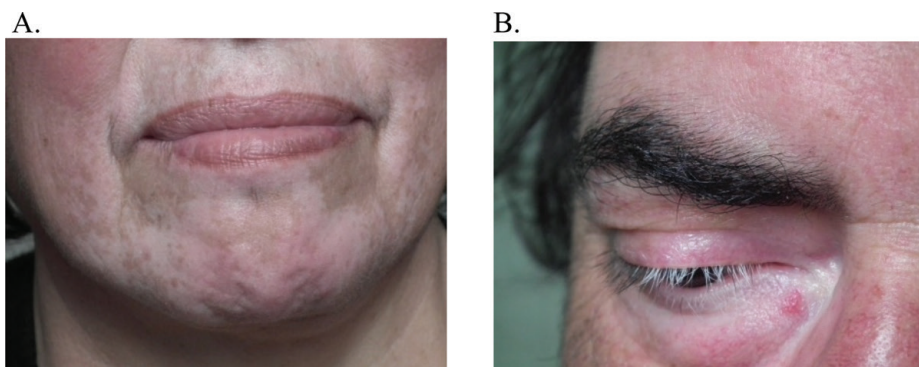


Figure 3.
Integumentary findings in VKH patients. (A) Areas of vitiligo in the perioral area and (B) poliosis in two adult patients with VKH.

4. Diagnosis

Diagnosis of VKH involves a comprehensive ophthalmic evaluation, in order to confirm the presentation of characteristic findings described above. Importantly, the bilateral nature of the condition and the presence of panuveitis, with areas of subretinal fluid and/or retinal detachments, as well as the inexistence of evidence of alternative diseases are hallmarks of the set of standardized diagnostic criteria previously published (**Table 1**) [3, 9, 24]. In that sense, the presence of integumentary and/or neurological findings defines the category of diagnosis (probable

-
1. No previous history of penetrating ocular trauma or surgery

 2. No clinical/laboratory evidence suggestive of another ocular condition

 3. **Ocular findings:** bilateral ocular involvement (*a or b must be present*):
 - a. Early manifestations:

 - a.1. Diffuse choroiditis, which may manifest as one of the following: focal areas of subretinal fluid and bullous serous retinal detachment

 - a.2. With equivocal fundus findings, both of the following must be present: characteristic *fluorescein retinal angiogram* findings (focal areas of delay on choroidal perfusion, multifocal areas of pinpoint leakage, large placoid areas of hyperfluorescence, pooling within subretinal fluid, optic nerve staining) and diffuse choroidal thickening without evidence of posterior scleritis on *ultrasonography*
-

b. Late manifestations:
b.1. History suggestive of prior presence of early manifestations and either both b.2 and b.3 findings or multiple signs from b.3
b.2. Ocular depigmentation (either of the following is sufficient): sunset glow fundus or Sugiura sign
b.3. Other ocular signs: nummular chorioretinal scars, retinal pigment epithelium clumping and/or migration, or recurrent/chronic anterior uveitis
4. Neurological/auditory findings:
a. Meningismus
b. Tinnitus
c. Pleocytosis on cerebrospinal fluid
5. Integumentary findings (not preceding ocular and neurological involvement):
a. Alopecia
b. Poliosis
c. Vitiligo
Diagnostic categories (<i>criteria 1 and 2 must be always present</i>):
1. Complete: ocular plus neurological/auditory plus integumentary findings
2. Incomplete: ocular plus either neurological/auditory or integumentary findings
3. Probable: only ocular findings
<i>*Modified from Read et al. [3].</i>

Table 1.
Revised diagnostic criteria for Vogt-Koyanagi-Harada disease*.

if only ocular findings are found, incomplete if at least an extraocular criteria is documented, and complete if all the extraocular criteria may be found) [3, 4, 25].

Despite these previously published diagnostic criteria, a moderate agreement among uveitis experts has been recently reported for the diagnosis of VKH, with a calculated kappa coefficient of 0.4 [25].

5. Treatment

The cornerstone of the therapy corresponds to the use of systemic corticosteroids (CS), based on the following principles: early treatment initiation, intensive (initial dose of prednisolone/prednisone of 1 mg/kg/day, with a maximum dose of 80 mg/day), and prolonged (at least 6 months) [27, 28].

Despite this aggressive therapy with systemic CS, a significant proportion of VKH patients present refractoriness, remaining with active inflammation and thus requiring immunomodulatory therapy (IMT) [9]. This subset of refractory patients has better functional outcomes if an earlier IMT is indicated [9].

Therefore, an early CS-response categorization should be carried out, in order to distinguish and to separate subjects with a potential benefit of early IMT initiation. In that sense, some clinical predictive factors of GC refractoriness have been described, such as baseline VA \leq 20/200, fundus depigmentation at diagnosis, and chronic disease, which are important facts to be considered in the context of an appropriate VKH initial evaluation [9].

Currently, a trend to the use of IMT, as first-line therapy, has been observed, with no preference in terms of a specific immunosuppressant [29].

6. Novel biomarkers of treatment response and disease activity

As stated above, systemic CS play a significant role for the management of VKH patients. CS have been broadly used for autoimmune and inflammatory diseases. It is a family of lipophilic medications that has its main mechanism of action at the level of the cellular nucleus, interacting directly with the DNA, enhancing or repressing gene expression [30].

Some significant developments have been published regarding potential biomarkers of treatment response based on the glucocorticoid receptor (GR), which is a ligand-dependent transcriptional factor [30]. Urzua et al. have found a distinct expression profile of GR isoforms that allows to categorize GC response as early as 2 weeks [26]. This laboratory-based approach is based on the quantification of mRNA levels of GR isoforms in two time points and a ratio calculation between both measurements. Furthermore, an in vitro assay has been developed, using a similar strategy based on GR expression measurements after in vitro manipulation of immune cells of VKH patients. In that sense, a single blood sample is required, and patient compliance is not mandatory since sampling for a second time or a CS systemic therapy is not required to perform the experiments (Urzua et al., data not published).

As previously described VKH may present with episodes of subclinical inflammation in which, despite clinical examination may appear with no disease activity, there is evidence of inflammatory foci at the level of choroid, using ancillary testing [17]. Although there have been efforts to standardize clinical examination in patients with uveitis, some issues remain, mainly related to the accuracy of measurements and subjectivity, especially with the clinical quantification of flare and vitreous inflammation [31, 32]. In that sense, a novel laboratory-based tool to categorize disease activity in VKH patients has been recently initiated. Following previous reports regarding the utility of GR quantification to evaluate treatment response in VKH, a protein implicated in this pathway has been studied as a candidate biomarker. A phosphatase of the MAPK pathway has been evaluated in different in vitro experimental conditions, and it has been found to have an association between its expression profile and disease activity in VKH patients (Urzua et al., data not published).

Significant evidence has been published regarding potential biomarkers for disease activity. In that sense, Yang et al. have reported a higher expression of NOD1/NOD2 and osteopontin (a matricellular protein) in patients with active VKH in comparison with healthy controls and inactive VKH [33, 34].

These promising biomarkers may help clinicians to make decisions in an inflammatory condition, which can present with significant choroidal inflammation with the absence of clinical evidence of active inflammation, with a resulting worsening in prognosis, in terms of sunset glow fundus and visual outcomes [21].

IntechOpen

Author details

Cristhian A. Urzua^{1,2}

1 Facultad de Medicina, Clinica Alemana-Universidad del Desarrollo, Santiago, Chile

2 Laboratorio de Enfermedades Autoinmunes Oculares y Sistemicas, Facultad de Medicina, Universidad de Chil, Santiago, Chile

*Address all correspondence to: cristhian.urzua@uchile.cl

IntechOpen

© 2019 The Author(s). Licensee IntechOpen. This chapter is distributed under the terms of the Creative Commons Attribution License (<http://creativecommons.org/licenses/by/3.0>), which permits unrestricted use, distribution, and reproduction in any medium, provided the original work is properly cited. 

References

- [1] Moorthy RS, Inomata H, Rao NA. Vogt-Koyanagi-Harada syndrome. Survey of Ophthalmology. 1995;**39**:265-292
- [2] Read RW, Rao NA. Utility of existing Vogt-Koyanagi-Harada syndrome diagnostic criteria at initial evaluation of the individual patient: a retrospective analysis. Ocular Immunology and Inflammation. 2000;**8**:227-234
- [3] Read RW, Holland GN, Rao NA, et al. Revised diagnostic criteria for Vogt-Koyanagi-Harada disease: report of an international committee on nomenclature. American Journal of Ophthalmology. 2001;**131**:647-652
- [4] Greco A, Fusconi M, Gallo A, et al. Vogt-Koyanagi-Harada syndrome. Autoimmunity Reviews. 2013;**12**:1033-1038
- [5] Kim MH, Seong MC, Kwak NH, et al. Association of HLA with Vogt-Koyanagi-Harada syndrome in Koreans. American Journal of Ophthalmology. 2000;**129**:173-177
- [6] Liberman P, Gauro F, Berger O, Urzua CA. Causes of Uveitis in a tertiary center in Chile: A cross-sectional retrospective review. Ocular Immunology and Inflammation. 2015;**23**:339-345
- [7] Nguyen M, Siak J, Chee SP, Diem VQH. The spectrum of Uveitis in Southern Vietnam. Ocular Immunology and Inflammation. 2017;**25**:S100-S106
- [8] Yang P, Ren Y, Li B, Fang W, Meng Q, Kijlstra A. Clinical characteristics of Vogt-Koyanagi-Harada syndrome in Chinese patients. Ophthalmology. 2007;**114**:606-614
- [9] Urzua CA, Velasquez V, Sabat P, et al. Earlier immunomodulatory treatment is associated with better visual outcomes in a subset of patients with Vogt-Koyanagi-Harada disease. Acta Ophthalmologica. 2015;**93**:e475-e480
- [10] Weisz JM, Holland GN, Roer LN, et al. Association between Vogt-Koyanagi-Harada syndrome and HLA-DR1 and -DR4 in Hispanic patients living in southern California. Ophthalmology. 1995;**102**:1012-1015
- [11] Arellanes-Garcia L, Bautista N, Mora P, et al. HLA-DR is strongly associated with Vogt-Koyanagi-Harada disease in Mexican Mestizo patients. Ocular Immunology and Inflammation. 1998;**6**:93-100
- [12] Ng JY, Luk FO, Lai TY, Pang CP. Influence of molecular genetics in Vogt-Koyanagi-Harada disease. Journal of Ophthalmic Inflammation and Infection. 2014;**4**:20
- [13] Hou S, Du L, Lei B, et al. Genome-wide association analysis of Vogt-Koyanagi-Harada syndrome identifies two new susceptibility loci at 1p31.2 and 10q21.3. Nature Genetics. 2014;**46**:1007-1011
- [14] Silpa-Archa S, Silpa-Archa N, Preble JM, Foster CS. Vogt-Koyanagi-Harada syndrome: Perspectives for immunogenetics, multimodal imaging, and therapeutic options. Autoimmunity Reviews. 2016;**15**:809-819
- [15] Sugita S, Takase H, Taguchi C, et al. Ocular infiltrating CD4+ T cells from patients with Vogt-Koyanagi-Harada disease recognize human melanocyte antigens. Investigative Ophthalmology & Visual Science. 2006;**47**:2547-2554
- [16] Attia S, Khochtali S, Kahloun R, Zaouali S, Khairallah M. Vogt-Koyanagi-Harada disease. Expert Review of Ophthalmology. 2012;**7**:565-585
- [17] Bouchenaki N, Cimino L, Auer C, Tao Tran V, Herbort CP. Assessment

and classification of choroidal vasculitis in posterior uveitis using indocyanine green angiography. *Klinische Monatsblätter für Augenheilkunde*. 2002;**219**:243-249

[18] Bouchenaki N, Herbort CP. Stromal choroiditis. In: Pleyer UMB, editor. *Essentials in Ophthalmology: Uveitis and Immunological Disorders*. Berlin, Heidelberg, New York: Springer; 2004. pp. 234-253

[19] Abu El-Asrar AM, Al Tamimi M, Hemachandran S, Al-Mezaine HS, Al-Muammar A, Kangave D. Prognostic factors for clinical outcomes in patients with Vogt-Koyanagi-Harada disease treated with high-dose corticosteroids. *Acta Ophthalmologica*. 2013;**91**:e486-e493

[20] Abu El-Asrar AM, Al Mudhaiyan T, Al Najashi AA, et al. Chronic recurrent Vogt-Koyanagi-Harada disease and development of 'Sunset Glow Fundus' predict worse retinal sensitivity. *Ocular Immunology and Inflammation*. 2017;**25**:475-485

[21] Kawaguchi T, Horie S, Bouchenaki N, Ohno-Matsui K, Mochizuki M, Herbort CP. Suboptimal therapy controls clinically apparent disease but not subclinical progression of Vogt-Koyanagi-Harada disease. *International Ophthalmology*. 2010;**30**:41-50

[22] Inomata H, Sakamoto T. Immunohistochemical studies of Vogt-Koyanagi-Harada disease with sunset sky fundus. *Current Eye Research* 9 Suppl:35-40, 1990

[23] Bacsal K, Wen DS, Chee SP. Concomitant choroidal inflammation during anterior segment recurrence in Vogt-Koyanagi-Harada disease. *American Journal of Ophthalmology*. 2008;**145**:480-486

[24] da Silva FT, Damico FM, Marin ML, et al. Revised diagnostic criteria

for vogt-koyanagi-harada disease: considerations on the different disease categories. *American Journal of Ophthalmology*. 2009;**147**:339-345.e5

[25] Jabs DA, Dick A, Doucette JT, et al. Interobserver Agreement Among Uveitis Experts on Uveitic Diagnoses: The Standardization of Uveitis Nomenclature Experience. *American Journal of Ophthalmology*. 2018;**186**:19-24

[26] Urzua CA, Guerrero J, Gatica H, Velasquez V, Goecke A. Evaluation of the Glucocorticoid Receptor as a Biomarker of Treatment Response in Vogt-Koyanagi-Harada Disease. *Investigative Ophthalmology & Visual Science*. 2017;**58**:974-980

[27] Nazari H, Rao NA. Resolution of subretinal fluid with systemic corticosteroid treatment in acute Vogt-Koyanagi-Harada disease. *The British Journal of Ophthalmology*. 2012;**96**:1410-1414

[28] Read RW, Yu F, Accorinti M, et al. Evaluation of the effect on outcomes of the route of administration of corticosteroids in acute Vogt-Koyanagi-Harada disease. *American Journal of Ophthalmology*. 2006;**142**:119-124

[29] Paredes I, Ahmed M, Foster CS. Immunomodulatory therapy for Vogt-Koyanagi-Harada patients as first-line therapy. *Ocular Immunology and Inflammation*. 2006;**14**:87-90

[30] Truss M, Beato M. Steroid hormone receptors: Interaction with deoxyribonucleic acid and transcription factors. *Endocrine Reviews*. 1993;**14**:459-479

[31] Denniston AK, Holland GN, Kidess A, et al. Heterogeneity of primary outcome measures used in clinical trials of treatments for intermediate, posterior, and panuveitis. *Orphanet Journal of Rare Diseases*. 2015;**10**:97

[32] Kempen JH, Ganesh SK, Sangwan VS, Rathinam SR. Interobserver agreement in grading activity and site of inflammation in eyes of patients with uveitis. *American Journal of Ophthalmology*. 2008;**146**:813-818.e1

[33] Chu M, Yang P, Hu R, et al. Elevated serum osteopontin levels and genetic polymorphisms of osteopontin are associated with Vogt-Koyanagi-Harada disease. *Investigative Ophthalmology & Visual Science*. 2011;**52**:7084-7089

[34] Deng B, Ye Z, Li L, et al. Higher expression of NOD1 and NOD2 is associated with Vogt-Koyanagi-Harada (VKH) syndrome but not behcet's disease (BD). *Current Molecular Medicine*. 2016;**16**:424-435

IntechOpen