

# We are IntechOpen, the world's leading publisher of Open Access books Built by scientists, for scientists

4,800

Open access books available

122,000

International authors and editors

135M

Downloads

Our authors are among the

154

Countries delivered to

TOP 1%

most cited scientists

12.2%

Contributors from top 500 universities



WEB OF SCIENCE™

Selection of our books indexed in the Book Citation Index  
in Web of Science™ Core Collection (BKCI)

Interested in publishing with us?  
Contact [book.department@intechopen.com](mailto:book.department@intechopen.com)

Numbers displayed above are based on latest data collected.

For more information visit [www.intechopen.com](http://www.intechopen.com)



# Management of Gastroschisis

*Alaa Obeida and Aly Shalaby*

## Abstract

Gastroschisis (GS) is one of the congenital abdominal wall defects, in which the bowel has prolapsed without a covering through a defect adjacent to (and nearly always to the right of) an otherwise normal umbilicus. Proper management of such cases gives them the opportunity to survive and thrive. In this chapter, simplified flowcharts for the initial management of GS, surgical intra-operative decisions and post-operative active follow-up of such cases will be presented and discussed. The first flowchart will discuss how to deal with a GS case from birth till the operative theatre, while the second flowchart will take the lead to guide the surgeon with the available surgical options and how to choose the suitable one for the case. Finally, the post-operative active follow-up fluid management and possible complications are discussed.

**Keywords:** gastroschisis, AWDs, fluid management, LMIC, complications

## 1. Introduction

Gastroschisis (GS) or more aptly “laparoschisis” is a congenital abdominal wall defect (AWD) leading to herniation of the gut more commonly to the right of the umbilical cord (**Figure 1**). It differs from other AWDs in causality, risk factors, and associated anomalies [1–3].

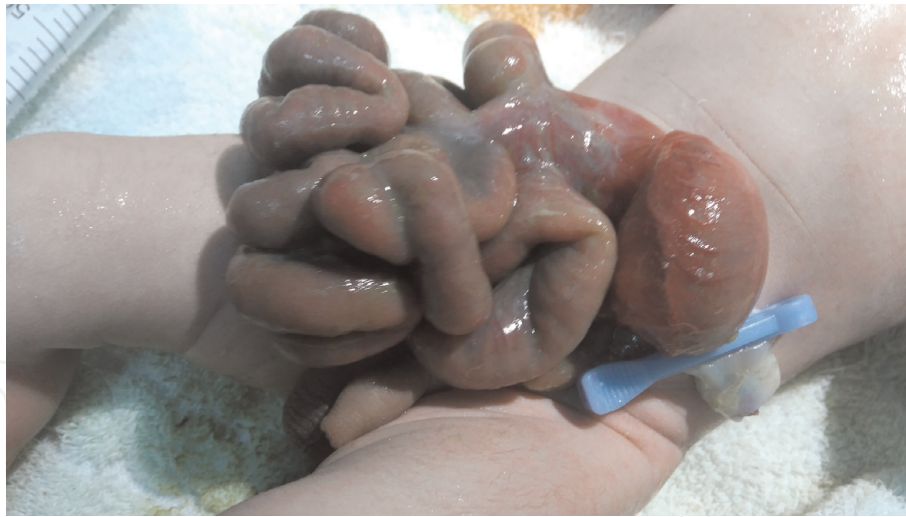GS incidence is increasing worldwide [4, 5] and is estimated around 1 in 2200 live births [6, 7]. Antenatal scans detect most cases [8], survival in developed countries is excellent [7] and apart from some gastrointestinal dysfunction, long-term problems are rare [9].

This chapter is dedicated to discuss in simplified flowchart-form the initial, operative and post-operative management of GS with emphasis on low-resource settings. In addition it aims to outline salient topics such as fluid management and complications.

## 2. Etiology and embryology

Though unexplained, a young maternal age and low socioeconomic status are the commonest risk factors for GS [10, 11]. Smoking, drugs, environmental toxins and poor nutrition have also been implicated [12]. A genetic link in the form of homozygous gene polymorphisms has been reported [13] and is substantiated by an increased prevalence among familial cases of birth defects and twins [14].

The embryological origin of GS is still a matter of conjecture. Several theories have been put forward attempting to expound the abdominal wall defect: failed body-wall folding [15]; a vascular insult to the omphalo-mesenteric artery [16] or to the right umbilical vein [17]; a localized disruption of the amniotic membrane [18]

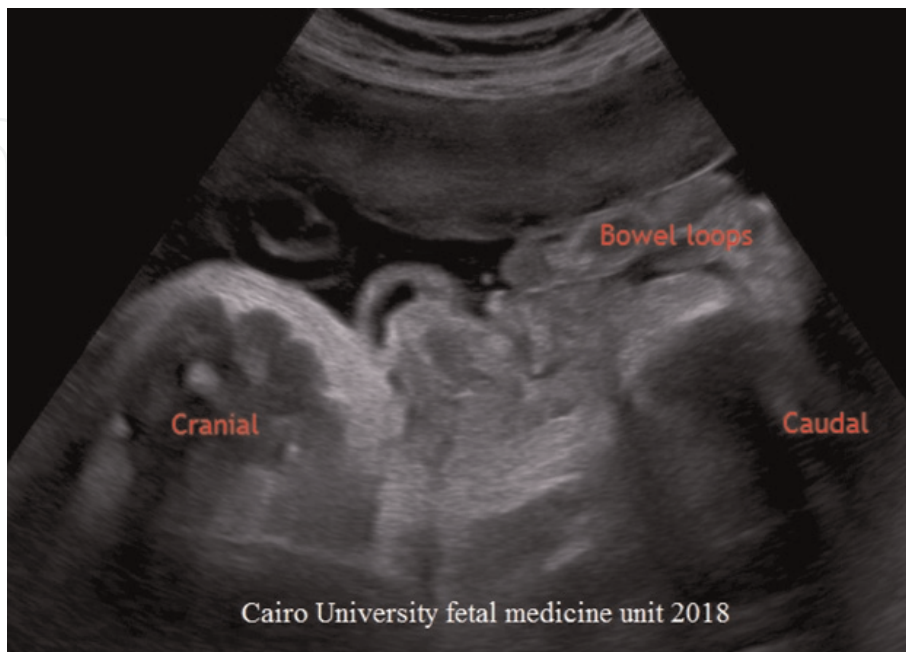

**Figure 1.**  
*Gastroschisis with prolapsed bowel to the right of the umbilicus.*

or teratogen-induced mesenchymal failure [19]. None of the theories are fully satisfactory [20]. The right-sided occurrence of the defect has been linked to the position of the yolk sac [15, 21] without clear reasoning as to why. Left-sided defects have also been described [22].

### **3. Antenatal diagnosis**

In high-income countries (HICs) routine antenatal scans may detect more than 97% of cases [23]. A diagnosis can be made as early as 10 weeks of gestation [24] and aids counseling, transfer and delivery [25, 26]. Ultrasound will typically pick up herniated bowel not covered by amnion, to the right of the umbilical cord (**Figure 2**). In contrast, an exomphalos will be covered by a membrane, lies in the



**Figure 2.**  
*Antenatal scan showing GS.*

midline and may involve solid organ prolapse. Ultrasound is instrumental in picking up closing GS which is defined as a worsening ratio of intra vs. extra peritoneal bowel dilatation [27]. Further aids to diagnosis of GS are high levels of maternal serum alpha-fetoprotein (MSAFP) [28], intrauterine growth retardation with or without oligo-/an-hydramnios [7, 29, 30]. As GS is usually an isolated anomaly with very few risks to the mother or child, termination of pregnancy is not habitually offered [2, 31, 32].

#### 4. Timing and mode of delivery

A spontaneous onset of labor will typically occur around 36 weeks gestation and the route of delivery is dependent on obstetric indications [33, 34]. There is a lack of high-level evidence to support early induction of labor in uncomplicated GS cases [35, 36] and a similar lack of evidence to support cesarean section [37]. Early (emergency) delivery is beneficial in closing GS [26].

#### 5. GS in low to middle income countries (LMICs)

LMICs have an overall high mortality rate in neonates with correctable congenital anomalies [38, 39] and suffer from a lack of medical facilities and personnel [40]. Non-governmental and governmental organizations have been criticized for not doing enough [41, 42] though new partnerships are attempting to redress this [43, 44].

Mortality from GS in low-to-middle-income countries (LMICs) can reach up to 80–100% [45–48] which is in sharp contrast to the <10% in HICs [49]. Sepsis is a major culprit in most cases of neonatal mortality in LMICs [48]. The Gastroschisis International (GiT) network has suggested that poor resuscitation combined with sepsis and abdominal compartment syndrome is directly linked to the poor outcome [50].

Antenatal care may not be well developed [51] or mothers may engage poorly with it [52] which risks births in areas far from the reach of the pediatric surgeon. A delay in transfer of the neonate with GS remains a main concern [47, 53] however a recent study from South Africa has suggested that resuscitation at the initial point of care and throughout transfer may be the key to improving the end result [51].

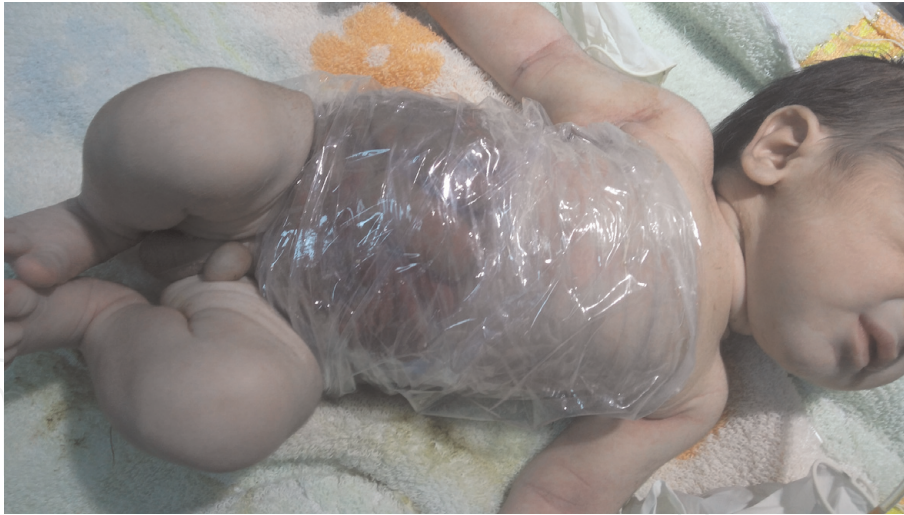#### 6. Initial management (pre-operative management)

A GS infant is ideally delivered at or near a facility with pediatric surgical support [25]. Conversely, outborn cases have been shown to have worse outcomes such as longer days on parenteral nutrition and longer duration to achieving full feeds [54].

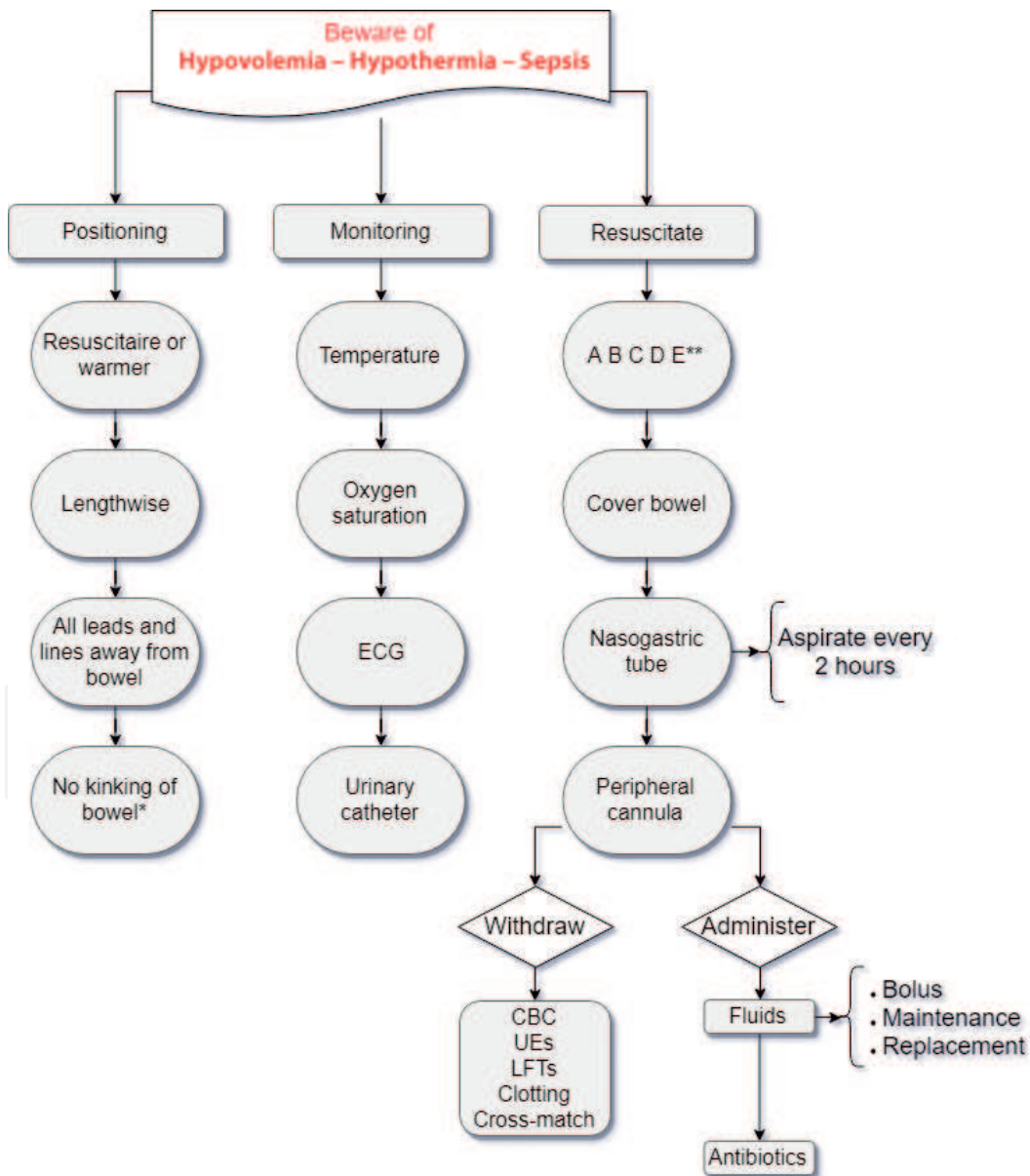
The accepted approach to managing GS is to cover the gut with a sterile bag (**Figure 3**), nasogastric decompression and fluid resuscitation. Hypothermia is a major risk due to the exposed gut and significant fluid losses [55]. Premature babies are particularly prone to hypothermia because of their high ratio of skin surface to weight and a lower amount of subcutaneous and brown fat. They may also have respiratory issues which impact on their oxygen consumption and heat production [55].

The authors follow the protocol outlined in **Figure 4**. At the outset doctors and nurses are reminded that the triad of hypovolemia, hypothermia and sepsis are the major threats to this neonate and that resuscitation is directed to mitigating their





**Figure 3.**  
Cling film covering the bowel in gastroschisis.



**Figure 4.**  
Initial management of gastroschisis. \*Kinking can be avoided by laying the child on their side or by propping up the bowel with gauze rolls while the child is supine. \*\* ABC of basic resuscitation. Do not forget blood sugar. CBC, complete blood count; UEs, urea and electrolytes; LFTs, liver function tests.

effects. Almost simultaneously, certainly not sequentially, the baby is positioned lengthwise on a resuscitaire or warmer to facilitate access. Any wires, leads or lines are shifted away from the baby and the bowel. Kinking of the bowel is avoided by laying the child on their side or by propping up the bowel with gauze rolls in the supine position. Probes for temperature and oxygen saturation are connected. ECG leads are placed and connected to a monitor. A urinary catheter is placed with an aseptic technique. Resuscitation follows APLS guidelines of airway, breathing, circulation, rapid initial examination while the bowel is covered with cling film. An appropriately-sized nasogastric tube is placed on free drainage supplemented by 2-hourly active aspiration. Peripheral vascular access is secured and bloods are taken for blood sugar (if not done earlier), a complete blood picture, kidney and liver functions, clotting and cross-match. A fluid bolus is then administered followed by maintenance according to body weight. Broad-spectrum antibiotics are given according to the hospital protocol.

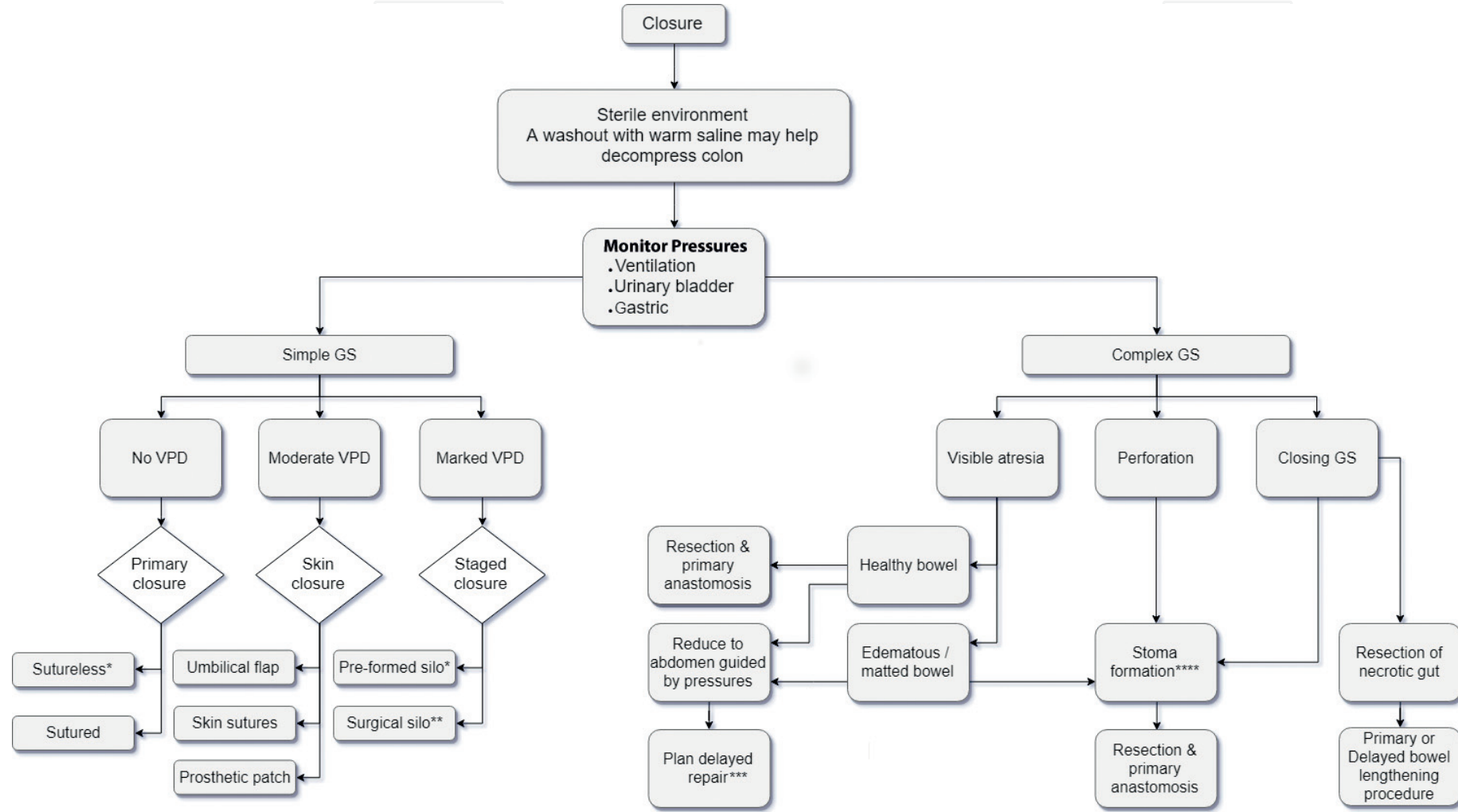
## 7. Intra-operative decision making

The aspired aim is to achieve full reduction of the bowel with muscle and skin closure of the abdominal wall, as cosmetically as possible. Safety of the child and the gut are paramount therefore if a complete primary closure is not possible staged reduction should be considered.

All manipulations should be done in a sterile environment. The authors routinely take all cases to theatre, however bedside procedures are also possible. Central vascular access is secured and a urinary catheter would have been placed during initial resuscitation in all cases.

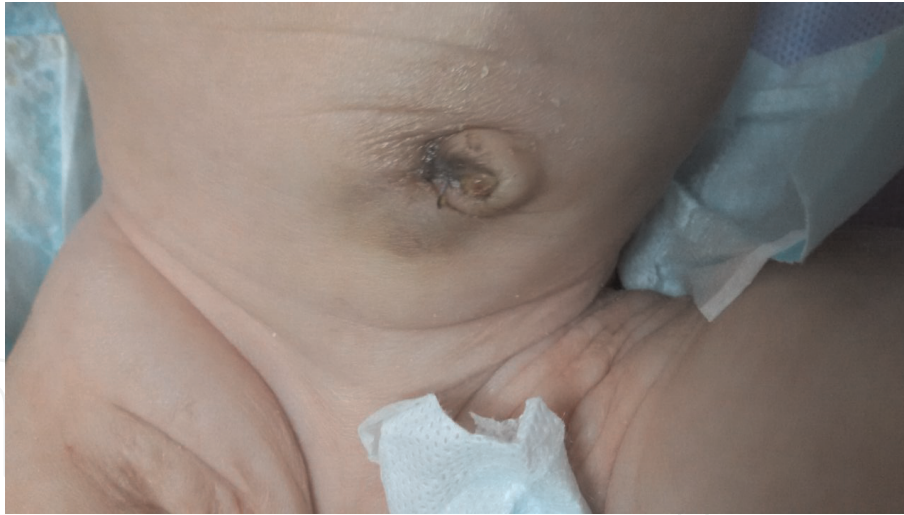The authors follow the guideline outlined in **Figure 5**: cases of simple GS with no obvious visceroperitoneal disproportion (VPD) will undergo primary closure. If very straightforward, sutureless closure with steri-strip dressings is done. On occasion some cases will require division of bands or strands of omentum adherent to the defect and they go on to have formal sutured closure of the defect. Primary (sutured) closure has excellent cosmetic results (**Figures 6 and 7**). Sutureless closure is associated with a higher incidence of umbilical hernia [56, 57]. Guided by ventilation pressures, cases with moderate VPD will undergo a skin closure with the size of the defect determining if the umbilicus, the skin or a prosthetic patch is needed. Marked VPD and high ventilation pressures call for staged silo closure. The authors fashion surgical silos from sterile intravenous fluid bags (**Figure 8a–c**). Surgical silos can be made from a variety of materials which are summarized in **Box 1**. Spring-loaded (pre-formed) silos are ready-made and obviate the need for suturing to the abdominal wall [20, 55]. They come in various sizes to allow for the variability in the GS defect (**Figure 9**). One may rely on gravity alone, active tucking or a combination of both to reduce the contents into the abdominal cavity. There is weak evidence in favor of the routine use of pre-formed silos instead of primary closure [20, 55, 58].

Complex GS is defined as any case with associated bowel atresia, stenosis, perforation or volvulus. In the presence of atresia, the authors' preference is to plan a delayed repair but a primary resection and anastomosis at the time of abdominal closure is also acceptable if the bowel is healthy and not too edematous. Stoma formation is fraught with high-output stoma complications such as failure to thrive and peri-stoma skin breakdown—therefore is not the surgery of choice in low-resource settings. Closing GS represents a spectrum of disease where the defect has started to narrow down around the prolapsed gut. At its simplest form it can lead to intestinal stenosis but may progress to atresia, gut ischemia up to complete

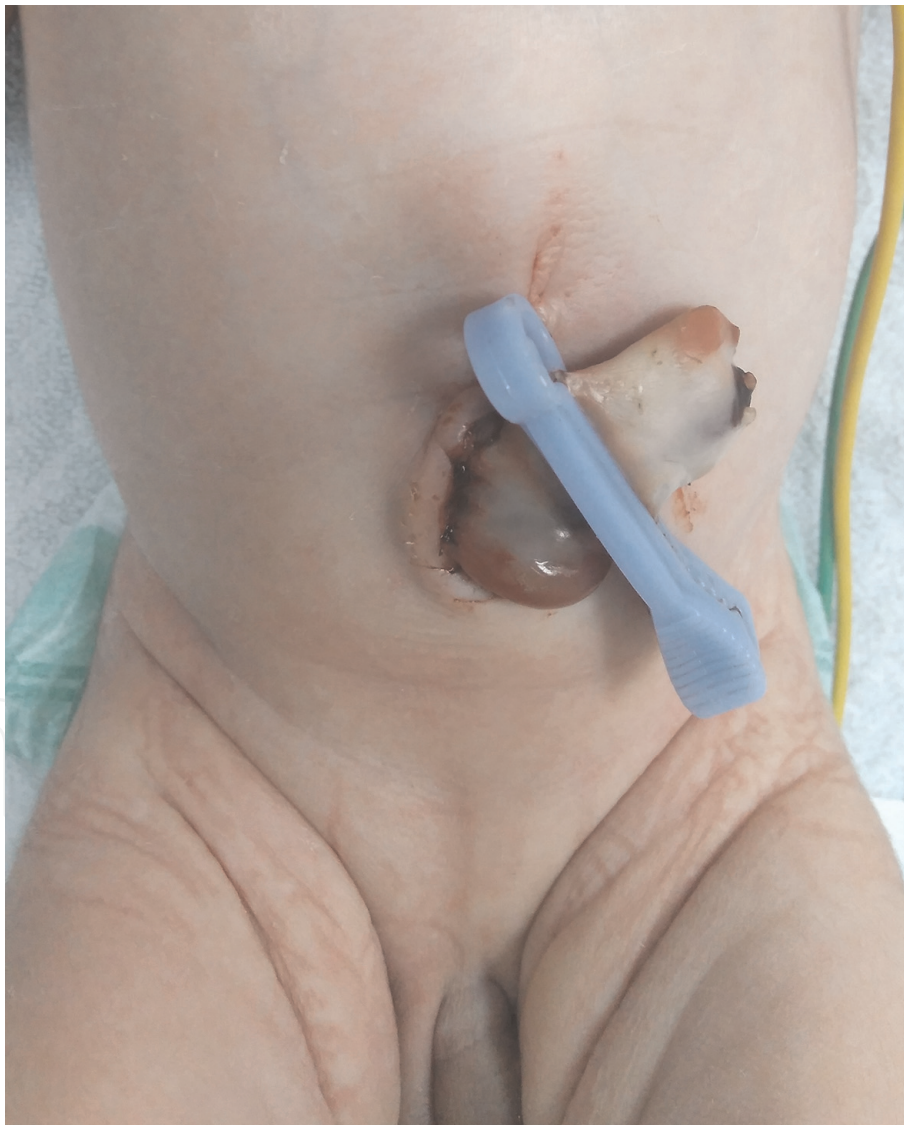

**Figure 5.** Options for closure of gastroschisis. \* Can be done cotside. \*\* Silo material, see Box 2. \*\*\* Delayed repair is around 6 weeks post-operatively. \*\*\*\* Avoid stoma in a low-resource setting. GS, gastroschisis; VPD, visceroperitoneal disproportion.





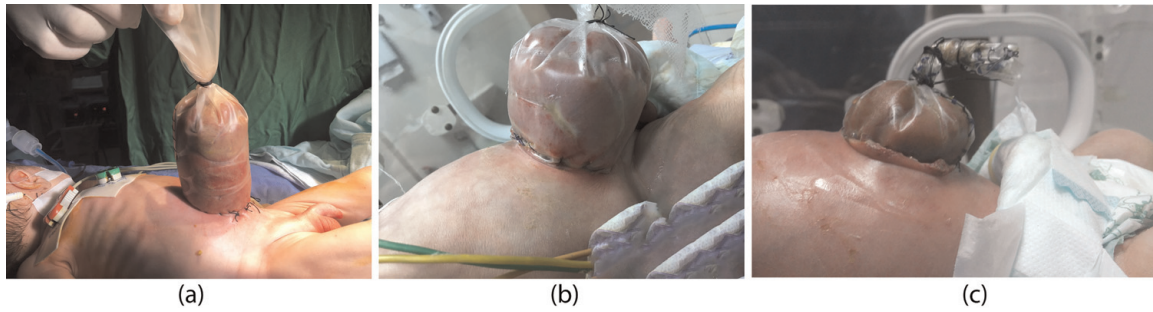
**Figure 6.**  
*Cosmetic result after primary closure.*



**Figure 7.**  
*Primary Closure.*

disappearance of the prolapsed bowel if the defect closes completely, aka closed GS or “vanishing gut syndrome” [61]. Closing GS is challenging even in HICs and is associated with worse outcomes compared to simple GS. Narrowing or atresia may





**Figure 8.**  
(a–c) Staged silo reduction.

- Prolene mesh
- Silicone sheet
- Goretex mesh
- Sterile adhesive drapes +/- prolene mesh
- Biomaterials (Alloderm, Permacol)
- IV fluid bag
- Female condom
- Alexis wound protector

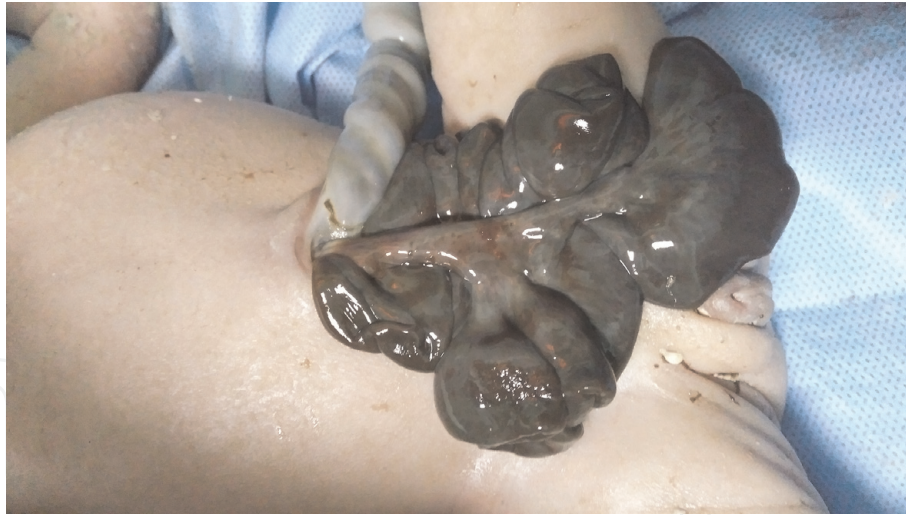**Box 1.**

Available silo materials [55, 59, 60].

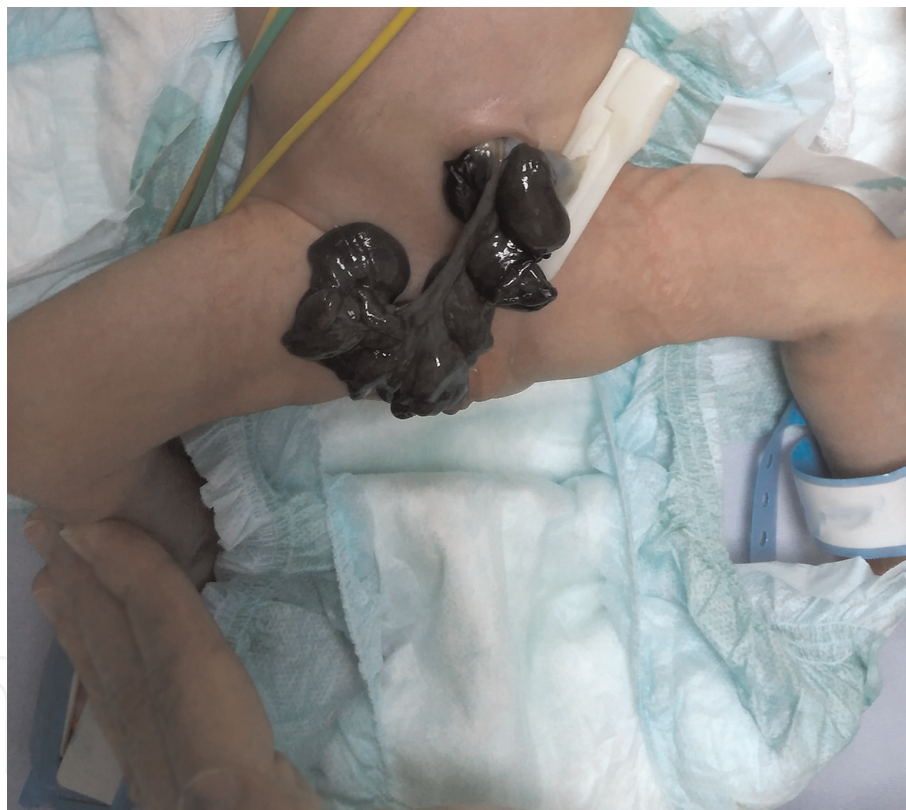

**Figure 9.**  
Pre-formed silos <http://bentecmed.com/bentec-medical-products/ventral-wall-defect-silo-bags/>.

lend themselves to resection and primary anastomosis (either at the time of reduction, or delayed). Necrotic gut will require resection (**Figures 10 and 11**) and vanished gut will indicate an ultra-short intra-abdominal segment. These cases will require either primary or delayed bowel lengthening procedures [62].



**Figure 10.**  
*Closing gastroschisis with necrotic bowel.*



**Figure 11.**  
*Closing gastroschisis with necrotic bowel.*

## 8. Post-operative care

The staged reduction process should take between 1 day and 2 weeks and is dependent on the degree of VPD. Enteral feeds are started once the gastro-intestinal system shows signs of resumed function: decreased nasogastric aspirates <20 ml/kg and bowel motions. Ideally expressed maternal breast milk is used [63–65], but formula feeds are acceptable. Elemental feeds may help protect against necrotizing enterocolitis. GS infants fed at around 7 days post closure seem to have the best outcome [66]. If the bowels do not open within 10–14 days a water-soluble contrast

enema should be done to rule out a bowel atresia. An atresia detected at the time of initial closure of by subsequent imaging may be safely repaired after 3–6 weeks. Albeit uncommon in GS, cases with any associated malformations will require further investigations and management according to the findings.

## **9. Fluid management in GS**

Publications frequently refer to a “consensus” among doctors on the optimal fluids required for GS. However, there is sparse evidence-based literature to guide the perioperative fluid management [65, 66]. Reports of fluid administration have varied from twice to three-times the normal maintenance volumes for neonates [67, 68] and were based on original research by Phillipart et al. in 1972 [69].

Fluid overload in the absence of hypovolemia has been proven to be deleterious in neonates [70]. It affects a patent ductus arteriosus, may cause intracranial hemorrhage, bronchopulmonary dysplasia or may even be fatal [71, 72]. Therefore the mere assumption that GS cases need vigorous volume expansion may be harmful. Preterm neonates may also benefit from fluid restriction according to a recent Cochrane review [73]. It has been suggested that the fluid overload will contribute to intestinal edema leading to a longer hospital stay and longer duration of parenteral nutrition through the increase of total body water and salt [65]. It may also play a part in development of NEC [74].

This practice of over transfusion is routinely carried out postoperatively as well [75]. While it may be of value in cases with a silo where there are ongoing losses of fluid from the base, it has no real justification in cases which undergo primary closure.

Few published sources will give an outright volume to go by. They will always be ranges and the clinician must be guided by continuous assessment of the child. Postnatal diuresis can complicate fluid-balance calculations but a useful milestone to assess the cardiovascular status is after administering 40 ml/kg of fluid. Albumin has been advocated as a volume expander in hypovolemic GS cases. It is not particularly useful in hypoalbuminemia associated with sepsis [76, 77]. An additional tool to help restore insensible water loss incurred through breathing is the humidification of incubator air.

## **10. Complications**

### **10.1 Abdominal compartment syndrome (ACS)**

A large degree of visceroperitoneal disproportion and over-zealous reduction runs the risk of increased intra-abdominal pressure. The latter will result in restricting diaphragmatic movement and compression of the inferior vena cava, which will in turn result in respiratory distress, renal, liver and bowel ischemia, respectively. They manifest as metabolic acidosis, oliguria, renal and liver dysfunction [55].

Frequent monitoring of oxygen saturation/ventilation setting, serial blood gases, urine output, serial abdominal examinations, lower limb perfusion are important in early detection of ACS. Oliguria alone is not a sensitive indicator of ACS as it may be due to hypovolemia. Pressure measurements can be taken using sophisticated transducers used with anesthesia machines or by simply connecting the tubing to a CVP water manometer. Reference values are quoted in **Box 2** [78–81].



- Gastric/urinary bladder pressure < 20 cm H<sub>2</sub>O or < 15–20 mmHg
- End-tidal CO<sub>2</sub> < 50 mmHg
- CVP < 4 mmHg or < 5.4 cm H<sub>2</sub>O
- Ventilation < 24 cm H<sub>2</sub>O

**Box 2.**  
*Reference values for safe abdominal closure [78–81].*

## 10.2 Sepsis

Sepsis is a common complication in LMICs. Most common sources are intra-abdominal, silo/wound infections, indwelling central lines or urinary catheters [50, 51].

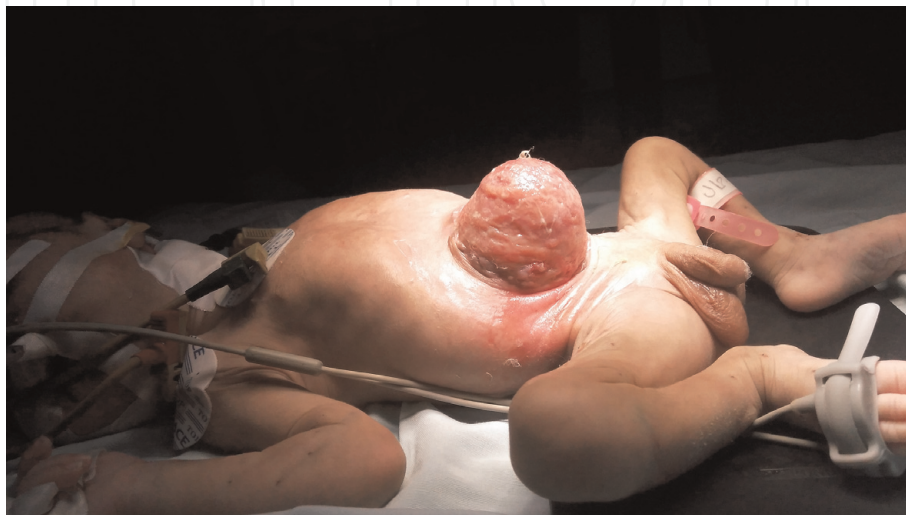As always, prevention is better than cure. Meticulous antisepsis protocols and timely use of antibiotics are important first tools. Early suspicion of central line-associated blood stream infection (CLABSI) or urinary tract infection (UTI) should prompt urgent cultures to be sent to the lab. The authors remove the urinary catheter once there is a stable urine output and no further risk of abdominal compartment syndrome.

## 10.3 Silo complications

Both pre-formed and surgical silos are prone to dislodgement and may cause bowel kinking, ischemia and perforation [58]. It is prudent to keep the silo and its contents visible at all times to allow early detection of any of these complications.

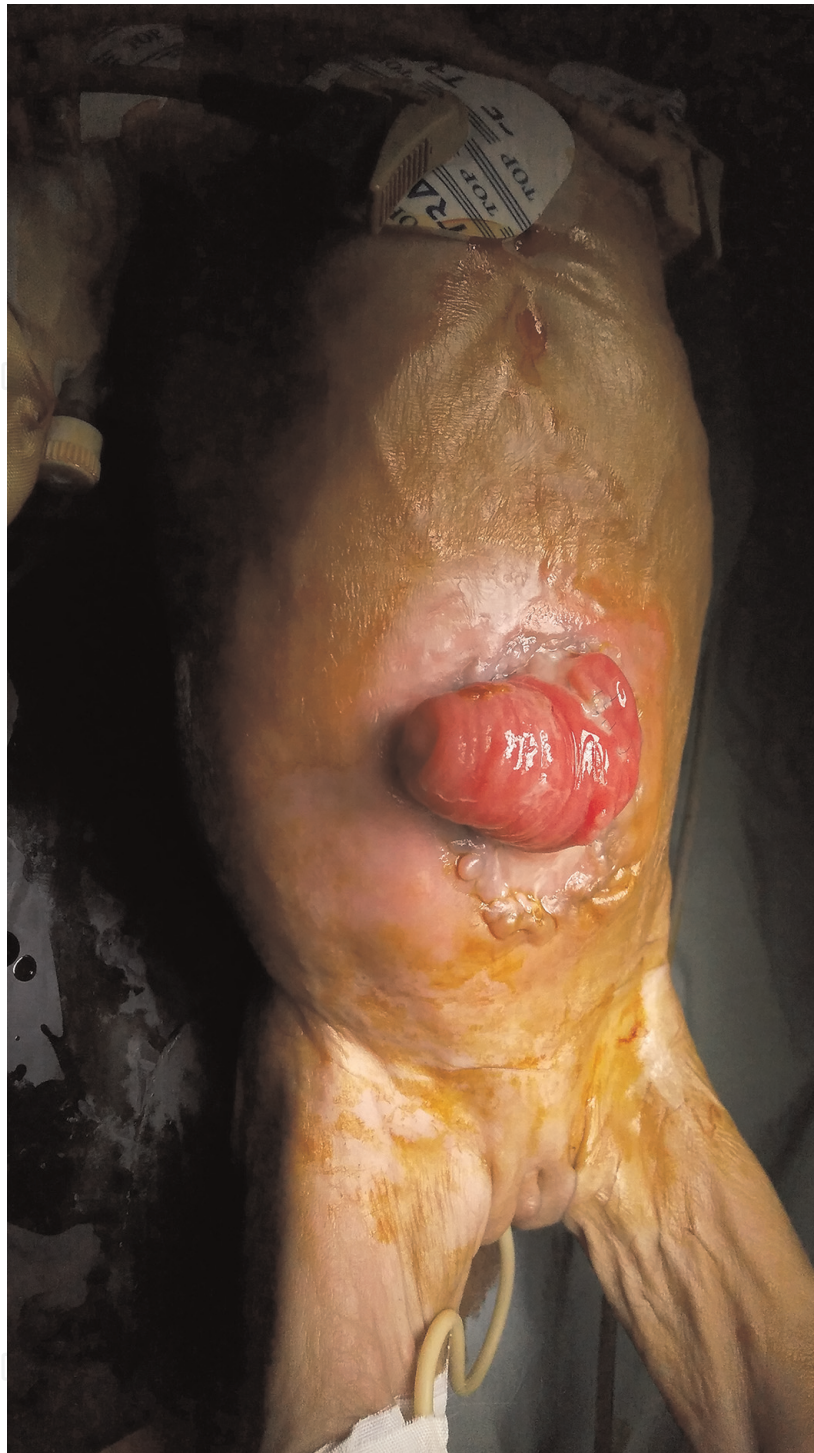## 10.4 Pneumothorax

Iatrogenic pneumothorax secondary to barotrauma is an unfortunate complication in ventilated neonates and occurs in around 8.7% of the cases [82]. In GS this may be due to high intra-abdominal pressure after bowel reduction. This is best anticipated in theatre and if pressures exceed 24 cm H<sub>2</sub>O, a staged reduction should



**Figure 12.**  
*Large abdominal wall defect with granulation in long-standing silo.*





**Figure 13.**  
*Entero-cutaneous fistula.*

be the surgery of choice. If post-operative ventilation is unavoidable then positive end-expiratory pressure (PEEP) or high-frequency oscillation ventilation (HFOV) is used. Neuromuscular paralysis may also help reduce ventilation pressures but is not always available in low-resource settings.

A pneumothorax is suspected when oxygen saturation drops and ventilation pressures rise sharply with absent ipsilateral air entry. An urgent plain chest x-ray will confirm this and should be followed by immediate needle decompression then a formal chest drain with an underwater seal. Bilateral asynchronous pneumothoraces are not uncommon [82].

## 10.5 Others

- **NEC:** It follows the same patterns and risk factors as with non-GS infants. Prematurity, formula feeds, rapid increase in feed volume—have all been implicated. Treatment is standard: nasogastric tube decompression, gut rest and antibiotics will often suffice [83, 84].
- **Large abdominal defect:** The GS defect is seldom large to start with and is occasionally enlarged by the surgeon to facilitate bowel reduction. Hence a large defect is a rare complication which may occur in long-standing cases of staged-reduction (**Figure 12**). Standard closure techniques include the use of a prosthetic material or plastic surgery techniques such as abdominal wall rotational flaps with or without lateral release incisions [85].
- **Enterocutaneous fistula:** (**Figure 13**) rare complication which may occur secondary to wound infection, NEC, or a combination of both. Vacuum dressings have been of value in treating such a complication [55, 86]. It is the authors' experience that vacuum dressings may paradoxically cause an enterocutaneous fistula if incorrectly placed or if the suction is too vigorous. Surgical closure when the infant is in a positive nitrogen balance is beneficial.

### Author details

Alaa Obeida\* and Aly Shalaby  
Pediatric Surgery Department, Cairo University, Specialized Pediatric Hospital,  
Cairo, Egypt

\*Address all correspondence to: [alaa.obeida@gmail.com](mailto:alaa.obeida@gmail.com)

### IntechOpen

© 2019 The Author(s). Licensee IntechOpen. This chapter is distributed under the terms of the Creative Commons Attribution License (<http://creativecommons.org/licenses/by/3.0>), which permits unrestricted use, distribution, and reproduction in any medium, provided the original work is properly cited. 

## References

- [1] Wilson RD, Johnson MP. Congenital abdominal wall defects: An update. *Fetal Diagnosis and Therapy*. 2004;**19**(5): 385-398
- [2] David AL, Tan A, Curry J. Gastroschisis: Sonographic diagnosis, associations, management and outcome. *Prenatal Diagnosis: Published in Affiliation With the International Society for Prenatal Diagnosis*. 2008; **28**(7):633-644
- [3] Gow KW, Bhatia A, Saad DF, Wulkan ML, Heiss KF. Left-sided gastroschisis. *The American Surgeon*. 2006;**72**(7):637-640
- [4] Tan KH, Kilby MD, Whittle MJ, Beattie BR, Booth IW, Botting BJ. Congenital anterior abdominal wall defects in England and Wales 1987–93: Retrospective analysis of OPCS data. *BMJ*. 1996;**313**(7062):903-906
- [5] International Clearinghouse for Birth Defects Surveillance and Research (ICBDSR). *ICBDSR Annual Report 2005, with data 2003*. Rome: ICBDSR Centre; 2005. [www.icbd.org](http://www.icbd.org)
- [6] Parker SE, Mai CT, Canfield MA, Rickard R, Wang Y, Meyer RE, et al. Updated national birth prevalence estimates for selected birth defects in the United States, 2004–2006. *Birth Defects Research Part A: Clinical and Molecular Teratology*. 2010;**88**(12):1008-1016
- [7] Holland AJ, Walker K, Badawi N. Gastroschisis: An update. *Pediatric Surgery International*. 2010;**26**(9): 871-878
- [8] Bond SJ, Harrison MR, Filly RA, Callen PW, Anderson RA, Golbus MS. Severity of intestinal damage in gastroschisis: Correlation with prenatal sonographic findings. *Journal of Pediatric Surgery*. 1988;**23**(6):520-525
- [9] Langer JC, Longaker MT, Crombleholme TM, Bond SJ, Finkbeiner WE, Rudolph CA, et al. Etiology of intestinal damage in gastroschisis. I: Effects of amniotic fluid exposure and bowel constriction in a fetal lamb model. *Journal of Pediatric Surgery*. 1989;**24**(10):992-997
- [10] Loane M, Dolk H, Bradbury I. A EUROCAT Working Group. Increasing prevalence of gastroschisis in Europ. 1980–2002: A phenomenon restricted to younger mothers? *Paediatric and Perinatal Epidemiology*. 2007;**21**(4):363-369
- [11] Mac Bird T, Robbins JM, Druschel C, Cleves MA, Yang S, Hobbs CA, et al. Demographic and environmental risk factors for gastroschisis and omphalocele in the National Birth Defects Prevention Study. *Journal of Pediatric Surgery*. 2009;**44**(8): 1546-1551
- [12] Forrester MB, Merz RD. Comparison of trends in gastroschisis and prenatal illicit drug use rates. *Journal of Toxicology and Environmental Health, Part A*. 2006; **69**(13):1253-1259
- [13] Torfs CP, Christianson RE, Iovannisci DM, Shaw GM, Lammer EJ. Selected gene polymorphisms and their interaction with maternal smoking, as risk factors for gastroschisis. *Birth Defects Research Part A: Clinical and Molecular Teratology*. 2006;**76**(10): 723-730
- [14] Hwang PJ, Kousseff BG. Omphalocele and gastroschisis: An 18-year review study. *Genetics in Medicine*. 2004;**6**(4):232
- [15] Feldkamp ML, Carey JC, Sadler TW. Development of gastroschisis: Review of hypotheses, a novel hypothesis, and



- implications for research. *American Journal of Medical Genetics Part A*. 2007;**143**(7):639-652
- [16] Hoyme HE, Higginbottom MC, Jones KL. The vascular pathogenesis of gastroschisis: Intrauterine interruption of the omphalomesenteric artery. *The Journal of Pediatrics*. 1981; **98**(2):228-231
- [17] Devries PA. The pathogenesis of gastroschisis and omphalocele. *Journal of Pediatric Surgery*. 1980;**15**(3):245
- [18] Shaw A. The myth of gastroschisis. *Journal of Pediatric Surgery*. 1975;**10**(2): 235-244
- [19] Duhamel B. Embryology of exomphalos and allied malformations. *Archives of Disease in Childhood*. 1963; **38**(198):142
- [20] Haddock C, Skarsgard ED. Understanding Gastroschisis and its Clinical Management: Where are We? [Internet]. *Expert Review of Gastroenterology & Hepatology*. Vol. 12. Taylor & Francis; 2018. pp. 405-415
- [21] Blechschmidt E. *The Stages of Human Development before Birth: An Introduction to Human Embryology*. Philadelphia: Saunders; 1961
- [22] Ashburn DA, Pranikoff T, Turner CS. Unusual presentations of gastroschisis. *The American Surgeon*. 2002;**68**(8):724
- [23] Fillingham A, Rankin J. Prevalence, prenatal diagnosis and survival of gastroschisis. *Prenatal Diagnosis*. 2008; **28**(13):1232-1237
- [24] Nicholas SS, Stamilio DM, Dicke JM, Gray DL, Macones GA, Odibo AO. Predicting adverse neonatal outcomes in fetuses with abdominal wall defects using prenatal risk factors. *American Journal of Obstetrics and Gynecology*. 2009;**201**(4):383-3e1
- [25] Murphy FL, Mazlan TA, Tarheen F, Corbally MT, Puri P. Gastroschisis and exomphalos in Ireland 1998–2004. Does antenatal diagnosis impact on outcome? *Pediatric Surgery International*. 2007; **23**(11):1059-1063
- [26] Shalaby A, Davenport M. Closed gastroschisis. *Pediatric Surgery International*. 2011;**27**(3):335
- [27] Vegunta RK, Wallace LJ, Leonardi MR, Gross TL, Renfro Y, Marshall JS, et al. Perinatal management of gastroschisis: Analysis of a newly established clinical pathway. *Journal of Pediatric Surgery*. 2005;**40**(3):528-534
- [28] Palomaki GE, Hill LE, Knight GJ, Haddow JE, Carpenter M. Second-trimester maternal serum alpha-fetoprotein levels in pregnancies associated with gastroschisis and omphalocele. *Obstetrics and Gynecology*. 1988;**71**(6 Pt 1):906-909
- [29] Luton D, Guibourdenche J, Vuillard E, Bruner J. Prenatal management of gastroschisis: The place of the amnioexchange procedure. *Clinics in Perinatology*. 2003;**30**(3):551-572
- [30] Reid KP, Dickinson JE, Doherty DA. The epidemiologic incidence of congenital gastroschisis in Western Australia. *American Journal of Obstetrics and Gynecology*. 2003; **189**(3):764-768
- [31] Campbell KH, Copel JA. Gastroschisis. In: *Obstetric Imaging: Fetal Diagnosis and Care*. Second ed. 2018. pp. 78-84
- [32] Hunter A, Soothill P. Gastroschisis —An overview. *Prenatal Diagnosis*. 2002;**22**:869-873
- [33] Abdel-Latif ME, Bolisetty S, Abeywardana S, Lui K. Mode of delivery and neonatal survival of infants with gastroschisis in Australia and New



Zealand. *Journal of Pediatric Surgery*. 2008;**43**(9):1685-1690

[34] Lausman AY, Langer JC, Tai M, Seaward PG, Windrim RC, Kelly EN, et al. Gastroschisis: What is the average gestational age of spontaneous delivery? *Journal of Pediatric Surgery*. 2007; **42**(11):1816-1821

[35] Cohen-Overbeek TE, Hatzmann TR, Steegers EA, Hop WC, Wladimiroff JW, Tibboel D. The outcome of gastroschisis after a prenatal diagnosis or a diagnosis only at birth: Recommendations for prenatal surveillance. *European Journal of Obstetrics & Gynecology and Reproductive Biology*. 2008;**139**(1): 21-27

[36] Moir CR, Ramsey PS, Ogburn PL, Johnson RV, Ramin KD. A prospective trial of elective preterm delivery for fetal gastroschisis. *American Journal of Perinatology*. 2004;**21**(05):289-294

[37] Mozurkewich E, Chilimigras J, Koepke E, Keeton K, King VJ. Indications for induction of labour: A best-evidence review. *BJOG: An International Journal of Obstetrics & Gynaecology*. 2009;**116**(5):626-636

[38] Murray CJ, Vos T, Lozano R, Naghavi M, Flaxman AD, Michaud C, et al. Disability-adjusted life years (DALYs) for 291 diseases and injuries in 21 regions, 1990–2010: A systematic analysis for the global burden of disease study 2010. *The Lancet*. 2012; **380**(9859):2197-2223

[39] Black RE, Cousens S, Johnson HL, et al. Global, regional, and national causes of child mortality in 2008: A systematic analysis. *Lancet*. 2010;**375**: 1969-1987

[40] Rosano A, Botto LD, Botting B, Mastroiacovo P. Infant mortality and congenital anomalies from 1950 to 1994: An international perspective. *Journal of*

*Epidemiology & Community Health*. 2000;**54**(9):660-666

[41] Ameh EA, Chirdan LB. Paediatric surgery in the rural setting: Prospect and feasibility. *West African Journal of Medicine*. 2001;**20**(1):52-55

[42] Bickler SW, Kyambi J, Rode H. Pediatric surgery in sub-Saharan Africa. *Pediatric Surgery International*. 2001;**17** (5–6):442-447

[43] Badrinath R, Kakembo N, Kisa P, Langer M, Ozgediz D, Sekabira J. Outcomes and unmet need for neonatal surgery in a resource-limited environment: Estimates of global health disparities from Kampala, Uganda. *Journal of Pediatric Surgery*. 2014; **49**(12):1825-1830

[44] Galukande M, Luboga S, Kijjambu SC. Improving recruitment of surgical trainees and training of surgeons in Uganda. *East and Central African Journal of Surgery*. 2006;**11**(1):17-24

[45] Arnold M. Is the incidence of gastroschisis rising in South Africa in accordance with international trends?— A retrospective analysis at Pretoria academic and Kalafong hospitals, 1981-2001. *South African Journal of Surgery*. 2004;**42**(3):86-88

[46] Ameh EA, Chirdan LB. Ruptured exomphalos and gastroschisis: A retrospective analysis of morbidity and mortality in Nigerian children. *Pediatric Surgery International*. 2000;**16**(1–2): 23-25

[47] Vilela PC, de Amorim MM, Falbo GH, Santos LC. Risk factors for adverse outcome of newborns with gastroschisis in a Brazilian hospital. *Journal of Pediatric Surgery*. 2001;**36**(4):559-564

[48] Askarpour S, Ostadian N, Javaherizadeh H, Chabi S. Omphalocele, gastroschisis: Epidemiology, survival, and mortality in imam Khomeini

hospital, Ahvaz-Iran. Polish Journal of Surgery. 2012;**84**(2):82-85. DOI: <https://doi.org/10.2478/v10035-012-0013-4>

[49] Driver CP, Bruce J, Bianchi A, Doig CM, Dickson AP, Bowen J. The contemporary outcome of gastroschisis. Journal of Pediatric Surgery. 2000; **35**(12):1719-1723

[50] Ford K, Poenaru D, Moulot O, Tavener K, Bradley S, Bankole R, et al. Gastroschisis: Bellwether for neonatal surgery capacity in low resource settings? Journal of Pediatric Surgery. 2016;**51**(8):1262-1267

[51] Stevens P, Muller E, Becker P. Gastroschisis in a developing country: Poor resuscitation is a more significant predictor of mortality than postnatal transfer time. South African Journal of Surgery. 2016;**54**(1):4-9

[52] Abou-Zahr C, Wardlaw T. Antenatal Care in Developing Countries. Promises, Achievements and Missed Opportunities: An Analysis of Trends, Levels and Differentials 1990-2001. Geneva: World Health Organization, UN Children's Fund; 2003

[53] Harrison DS. Factors associated with mortality among neonates presenting with gastroschisis in Zimbabwe. South African Journal of Surgery. 2006;**44**(4): 157

[54] Kitchanan S, Patole SK, Muller R, Whitehall JS. Neonatal outcome of gastroschisis and exomphalos: A 10-year review. Journal of Paediatrics and Child Health. 2000;**36**(5):428-430

[55] Marven S, Owen A. Contemporary postnatal surgical management strategies for congenital abdominal wall defects. Seminars in Pediatric Surgery. 2008;**17**(4):222-235

[56] Witt RG, Zobel M, Padilla B, Lee H, MacKenzie TC, Vu L. Evaluation of clinical outcomes of sutureless vs

sutured closure techniques in gastroschisis repair. Journal of the American Medical Association surgery. 2019;**154**(1):33-39

[57] Tullie LG, Bough GM, Shalaby A, Kiely EM, Curry JI, Pierro A, et al. Umbilical hernia following gastroschisis closure: A common event? Pediatric Surgery International. 2016;**32**(8): 811-814

[58] Charlesworth P, Akinola I, Hammerton C, Praveena P, Desai A, Patel S, et al. Preformed silos versus traditional abdominal wall closure in gastroschisis: 163 infants at a single institution. European Journal of Pediatric Surgery. 2014;**24**(01): 088-093

[59] Bustorff-Silva JM, Schmidt AF, Gonçalves A, Marba S, Sbragia L. The female condom as a temporary silo: A simple and inexpensive tool in the initial management of the newborn with gastroschisis. The Journal of Maternal-Fetal & Neonatal Medicine. 2008;**21**(9): 648-651

[60] Kusafuka J, Yamataka A, Okazaki T, Okawada M, Urao M, Lane GJ, et al. Gastroschisis reduction using "applied Alexis", a wound protector and retractor. Pediatric Surgery International. 2005;**21**(11):925-927

[61] Perrone EE, Olson J, Golden JM, Besner GE, Gayer CP, Islam S, et al. Closing gastroschisis: The good, the bad, and the not-so ugly. Journal of Pediatric Surgery. 1 Jan 2019;**54**(1):60-64

[62] Emil S. Surgical strategies in complex gastroschisis. Seminars in Pediatric Surgery. 2018;**27**(5):309-315

[63] Jayanthi S, Seymour P, Puntis JW, Stringer MD. Necrotizing enterocolitis after gastroschisis repair: A preventable complication?. Journal of Pediatric Surgery. 1 May 1998;**33**(5):705-707

- [64] Aljahdali A, Mohajerani N, Skarsgard ED. Effect of timing of enteral feeding on outcome in gastroschisis. *Journal of Pediatric Surgery*. 1 May 2013;**48**(5):971-976
- [65] Jansen LA, Safavi A, Lin Y, MacNab YC, Skarsgard ED. Preclosure fluid resuscitation influences outcome in gastroschisis. *American Journal of Perinatology*. 2012;**29**(04):307-312
- [66] Gamba P, Midrio P. Abdominal wall defects: Prenatal diagnosis, newborn management, and long-term outcomes. *Seminars in Pediatric Surgery*. 2014; **23**(5):283-290
- [67] Ledbetter DJ. Gastroschisis and omphalocele. *Surgical Clinics*. 2006; **86**(2):249-260
- [68] Cooney DR. Defects of the abdominal wall. In: O'Neill JA, Rowe MI, Grosfeld JL, et al., editors. *Pediatric Surgery*. 5th ed. Vol. 1045. St Louis: Mosby; 1998
- [69] Philippart AI, Canty TG, Filler RM. Acute fluid volume requirements in infants with anterior abdominal wall defects. *Journal of Pediatric Surgery*. 1972;**7**(5):553-558
- [70] Ewer AK, Tyler W, Francis A, Drinkall D, Gardosi JO. Excessive volume expansion and neonatal death in preterm infants born at 27–28 weeks gestation. *Paediatric and Perinatal Epidemiology*. 2003;**17**(2):180-186
- [71] Arikian AA, Zappitelli M, Goldstein SL, Naipaul A, Jefferson LS, Loftis LL. Fluid overload is associated with impaired oxygenation and morbidity in critically ill children. *Pediatric Critical Care Medicine*. 2012;**13**(3):253-258
- [72] Willson DF, Thomas NJ, Tamburro R, Truemper E, Truwit J, Conaway M, et al. The relationship of fluid administration to outcome in the pediatric calfactant in acute respiratory distress syndrome trial. *Pediatric Critical Care Medicine*. 2013;**14**(7): 666-672
- [73] Bell EF, Acarregui MJ. Restricted versus liberal water intake for preventing morbidity and mortality in preterm infants. *Cochrane Database of Systematic Reviews*. 2014;**12**. Artical ID: CD000503
- [74] Oldham KT, Coran AG, Drongowski RA, Baker PJ, Wesley JR, Polley TZ. The development of necrotizing enterocolitis following repair of gastroschisis: A suprisingly high incidence. *Journal of Pediatric Surgery*. 1988;**23**(10):945-949
- [75] Bonasso PC, Lucke-Wold B, Hobbs GR, Vaughan RA, Shorter NA, Nakayama DK. Excessive postoperative fluid administration in infants with gastroschisis. *The American Surgeon*. 2016;**82**(8):704-706
- [76] AL-Khafaji A, Webb AR. Should albumin be used to correct hypoalbuminemia in the critically ill? No. *Transfusion Alternatives in Transfusion Medicine*. 2003;**5**(4): 392-396
- [77] Vincent JL, Russell JA, Jacob M, Martin G, Guidet B, Wernerman J, et al. Albumin administration in the acutely ill: What is new and where next? *Critical Care*. 2014;**18**(4):231
- [78] Puffinbarger NK, Taylor DV, Tuggle DW, Tunell WP. End-tidal carbon dioxide for monitoring primary closure of gastroschisis. *Journal of Pediatric Surgery*. 1996;**31**(2):280-282
- [79] Olesevich M, Alexander F, Khan M, Cotman K. Gastroschisis revisited: Role of intraoperative measurement of abdominal pressure. *Journal of Pediatric Surgery*. 2005;**40**(5):789-792
- [80] Banieghbal B, Gouws M, Davies MR. Respiratory pressure monitoring as

an indirect method of intra-abdominal pressure measurement in gastroschisis closure. *European Journal of Pediatric Surgery*. 2006;**16**(02):79-83

[81] Hong CM, Patel A. Novel intra-operative pulse oximetry monitoring for gastroschisis: A noninvasive monitor of intra-abdominal pressure. *Pediatric Anesthesia*. 2008;**18**(4):344-345

[82] Watkinson M, Tiron I. Events before the diagnosis of a pneumothorax in ventilated neonates. *Archives of Disease in Childhood-Fetal and Neonatal Edition*. 2001;**85**(3):F201-F203

[83] Snyder CL. Outcome analysis for gastroschisis. *Journal of Pediatric Surgery*. 1999;**34**(8):1253-1256

[84] Gupta R, Cabacungan ET. Outcome of neonates with gastroschisis at different gestational ages using a national database. *Journal of Pediatric Surgery*. 2018;**53**(4):661-665

[85] Svetanoff WJ, Zendejas B, Demehri FR, Cuenca A, Nath B, Smithers CJ. Giant gastroschisis with complete liver herniation: A case report of two patients. *Case Reports in Surgery*. 2019; **2019**:8. Article ID: 4136214. <https://doi.org/10.1155/2019/4136214>

[86] Waldhausen JH. Surgical management of gastroschisis. *NeoReviews*. 2005;**6**(11):e500-e507