

We are IntechOpen, the world's leading publisher of Open Access books Built by scientists, for scientists

4,800

Open access books available

122,000

International authors and editors

135M

Downloads

Our authors are among the

154

Countries delivered to

TOP 1%

most cited scientists

12.2%

Contributors from top 500 universities



WEB OF SCIENCE™

Selection of our books indexed in the Book Citation Index
in Web of Science™ Core Collection (BKCI)

Interested in publishing with us?
Contact book.department@intechopen.com

Numbers displayed above are based on latest data collected.
For more information visit www.intechopen.com



The Cerebellum and Autism: More than Motor Control

*Marta Fernández, Teresa Sierra-Arregui
and Olga Peñagarikano*

Abstract

Autism spectrum disorder is a neurodevelopmental disorder characterized by deficits in social cognition at its core. Human and animal studies converge in the existence of a network of key brain structures involved in the perception, integration, and coding of social cues. These structures mainly involve areas traditionally associated with cognitive function, such as the prefrontal cortex; processing of emotions, such as the amygdala; and motivation and reward, such as the nucleus accumbens. The cerebellum, conventionally associated with motor functions, is lately being considered as a key structure within the social circuitry. Cerebellar neuroanatomical alterations are among the most replicated findings in postmortem brain samples of patients with autism. In addition, cerebellar defects have been proposed to affect the functioning of distal brain areas to which the cerebellum projects. In fact, animal studies support the inclusion of the cerebellum as part of the brain network regulating social cognition and provide a mechanistic tool to study its function within the social network. In this chapter, we review current evidence from human and animal studies, opening a new avenue for further research.

Keywords: autism, social behavior, neural circuit, cerebellum, dopamine, VTA, NAcc, animal model

1. Introduction

Autism spectrum disorder (ASD) represents a group of heterogeneous neurodevelopmental conditions characterized by deficits in social cognition, together with the presence of restricted and/or repetitive patterns of behaviors, activities, or interests [1]. Social cognition refers to those cognitive processes that allow individuals to successfully navigate the challenges of living in a social group. Thus, a functional social cognitive system involves the integration of several domains of behavior including attention, memory, emotion, and motivation to be able to understand identity, potential actions, social hierarchy, and emotional status of a conspecific and therefore guide the appropriate behavioral response [2]. In autism, deficits in social cognition processes are found at multiple levels, such as failure to initiate or respond to social interactions, lack of interest in social situations, abnormal social approach, difficulties expressing and understanding verbal and nonverbal communication (i.e., body language and facial expressions), and problems adjusting behavior to different social situations, among others [1]. Autism affects roughly 1 in 59 children, becoming one of the primary mental health issues

worldwide [3]. In addition to the main symptoms, ASD is usually associated with other behavioral and/or neurological problems, such as hyperactivity, epilepsy, aggression, irritability, sleep problems, gastrointestinal symptoms, and sensory processing abnormalities [4].

Although currently accepted to be highly genetic (over 90% of the risk of developing ASD is due to genetic variation) [5], the etiology of ASD is complex, and its genetic architecture is diverse. Common allelic variation with small effect sizes is responsible for most cases, while rare but highly penetrant mutations that usually lead to other syndromes associated with autism are observed in about 20% of the cases [6]. In addition to genetic factors, exposition to some environmental factors during prenatal periods has also been associated with autism. Some of the most replicated are the intake of valproic acid, a drug used to treat epilepsy, during pregnancy and maternal infections. In all, the combination of interactions between genetic predisposition and environmental factors will determine the development of the disorder [7]. Given the clinical and etiological heterogeneity of ASD, the investigation of its pathophysiology has been challenging. From a research point of view, the study of “single gene” causes of autism, although rare in the population, has been proven to be useful to understand its pathophysiology and develop targeted treatments. In addition, animal models of monogenic causes of autism are easily generated and constitute a critical component of research. Research from both human and animal studies converge in a series of key brain structures and circuits involved in social cognition and their dysfunction in autism. Within these circuits, the cerebellum, traditionally associated with movement control, is becoming an important player in the social brain network. In this chapter, we will first start by describing the social brain circuitry traditionally thought to be affected in autism; we will then present evidence for the role of the cerebellum as a new player in the social circuitry and its role in the pathophysiology of ASD; finally, we will present data from animal models of monogenic causes of ASD in which a cerebellar pathology has been described such as Fragile X syndrome (*FMR1*), tuberous sclerosis syndrome (*TSC1/TSC2*), and Phelan-McDermid syndrome (*SHANK3*), supporting the role of the cerebellum in social defects. In all, we believe the current evidence grants the need of further research of the cerebellar role in ASD pathophysiology.

2. Neural circuits involved in social cognition

In humans, brain regions implicated in social cognition have been identified mainly by lesion studies or by functional magnetic resonance imaging (fMRI) detecting differential activation in response to social versus nonsocial cues. Accordingly, a network of key brain structures involved in the perception, integration, and coding of social cues have been identified, receiving the denomination of “the social brain.” These structures comprise brain areas traditionally involved in *cognitive processes*, such as frontal and temporal cortices; *motivation and reward*, such as the basal ganglia; and *processing of emotions*, such as the amygdala [8–10]. Proper function of the social brain should be considered in terms of the coordinated activity of the neural network involving these structures [11]. Accordingly, individuals with autism have been reported to present structural and/or functional alterations in these areas. Aberrant cortical organization is a pathological observation commonly seen in postmortem brain tissue of individuals with ASD [12]. Connectivity studies using fMRI indicate alterations in the PFC, with increased local and decreased long-range connectivity [13], which might be accounted for by the observed disorganized cortical structure. Structural MRI studies report

increased amygdala size in children with autism, and the extent of amygdala enlargement is correlated with social deficits [14]. However, fMRI studies conversely report both hyperactivation [15] and hypoactivation [8] of the amygdala in response to social stimuli. These contrasting results have been suggested to indicate either a failure of the amygdala to engage upon social stimuli or, alternatively, an overreaction to such stimuli, coding them as threatening. Both cases would in turn result in social withdrawal. Similar contrasting results have been found when studying the reward system in ASD, as some studies observe a generalized decreased activation of the NAcc independent of stimuli [16], and others indicate that the hypoactivation is stimulus-dependent as individuals with ASD react to cues that are salient to them but not necessarily to neurotypical individuals [17], indicating that in autism a different set of cues might be coded as salient.

The cerebellum, conventionally associated with motor functions, is lately being considered a key structure within the social circuitry [18]. In fact, cerebellar neuroanatomical alterations, including the reduced size and number of Purkinje cells, are among the most replicated findings in postmortem brain samples of individuals with autism [19]. In addition, cerebellar defects have been proposed to affect the functioning of distal brain areas to which the cerebellum projects [20]. For example, the PFC long-range connection deficits observed in ASD mentioned above include the cerebellum [13]. The *developmental disconnection hypothesis* of autism suggests that certain areas of the brain that normally connect to the frontal lobe become disconnected during development. Thus, a change in connectivity in a certain area could affect the functioning of other brain regions either through compensation or adaptation of nearby circuitries [21]. Along these lines, deficits in connectivity of the cerebellum could account for dysfunction in connected areas, being possible to affect some of the social brain structures previously mentioned.

Although human neuroanatomical and functional studies have been very useful in the identification of the brain regions involved in social cognition, animal studies are critical to understand how information is processed at the circuit and molecular level, from the perception of the stimulus to the expression of a behavioral response. The mouse (*Mus musculus*) is currently the most widely studied, mainly for practical reasons and technical amenability. In addition, as mammals, mice present the same key brain structures and express a wide range of social behaviors that can be easily measured in the lab [22]. A schematic representation of the brain structures and circuits implicated in social cognition processes in rodents is presented in **Figure 1**. Animal studies have corroborated the role of previously described structures in social behavior and have given insight into circuit function. For example, disruption of the ratio between cortical excitation and inhibition (E/I) has been extensively hypothesized to be a causal mechanism in autism [23]. Again, one must consider that the cortical E/I balance is a complex process controlled both locally and distally by neuromodulation from connecting circuits, arguing against the specificity of a certain structure as preferentially involved in ASD since alterations in distally connected regions could also lead to an altered cortical E/I ratio. Nevertheless, in 2011, the application of the recently developed optogenetic techniques allowed to test for the first time this hypothesis in vivo [24]. The authors found that increasing, but not reducing, the E/I balance in the PFC would lead to social dysfunction in mice. Similarly, recent studies have indicated the role of the reward system and, specifically, dopaminergic projections from the ventral tegmental area to the NAcc, in the modulation of social interaction. Dopamine (DA) is a neurotransmitter traditionally linked to movement control and reward processing, including social reward and domains of behavior that are modulated by two separated DA pathways. DA-producing neurons are located in two main brain areas, the ventral tegmental area (VTA) and the substantia nigra (SN). The *nigrostriatal pathway* originates in the

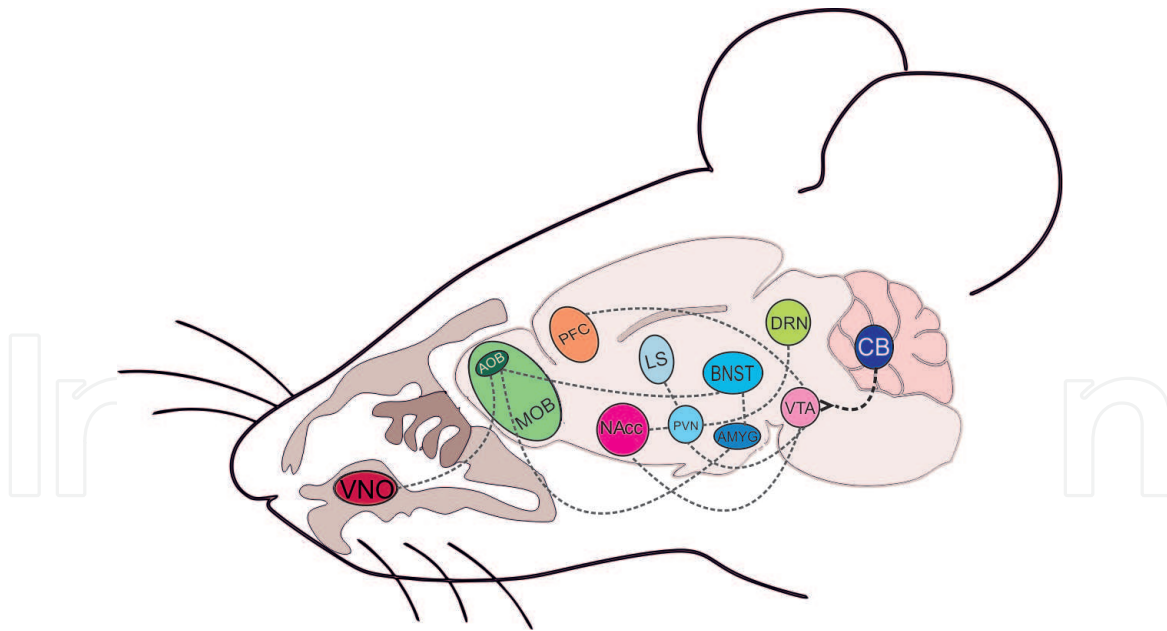


Figure 1.

Brain circuits linked to social cognition in mice. Olfactory signals from a social stimulus are perceived through the olfactory bulb and transferred to the amygdala (AMYG) and probably other structures to be processed. This social cue will modulate the activity of several structures. One of such, the ventral tegmental area (VTA), mainly composed of dopaminergic neurons, projects to the PFC (executive function) and NAcc (reward system). Of note, the cerebellum modulates VTA activity implying a role in social behavior and reward. Adapted from [28].

SN and projects to the striatum, modulating movement; and the *mesocorticolimbic pathway*, involved in cognitive processes including social cognition, originates in the VTA and is further subdivided into two pathways: the *mesocortical pathway*, which projects to the cortex, and the *mesolimbic pathway* which projects to limbic areas such as the NAcc [25]. Recently, it has been found that in mice, optogenetic stimulation of dopaminergic VTA-NAcc projections increased, while inhibition decreased during the time the animals were engaged in social exploration [26]. Interestingly, very recently Carta et al. [27] have demonstrated the role of the cerebellum in modulation of the reward pathway through direct control of the activity of the VTA, which could have profound implications for social behavior. The authors found that the cerebellum sends excitatory projections to the VTA and that optogenetic modulation of the cerebellum-VTA pathway bidirectionally modulated social behavior and reward. Considering previous studies where stimulation of VTA-NAcc DA projections modulates social behavior, it is highly likely that the cerebellum indirectly controls the activity of these projections. A cartoon deciphering the main brain structures and connections involved in social cognition in mice is presented in **Figure 1**.

3. The cerebellum

The cerebellum (Latin, *little brain*) is located in the posterior cranial fossa. Classically, the cerebellum has been linked to motor behaviors; however, more recent studies provide evidence for a role of the cerebellum in higher functions such as cognition, language, and social and affective behaviors [18].

3.1 Cerebellar anatomy

Structurally, the cerebellum is constituted of ten lobules: lobules I through V (which form the anterior lobe), lobules VI through IX (posterior lobe), and lobule X (flocculonodular lobe). Lobules VII and VIII are further subdivided (VIIA and VIIB

and VIIIA and VIIIB); besides, the hemispheric extension of lobe VIIA is expanded and forms two major lobules, Crus I and Crus II. Dividing the cerebellum ventrally into two hemispheres, there is a central midline called the vermis (**Figure 2**) [20]. Within this anatomical division, a functional division according to the connection of each lobe can be found, establishing a topographic organization (see Subsection 3.2).

At the cellular level, the cerebellum is composed of an outer cortex constituted of gray matter, the cerebellar cortex, and an inner core formed mainly by white matter which encloses the deep cerebellar nuclei, the sole output channel of the cerebellum (see below). The cerebellar cortex is structured in three different cell layers: (1) *Molecular layer*: it is the outer layer, and it is composed of two types of cells, basket, and stellate neurons. Both are inhibitory and are part of the regulatory system of Purkinje cells. (2) *Purkinje cell layer*: it is located below the molecular layer. The Purkinje cells (PCs) represent the only output from the cerebellar cortex and are inhibitory. These neurons have a wide dendritic arbor, which extends to the top of the surface of the molecular layer, and project their axons to the deep cerebellar neurons in the inner cerebellar core, which are the only output of the cerebellum. (3) *Granular layer*: it is the deepest layer of the cerebellar cortex, and it is composed of excitatory granule cells which send their axons toward the molecular layer, forming the parallel fibers and making contacts with dendrites of PC. Granule neurons together with basket and stellate cells in the molecular layer constitute the main regulatory system of PC. Inhibitory interneurons—Golgi cells—are also found within the granular layer and act by altering the mossy fiber-granule cell synapse (see below). The Golgi cells receive input from the parallel fibers and provide an inhibitory feedback to the cells of origin of the parallel fibers (the granule cells).

Neurons in the deep cerebellar nuclei represent virtually all the output from the cerebellum. They receive inhibitory information from the PC and excitatory inputs from outside the cerebellum through the mossy and climbing fibers. The *climbing fibers* are originated in the brain stem (posterior part of the brain, continuous to the spinal cord, composed by the midbrain, the pons, and the medulla oblongata), particularly in the inferior olivary nucleus of the medulla oblongata. These axons

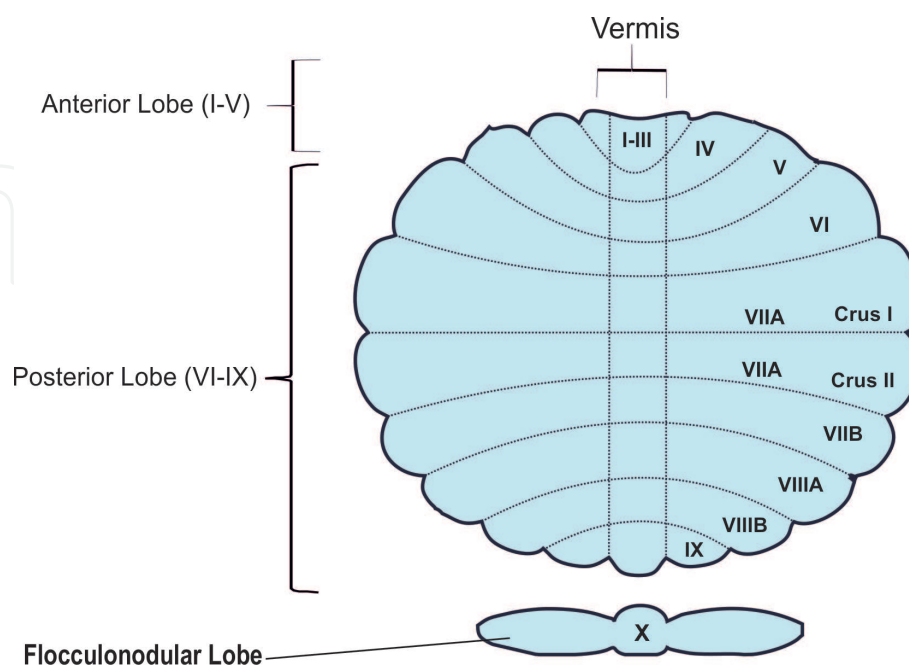


Figure 2. Structural anatomy of the human cerebellum. Representation of the cerebellar lobules: anterior, posterior, and flocculonodular and their subdivisions. Lobules VII and VIII are further subdivided into lobules A and B. Crus I/Crus II constitutes further subdivisions of lobule VIIA. The vermis represents a midline separating the cerebellum in two hemispheres. Modified from [20].

make excitatory synapses with PC dendrites and with neurons in the deep cerebellar nuclei. The *mossy fibers* originate from several parts of the brain and spinal cord. These fibers form excitatory synapses with granule cells and with neurons of deep cerebellar nuclei. In turn, PCs receive two types of excitatory input from outside the cerebellum, one directly from the climbing fibers and the other indirectly via the parallel fibers of the granule cells (**Figure 3**) [29]. Anatomical investigations in animals and postmortem humans have established that cerebro-cerebellar connections are contralateral to each other and include an efferent cerebello-cortical pathway from the cerebellar nuclei to the cerebral cortex through the thalamus and an afferent cortico-cerebellar pathway through the pons.

3.2 Cerebellum connections and topography

The cerebellum has a unique topographic organization such as each region is attributed with a separate function based on their specific connectivity. Thus, the anterior lobe and lobule VIII contain the representation of the sensorimotor cerebellum; lobules VI and VII (including Crus I/Crus II and lobule VIIB) of the posterior lobe comprise the cognitive cerebellum; and the posterior vermis encompasses the limbic cerebellum. Dysfunction in the connection of these cerebellar areas with the spinal cord or cerebral regions will result in alterations in movement or cognitive functions, respectively [30, 31]. More specifically, the cerebellum has been proposed to have an important role in language by means of its connections with cortical areas implicated in this process. Studies using viral tracing in nonhuman primates report

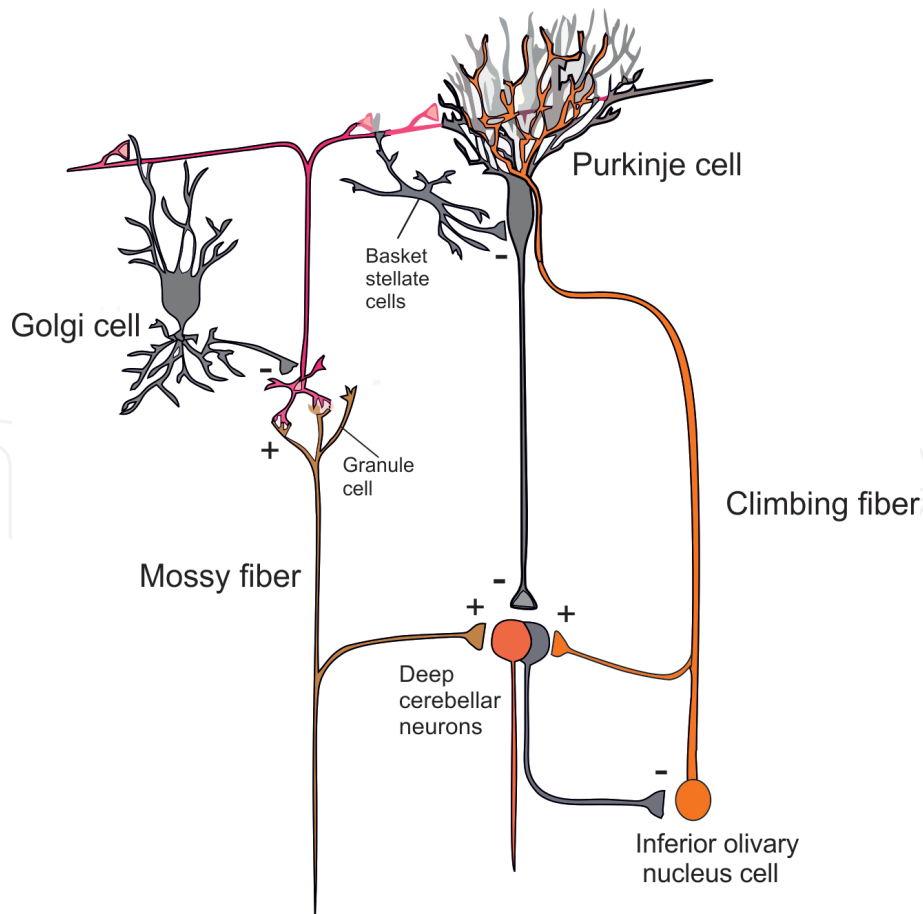


Figure 3. Main cerebellar circuits. The mossy and climbing fibers carry the input information toward the cerebellum. The PC transmit the information to the deep cerebellar nuclei, which are the cerebellar output. The interactions between the cells are represented with (+) in case of excitatory connections and (-) when connections are inhibitory. Modified from [29].

the existence of strong connections between right Crus I/Crus II and different cortical regions implicated in language, such as Brodmann's area BA46 in the PFC [32]. In fact, dysfunction in cerebellar-prefrontal loops might underlie poorer performance on measures of language-related executive function in human patients with cerebellar abnormalities [33]. The cerebellum also seems to play a role in several social and affective processes. For example, imitation is a critical skill for implicit learning of social rules, and fMRI studies in humans show that during a task that involves observation and imitation of an action performed by a human model, activation of the Crus I/Crus II regions in the posterior cerebellum is increased [34]. Also, during a passive viewing paradigm, a stronger activation in the posterior cerebellum (lobules VI, VII, and X) has been found when comparing social versus nonsocial stimuli [35]. In fact, a recent meta-analysis of over 350 fMRI studies exploring the role of the cerebellum in social cognition supports that it plays a crucial role in several social paradigms such as mirroring (i.e., observation of human motion) and mentalizing (i.e., interpreting other people's thoughts and intentions) [36, 37].

4. Evidence that the cerebellum is involved in ASD

In the recent years, there has been increasing evidence showing a crucial role for the cerebellum in the etiology of ASD [38–40]. Although the field of cerebellar research in disorders of social cognition such as autism is still in its early stages, below we will describe the main structural and functional cerebellar abnormalities that have been described to date in autism, which provide strong evidence to grant further research.

4.1 Structural cerebellar abnormalities found in autism

The cerebellum is actually one of the most consistent sites of neural abnormalities found in autism [41]. Specifically, the reduced size and number of PCs are among the most replicated findings in postmortem brain tissue of individuals with autism [19]. This reduction in PC in autism patients has been found to be more pronounced in the Crus I/Crus II region of lobule VIIA [42]. Accordingly, a reduction in gray matter volume, smaller ratio of gray to white matter, and smaller vermis lobules VI–VII have been found in children with autism compared to controls [43, 44]. Further, in ASD patients, the degree of reduction in gray matter of Crus I/Crus II has been repeatedly found to correlate with the severity of symptoms in the social interaction and communication behavioral domains of ASD [39, 45]. Of note, some reports using adult brains indicate the presence of gliosis as an accompanying factor to the reduction of PC [46]. Other observed cerebellar cellular abnormalities are the presence of neuro-inflammatory processes [47].

Besides structural and cellular alterations, molecular abnormalities have also been reported in the cerebellum of ASD individuals. Alterations in the distribution of the mRNA levels of glutamic acid decarboxylase 67 (GAD67), an enzyme involved in the synthesis of the inhibitory neurotransmitter GABA, have been found. Thus, decreased GAD67 mRNA has been reported in PC [48], while increased GAD67 mRNA has been reported in cerebellar interneurons [49]. These cerebellar imbalances could account for the proposed E/I disequilibrium in ASD, as they could affect cerebro-cerebellar circuits [50].

4.2 Abnormalities of cerebellar function

Studies in humans using resting-state functional connectivity (rsFC) techniques have reported connectivity alterations between cerebellar and cortical areas in

autism compared to typically developing individuals. Overall, a general cerebro-cerebellar over-connectivity has been found in the ASD group. However, both hyper-connectivity and hypo-connectivity have been reported depending on the regions analyzed. For example, cerebellar-sensorimotor FC (premotor and primary motor cortices, somatosensory temporal cortex, and occipital lobe) has been found to be atypically increased in ASD, while cerebellar-supramodal FC (prefrontal cortex, posterior parietal cortex, and inferior and middle temporal gyri) has been found to be decreased [51]. Analysis of cerebellar FC with language-related areas revealed a significantly reduced FC in ASD between the cerebellum and Broca's area and Wernicke's area [52], suggesting that the cerebellum plays a role in language functioning. Studies aiming at assessing the developmental pattern of cerebello-cerebral FC also report developmental alterations in ASD. FC between the cerebellum and subcortical regions was found to decrease in neurotypical individuals, while it increased in ASD [53]. It must be noted that no specific correlation between FC patterns and autism behavior has been detected, although reduced connectivity seems to be accompanied by an increase in the severity of the disorder [52], as assessed by the Social Communication Questionnaire, an ASD screening measure consisting of a brief (40-item) parent report that focuses on ASD symptomatology likely to be observed by a primary caregiver.

Few studies have investigated to date the FC between the cerebellum and cortical areas during task performance in ASD. During a sequential finger-tapping task, activations in motor circuits were found in both cases and controls. However, children with typical development showed activation of cerebellar structures that were silent in autistic children (lobules IV/V and anterior cerebellum). In addition, a reduced FC between premotor areas and the cerebellum was observed in autistic children, suggesting alterations in long-range cerebro-cerebellar connections [54]. In a task that requires perception and imitation of human actions, fMRI detected an engagement between the posterior superior temporal sulcus (pSTS) and the cerebellar region Crus I [55]. Interestingly, the degree of functional coactivation of pSTS and Crus I could predict social deficits in ASD in the "mentalizing skills" questionnaire, a parent report for specific social cognition skills based on imaginative mental activity that allows an understanding of the behavior of other people (intentions, needs, desires, or goals). Thus, stronger Crus I-pSTS interactions were associated with better mentalizing ability [55]. On a similar note, during a task that involves decoding the interactions between animated figures, aimed at examining the "theory of mind" network, that is, the ability to attribute mental states to others, a reduced cerebellar activation, particularly in Crus I, in participants with ASD was found [56]. Although many more studies are needed, overall the above-presented data indicate a role for cerebellar connections with key cortical social brain sites and, specifically for region Crus I/Crus II, in the pathogenesis of ASD.

5. Evidence from monogenic forms of ASD

The clinical and genetic heterogeneity present in ASD has made the study of the pathophysiology of the disease challenging. The study of genetically defined autism, as in the case of monogenic forms of ASD, which show a relatively homogeneous and well-characterized clinical manifestation, allows us to understand cellular and molecular mechanisms relevant to the disease. Although monogenic causes of ASD are often syndromic and not all patients with the syndrome show autistic features, by studying patients with and without ASD, we can start deciphering the pathomechanisms that lead to the disorder. As shown below, human post-mortem and brain imaging studies of syndromic forms of ASD support the role of

the cerebellum in the pathophysiology of the disease. Animal models of monogenic autism are easily generated and provide opportunities for direct manipulation of these brain regions and circuits to test their precise functions in social behavior paradigms. We will describe below the main syndromes with reported cerebellar dysfunction and supporting data from animal models (**Table 1**). In all, human and animal data point out a role for the cerebellum in social deficits in ASD.

5.1 Fragile X syndrome (FMR1 gene)

Fragile X syndrome (FXS) is the most common form of inherited intellectual disability, and ~30% of FXS patients are also diagnosed with ASD. FXS is considered also as the most common genetic cause of ASD, representing around 3% of ASD individuals. FXS arises from loss of function mutations in the X-linked FMR1 gene, which result in either total absence or functional inactivation of the encoded protein (FMRP), an mRNA-binding protein involved in translational regulation [65]. Although FXS affects many brain regions, cerebellar PC loss and cell displacement, as seen in idiopathic autism, have been reported in human postmortem studies of FXS [66]. Interestingly, imaging studies have identified specific abnormalities in the posterior cerebellar vermis (lobules VI–VII) in FXS patients with ASD that are not seen in FXS patients without comorbid ASD diagnosis. Further, these

Mouse model	Structural abnormalities	Functional abnormalities	Refs.
Fmr1 KO	<ul style="list-style-type: none"> • Decreased deep nuclei volume • Reduced number of neurons in deep nuclei • Increased astrocytes in deep nuclei • Reduced volume of cerebellar cortex • Reduced cerebellar volume during development • Elongated spines in PC 	<ul style="list-style-type: none"> • Deficits in eyeblink conditioning • Altered parallel fibers-PC synapses 	[57–60]
Fmr1-PC cKO	<ul style="list-style-type: none"> • Reduced cerebellar volume • Cellular loss deep nuclei • Elongated spines in PC 	<ul style="list-style-type: none"> • Deficits in eyeblink conditioning • Altered parallel fibers-PC synapses 	[60]
TSC1-PC cKO +/-	<ul style="list-style-type: none"> • Abnormal spine density • Neurodegeneration of PC 	<ul style="list-style-type: none"> • Decreased PC excitability • Deficits in eyeblink conditioning 	[61, 62]
TSC1-PC cKO -/-	<ul style="list-style-type: none"> • Neurodegeneration of PC starting at 2 months 	<ul style="list-style-type: none"> • Decreased PC excitability • Deficits in eyeblink conditioning 	[61, 62]
TSC2-PC cKO +/-	<ul style="list-style-type: none"> • Increased size of PC and apoptosis 	N/A	[63]
SHANK2 KO	N/A	<ul style="list-style-type: none"> • Decreased PC plasticity • Altered parallel fibers-PC synapses 	[64]
SHANK3 ΔC	<ul style="list-style-type: none"> • Decreased density of PC • Lower spine density in PC • Reduced complexity of dendritic tree in PC 	<ul style="list-style-type: none"> • Deficits in eyeblink conditioning 	[62]

Table 1.
Cerebellar abnormalities in mouse models of ASD.

lobules are also abnormal in non-syndromic ASD [57]. Moreover, positive correlations between the size of the posterior vermis and several subscales of the autism behavior checklist, a list of nonadaptive behaviors that represent an individual's challenges to respond appropriately to daily life situations, in persons with FXS, have been reported [58]. On a different note, recent postmortem work has shown reductions in FMRP in cerebella and frontal cortices of subjects with autism who do not carry a mutation for FXS [59].

The *Fmr1* knockout (KO) mouse is a validated and widely studied animal model of ASD. By means of high-resolution MRI imaging to study brain structure, the cerebellum in *Fmr1* KO mice was found to show significant volume alterations comparing with wild-type controls. Specifically, the deep cerebellar nuclei, which transfer the output of the cerebellar cortex to the thalamus and cerebral cortex, were smaller in *Fmr1* mice. Moreover, this reduced volume was accompanied by loss of neurons and increase in astrocytes, as measured by immunohistochemical techniques [60]. Later, the same authors also identified a volume reduction in the cerebellar cortex in these mice [67]. Further, a detailed study by diffusion tensor imaging of postnatal development in the *Fmr1* KO mouse showed reduced cerebellar volume in the first few weeks after birth [68]. In addition to the full KO, a conditional *Fmr1* KO mouse (*Fmr1* cKO) has also been generated. Deletion of *Fmr1* specifically in PC leads to several structural and functional abnormalities in the cerebellum also seen in the full *Fmr1* KO, such as a reduction of cerebellar volume, cellular loss in the cerebellar nuclei, and longer spines in PC. Functionally, an enhanced LTD induction at the parallel fiber synapses that innervate these spines is seen [63]. In addition, both *Fmr1* KO and PC-*Fmr1* cKO mice present alterations in classical delay eyeblink conditioning, a Pavlovian associative learning where subjects learn to execute an appropriately timed eyeblink in response to a previously neutral conditioning stimulus in which the cerebellum plays a key role. Specifically, the percentage of conditioned responses and their peak amplitude and peak velocity were reduced. [63]. Interestingly, FXS patients were found to display the same cerebellar deficits in eyeblink conditioning as mutant mice [63]. Together these results suggest that the deficits in eyeblink conditioning are likely due to the loss of FMRP in PC.

5.2 Tuberous sclerosis (TSC1/TSC2 genes)

Tuberous sclerosis (TS) is another rare syndromic disorder associated with ASD. TS is characterized by the development of non-cancerous tumors in the brain and other organs leading to neurological symptoms such as developmental delay, epilepsy, and ASD. It is an autosomal dominant condition caused by mutations in either the *TSC1* or *TSC2* genes, which form a tumor suppressor complex involved in the regulation of the mTOR signaling pathway. Approximately 40% of TS patients are co-diagnosed with ASD, and, interestingly, those with cerebellar lesions have been found to have a more severe ASD diagnosis [61]. Further, PC loss has been found in postmortem cerebellum samples from TSC patients [62].

Several lines of mutant TSC mice have been generated and studied in detail. A mutant mouse in which the *Tsc2* gene was selectively deleted from PCs starting at postnatal day 6 was generated to mimic patients with one nonfunctioning *TSC2* allele [62]. The haploinsufficiency of *TSC2* caused a progressive increase in PC cell size and subsequent death from apoptosis. *TSC2*-null PCs showed increased endoplasmic reticulum and oxidative stress, which were rescued by treatment with the mTOR inhibitor rapamycin. In a subsequent study, the authors reported that PC-*TSC2*-haploinsufficient mice showed social deficits and repetitive behaviors [64]. These observations indicate that selective loss of *TSC2* in PCs in a *TSC2*-haploinsufficient background is enough to lead to autistic-like behavioral deficits.

A conditional PC-TSC1 KO mouse has also been generated. Both heterozygous and homozygous losses of TSC1 in mouse cerebellar PCs result in autistic-like behaviors, including abnormal social interaction and repetitive behavior and vocalizations, in addition to decreased PC excitability. Similar to TSC2 mutants, treatment of TSC1 mutant mice with the mTOR inhibitor, rapamycin, prevented the pathological and behavioral deficits. Strikingly, PC-TSC1 homozygous mice, but not PC-TSC1 heterozygous mice, showed PC loss at 2 months of age. The fact that PC-TSC1 heterozygous mice showed autistic symptoms and PC excitability alterations in the absence of PC loss suggests that the decrease in PC excitability is likely driving the phenotype [69]. Further, this model has also been reported to show deficits in eyeblink conditioning; they specifically show lower percentage of conditioned response in this test [70]. These findings demonstrate new roles for TSC1/TSC2 in PC function and define a molecular basis for a cerebellar contribution to cognitive disorders such as autism.

5.3 Phelan-McDermid syndrome (SHANK3 gene)

Phelan-McDermid syndrome (PMS) is due to heterozygous chromosome 22q13 deletions and is often co-diagnosed with ASD. The clinical manifestations of PMS include global developmental delay/intellectual disability and absent or delayed speech [71]. Although the deletion encompasses numerous genes, a good candidate that could account for ASD symptoms is SHANK3, a gene within which mutations have independently been associated with non-syndromic ASD. ASD patients with SHANK3 deletions are also known to have severe core symptoms and mental disabilities [72]. Although to our knowledge there is no data addressing the effect of SHANK3 mutations on cerebellar anatomy and function, recent research suggests that mutations in *SHANK3* may be related to cerebellar abnormalities. SHANK3 is highly expressed in cerebellar granule cells [73] and has been suggested to play a role in the recruitment of axon terminals to cerebellar granule cell dendrites [74]. In addition, cerebellar vermis hypoplasia has been found in patients with PMS, suggesting that SHANK3 may be involved in cerebellar development [75].

Multiple mouse lines with SHANK3 mutations exist, and several display behaviors analogous to the core symptoms of autism, including isoform-specific SHANK3B KO [76], SHANK3 (Δ exons4–9) deleting major isoforms of the gene [77], and SHANK3 (Δ C), deleting the C-terminal region of the gene [78]. SHANK3 (Δ C) mice present a decreased density of PC compared to controls [70], and they show deficits in the eyeblink conditioning task, showing lower percentage of conditioning response and a delay in the response latency [70].

Interestingly, mutations in other proteins from the SHANK family, such as SHANK2, have been also linked to ASD. A KO mouse for SHANK2 shows alterations in social and repetitive behaviors and presents changes in PC electrophysiological characteristics, such as decreased intrinsic PC plasticity, synaptic strength at the PC-parallel fiber synapse, and enhanced inhibitory input into PC. Further PC-specific SHANK2 KO replicated these findings, arguing for a cerebellar role in autistic-like behaviors [79].

6. Conclusion

The cerebellum has been recently indicated as a key structure not only for sensorimotor control but also for language, social cognition, and emotion, via its extensive connections with cortical areas. In the present work, we aimed to provide an up-to-date overview of current findings on cerebellar involvement

in the pathophysiology of ASD. Anatomical studies report cerebellar abnormalities in postmortem brain tissue from autistic individuals, neuroimaging studies indicate abnormal cerebellar activation when performing social paradigms, and animal models of monogenic forms of autism converge on the cerebellum as one of the common sites of abnormalities. The cerebellum represents an emerging field of interest for ASD research, based on the hypothesis that ASD is a connectivity disorder and cerebellar dysfunction could impact other brain areas within the social network, leading to the core ASD symptoms. Although the literature in this new field is at a very early stage, based on the presented data, future studies should not exclude the cerebellum in analyses of structural and functional differences in ASD.

Acknowledgements

This work was supported by the following grants: Spanish Ministry of Economy and Competitiveness/European Regional Development Fund (MINECO/FEDER grant SAF2015-64163-R). OP is a Ramon y Cajal Fellow (RYC-2013-12558), MF is supported by a predoctoral fellowship from the Spanish Ministry of Economy and Competitiveness MINECO (BES-2016-078420), and TS-A is supported by a predoctoral fellowship from the Basque Government.

Author details

Marta Fernández, Teresa Sierra-Arregui and Olga Peñagarikano*
Department of Pharmacology, University of the Basque Country (UPV/EHU),
Spain

*Address all correspondence to: olga.penagarikano@ehu.eus

IntechOpen

© 2019 The Author(s). Licensee IntechOpen. This chapter is distributed under the terms of the Creative Commons Attribution License (<http://creativecommons.org/licenses/by/3.0>), which permits unrestricted use, distribution, and reproduction in any medium, provided the original work is properly cited. 

References

- [1] Association AP. Diagnostic and Statistical Manual of Mental Disorders. 5th ed. Washington DC: American Psychiatric Publishing; 2013
- [2] Adolphs R. The neurobiology of social cognition. *Current Opinion in Neurobiology*. 2001;**11**(2):231-239
- [3] Baio J, Wiggins L, Christensen DL, Maenner MJ, Daniels J, Warren Z, et al. Prevalence of autism Spectrum disorder among children aged 8 years—Autism and developmental disabilities monitoring network, 11 sites, United States, 2014. *MMWR Surveillance Summaries*. 2018;**67**(6):1-23
- [4] Geschwind DH. Advances in autism. *Annual Review of Medicine*. 2009;**60**:367-380
- [5] Sandin S, Lichtenstein P, Kuja-Halkola R, Hultman C, Larsson H, Reichenberg A. The heritability of autism spectrum disorder. *Journal of the American Medical Association*. 2017;**318**(12):1182-1184
- [6] Berg JM, Geschwind DH. Autism genetics: Searching for specificity and convergence. *Genome Biology*. 2012;**13**(7):247
- [7] Bolte S, Girdler S, Marschik PB. The contribution of environmental exposure to the etiology of autism spectrum disorder. *Cellular and Molecular Life Sciences*. 2018;**76**(7):1275-1297
- [8] Baron-Cohen S, Ring HA, Wheelwright S, Bullmore ET, Brammer MJ, Simmons A, et al. Social intelligence in the normal and autistic brain: An fMRI study. *The European Journal of Neuroscience*. 1999;**11**(6):1891-1898
- [9] Brothers L, Ring B, Kling A. Response of neurons in the macaque amygdala to complex social stimuli. *Behavioural Brain Research*. 1990;**41**(3):199-213
- [10] Baez-Mendoza R, Schultz W. The role of the striatum in social behavior. *Frontiers in Neuroscience*. 2013;**7**:233
- [11] Kennedy DP, Adolphs R. The social brain in psychiatric and neurological disorders. *Trends in Cognitive Sciences*. 2012;**16**(11):559-572
- [12] Courchesne E, Mouton PR, Calhoun ME, Semendeferi K, Ahrens-Barbeau C, Hallett MJ, et al. Neuron number and size in prefrontal cortex of children with autism. *Journal of the American Medical Association*. 2011;**306**(18):2001-2010
- [13] Courchesne E, Pierce K. Why the frontal cortex in autism might be talking only to itself: Local over-connectivity but long-distance disconnection. *Current Opinion in Neurobiology*. 2005;**15**(2):225-230
- [14] Schumann CM, Barnes CC, Lord C, Courchesne E. Amygdala enlargement in toddlers with autism related to severity of social and communication impairments. *Biological Psychiatry*. 2009;**66**(10):942-949
- [15] Kleinmans NM, Richards T, Weaver K, Johnson LC, Greenberg J, Dawson G, et al. Association between amygdala response to emotional faces and social anxiety in autism spectrum disorders. *Neuropsychologia*. 2010;**48**(12):3665-3670
- [16] Chevallier C, Kohls G, Troiani V, Brodtkin ES, Schultz RT. The social motivation theory of autism. *Trends in Cognitive Sciences*. 2012;**16**(4):231-239
- [17] Dichter G, Adolphs R. Reward processing in autism: A thematic series. *Journal of Neurodevelopmental Disorders*. 2012;**4**(1):20

- [18] Schmahmann JD, Caplan D. Cognition, emotion and the cerebellum. *Brain*. 2006;**129**(Pt 2): 290-292
- [19] Wegiel J, Flory M, Kuchna I, Nowicki K, Ma SY, Imaki H, et al. Stereological study of the neuronal number and volume of 38 brain subdivisions of subjects diagnosed with autism reveals significant alterations restricted to the striatum, amygdala and cerebellum. *Acta Neuropathologica Communications*. 2014;**2**:141
- [20] Mosconi MW, Wang Z, Schmitt LM, Tsai P, Sweeney JA. The role of cerebellar circuitry alterations in the pathophysiology of autism spectrum disorders. *Frontiers in Neuroscience*. 2015;**9**:296
- [21] Geschwind DH, Levitt P. Autism spectrum disorders: Developmental disconnection syndromes. *Current Opinion in Neurobiology*. 2007;**17**(1):103-111
- [22] Crawley JN. Behavioral phenotyping strategies for mutant mice. *Neuron*. 2008;**57**(6):809-818
- [23] Rubenstein JL, Merzenich MM. Model of autism: Increased ratio of excitation/inhibition in key neural systems. *Genes, Brain, and Behavior*. 2003;**2**(5):255-267
- [24] Yizhar O, Fenno LE, Prigge M, Schneider F, Davidson TJ, O'Shea DJ, et al. Neocortical excitation/inhibition balance in information processing and social dysfunction. *Nature*. 2011;**477**(7363):171-178
- [25] Schultz W. Updating dopamine reward signals. *Current Opinion in Neurobiology*. 2013;**23**(2):229-238
- [26] Gunaydin LA, Grosenick L, Finkelstein JC, Kauvar IV, Fenno LE, Adhikari A, et al. Natural neural projection dynamics underlying social behavior. *Cell*. 2014;**157**(7):1535-1551
- [27] Carta I, Chen CH, Schott AL, Dorizan S, Khodakhah K. Cerebellar modulation of the reward circuitry and social behavior. *Science*. 2019;**363**(6424): pii: eaav0581
- [28] Fernandez M, Mollinedo-Gajate I, Penagarikano O. Neural circuits for social cognition: Implications for autism. *Neuroscience*. 2018;**370**:148-162
- [29] Raymond JL, Lisberger SG, Mauk MD. The cerebellum: A neuronal learning machine? *Science*. 1996;**272**(5265):1126-1131
- [30] Stoodley CJ, Schmahmann JD. Evidence for topographic organization in the cerebellum of motor control versus cognitive and affective processing. *Cortex*. 2010;**46**(7):831-844
- [31] Bostan AC, Strick PL. The basal ganglia and the cerebellum: Nodes in an integrated network. *Nature Reviews Neuroscience*. 2018;**19**(6):338-350
- [32] Strick PL, Dum RP, Fiez JA. Cerebellum and nonmotor function. *Annual Review of Neuroscience*. 2009;**32**:413-434
- [33] Stoodley CJ, Schmahmann JD. The cerebellum and language: Evidence from patients with cerebellar degeneration. *Brain and Language*. 2009;**110**(3):149-153
- [34] Jack A, Englander ZA, Morris JP. Subcortical contributions to effective connectivity in brain networks supporting imitation. *Neuropsychologia*. 2011;**49**(13):3689-3698
- [35] Jack A, Pelphrey KA. Neural correlates of animacy attribution include neocerebellum in healthy adults. *Cerebral Cortex*. 2015;**25**(11):4240-4247

- [36] Van Overwalle F, Baetens K, Marien P, Vandekerckhove M. Social cognition and the cerebellum: A meta-analysis of over 350 fMRI studies. *NeuroImage*. 2014;**86**:554-572
- [37] Van Overwalle F, Baetens K, Marien P, Vandekerckhove M. Cerebellar areas dedicated to social cognition? A comparison of meta-analytic and connectivity results. *Social Neuroscience*. 2015;**10**(4):337-344
- [38] Rogers TD, McKimm E, Dickson PE, Goldowitz D, Blaha CD, Mittleman G. Is autism a disease of the cerebellum? An integration of clinical and pre-clinical research. *Frontiers in Systems Neuroscience*. 2013;**7**:15
- [39] D'Mello AM, Crocetti D, Mostofsky SH, Stoodley CJ. Cerebellar gray matter and lobular volumes correlate with core autism symptoms. *NeuroImage: Clinical*. 2015;**7**:631-639
- [40] Wang SS, Kloth AD, Badura A. The cerebellum, sensitive periods, and autism. *Neuron*. 2014;**83**(3):518-532
- [41] Fatemi SH, Aldinger KA, Ashwood P, Bauman ML, Blaha CD, Blatt GJ, et al. Consensus paper: Pathological role of the cerebellum in autism. *Cerebellum*. 2012;**11**(3):777-807
- [42] Skefos J, Cummings C, Enzer K, Holiday J, Weed K, Levy E, et al. Regional alterations in purkinje cell density in patients with autism. *PLoS One*. 2014;**9**(2):e81255
- [43] Courchesne E, Karns CM, Davis HR, Ziccardi R, Carper RA, Tigue ZD, et al. Unusual brain growth patterns in early life in patients with autistic disorder: An MRI study. *Neurology*. 2001;**57**(2):245-254
- [44] Bolduc ME, du Plessis AJ, Sullivan N, Guizard N, Zhang X, Robertson RL, et al. Regional cerebellar volumes predict functional outcome in children with cerebellar malformations. *Cerebellum*. 2012;**11**(2):531-542
- [45] Riva D, Annunziata S, Contarino V, Erbetta A, Aquino D, Bulgheroni S. Gray matter reduction in the vermis and CRUS-II is associated with social and interaction deficits in low-functioning children with autistic spectrum disorders: A VBM-DARTEL study. *Cerebellum*. 2013;**12**(5):676-685
- [46] Bailey A, Luthert P, Dean A, Harding B, Janota I, Montgomery M, et al. A clinicopathological study of autism. *Brain*. 1998;**121**(Pt 5):889-905
- [47] Vargas DL, Nascimbene C, Krishnan C, Zimmerman AW, Pardo CA. Neuroglial activation and neuroinflammation in the brain of patients with autism. *Annals of Neurology*. 2005;**57**(1):67-81
- [48] Yip J, Soghomonian JJ, Blatt GJ. Decreased GAD67 mRNA levels in cerebellar Purkinje cells in autism: Pathophysiological implications. *Acta Neuropathologica*. 2007;**113**(5):559-568
- [49] Yip J, Soghomonian JJ, Blatt GJ. Increased GAD67 mRNA expression in cerebellar interneurons in autism: Implications for Purkinje cell dysfunction. *Journal of Neuroscience Research*. 2008;**86**(3):525-530
- [50] Hegarty JP 2nd, Weber DJ, Cirstea CM, Beversdorf DQ. Cerebro-cerebellar functional connectivity is associated with cerebellar excitation-inhibition balance in autism spectrum disorder. *Journal of Autism and Developmental Disorders*. 2018;**48**(10):3460-3473
- [51] Khan AJ, Nair A, Keown CL, Datko MC, Lincoln AJ, Muller RA. Cerebro-cerebellar resting-state functional connectivity in children and adolescents with autism spectrum disorder. *Biological Psychiatry*. 2015;**78**(9):625-634

- [52] Verly M, Verhoeven J, Zink I, Mantini D, Peeters R, Deprez S, et al. Altered functional connectivity of the language network in ASD: Role of classical language areas and cerebellum. *NeuroImage: Clinical*. 2014;**4**:374-382
- [53] Padmanabhan A, Lynn A, Foran W, Luna B, O'Hearn K. Age related changes in striatal resting state functional connectivity in autism. *Frontiers in Human Neuroscience*. 2013;**7**:814
- [54] Mostofsky SH, Powell SK, Simmonds DJ, Goldberg MC, Caffo B, Pekar JJ. Decreased connectivity and cerebellar activity in autism during motor task performance. *Brain*. 2009;**132**(Pt 9):2413-2425
- [55] Jack A, Morris JP. Neocerebellar contributions to social perception in adolescents with autism spectrum disorder. *Developmental Cognitive Neuroscience*. 2014;**10**:77-92
- [56] Kana RK, Maximo JO, Williams DL, Keller TA, Schipul SE, Cherkassky VL, et al. Aberrant functioning of the theory-of-mind network in children and adolescents with autism. *Molecular Autism*. 2015;**6**:59
- [57] Kaufmann WE, Cooper KL, Mostofsky SH, Capone GT, Kates WR, Newschaffer CJ, et al. Specificity of cerebellar vermian abnormalities in autism: A quantitative magnetic resonance imaging study. *Journal of Child Neurology*. 2003;**18**(7):463-470
- [58] Gothelf D, Furfaro JA, Hoefl F, Eckert MA, Hall SS, O'Hara R, et al. Neuroanatomy of fragile X syndrome is associated with aberrant behavior and the fragile X mental retardation protein (FMRP). *Annals of Neurology*. 2008;**63**(1):40-51
- [59] Fatemi SH, Folsom TD. Dysregulation of fragile X mental retardation protein and metabotropic glutamate receptor 5 in superior frontal cortex of individuals with autism: A postmortem brain study. *Molecular Autism*. 2011;**2**:6
- [60] Ellegood J, Pacey LK, Hampson DR, Lerch JP, Henkelman RM. Anatomical phenotyping in a mouse model of fragile X syndrome with magnetic resonance imaging. *NeuroImage*. 2010;**53**(3):1023-1029
- [61] Eluvathingal TJ, Behen ME, Chugani HT, Janisse J, Bernardi B, Chakraborty P, et al. Cerebellar lesions in tuberous sclerosis complex: Neurobehavioral and neuroimaging correlates. *Journal of Child Neurology*. 2006;**21**(10):846-851
- [62] Reith RM, Way S, McKenna J 3rd, Haines K, Gambello MJ. Loss of the tuberous sclerosis complex protein tuberin causes Purkinje cell degeneration. *Neurobiology of Disease*. 2011;**43**(1):113-122
- [63] Koekkoek SK, Yamaguchi K, Milojkovic BA, Dortland BR, Ruigrok TJ, Maex R, et al. Deletion of FMR1 in Purkinje cells enhances parallel fiber LTD, enlarges spines, and attenuates cerebellar eyelid conditioning in fragile X syndrome. *Neuron*. 2005;**47**(3):339-352
- [64] Reith RM, McKenna J, Wu H, Hashmi SS, Cho SH, Dash PK, et al. Loss of TSC2 in Purkinje cells is associated with autistic-like behavior in a mouse model of tuberous sclerosis complex. *Neurobiology of Disease*. 2013;**51**:93-103
- [65] Penagarikano O, Mulle JG, Warren ST. The pathophysiology of fragile X syndrome. *Annual Review of Genomics and Human Genetics*. 2007;**8**:109-129
- [66] Greco CM, Navarro CS, Hunsaker MR, Maezawa I, Shuler JF, Tassone F, et al. Neuropathologic features in the hippocampus and cerebellum of three older men with fragile X syndrome. *Molecular Autism*. 2011;**2**(1):2

- [67] Ellegood J, Anagnostou E, Babineau BA, Crawley JN, Lin L, Genestine M, et al. Clustering autism: Using neuroanatomical differences in 26 mouse models to gain insight into the heterogeneity. *Molecular Psychiatry*. 2015;**20**(1):118-125
- [68] Pacey LK, Xuan IC, Guan S, Sussman D, Henkelman RM, Chen Y, et al. Delayed myelination in a mouse model of fragile X syndrome. *Human Molecular Genetics*. 2013;**22**(19):3920-3930
- [69] Tsai PT, Hull C, Chu Y, Greene-Colozzi E, Sadowski AR, Leech JM, et al. Autistic-like behaviour and cerebellar dysfunction in Purkinje cell TSC1 mutant mice. *Nature*. 2012;**488**(7413):647-651
- [70] Kloth AD, Badura A, Li A, Cherskov A, Connolly SG, Giovannucci A, et al. Cerebellar associative sensory learning defects in five mouse autism models. *eLife*. 2015;**4**:e06085
- [71] Phelan K, McDermid HE. The 22q13.3 deletion syndrome (Phelan-McDermid syndrome). *Molecular Syndromology*. 2012;**2**(3-5):186-201
- [72] Chen BY, Zou XB, Zhang J, Deng HZ, Li JY, Li LY, et al. Copy-number variations of SHANK3 and related clinical phenotypes in children with autism. *Zhonghua Er Ke Za Zhi*. 2011;**49**(8):607-611
- [73] Beri S, Tonna N, Menozzi G, Bonaglia MC, Sala C, Giorda R. DNA methylation regulates tissue-specific expression of SHANK3. *Journal of Neurochemistry*. 2007;**101**(5):1380-1391
- [74] Roussignol G, Ango F, Romorini S, Tu JC, Sala C, Worley PF, et al. SHANK expression is sufficient to induce functional dendritic spine synapses in aspiny neurons. *The Journal of Neuroscience*. 2005;**25**(14):3560-3570
- [75] Aldinger KA, Kogan J, Kimonis V, Fernandez B, Horn D, Klopocki E, et al. Cerebellar and posterior fossa malformations in patients with autism-associated chromosome 22q13 terminal deletion. *American Journal of Medical Genetics. Part A*. 2013;**161A**(1):131-136
- [76] Peca J, Feliciano C, Ting JT, Wang W, Wells MF, Venkatraman TN, et al. SHANK3 mutant mice display autistic-like behaviours and striatal dysfunction. *Nature*. 2011;**472**(7344):437-442
- [77] Wang X, McCoy PA, Rodriguiz RM, Pan Y, Je HS, Roberts AC, et al. Synaptic dysfunction and abnormal behaviors in mice lacking major isoforms of SHANK3. *Human Molecular Genetics*. 2011;**20**(15):3093-3108
- [78] Kouser M, Speed HE, Dewey CM, Reimers JM, Widman AJ, Gupta N, et al. Loss of predominant SHANK3 isoforms results in hippocampus-dependent impairments in behavior and synaptic transmission. *The Journal of Neuroscience*. 2013;**33**(47):18448-18468
- [79] Peter S, Ten Brinke MM, Stedehouder J, Reinelt CM, Wu B, Zhou H, et al. Dysfunctional cerebellar Purkinje cells contribute to autism-like behaviour in SHANK2-deficient mice. *Nature Communications*. 2016;**7**:12627