

We are IntechOpen, the world's leading publisher of Open Access books Built by scientists, for scientists

4,800

Open access books available

122,000

International authors and editors

135M

Downloads

Our authors are among the

154

Countries delivered to

TOP 1%

most cited scientists

12.2%

Contributors from top 500 universities



WEB OF SCIENCE™

Selection of our books indexed in the Book Citation Index
in Web of Science™ Core Collection (BKCI)

Interested in publishing with us?
Contact book.department@intechopen.com

Numbers displayed above are based on latest data collected.
For more information visit www.intechopen.com



Necrotizing Enterocolitis

Rita Prasad Verma and Archana Kota

Abstract

Necrotizing enterocolitis (NEC) is the commonest inflammatory gastrointestinal disorder of newborn infants, occurring primarily in premature neonates. Presenting as a medical and surgical emergency, it is associated with significant morbidity and mortality. NEC is characterized by acute intestinal inflammation and necrosis with intramural dissection of gas, pathognomically appearing as pneumatosis intestinalis on radiography. The incidence and mortality, with an inverse relationship to maturation, range between 3–11% and 17–20% respectively. Mortality may be up to 50% in extremely premature infants who require surgery for intestinal perforation or gangrene. The exact etiopathogenesis is unknown. Over 90% of infants are premature and more than 98% are enterally fed. NEC presents with feeding intolerance and abdominal distension, which may rapidly progress to cardiorespiratory decompensation and death in severe cases. Intestinal dysbiosis and its functional and immunological immaturity are proposed to play roles in the pathogenesis. While exact triggers are undetermined, the disease is marked by an anomalous immunological response of enterocytes to inflammation, invoking cytokines and chemokines. NEC is treated with bowel rest, antibiotics, cardiorespiratory support, parenteral nutrition, and blood products transfusion. Approximately 30% of cases require surgery and a significant number of survivors suffer from neurological deficits, intestinal dysfunction, and post surgical short bowel syndrome.

Keywords: necrotizing enterocolitis, preterm infants, pneumatosis intestinalis, intestinal gangrene, intestinal perforation, intestinal dysbiosis, short bowel syndrome, feeding intolerance, heme positive stools, abdominal distension, cardiovascular decompensation

1. Introduction

Necrotizing enterocolitis (NEC) is an acquired, multifactorial and devastating gastrointestinal disease associated with high morbidity and mortality in preterm neonates. With an incidence of about 7% in infants with BW < 1500 g and mortality up to 30%, NEC presents as a medical and surgical emergency [1, 2]. It is characterized by ischemia, necrosis, and inflammation of bowel wall with invasion by gas-forming organisms and intramural dissection of gas, characteristically appearing as pneumatosis intestinalis in radiological and pathological studies. While exact etiology is undetermined, the pathogenesis is believed to be an anomalous innate immune response to an altered, less diverse intestinal microbiota by the highly immunoreactive enterocytes of premature infants, leading to inflammation and tissue necrosis [3, 4]. The clinical presentation can be severe with cardiorespiratory collapse, shock, and disseminated intravascular coagulopathy (DIC), escalating

to multisystem failure and death [2]. About one third of the cases require surgical intervention due to intestinal perforation and gangrene [5]. NEC is the commonest gastrointestinal (GI) disorder of preterm newborn infants, although term infants can be affected. NEC is associated with significant adverse outcomes, and approximately half of the survivors suffer from abnormal neurodevelopment independent of maturational status at birth. It is one of the most important causes of intestinal failure in children. Despite substantial advances in its diagnosis, prevention, and management strategies, the incidence has not changed, especially in very low birth weight neonates, and the morbidity and mortality associated with necrotizing enterocolitis continue to be high.

2. Epidemiology

NEC constitutes about 2–5% of all NICU admissions. The incidence reported in 2012 by the Canadian Neonatal Network (CNN) in infants less than 33 weeks of gestational age (GA) was 5.1% [1]. In the United States the incidence is estimated to be 1–3 per 1000 live births [2, 6], while its prevalence is 0.3–2.4 per 1000 live births. There is considerable variability in incidence among different geographical locations and neonatal intensive care units [6–8]. Henry and Moss noted an overall incidence of 3–7% in 2005 [5]. A review by the National Institute of Child Health and Human Development (NICHD) Neonatal Research Network data from 1998 to 2001 reported a 7% incidence of NEC among very low birth weight infants [9], while a more recent report from the network in 2010 documented an incidence of 11–15% in neonates < 1500 g or < 32 weeks at birth [10]. The incidence was found to be relatively unchanged at approximately 7% in infants weighing <1500 g in another report published in 2011 [11]. Ninety percent of the infants are preterm and the rest term or late preterm. Incidence and mortality are inversely related to GA and birth weight (BW). Mortality in preterm infants from NEC may be up to 30–50%, and 27% of infants require surgical intervention with an overall case fatality rate of 15% [5, 11, 12]. The mortality rate is higher in surgical NEC and African American males [13]. Forty-six percent of survivors suffer from abnormal neurodevelopment, and 12% of all cases of GI failure in children are due to NEC [14]. The risk and mortality associated with NEC were stratified according to BW and GA in a cohort of extremely premature infants in who the overall incidence was estimated to be 7.5% (Tables 1 and 2) [2].

Despite the variability in incidence among studies with rates ranging between 3 and 15% in VLBW infants, a relative stability in the incidence over time has been noted. Survival in NEC has not changed in the past five decades, the average mortality being 20–30% and up to 50% in infants requiring surgical management [10]. The proportion of neonates with NEC requiring surgical intervention has

Birth weight (grams)	Risk of NEC(%)	Mortality with NEC (%)
501-750	12	42
751-1000	9	29
1001-1250	6	21
1251-1500	3	16

Table 1.
Risk and mortality associated with NEC based on birth weight.

Gestational Age (in weeks)	Risk of NEC (percent %)
22	11
23	16
24	11
25	9
26	10
27	8
28	8

Table 2.
Risk of NEC based on gestational age.

also remained stable at approximately 30% [15]. The reasons for such observations are the decreasing gestational age limit for neonatal viability and increased survival of extremely premature infants with advances in neonatal care. Practice implementations, such as standardizing enteral feeding guidelines, exclusive feedings of own mother's milk, using donor breast milk when mother's milk is not available, minimizing duration of empiric antibiotics after birth, and avoiding packed red blood cells (PRBC) transfusions as well as antacid use in preterm infants, are associated with a decrease in incidence of NEC in very low birth weight infants [16].

3. Etiology and risk factors

The exact etiology of NEC is undetermined and multiple risk factors have been forwarded. NEC occurs in a stereotypic relation at chronological age of onset to the gestational age at birth, the younger the gestation, the later the onset; and requires that the infant be fed [1, 11]. In one study the median age at onset in infants with a GA of less than 26 weeks was 23 days compared to a median age of 11 days for more mature infants with a GA of greater than 31 weeks [17]. Prematurity is the single greatest risk factor with almost 90% patients being premature. Enteral feeding is the second most common feature with over 98% of cases having a history of feeding. However, rate of advancement unless excessive, trophic, and early versus late and colostrum feeding are not conclusively proven to have any effect on the occurrence of NEC [18]. Other suggested risk factors are the 5 min Apgar score < 7, outborn status, body temperature of 36°C at 1 h of age, cesarean section, use of indomethacin with or without dexamethasone, sepsis, use of inotropes, severe metabolic acidosis, patent ductus arteriosus (PDA), gastroschisis, severe anemia, polycythemia, packed red blood cell (PRBC) transfusion, use of H₂ antagonist, exposure to empirical antimicrobials, and black and Hispanic ethnicity [19]. Approximately 10% of cases occur in term and late preterm infants. Risk factors for NEC in term infants are nonhuman milk feeding; preexisting illnesses, such as congenital heart disease; primary gastrointestinal disorders; sepsis; polycythemia; respiratory disease; hypotension; neonatal

abstinence; fetal growth restriction; and perinatal hypoxia [20]. Despite the fact that no predilection for sex, race, or ethnicity has been conclusively established, a higher incidence is observed in male African American infants than in any other single demographic. This could be related to the higher incidence of prematurity in this ethnic group than in the general US population. Hypoxic ischemic injury is no longer considered a major predisposing factor in the development of NEC except in term babies [21].

4. Pathology

NEC primarily affects the ileum and colon, the commonest location being ileocecal area [22]. The entire gastrointestinal tract may be involved in severe cases. On gross examination, the bowel loops are distended with areas of hemorrhage, congestion, necrosis, and pneumatosis (**Figure 1**). On microscopic examination, signs of inflammation, mucosal edema, bacterial invasion, submucosal and intramural gas bubbles, and ischemic transmural necrosis are seen. Intestinal perforation may happen when the entire thickness of bowel is involved leading to pneumoperitoneum, peritonitis, and portal venous gas (**Figure 2**). Microscopically, the predominant feature is coagulation necrosis, suggesting an ischemic origin of NEC. The aggregated inflammatory cells are both acute and chronic, such as neutrophils, lymphocytes, and macrophages representing an appropriate response to pathogenic bacterial invasion and tissue necrosis. Epithelial regeneration, granulation tissue formation and fibrosis may be seen suggesting reparative histological process [23]. Common pathogens isolated in NEC are Enterobacteriaceae including *Escherichia*, *Salmonella*, *Enterobacter*, and *Klebsiella* (68%); staphylococcal species (26%); clostridium species (4%); viruses including rota, echo, corona, and toro (11%); and candida (1%). No organism is isolated in 3% of cases.

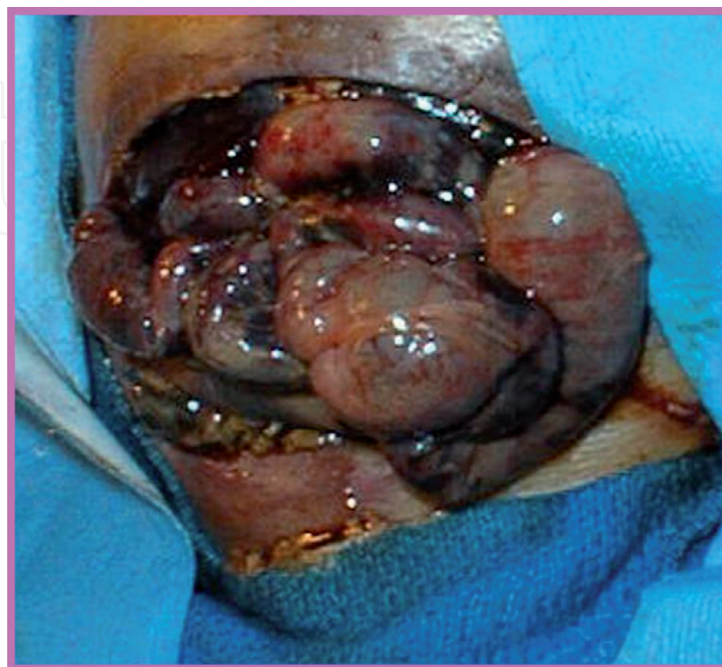


Figure 1. Macroscopic appearance of necrotizing enterocolitis showing necrotic bowel loops. [Courtesy of Renu Sharma, MD, Professor of Pediatrics, University of Florida at Jacksonville, USA].

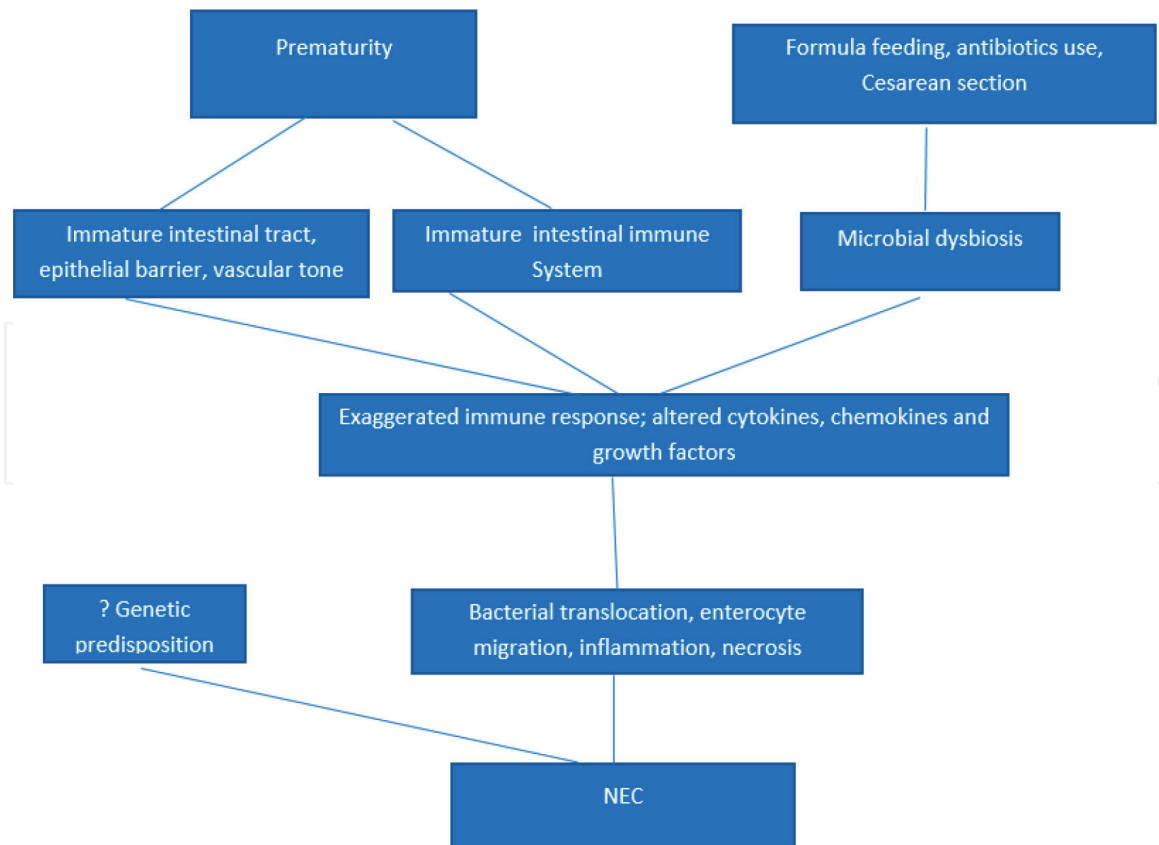


Figure 2.
Schematic presentation of pathogenesis of NEC.

5. Pathogenesis

The pathogenesis of NEC is complex, multifactorial, and incompletely defined. The disorder is believed to be a composite result of intestinal immaturity, aberrant immunological response, and gut microbial dysbiosis [3, 4, 23, 24]. It almost never occurs when the intestinal immune system is mature and intact, even when other risk factors are present. Experimental NEC does not occur in sterile environment. Research support the hypothesis that NEC in the preterm infant results from a multifactorial process that requires the concurrent presence of an immature intestinal tract and immune system leading to increased susceptibility, factors causing disruption of the normal intestinal bacterial microbiome with growth of potentially pathogenic bacteria, and an exaggerated inflammatory host response with the release of cytokines and chemokines (**Figure 2**). A genetically determined predisposition to necrotizing enterocolitis has been also proposed implying the contribution of genetic polymorphisms in the pro-inflammatory cytokines associated with NEC [25]. The combination of compromised intestinal epithelial barrier; underdeveloped and anomalous immune defense; abnormal mesenteric vascular development, tone, and flow; and altered luminal microbiota shaped by formula feedings, antibiotic exposure, and cesarean delivery presumably leads to intestinal inflammation and gangrene. NEC is triggered when several risk factors heighten neonatal intestinal inflammation and an irreversible borderline is surpassed.

5.1 Intestinal immaturity, dysbiosis, and barrier dysfunction

Immaturity of neonatal intestinal mucosal barrier and mucosal immune system is characterized by decreased mucus coat, altered mucus protein, reduced Ig A, and abnormal epithelial membrane and tight junctions [4, 26, 27]. Preterm intestinal

mucosa is highly immunoreactive, and fetal human enterocytes have been shown to evoke excessive immunological and inflammatory response compared to adults. An imbalance between epithelial cell injury and repair leads to a gut barrier failure and a consequent cycle of bacterial invasion, immune activation, uncontrolled inflammation, and gut necrosis (**Figure 2**).

5.2 Feeding and immature GI function

Premature GIT is relatively deficient in digestive functions and peristaltic motility in addition to immune responses [28]. Dysfunctional gastric emptying and increased gastric pH add to gut barrier disruption and epithelial permeability [4, 29–31]. Aggressive feeding with peristaltic dysmotility leads to stasis of intraluminal contents and intestinal dilatation, which may further impair epithelial barrier (EB). These, in concurrence with microbial dysbiosis, result in abnormal signal transduction across the EB with consequent inflammation, apoptosis, and necrosis. The balance between the pro-inflammatory and anti-inflammatory signaling is affected with an inappropriate response to pathogenic microorganisms.

5.3 Role of cytokines and chemokines

NEC is associated with increased expression of inflammatory cytokines, such as tumor necrosis factor (TNF), interleukin (IL)-1 β , IL-6, IL-8/CXC-motif ligand 8 (CXCL8), IL 10 monocyte chemoattractant protein-1/CC-motif ligand (CCL)-2, macrophage inflammatory protein-1 β /CCL3, and C-reactive protein in plasma and affected tissues [32]. These cytokines can disrupt the epithelial barrier and augment intestinal injury. Serum levels of cytokines/chemokines are elevated in NEC, and increased TLR4 and abnormal I κ B/NF κ B suggest excessive abnormal immunological response [33–35]. Lower blood TGF- β and interleukin (IL)-2 and higher IL-8 levels are found in ELBW infants with NEC. A developmental immaturity is noted in I κ B expression, the molecule that inhibits cytokines activation via NF κ B in NEC. Recently the role of toll-like receptor 4 (TLR4) signaling in the pathogenesis of NEC has been highlighted. Hypoxia, infection, and prematurity accentuate the expression of TLR4 in the intestinal mucosa. TLR4 is subsequently activated by enteric bacteria, triggering an inflammatory cascade which results in increased gut mucosal injury and reduced epithelial repair. Activation of cytoplasmic innate immune receptors, NOD2 and TLR9 leads to inhibition of TLR4, with restoration of the intestinal epithelial barrier and reduction in severity of NEC in experimental models. Other factors implicated in pathogenesis of NEC are platelet-activating factor, nitric oxide, reactive oxygen species, and transforming growth factors. However, despite success in animal model systems, no significant improvement in treatment and outcomes of NEC has been achieved due to an incomplete understanding of the developing immune system in premature infants and inability to replicate them in animal models [32].

6. Clinical presentation

NEC presents acutely with feeding intolerance, heme-positive stools, abdominal distension, gastric residuals, and vomiting in a previously stable and feeding preterm infant. Commonly associated nonspecific symptoms are temperature instability, apnea, bradycardia, oxygen desaturation, and lethargy. There may be abdominal wall erythema, abdominal tenderness, and decreased or absent bowel sounds (**Figure 3**). As the disease process advances, cardiorespiratory

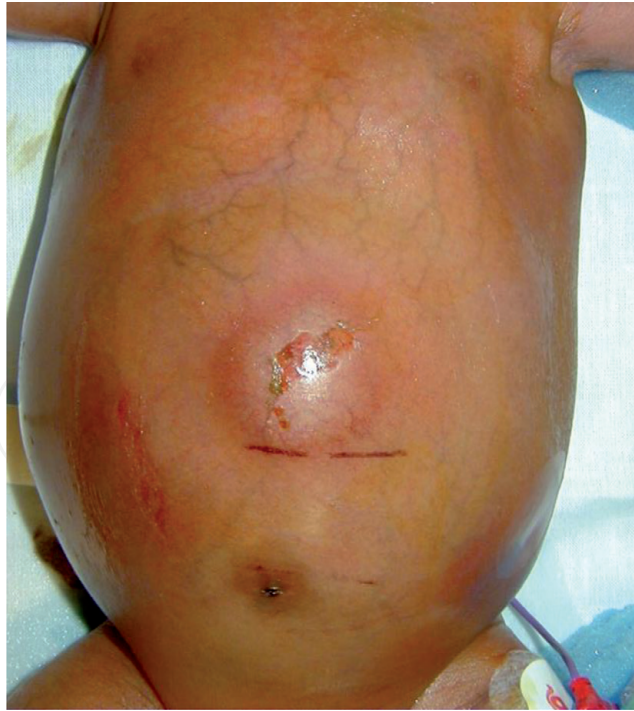

Figure 3.
Abdominal distension, erythema and skin ulceration in a case of necrotizing enterocolitis. [Courtesy of Renu Sharma, MD, Professor of Pediatrics, University of Florida at Jacksonville, USA].

decompensation, septic shock, and multi-organ failure may supervene. The diagnosis is confirmed by the presence of pneumatosis intestinalis in abdominal X-ray which is pathognomonic of NEC (**Figure 4**). The course may be mild to moderate with recovery with antibiotics, GI rest, and correction of biochemical and hematological anomalies, or fulminant with early signs of severe systemic

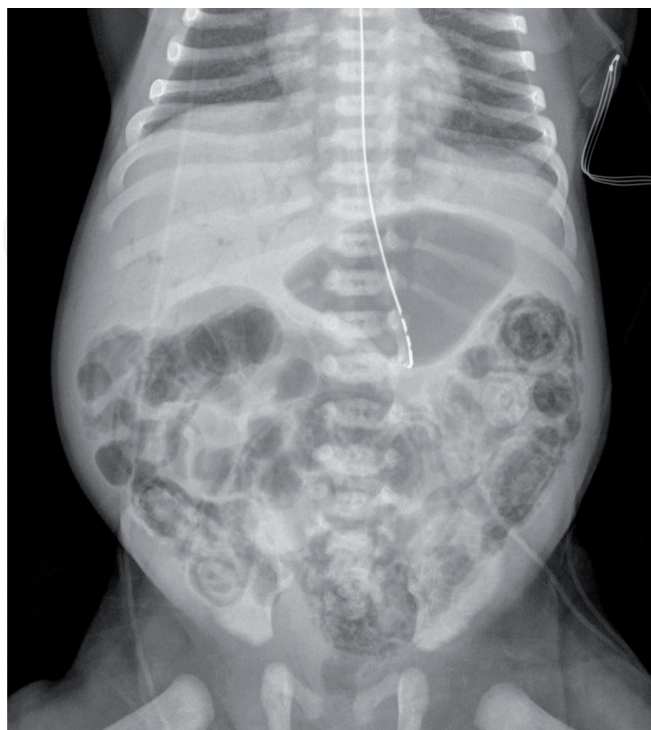

Figure 4.
Extensive pneumatosis with branching linear lucencies in the liver, consistent with portal venous gas. [Courtesy of Dr. Renu Aggarwal, Attending Neonatologist, NYU Winthrop Hospital, Mineola, NY, USA].

	STAGE	SYSTEMIC SIGNS	ABDOMINAL SIGNS	RADIOGRAPHIC SIGNS
IA	Suspected	Temperature instability, apnea, bradycardia, lethargy	Gastric residuals, abdominal distension, emesis, guaiac-positive stool	Normal or intestinal dilation; mild ileus
IB	Suspected	Same as IA	Gross bloody stool	Same as IA
IIA	Definite, mildly ill	Same as IA	IA, IB plus decreased or absent bowel sounds with/without abdominal tenderness	Intestinal dilation, ileus, pneumatosis intestinalis
IIB	Definite, moderately ill	IIA plus mild metabolic acidosis and mild thrombocytopenia	IIA plus abdominal tenderness plus absent bowel sounds with/without abdominal cellulitis, or right lower quadrant mass, absent bowel sounds	IIA plus abdominal tenderness plus absent bowel sounds with/without abdominal cellulitis, or right lower quadrant mass, absent bowel sounds
IIIA	Advanced, severely ill, intact bowel	IIB plus hypotension, bradycardia, severe apnea, combined respiratory and metabolic acidosis, DIC, neutropenia, anuria	IIB plus signs of peritonitis, marked abdominal tenderness, distension, and abdominal wall erythema	IIB plus definite ascites
IIIB	Advanced, severely ill, perforated bowel	Same as IIIA	Same as IIIA	IIB plus pneumoperitoneum

Adapted from: .Neu J. Necrotizing enterocolitis: the search for a unifying pathogenic theory leading to prevention. *Pediatr Clin North Am.* 1996;43(2):409–43:

Table 3.
Modified Bell's staging criteria for necrotizing enterocolitis in neonates [33].

inflammatory response and poor response to correction of metabolic and hematological derangements, such as severe metabolic acidosis, hyponatremia, hyperglycemia, thrombocytopenia, DIC, anemia, and neutropenia, eventually progressing to death.

Age of onset varies in an inverse relationship with GA at birth, and the average post menstrual gestational age of NEC is estimated to be 31–32 weeks. In a cohort of preterm infants under 33 weeks gestational age, NEC presented at a mean of 7 days in more mature infants, while it was delayed to 32 days in lower birth weight and gestational age neonates [1]. The average age of onset has been reported to be 20.2 days for babies born at less than 30 weeks' estimated gestational age, 13.8 days for babies born at 31–33 weeks, and 5.4 days for babies born after 34 weeks of gestation. Term infants develop necrotizing enterocolitis much earlier, with the average age of onset within the first week or within the first 1–2 days of life [36].

To classify the severity of NEC based on clinical findings, a staging criterion was proposed by Bell in 1978 which was later modified (**Table 3**) [37]. In about one third of cases, NEC is suspected but not confirmed (stage I), and symptoms resolve gradually with treatment. In 25–40% of cases, the progression of NEC is fulminant with signs of peritonitis and sepsis and the rapid development of DIC and shock (stage III). About 30% of the cases may develop intestinal perforation, peritonitis, and other complications necessitating surgical intervention. Mean LOS is 62 days in surgical and 36 days in medical NEC cases [15]. Surgical NEC cases incur higher hospital costs.

7. Laboratory and radiological investigations

In all cases of NEC, CBC with diff, blood culture, C-reactive protein, serum electrolytes, pH, lactate, acid-base indicators, arterial blood gases,

and pertinent radiography should be done. The characteristic anomalies are metabolic or mixed acidosis, high C-reactive protein (CRP), hyponatremia, hyperglycemia, thrombocytopenia, neutropenia, or leukocytosis with high I/T ratio. CSF studies are suggested, and peritoneal fluid analysis for bacteria and fecal material should be done if paracentesis abdominis is performed for therapeutic or diagnostic purposes. Presentation of NEC is similar to, or may be associated with sepsis, and the differentiation is confirmed by the presence of pneumatosis intestinalis (PI) on radiography (**Figure 5**). Apart from PI other radiological features of NEC are ileus, bowel wall thickness, and bowel perforation with peritoneal air. Bowel wall thickening, with or without echogenicity, indicates increasing inflammation, swelling, and perfusion of the area. Bowel loops may be separated by the presence of peritoneal fluid and give an impression of thickening. Thin bowel wall with a central echogenic focus and a hypoechoic rim, called pseudo-kidney sign, if present, may indicate necrotic bowel and imminent perforation. Ultrasound detection of small air bubbles in the bowel wall as in pneumatosis intestinalis can be spatially differentiated from air bubbles in stool that can sometimes be misdiagnosed as pneumatosis on radiographs. Ultrasonography also can detect intermittent gas bubbles in the liver parenchyma and portal venous system that are not detected on radiography. Ultrasound is more sensitive in detecting peritoneal fluid collections. Doppler ultrasound is dynamic and permits real-time visualization of bowel wall thickness, peristalsis, and perfusion. It is more sensitive than abdominal radiography in detecting bowel necrosis [15]. Evidence of free peritoneal air and ascites indicate intestinal perforation. Contrast enemas are not recommended if NEC is suspected, as it may result in bowel perforation with extravasation of contrast material into the peritoneum. Near-infrared spectroscopy (NIRS) is a new, noninvasive method of estimating local tissue hemoglobin oxygen saturation by measuring the difference between oxyhemoglobin and deoxyhemoglobin and may have utility in diagnosing intestinal ischemia in NEC. Fortune et al. demonstrated cerebro-splanchnic oxygenation ratio < 0.75 to have a positive predictive value of 0.75 for intestinal ischemia, whereas, if above 0.75, intestinal ischemia is excluded with a negative predictive value of 0.96 [38].

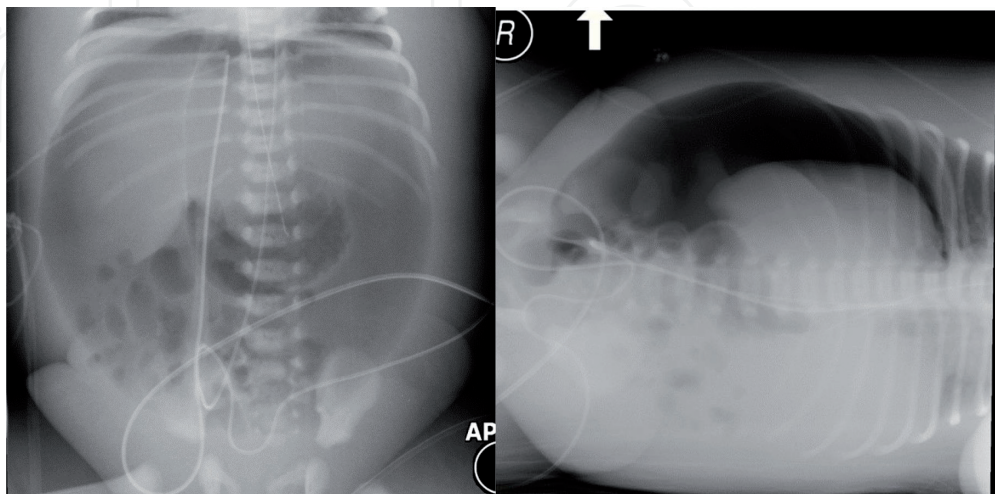


Figure 5.

On left: massive pneumoperitoneum with visualization of falciform ligament, massive lucency involving the entire abdomen, visualization of the liver margin. On right: left lateral decubitus radiograph demonstrating massive lucency with visualization of the liver margin and bowel. [Courtesy of Dr. Renu Aggarwal, Attending Neonatologist, NYU Winthrop Hospital, Mineola, NY, USA].

7.1 Differentiating medical and surgical NEC: use of biomarkers

Pneumoperitoneum is not a very reliable clinical feature for surgical NEC and is observed in less than half of all infants with intestinal perforation or necrosis [15, 39]. Clinical deterioration despite maximal medical therapy is considered a relative indication for surgical intervention. Research has been done to identify a dependable predictor for intestinal necrosis. The most commonly used biochemical markers for bowel necrosis among pediatric surgeons are platelet count (99%), C-reactive protein (CRP) concentration (90%), white blood cell count (83%), lactate levels (43%), fecal calprotectin 10%, and interleukin (IL)-6 or interleukin-8 10% [40]. Fecal calprotectin is a marker of intestinal inflammation and can differentiate between local Bell stage II and systemic Bell III NEC with 76% sensitivity and 92% specificity [41]. Fecal levels of another protein, S100A12, are noted to be higher in infants with suspected NEC who subsequently develop bowel perforation. Unremitting and relentlessly high CRP levels despite treatment may indicate advanced stage of NEC and bowel necrosis. IL-8 levels have been shown to be significantly elevated in patients developing surgical NEC compared to medically managed NEC [42]. The levels can also discriminate NEC totalis from focal and multifocal diseases and predict 60-day mortality [43]. Maximum concentration of CRP and duration of CRP elevation are increased in infants who developed intestinal strictures following NEC, while the negative predictive value of CRP levels <10 mg/dL for stricture development is 100% [44]. Intestinal fatty acid-binding protein (I-FABP), a marker of intestinal injury and progression to severe NEC, is located in mature enterocytes of small intestinal villi and is released into the blood stream after cell disruption and subsequently excreted into the urine. At onset of symptoms, I-FABP concentrations have been shown to be significantly higher in infants who later developed surgical NEC [45]. Other biomarkers being investigated for surgical NEC are serum amyloid A protein, liver fatty acid-binding protein, urine peptides, and heart rate characteristic index.

8. Differential diagnosis

Blood stream infection can present like NEC and must be ruled out. Sepsis and other conditions that can cause feeding intolerance, rectal bleeding, abdominal distension, gastric retention of feed, or intestinal perforation can be differentiated from NEC by the absence of radiologic evidence of pneumatosis intestinalis and the characteristic combination of rectal bleeding presenting as heme-positive or grossly bloody stools, abdominal distention, bilious vomiting, and gastric aspirates as seen in NEC. Spontaneous intestinal perforation is characterized by a single noninflammatory perforation that is typically located at the terminal ileum or colon. It occurs primarily in infants with birth weight <1000 g and is differentiated from NEC by the presence of less severe systemic signs and absence of pneumatosis intestinalis. Infectious enteritis may present with frequent, occasionally bloody stools with abdominal distension but no pneumatosis. Congenital anomalies of GIT, such as Hirschsprung disease, small bowel atresia, meconium ileus, and acquired conditions like volvulus and intussusception, present with intestinal obstruction and at times secondary enterocolitis. Abdominal radiography differentiates these conditions from NEC. Anal fissures can result in rectal bleeding and can be detected on pertinent thorough physical examination. Milk protein allergy-induced enterocolitis may present with heme-positive stools and other GI symptoms similar to NEC in preterm infants but no pneumatosis. Such patients respond to dietary modification by switching the formula to extensively hydrolyzed or amino acid-based ones and may have eosinophilia along with thrombocytosis.

9. Management

The basic principles of management of NEC are bowel decompression and rest, antibiotics coverage, cardiorespiratory support, fluid resuscitation, provision of blood products, and surgical intervention if indicated. The management strategies according to Bell's staging are outlined in **Table 4**. Surgical consultation is obtained in all stages of NEC including stage 1. Total parenteral nutrition (TPN) should be provided during the period that the infant is nil by mouth.

9.1 Medical management

The principles are as follows: (1) bowel decompression and rest, (2) parenteral hydration and nutrition, (3) respiratory and cardiovascular support, (4) antibiotic therapy, (5) general supportive care, (6) fluid resuscitation, and (7) serial close laboratory monitoring and radiologic surveillance. The focus is on limiting the progression of the disease. Intermittent or continuous nasogastric suction is done for bowel decompression, TPN is provided to ensure nutrition, and fluid is replaced to correct third space losses. Adequate cardiorespiratory support is of paramount value, and hematologic anomalies, such as DIC, anemia, and thrombocytopenia, are promptly corrected. Metabolic abnormalities, such as metabolic acidosis, hyponatremia, and hyper- or hypoglycemia, are appropriately treated. Even though an infectious agent has not been identified or attributed to NEC, antibiotics are routinely used in its treatment. Observational data reveal that 20–30% cases of NEC have bacteremia, and pathogenic bacteria are recovered from pathologic specimens and peritoneal fluid. Epidemic outbreaks of NEC are common, and the clinical picture improves with antibiotics. The efficacy of antibiotic agents is documented in experimental animal models for NEC. The commonly used empiric broad-spectrum antibiotic combinations are as follows: ampicillin gentamicin (or amikacin), ampicillin, gentamicin (or amikacin) and clindamycin or ampicillin, cefotaxime, and metronidazole. Ceftazidime is an alternative choice for cefotaxime. Other antibiotic combinations are tazobactam and gentamicin (or amikacin); vancomycin, piperacillin-tazobactam, and gentamicin; and meropenem and vancomycin if methicillin-resistant staphylococcus or ampicillin-resistant enterococcus infections are suspected. Amikacin may be used in centers with significant gentamicin resistance. Metronidazole or clindamycin is added to cover anaerobic bacteria, especially in cases where infant is fed orally before NEC supervenes.

Evaluation of progression of the disease is important in order to take appropriate and timely steps to avoid further damage to the bowel. Serial laboratory monitoring is routinely performed. At diagnosis stool for guaiac test, complete blood and differential neutrophil counts, blood culture, CSF study if indicated, C-reactive protein, platelet count, serum electrolytes, pH, creatinine, blood urea nitrogen, and acid-base studies are obtained and monitored q 12 or 24 h or more frequently

NEC Bell's stage	Treatment
1a and 1b	Antibiotics × 3 days, NPO
2a	NPO, antibiotics × 7–10 days
2b	NPO, antibiotics × 14 days
3a	As in 2b plus, fluid resuscitation, inotropic and ventilator support, blood products
3b	As in 3a plus surgery

Table 4.
Management principles of NEC [65].

if needed. In addition, arterial blood gas values are measured and repeated every 4–6–12 h as per the severity of respiratory decompensation. Serial lactate levels are helpful in monitoring progression of the necrotic process and assessing systemic status. Worsening or persistent metabolic acidosis and persistent hyperglycemia or thrombocytopenia are poor prognostic signs. Improvement in metabolic acidosis is a positive prognostic sign but may be misleading if blood circulation to the necrotic bowel is completely severed and the generated lactic acid cannot enter the circulation. Blood in stools is not predictive of resolution or outcome. Radiographic monitoring is done with abdominal radiograph performed in supine position during the initial phase of illness. A lateral decubitus view is simultaneously obtained with the infant's left side down to visualize the presence of free air over the liver. It should be repeated q 6–12 h as per the severity and progression of the disease and when improvement is obtained less frequently. In the initial stages q 4–6 h may be appropriate and advisable. Supine cross-table lateral view may be done to visualize layering of free air under umbilical area if patient is too sick to move or put in a decubitus position (**Figure 2**). Radiography is discontinued when pneumatosis resolves and bowel gas pattern normalizes.

9.2 Surgical management

The only definite indication for surgery is intestinal perforation. Other relative indications, which are highly suggestive of bowel perforation or necrosis, are abdominal mass, fixed dilated bowel loop, positive paracentesis, and severe metabolic acidosis that is unresponsive to treatment (**Figures 5 and 6**) [46]. Signs that indicate peritonitis or bowel necrosis are unremitting clinical deterioration, worsening or unrelenting metabolic acidosis, and DIC or thrombocytopenia. Signs of ascites and intestinal obstruction may be present. Perforation can occur without evidence of free air on the radiograph as the timing of study may not coincide with the occurrence of perforation and the free air may get absorbed. Likewise, pneumatosis may not be always caught on serial X-rays. Under such conditions other signs and clinical judgment should be used to assess the severity and need for surgery. As clinical parameters may not be reliable to assess progression to surgical from medical NEC, abnormalities in biochemical markers, such as platelet count, CRP, WBC count, blood lactate, fecal calprotectin, and serum IL-6 and IL-8 may be used. Surgical procedures performed in cases of NEC are exploratory laparotomy with resection of the affected intestinal region or primary peritoneal drainage (PPD). PPD is preferred as the initial procedure in ELBW infants and is performed in the NICU at bedside with analgesia and local anesthesia. Laparotomy is done in an operating room under general anesthesia and may require a second surgical procedure for reanastomosis.

In primary peritoneal drainage abdomen is prepped with iodine solution, and local anesthesia is administered. Small transverse incision is made at McBurney's point and abdominal wall layers bluntly dissected to enter the peritoneal cavity. A rush of air and the presence of meconium are generally encountered. Cultures are obtained, and then peritoneal cavity is copiously irrigated with warm saline solution. Following this Penrose drain is gently threaded into the abdomen and secured. The drain site is observed over the subsequent days. When there is no intestinal or meconium drainage, the drain is backed out daily until removed. After the return of bowel function, a trial of feeding can be started, or the patency of the gastrointestinal tract may be determined with a contrast study. In laparotomy the procedure includes resection of the affected bowel segment and placement of a proximal enterostomy (usually an ileostomy) and distal mucous fistula. Primary reanastomosis, if required, usually is performed 8–12 weeks after the initial procedure, depending

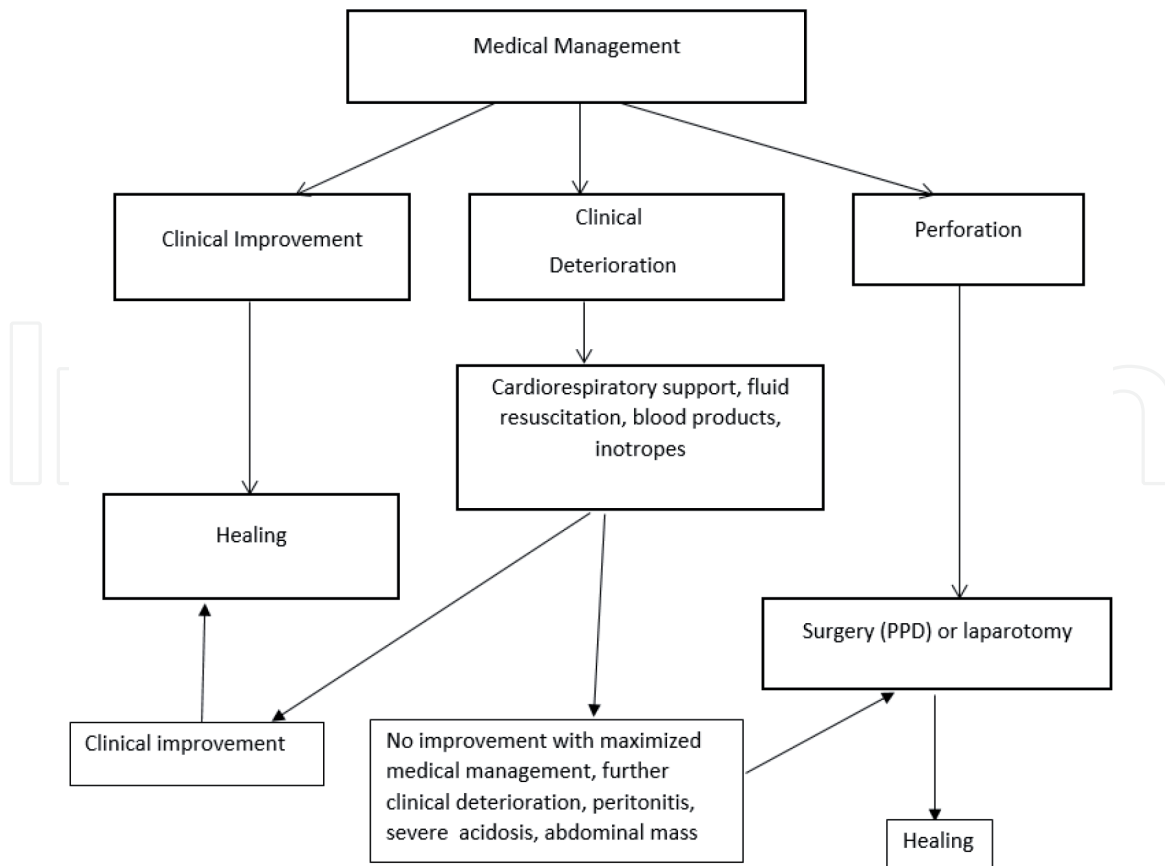


Figure 6.
Flow chart outlining management principles in NEC.

upon the infant's clinical condition. A contrast enema usually is performed before the reanastomosis to detect intestinal strictures. If NEC affects only a short segment of bowel, and the resection is limited, some surgeons perform a primary anastomosis. Complications associated with ileostomies are fluid and electrolyte abnormalities, delayed resumption of oral feedings, poor growth, and stenosis of the enterostomy site. An alternative approach is placement of an intestinal patch and peritoneal drain instead of resection and enterostomy. Preservation of ileocecal valve is a favorable prognostic sign. When a substantial length of bowel is affected, resection is restricted to segments of definite necrosis or perforation to avoid the risk of short bowel syndrome. If the potential viability of some segments is uncertain, one approach is to place peritoneal drains and plan a second operation in 2–3 days to reexamine the bowel and excise necrotic segments.

Recently, standard and fluorescein laparoscopy has been used in cases of NEC when there is no evidence of perforation, but clinical deterioration with maximum support continues, and a diagnosis for the presence and extent of bowel necrosis needs to be made in order to decide against, or in favor of, surgical exploration and its type [47]. Laparoscopy can also identify infants who do not need surgical intervention as it can visualize the viability and perfusion status of the bowel. According to a Cochrane review by Smith and Thyoka, which included eight reports and 44 patients, laparoscopy was able to diagnose NEC in 91% of the cases and exclude in 9% [48]. Moreover, additional surgical intervention was avoided in eight (18%) infants. Among those who did not require surgery, NEC was excluded in four (9%), while two (5%) had no perforation or intestinal gangrene, and two (5%) had NEC totalis which contraindicated surgery. Thirty-six infants out of 44 required surgery following laparoscopy, which included placement of a peritoneal drain (9) or a stoma (20) and intestinal resection and anastomosis (7). Perforation was detected in 25 out of 44 (57%) infants and was missed in one case which subsequently

required laparotomy. Six (14%) infants died due to NEC totalis and two of ongoing and recurrent NEC following recovery from the acute episode of each. The authors concluded that laparoscopy is a useful procedure in the management of NEC, with one-fifth of patients not requiring further surgery. However, due to the lack of enough evidence about its utility and benefits, the procedure is generally not undertaken in the routine management of NEC.

9.3 Comparison of laparotomy and PPD

There are limited data about the superiority of one procedure over other. In a multicenter controlled study, 117 infants who were <34 weeks of gestation with perforated NEC were randomized to PPD or laparotomy. No differences were noted in mortality (34.5 versus 35.5%), TPN dependence on postoperative day 90 (47.2 versus 40%), and length of hospital stay (126 ± 58 versus 116 ± 56 days) [49]. A subgroup analysis of cases with extensive pneumatosis intestinalis, GA less than 25 weeks, and serum pH less than 7.30 at presentation showed no significant advantage of one procedure over the other. In another randomized multicenter trial of 69 extremely low birth weight (ELBW) infants with NEC or SIP, no difference in the survival rates was noted between the two interventions, while 74% treated with PPD subsequently required laparotomy [50]. A cohort study from the NICHD neonatal research group reported no difference in mortality rate, and 24% treated with PPD required subsequent laparotomy. Blakely et al. reported that PPD is more likely to result in a composite outcome of death or neurodevelopmental impairment at 18–22 months postmenstrual age [51]. However in their study, PPD was performed in infants who were more premature (gestational age 24.7 versus 25.7 weeks), were more likely to be hypotensive, required higher respiratory support, and were more likely to have a pre-operative diagnosis of SIP. Most of these studies are compromised by a lack of power.

9.4 Post-surgery intestinal failure and short bowel syndrome

About 9% of NEC cases result in short bowel syndrome (SBS) with incidence inversely related to GA and almost 42% in intestinal failure and SBS [52, 53]. Such infants suffer from significant malabsorption and are at risk for sepsis, cholestasis, and liver failure due to prolonged parenteral nutrition (PN). It is suggested that infants with residual small bowel length $\leq 10\%$ of expected small bowel length may develop SBS. The cumulative probability of weaning from PN by 24 months is 96% in infants with >50 cm of residual small bowel compared to 38% in those who have <50 cm of residual small bowel. Those with ≥ 41 cm of residual bowel are significantly more likely to achieve enteral autonomy than those with less than 41 cm [53]. In general, those with post-resection length of remaining bowel less than 25% of the normal small bowel length have higher chances of developing SBS. The length of remaining bowel, however, is not the sole or best predictor of SBS. Infants at risk of SBS are as follows: parenteral antibiotics or mechanical ventilation on the day of onset of NEC, birth weight less than 750 g, enteral nutrition before the diagnosis of NEC, percentage of bowel resected, and placement and duration of a diverting jejunostomy. The intestines continue to grow after resection and contribute to the process of attaining enteral autonomy.

9.5 Surgical procedures for short bowel syndrome

In a NICHD cohort, 95% of cases of SBS were due to NEC with an overall incidence of 0.7% of infants <1500 g at birth [52]. Approximately 42% of cases of NEC in infants <1500 g of BW who undergo surgery develop intestinal failure and SBS,

risk factors being lower birth weight, antibiotics use, positive pressure ventilation on the day of NEC, feeding, and lower post-resection length of remaining bowel [53]. Intestinal tailoring and lengthening procedure, also called “autologous intestinal reconstruction surgery” are performed in conditions where likelihood of weaning from PN is low despite rigorous intestinal rehabilitation measures. The criteria for surgery, tentative and not well supported by studies, include dilated small intestine, failure to attain intestinal autonomy, and absence of liver failure and GI dysmotility. The procedures aim at surgical lengthening of the bowel to increase the absorptive area and tapering or plicating the dilated bowel to improve motility. There is not enough literature on the subject to assess its clinical advantage. Bianchi procedure is a longitudinal intestinal lengthening and tailoring procedure (LILT) and may be successful in improving absorption and nutritional status but requires multiple anastomoses. Complications of this procedure include fistula formation, anastomotic stenosis, or leakage and sepsis [54]. The 6-year survival rate is 45%, and survivors have residual bowel length greater than 40 cm and no liver disease. The Bianchi procedure is not recommended in neonates with liver disease or intestine length less than 50 cm. The serial transverse enteroplasty procedure (STEP) is a substitute for LILT which increases the girth of bowel. It has a simpler technique that does not need bowel anastomoses, and the tapering can be performed on dilated bowel. STEP increases intestinal length, improves intestinal absorptive capacity, and may decrease the risk of D-lactic acidosis due to bacterial overgrowth. STEP is more favored over other techniques as the weaning from parenteral nutrition is faster and the need for later transplants lesser. There is no difference in early complications, growth rates, or survival between the two procedures, and nearly half of patients operated achieve enteral autonomy, with the median time to wean from parenteral nutrition (PN) being 21 months postoperatively. Patients whose bowel re-dilates after a lengthening procedure have worse overall outcomes. Complications of STEP include gastrointestinal bleeding, staple line leak, hematoma, abscess formation, stricture, pleural effusion, obstruction, a need for transplantation, and even death. In a recent publication, the rate of independence from PN post-STEP was reported as 58% with parenteral calories decreasing from 71 to 36% within 1 month and to 12% after 1 year. The total increase in intestinal length achieved was about 49% [54].

Small bowel transplantation (SBT) may be considered in patients who have progressive, severe, or irreversible intestinal failure with associated liver disease. Other considerations might be a lack of venous access, recurrent life-threatening central venous catheter-associated sepsis, complete mesenteric thrombosis, slow growing tumors of the hepatic hilum or root of mesentery, or extremely short residual bowel with no chance of achieving enteral autonomy in patients who prefer transplantation over lifelong PN dependence [54]. Small bowel transplantation has a 5-year graft survival rate of 48% with lifelong immunosuppressant medications. Types of transplantation include isolated intestine, isolated liver, combined liver and intestine, and multi-visceral. Complications are rejection, infection, graft-versus-host disease, and posttransplant lymphoproliferative disease. Overall, one year patient and intestine graft survival is 89%, being 79% in intestine and 72% in liver-intestine graft recipients. Patient and intestine graft survival falls to 46% by 10 years. At 10 years the survival of intestine only recipients is 29%, whereas, that of liver-intestine recipients 39-42%. More recently, living donor intestinal transplantation has been done successfully in pediatric patients which eliminates waiting time.

9.6 Intestinal rehabilitation

This requires a multidisciplinary approach. The focus is on optimizing enteral feeding and weaning from PN with judicious use of pharmacotherapy and surgical

interventions. The approach is associated with improved survival and achievement of independence from PN.

10. Complications

The acute complications of NEC are sepsis, meningitis, peritonitis, intraabdominal abscess formation, DIC, thrombocytopenia, hypotension, shock, respiratory failure, metabolic or combined acidosis, hyponatremia, hyperglycemia, or less often hypoglycemia. Late complications are stricture formation, short bowel syndrome, and intestinal failure [55]. Rarely enterocele, enterocolic fistula, and intraabdominal abscess formation may be encountered. About 24% (95% CI 17–31%) of infants treated medically or surgically develop strictures in bowel which is unrelated to the severity of NEC or gestational age. The commonest location is in the colon, followed by the ileum and jejunum. Multiple sites strictures are seen. It can appear within 2 to 3 months of the acute episode and as late as 20 months. Stricture may lead to local bacterial overgrowth resulting in repeated infections, bloody stools, failure to thrive, and symptoms of bowel obstruction. Strictures are more common following enterostomy; therefore contrast enemas should be performed 4–6 weeks after the occurrence of NEC and prior to surgical closure of enterostomy with reanastomosis or if and when feeding intolerance develops. Recurrent NEC may occur in 8% and adhesion ileus in 6% cases of NEC. Overall intestinal failure happens in 13% of all cases of NEC, inclusive of medically and surgically treated infants.

11. Long-term outcomes

Approximately half of all cases of NEC display no long-term sequelae. This includes cases of stage I NEC from Bell's criteria. NEC is associated with significant impairment of growth and neurodevelopment [56–58]. Ten to thirteen percent of patients suffer from late gastrointestinal morbidity if resection is performed. Majority of infants who have had no extensive intestinal resection have normal gastrointestinal function at 1–10 years of age.

11.1 Growth and neurodevelopment

In a large multicenter study from the National Institute of Child Health and Human Development (NICHD) Neonatal Research Network, extremely low birth weight (ELBW) infants (BW <1000 g) who required surgical care were more likely to have significant growth delay and poorer developmental outcome at 18–22 months compared with infants without NEC [56]. ELBW treated medically or surgically suffer from significant growth failure until 22 months, and in a lesser percentage beyond that age [57], while those who were medically treated do not differ in growth or developmental testing compared with those without NEC [58]. Infants with NEC are at increased risk for cerebral palsy and cognitive and severe visual impairment. At 7 years of age, survivors with NEC compared to controls demonstrate a higher rate of neurologic functional impairment.

11.2 Mortality

Overall survival in cases with NEC is 70–80%, being >95% in medical and 70–75% in surgical NEC [59]. Lower BW and GA and surgical intervention, such as laparotomy and peritoneal drainage, are independent predictors for mortality.

Other risk factors associated with death from NEC are mechanical ventilation, treatment with vasopressor agents, surgical intervention, and black ethnicity as per a retrospective multicenter review of data [60]. Two thirds of NEC deaths occur within 7 days of diagnosis, with a median time of death being 1 day from the day of onset. Infants who die within 7 days of diagnosis have higher BW, and more often they are on vasopressors and high-frequency ventilation at the time of diagnosis. Risk factors for fulminant NEC, defined as death within 48 h of onset, are presence of portal venous air, increase in feeding volume by >20 mL/kg per day, HCT <22%, I/T ratio > 0.5, and total lymphocyte count <4000/ μ L as demonstrated in a multicenter study [61].

11.3 Financial burden of NEC

The average total treatment cost of one case of NEC is US \$500,000 [62, 63]. Total annual estimated cost of care of NEC in the United States is between \$500 million and \$1 billion. Infants with NEC are hospitalized for 60 days longer than unaffected preterm infants if surgery is performed and >20 days longer if surgery is not required. Bowel resection—one of the most severe complications of NEC—is the major cause of short bowel syndrome in pediatric patients, making 95% of all such cases. The total mean cost of care over a 5-year period for a child with the short bowel syndrome has been estimated to be nearly \$1.5 million.

12. Prevention

Prevention is the primary strategy in this devastating disease with undetermined etiology. Breast milk feeding, prolonging gestation to avoid prematurity, antenatal steroid, and the use of probiotics/prebiotics are established prevention strategies in NEC [16]. Nonaggressive feeding is evidenced to be efficacious. The rate of advancement of feeding under 20 ml/kg/day is considered to be safe. Newer strategies, such as use of toll-like receptor agonist, glutamine, n-3 fatty acids, anti-cytokines, and growth factors are proposed preventive interventions, but most of these either lack evidence or have questionable safety. Compound CpG-DNA inhibit TLR4 signaling, thereby dramatically reducing the severity of NEC in mice. Clinically, the following measures are suggested to be practiced in order to reduce the risk of NEC: human milk (both mother's and donor's); standardized feeding guidelines, including early initiation with trophic feeds; the use of probiotics; antibiotic stewardship; optimization of enteral nutrition and growth; elimination of H2 blockers and acid pump suppressors; elimination of cow's milk products; transfusion protocols; and transfusion outcome monitoring. Avoidance of hyperosmolar agents, treatment of polycythemia, and delayed cord clamping are other interventions that are suggested to be followed. Prophylactic probiotics, although not yet universally applied due to uncertainties about its dose and duration of therapy, have been documented to reduce the incidence of NEC, especially that of severe cases (RR 0.75 95% CI -0.57 to 0.92) in infants <1500 g in multiple studies [64]. There are concerns about bacteremia and some aspects of quality control which restrict its use.

13. Future directions

NEC remains a major unsolved medical challenge for which no specific therapy exists. Recent research is concentrated on the role of TLR4 signaling within the intestinal epithelium and intestinal stem cells and modulation of the genetics and

intestinal microbiome. Fecal microbiota transplantation (FMT) has been shown to reverse the severity of experimental necrotizing enterocolitis (NEC) via oxidative stress modulation [65]. FMT decreases the extent of TLR4-mediated pro-inflammatory signaling through TLR9 in the intestinal mucosa tissue. FMT also suppresses intestinal apoptosis and bacterial translocation across the intestinal barrier, which is accompanied by decreased inflammatory cytokine levels, altered bacterial microbiota, and regulated lymphocyte proportions. Research is needed to determine if the use of biomarkers along with specific clinical-biochemical indicators could lead to earlier intervention with modalities, such as peritoneal drainage or laparotomy that might decrease the severity of the disease process, thereby improving the long-term neurodevelopmental and growth outcomes. Improved care of short bowel syndrome with new surgical and medical approaches are additional subject for investigation. Tissue engineering techniques and techniques involving intestinal stem cells may represent unique, novel strategies for intestinal failure after severe NEC in the future.

IntechOpen

Author details

Rita Prasad Verma* and Archana Kota
Department of Pediatrics, Nassau University Medical Center, East Meadow,
NY, USA

*Address all correspondence to: rverma2@numc.edu

IntechOpen

© 2019 The Author(s). Licensee IntechOpen. This chapter is distributed under the terms of the Creative Commons Attribution License (<http://creativecommons.org/licenses/by/3.0>), which permits unrestricted use, distribution, and reproduction in any medium, provided the original work is properly cited. 

References

- [1] Yee WH, Soraisham AS, Shah VS, et al. Incidence and timing of presentation of necrotizing enterocolitis in preterm infants. *Pediatrics*. 2012;**129**(2):e298-e304. DOI: 10.1542/peds.2011-2022
- [2] Stoll BJ, Hansen NI, Bell EF, et al. Trends in care practices, morbidity, and mortality of extremely preterm neonates, 1993-2012. *JAMA*. 2015;**314**:1039
- [3] Niño DF, Sodhi CP, Hackam DJ. Necrotizing enterocolitis: New insights into pathogenesis and mechanisms. *Nature Reviews. Gastroenterology & Hepatology*. 2016;**13**:590
- [4] Sharma R, Tepas JJ 3rd, Hudak ML, et al. Neonatal gut barrier and multiple organ failure: Role of endotoxin and proinflammatory cytokines in sepsis and necrotizing enterocolitis. *Journal of Pediatric Surgery*. 2007;**42**(3):454-461
- [5] Holman RC, Stoll BJ, Curns AT, et al. Necrotising enterocolitis hospitalisations among neonates in the United States. *Paediatric and Perinatal Epidemiology*. 2006;**20**:498
- [6] Battersby B, Santhalingam T, Costeloe K, Modi N. Incidence of neonatal necrotising enterocolitis in high-income countries: A systematic review. *Archives of Disease in Childhood: Fetal & Neonatal*. 2018;**103**:F182-F189. DOI: 10.1136/archdischild-2017-313880
- [7] Rees CM, Eaton S, Pierro A. National prospective surveillance study of necrotizing enterocolitis in neonatal intensive care units. *Journal of Pediatric Surgery*. 2010;**45**:1391-1397
- [8] Henry MC, Moss LR. Surgical therapy for necrotizing enterocolitis: Bringing evidence to the bedside. *Seminars in Pediatric Surgery*. 2005;**14**:181-190
- [9] Guillet R, Stoll BJ, Cotten CM, et al. Association of H2-blocker therapy and higher incidence of necrotizing enterocolitis in very low birth weight infants. *Pediatrics*. 2006;**117**:e137-e142
- [10] Stoll BJ, Hansen NI, Bell EF, et al. Neonatal outcomes of extremely preterm infants from the NICHD Neonatal Research Network. *Pediatrics*. 2010;**126**:443-456
- [11] Lin HC, Wu SF, Underwood M. Necrotizing enterocolitis. *The New England Journal of Medicine*. 2011;**364**:1878-1879
- [12] Fanaroff AA, Stoll BJ, Wright LL, Carlo WA, Ehrenkranz RA, Stark AR, et al. Trends in neonatal morbidity and mortality for very low birthweight infants. *American Journal of Obstetrics and Gynecology*. 2007;**196**(2):147
- [13] Hull MA, Fisher JG, Gutierrez IM, Jones BA, Kang KH, Kenny M, et al. Mortality and management of surgical necrotizing enterocolitis in very low birth weight neonates: A prospective cohort study. *Journal of the American College of Surgeons*. 2014;**18**(6):1148-1155
- [14] Reese CM, Pierro A, Eaton S. Neurodevelopmental outcomes of neonates with medically and surgically treated necrotizing enterocolitis. *Archives of Disease in Childhood: Fetal and Neonatal Edition*. 2007;**92**(3):F193-F198
- [15] Robinson JR, Rellinger EJ, Hatch LD, Weitkamp J, Speck E, Danko M, et al. Surgical necrotizing enterocolitis. *Seminars in Perinatology*. 2017;**41**(1):70-79
- [16] Patel AL, Panagos PG, Silvestri JM. Reducing incidence of necrotizing enterocolitis. *Clinics in Perinatology*. 2017;**44**:683-700

- [17] Uauy RD, Fanaroff AA, Korones SB, et al. Necrotizing enterocolitis in very low birth weight infants: Biodemographic and clinical correlates. National Institute of Child Health and Human Development Neonatal Research Network. *Journal of Pediatrics*. 1991;**119**:630
- [18] Berseth CL. Feeding strategies and necrotizing enterocolitis. *Current Opinion in Pediatrics*. 2005;**17**:170
- [19] Gephart SM, Spitzer AR, Effken JA, Dodd E, Halpern M, McGrath JM. Discrimination of GutCheck (NEC): A clinical risk index for necrotizing enterocolitis. *Journal of Perinatology*. 2014;**34**(6):468-475
- [20] Lambert DK, Christensen RD, Henry E, et al. Necrotizing enterocolitis in term neonates: Data from a multihospital health-care system. *Journal of Perinatology*. 2007;**27**:437-443
- [21] Neu J. The 'myth' of asphyxia and hypoxia-ischemia as primary causes of necrotizing enterocolitis. *Biology of the Neonate*. 2005;**87**:97-98
- [22] Liu Z, Li N, Neu J. Tight junctions, leaky intestines, and pediatric diseases. *Acta Paediatrica*. 2005;**94**(4):386-393
- [23] Neu J, Walker WA. Necrotizing enterocolitis. *The New England Journal of Medicine*. 2011;**364**(3):255-264
- [24] Ballance WA, Dahms BB, Shenker N, Kliegman RM. Pathology of neonatal necrotizing enterocolitis: A ten year experience. *The Journal of Pediatrics*. 1990;**117**:S6-S13
- [25] Frost BL, Modi BP, Jaksic T, Caplan MS. New medical and surgical insights into neonatal necrotizing enterocolitis: A review. *JAMA Pediatrics*. 2017;**171**(1):83-88
- [26] Treszl A, Tulassay T, Vasarhelyi B. Genetic basis for necrotizing enterocolitis—Risk factors and their relations to genetic polymorphisms. *Frontiers in Bioscience*. 2006;**11**(2006):570-580
- [27] Sharma R, Young C, Neu J. Molecular modulation of intestinal epithelial barrier: Contribution of microbiota. *Journal of Biomedicine & Biotechnology*. 2010:305879. DOI: 10.1155/2010/305879. [Epub 2010 Jan 31]
- [28] Lin PW, Nasr TR, Stoll BJ. Necrotizing enterocolitis: Recent scientific advances in pathophysiology and prevention. *Seminars in Perinatology*. 2008;**32**(2):70-82
- [29] Hunter CJ, Upperman JS, Ford HR, Camerini V. Understanding the susceptibility of the premature infant to necrotizing enterocolitis (NEC). *Pediatric Research*. 2008;**63**:117-123
- [30] Denning TL, Bhatia AM, Kane AF, et al. Pathogenesis of NEC: Role of the innate and adaptive immune response. *Seminars in Perinatology*. 2017;**41**:15-28
- [31] Tanner SM, Berryhill TF, Eelenburg JL, et al. Pathogenesis of NEC: Modelling the innate immune response. *American Journal of Pathology*. 2015;**185**(1):4-16
- [32] Maheshwari A, Schelonka RL, Dimmitt RA, et al. Cytokines associated with necrotizing enterocolitis in extremely-low-birth-weight infants. *Pediatric Research*. 2014;**76**(1):100-108
- [33] Sodhi CP et al. Toll-like receptor-4 inhibits enterocyte proliferation via impaired β -catenin signaling in necrotizing enterocolitis. *Gastroenterology*. 2010;**138**:185-196
- [34] Lu P, Sodhi CP, Hackam DJ. Toll-like receptor regulation of intestinal development and inflammation in the pathogenesis of necrotizing enterocolitis. *Pathophysiology*. 2014;**21**:81-93

- [35] Yazji I et al. Endothelial TLR4 activation impairs intestinal microcirculatory perfusion in necrotizing enterocolitis via eNOS-NO-nitrite signaling. *Proceedings of the National Academy of Sciences of the United States of America*. 2013;**110**:9451-9456
- [36] Ostlie DJ, Spilde TL, St Peter SD, et al. Necrotizing enterocolitis in full-term infants. *Journal of Pediatric Surgery*. 2003;**38**:1039-1042
- [37] Walsh MC, Kliegman RM. Necrotizing enterocolitis: Treatment based on staging criteria. *Pediatric Clinics of North America*. 1986;**33**:179-201
- [38] Fortune PM, Wagstaff M, Petros AJ. Cerebro-splanchnic oxygenation ratio (CSOR) using near infrared spectroscopy may be able to predict splanchnic ischaemia in neonates. *Intensive Care Medicine*. 2001;**27**:1401-1407
- [39] Munaco AJ, Veenstra MA, Brownie E, Danielson LA, Nagappala KB, Klein MD. Timing of optimal surgical intervention for neonates with necrotizing enterocolitis. *The American Surgeon*. 2015;**81**:438-443
- [40] Zani A, Eaton S, Puri P, et al. International survey on the management of necrotizing enterocolitis. *European Journal of Pediatric Surgery*. 2015;**25**:27-33
- [41] Aydemir O, Aydemir C, Sarikabadayi YU, et al. Fecal calprotectin levels are increased in infants with necrotizing enterocolitis. *The Journal of Maternal-Fetal & Neonatal Medicine*. 2012;**25**:2237-2241
- [42] Benkoe T, Reck C, Gleiss A, et al. Interleukin 8 correlates with intestinal involvement in surgically treated infants with necrotizing enterocolitis. *Journal of Pediatric Surgery*. 2012;**47**:1548-1554
- [43] Benkoe T, Reck C, Pones M, et al. Interleukin-8 predicts 60-day mortality in premature infants with necrotizing enterocolitis. *Journal of Pediatric Surgery*. 2014;**49**:385-389
- [44] Gaudin A, Farnoux C, Bonnard A, et al. Necrotizing enterocolitis (NEC) and the risk of intestinal stricture: The value of C-reactive protein. *PLoS One*. 2013;**8**:e76858
- [45] Guthmann F, Borchers T, Wolfrum C, Wustrack T, Bartholomaeus S, Spener F. Plasma concentration of intestinal- and liver-FABP in neonates suffering from necrotizing enterocolitis and in healthy preterm neonates. *Molecular and Cellular Biochemistry*. 2002;**239**:227-234
- [46] Tepas JJ 3rd, Sharma R, Leapheart CL, Celso BG, Pieper P, Esquivia-Lee V. Timing of surgical intervention in necrotizing enterocolitis can be determined by trajectory of metabolic derangement. *Journal of Pediatric Surgery*. 2010;**45**:310-313
- [47] Lacher M, Kuebler FK, Dingemann J, Ure BM. Minimal invasive surgery in the newborn: Current status and evidence. *Seminars in Pediatric Surgery*. 2014;**23**:249-256
- [48] Smith J, Thyoka M. What role does laparoscopy play in the diagnosis and immediate treatment of infants with necrotizing enterocolitis? *Journal of Laparoendoscopic & Advanced Surgical Techniques*. 2013;**4**:397-401
- [49] Rao SC, Basani L, Simmer K, Samnakay N, Deshpande G. Peritoneal drainage versus laparotomy as initial surgical treatment for perforated necrotizing enterocolitis or spontaneous intestinal perforation in preterm low birth weight infants. *Cochrane Database of Systematic Reviews*. 2011;**6**:CD006182. DOI: 10.1002/14651858.CD006182.pub2

- [50] Rees CM, Eaton S, Kiely EM, et al. Peritoneal drainage or laparotomy for neonatal bowel perforation? A randomized controlled trial. *Annals of Surgery*. 2008;**248**:444-491
- [51] Blakely ML, Tyson JE, Lally KP, et al. Laparotomy versus peritoneal drainage for necrotizing enterocolitis or isolated intestinal perforation in extremely low birth weight infants: Outcomes through 18 months adjusted age. *Pediatrics*. 2006;**117**:e680
- [52] Cole CR, Hansen NI, Higgins RD, Ziegler TR, Stoll BJ. Very low birth weight preterm infants with surgical short bowel syndrome: Incidence, morbidity and mortality, and growth outcomes at 18 to 22 months. *Pediatrics*. 2008;**122**:e573-e582
- [53] Duro D, Kalish LA, Johnston P, et al. Risk factors for intestinal failure in infants with necrotizing enterocolitis: A Glaser Pediatric Research Network study. *Journal of Pediatrics*. 2010;**157**(2):203-208.e1
- [54] Amin SC, Pappas C, Iyengar H, Maheshwari A. Short bowel syndrome in the NICU. *Clinics in Perinatology*. 2013;**40**(1):53-68
- [55] Schwartz MZ, Richardson CJ, Hayden CK, et al. Intestinal stenosis following successful medical management of necrotizing enterocolitis. *Journal of Pediatric Surgery*. 1980;**15**:890
- [56] Hintz SR, Kendrick DE, Stoll BJ, et al. Neurodevelopmental and growth outcomes of extremely low birth weight infants after necrotizing enterocolitis. *Pediatrics*. 2005;**115**:696
- [57] Hong CR, Fullerton BS, Mercier CE, et al. Growth morbidity in extremely low birth weight survivors of necrotizing enterocolitis at discharge and two-year follow-up. *Journal of Pediatric Surgery*. 2018;**53**:1197-1202
- [58] Schulzke SM, Deshpande GC, Patole SK. Neurodevelopmental outcomes of very low-birth-weight infants with necrotizing enterocolitis: A systematic review of observational studies. *Archives of Pediatrics & Adolescent Medicine*. 2007;**161**:583
- [59] Fitzgibbons SC, Ching Y, Yu D, et al. Mortality of necrotizing enterocolitis expressed by birth weight categories. *Journal of Pediatric Surgery*. 2009;**44**:1072-1075
- [60] Clark RH, Gordon P, Walker WM, Laughon M, Smith PB, Spitzer AR. Characteristics of patients who die of necrotizing enterocolitis. *Journal of Perinatology*. 2011;**32**(3):199-204
- [61] Lambert DK, Christensen RD, Baer VL, et al. Fulminant necrotizing enterocolitis in a multihospital healthcare system. *Journal of Perinatology*. 2012;**32**:194
- [62] Stey A et al. Outcomes and costs of surgical treatments of necrotizing enterocolitis. *Pediatrics*. 2015;**135**:e1190-e1197
- [63] Bisquera JA, Cooper TR, Berseth CL. Impact of necrotizing enterocolitis on length of stay and hospital charges in very low birth weight infants. *Pediatrics*. 2002;**109**:423-428
- [64] Thomas JP, Raine T, Reddy S, Belteki G. Probiotics for the prevention of necrotising enterocolitis in very low-birth-weight infants: a meta-analysis and systematic review. *Acta Paediatr* 2017;**106**:1729-1741
- [65] Li X, Li X, Shang Q, Gao Z, Hao F, Guo H, et al. Fecal microbiota transplantation (FMT) could reverse the severity of experimental necrotizing enterocolitis (NEC) via oxidative stress modulation. *Free Radical Biology & Medicine*. 2017;**108**:32-43