

We are IntechOpen, the world's leading publisher of Open Access books Built by scientists, for scientists

4,800

Open access books available

122,000

International authors and editors

135M

Downloads

Our authors are among the

154

Countries delivered to

TOP 1%

most cited scientists

12.2%

Contributors from top 500 universities



WEB OF SCIENCE™

Selection of our books indexed in the Book Citation Index
in Web of Science™ Core Collection (BKCI)

Interested in publishing with us?
Contact book.department@intechopen.com

Numbers displayed above are based on latest data collected.

For more information visit www.intechopen.com



The Use of Phototherapy in Treatment of Geographic Tongue in Patients with Psoriasis

Fernanda Mombrini Pigatti,

Fabiana de Freitas Bombarda-Nunes,

Lucas Fernandes Leal and Thays Teixeira de Souza

Abstract

Psoriasis is an autoimmune inflammatory skin disease associated with an oral condition called benign migratory glossitis (geographical tongue). A series of light/laser with different mechanisms of action has been widely used in the last decades to treat skin psoriasis lesions. For this, the effects of phototherapy require the correct indication of the sources and parameters of light/laser in the management of different psoriatic lesions. The objective of this chapter is to update clinical knowledge on how to select light/laser sources and individual therapeutic regimens in benign migratory glossitis.

Keywords: psoriasis, glossitis, benign migratory, therapeutics, phototherapy, lasers

1. Introduction

Benign migratory glossitis is a pathological condition referred to in literature as geographic tongue, annulus migrans, erythema migrans, benign wandering glossitis, exfoliatio areata linguae, or transitory benign plaque of the tongue [1–3]. It is an asymptomatic inflammatory disorder of unknown etiology considered as a normal variant rather than an injury. Many authors classify this injury as a congenital anomaly, an inflammatory reaction, or an oral symptom of systemic psoriasis [1, 2].

Geographic tongue (GT) often affects the dorsum and sometimes the lateral borders of the tongue. Clinically it manifests as multifocal reddish areas with asymmetric distribution well demarcated by slightly elevated whitish edges. The erythematous zones occur due to the atrophy of the filiform papillae and, consequently, the narrowing of the epithelium [1, 3].

Most cases are asymptomatic and do not require treatment. It is only necessary to assure the patient that it is a benign and self-limiting lesion. Symptomatic cases include symptoms such as burning and burning sensation that may compromise quality of life. However, there is no consensus in the literature regarding the best treatment [1, 2, 4].

In ancient Egypt, approximately 3500 years ago, the use of sunlight was started in the treatment of cutaneous diseases, being used alone or in combination with

some plant extract. However, sunlight on the tissues remained unexplored for a long time, and only after the emergence of the lasers, a new impulse was given to the interaction of radiation with matter, due to its properties of coherence, collimation, and monochromaticity. Stimulated emission was first described in 1917 by Einstein in a theoretical manner [5].

In recent years, low-level light/laser therapy (LLLT) has been widely applied in dermatology.

LLLT is also called “cold laser,” which involves ultraviolet, visible, and near infrared with much lower energy densities than those lasers used for ablation, cutting, and thermally coagulating tissues. Many types of phototherapy have been developed and used for the treatment of psoriasis over the last few decades. In 1923, Goeckerman used a high-pressure mercury lamp to produce broadband artificial UV-B and coal tar to treat psoriasis. The treatment with energy from different types of light has been improved in the skin lesions of patients with psoriasis, now being used in the geographic tongue. Because of its ability of stronger penetration and potential photobiomodulation, LLLT has a promising expectation in treatment of GT [6–8].

When patients with GT were treated sequentially LLLT, there was a significant reduction in pain. Improvement in clinical signs is estimated in 60–100% of the lesions. This finding is similar with outcomes in other oral lesions regarding the analgesic effect of low-level laser therapy based on biostimulation [9, 10].

2. Psoriasis and geographic tongue

2.1 Etiology

Geographic tongue (GT) is a chronic oral lesion, immunologically mediated and with unknown etiology. It affects between 0.6 and 4.8% of the world population, occurring more often in children, with a slight preference for females. It is characterized by serpiginous white areas around the depapillated mucosa. Remission and reactivation in diverse locations originated the denomination benign migratory glossitis [4, 11–14].

Psoriasis is a chronic skin-articular disease, with genetic and immunological basis and with great importance in clinical practice. Psoriasis occurs in approximately 1–3% of the world population, affecting white individuals of both sexes. Despite its unknown etiology, it is known that there is a defect in the normal developmental cycle of the epidermis, from a disorder in the proliferation and differentiation of keratinocytes associated with inflammatory and vascular alterations. Psoriatic lesions can be localized or diffuse and affect almost the entire extent of the skin with an unpredictable clinical course [8, 15–17].

GT is the most frequent oral manifestation in patients with psoriasis. In addition to clinical and histological similarity, both disorders present the human leukocyte antigen HLA-Cw6 (HLA) as a common genetic marker. However, it is difficult to state that the geographic tongue represents oral psoriasis since some non-psoriatic patients present this oral lesion [18, 19].

Some authors suggest that GT may represent an early oral manifestation of psoriasis and have described the relationship between GT and the severity of psoriasis by the *Psoriasis Area and Severity Index*. Furthermore, fissured tongue (FT), the oral condition most often associated with GT, has also been indicated as a late oral manifestation of psoriasis. It is believed that the prevalence of oral lesions would be even higher if patients with psoriasis underwent a thorough oral examination. In

addition, there are few studies with histological and genetic analyses on lesions of geographic tongue and its relation with psoriasis [14, 20].

GT is clinically classified as active or typical, when it is demarcated by a slightly raised white or keratotic border or intense red, and passive, abortive, or atypical if it lacks that edge or disappears before the end of the process of GT formation [21].

The recurrence of lesions even after the various therapeutic modalities does not follow a typical pattern for all patients. The incidence of geographic tongue in early psoriasis may be an indicator of disease severity [15].

In cases of recurrence, it is important to initially establish the correct diagnosis and exclude some differential diagnoses such as candidiasis, lichen planus, erythroplasia, lupus erythematosus, trauma, and drug reactions.

Some lifestyle changes such as doing physical activity, eating well, not smoking, and not abusing alcoholic beverages can considerably delay the recurrence of episodes that do not have a definite time [22].

2.2 Treatment

Treatment of GT is indicated only in symptomatic cases and often includes corticosteroids. However, there is no established treatment reported in literature. Multiple treatment modalities are resorted to, including antihistamines, anxiolytics, corticosteroids, topical anesthetics, nutritional supplements, and avoidance of spicy or acidic food [1, 4].

Laser therapy has known biological effects, such as the modulating action of inflammation. The ability to modulate various metabolic events through photophysical and biochemical processes explains the effects of this therapeutic modality [7]. Laser energy is absorbed only by a thin layer of adjacent tissue beyond the point reached by radiation. For this reason, it is recommended at the present time that low penetrating tissue lasers with wavelengths between 640 and 940 nm be used and that this application be performed in a punctual way and the one closest to the lesion.

This therapy is an effective, safe, and accessible treatment without incurring any systemic side effects, in contrast to biologic agents or other drugs. Moreover, phototherapy can be combined with biologic agents for the treatment of GT [6, 22].

Low-level light/laser therapy (LLLT) is widely used in dermatology, with effective results in the treatment of psoriasis. A preliminary study analyzed the efficiency of the combination of infrared laser (830 nm) and red laser (630 nm) in the treatment of recalcitrant psoriasis. Because of its ability of penetrating tissues and its photobiomodulatory action, LLLT is a promising bet in treatment of GT [7, 8].

The short-term side effects of phototherapy are usually mild and self-limiting occurring during treatment or within the first 24 h after treatment, such as erythema, edema, pruritus, pain, purpura, transient petechiae, blistering, and crusting. Pigmentary disorder, photoaging, cataracts, and carcinogenesis are main long-term side effects [9].

The majority of lasers used to deliver low-level laser therapy are composed of a gaseous mixture of helium and neon gas (He-Ne lasers) that emit red light (632.8 nm) in the region, or the majority of them are gallium arsenide (GaAs). The LLLT wavelength ranges from 600 to 1070 nm; however, lasers at 700–770 nm limit biochemical activity, although they are associated with greater penetration power [23]. Blue light (400–480 nm) safely improves GT lesions by reducing keratinocyte proliferative activity and modulating T-cell immune responses in either wavelength. Red light (620–770 nm) has the ability to penetrate tissues about 6 mm, stimulate mitochondrial activity, and reduce topical inflammation from macrophage modulation [7, 8, 24].

Comparatively, the diode that emits visible red light has a lower penetration power and is more suitable for tissue repair, whereas the diode with a longer wavelength and therefore emitting infrared laser has a greater capacity for penetration, with a higher indication only for analgesia. The control of the exacerbation of lesions of geographic tongue, using the low-intensity lasers, can be explained by its effects that increase the cellular metabolism, stimulating the mitochondrial activity and acting as analgesics, anti-inflammatory, and repairers of the tongue lesion [25].

When this modality of therapy is compared with the He-Ne (helium-neon) and GaAlAs (gallium-aluminum-arsenic) lasers, the literature is still precarious and requires comparative long-term experimental studies, so the choice of low-intensity laser is safe compared to other types of lasers.

Regarding the advantages of laser therapy in comparison to topical treatment, there is still a lack of long-term evidence of its effectiveness and whether there is any influence on the recurrence frequency of the lesions and the intensity of the symptoms. However, laser therapy consists of a therapeutic modality that is easy to perform by the skilled professional and easy to accept by the patient, being able to promote immediate analgesia without side effects, demonstrating a great clinical difference when compared to topical and/or systemic medications.

3. Conclusion

Finally, laser irradiation at green, red, or infrared wavelength with special parameters can change gene expression and release of various mediators in human and animal cells. While geographic tongue is a transient lesion, fissured tongue seems to be a permanent lesion of the tongue. Treatment of oral lesions is indicated only in symptomatic cases. Therefore, phototherapy will only be effective against geographic tongue if there is pain or burning sensation (**Figure 1**).

LLLT has been also commonly used in a variety of conditions for acceleration of healing and relief of pain and inflammation. Its advantages of noninvasion, few side effects, and measurable benefits merit to be explored in the treatment of GT [26–28].

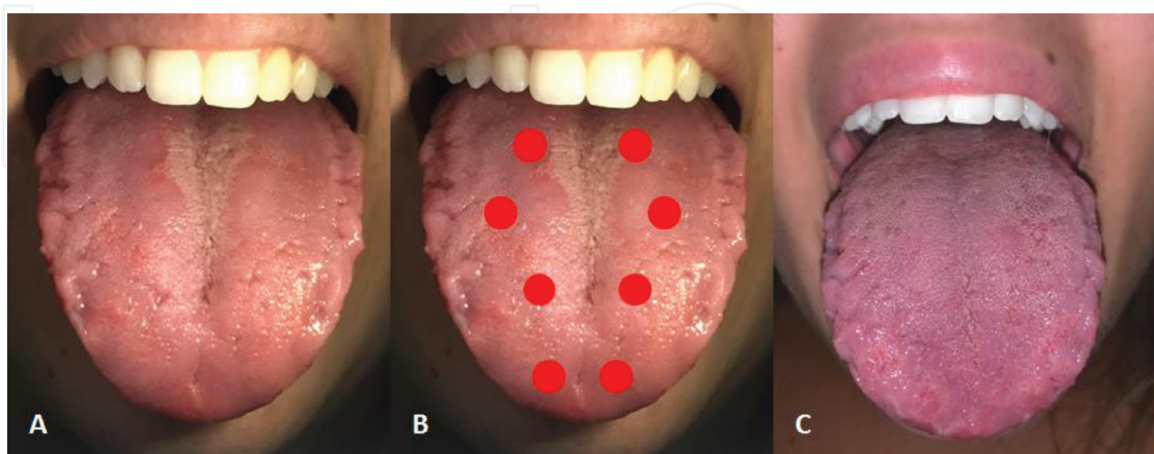


Figure 1. (A) Geographic tongue exhibiting white and red areas associated with fissured tongue. (B) Points of application of red LLLT 2 J with 1 cm of distance in all the dorsum of the tongue. (C) Partial regression after just one session of laser therapy.

IntechOpen

Author details

Fernanda Mombriani Pigatti^{1*}, Fabiana de Freitas Bombarda-Nunes²,
Lucas Fernandes Leal² and Thays Teixeira de Souza³

1 Department of Oral Pathology, School of Dentistry, Federal University of Juiz de Fora, Governador Valadares, Minas Gerais, Brazil

2 Department of Oral Pathology, School of Dentistry, FAESA University Center, Espírito Santo, Brazil

3 Department of Oral Pathology, School of Dentistry, Fluminense Federal University, Rio de Janeiro, Brazil

*Address all correspondence to: fer.pigatti@gmail.com

IntechOpen

© 2019 The Author(s). Licensee IntechOpen. This chapter is distributed under the terms of the Creative Commons Attribution License (<http://creativecommons.org/licenses/by/3.0>), which permits unrestricted use, distribution, and reproduction in any medium, provided the original work is properly cited. 

References

- [1] de Campos WG, Esteves CV, Fernandes LG, Domaneschi C, Júnior CAL. Treatment of symptomatic benign migratory glossitis: A systematic review. *Clinical Oral Investigations*. 2018;**22**(7):2487-2493
- [2] Purani JM, Purani HJ. Treatment of geographic tongue with topical tacrolimus. *BML Case Reports*. 2014;**2014**:bcr-2013-201268
- [3] Najafi S, Gholizadeh N, Akhavan Rezaayat E, Kharrazifard MJ. Treatment of symptomatic geographic tongue with triamcinolone acetonide alone and in combination with retinoic acid: A randomized clinical trial. *Journal of Dentistry (Tehran, Iran)*. 2016;**13**(1):23-28
- [4] Assimakopoulos D, Patrikakos G, Fotika C, Elisaf M. Benign migratory glossitis or geographic tongue: An enigmatic oral lesion. *The American Journal of Medicine*. 2002;**113**:751-755
- [5] Brodsky M, Abrouk M, Lee P, Kelly KM. Revisiting the history and importance of phototherapy in dermatology. *JAMA Dermatology*. 2017;**153**(5):435
- [6] Zhang P, Wu MX. A clinical review of phototherapy for psoriasis. *Lasers in Medical Science*. 2018;**33**(1):173-180
- [7] Avci P, Gupta A, Sadasivam M, Vecchio D, Pam Z, Pam N, et al. Low-level laser (light) therapy (LLLT) in skin: Stimulating, healing, restoring. *Seminars in Cutaneous Medicine and Surgery*. 2013;**32**(1):41-52
- [8] Chung H, Dai T, Sharma SK, Huang YY, Carroll JD, Hamblin MR. The nuts and bolts of low-level laser (light) therapy. *Annals of Biomedical Engineering*. 2012;**40**(2):516-533
- [9] Seebode C, Lehmann J, Emmert S. Photocarcinogenesis and skin cancer prevention strategies. *Anticancer Research*. 2016;**36**(3):1371-1378
- [10] Mutafchieva MZ et al. Effects of low-level laser therapy on erosive-atrophic oral lichen planus. *Folia Medica (Plovdiv)*. 2018;**60**(3):417-424
- [11] Picciani BL, Domingos TA, Teixeira-Souza T, Santos V de C, Gonzaga HF, Cardoso-Oliveira J, et al. Geographic tongue and psoriasis: Clinical, histopathological, immunohistochemical and genetic correlation—A literature review. *Anais Brasileiros de Dermatologia*. 2016;**91**(4):410-421
- [12] Picciani B, Santos VC, Teixeira-Souza T, Izahias LM, Curty Á, Avelleira JC, et al. Investigation of the clinical features of geographic tongue: Unveiling its relationship with oral psoriasis. *International Journal of Dermatology*. 2017;**56**(4):421-427
- [13] Miloğlu O, Göregen M, Akgül HM, Acemoğlu H. The prevalence and risk factors associated with benign migratory glossitis lesions in 7619 Turkish dental outpatients. *Oral Surgery, Oral Medicine, Oral Pathology, Oral Radiology, and Endodontics*. 2009;**107**:e29-e33
- [14] Jainkittivong A, Langlais RP. Geographic tongue: Clinical characteristics of 188 cases. *The Journal of Contemporary Dental Practice*. 2005;**6**:123-135
- [15] Picciani B, Silva-Junior G, Carneiro S, Sampaio AL, Goldemberg DC, Oliveira J, et al. Geographic stomatitis: An oral manifestation of psoriasis? *Journal of Dermatological Case Reports*. 2012;**6**:113-116

- [16] Raut AS, Prabhu RH, Patravale VB. Psoriasis clinical implications and treatment: A review. *Critical Reviews in Therapeutic Drug Carrier Systems*. 2013;**30**:183-216
- [17] Johnson MA, Armstrong AW. Clinical and histologic diagnostic guidelines for psoriasis: A critical review. *Clinical Reviews in Allergy and Immunology*. 2013;**44**:166-172
- [18] Bachelez H. Immunopathogenesis of psoriasis: Recent insights on the role of adaptive and innate immunity. *Journal of Autoimmunity*. 2005;**25**:69-73
- [19] Ulmansky M, Michelle R, Azaz B. Oral psoriasis: Report of six new cases. *Journal of Oral Pathology & Medicine*. 1995;**24**:42-45
- [20] Picciani BL, Silva-Junior GO, Michalski-Santos B, Avelleira JC, Azulay DR, Pires FR, et al. Prevalence of oral manifestations in 203 patients with psoriasis. *Journal of the European Academy of Dermatology and Venereology*. 2011;**25**:1481-1483
- [21] Hernández-Pérez F1, Jaimes-Aveldañez A, Urquizo-Ruvalcaba Mde L, Díaz-Barcelot M, Irigoyen-Camacho ME, et al. Prevalence of oral lesions in patients with psoriasis. *Medicina Oral, Patología Oral y Cirugía Bucal*. 2008;**13**:E703-E708
- [22] González-Álvarez L, García-Pola MJ, Garcia-Martin JM. Geographic tongue: Predisposing factors, diagnosis and treatment. A systematic review. *Revista Clínica Española*. 2018;**218**(9):481-488
- [23] Karu TI, Kolyakov SF. Exact action spectra for cellular responses relevant to phototherapy. *Photomedicine and Laser Surgery [Internet]*. 2005;**23**(4):355-361
- [24] Calzavara-Pinton PG, Sala R, Arisi M, Rossi MT, Venturini M, Ortel B. Synergism between narrowband ultraviolet B phototherapy and etanercept for the treatment of plaque-type psoriasis. *The British Journal of Dermatology*. 2013;**169**(1):130-136
- [25] Silveira PCL, da Silva LA, Fraga DB, Freitas TP, Streck EL, Pinho R. Evaluation of mitochondrial respiratory chain activity in muscle healing by low-level laser therapy. *Journal of Photochemistry and Photobiology B: Biology*. 2009;**95**(2):89-92
- [26] Weinstabl A, Hoff-Lesch S, Merk HF, von Felbert V. Prospective randomized study on the efficacy of blue light in the treatment of psoriasis vulgaris. *Dermatologica*. 2011;**223**:251-259
- [27] Zhang Q, Dong T, Li P, Wu MX. Noninvasive low-level laser therapy for thrombocytopenia. *Science Translational Medicine*. 2016;**8**(349):349 ra101
- [28] Zhang Q, Zhou C, Hamblin MR, Wu MX. Low-level laser therapy effectively prevents secondary brain injury induced by immediate early responsive gene X-1 deficiency. *Journal of Cerebral Blood Flow and Metabolism*. 2014;**34**(8):1391-1401